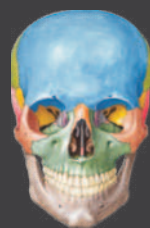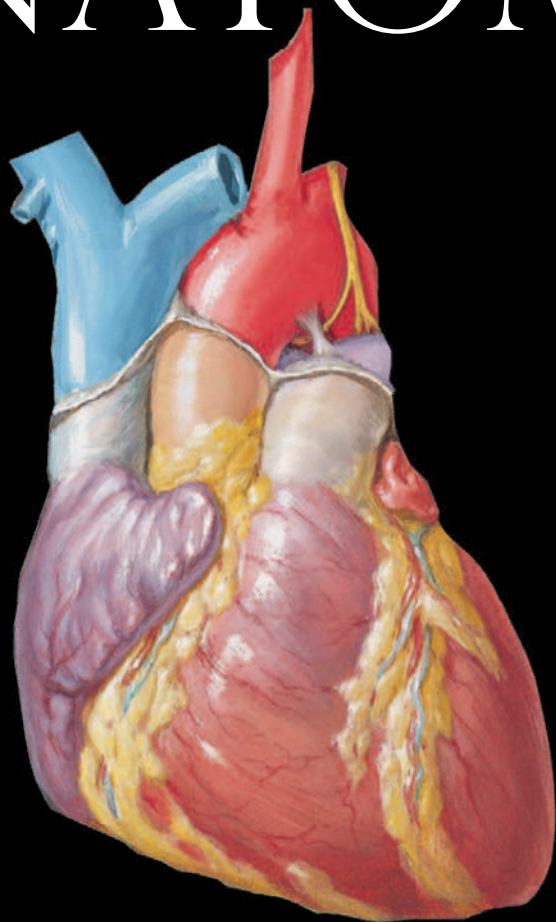


FRANK H. NETTER, MD



ATLAS OF HUMAN ANATOMY



NETTER

7

SEVENTH
EDITION

ELSEVIER

ELSEVIER

1600 John F. Kennedy Blvd.
Ste. 1800
Philadelphia, PA 19103-2899

ATLAS OF HUMAN ANATOMY, SEVENTH EDITION

Standard Edition: 978-0-323-39322-5
Professional Edition: 978-0-323-55428-2
International Edition: 978-0-323-39321-8

Copyright © 2019 by Elsevier Inc.

Previous editions copyrighted 2014, 2011, 2006, 2003, 1997, 1989

All rights reserved. No part of this publication may be reproduced or transmitted in any form or by any means, electronic or mechanical, including photocopying, recording, or any information storage and retrieval system, without permission in writing from the publisher. Details on how to seek permission, further information about the Publisher's permissions policies and our arrangements with organizations such as the Copyright Clearance Center and the Copyright Licensing Agency can be found at our website: www.elsevier.com/permissions.

This book and the individual contributions contained in it are protected under copyright by the Publisher (other than as may be noted herein).

Permission to use Netter Art figures may be sought through the website NetterImages.com or by emailing Elsevier's Licensing Department at H.Licensing@elsevier.com.

Notices

Knowledge and best practice in this field are constantly changing. As new research and experience broaden our understanding, changes in research methods, professional practices, or medical treatment may become necessary.

Practitioners and researchers must always rely on their own experience and knowledge in evaluating and using any information, methods, compounds, or experiments described herein. In using such information or methods they should be mindful of their own safety and the safety of others, including parties for whom they have a professional responsibility.

With respect to any drug or pharmaceutical products identified, readers are advised to check the most current information provided (i) on procedures featured or (ii) by the manufacturer of each product to be administered, to verify the recommended dose or formula, the method and duration of administration, and contraindications. It is the responsibility of practitioners, relying on their own experience and knowledge of their patients, to make diagnoses, to determine dosages and the best treatment for each individual patient, and to take all appropriate safety precautions.

To the fullest extent of the law, neither the Publisher nor the authors, contributors, or editors, assume any liability for any injury and/or damage to persons or property as a matter of products liability, negligence or otherwise, or from any use or operation of any methods, products, instructions, or ideas contained in the material herein.

International Standard Book Number: 978-0-323-39322-5

Executive Content Strategist: Elyse O'Grady
Senior Content Development Specialist: Marybeth Thiel
Publishing Services Manager: Patricia Tannian
Senior Project Manager: John Casey
Book Design: Patrick Ferguson

Printed in China

9 8 7 6 5 4 3 2 1



Working together
to grow libraries in
developing countries

www.elsevier.com • www.bookaid.org

CONSULTING EDITORS

Carlos A. G. Machado, MD
Chief Contributing Medical Illustrator

John T. Hansen, PhD

Lead Editor

Professor of Neuroscience
Former Chair of Neurobiology and Anatomy and
Associate Dean for Admissions
University of Rochester Medical Center
Rochester, New York

Brion Benninger, MD, MSc

Professor of Medical Innovation, Technology, &
Research; Professor of Clinical Anatomy
Executive Director, Chair, Medical Anatomy Center
Department of Medical Anatomical Sciences
Faculty College of Dentistry
Western University of Health Sciences
Lebanon Oregon;
Faculty, Sports Medicine Fellows, Orthopaedic and
General Surgery Residencies
Samaritan Health Services, Corvallis, Oregon;
Faculty, Surgery, Orthopedics & Rehabilitation, and Oral
Maxillofacial Surgery
Oregon Health & Science University
Portland, Oregon

Jennifer Brueckner-Collins, PhD

Professor and Vice Chair of Educational Programs
Department of Anatomical Sciences and Neurobiology
University of Louisville School of Medicine
Louisville, Kentucky

Todd M. Hoagland, PhD

Professor
Department of Cell Biology, Neurobiology, and Anatomy
Medical College of Wisconsin
Milwaukee, Wisconsin

R. Shane Tubbs, MS, PA-C, PhD

Chief Scientific Officer, and Vice President
Seattle Science Foundation
Seattle, Washington;
Professor of Anatomy
Department of Anatomical Sciences
St. George's University
Grenada, West Indies;
Centre of Anatomy and Human Identification
Dundee University
United Kingdom

EDITORS OF PREVIOUS EDITIONS

First Edition

Sharon Colacino, PhD

Second Edition

Arthur F. Dalley II, PhD

Third Edition

John T. Hansen, PhD

Fourth Edition

John T. Hansen, PhD
Jennifer K. Brueckner, PhD
Stephen W. Carmichael, PhD, DSc
Thomas R. Gest, PhD
Noelle A. Granger, PhD
Anil H. Waljii, MD, PhD

Fifth Edition

John T. Hansen, PhD
Brion Benninger, MD, MS
Jennifer K. Brueckner, PhD
Stephen W. Carmichael, PhD, DSc
Noelle A. Granger, PhD
R. Shane Tubbs, MS, PA-C, PhD

Sixth Edition

John T. Hansen, PhD
Brion Benninger, MD, MS
Jennifer Brueckner-Collins, PhD
Todd M. Hoagland, PhD
R. Shane Tubbs, MS, PA-C, PhD

INTERNATIONAL ADVISORY BOARD

Hassan Amiralli, MBBS, MS (Surg)

Professor and Chair
Department of Anatomy
American University of Antigua
College of Medicine
Antigua, West Indies

Nihal Apaydin, MD, PhD

Professor, Department of Anatomy
Faculty of Medicine
Vice Director, Brain Research Center
Ankara University
Ankara, Turkey

Keith E. Baynes, MD

Section Chief, MSK and General
Radiology
Associate Professor of Radiology
Medical College of Wisconsin
Milwaukee, Wisconsin

Francisco J. Caycedo, MD

Specialist in Foot and Ankle Surgery
Sports Medicine and
Musculoskeletal Ultrasound
OrthoSports Associates—St.
Vincent's Birmingham
Birmingham, Alabama

William E. Cullinan, PhD

Professor, Department of
Biomedical Sciences
Director, Integrative Neuroscience
Research Center
Dean, College of Health Sciences
Marquette University
Milwaukee, Wisconsin

Joe Iwanaga, DDS, PhD

Assistant Professor
Division of Gross and Clinical
Anatomy
Department of Anatomy
Kurume University School of
Medicine
Kurume, Japan

Christopher R. Kelly, MD

Clinical Fellow
Division of Cardiology
Columbia University Medical Center
New York, New York

Robert Louis, MD

Director, Skull Base and Pituitary
Tumor Program
Minimally Invasive Brain and Spine
Surgery
Hoag Neurosciences Institute
Newport Beach, California

Virginia T. Lyons, PhD

Associate Professor of Medical
Education
Associate Dean of Preclinical
Year 1
Geisel School of Medicine at
Dartmouth
Hanover, New Hampshire

Thazhumpal Chacko Mathew, PhD

Professor and Vice Dean for
Research, Training, and
Consultation
Faculty of Allied Health Sciences
Health Sciences Centre
Kuwait University
Kuwait City, Kuwait

Paul E. Neumann, MD

Professor, Department of Anatomy
and Neurobiology
Faculty of Medicine
Dalhousie University
Halifax, Nova Scotia, Canada

Eduardo Cotecchia Ribeiro, PhD

Associate Professor of Descriptive
and Topographic Anatomy
Department of Morphology and
Genetics
School of Medicine
Federal University of São Paulo
São Paulo, Brazil

Danielle F. Royer, PhD

Associate Professor
Cell and Developmental Biology
University of Colorado, Anschutz
Medical Campus
Aurora, Colorado

Jonathan Spratt, MB, BChir

Clinical Director of Radiology
Sunderland City Hospitals
Sunderland, United Kingdom
Former Examiner in Anatomy
Royal College of Radiologists
and Royal College of Surgeons of
England
Visiting Professor of Anatomy
St. George's University
Grenada, West Indies

Susan Standring, MBE, PhD, DSc

Professor Emeritus of Anatomy
Department of Anatomy
King's College London
London, United Kingdom

Mark E. Sturgill, DO

Pediatric and Neuroradiologist
Radiology Partners
Hopkinsville, Kentucky

William J. Swartz, PhD

Professor of Cell Biology and
Anatomy
Louisiana State University
Health Sciences Center
New Orleans, Louisiana

Kimberly Topp, PT, PhD

Professor and Chair
Department of Physical Therapy and
Rehabilitation Science
Department of Anatomy
University of California, San
Francisco
San Francisco, California

Ivan Varga, PhD

Professor of Anatomy, Histology,
and Embryology
Faculty of Medicine
Comenius University
Bratislava, Slovak Republic

Peter J. Ward, PhD

Associate Professor of Anatomy
West Virginia School of Osteopathic
Medicine
Lewisburg, West Virginia

Robert J. Ward, MD

Chief, Musculoskeletal Imaging and
Intervention
Director, Bone Densitometry
Department of Radiology
Tufts Medical Center
Director, Undergraduate Radiology
Education
Assistant Professor of Radiology and
Orthopedics
Tufts University School of Medicine
Boston, Massachusetts

Kristy A. Weir, PhD

School of Biomedical Sciences
The University of Queensland
St Lucia, Queensland, Australia

NEW TO THIS EDITION

With your copy of the Frank H. Netter, MD, *Atlas of Human Anatomy*, you own a collection of some of the most well-known depictions of human anatomy in medicine and healthcare. In addition to the famous work of Dr. Netter, with your copy of this 7th edition, you also have access to nearly 100 painted pieces by Carlos A. G. Machado, MD, one of the foremost medical illustrators working today. Dr. Machado's contributions to the *Atlas* highlight important views of anatomy that have become more clinically relevant in recent years— anatomic views that have resulted from improved dissection techniques and modern imaging. In addition, you have access to more than 50 carefully selected radiologic images that help bridge the idealized illustrated anatomy with living anatomy viewed in the clinic.

While numerous updates have been made to the illustrated plates and tables to make them easier to learn from, the most significant changes to this edition include:

Introductory Section

To fulfill the requests from many students and fans of Netter's *Atlas*, we have added a new opening section containing several overview plates. These plates provide the very first head-to-toe views in the *Atlas of Human Anatomy*!

Clinical Tables

The *Atlas of Human Anatomy* is the only anatomy atlas illustrated by physicians. Dr. Netter was a surgeon and Dr. Machado is a cardiologist. The views of anatomy in this atlas have always reflected a clinical perspective. In line with this clinical focus, and in congruence with integrated curricula in health and medicine, tables at the end of each regional section highlight the most commonly injured structures, as well as other structures with high clinical significance and commonly covered in anatomy courses. The tables provide students with quick summaries, organized by body system, and note where to best view these key structures in the illustrated plates.

New Art Plates by Dr. Machado

For this edition alone, over 25 new illustrations have been painted by Dr. Machado. Suggestions for new plates of additional anatomic views and concepts are submitted by students, faculty, anatomists, physicians, and others. Sometimes suggestions are solicited at major anatomy conferences with a "What Should Carlos Paint Next?" idea box. Decisions around which new plates are prioritized and given space in a new edition come from discussions among consulting editors. The new plates for this edition are largely those that portray structures with clinical significance (Fascial Columns of the Neck, Deep Veins of the Leg, Hip Bursae, and Vasculature of the Prostate) or those that are difficult to visualize (Infratemporal Fossa)—and, of course, the new additions created for the introductory section.


Terminology Updates

The *Atlas of Human Anatomy* uses terminology accepted (in Göttingen, Germany, on September 24, 2016) by the Federative International Programme on Anatomical Terminologies and published as updates to the 1998 *Terminologia Anatomica*. Numerous updates to terminology have been made, so in select cases, former terminology has been included within parentheses to assist with the transition.

New Radiologic Images

Over 50 radiologic images—some completely new views and others replacing existing views using newer imaging tools—are included in this edition. Images have been selected based on their utility to students studying gross anatomy.

Your *Atlas of Human Anatomy* content has been updated, created, and overseen by a team of dedicated and passionate consulting editors, with the help of a stellar international advisory board, and guided by the feedback of many students, educators, anatomists, and clinicians that love Netter's *Atlas*. Please feel free to comment on the Netter Images Facebook page or Twitter feeds or email us directly with your thoughts, suggestions, or questions at NetterAppFeedback@Elsevier.com.



To my dear wife, Vera

PREFACE TO THE FIRST EDITION

I have often said that my career as a medical artist for almost 50 years has been a sort of “command performance” in the sense that it has grown in response to the desires and requests of the medical profession. Over these many years, I have produced almost 4,000 illustrations, mostly for *The CIBA* (now *Netter*) *Collection of Medical Illustrations* but also for *Clinical Symposia*. These pictures have been concerned with the varied subdivisions of medical knowledge such as gross anatomy, histology, embryology, physiology, pathology, diagnostic modalities, surgical and therapeutic techniques, and clinical manifestations of a multitude of diseases. As the years went by, however, there were more and more requests from physicians and students for me to produce an atlas purely of gross anatomy. Thus, this atlas has come about, not through any inspiration on my part but rather, like most of my previous works, as a fulfillment of the desires of the medical profession.

It involved going back over all the illustrations I had made over so many years, selecting those pertinent to gross anatomy, classifying them and organizing them by system and region, adapting them to page size and space, and arranging them in logical sequence. Anatomy of course does not change, but our understanding of anatomy and its clinical significance does change, as do anatomical terminology and nomenclature. This therefore required much updating of many of the older pictures and even

revision of a number of them in order to make them more pertinent to today’s ever-expanding scope of medical and surgical practice. In addition, I found that there were gaps in the portrayal of medical knowledge as pictorialized in the illustrations I had previously done, and this necessitated my making a number of new pictures that are included in this volume.

In creating an atlas such as this, it is important to achieve a happy medium between complexity and simplification. If the pictures are too complex, they may be difficult and confusing to read; if oversimplified, they may not be adequately definitive or may even be misleading. I have therefore striven for a middle course of realism without the clutter of confusing minutiae. I hope that the students and members of the medical and allied professions will find the illustrations readily understandable, yet instructive and useful.

At one point, the publisher and I thought it might be nice to include a foreword by a truly outstanding and renowned anatomist, but there are so many in that category that we could not make a choice. We did think of men like Vesalius, Leonardo da Vinci, William Hunter, and Henry Gray, who of course are unfortunately unavailable, but I do wonder what their comments might have been about this atlas.

Frank H. Netter, MD
(1906–1991)

FRANK H. NETTER, MD

Frank H. Netter was born in New York City in 1906. He studied art at the Art Students League and the National Academy of Design before entering medical school at New York University, where he received his Doctor of Medicine degree in 1931. During his student years, Dr. Netter’s notebook sketches attracted the attention of the medical faculty and other physicians, allowing him to augment his income by illustrating articles and textbooks. He continued illustrating as a sideline after establishing a surgical practice in 1933, but he ultimately opted to give up his practice in favor of a full-time commitment to art. After service in the United States Army during World War II, Dr. Netter began his long collaboration with the CIBA Pharmaceutical Company (now Novartis Pharmaceuticals). This 45-year partnership resulted in the production of the extraordinary collection of medical art so familiar to physicians and other medical professionals worldwide.

Icon Learning Systems acquired the Netter Collection in July 2000 and continued to update Dr. Netter’s original paintings and to add newly commissioned paintings by artists trained in the style of Dr. Netter. In 2005, Elsevier Inc. purchased the Netter Collection and all publications from Icon Learning Systems. There are now over 50 publications featuring the art of Dr. Netter available through Elsevier Inc.

Dr. Netter’s works are among the finest examples of the use of illustration in the teaching of medical concepts. The 13-book *Netter Collection of Medical Illustrations*, which includes the greater part of the more than 20,000 paintings created by Dr. Netter, became and remains one of the most famous medical works ever published. *The Netter Atlas of Human Anatomy*, first published in 1989, presents the anatomic paintings from the Netter Collection. Now translated into 16 languages, it is the anatomy atlas of choice among medical and health professions students the world over.

The Netter illustrations are appreciated not only for their aesthetic qualities, but, more importantly, for their intellectual content. As Dr. Netter wrote in 1949 “clarification of a subject is the aim and goal of illustration. No matter how beautifully painted, how delicately and subtly rendered a subject may be, it is of little value as a *medical illustration* if it does not serve to make clear some medical point.” Dr. Netter’s planning, conception, point of view, and approach are what inform his paintings and what make them so intellectually valuable.

Frank H. Netter, MD, physician and artist, died in 1991.

ACKNOWLEDGMENTS

Carlos A. G. Machado, MD

I struck luck when joining this golden team of consulting editors exceedingly knowledgeable in the fields of clinical anatomy and medical education. It has been a great honor to work with and be under their guidance, as well as under the highly competent coordination of Elyse O'Grady and Marybeth Thiel, Elsevier's Executive Content Strategist and Senior Content Development Specialist, respectively.

This unique book would not exist without the genius of its creator, Dr. Frank Netter, to whom I owe special thanks, also in the name of generations of students and health professionals who, like myself, have learned so much from his incommensurable body of work.

I dedicate my work and express my most sincere thanks to my beloved parents, Carlos and Neide, who provided me with the foundation of my education; to my patient wife, Adriana, and talented daughter, Beatriz, for their love and support; to the students, teachers, and health professionals who rely on my work to learn and teach; to all the body donors and living friends that have respectively been the subjects of my studies and models of most of the illustrations I have created for the *Atlas*; and to my teachers Eugênio Cavalcante, Mário Fortes, and Paulo Carneiro for taking my interest in human/clinical anatomy much further.

John T. Hansen, PhD

At Elsevier I would like to thank Marybeth Thiel, Senior Content Development Specialist, Elyse O'Grady, Executive Content Strategist, John Casey, Senior Project Manager, Patricia Tannian, Publishing Services Manager, Julia Dummitt, Design Manager, Karen Giacomucci, Illustration Buyer, and Madelene Hyde, Publishing Director, for their continuous support and meticulous attention to detail during the development of this seventh edition of the *Atlas of Human Anatomy*. They, along with the entire editorial, production, design, and marketing teams at Elsevier have been a delight to work with and to know. I also wish to thank my consulting editors for their insightful and constructive suggestions as we strive to make every new edition of the *Atlas* better. I am also indebted to Carlos Machado for his superb artistic skill in producing and updating a number of plates that appear in this latest edition of the *Atlas*. His renderings of human anatomy are the perfect complement to the Netter images. In addition to my fellow editors, I wish to express my thanks to my faculty

colleagues at Rochester and to all my past and present students who have provided generous and constructive feedback and have enriched my life. Finally, I am indebted to my entire family for their continued support and especially to my wife, Paula. Their love and encouragement sustains me and is the source of all the happiness and joy I know.

Brion Benninger, MD, MSc

Every day I am thankful for my wife, Alison, and son, Jack, for the laughs we have as a family, often from my follies, which is such a tonic. I thank Elsevier, especially Marybeth Thiel, Elyse O'Grady, and Madelene Hyde for their professionalism and guidance, enabling John Hansen, Carlos Machado, and my fellow coeditors to work in a unique and dynamic environment. I thank those clinicians who trained me, especially my early gifted surgeon/anatomist/teacher mentors, Drs. Gerald Tressidor and Harold Ellis CBE (Cambridge & Guy's Hospital); Dr. S. Standing, who embodies professionalism and displays fortitude; Drs. P. Crone and J. Heatherington, and the University Board for their stellar support; my past and future students and patients; and clinical colleagues from all corners of the world who keep anatomy dynamic, fresh, and wanting more. Special thanks to Jim Diegel and Erik Szeto, friends, mentors and fellow visionaries who also see "outside the box," challenging status quo. A heartfelt tribute to my late mentors, friends, and sister, Jim McDaniel, Bill Bryan, and Gail Hendricks, all who represent what is good in teaching, caring, and healing. They made this world a wee bit better. Lastly, I thank my mother for her love of education and equality and my father for his inquisitive and creative mind.

Jennifer Brueckner-Collins, PhD

Many thanks to the Elsevier team, particularly Marybeth Thiel and Elyse O'Grady, for their guidance and expertise during our preparation of the seventh edition. It is always an honor to work with Carlos Machado, whose passion for and mastery of the art of clinical anatomy and medicine never cease to amaze me. I am forever indebted to Brian MacPherson, who has served as a teacher, mentor, and friend to me for more than 20 years....you showed me what it means to be a true educator and I have been so fortunate to have the opportunity to build a career based on those principles. To Kurt and Lincoln, you are my inspiration....my world....my life and I love you to the snow moon and back.

Todd M. Hoagland, PhD

It is a privilege to teach clinical human anatomy and I am eternally grateful to all the body donors and their families for enabling healthcare professionals to train in the dissection laboratory. It is my honor to work with outstanding medical students and colleagues at the Medical College of Wisconsin. I am grateful to John Hansen and the professionals of the Elsevier team for the opportunity to be a steward of the incomparable Netter's *Atlas*. Marybeth Thiel and Elyse O'Grady were especially helpful and a pleasure to work with. It was an honor to collaborate with the brilliant Carlos Machado and all the consulting editors. I thank Bill Swartz and Mark Moss for being outstanding mentors, and I thank all of the graduate students I've worked with, especially Rebecca Lufler. I am deeply appreciative of Stan Hillman and Jack O'Malley for inspiring me with masterful teaching and rigorous expectations. I am indebted to Gary Kolesari and Richard Hoyt Jr. for

helping me become a competent clinical anatomist, and to Rob Bouchie for his camaraderie. I am most grateful to my brother, Bill, for his unwavering optimism and gregarious nature. I thank my mother, Liz, for her dedication and love and for instilling a strong work ethic. Finally, I am humbled by my two awesome children, Ella and Caleb, for helping me redefine love, wonder, and joy.

R. Shane Tubbs, MS, PA-C, PhD

Elsevier and the Netter team have once again been a joy to work with. I thank Elyse O'Grady, Marybeth Thiel, and John Casey for their tremendous work on this edition. In addition, Carlos Machado has again added his expertise to bringing his anatomical images to life. As always, my work is inspired by my beautiful wife, Susan, and son, Isaiah. Lastly, I am indebted to my parents, Richard and Karon Tubbs, who supported me in my career to better understand the human body.



extern

www.extern.ir

مرجع داندود رایگان کتب پزشکی، پیراپزشکی، علوم پایه، دندان پزشکی و داروسازی
فیلم ها و تصاویر آموزشی پزشکی برای دانشجویان، اکسپرن ها، اینترن ها و رزیدنت ها
مرجع مقالات پزشکی و سلامتی بر اساس رفرنس های معتبر

CONTENTS

SECTION 1 INTRODUCTION Plates 1-7

Introduction Plates 1-7

- 1 Body Planes and Terms of Relationship
- 2 Surface Anatomy: Regions (Anterior View of Female)
- 3 Surface Anatomy: Regions (Posterior View of Male)
- 4 Major Arteries and Pulse Points
- 5 Major Systemic Veins of the Cardiovascular System
- 6 General Organization of the Nervous System
- 7 Overview of the Lymphatic System

Electronic Bonus Plates Plates BP1-BP16

- BP 1 Cross Section of Skin
- BP 2 Pilosebaceous Unit
- BP 3 Major Body Cavities
- BP 4 Skeletal System: Axial and Appendicular Skeletons
- BP 5 Types of Synovial Joints
- BP 6 Joints: Connective Tissues and Articular Cartilage
- BP 7 Architecture of Bone
- BP 8 Muscular System
- BP 9 Overview of the Gastrointestinal System
- BP 10 Overview of the Endocrine System
- BP 11 Neurons and Synapses
- BP 12 Features of a Typical Peripheral Nerve
- BP 13 Sites of Visceral Referred Pain
- BP 14 General Organization of the Cardiovascular System
- BP 15 Cardiovascular System: Composition of Blood
- BP 16 Arterial Wall

SECTION 2 HEAD AND NECK Plates 8-160

Surface Anatomy Plate 8

- 8 Head and Neck: Surface Anatomy

Superficial Head and Neck Plates 9-10

- 9 Cutaneous Nerves of Head and Neck
- 10 Superficial Arteries and Veins of Face and Scalp

Bones and Ligaments Plates 11-30

- 11 Skull: Anterior View
- 12 Skull: Radiographs
- 13 Skull: Lateral View
- 14 Skull: Lateral Radiograph
- 15 Skull: Midsagittal Section
- 16 Calvaria
- 17 Cranial Base: Inferior View
- 18 Cranial Base: Superior View
- 19 Foramina and Canals of Cranial Base: Inferior View
- 20 Foramina and Canals of Cranial Base: Superior View
- 21 Skull of Newborn
- 22 Bony Framework of Head and Neck
- 23 Pterygoid Fossae
- 24 Mandible
- 25 Temporomandibular Joint
- 26 Cervical Vertebrae: Atlas and Axis
- 27 Cervical Vertebrae (continued)
- 28 Cervical Vertebrae: Uncovertebral Joints
- 29 External Craniocervical Ligaments
- 30 Internal Craniocervical Ligaments

Neck Plates 31-41

- 31 Muscles of Facial Expression: Lateral View
- 32 Muscles of Neck: Anterior View
- 33 Fascial Layers of Neck
- 34 Cervical Fasciae
- 35 Infrahyoid and Suprahyoid Muscles
- 36 Muscles of Neck: Lateral View
- 37 Anterior and Lateral Cervical Muscles
- 38 Superficial Veins and Cutaneous Nerves of Neck
- 39 Nerves and Vessels of Neck
- 40 Nerves and Vessels of Neck (continued)
- 41 Carotid Arteries

Nasal Region Plates 42-64

- 42 Nose
- 43 Lateral Wall of Nasal Cavity
- 44 Lateral Wall of Nasal Cavity (continued)
- 45 Medial Wall of Nasal Cavity (Nasal Septum)
- 46 Nerves of Nasal Cavity
- 47 Arteries of Nasal Cavity: Bony Nasal Septum Turned Up
- 48 Nerves of Nasal Cavity: Bony Nasal Septum Turned Up
- 49 Nose and Maxillary Sinus: Transverse Section
- 50 Paranasal Sinuses: Coronal and Transverse Sections
- 51 Paranasal Sinuses: Parasagittal Views
- 52 Paranasal Sinuses: Changes with Age

53	Salivary Glands
54	Facial Nerve Branches and Parotid Gland
55	Muscles Involved in Mastication
56	Muscles Involved in Mastication (continued)
57	Maxillary Artery
58	Proximal Maxillary and Superficial Temporal Arteries
59	Mandibular Nerve (CN V ₃)
60	Superior View of Infratemporal Fossa
61	Ophthalmic (CN V ₁) and Maxillary (CN V ₂) Nerves
62	Autonomic Innervation of Nasal Cavity
63	Nerves and Arteries of the Deep Face
64	Orientation of Nerves and Vessels of the Cranial Base

Oral Region Plates 65-74

65	Inspection of Oral Cavity
66	Afferent Innervation of Oral Cavity and Tongue
67	Roof of Oral Cavity
68	Tongue and Salivary Glands: Sections
69	Floor of Oral Cavity
70	Tongue
71	Tongue (continued)
72	Fauces
73	Teeth
74	Teeth (continued)

Pharynx Plates 75-86

75	Muscles of Pharynx: Partially Opened Posterior View
76	Posterior View of Pharynx: Nerves and Vessels
77	Pharynx: Medial View
78	Muscles of Pharynx: Medial View
79	Pharynx: Opened Posterior View
80	Pharyngoesophageal Junction
81	Muscles of Pharynx: Lateral View
82	Nerves of Oral, Head, and Neck Regions
83	Arteries of Oral and Pharyngeal Regions
84	Veins of Face and Neck Regions
85	Lymph Vessels and Nodes of Head and Neck
86	Lymph Vessels and Nodes of Pharynx and Tongue

Thyroid Gland and Larynx Plates 87-93

87	Thyroid Gland: Anterior View
88	Thyroid Gland and Pharynx: Posterior View
89	Parathyroid Glands
90	Cartilages of Larynx
91	Intrinsic Muscles of Larynx
92	Nerves and Coronal Section of Larynx
93	Action of Intrinsic Muscles of Larynx

Orbit and Contents Plates 94-104

94	Eyelids
95	Lacrimal Apparatus
96	Extrinsic Eye Muscles
97	Nerves of Orbit
98	Superior and Anterior Views of Orbit
99	Arteries and Veins of Orbit and Eyelids
100	Eyeball: Transverse Section
101	Anterior and Posterior Chambers of Eyeball
102	Lens and Supporting Structures
103	Intrinsic Arteries and Veins of Eye
104	Vascular Supply of Eye

Ear Plates 105-110

105	Ear and Course of Sound in Cochlea
106	External Ear and Tympanic Cavity
107	Tympanic Cavity
108	Bony and Membranous Labyrinths
109	Bony and Membranous Labyrinths (continued)
110	Orientation of Labyrinths in Skull

Meninges and Brain Plates 111-126

111	Meninges and Diploic Veins
112	Meningeal Arteries
113	Meninges and Superficial Cerebral Veins
114	Dural Venous Sinuses: Sagittal Section
115	Dural Venous Sinuses (continued)
116	Brain: Lateral Views
117	Brain: Medial Views
118	Brain: Inferior View
119	Ventricles of Brain
120	Circulation of Cerebrospinal Fluid
121	Basal Nuclei (Ganglia)
122	Thalamus and Related Structures
123	Hippocampus and Fornix
124	Brain Stem
125	Ventricles and Cerebellum
126	Cerebellum

Cranial and Cervical Nerves Plates 127-146

127	Cranial Nerve Nuclei in Brain Stem: Schema
128	Cranial Nerve Nuclei in Brain Stem: Schema (continued)
129	Cranial Nerves (Motor and Sensory Distribution): Schema
130	Olfactory Nerve (CN I): Schema
131	Optic Nerve (CN II) (Visual Pathway): Schema

132	Oculomotor (CN III), Trochlear (CN IV), and Abducens (CN VI) Nerves: Schema
133	Trigeminal Nerve (CN V): Schema
134	Facial Nerve (CN VII): Schema
135	Vestibulocochlear Nerve (CN VIII): Schema
136	Glossopharyngeal Nerve (CN IX): Schema
137	Vagus Nerve (CN X): Schema
138	Accessory Nerve (CN XI): Schema
139	Hypoglossal Nerve (CN XII): Schema
140	Cervical Plexus: Schema
141	Autonomic Nerves in Neck
142	Autonomic Nerves in Head
143	Ciliary Ganglion: Schema
144	Pterygopalatine and Submandibular Ganglia: Schema
145	Otic Ganglion: Schema
146	Taste Pathways: Schema

Cerebral Vasculature Plates 147-158

147	Arteries to Brain and Meninges
148	Internal Carotid Artery in Petrous Part of Temporal Bone
149	Arteries to Brain: Schema
150	Arteries of Brain: Inferior Views
151	Cerebral Arterial Circle (of Willis)
152	Arteries of Brain: Frontal View and Section
153	Arteries of Brain: Lateral and Medial Views
154	Arteries of Posterior Cranial Fossa
155	Veins of Posterior Cranial Fossa
156	Deep Veins of Brain
157	Subependymal Veins of Brain
158	Hypothalamus and Hypophysis

Regional Imaging Plates 159-160

159	Cranial Imaging (MRA and MRV)
160	Cranial Imaging (MRI)

Structures with High Clinical Significance Tables 2.1-2.3

Muscle Tables Tables 2.4-2.9

Electronic Bonus Plates Plates BP17-BP32

BP17	3D Skull Reconstruction CTs
BP18	Degenerative Changes in Cervical Vertebrae
BP19	Atlantooccipital Junction
BP20	Muscles of Facial Expression: Anterior View
BP21	Musculature of Face
BP22	Paranasal Sinuses

- BP23 Subclavian Artery
- BP24 Opening of the Mandible
- BP25 Afferent Innervation of Oral Cavity and Pharynx
- BP26 Fasciae of Orbit and Eyeball
- BP27 Tympanic Cavity
- BP28 Anatomy of the Pediatric Ear
- BP29 Auditory Tube (Eustachian)
- BP30 Arteries and Veins of Hypothalamus and Hypophysis
- BP31 Cranial Imaging (MRV and MRA)
- BP32 Axial and Coronal MRIs of Brain

SECTION 3 BACK AND SPINAL CORD Plates 161-186

Surface Anatomy Plate 161

- 161 Back: Surface Anatomy

Bones and Ligaments Plates 162-168

- 162 Vertebral Column
- 163 Thoracic Vertebrae
- 164 Lumbar Vertebrae
- 165 Vertebrae: Radiograph and MRI
- 166 Sacrum and Coccyx
- 167 Vertebral Ligaments: Lumbosacral Region
- 168 Vertebral Ligaments: Lumbar Region

Spinal Cord Plates 169-179

- 169 Spinal Cord and Anterior Rami
- 170 Relation of Spinal Nerve Roots to Vertebrae
- 171 Dermatomes
- 172 Sympathetic Nervous System: Schema
- 173 Parasympathetic Nervous System: Schema
- 174 Spinal Meninges and Nerve Roots
- 175 Spinal Nerve Origin: Cross Sections
- 176 Arteries of Spinal Cord: Schema
- 177 Arteries of Spinal Cord: Intrinsic Distribution
- 178 Veins of Spinal Cord and Vertebral Column
- 179 Veins of Vertebral Column: Vertebral Veins

Muscles and Nerves Plates 180-184

- 180 Muscles of Back: Superficial Layer
- 181 Muscles of Back: Intermediate Layer
- 182 Muscles of Back: Deep Layer
- 183 Nerves of Back
- 184 Suboccipital Triangle

Cross-Sectional Anatomy Plates 185-186

- 185 Lumbar Region of Back: Cross Section
- 186 Typical Thoracic Spinal Nerve: Cross Section

Structures with High Clinical Significance Table 3.1

Muscle Tables Tables 3.2-3.3

Electronic Bonus Plates Plates BP33-BP43

- BP33 Vertebral Ligaments
- BP34 Cervical Spine: Radiographs
- BP35 Cervical Spine: MRI and Radiograph
- BP36 Thoracolumbar Spine: Lateral Radiograph
- BP37 Lumbar Vertebrae: Radiographs
- BP38 Lumbar Spine: MRIs
- BP39 Sympathetic Nervous System: General Topography
- BP40 Parasympathetic Nervous System: General Topography
- BP41 Cholinergic and Adrenergic Synapses: Schema
- BP42 Vertebral Veins: Detail Showing Venous Communications
- BP43 Spinal Cord Cross Sections: Fiber Tracts

SECTION 4 THORAX Plates 187-248

Surface Anatomy Plate 187

- 187 Thorax: Surface Anatomy

Mammary Gland Plates 188-191

- 188 Mammary Gland
- 189 Arteries of Mammary Gland
- 190 Lymph Vessels and Nodes of Mammary Gland
- 191 Lymphatic Drainage of Breast

Body Wall Plates 192-201

- 192 Bony Framework of Thorax
- 193 Ribs and Associated Joints
- 194 Anterior Thoracic Wall
- 195 Anterior Thoracic Wall (continued)
- 196 Anterior Thoracic Wall: Internal View
- 197 Intercostal Nerves and Arteries
- 198 Veins of Internal Thoracic Wall
- 199 Phrenic Nerve
- 200 Respiratory Diaphragm: Thoracic Surface
- 201 Respiratory Diaphragm: Abdominal Surface

Lungs Plates 202-214

202	Topography of Lungs: Anterior View
203	Topography of Lungs: Posterior View
204	Lungs in Situ: Anterior View
205	Lungs: Medial Views
206	Bronchopulmonary Segments
207	Bronchopulmonary Segments (continued)
208	Trachea and Major Bronchi
209	Bronchi and Intrapulmonary Airways
210	Great Vessels of Superior Mediastinum
211	Bronchial Arteries and Veins
212	Lymph Vessels and Nodes of Lung
213	Autonomic Nerves of Thorax
214	Innervation of Tracheobronchial Tree: Schema

Heart Plates 215-233

215	Heart in Situ
216	Heart: Anterior Exposure
217	Heart: Radiographs and CT Angiogram; Auscultation of Heart
218	Heart: Base and Diaphragmatic Surface
219	Pericardial Sac
220	Mediastinum: Cross Section
221	Thorax: Coronal Section of Heart and Ascending Aorta
222	Coronary Arteries and Cardiac Veins
223	Coronary Arteries: Imaging
224	Right Atrium and Ventricle
225	Left Atrium and Ventricle
226	Valves and Fibrous Skeleton of Heart
227	Valves and Fibrous Skeleton of Heart (continued)
228	Atria, Ventricles, and Interventricular Septum
229	Conducting System of Heart
230	Nerves of Thorax
231	Innervation of Heart: Schema
232	Innervation of Blood Vessels: Schema
233	Prenatal and Postnatal Circulation

Mediastinum Plates 234-243

234	Mediastinum: Right Lateral View
235	Mediastinum: Left Lateral View
236	Esophagus in Situ
237	Topography and Constrictions of Esophagus
238	Musculature of Esophagus
239	Esophagogastric Junction
240	Arteries of Esophagus
241	Veins of Esophagus
242	Lymph Vessels and Nodes of Esophagus
243	Nerves of Esophagus

Regional Scans Plate 244

244 Chest Scans: Axial CT Images

Cross-Sectional Anatomy Plates 245-248

245 Cross Section of Thorax at T3 Level
246 Cross Section of Thorax at T3-4 Disc Level
247 Cross Section of Thorax at T4-5 Disc Level
248 Cross Section of Thorax at T7 Level

Structures with High Clinical Significance Tables 4.1-4.2**Muscle Table** Table 4.3**Electronic Bonus Plates** Plates BP44-BP57

BP44 Respiratory System
BP45 Cervical Ribs and Related Anomalies
BP46 Muscle Attachments of Ribs
BP47 Muscles of Respiration
BP48 Intrapulmonary Airways: Schema
BP49 Intrapulmonary Blood Circulation: Schema
BP50 Gas Exchange
BP51 Anterior Aspect of Heart
BP52 Coronary Arteries: Right Anterior Oblique Views with Arteriograms
BP53 Coronary Arteries and Cardiac Veins: Variations
BP54 Intrinsic Nerves and Variations in Nerves of Esophagus
BP55 Arteries of Esophagus: Variations
BP56 Thorax: Coronal Section (Midaxillary Line, Tracheal Bifurcation, Left Atrium)
BP57 Thorax: Coronal CTs

SECTION 5 ABDOMEN Plates 249-332**Surface Anatomy** Plate 249

249 Abdomen: Surface Anatomy

Body Wall Plates 250-269

250 Bony Framework of Abdomen
251 Regions and Planes of Abdomen
252 Anterior Abdominal Wall: Superficial Dissection
253 Anterior Abdominal Wall: Intermediate Dissection
254 Anterior Abdominal Wall: Deep Dissection
255 Rectus Sheath: Cross Section
256 Anterior Abdominal Wall: Internal View

257	Posterolateral Abdominal Wall
258	Arteries of Anterior Abdominal Wall
259	Veins of Anterior Abdominal Wall
260	Nerves of Anterior Abdominal Wall
261	Thoracoabdominal Nerves
262	Inguinal Region: Dissections
263	Inguinal Canal and Spermatic Cord
264	Femoral Sheath and Inguinal Canal
265	Posterior Abdominal Wall: Internal View
266	Arteries of Posterior Abdominal Wall
267	Veins of Posterior Abdominal Wall
268	Lymph Vessels and Nodes of Posterior Abdominal Wall
269	Nerves of Posterior Abdominal Wall

Peritoneal Cavity Plates 270-275

270	Greater Omentum and Abdominal Viscera
271	Mesenteric Relations of Intestines
272	Mesenteric Relations of Intestines (continued)
273	Omental Bursa: Stomach Reflected
274	Omental Bursa: Cross Section
275	Peritoneum of Posterior Abdominal Wall

Viscera (Gut) Plates 276-283

276	Stomach in Situ
277	Mucosa of Stomach
278	Duodenum in Situ
279	Mucosa and Musculature of Small Intestine
280	Ileocecal Region
281	Ileocecal Region (continued)
282	(Vermiform) Appendix
283	Mucosa and Musculature of Large Intestine

Viscera (Accessory Organs) Plates 284-289

284	Surfaces and Bed of Liver
285	Liver in Situ: Vascular and Duct Systems
286	Liver Structure: Schema
287	Gallbladder, Extrahepatic Bile Ducts, and Pancreatic Duct
288	Pancreas in Situ
289	Spleen

Visceral Vasculature Plates 290-299

290	Arteries of Stomach, Liver, and Spleen
291	Arteries of Liver, Pancreas, Duodenum, and Spleen
292	Celiac Arteriogram and CT Angiogram
293	Arteries of Duodenum and Head of Pancreas
294	Arteries of Small Intestine
295	Arteries of Large Intestine

296	Veins of Stomach, Duodenum, Pancreas, and Spleen
297	Veins of Small Intestine
298	Veins of Large Intestine
299	Hepatic Portal Vein Tributaries: Portacaval Anastomoses

Innervation Plates 300-310

300	Autonomic Nerves and Ganglia
301	Autonomic Innervation of Stomach and Duodenum
302	Autonomic Innervation of Stomach and Duodenum (continued)
303	Autonomic Innervation of Esophagus, Stomach, and Duodenum: Schema
304	Autonomic Innervation of Small Intestine
305	Autonomic Innervation of Large Intestine
306	Autonomic Innervation of Intestines: Schema
307	Autonomic Reflex Pathways: Schema
308	Enteric Plexuses of Intestine
309	Autonomic Innervation of Liver: Schema
310	Autonomic Innervation of Pancreas: Schema

Kidneys and Suprarenal Glands Plates 311-324

311	Kidneys in Situ: Anterior Views
312	Kidneys in Situ: Posterior Views
313	Renal Artery and Vein in Situ
314	Gross Structure of Kidney
315	Intrarenal Arteries and Renal Segments
316	Ureters in Abdomen and Pelvis
317	Arteries of Ureters and Urinary Bladder
318	Renal Fasciae
319	Lymph Vessels and Nodes of Kidneys and Urinary Bladder
320	Autonomic Nerves of Kidneys, Ureters, and Urinary Bladder
321	Autonomic Innervation of Kidneys and Upper Ureters: Schema
322	Autonomic Nerves of Suprarenal Glands: Dissection and Schema
323	Arteries and Veins of Suprarenal Glands in Situ
324	Abdominal Wall and Viscera: Paramedian (Parasagittal) Section

Lymphatics Plate 325

325	Abdominal and Pelvic Lymphatics: Schema
-----	---

Regional Scans Plates 326-327

326	Abdominal Scans: Axial CT Images
327	Abdominal Scans: Axial CT Images (continued)

Cross-Sectional Anatomy Plates 328-332

328	Cross Section at T10, Esophagogastric Junction
329	Cross Section at T12, Inferior to Xiphoid
330	Cross Section at T12–L1, Intervertebral Disc
331	Cross Section at L1–2, Intervertebral Disc
332	Cross Section at L3–4

Structures with High Clinical Significance Tables 5.1-5.2**Muscle Table** Table 5.3**Electronic Bonus Plates** Plates BP58-BP87

BP58	Inguinal and Femoral Regions
BP59	Indirect Inguinal Hernia
BP60	Variations in Position and Contour of Stomach in Relation to Body Habitus
BP61	Layers of Duodenal Wall
BP62	CT and MRCP Showing Appendix, Gallbladder, and Ducts; Nerve Branches of Hepatic Artery
BP63	Topography of Liver
BP64	Variations in Form of Liver
BP65	Sigmoid Colon: Variations in Position
BP66	Variations in Arterial Supply to Cecum and Posterior Peritoneal Attachment of Cecum
BP67	Variations in Pancreatic Duct
BP68	Variations in Cystic, Hepatic, and Pancreatic Ducts
BP69	Variations in Cystic Arteries
BP70	Variations in Hepatic Arteries
BP71	Variations and Anomalies of Hepatic Portal Vein
BP72	Variations in Celiac Trunk
BP73	Variations in Colic Arteries
BP74	Variations in Colic Arteries (continued)
BP75	Variations in Renal Artery and Vein
BP76	Histology of Renal Corpuscle
BP77	Nephron and Collecting Tubule: Schema
BP78	Blood Vessels in Parenchyma of Kidney: Schema
BP79	Lymph Vessels and Nodes of Stomach
BP80	Lymph Vessels and Nodes of Pancreas
BP81	Lymph Vessels and Nodes of Small Intestine
BP82	Lymph Vessels and Nodes of Large Intestine
BP83	Lymph Vessels and Nodes of Liver
BP84	Schematic Cross Section of Abdomen at Middle T12
BP85	Transverse Section of Abdomen: Level of L5, Near Transtubercular Plane
BP86	Transverse Section of Abdomen: Level of S1, Anterior Superior Iliac Spine
BP87	Axial CT Image of Upper Abdomen

SECTION 6 PELVIS AND PERINEUM Plates 333-401

Surface Anatomy Plate 333

333 Pelvis and Perineum: Surface Anatomy

Bones and Ligaments Plates 334-338

334 Bony Framework of Pelvis
335 Male and Female Pelvis: Radiographs
336 Sex Differences of Pelvis: Measurements
337 Bones and Ligaments of Pelvis
338 Bones and Ligaments of Pelvis (continued)

Pelvic Floor and Contents Plates 339-349

339 Pelvic Diaphragm: Female
340 Pelvic Diaphragm: Female (continued)
341 Pelvic Diaphragm: Female (continued)
342 Pelvic Diaphragm: Male
343 Pelvic Diaphragm: Male (continued)
344 Pelvic Contents: Female
345 Pelvic Viscera and Perineum: Female
346 Pelvic Viscera: Female
347 Endopelvic Fascia and Potential Spaces
348 Pelvic Contents: Male
349 Pelvic Viscera and Perineum: Male

Urinary Bladder Plates 350-352

350 Urinary Bladder: Orientation and Supports
351 Female Sphincters
352 Urinary Bladder: Female and Male

Uterus, Vagina, and Supporting Structures Plates 353-357

353 Uterus, Vagina, and Supporting Structures
354 Uterus: Fascial Ligaments
355 Uterus and Adnexa
356 Female Pelvic Relationships
357 Pelvic Ligaments

Perineum and External Genitalia: Female Plates 358-361

358 Female Perineum and External Genitalia (Pudendum or Vulva)
359 Female Perineum (Superficial Dissection)
360 Female Perineum and Deep Perineum
361 Female Perineal Spaces

Perineum and External Genitalia: Male Plates 362-369

- 362 Male Perineum and External Genitalia (Superficial Dissection)
- 363 Male Perineum and External Genitalia (Deeper Dissection)
- 364 Penis
- 365 Male Perineal Spaces
- 366 Prostate Gland and Seminal Vesicles
- 367 Urethra
- 368 Descent of Testis
- 369 Scrotum and Contents

Homologues of Genitalia Plates 370-371

- 370 Homologues of External Genitalia
- 371 Homologues of Internal Genitalia

Testis, Epididymis, and Ductus Deferens Plate 372

- 372 Testis, Epididymis, and Ductus Deferens

Rectum Plates 373-378

- 373 Rectum in Situ: Female and Male
- 374 Ischioanal Fossae
- 375 Rectum and Anal Canal
- 376 Anorectal Musculature
- 377 External Anal Sphincter Muscle: Perineal Views
- 378 Actual and Potential Perineopelvic Spaces

Regional Scan Plate 379

- 379 Pelvic Scans: Sagittal T2-Weighted MRIs

Vasculature Plates 380-390

- 380 Arteries of Rectum and Anal Canal: Male Posterior View
- 381 Veins of Rectum and Anal Canal: Female Anterior View
- 382 Arteries and Veins of Pelvic Organs: Female Anterior View
- 383 Arteries and Veins of Testis: Anterior View
- 384 Arteries of Pelvis: Female
- 385 Arteries and Veins of Pelvis: Male
- 386 Arteries and Veins of Perineum and Uterus
- 387 Arteries and Veins of Perineum: Male
- 388 Lymph Vessels and Nodes of Pelvis and Genitalia: Female
- 389 Lymph Vessels and Nodes of Perineum: Female
- 390 Lymph Vessels and Nodes of Pelvis and Genitalia: Male

Innervation Plates 391-399

- 391 Nerves of External Genitalia: Male
- 392 Nerves of Pelvic Viscera: Male
- 393 Nerves of Perineum: Male

394	Nerves of Pelvic Viscera: Female
395	Nerves of Perineum and External Genitalia: Female
396	Neuropathways in Parturition
397	Innervation of Female Reproductive Organs: Schema
398	Innervation of Male Reproductive Organs: Schema
399	Innervation of Urinary Bladder and Lower Ureter: Schema

Cross-Sectional Anatomy Plates 400-401

400	Male Pelvis: Cross Section of Bladder–Prostate Gland Junction
401	Female Pelvis: Cross Section of Vagina and Urethra

Structures with High Clinical Significance Tables 6.1-6.2

Muscle Tables Tables 6.3-6.4

Electronic Bonus Plates Plates BP88-BP98

BP88	Fasciae of Male and Female Pelvis and Perineum
BP89	Male and Female Cystourethrograms
BP90	Female Urethra
BP91	Genetics of Reproduction
BP92	Menstrual Cycle
BP93	Testes
BP94	Uterine Development
BP95	Ovary, Ova, and Follicles
BP96	Variations in Hymen
BP97	Cross Section Through Prostate
BP98	Arteries and Veins of Pelvis: Male

SECTION 7 UPPER LIMB Plates 402-470

Surface Anatomy Plate 402

402	Upper Limb: Surface Anatomy
-----	-----------------------------

Cutaneous Anatomy Plates 403-407

403	Dermatomes of Upper Limb and Segmental Nerve Function
404	Cutaneous Innervation of Upper Limb
405	Cutaneous Nerves and Superficial Veins of Proximal Upper Limb
406	Cutaneous Nerves and Superficial Veins of Forearm and Hand
407	Lymph Vessels and Nodes of Upper Limb

Shoulder and Axilla Plate 408-420

- 408 Clavicle and Sternoclavicular Joint
- 409 Humerus and Scapula: Anterior Views
- 410 Humerus and Scapula: Posterior Views
- 411 Shoulder: Anteroposterior Radiograph
- 412 Shoulder with Details of Glenohumeral Joint
- 413 Muscles of Shoulder
- 414 Axilla: Posterior Wall
- 415 Muscles of Rotator (Compressor) Cuff
- 416 Pectoral, Clavipectoral, and Axillary Fasciae
- 417 Scapulothoracic and Shoulder Dissection
- 418 Axillary Artery and Anastomoses Around Scapula
- 419 Axilla: Anterior View
- 420 Brachial Plexus: Schema

- 421 Muscles of Arm: Anterior Views
- 422 Muscles of Arm: Posterior Views
- 423 Brachial Artery in Situ
- 424 Arteries of Arm and Proximal Forearm
- 425 Arm: Serial Cross Sections

Elbow and Forearm Plates 426-441

- 426 Bones of Elbow
- 427 Elbow: Radiographs
- 428 Ligaments of Elbow
- 429 Bones of Forearm
- 430 Individual Muscles of Forearm: Rotators of Radius
- 431 Individual Muscles of Forearm: Extensors of Wrist and Digits
- 432 Individual Muscles of Forearm: Flexors of Wrist
- 433 Individual Muscles of Forearm: Flexors of Digits
- 434 Muscles of Forearm (Superficial Layer): Posterior View
- 435 Muscles of Forearm (Deeper Layer): Posterior View
- 436 Muscles of Forearm (Superficial Layer): Anterior View
- 437 Muscles of Forearm (Intermediate Layer): Anterior View
- 438 Muscles of Forearm (Deep Layer): Anterior View
- 439 Attachments of Muscles of Forearm: Anterior View
- 440 Attachments of Muscles of Forearm: Posterior View
- 441 Forearm: Serial Cross Sections, Anterior View

Wrist and Hand Plates 442-461

- 442 Carpal Bones
- 443 Movements of Wrist
- 444 Ligaments of Wrist
- 445 Ligaments of Wrist (continued)
- 446 Bones of Wrist and Hand

447	Wrist and Hand: Radiographs
448	Metacarpophalangeal and Interphalangeal Ligaments
449	Wrist and Hand: Superficial Palmar Dissections
450	Wrist and Hand: Deeper Palmar Dissections
451	Lumbrical Muscles and Bursae, Spaces, and Sheaths: Schema
452	Flexor Tendons, Arteries, and Nerves at Wrist
453	Bursae, Spaces, and Tendon Sheaths of Hand
454	Flexor and Extensor Tendons in Fingers
455	Intrinsic Muscles of Hand
456	Arteries and Nerves of Hand: Palmar Views
457	Wrist and Hand: Superficial Dissection
458	Wrist and Hand: Superficial Dorsal Dissection
459	Nerves and Arteries of Dorsal Hand and Wrist
460	Extensor Tendons at Wrist
461	Fingers

Neurovasculature Plates 462-469

462	Cutaneous Innervation of Wrist and Hand
463	Arteries and Nerves of Upper Limb: Anterior View
464	Nerves of Upper Limb
465	Musculocutaneous Nerve: Anterior View
466	Median Nerve
467	Ulnar Nerve
468	Radial Nerve in Arm and Nerves of Posterior Shoulder: Posterior View
469	Radial Nerve in Forearm and Hand

Regional Imaging Plate 470

470	Shoulder MRI and CT Scan
-----	--------------------------

Structures with High Clinical Significance Tables 7.1-7.2

Muscle Tables Tables 7.3-7.6

Electronic Bonus Plates Plates BP99-BP106

BP99	Veins of Upper Limb
BP100	Arteries of Arm and Proximal Forearm
BP101	Arteries of Forearm and Hand
BP102	Ligaments of Wrist
BP103	Flexor and Extensor Zones of Hand
BP104	Section Through Metacarpal and Distal Carpal Bones
BP105	Cross Section of Hand: Axial View
BP106	Cross Section of Hand: Axial View (continued)

SECTION 8 LOWER LIMB Plates 471-535

Surface Anatomy Plate 471

471 Lower Limb: Surface Anatomy

Cutaneous Anatomy Plates 472-475

472 Dermatomes of Lower Limb and Segmental Nerve Function
473 Superficial Nerves and Veins of Lower Limb: Anterior View
474 Superficial Nerves and Veins of Lower Limb: Posterior View
475 Lymph Vessels and Nodes of Lower Limb

Hip and Thigh Plates 476-496

476 Coxal Bone
477 Hip Joint
478 Hip Joint: Anteroposterior Radiograph
479 Femur
480 Bony Attachments of Muscles of Hip and Thigh: Anterior View
481 Bony Attachments of Muscles of Hip and Thigh: Posterior View
482 Muscles of Thigh: Anterior Views
483 Muscles of Thigh: Anterior Views (continued)
484 Muscles of Hip and Thigh: Lateral View
485 Muscles of Hip and Thigh: Posterior Views
486 Psoas and Iliacus Muscles
487 Lumbosacral and Coccygeal Plexuses
488 Lumbar Plexus
489 Sacral and Coccygeal Plexuses
490 Arteries and Nerves of Thigh: Anterior Views
491 Arteries and Nerves of Thigh: Anterior Views (continued)
492 Arteries and Nerves of Thigh: Posterior View
493 Nerves of Hip and Buttock
494 Hip Bursae: Posterior and Anterolateral Views
495 Arteries of Femoral Head and Neck
496 Thigh: Serial Cross Sections

Knee Plates 497-503

497 Knee: Medial and Lateral Views
498 Knee: Anterior Views
499 Knee: Interior Views
500 Knee: Cruciate and Collateral Ligaments
501 Knee: Anteroposterior Radiograph and Posterior View
502 Knee: Posterior and Sagittal Views
503 Arteries of Lower Limb: Schema

Leg Plates 504-514

504	Tibia and Fibula
505	Tibia and Fibula (continued)
506	Attachments of Muscles of Leg
507	Muscles of Leg (Superficial Dissection): Posterior View
508	Muscles of Leg (Intermediate Dissection): Posterior View
509	Muscles of Leg (Deep Dissection): Posterior View
510	Muscles of Leg: Lateral View
511	Muscles of Leg (Superficial Dissection): Anterior View
512	Muscles of Leg (Deep Dissection): Anterior View
513	Venous Drainage of Leg
514	Leg: Cross Sections and Fascial Compartments

Ankle and Foot Plates 515-528

515	Bones of Foot
516	Bones of Foot (continued)
517	Calcaneus
518	Ligaments and Tendons of Ankle
519	Ligaments and Tendons of Foot: Plantar View
520	Tendon Sheaths of Ankle
521	Muscles of Dorsum of Foot: Superficial Dissection
522	Dorsum of Foot: Deep Dissection
523	Plantar Region of Foot: Superficial Dissection
524	Muscles of Plantar Region of Foot: First Layer
525	Muscles of Plantar Region of Foot: Second Layer
526	Muscles of Plantar Region of Foot: Third Layer
527	Interosseous Muscles and Deep Arteries of Foot
528	Interosseous Muscles of Foot

Neurovasculature Plates 529-533

529	Femoral Nerve and Lateral Femoral Cutaneous Nerve
530	Obturator Nerve
531	Sciatic Nerve and Posterior Femoral Cutaneous Nerve
532	Tibial Nerve
533	Common Fibular Nerve

Regional Imaging Plates 534-535

534	Hip MRI and 3D CT
535	Ankle: Radiographs

Structures with High Clinical Significance Tables 8.1-8.2

Muscle Tables Tables 8.3-8.6

Electronic Bonus Plates Plates BP107-BP117

- BP107 Veins of Lower Limb
- BP108 Arteries of Thigh and Knee
- BP109 Cross-Sectional Anatomy of Hip: Axial View
- BP110 Arteries of Knee and Foot
- BP111 Leg: Serial Cross Sections
- BP112 Osteology of Knee
- BP113 Knee Radiograph: Lateral View
- BP114 Anatomy of Foot: Nerves and Arteries
- BP115 Cross-Sectional Anatomy of Ankle and Foot
- BP116 Cross-Sectional Anatomy of Ankle and Foot (continued)
- BP117 Anatomy of Toenail

Download more ebooks from extern.ir

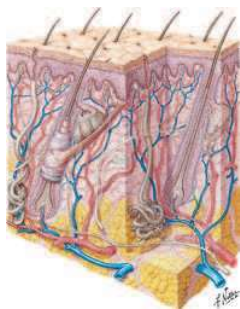
INTRODUCTION

1

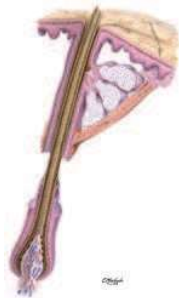Introduction

1-7

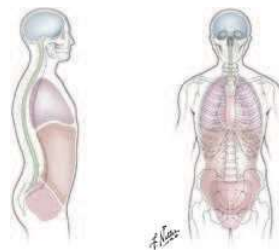ELECTRONIC BONUS PLATES



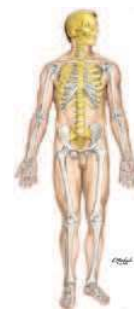BP 1 Cross Section of Skin



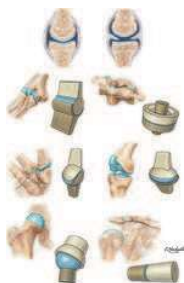BP 2 Pilosebaceous Unit



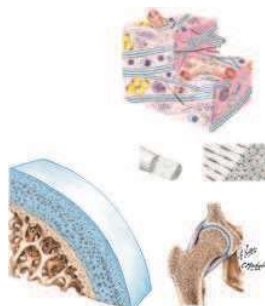BP 3 Major Body Cavities



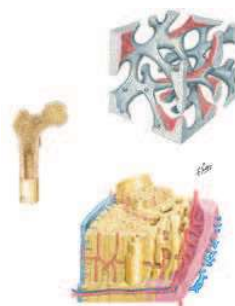
BP 4 Skeletal System:
Axial and Appendicular
Skeletons



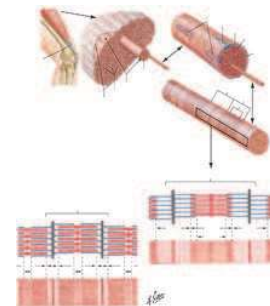
BP 5 Types of
Synovial Joints



BP 6 Joints: Connective
Tissues and Articular
Cartilage

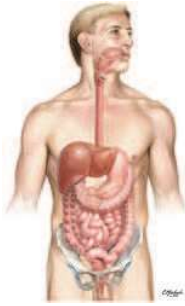

BP 7 Architecture of Bone

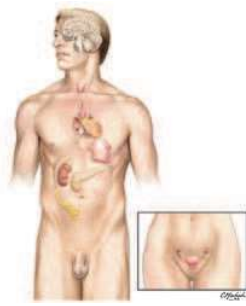

BP 8 Muscular System

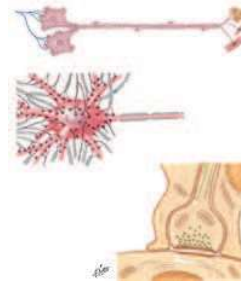
ELECTRONIC BONUS PLATES—*cont'd*



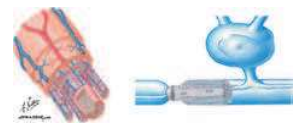BP 9 Overview of the Gastrointestinal System



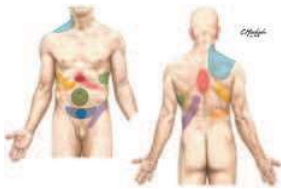
BP 10 Overview of the Endocrine System



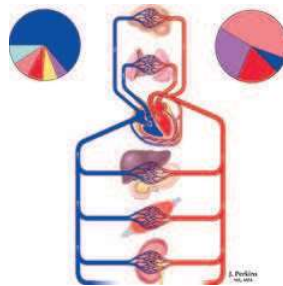
BP 11 Neurons and Synapses



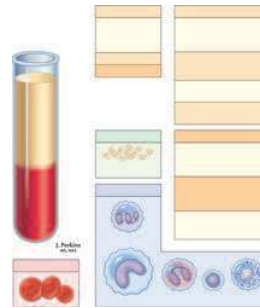
BP 12 Features of a Typical Peripheral Nerve



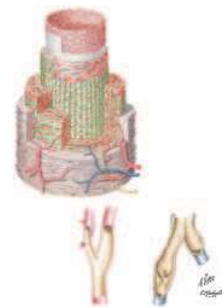BP 13 Sites of Visceral Referred Pain



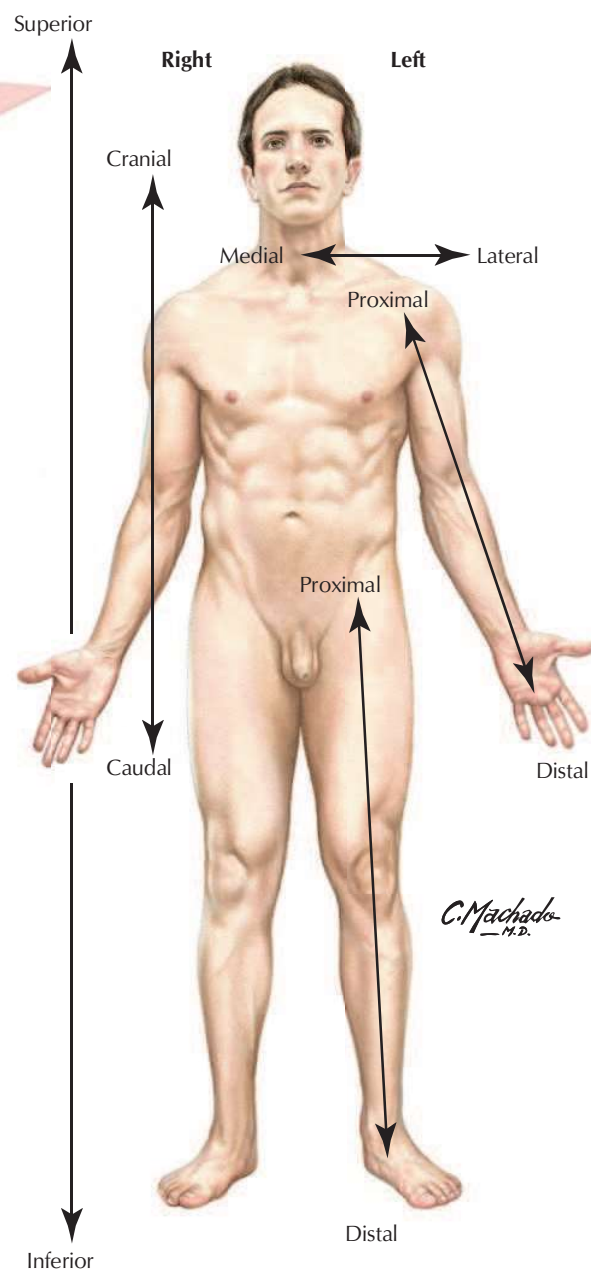
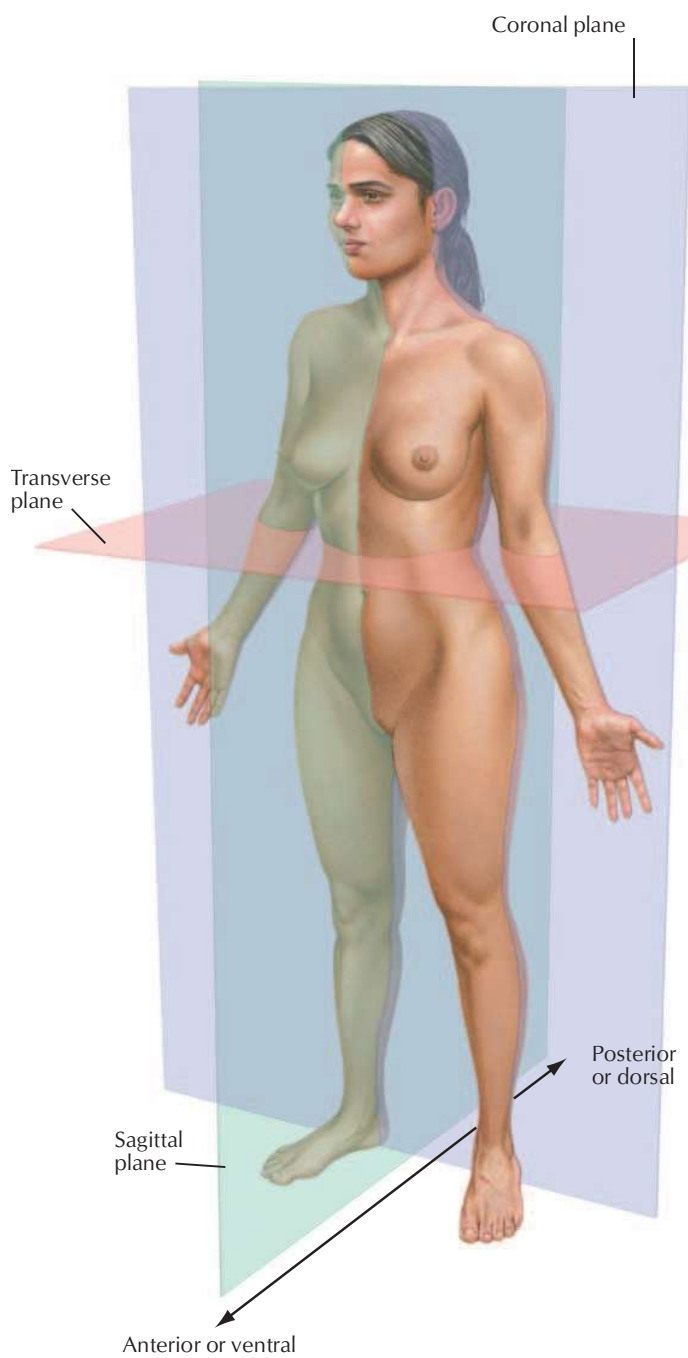
BP 14 General Organization of the Cardiovascular System



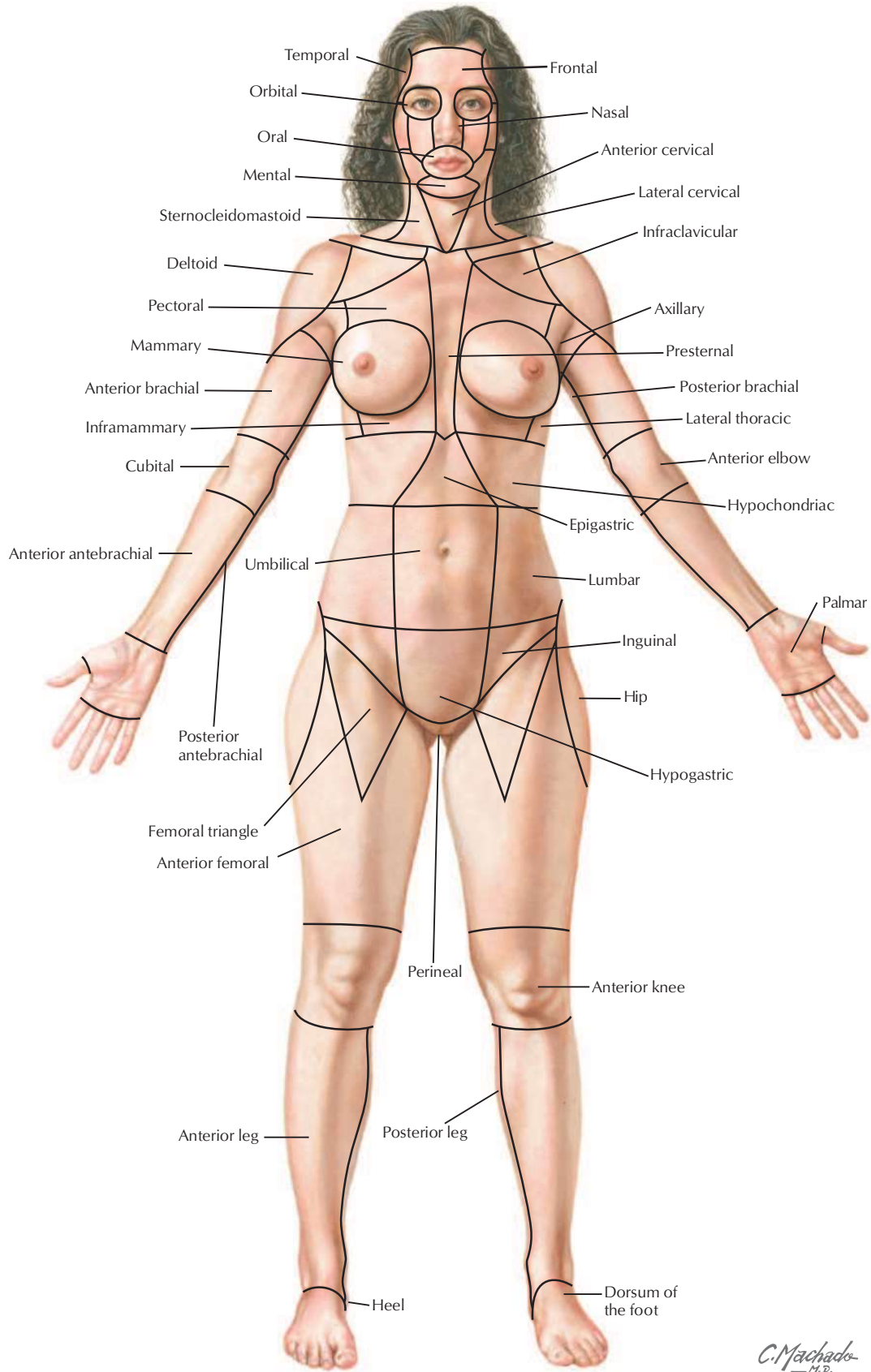
BP 15 Cardiovascular System: Composition of Blood



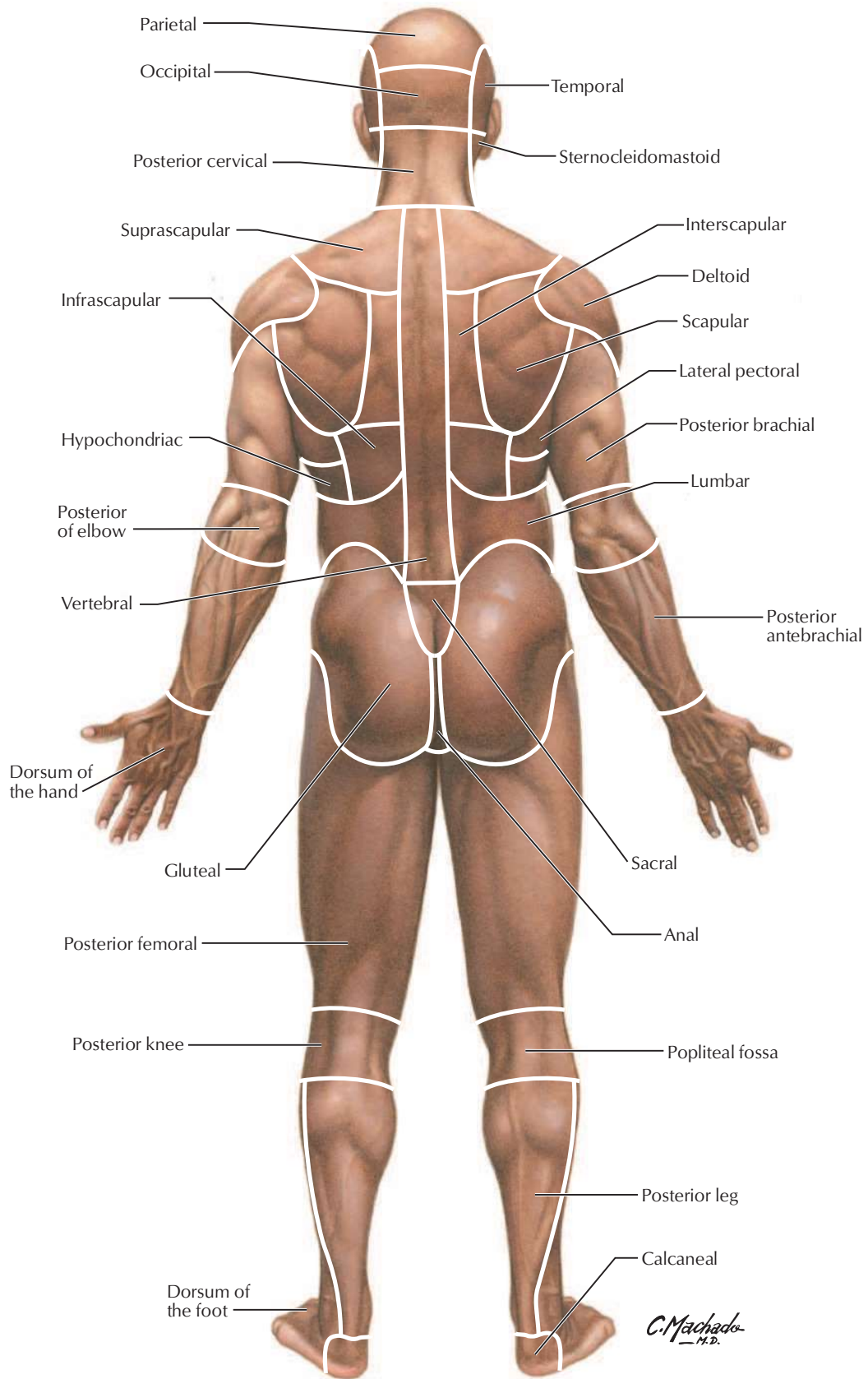
BP 16 Arterial Wall

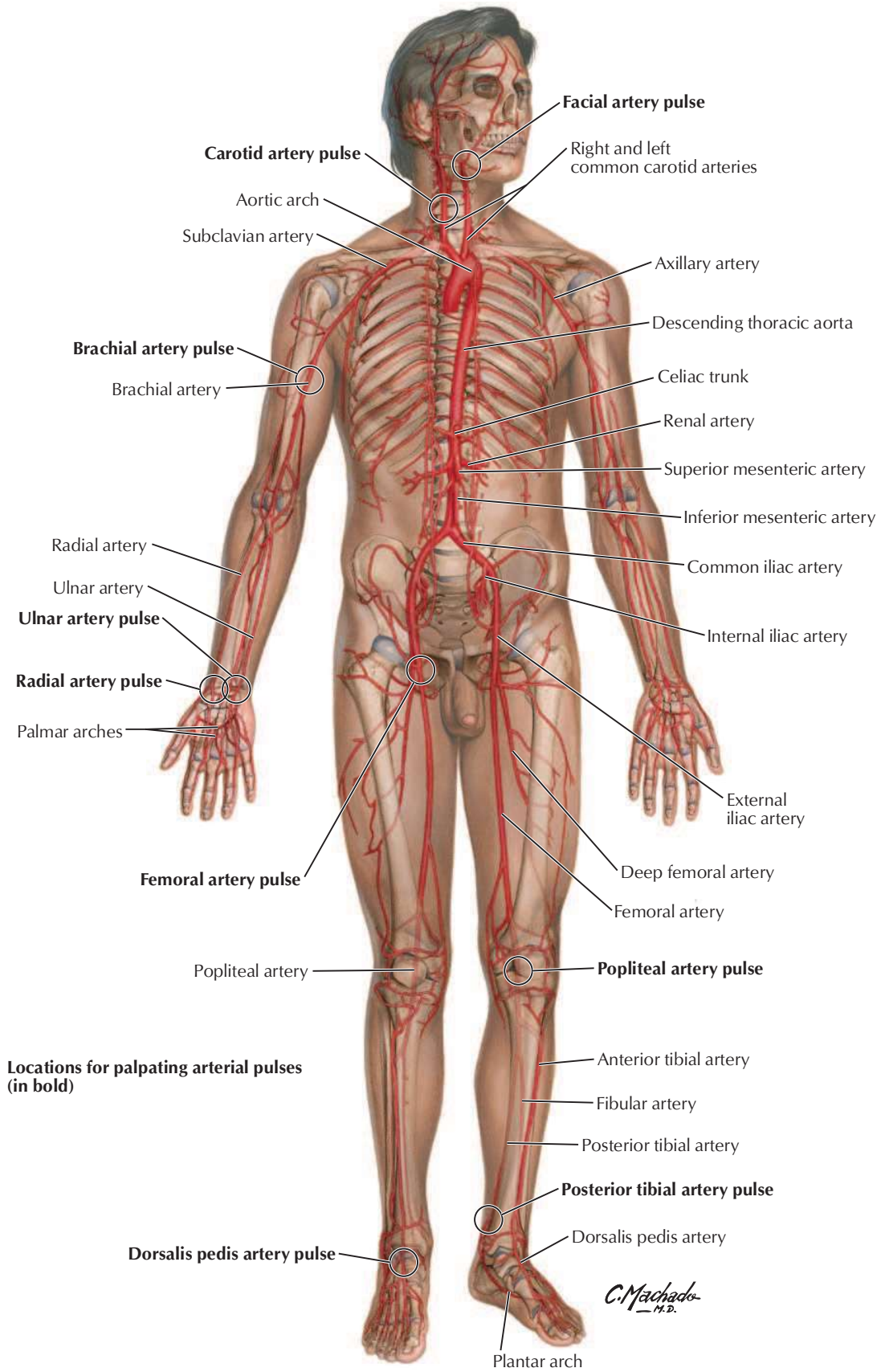


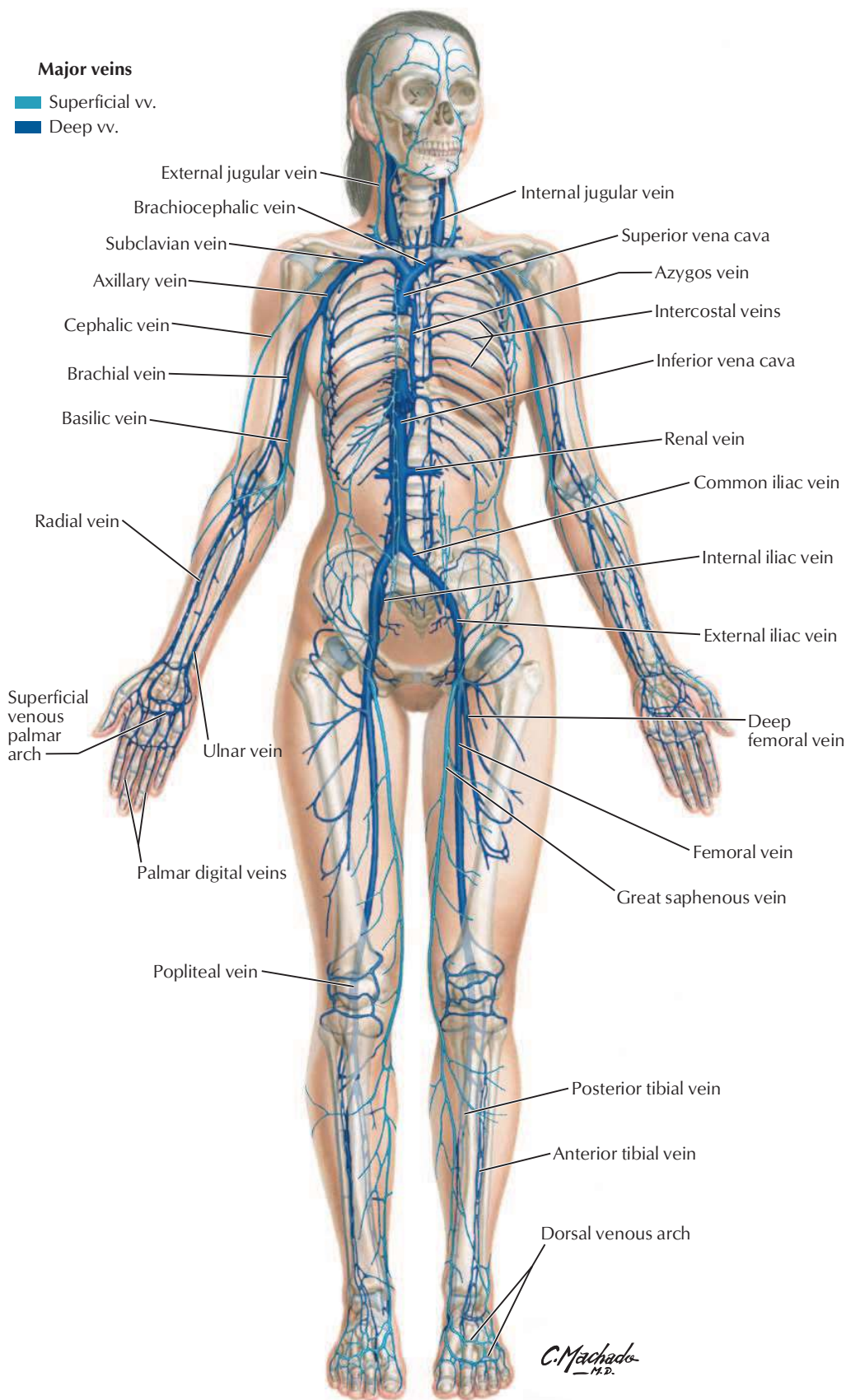
Surface Anatomy: Regions (Anterior View of Female)

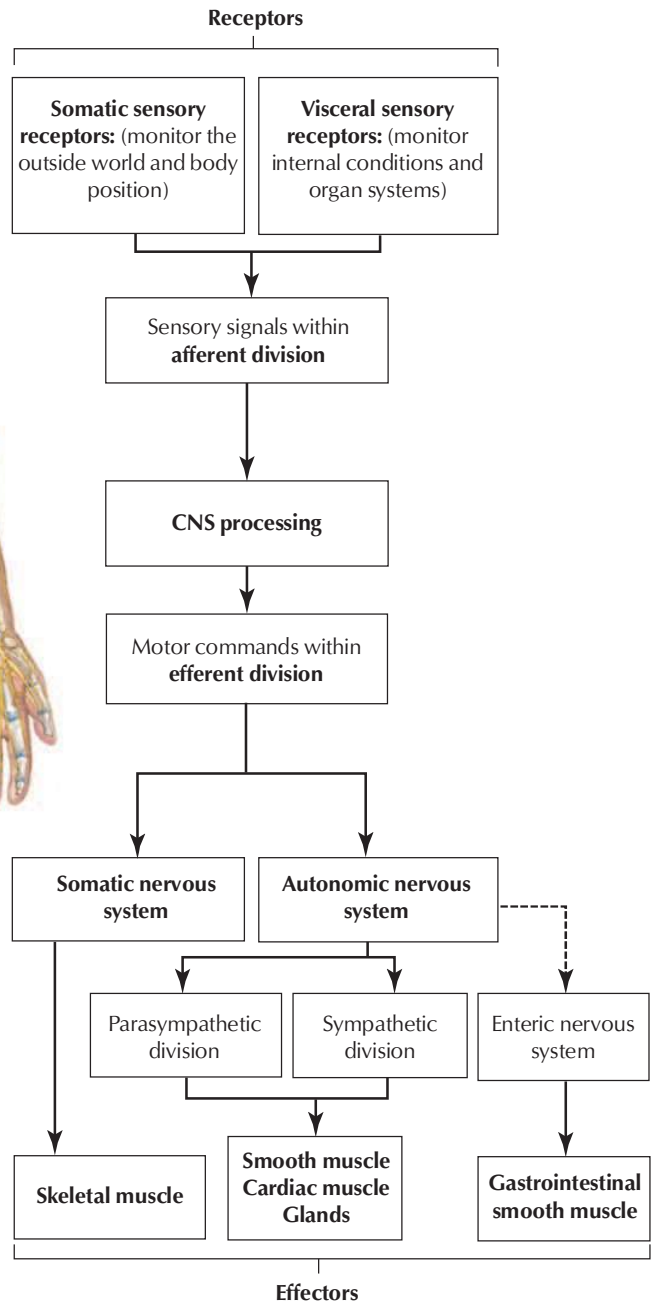
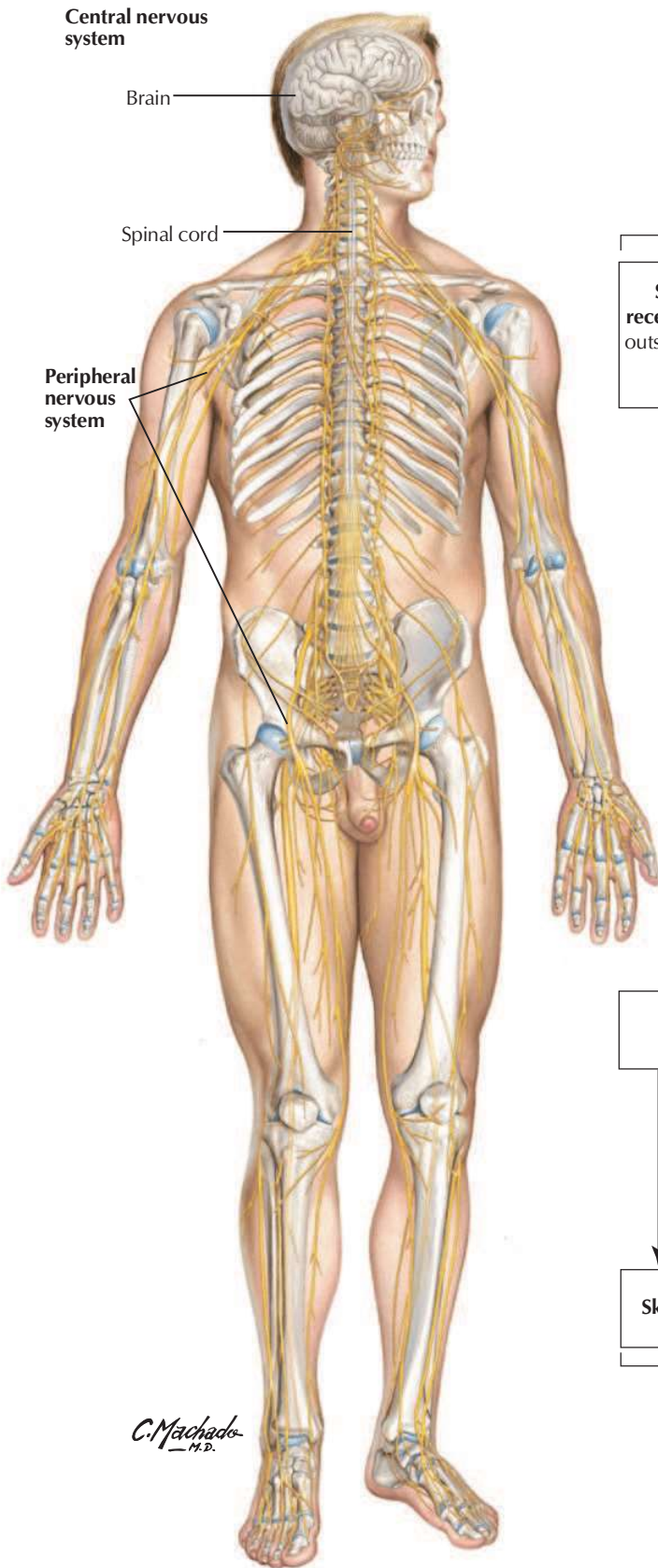


C. Machado
M.D.

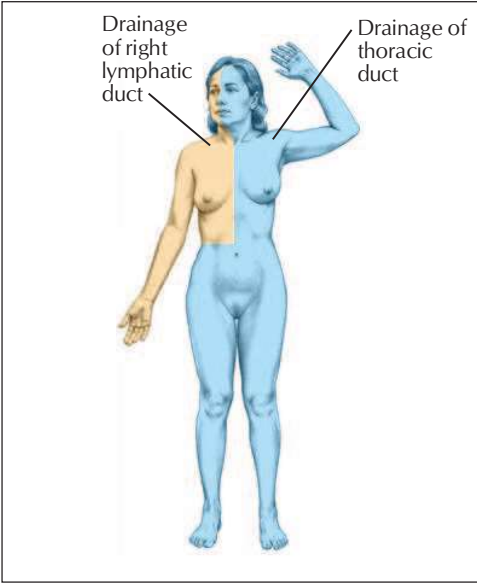
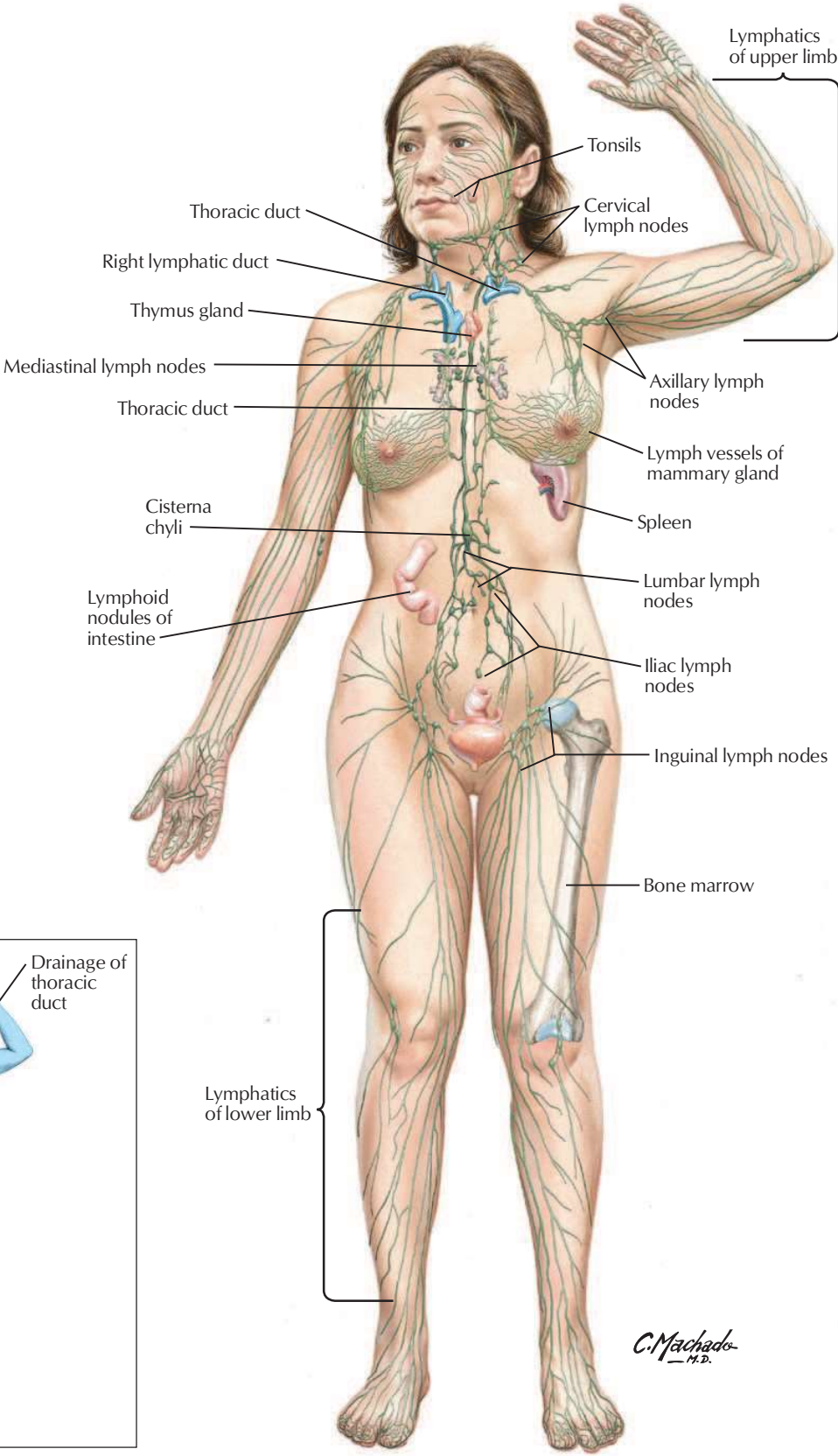




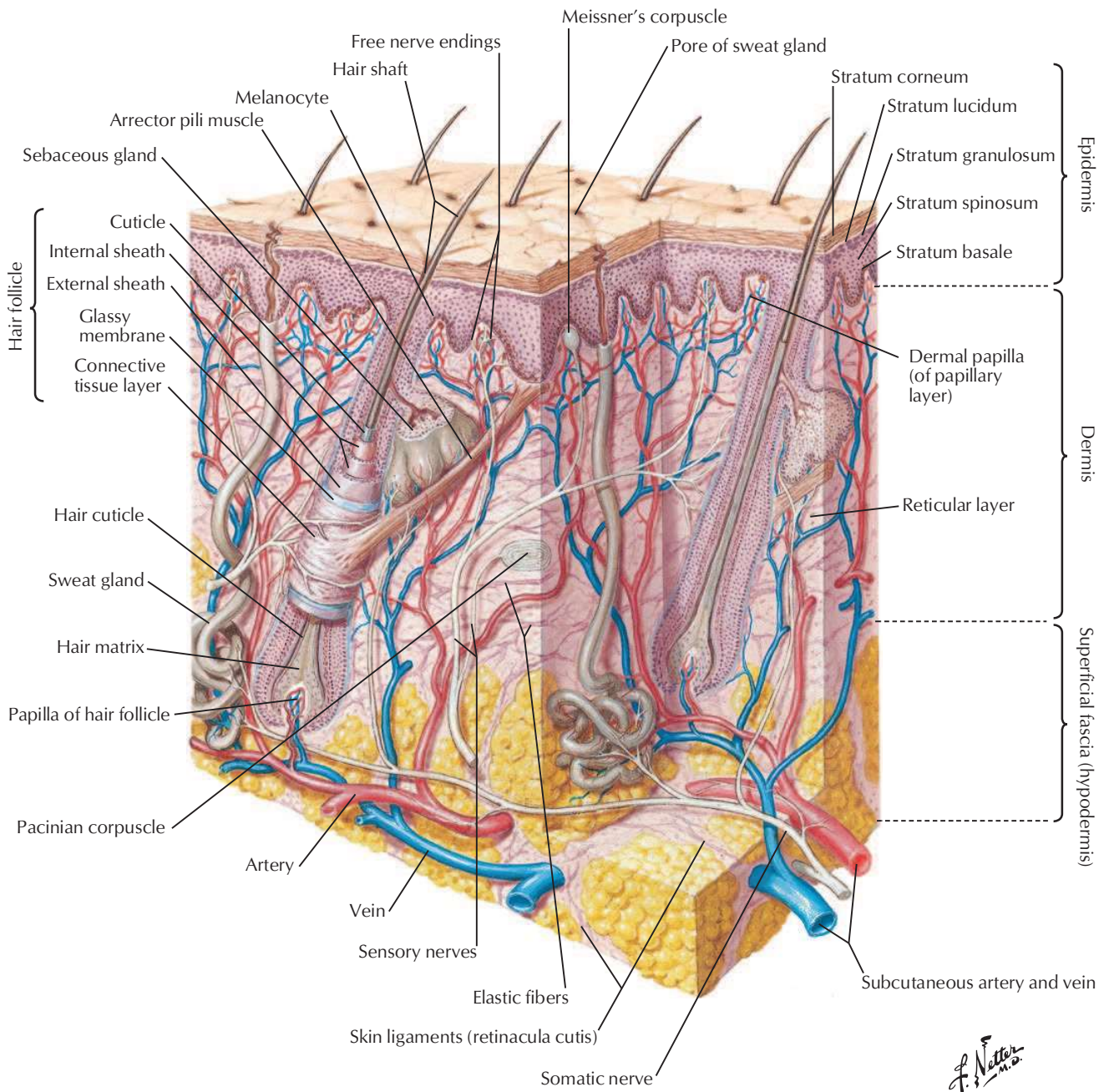


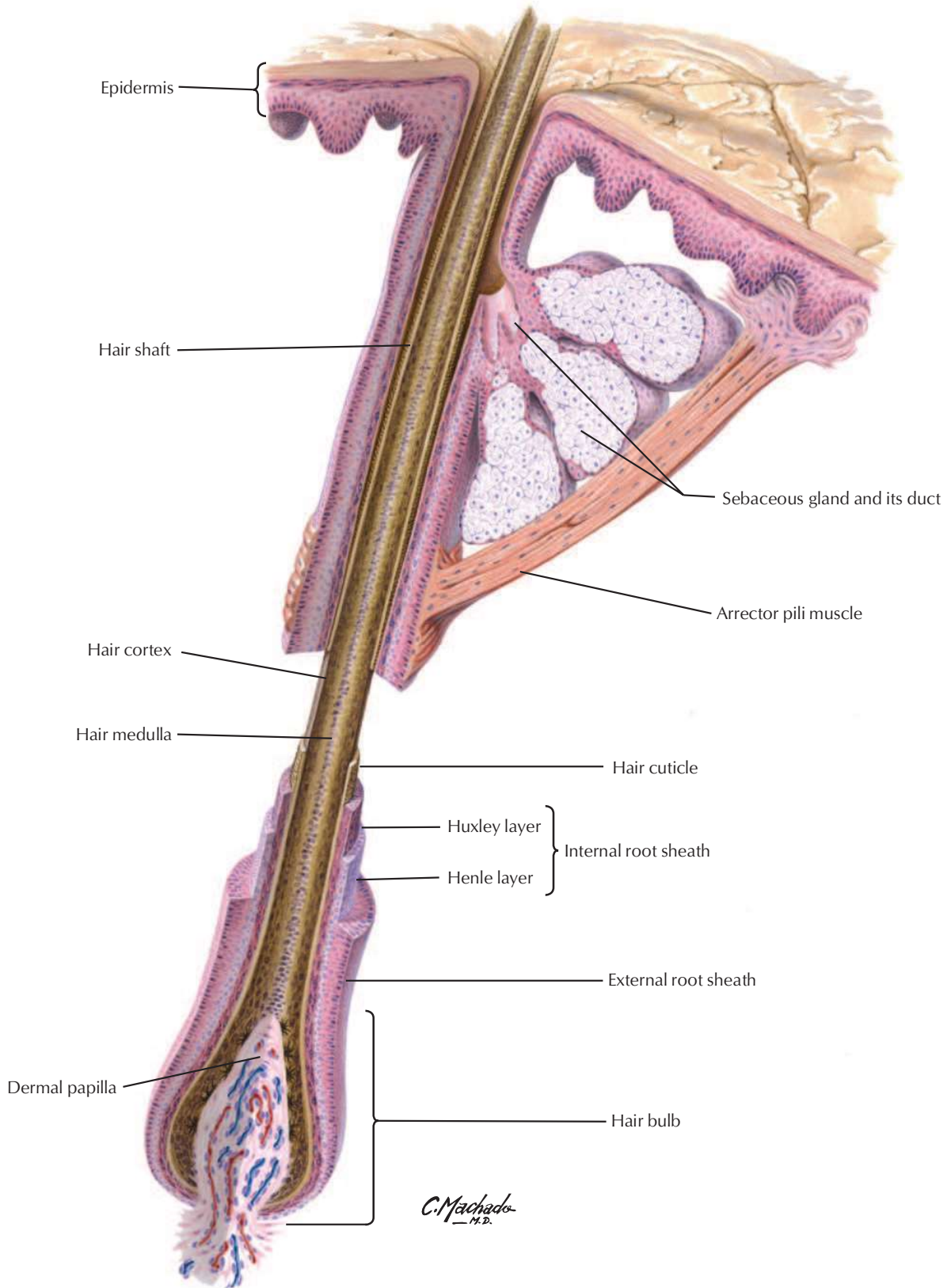


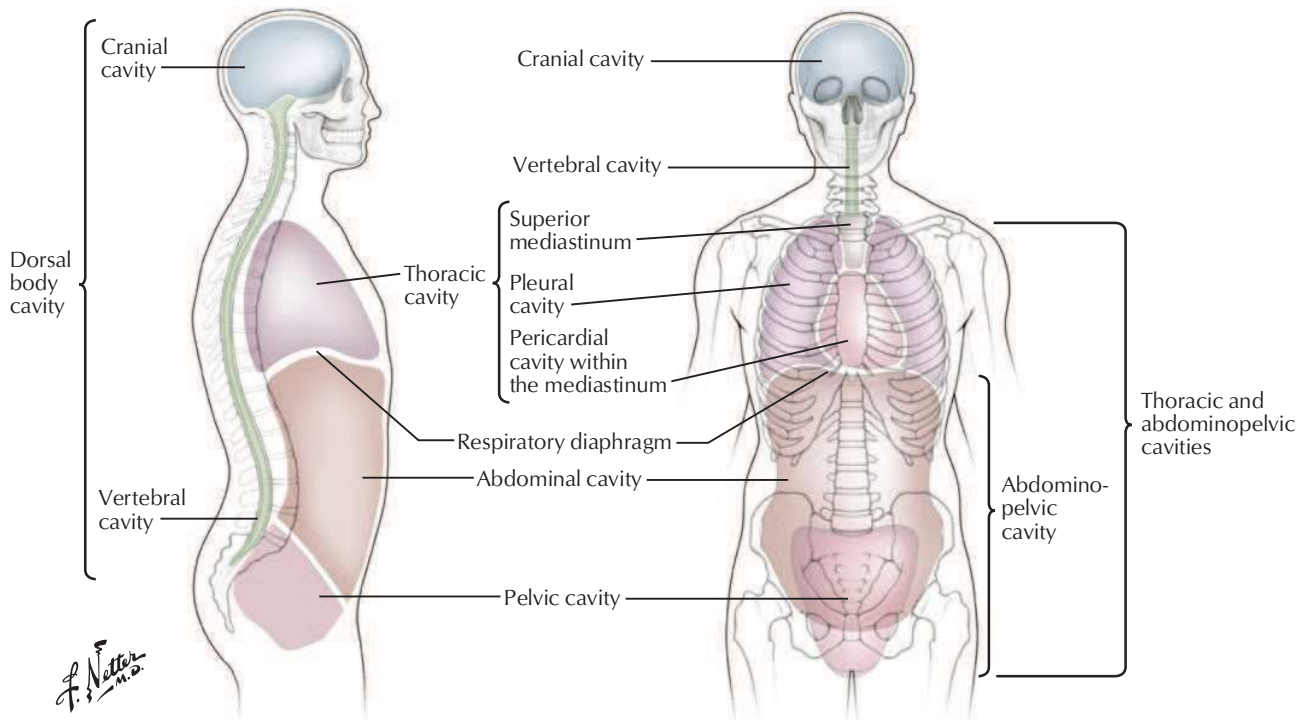
Overview of the Lymphatic System



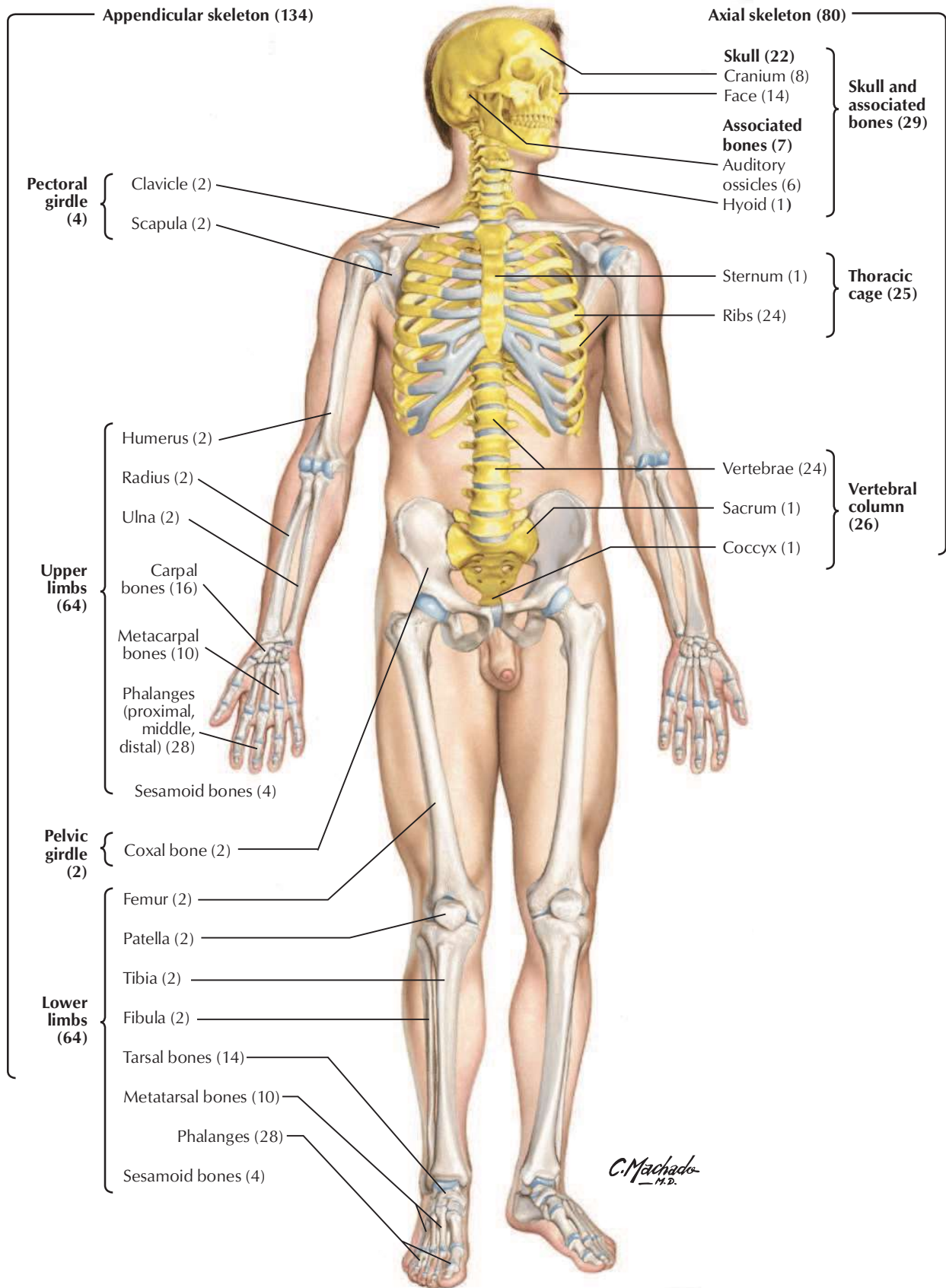
C. Machado
M.D.



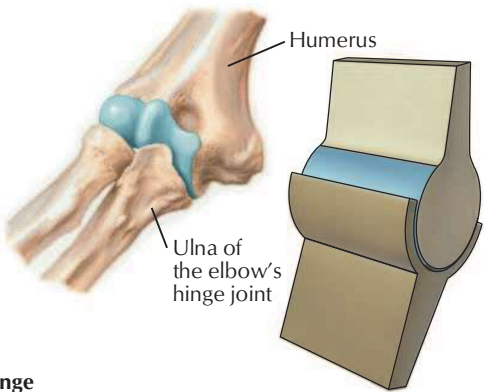
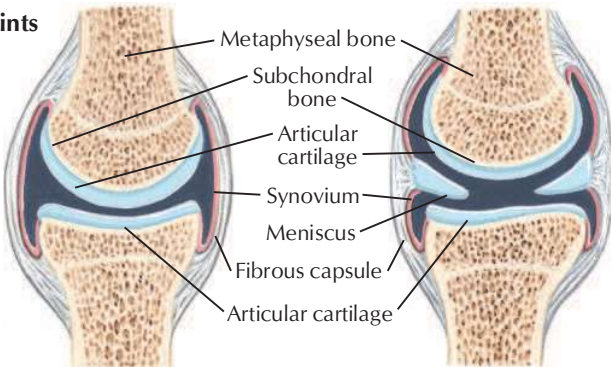




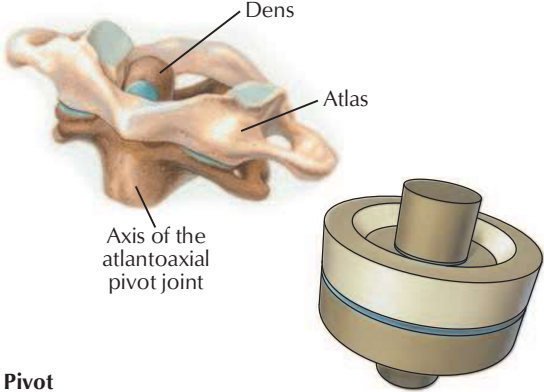
Skeletal System: Axial and Appendicular Skeletons



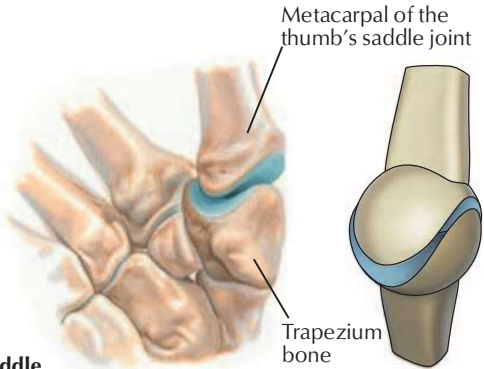
Structure of synovial joints



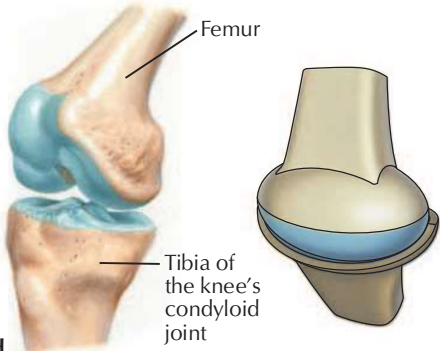
A. Hinge



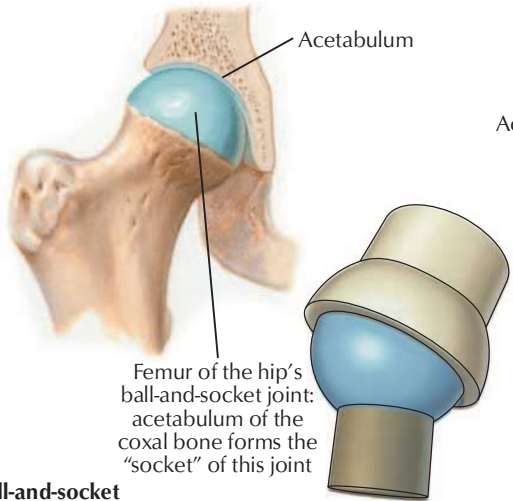
B. Pivot



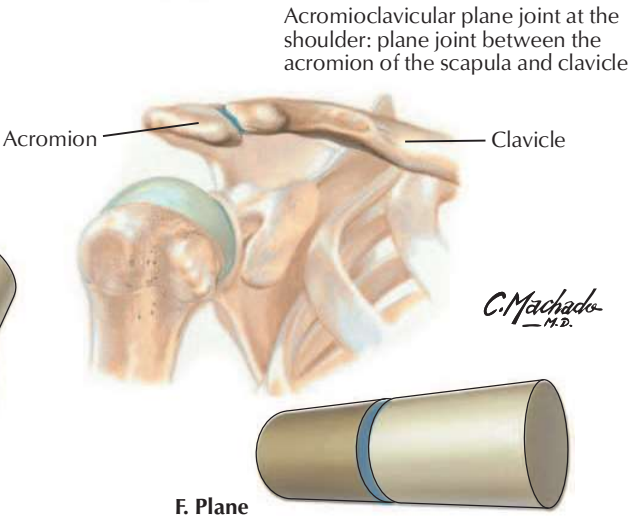
C. Saddle



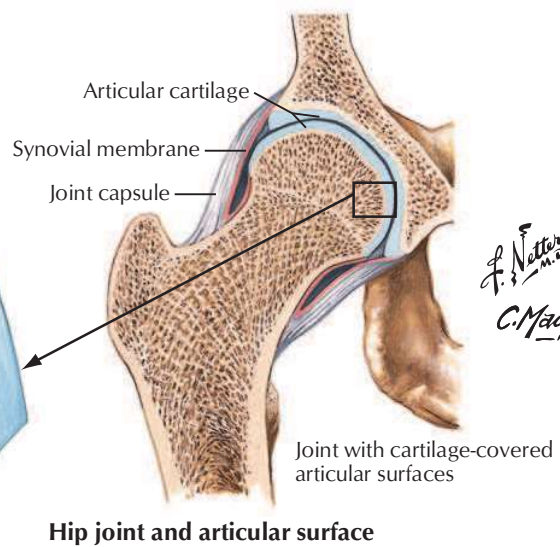
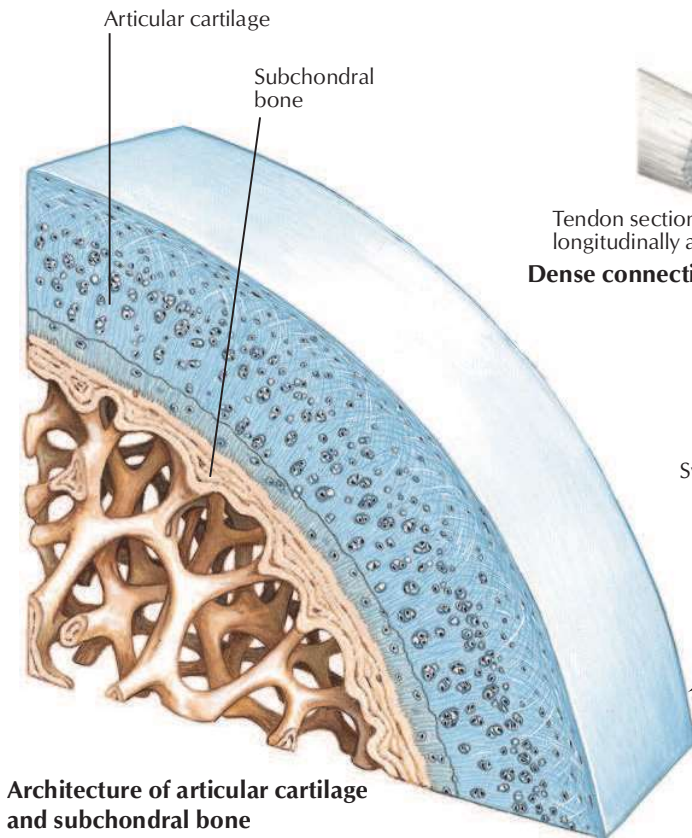
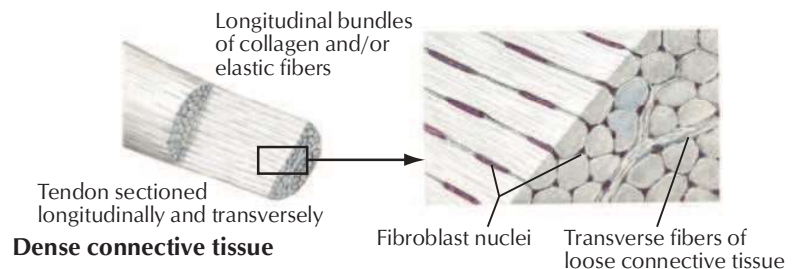
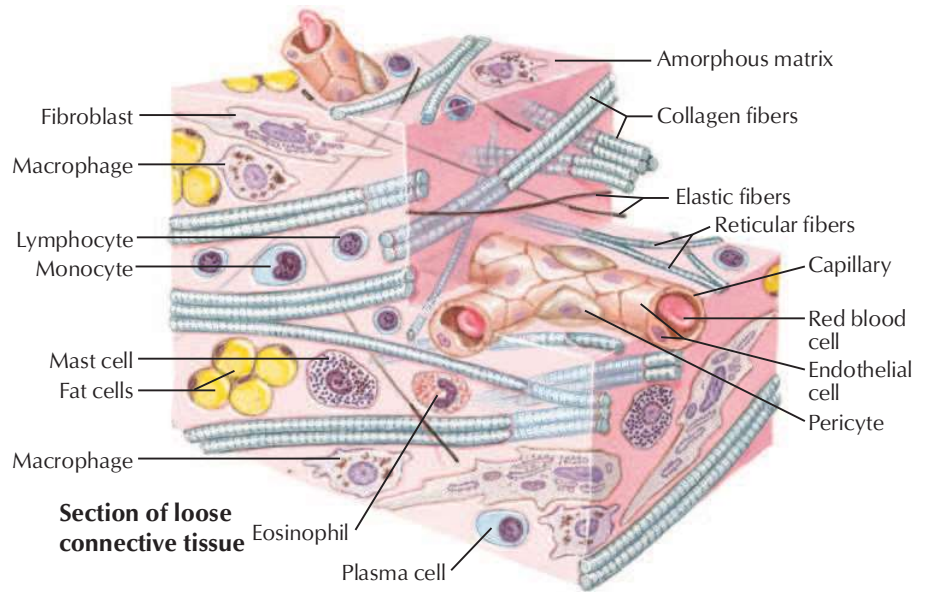
D. Condyloid

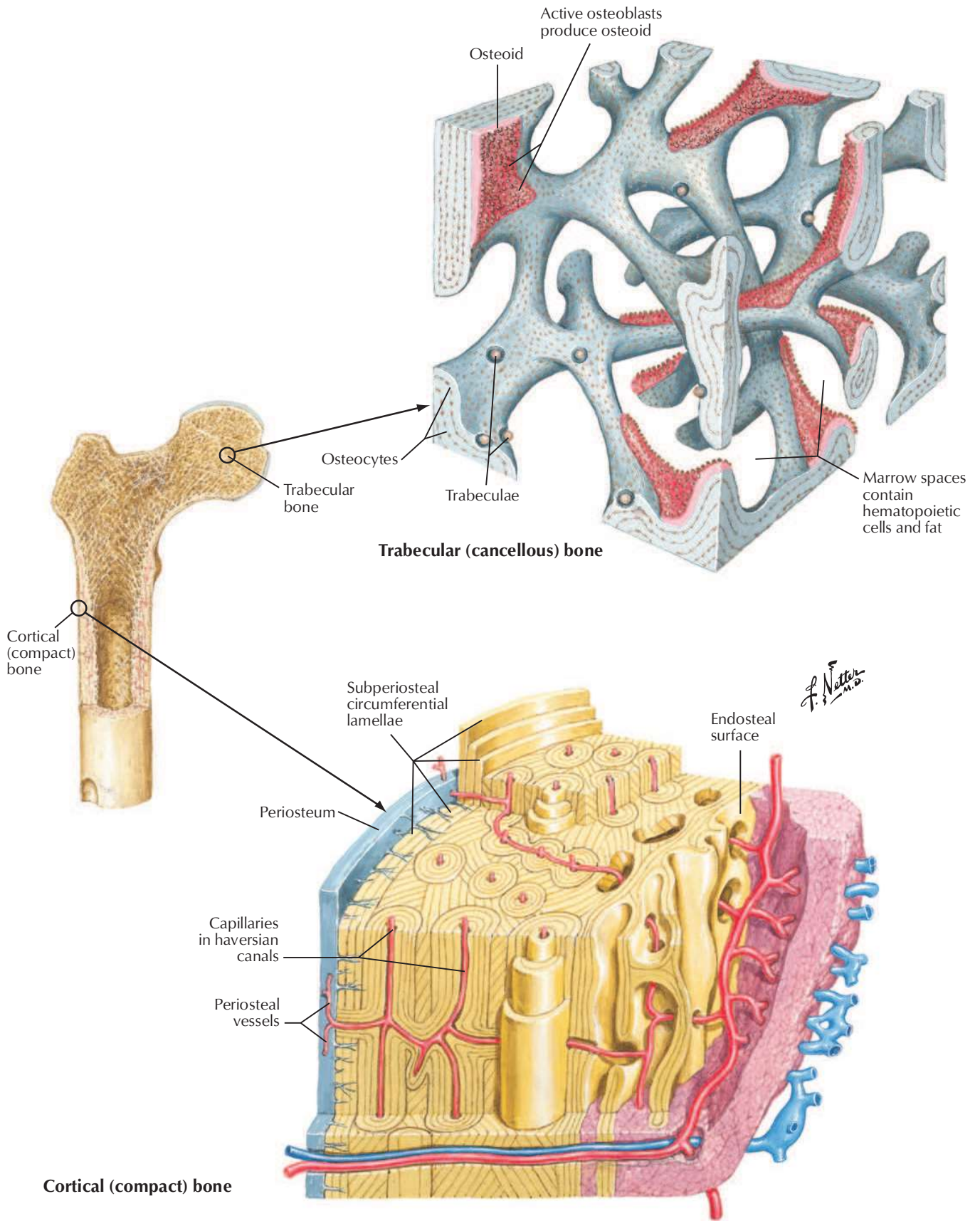


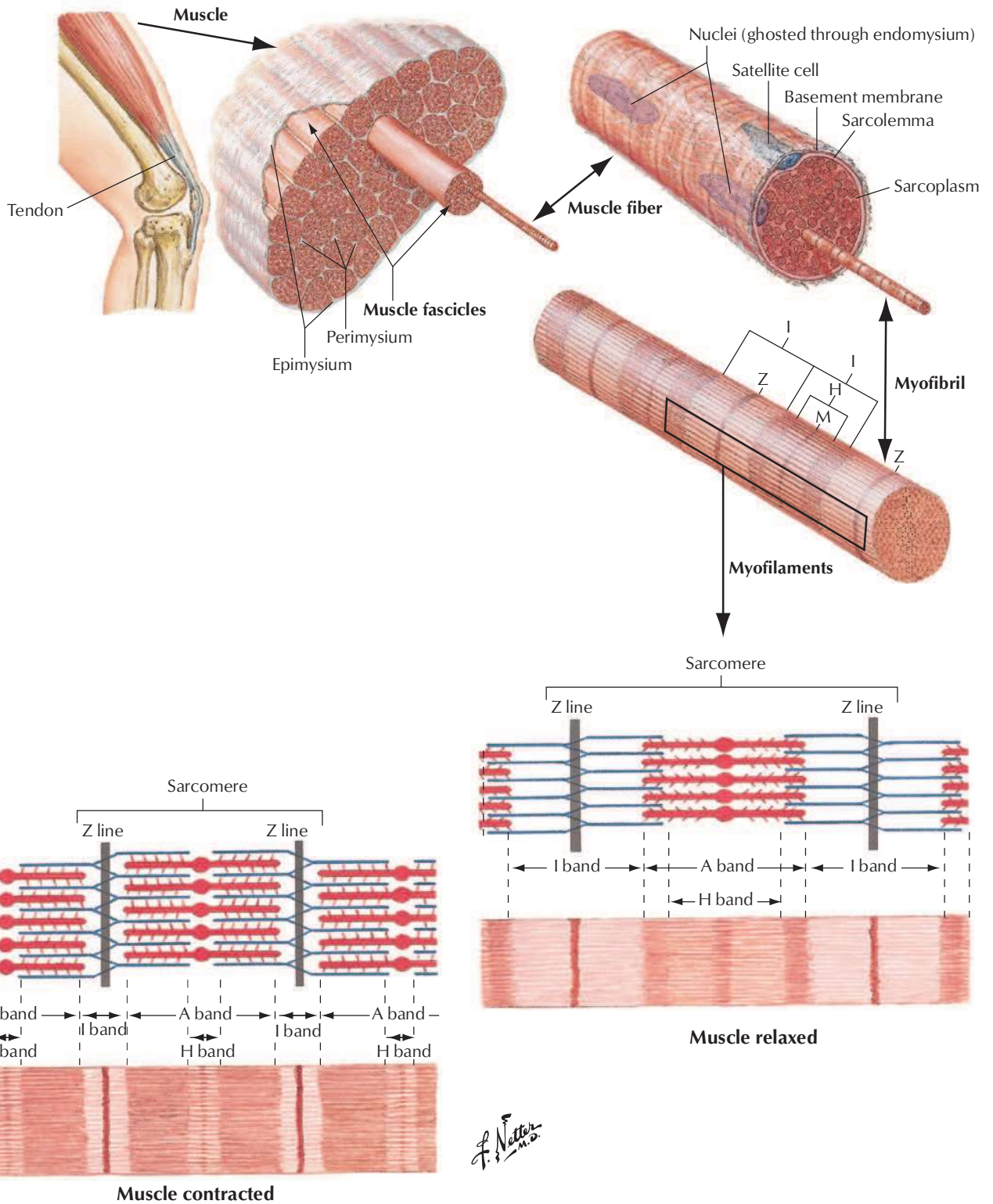
E. Ball-and-socket



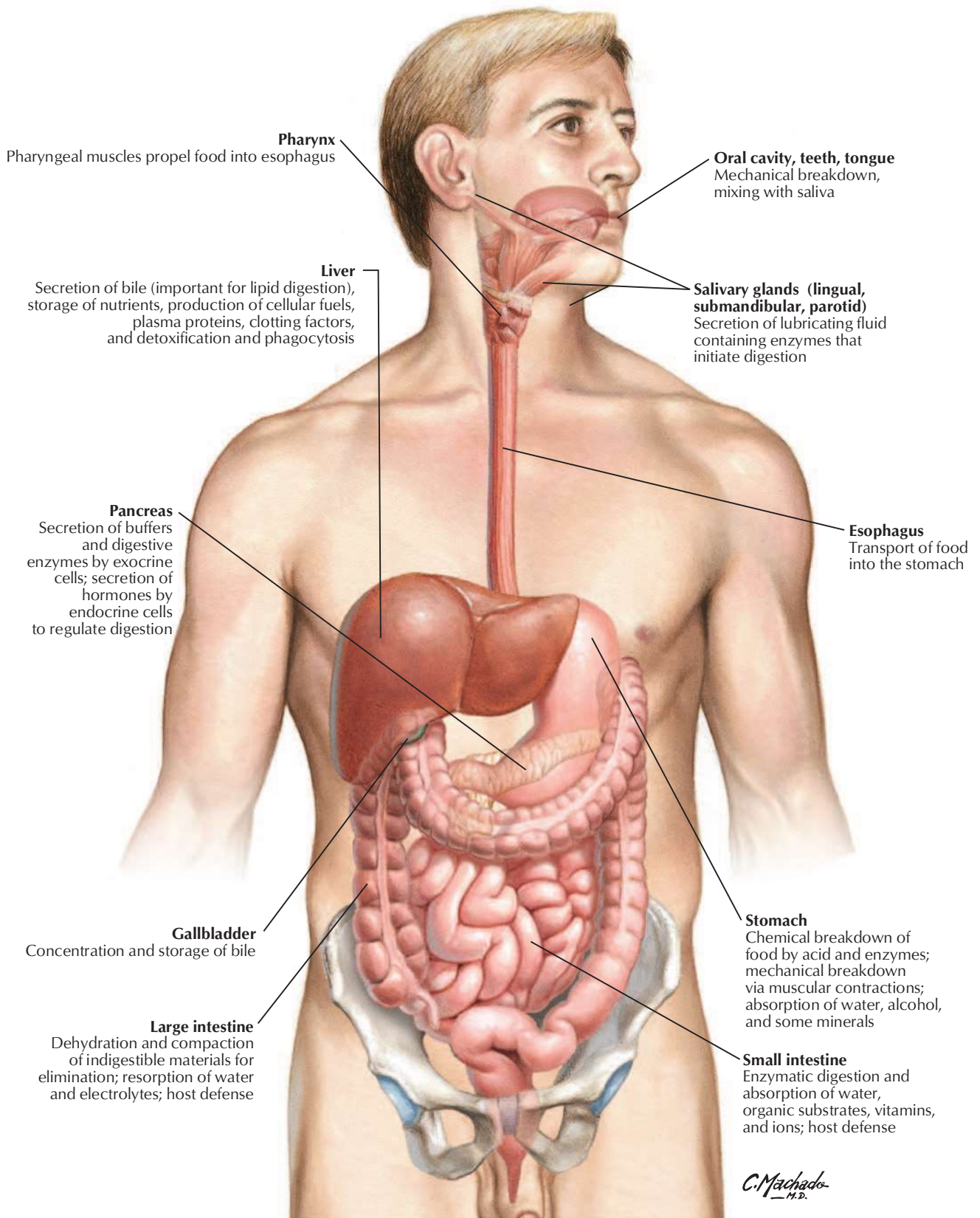
F. Plane

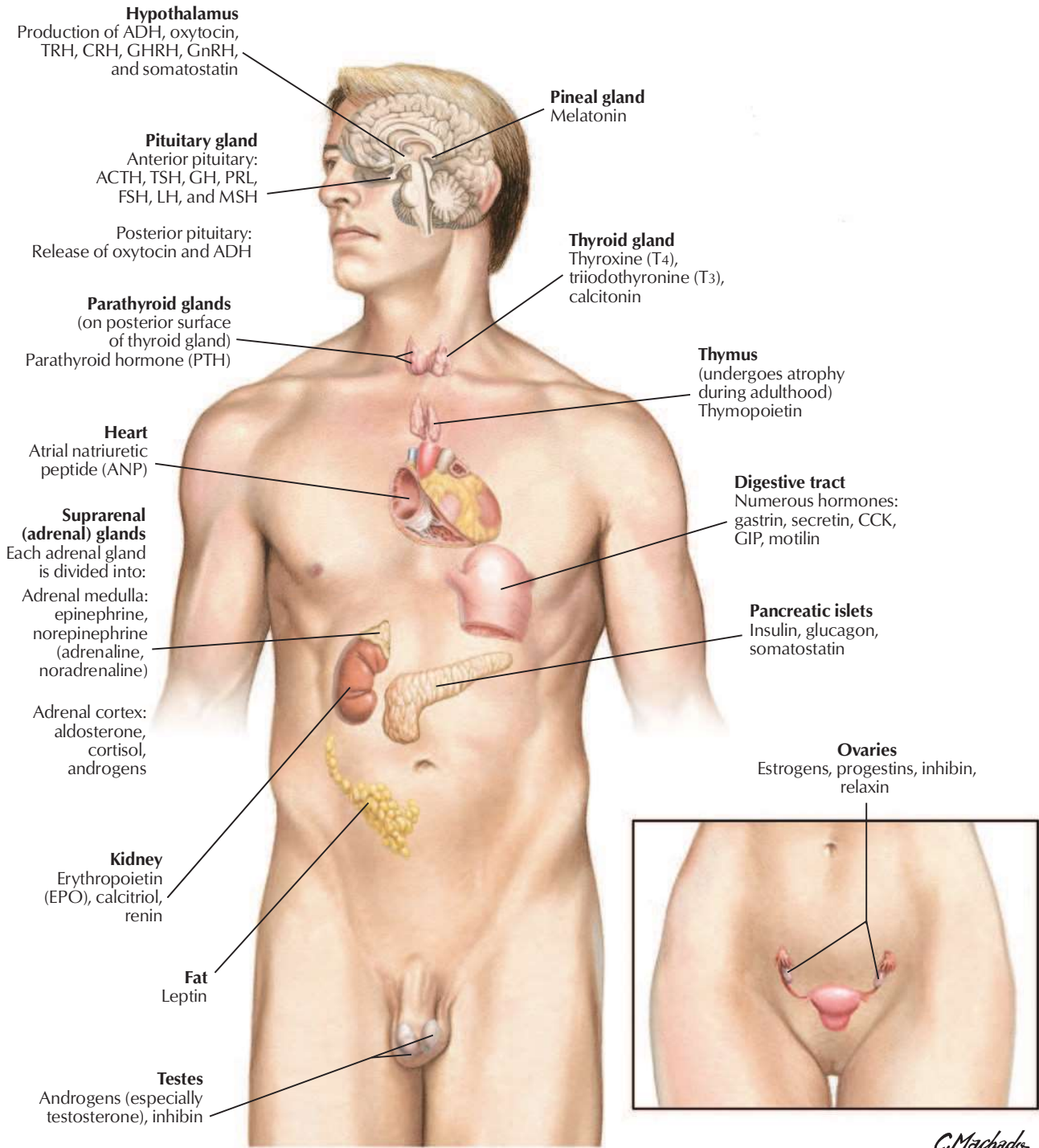


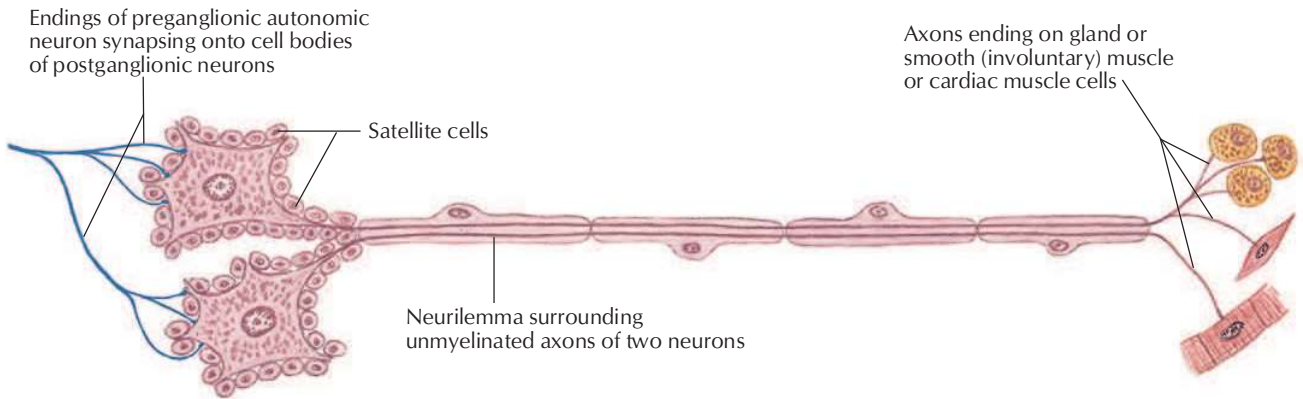




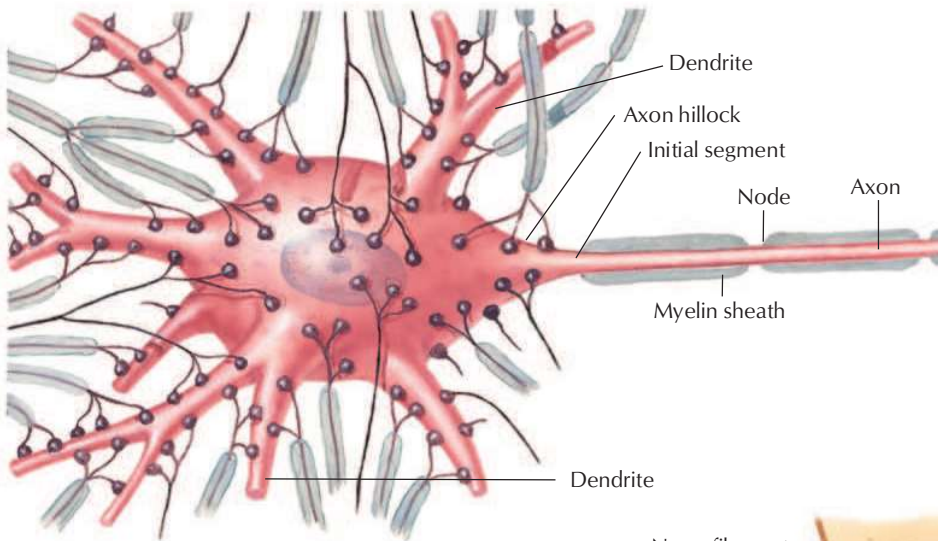
Overview of the Gastrointestinal System





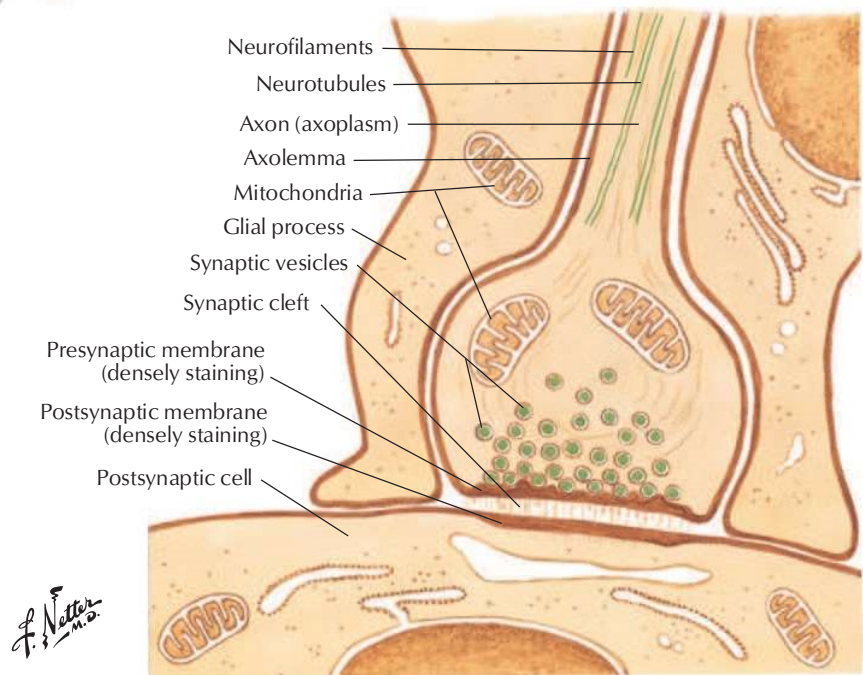


Two postganglionic autonomic neurons of a sympathetic or parasympathetic ganglion



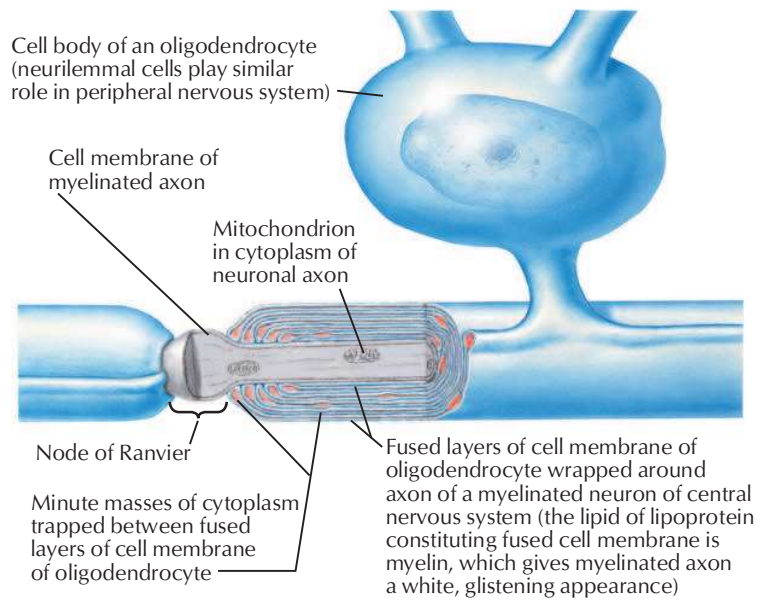
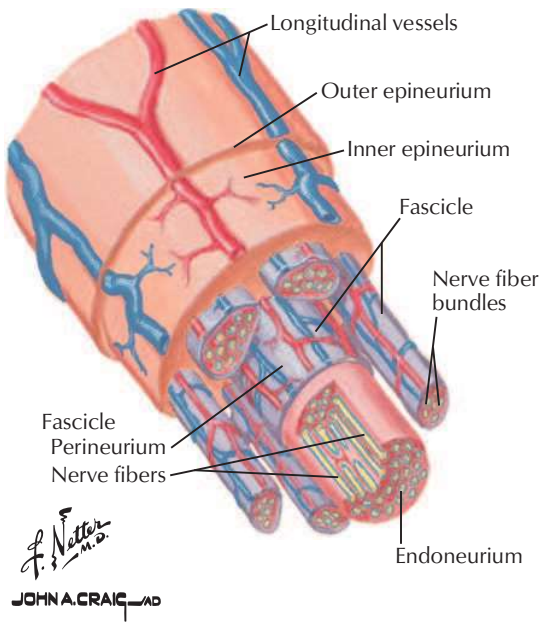
Schematic of synaptic endings

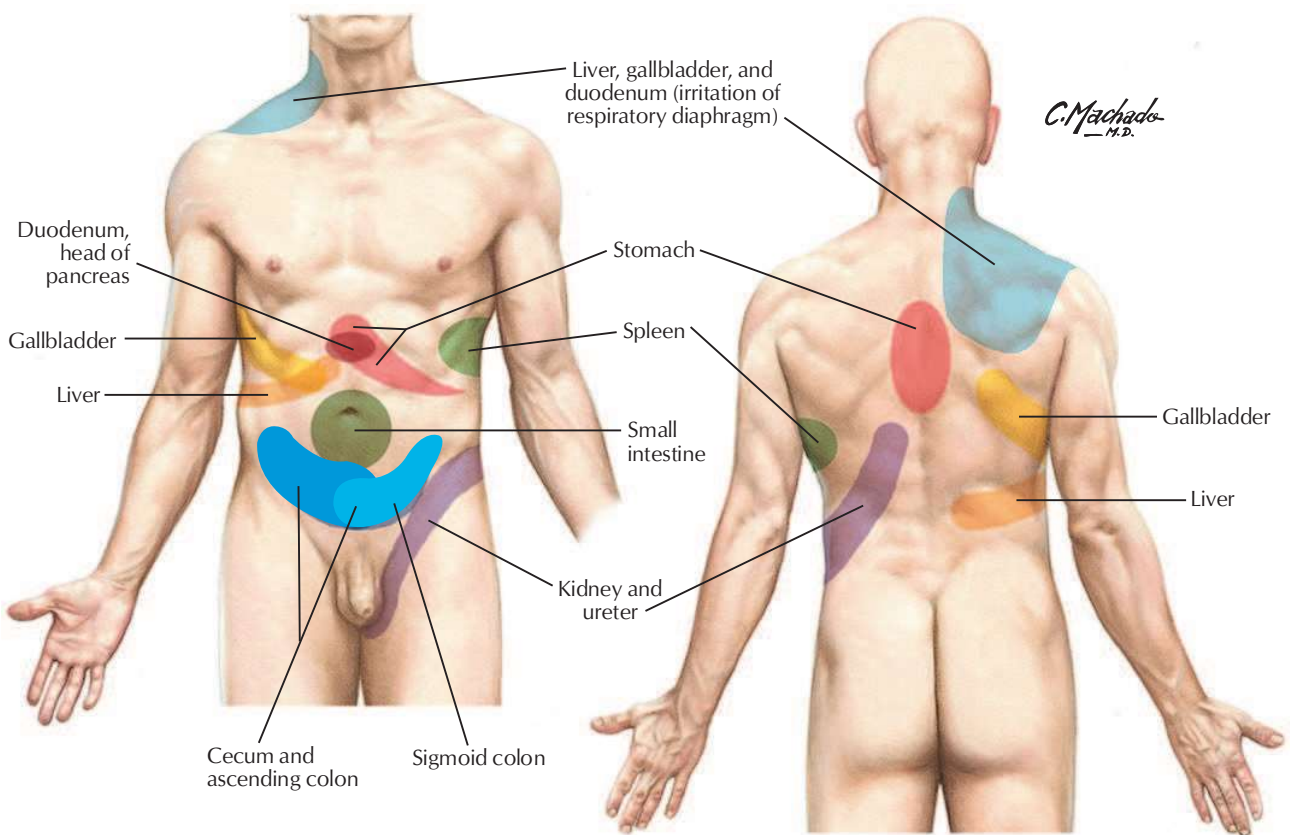
Numerous boutons (synaptic knobs) of presynaptic neurons terminating on a motor neuron and its dendrites

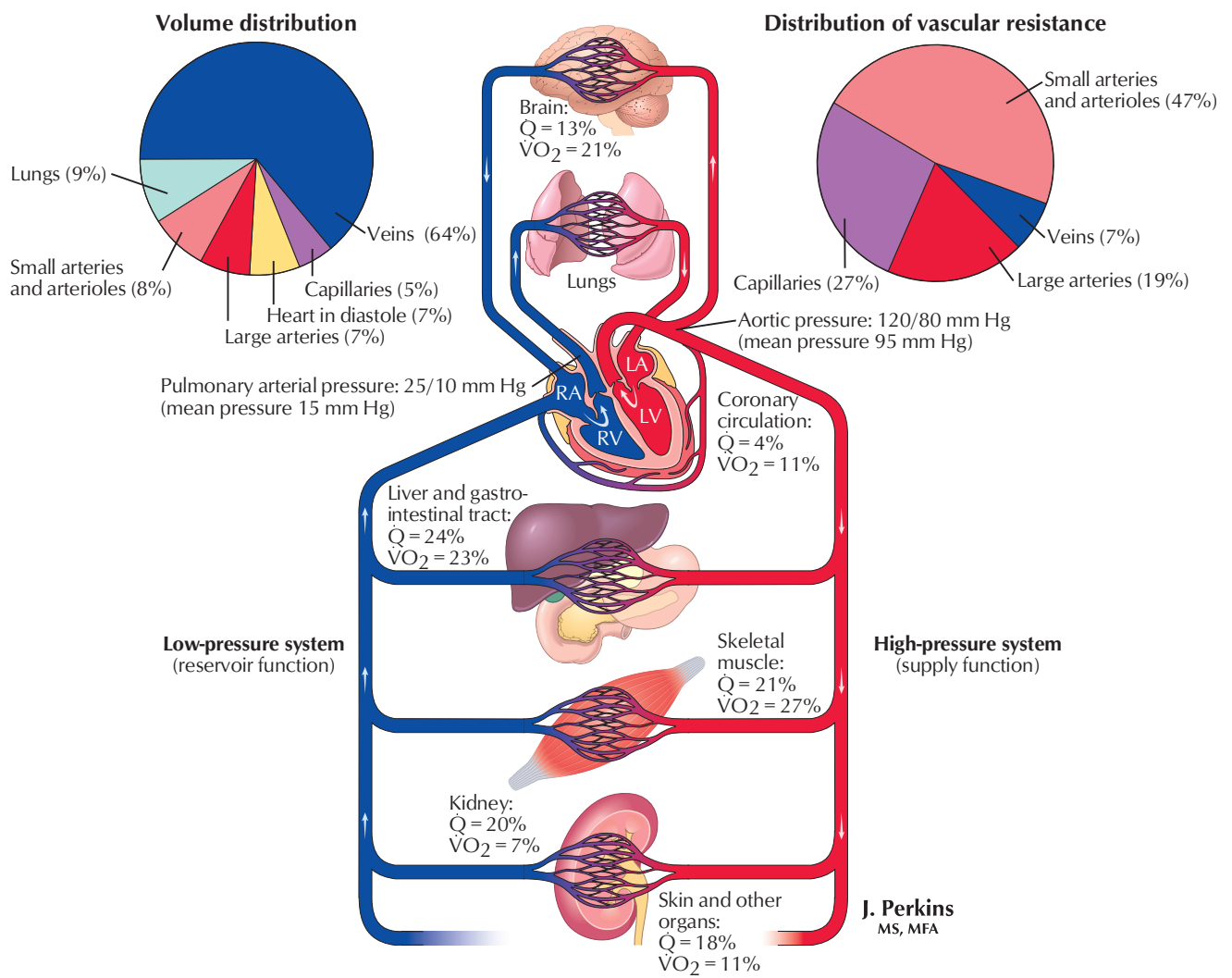


Enlarged section of bouton

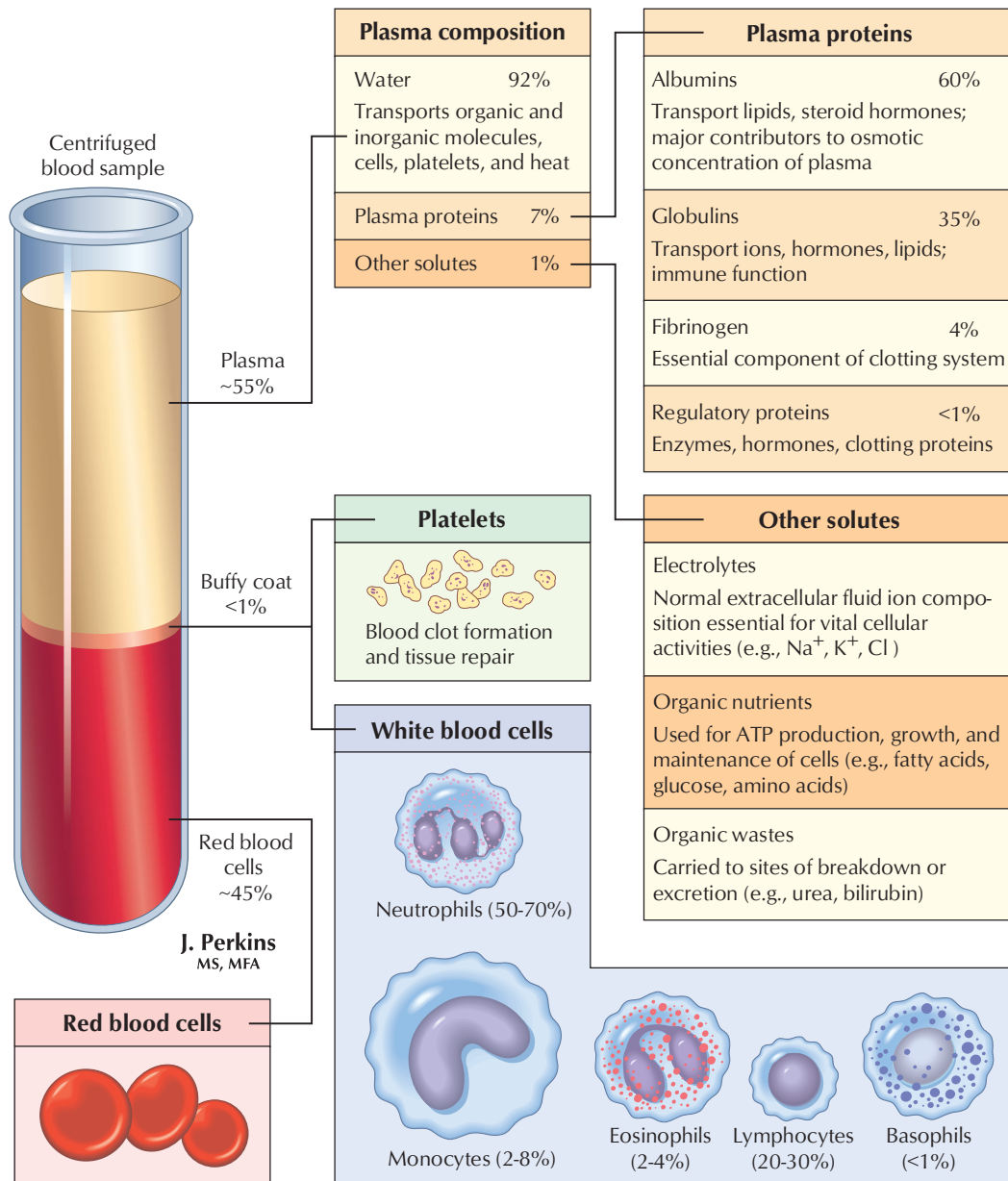
Features of a Typical Peripheral Nerve



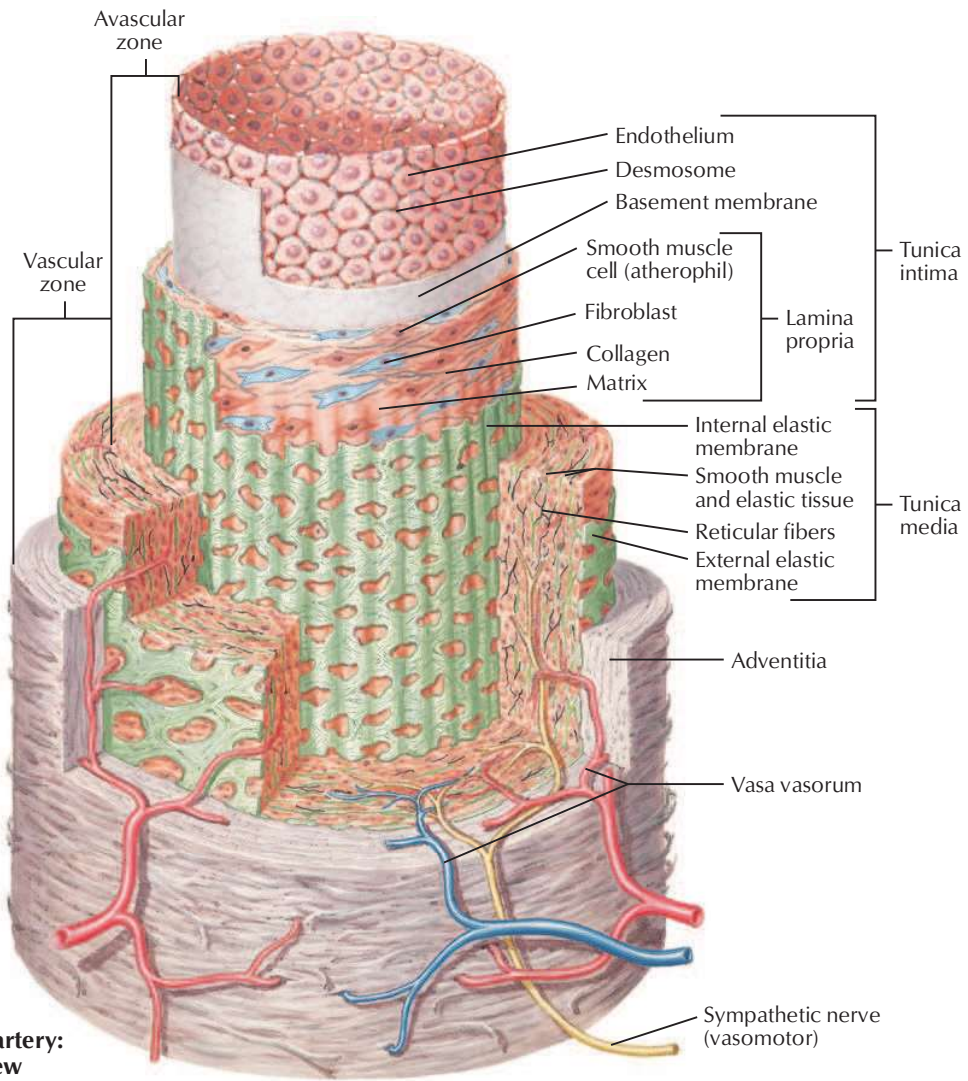




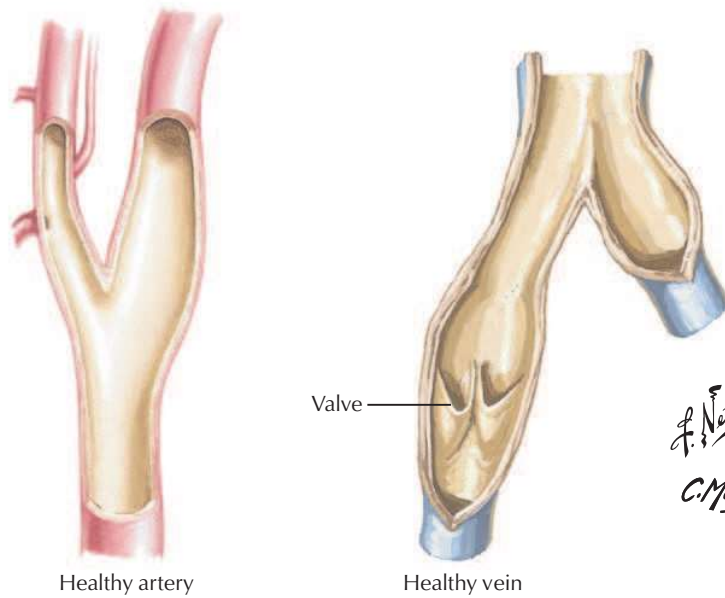
Q = blood flow per minute
 VO₂ = oxygen used per minute



Arterial Wall



Wall of an artery: cutaway view

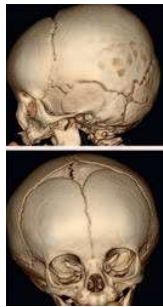

F. Netter M.D.
C. Machado M.D.

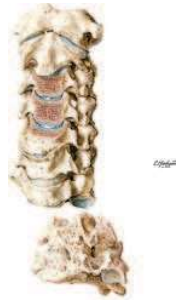HEAD AND NECK 2

Surface Anatomy	8	Ear	105-110
Superficial Head and Neck	9-10	Meninges and Brain	111-126
Bones and Ligaments	11-30	Cranial and Cervical Nerves	127-146
Neck	31-41	Cerebral Vasculature	147-158
Nasal Region	42-64	Regional Imaging	159-160
Oral Region	65-74	Structures with High Clinical Significance	Tables 2.1-2.3
Pharynx	75-86	Muscle Tables	Tables 2.4-2.9
Thyroid Gland and Larynx	87-93	Electronic Bonus Plates	BP17-BP32
Orbit and Contents	94-104		

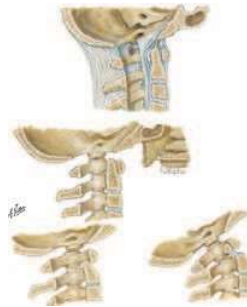
ELECTRONIC BONUS PLATES



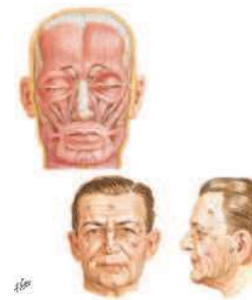BP17 3D Skull Reconstruction CTs



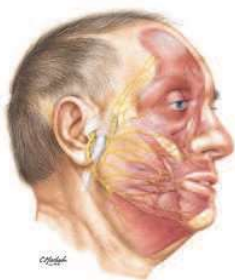BP18 Degenerative Changes in Cervical Vertebrae



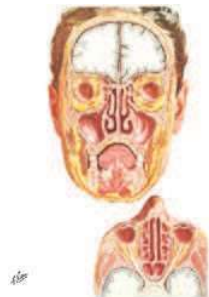BP19 Atlantooccipital Junction



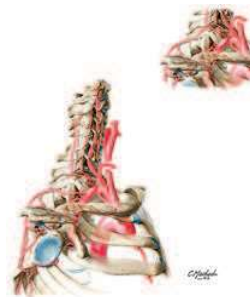
BP20 Muscles of Facial Expression: Anterior View



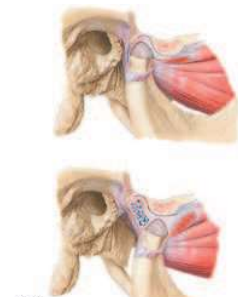
BP21 Musculature of Face



BP22 Paranasal Sinuses

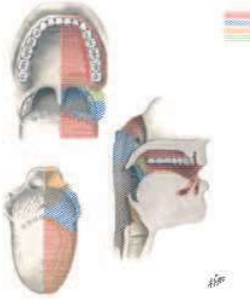


BP23 Subclavian Artery

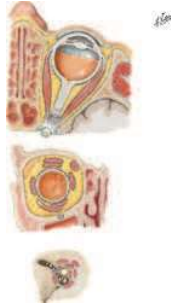

BP24 Opening of the Mandible

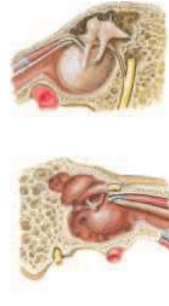
ELECTRONIC BONUS PLATES—*cont'd*



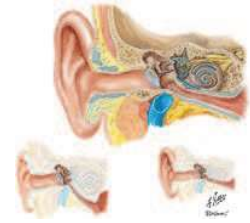BP25 Afferent Innervation of Oral Cavity and Pharynx



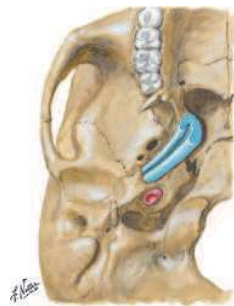BP26 Fasciae of Orbit and Eyeball



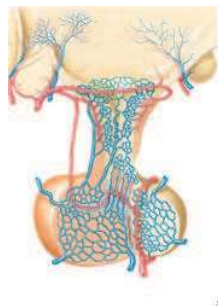BP27 Tympanic Cavity



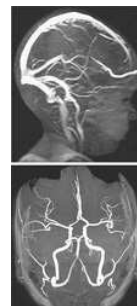BP28 Anatomy of the Pediatric Ear



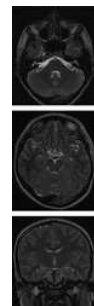
BP29 Auditory Tube (Eustachian)



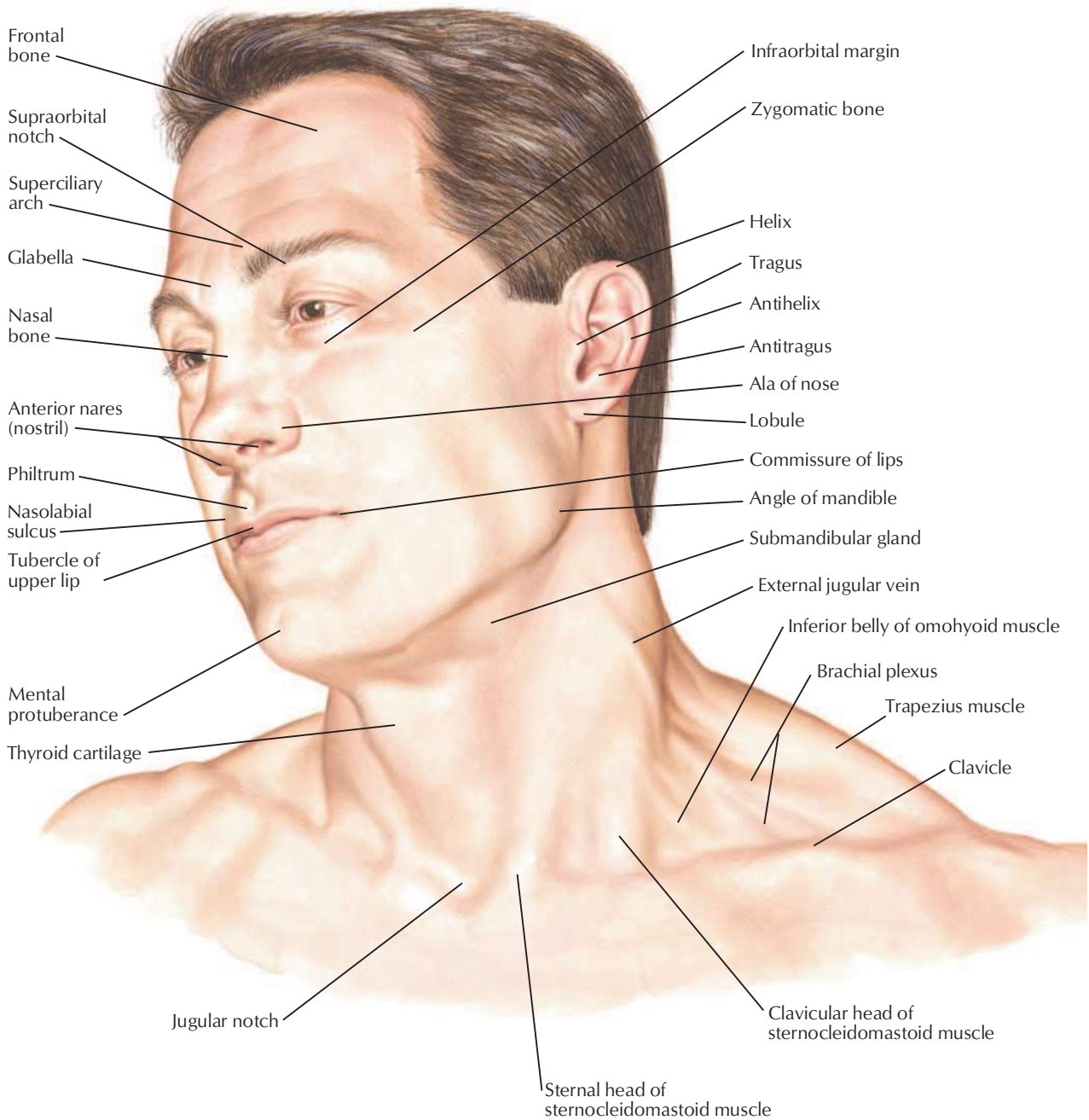
BP30 Arteries and Veins of Hypothalamus and Hypophysis



BP31 Cranial Imaging (MRV and MRA)



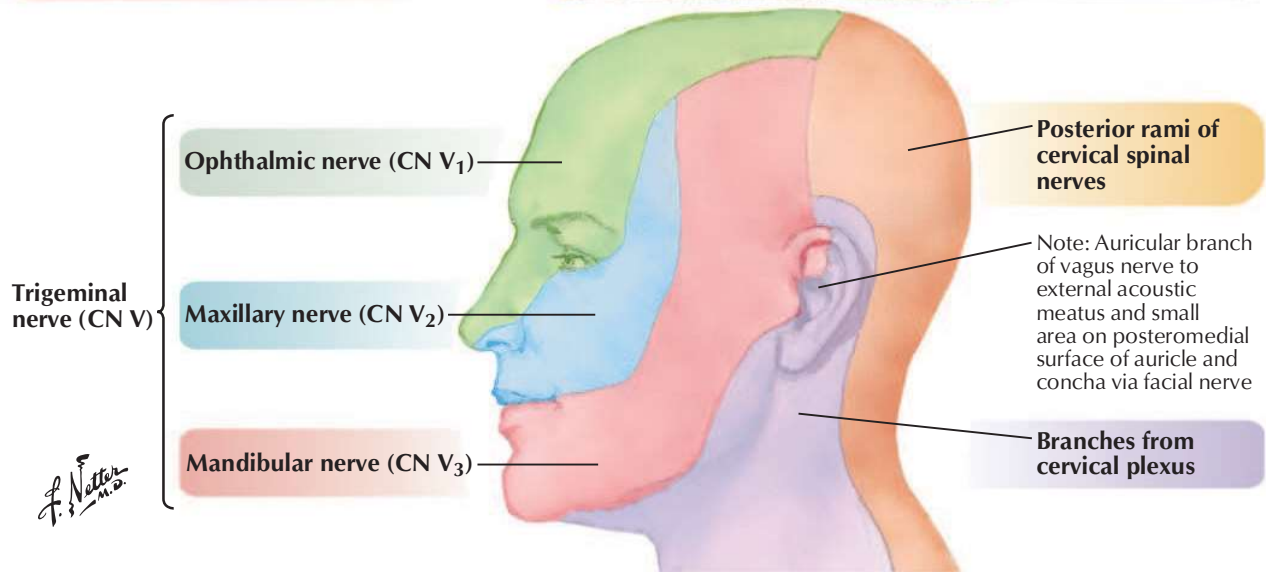
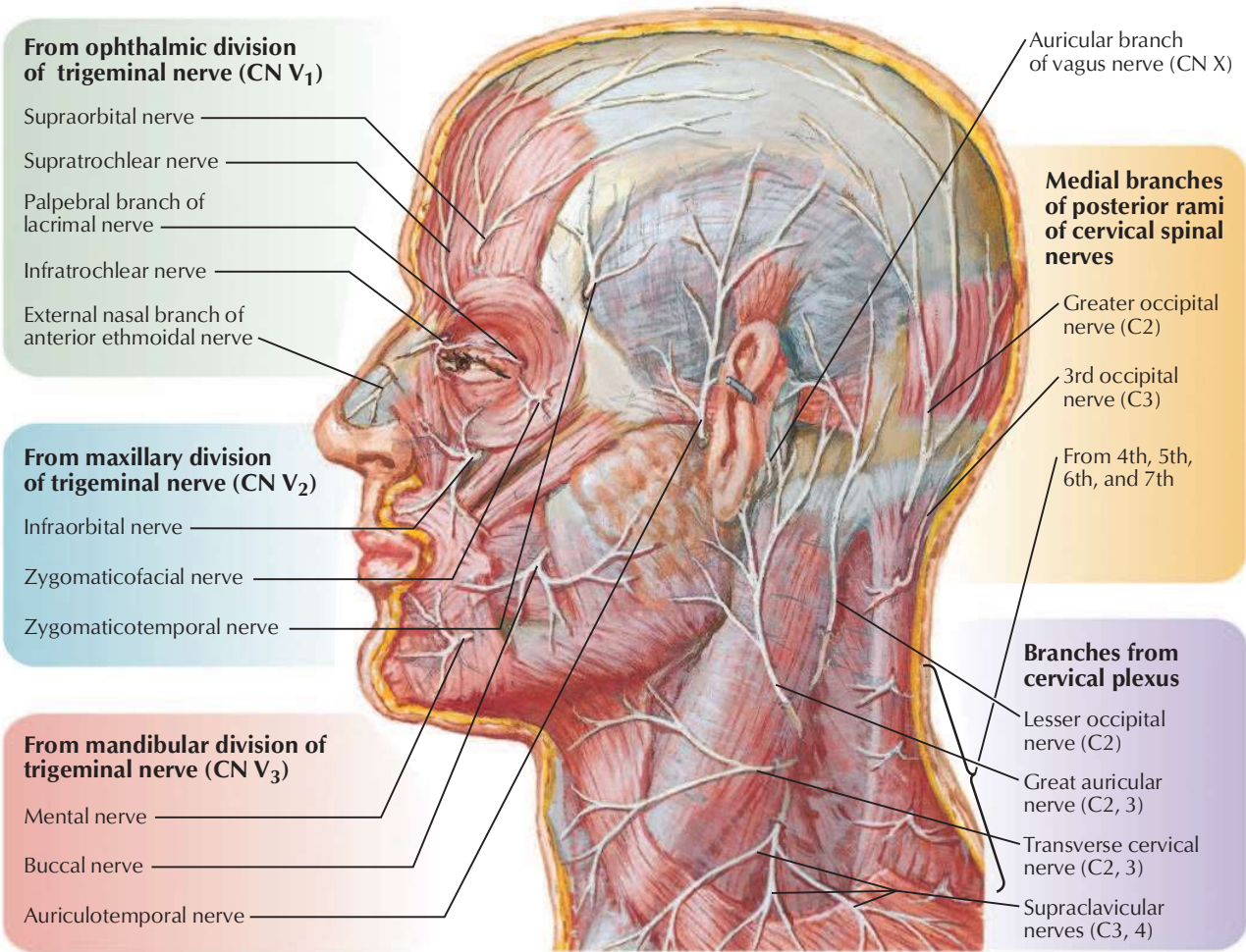
BP32 Axial and Coronal MRIs of Brain



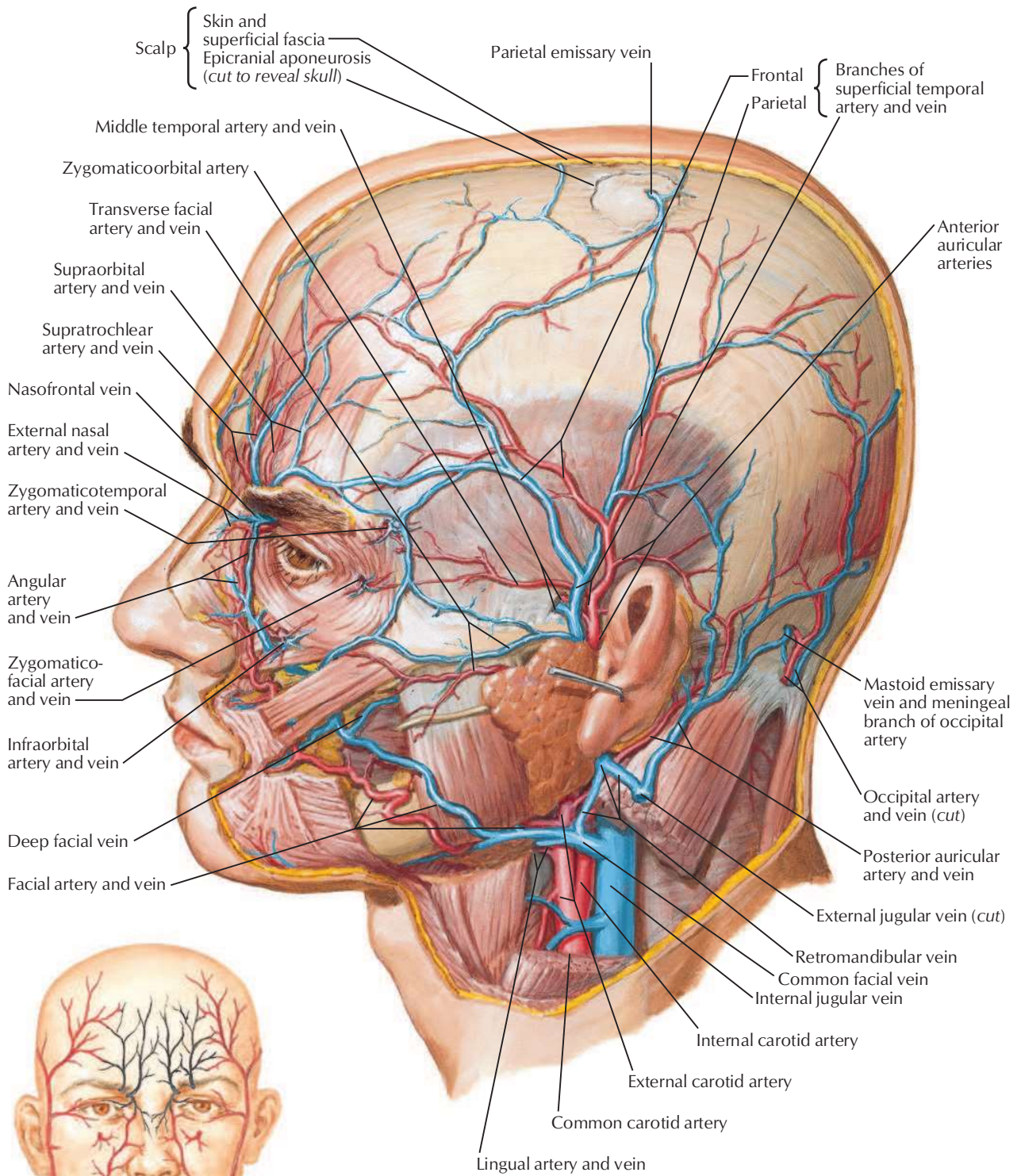
C. Machado
M.D.

Cutaneous Nerves of Head and Neck

See also [Plates 39, 42, 61](#)



See also **Plates 57, 83, 84**



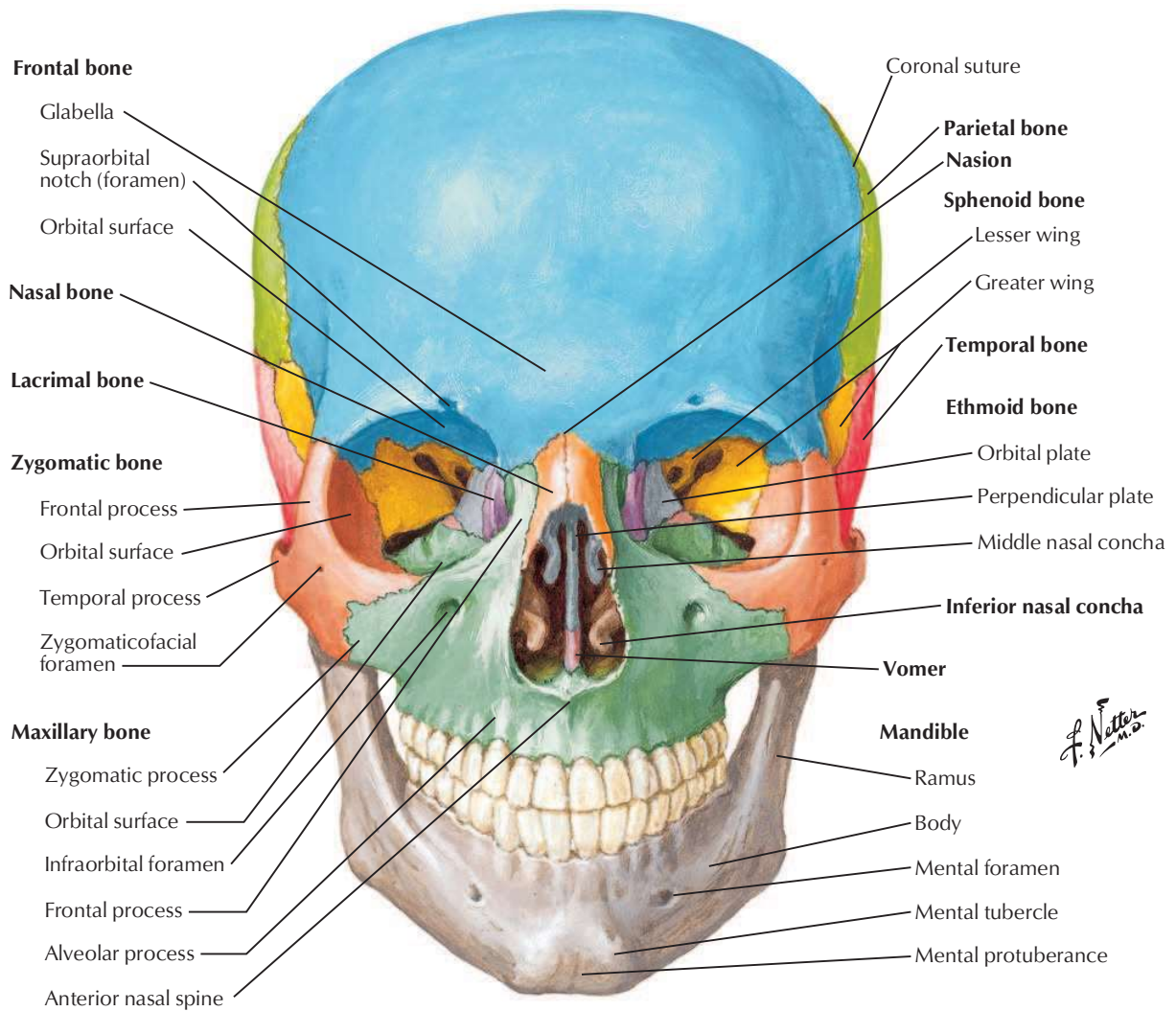
Sources of arterial supply of face

Black: from internal carotid artery (via ophthalmic artery)
 Red: from external carotid artery

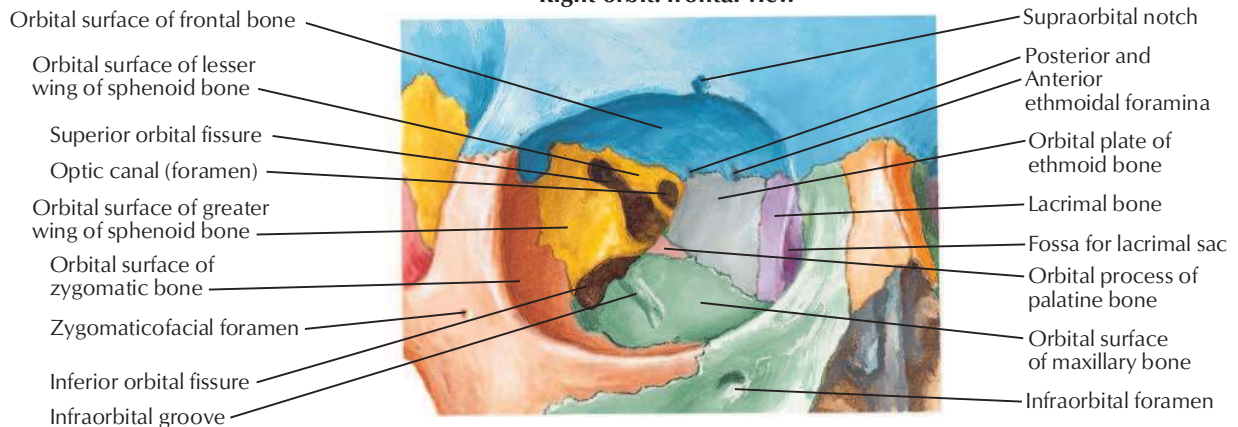
F. Netter M.D.

Skull: Anterior View

See also [Plate 13](#)

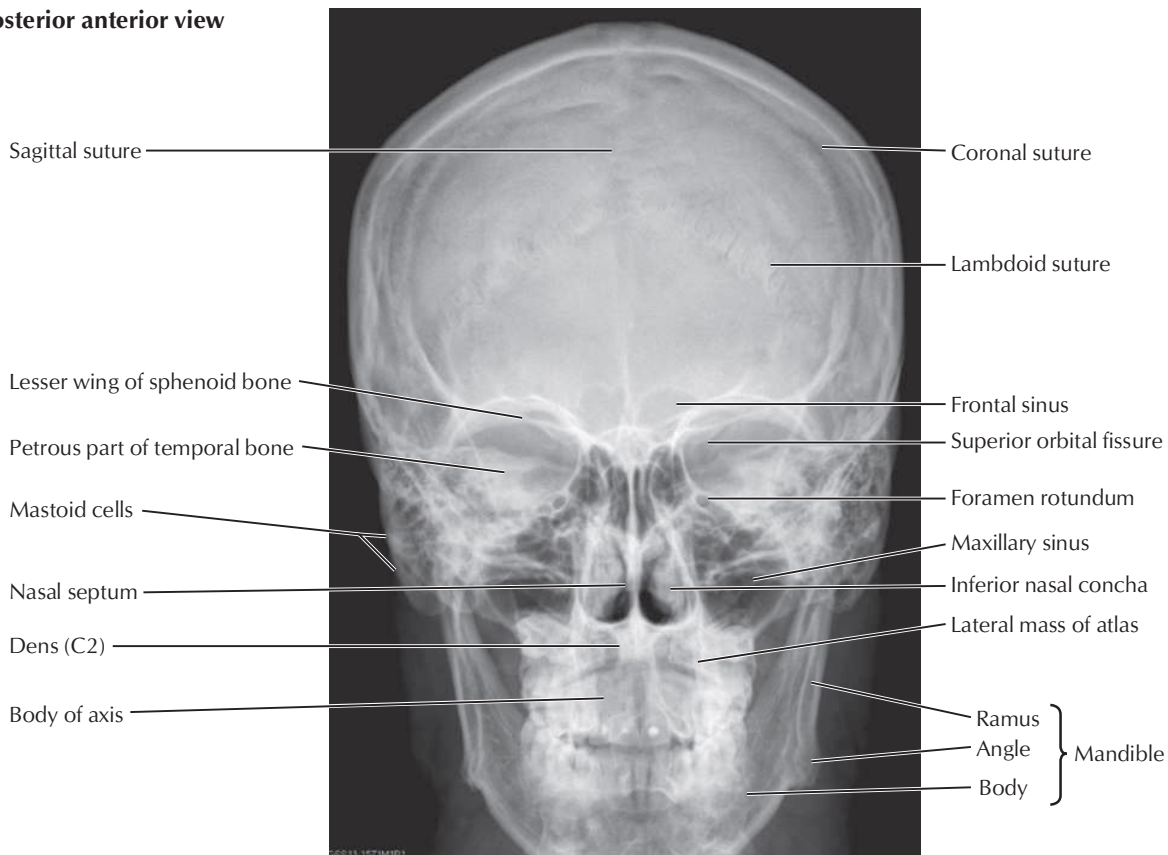


Right orbit: frontal view

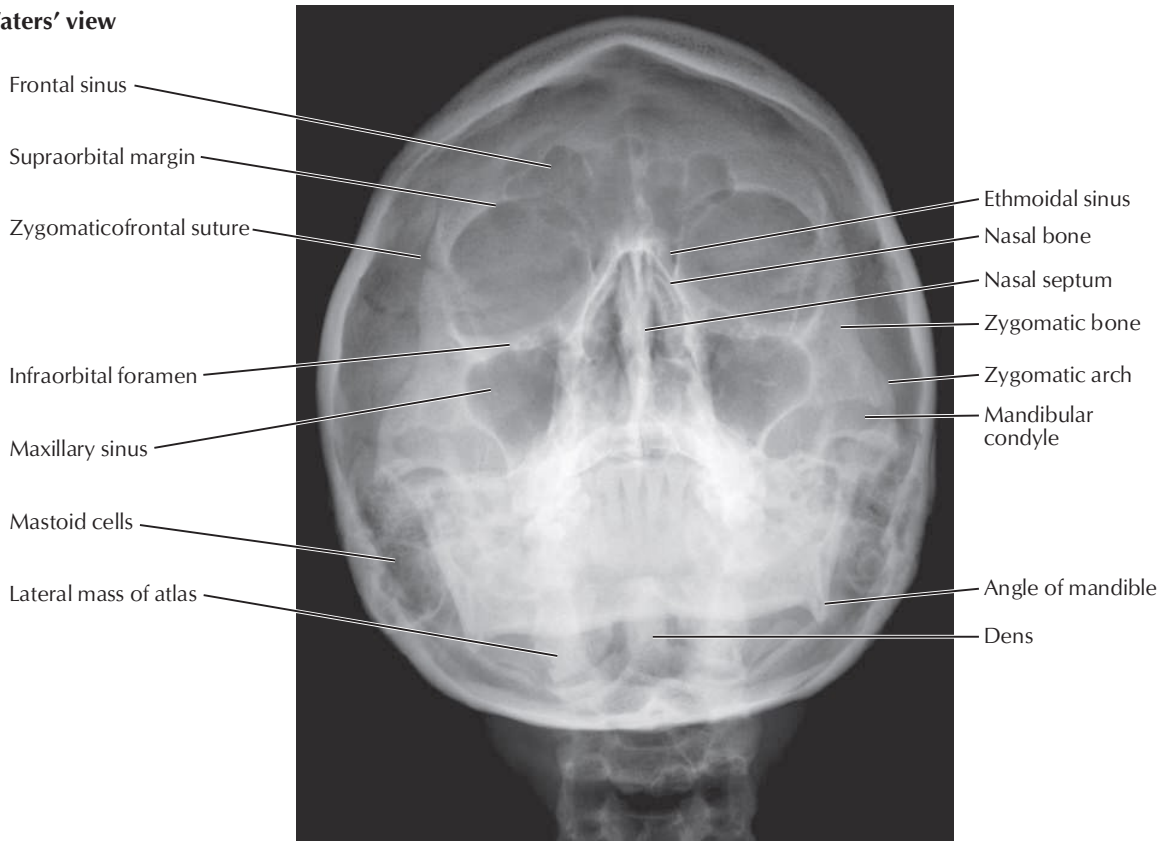


See also [Plate 11](#)

Posterior anterior view

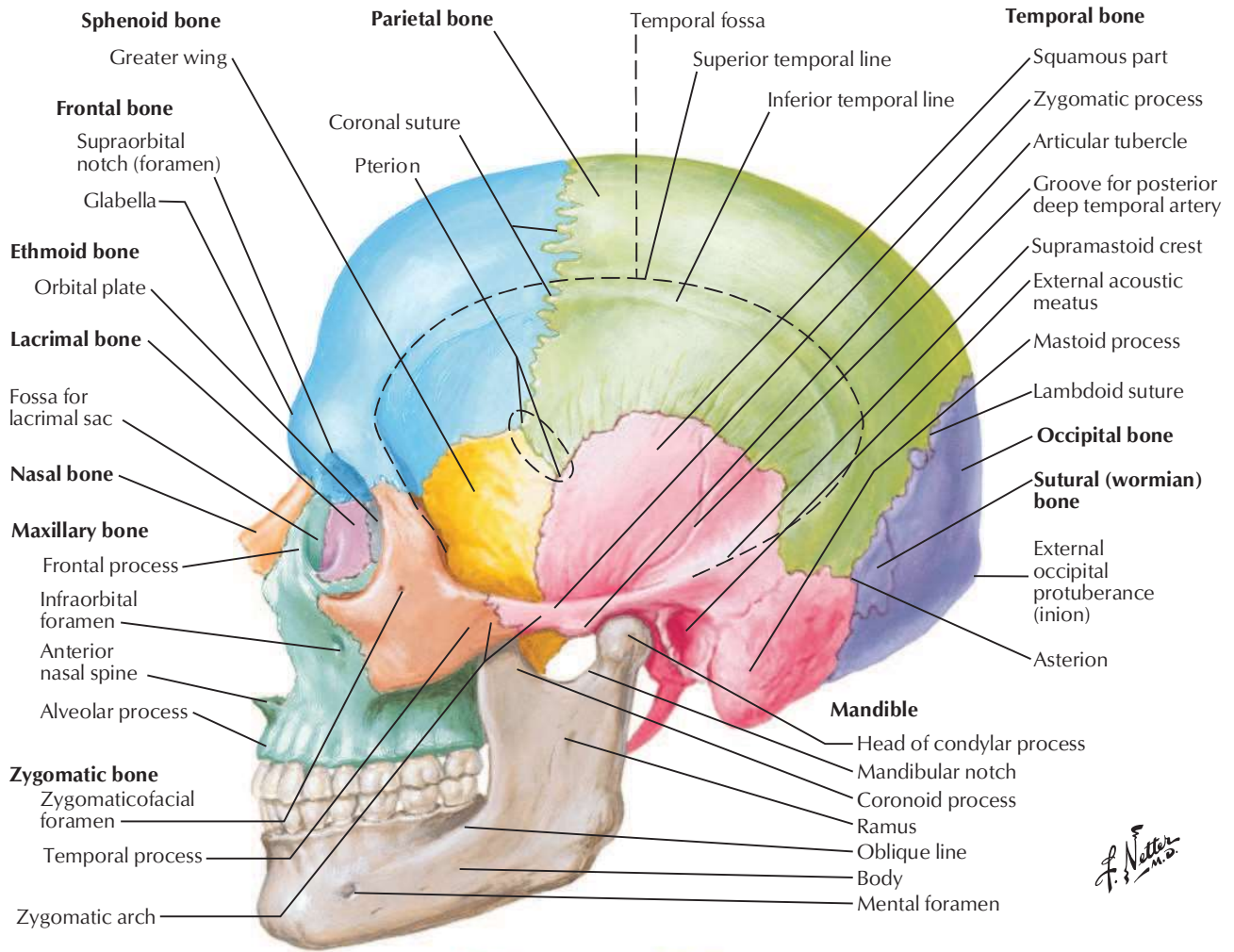
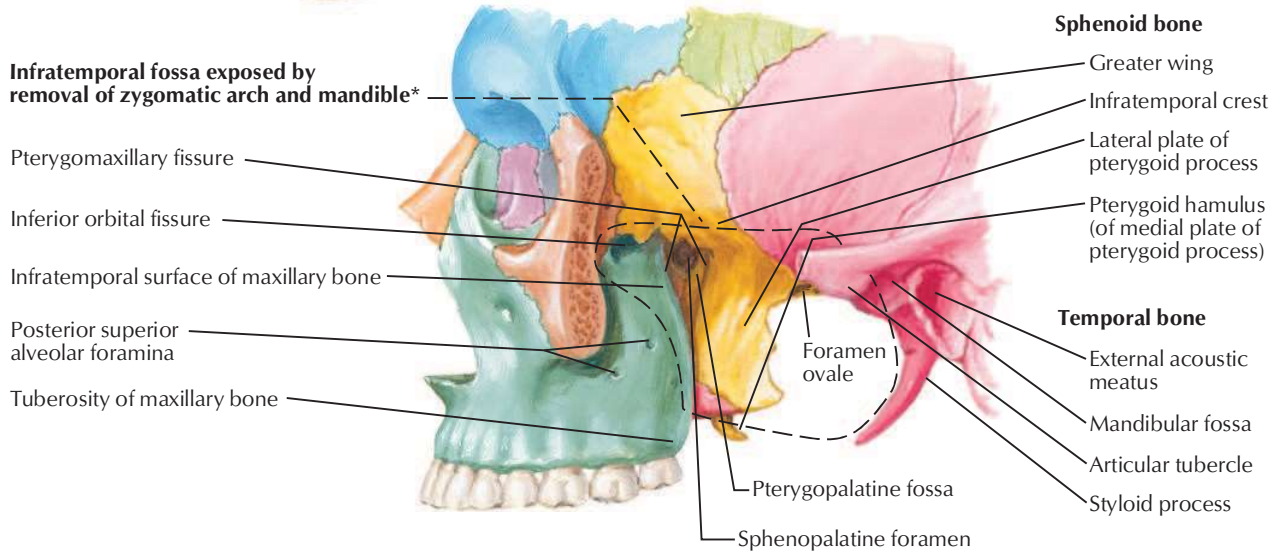


Waters' view



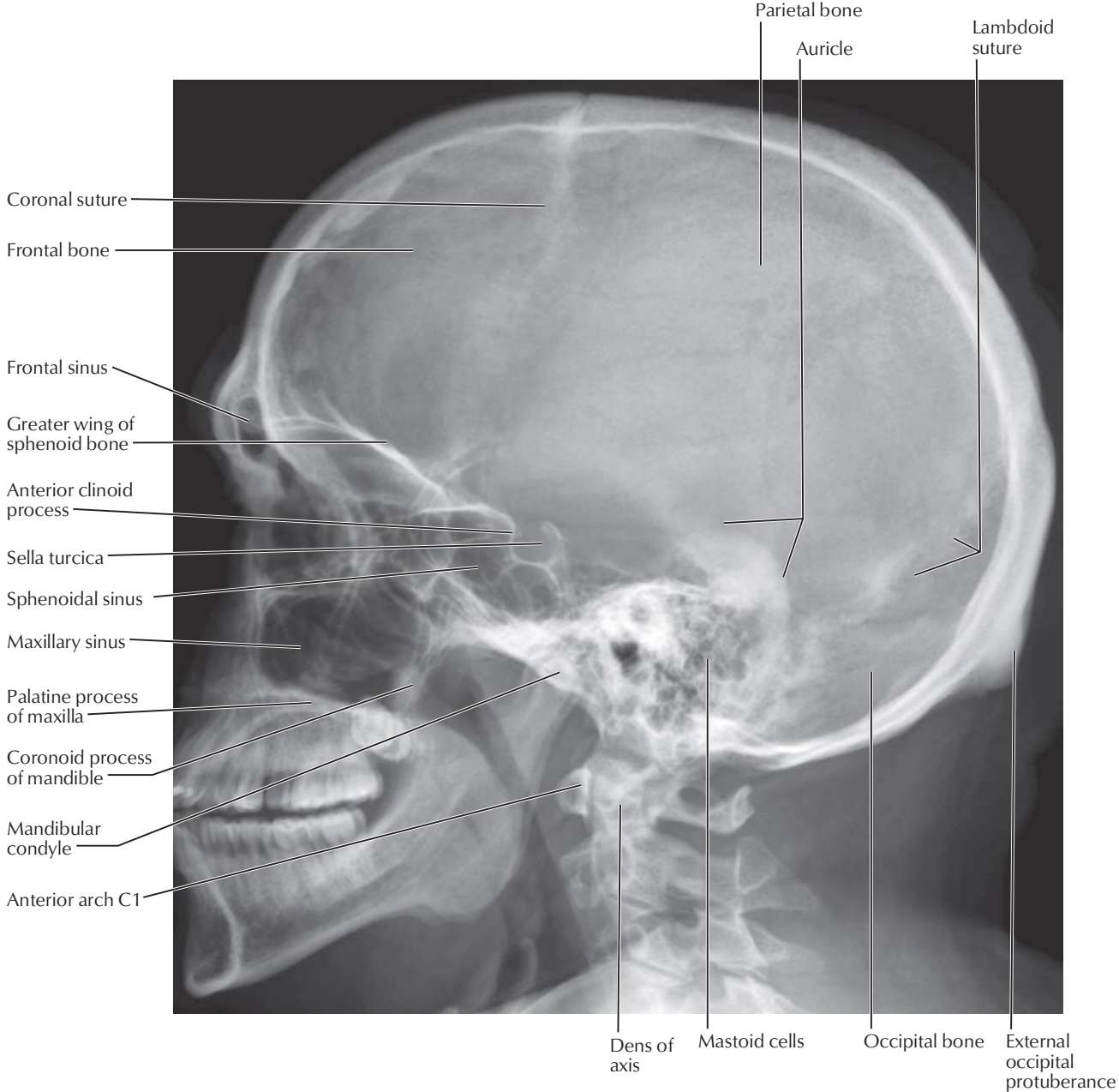
Skull: Lateral View

See also [Plates 14, 15, 22](#)

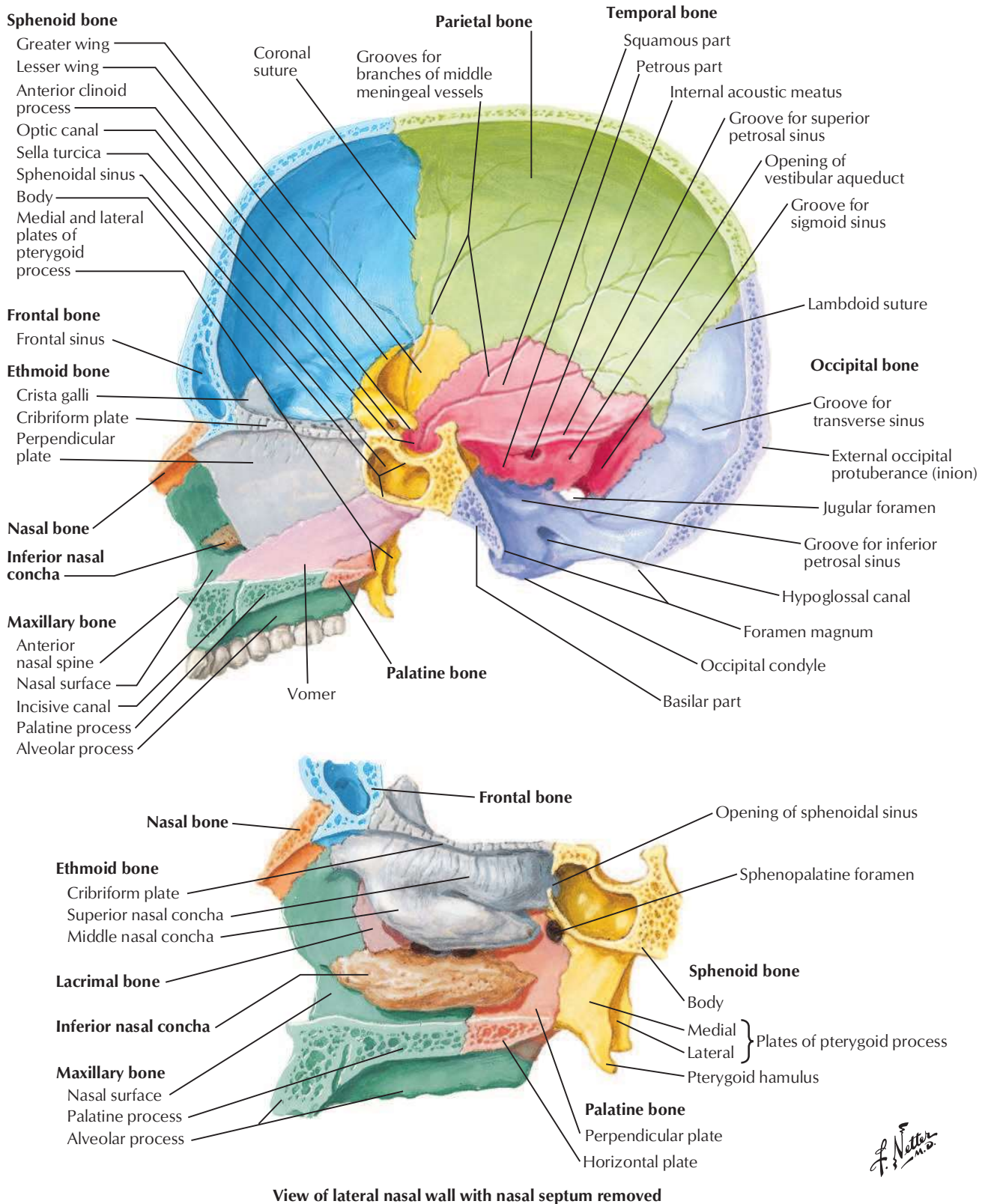
*Superficially, mastoid process forms posterior boundary.

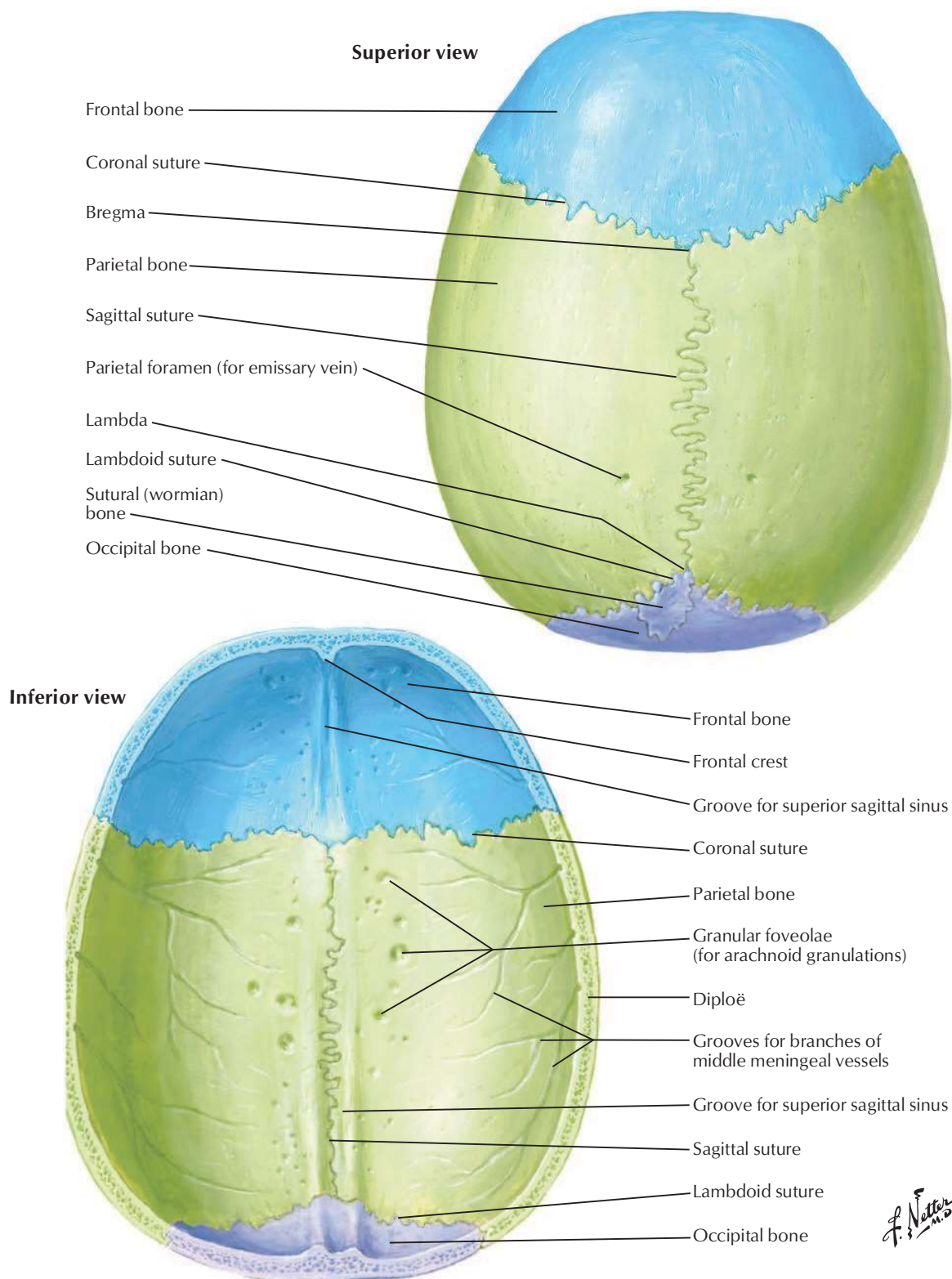
See also [Plate 15](#)

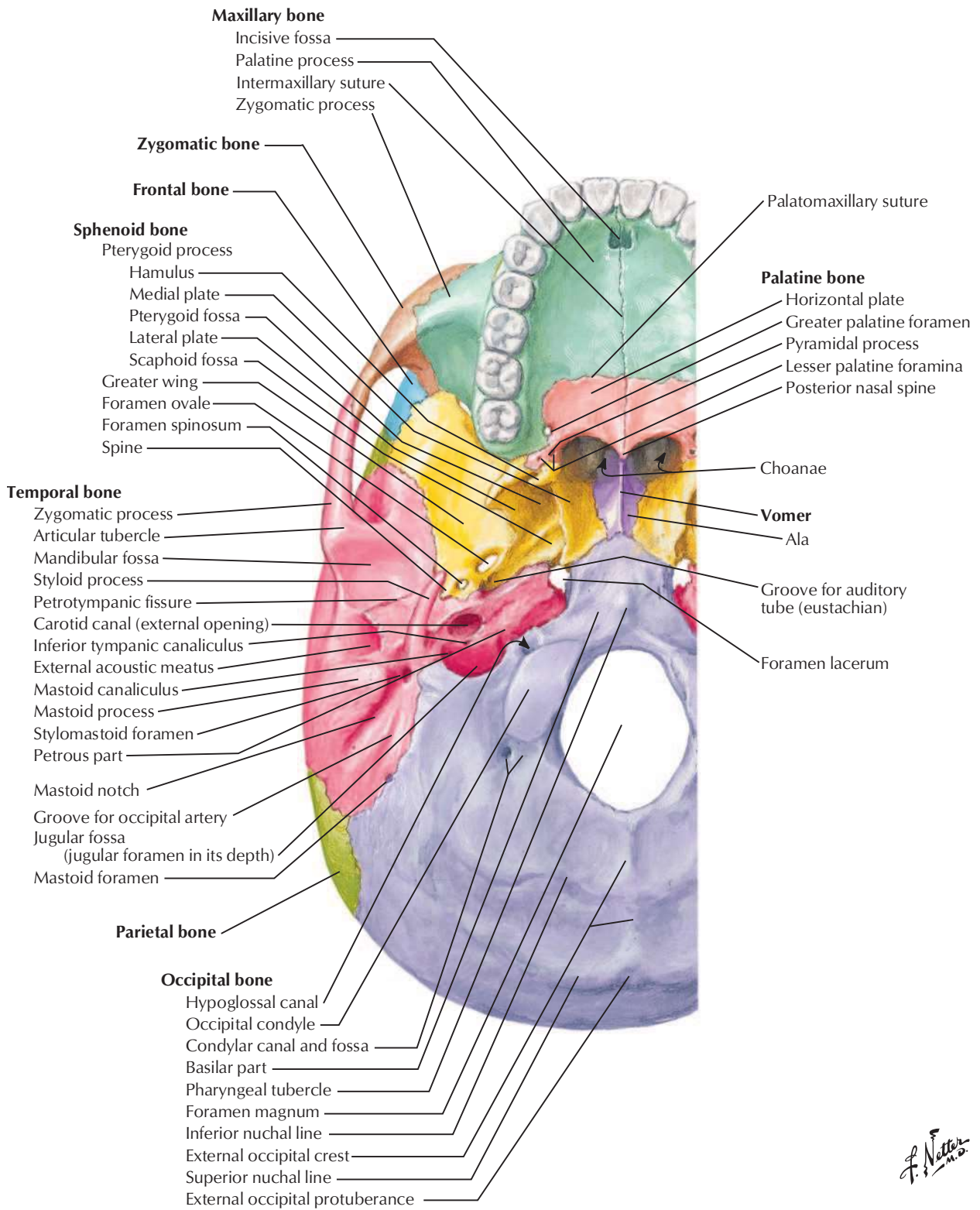


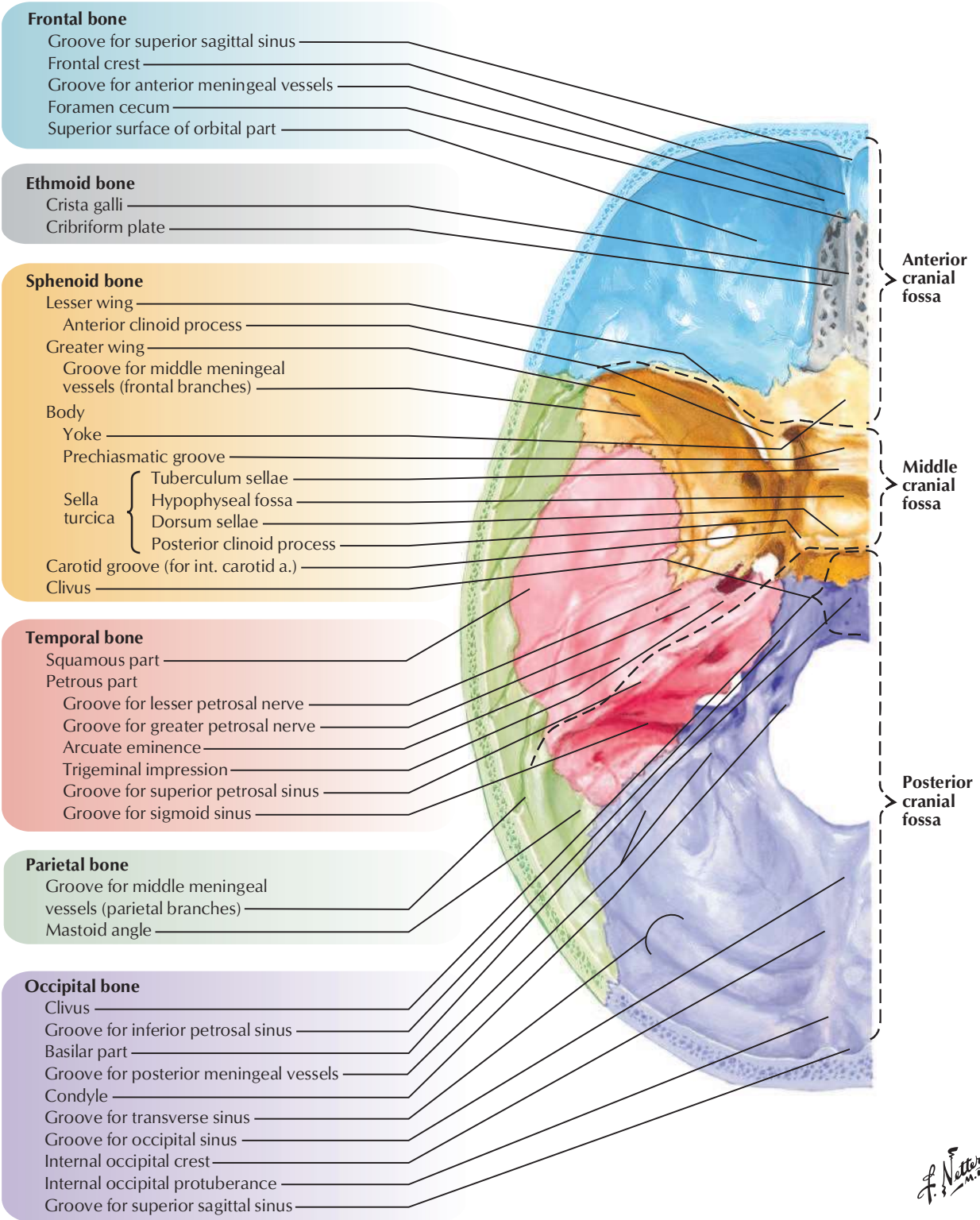
Skull: Midsagittal Section

See also [Plates 44, 46](#)



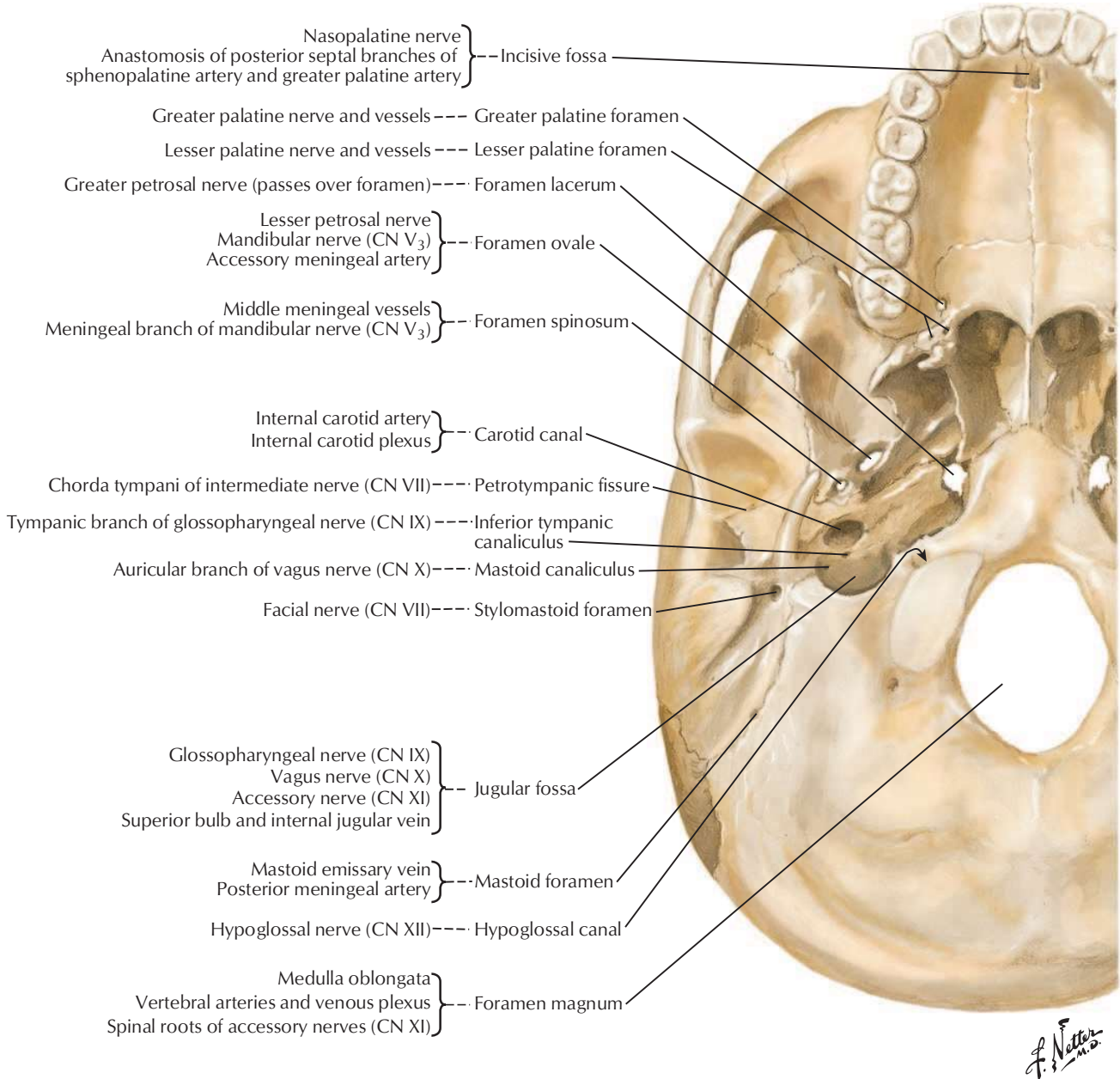




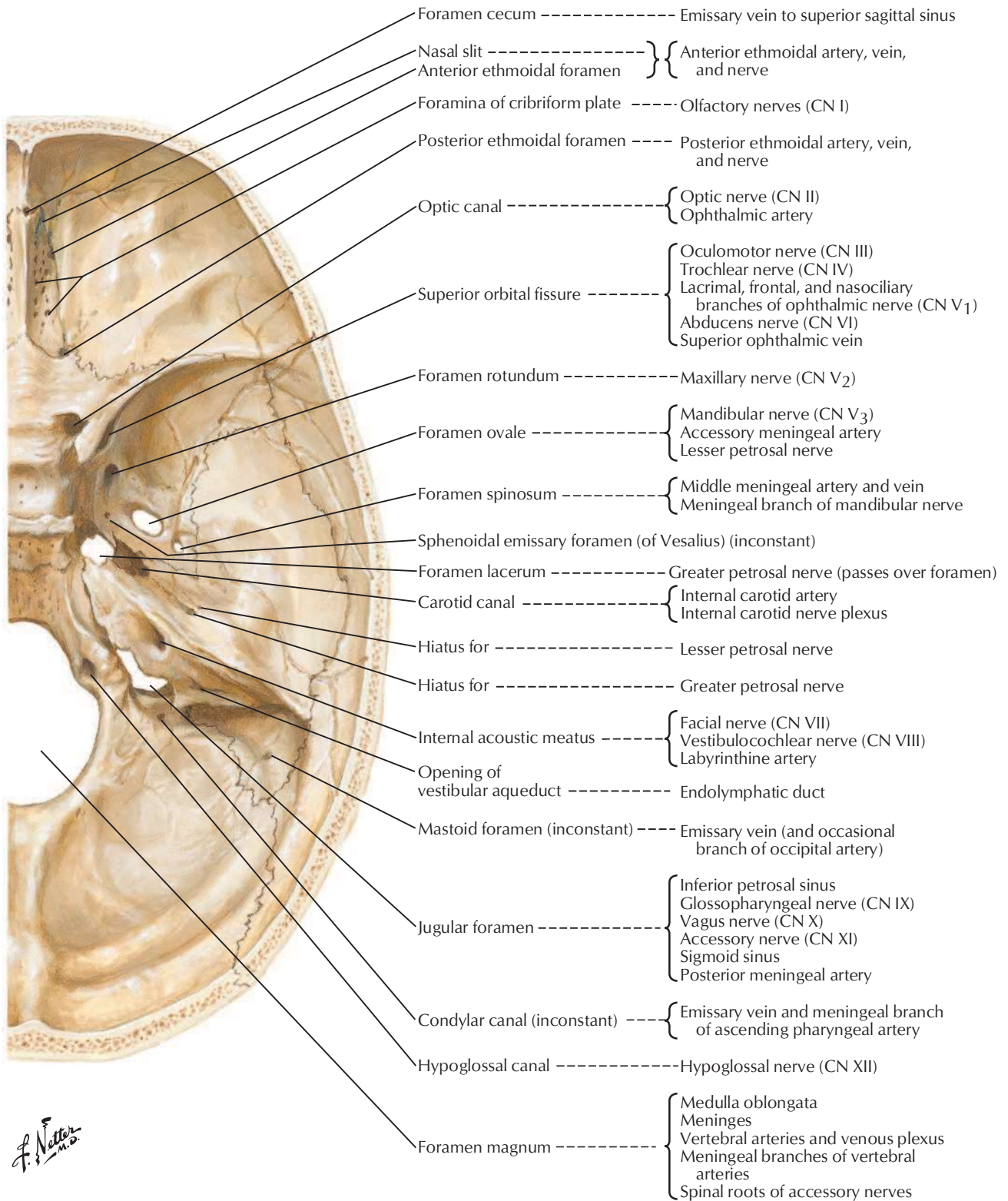


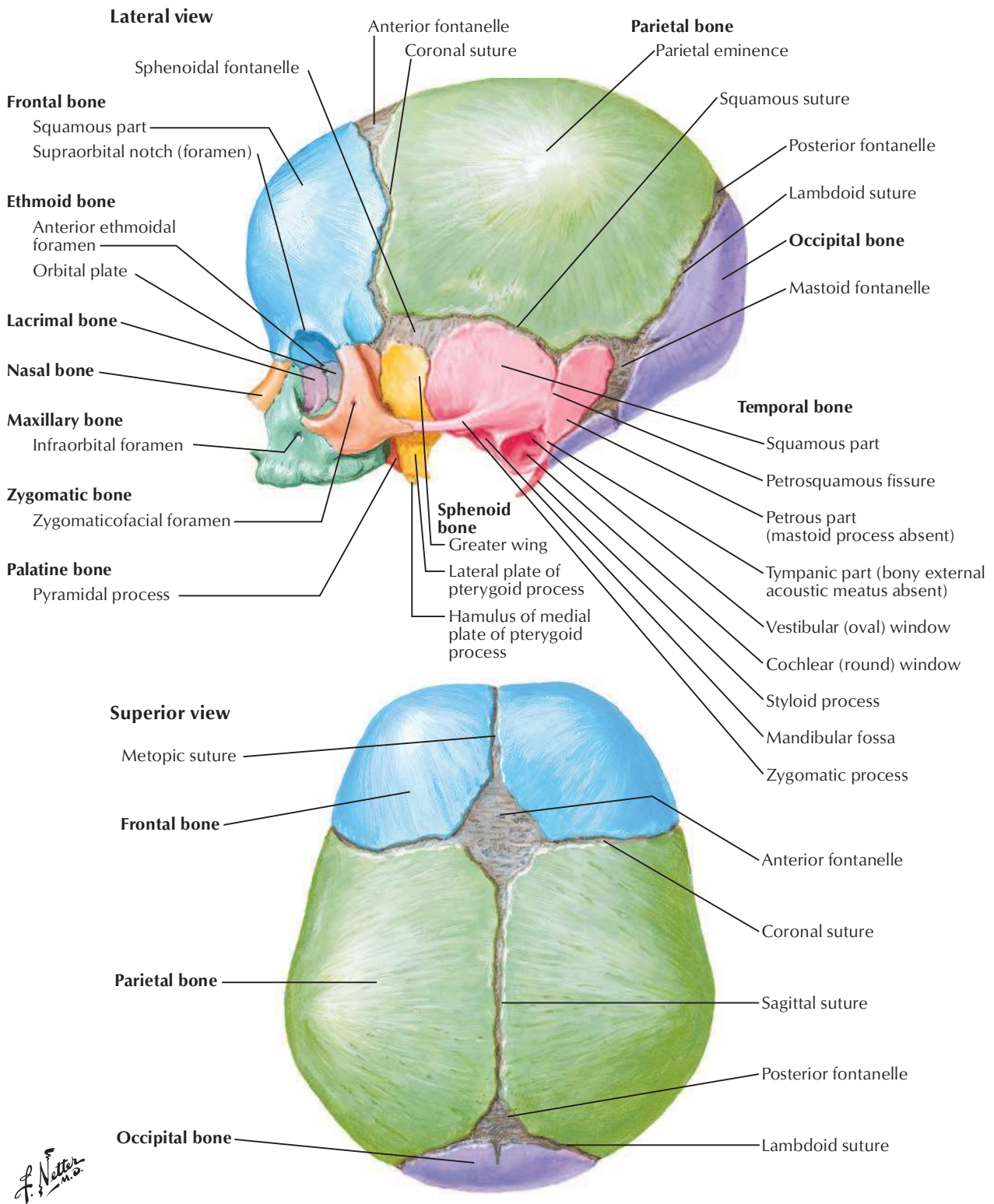
Foramina and Canals of Cranial Base: Inferior View

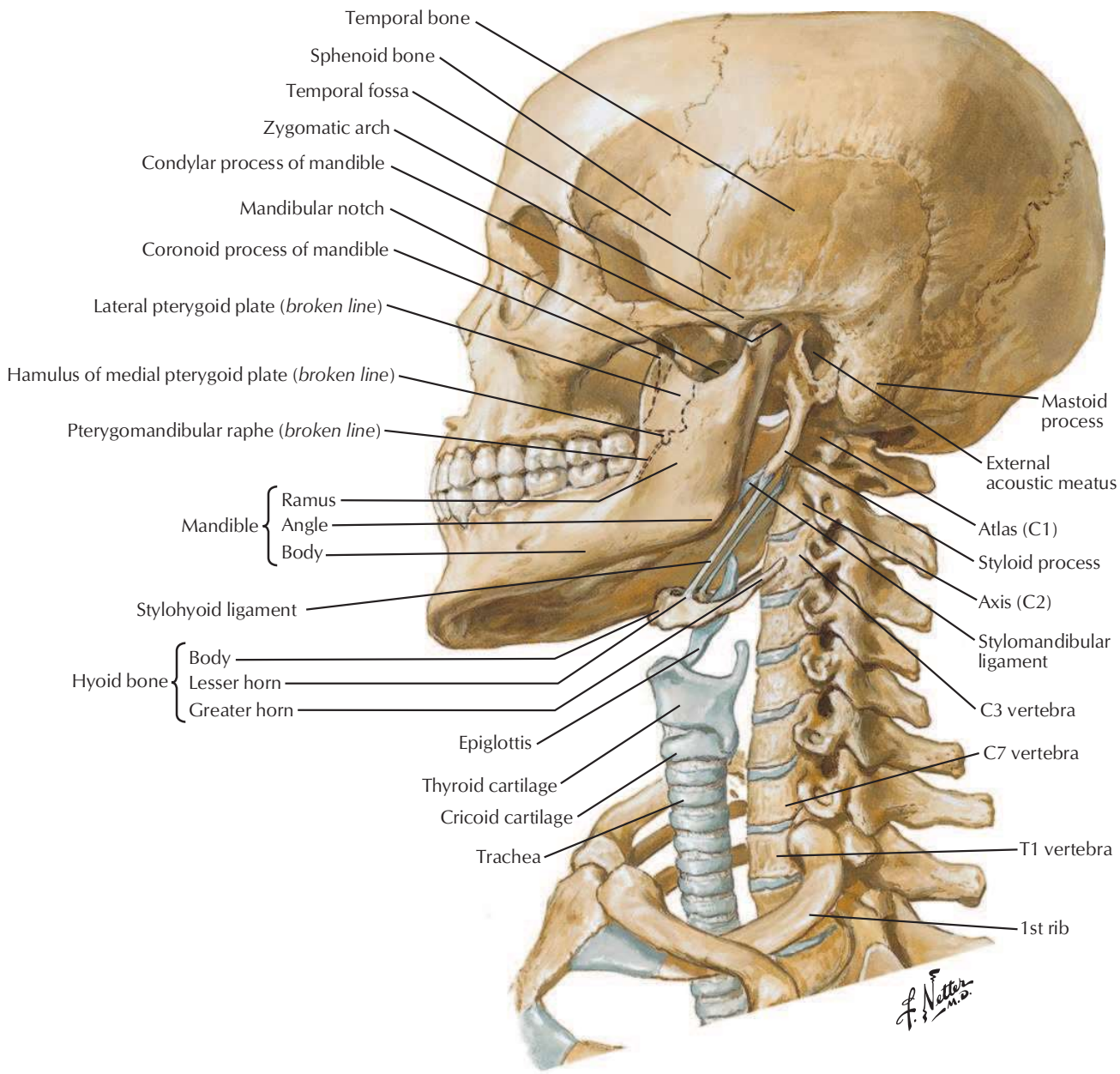
See also [Plate 17](#)



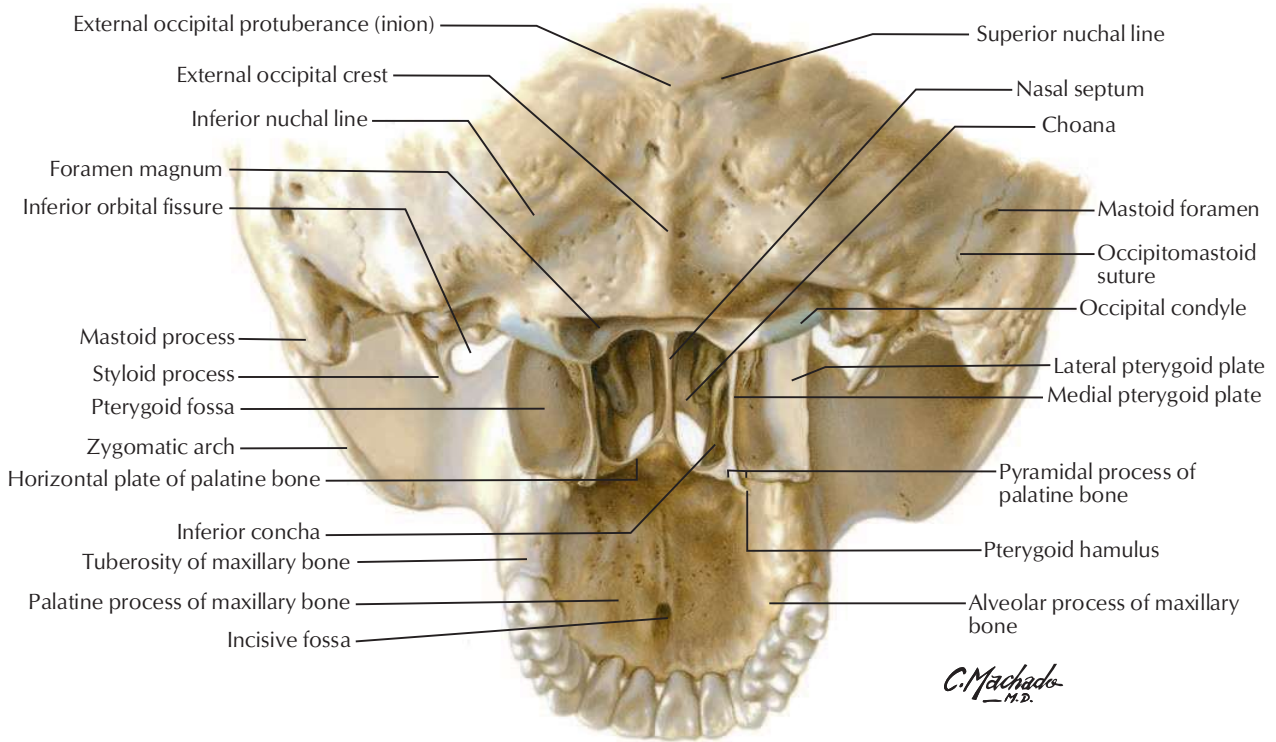
See also **Plates 18, 115**



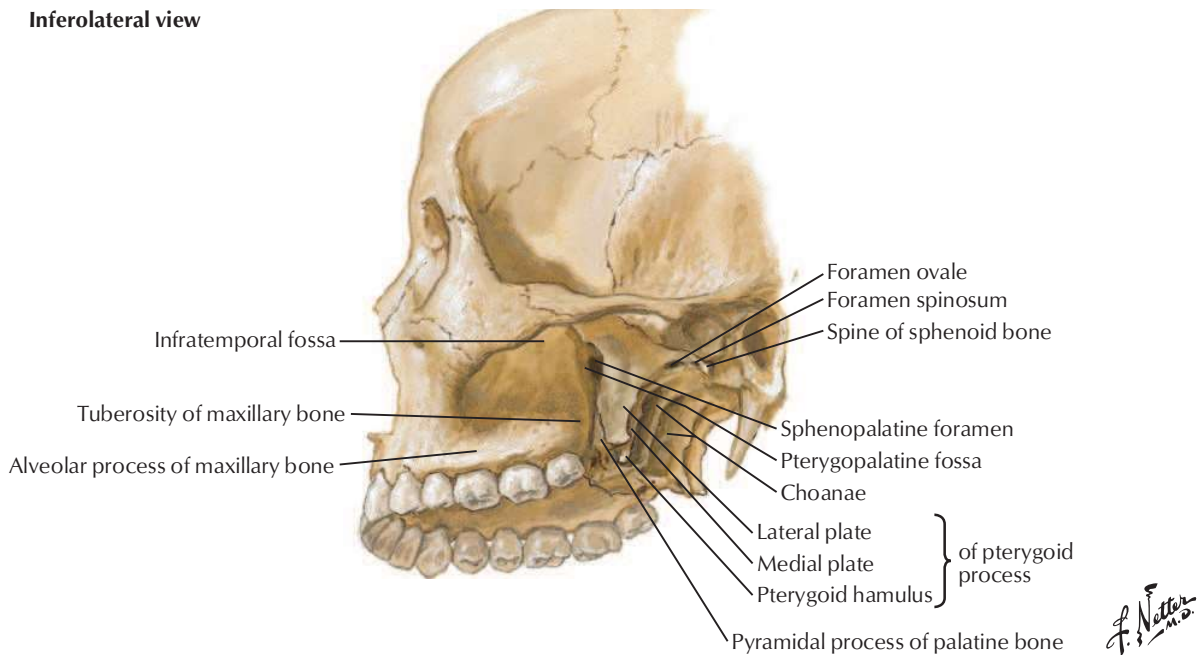


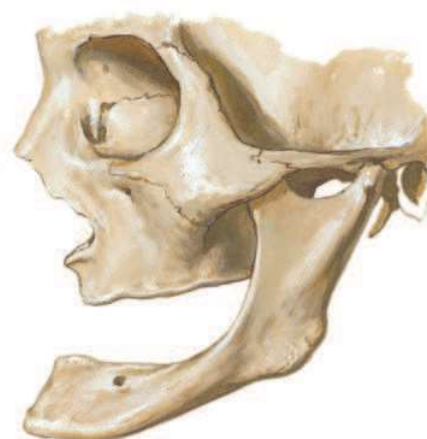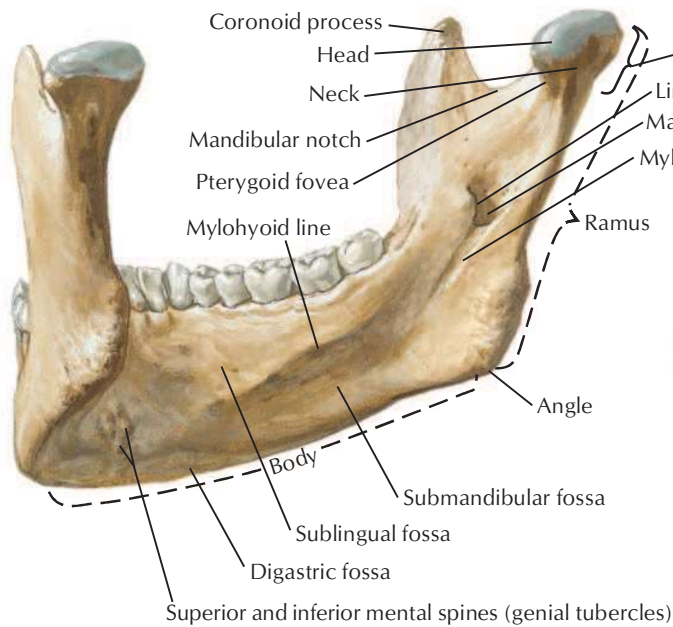
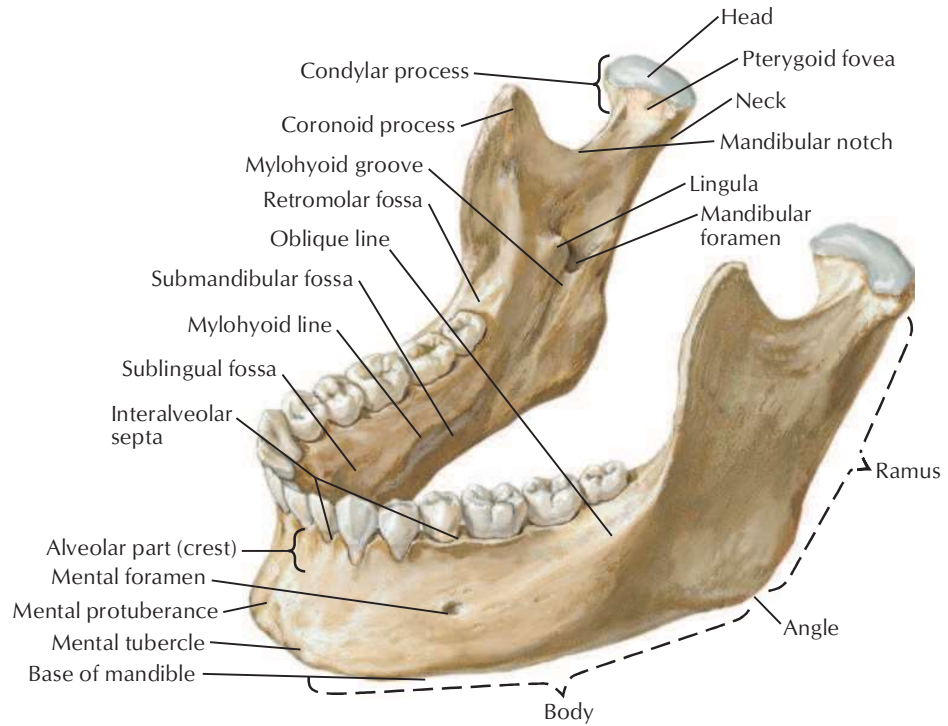


Posterior view

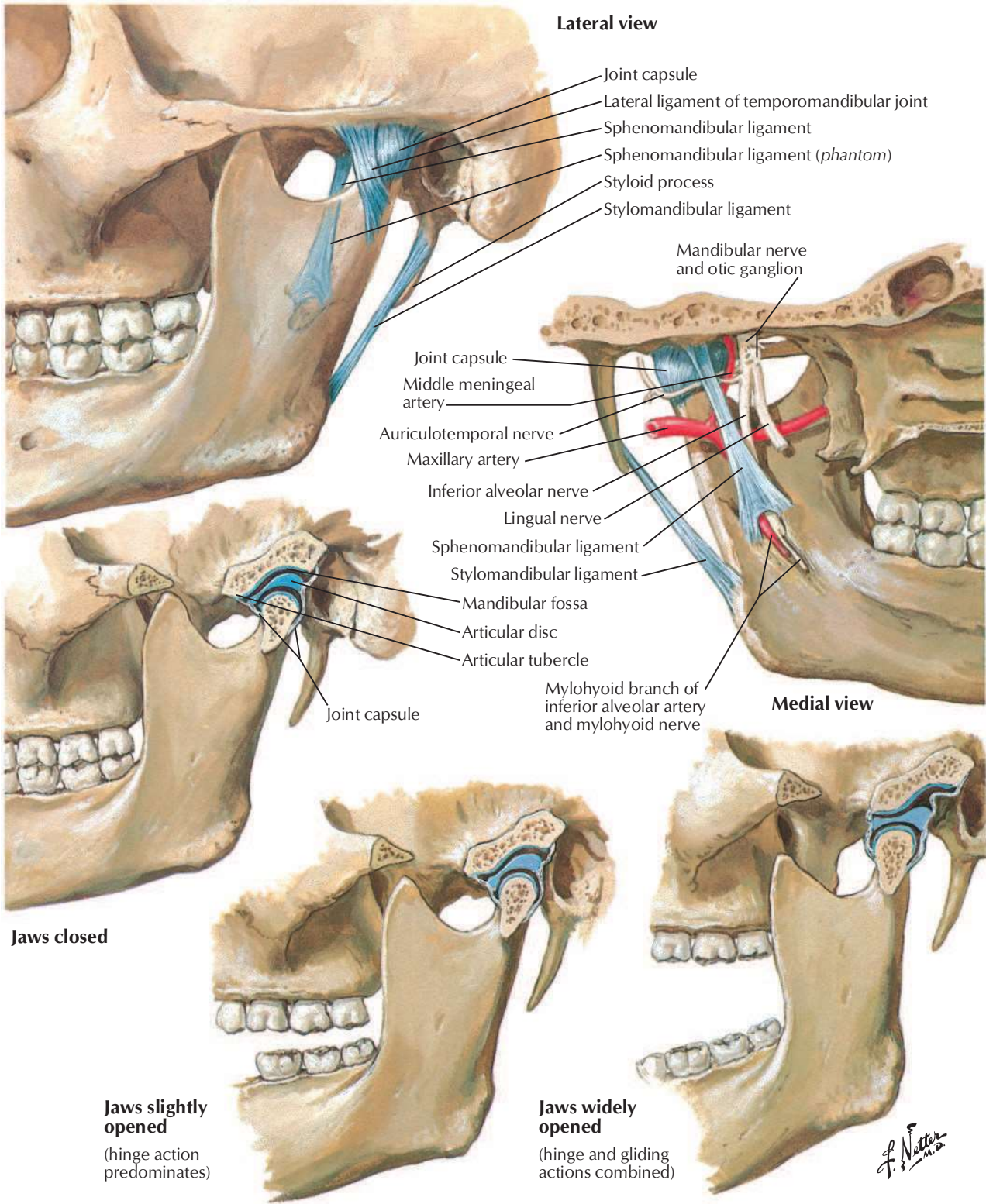


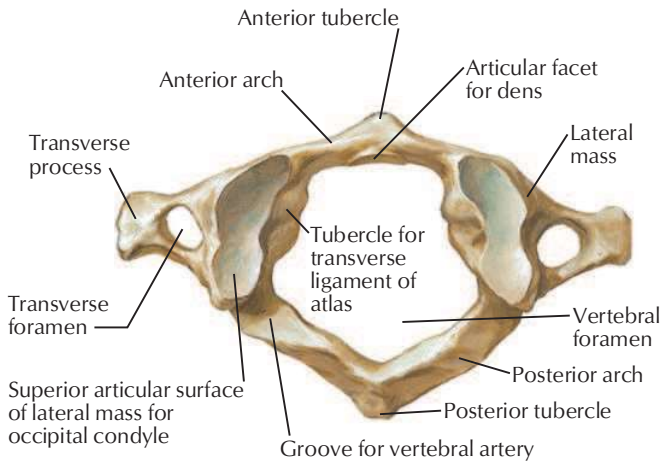
Inferolateral view



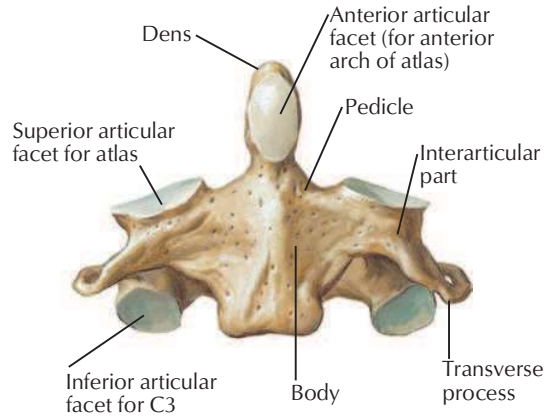


Mandible of aged person (edentulous)

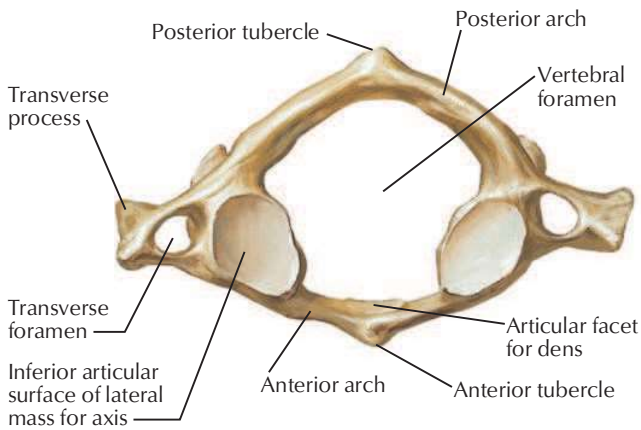




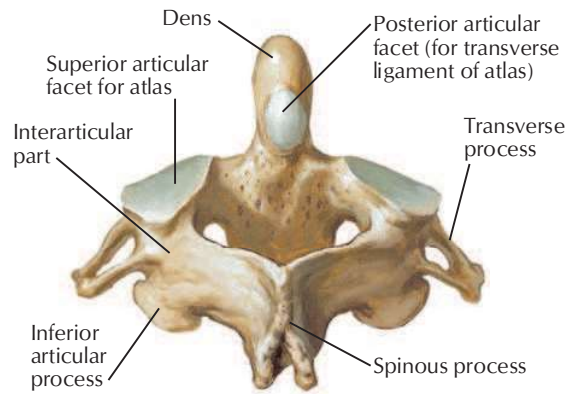
Atlas (C1): superior view



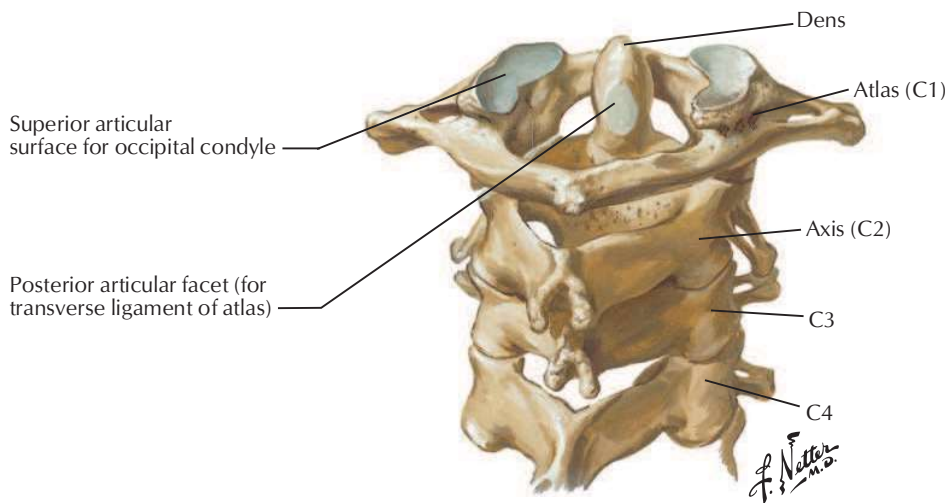
Axis (C2): anterior view



Atlas (C1): inferior view

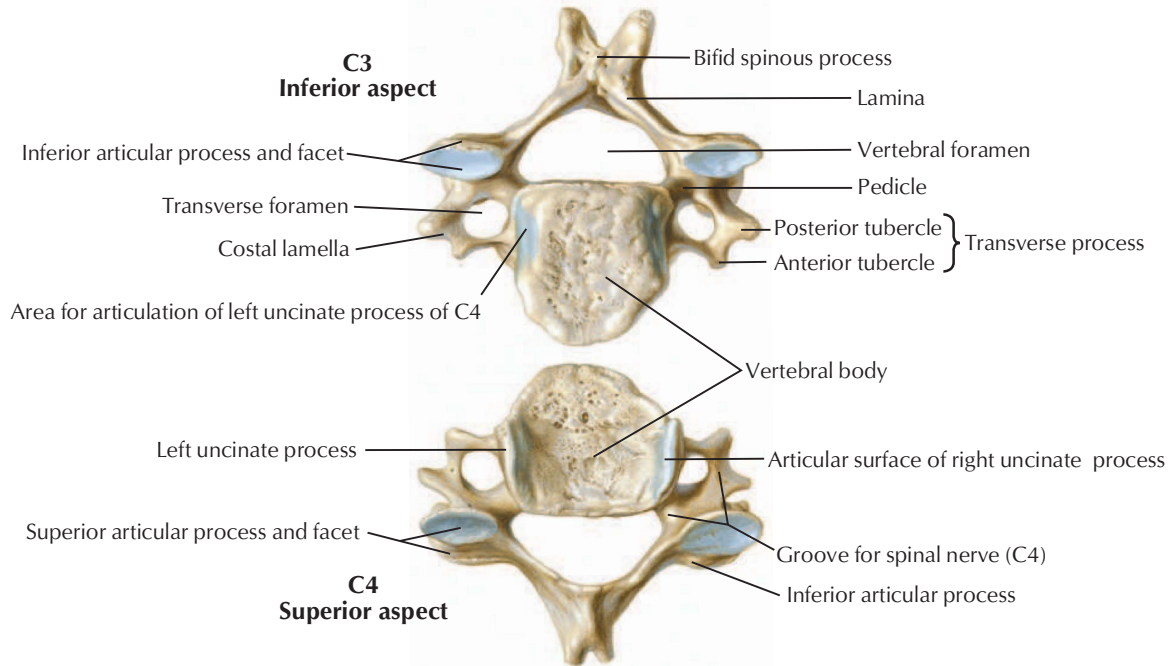


Axis (C2): posterosuperior view

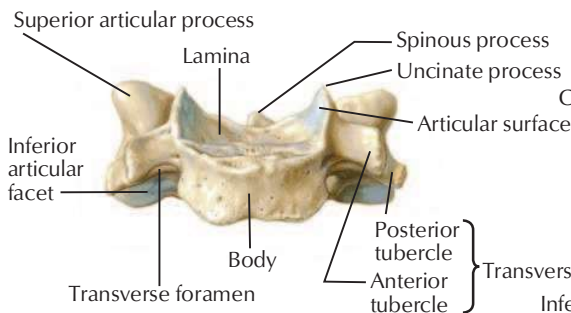


Upper cervical vertebrae, assembled: posterosuperior view

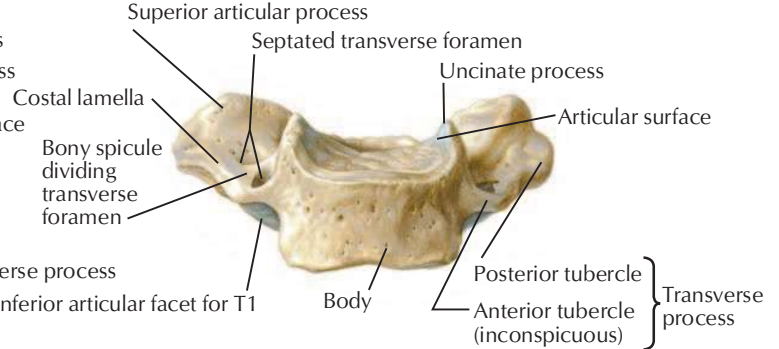
Inferior aspect of C3 and superior aspect of C4 showing the sites of the facet and uncovertebral articulations



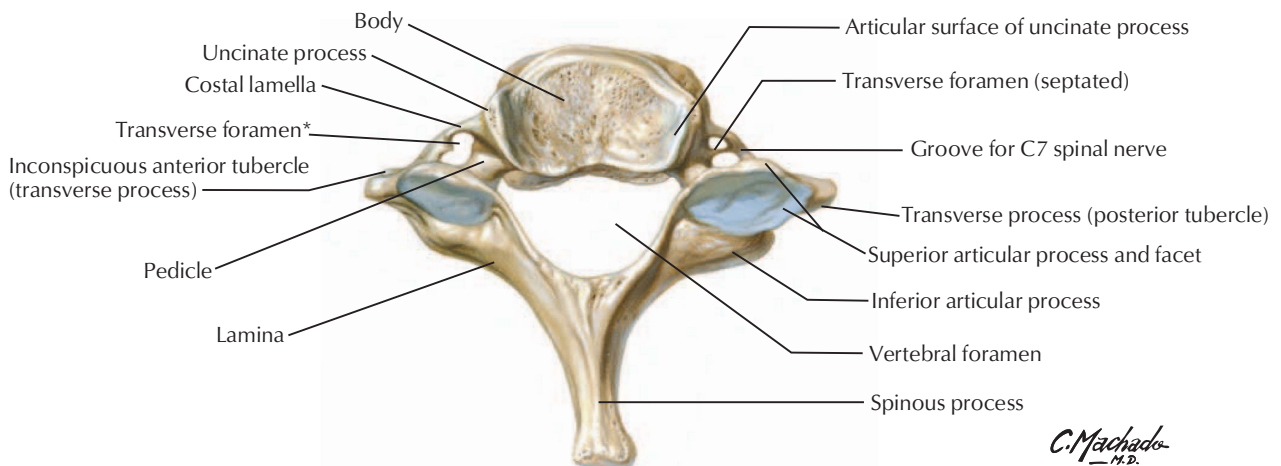
4th cervical vertebra: anterior view



7th cervical vertebra: anterior view



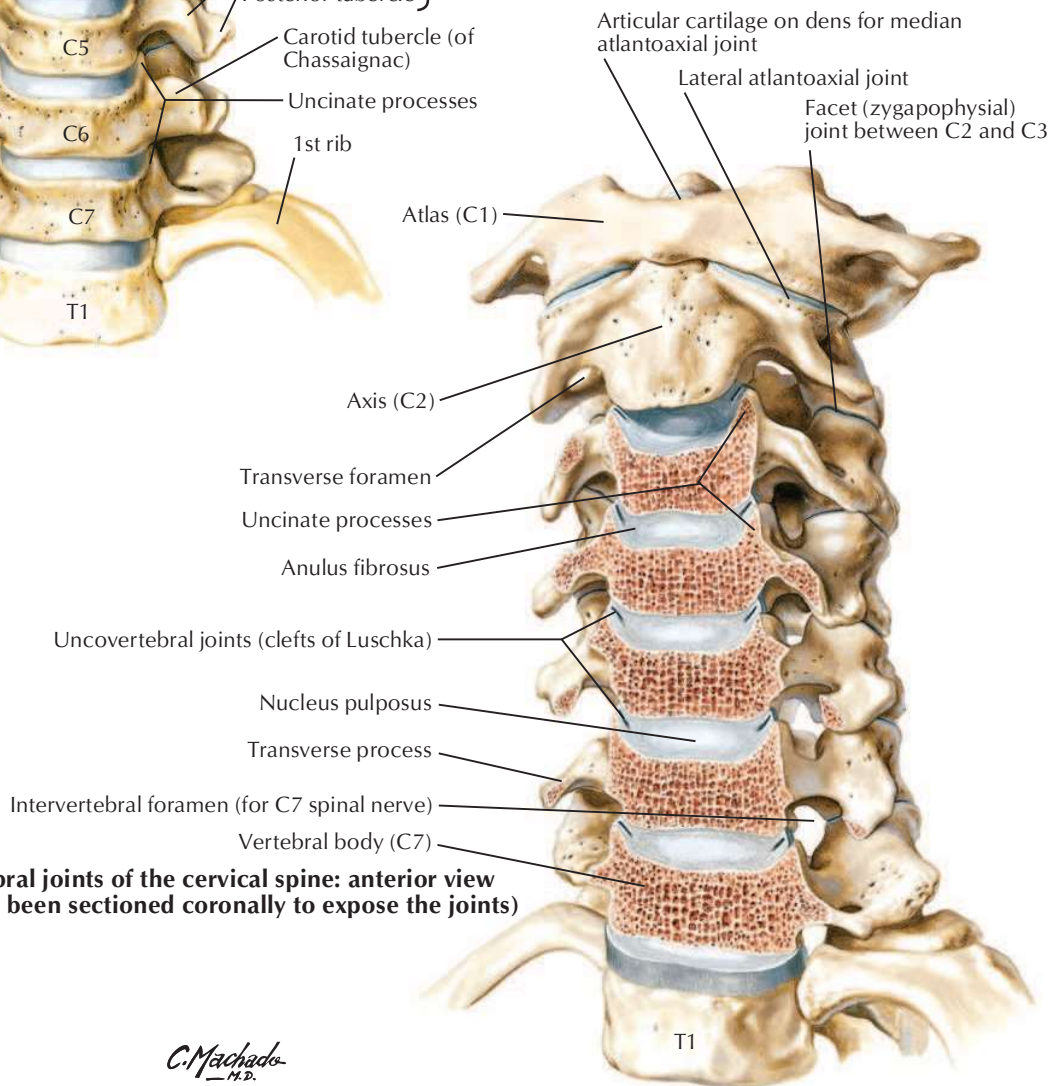
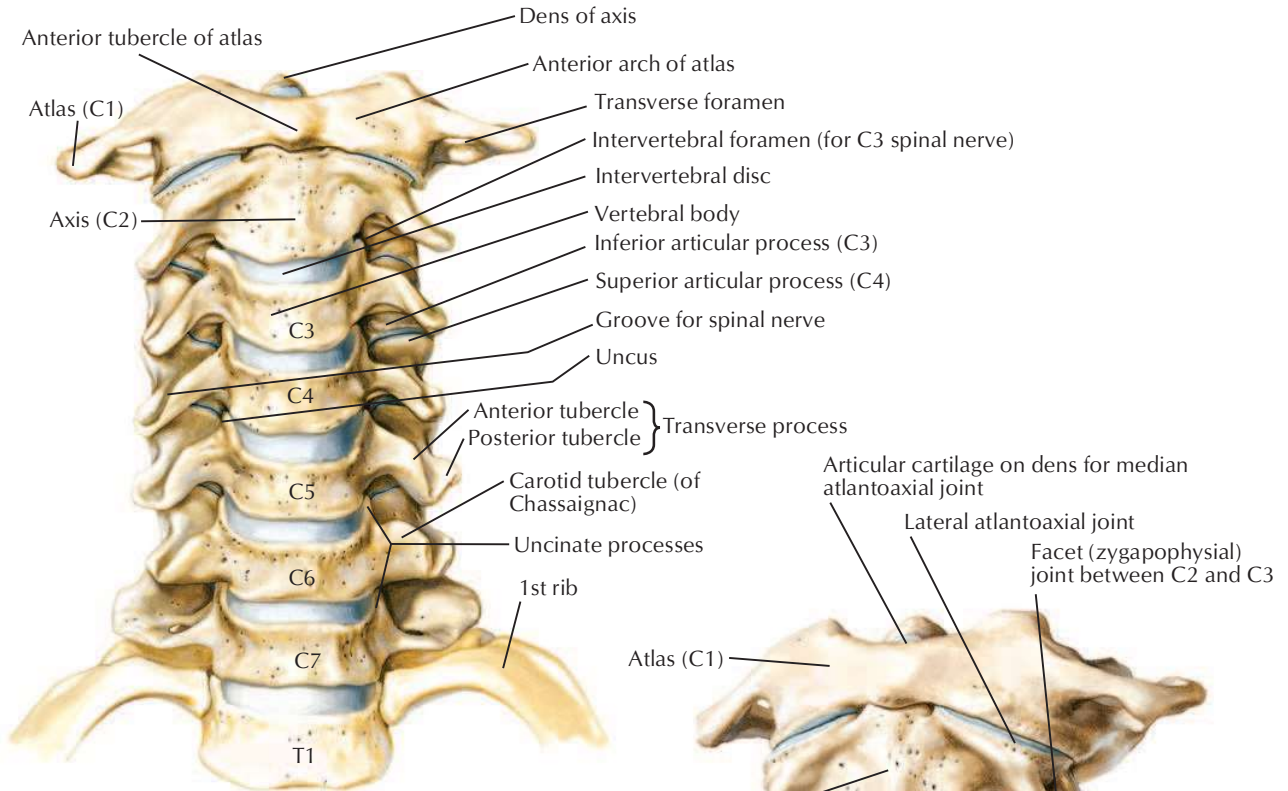
7th cervical vertebra (vertebra prominens): superior view



C. Machado M.D.

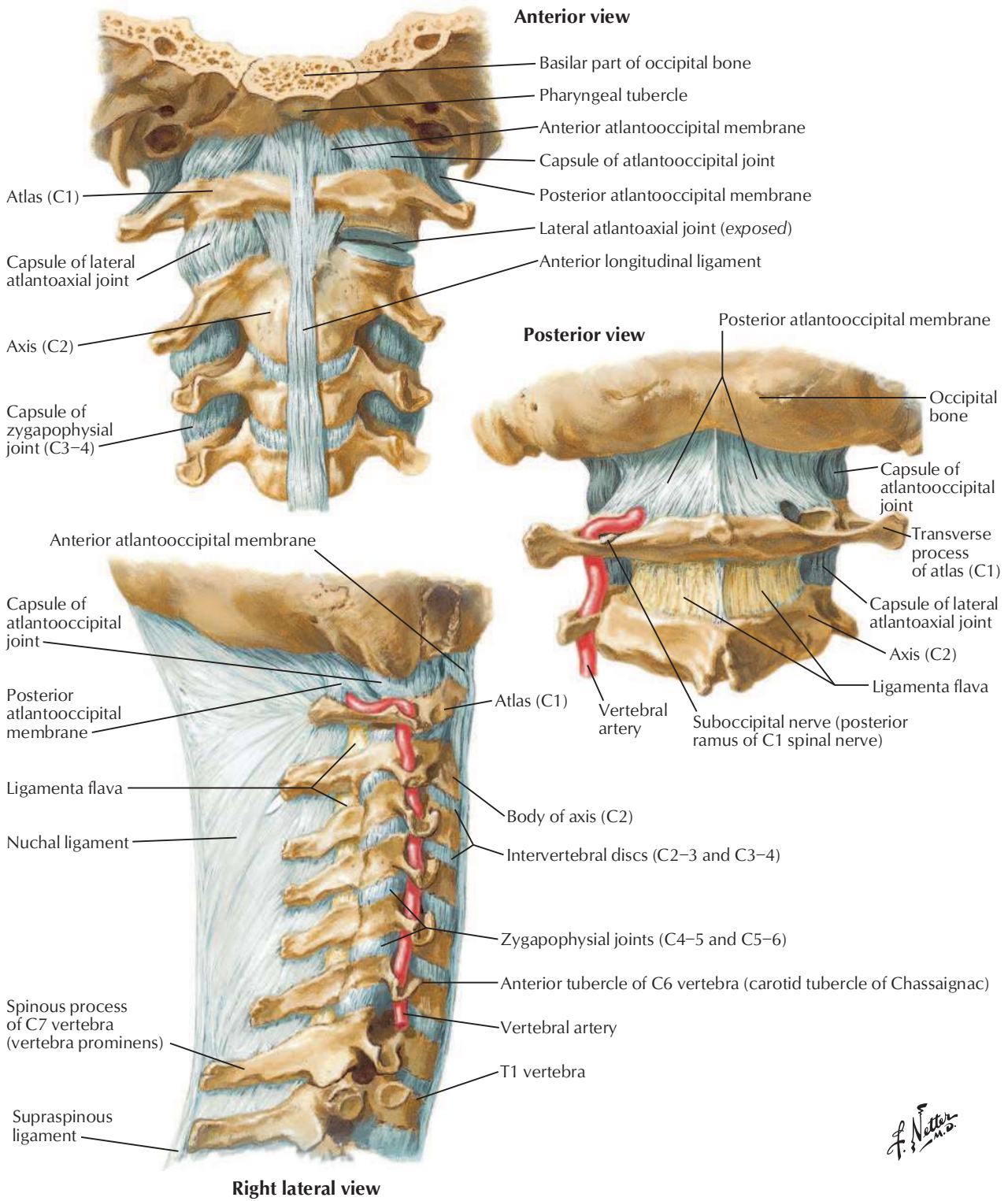
*The foramina transversaria of C7 transmit vertebral veins, but usually not the vertebral artery, and are asymmetrical in this specimen.

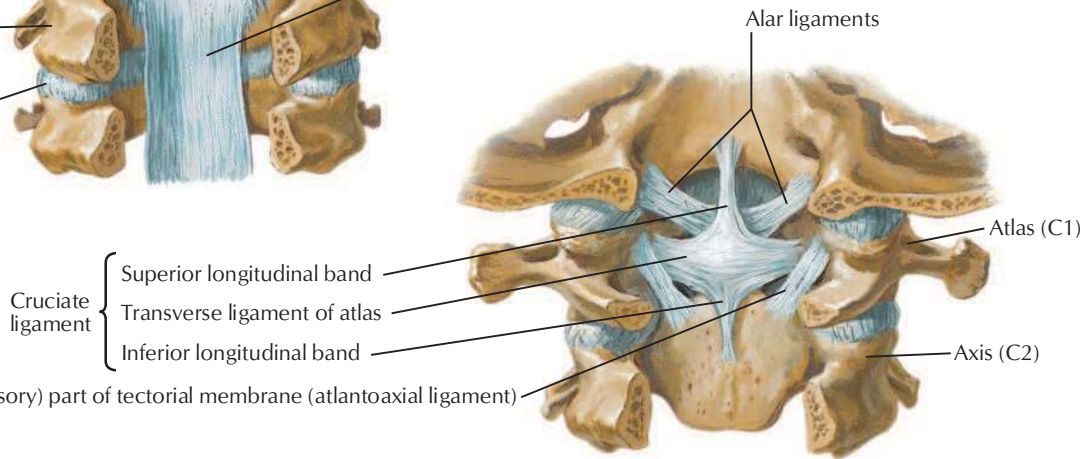
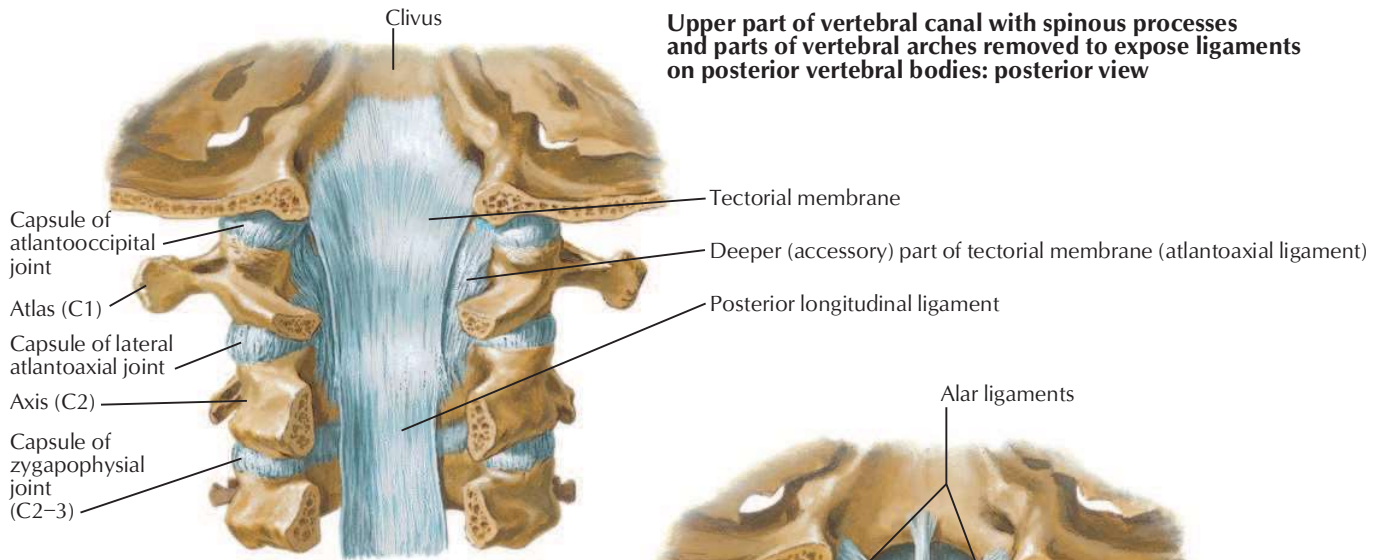
Cervical vertebrae: anterior view



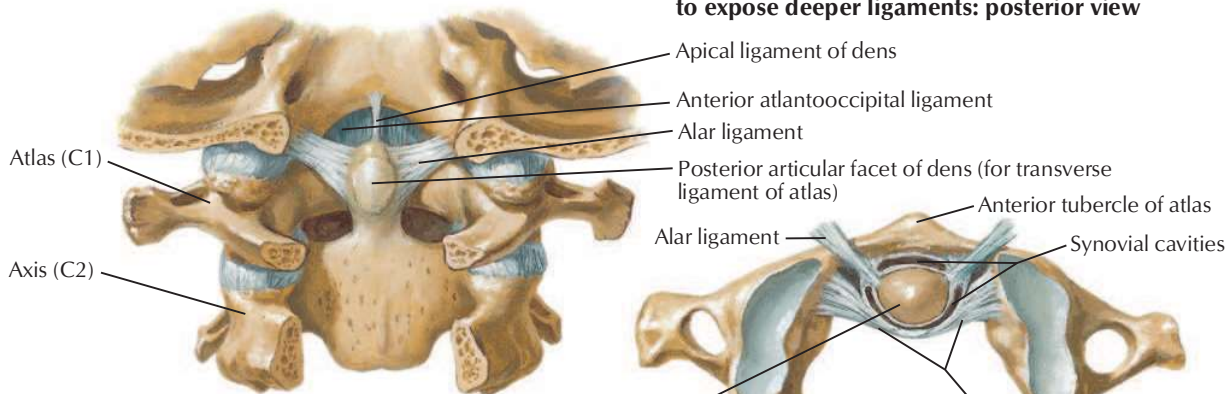
The uncovertebral joints of the cervical spine: anterior view (C3 to C7 have been sectioned coronally to expose the joints)

C. Machado M.D.

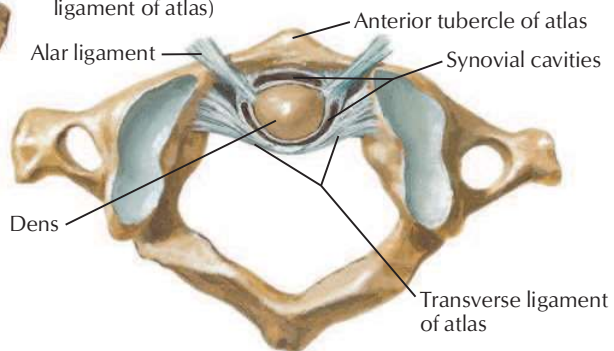




Principal part of tectorial membrane removed to expose deeper ligaments: posterior view



Cruciate ligament removed to show deeper ligaments: posterior view

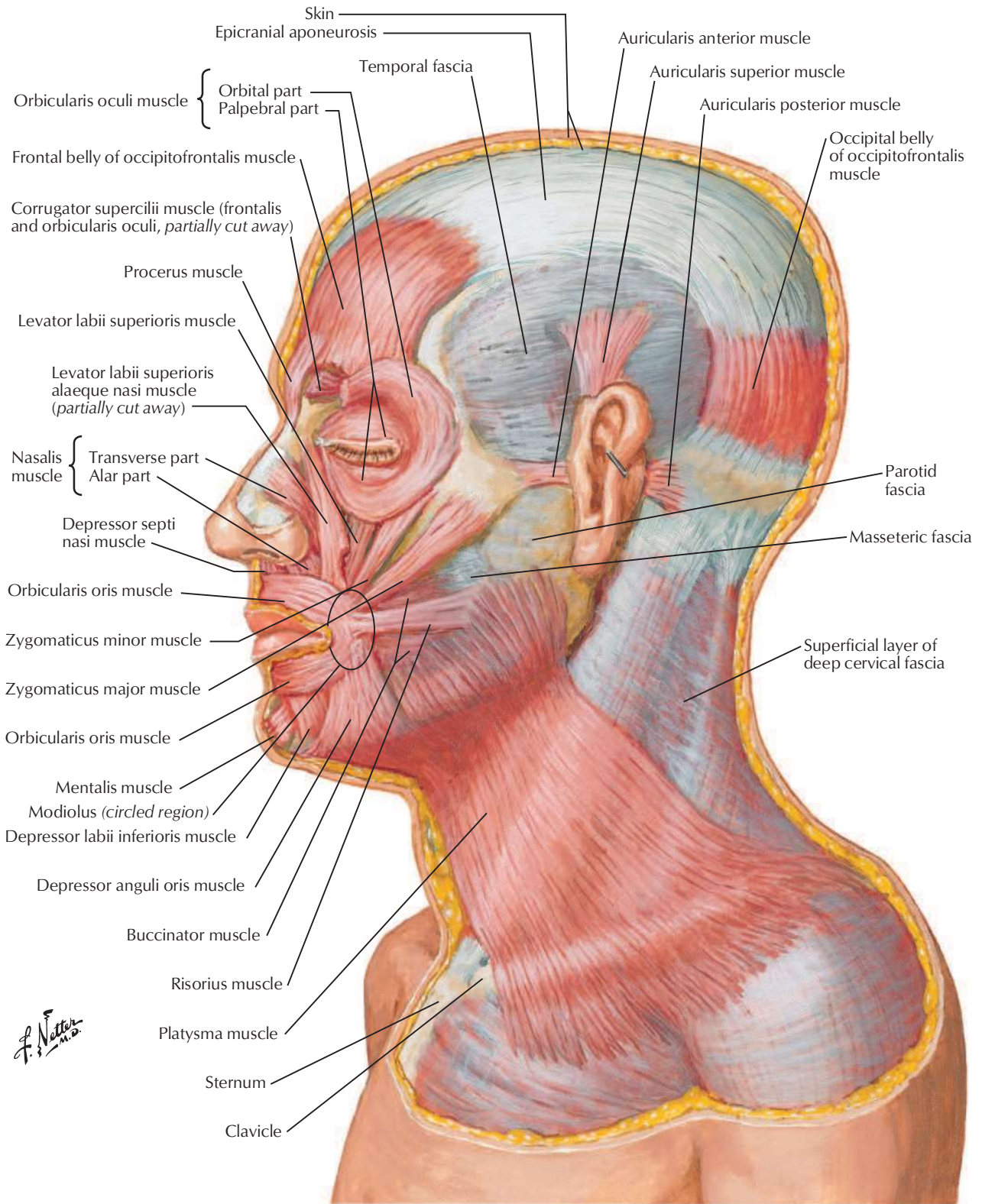


Median atlantoaxial joint: superior view

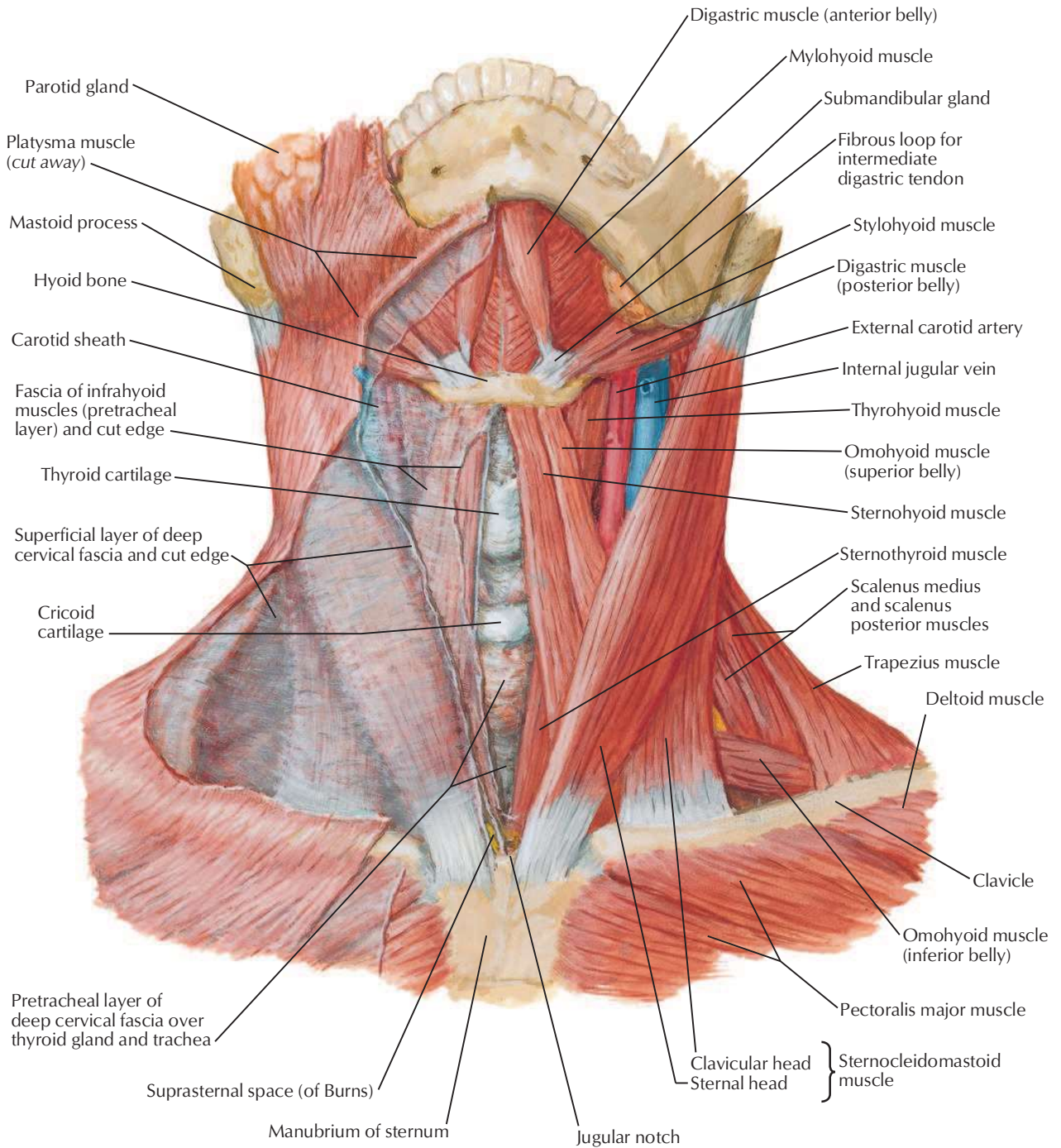
F. Netter M.D.

Muscles of Facial Expression: Lateral View

See also [Plates 34, 55, 56](#)

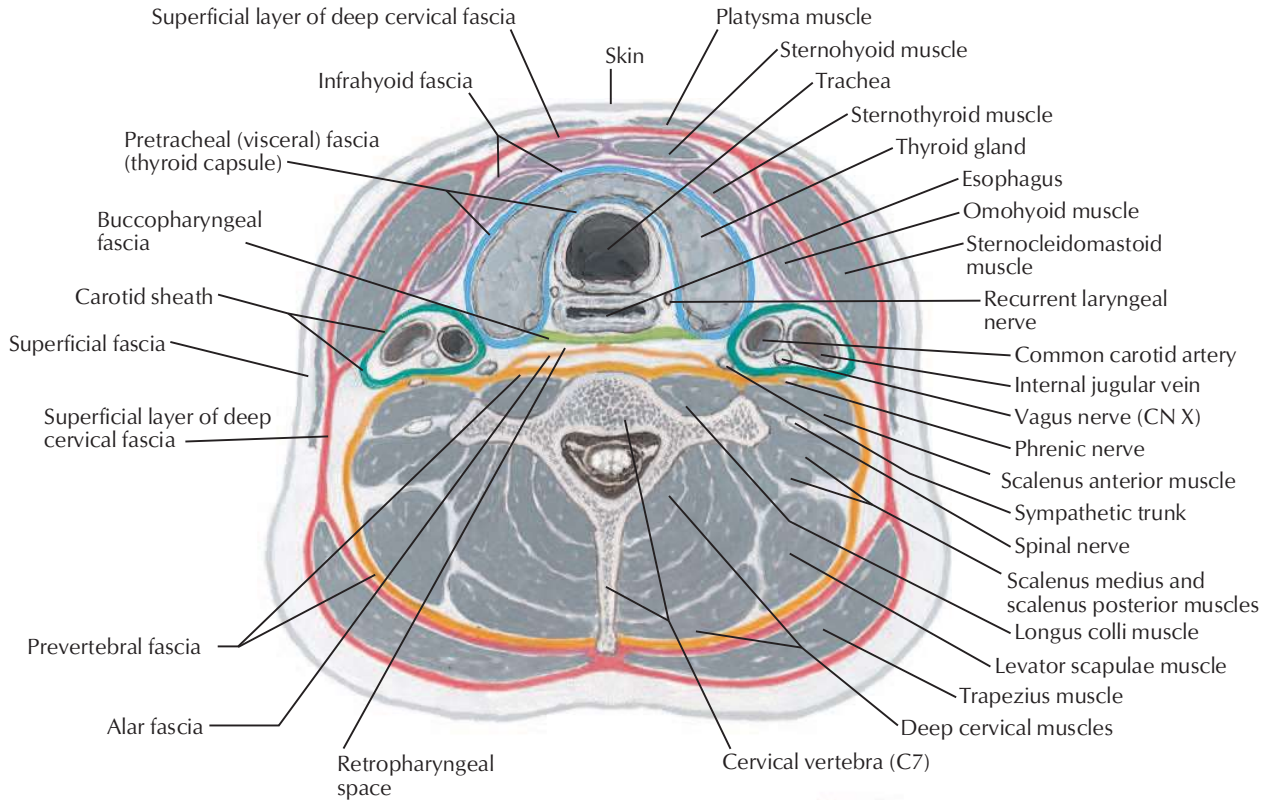


See also Plates 33, 35, 38

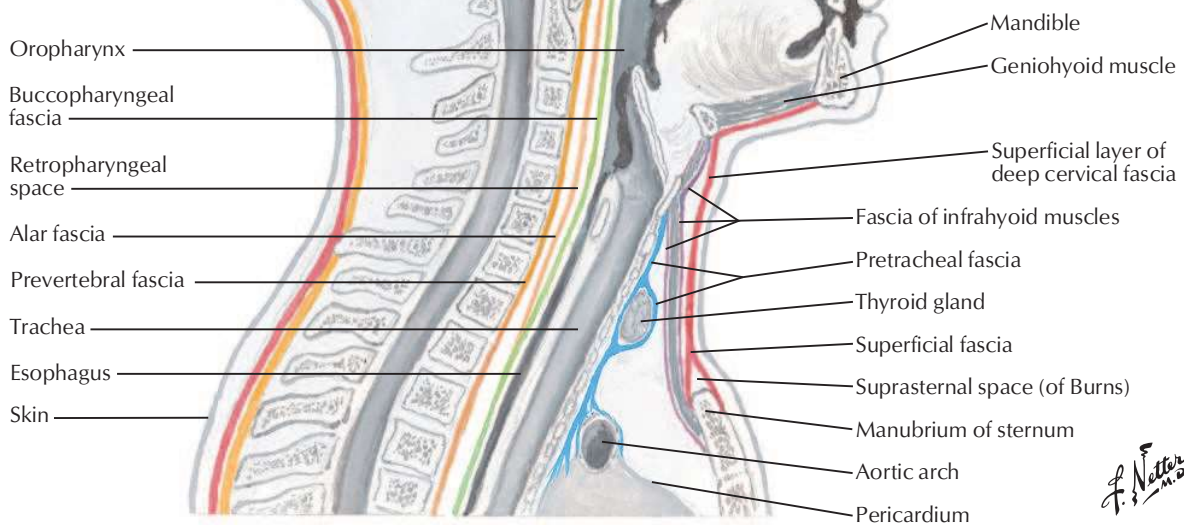

F. Netter M.D.

Cross section

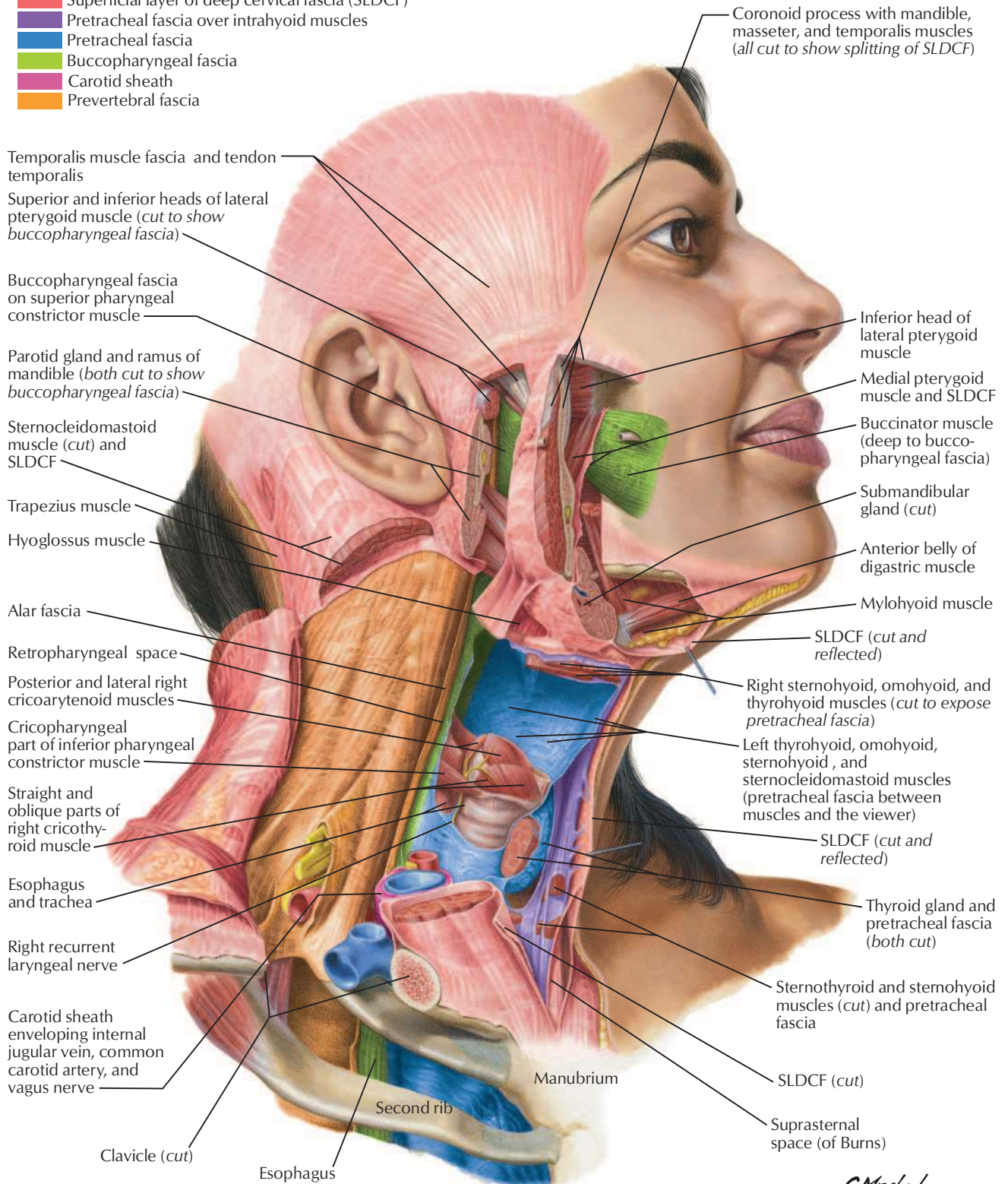


Midsagittal section



See also Plates 32, 33, 38

- Superficial layer of deep cervical fascia (SLDCF)
- Pretracheal fascia over intrathyroid muscles
- Pretracheal fascia
- Buccopharyngeal fascia
- Carotid sheath
- Prevertebral fascia

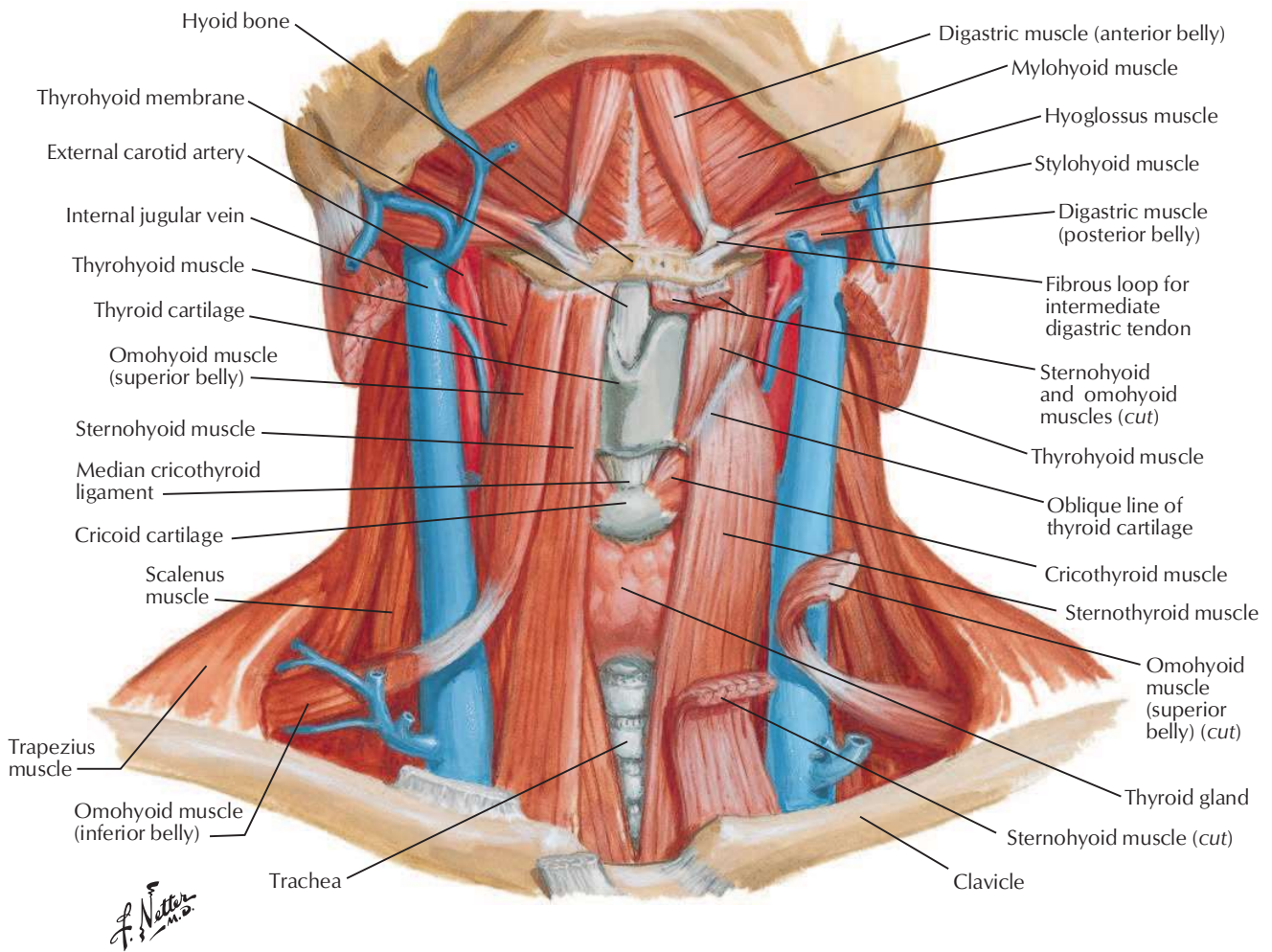


C. Machado M.D.

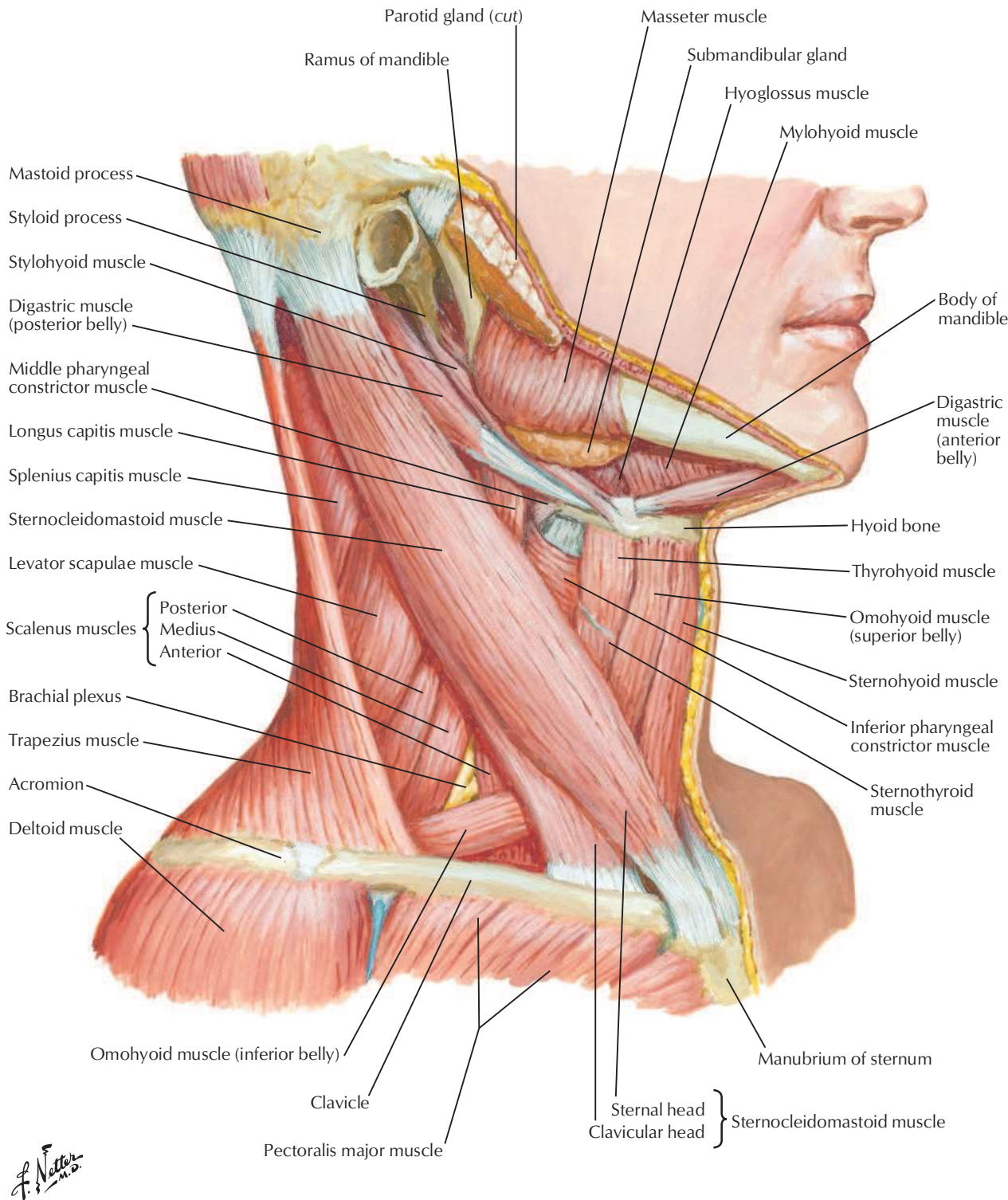
SLDCF: Superficial layer of deep cervical fascia

Infrahyoid and Suprahyoid Muscles

See also [Plates 32, 36, 69](#)

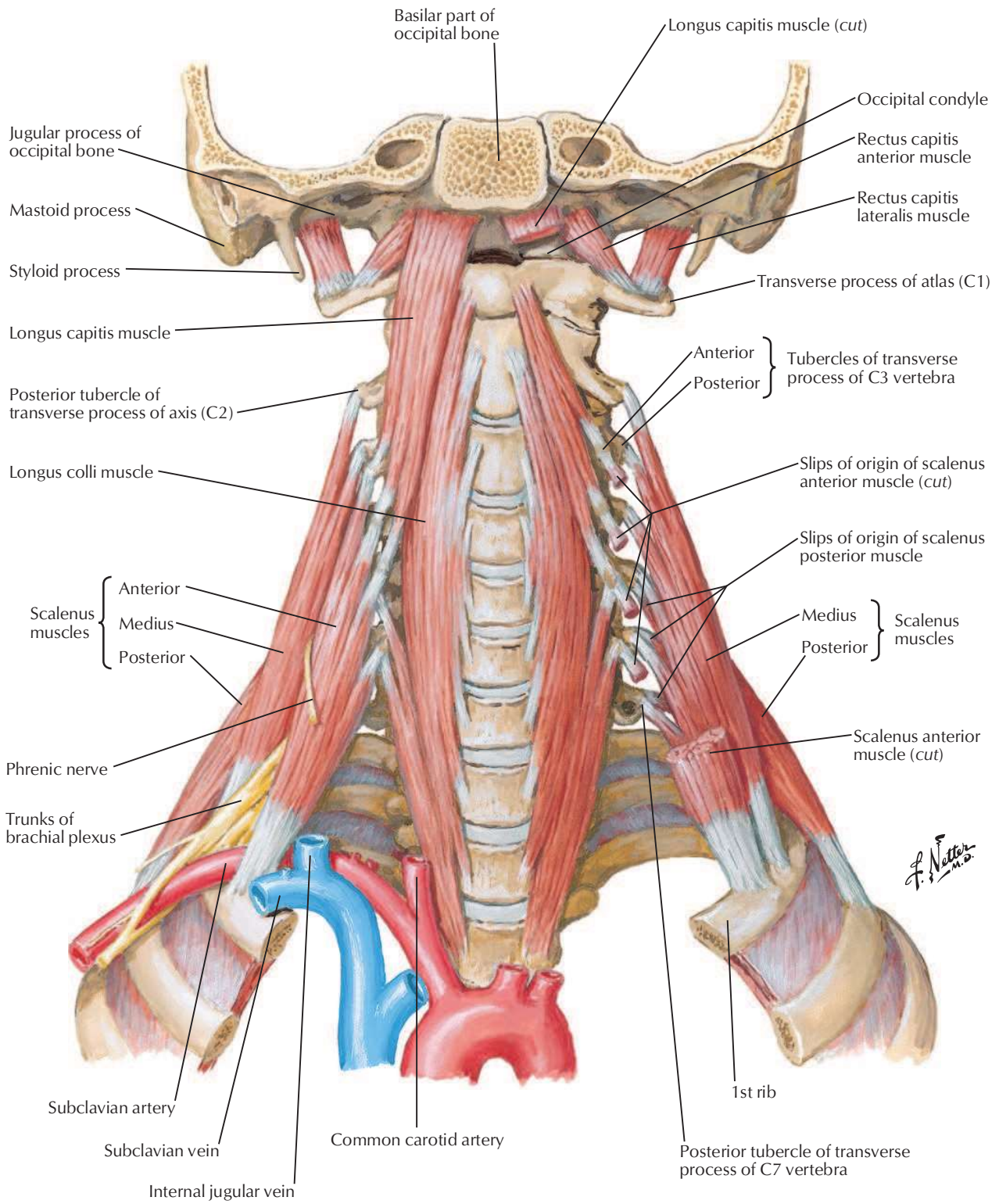


See also Plates 32, 35, 38

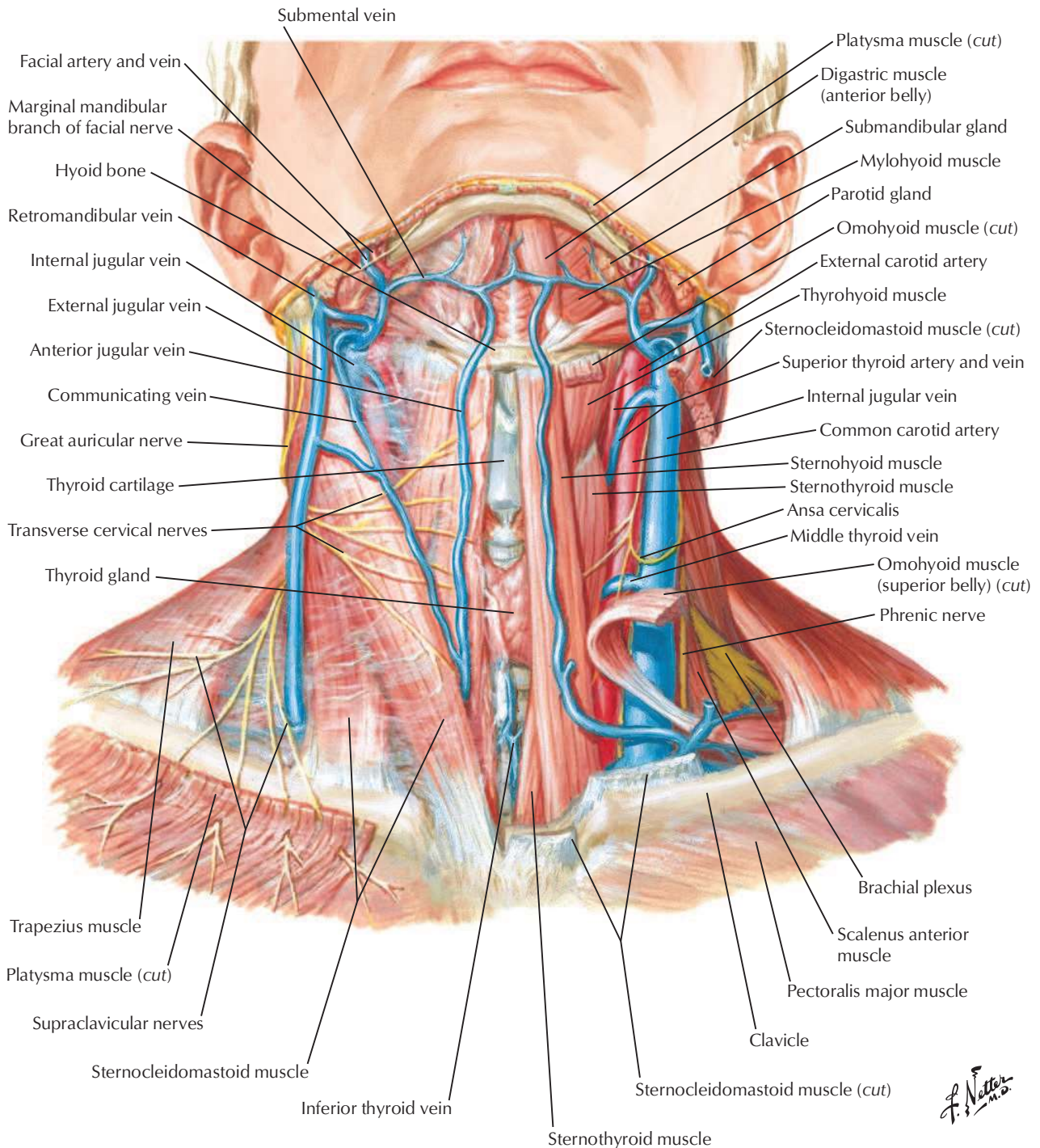


F. Netter M.D.

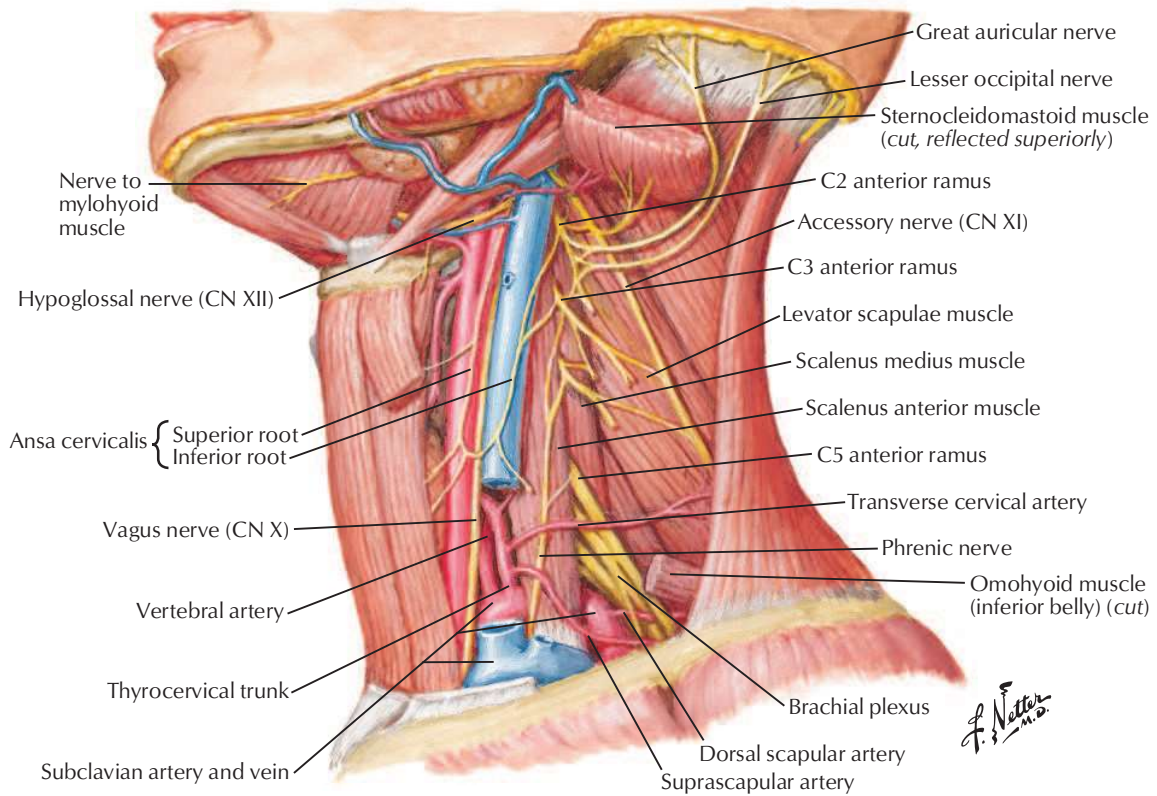
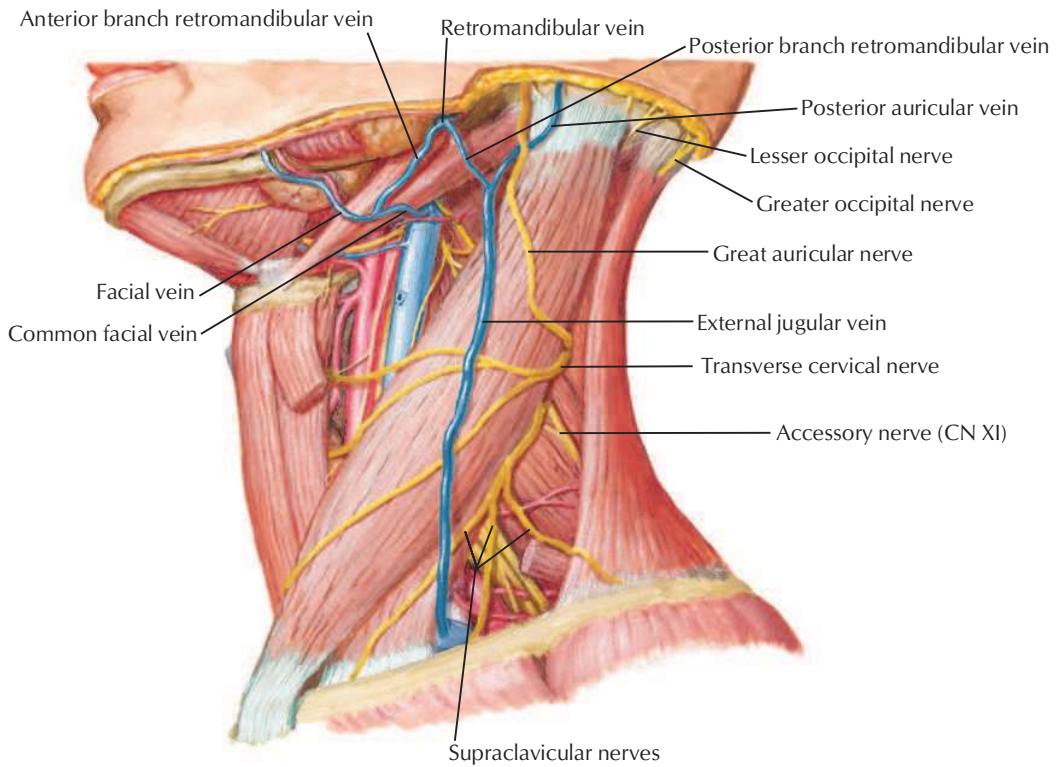
Anterior and Lateral Cervical Muscles



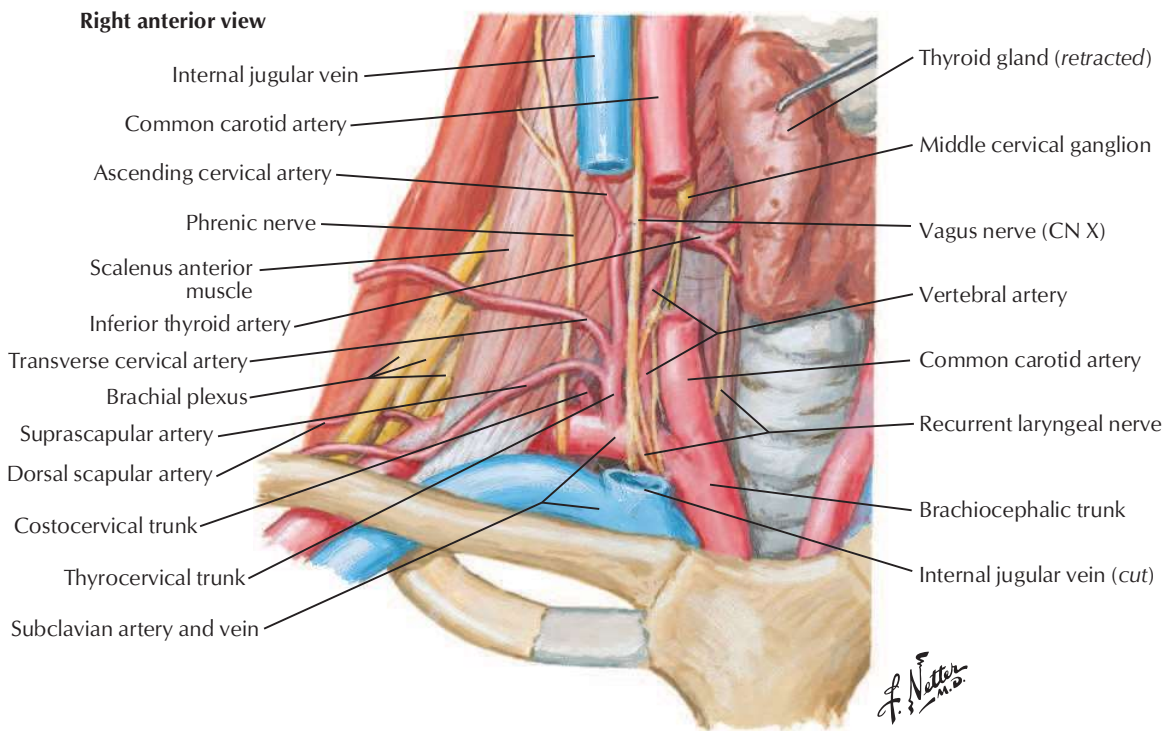
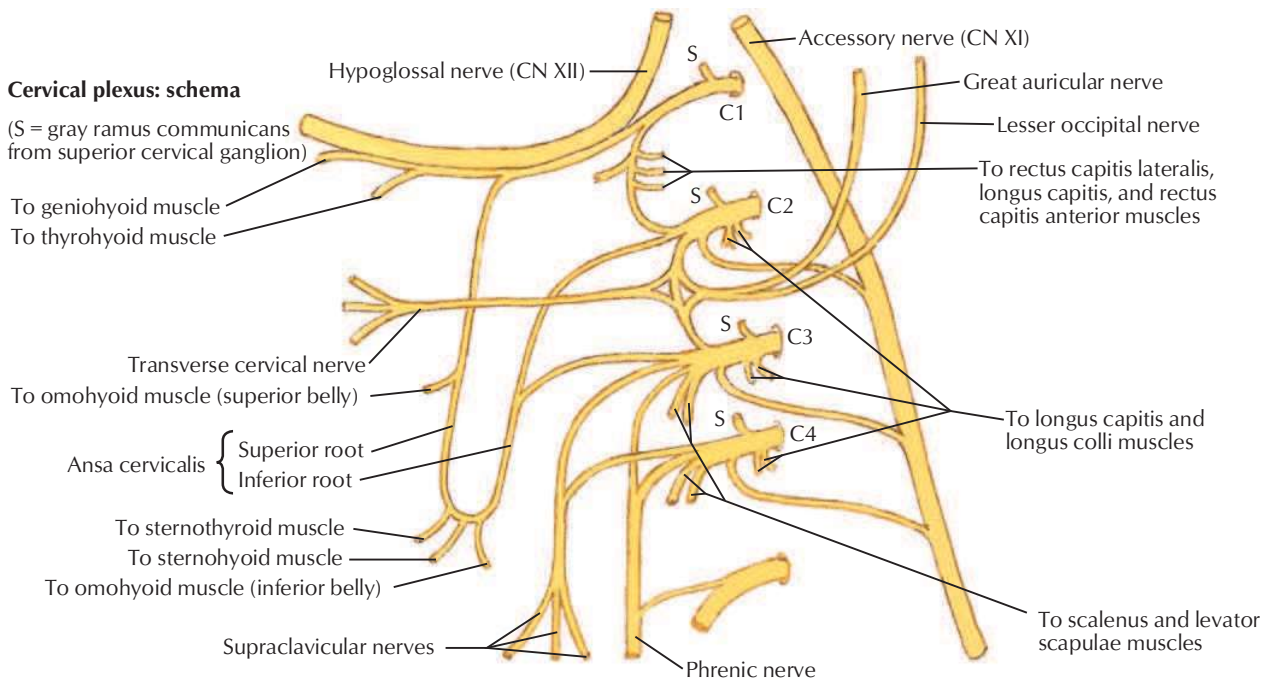
For deep veins of neck see [Plate 84](#)



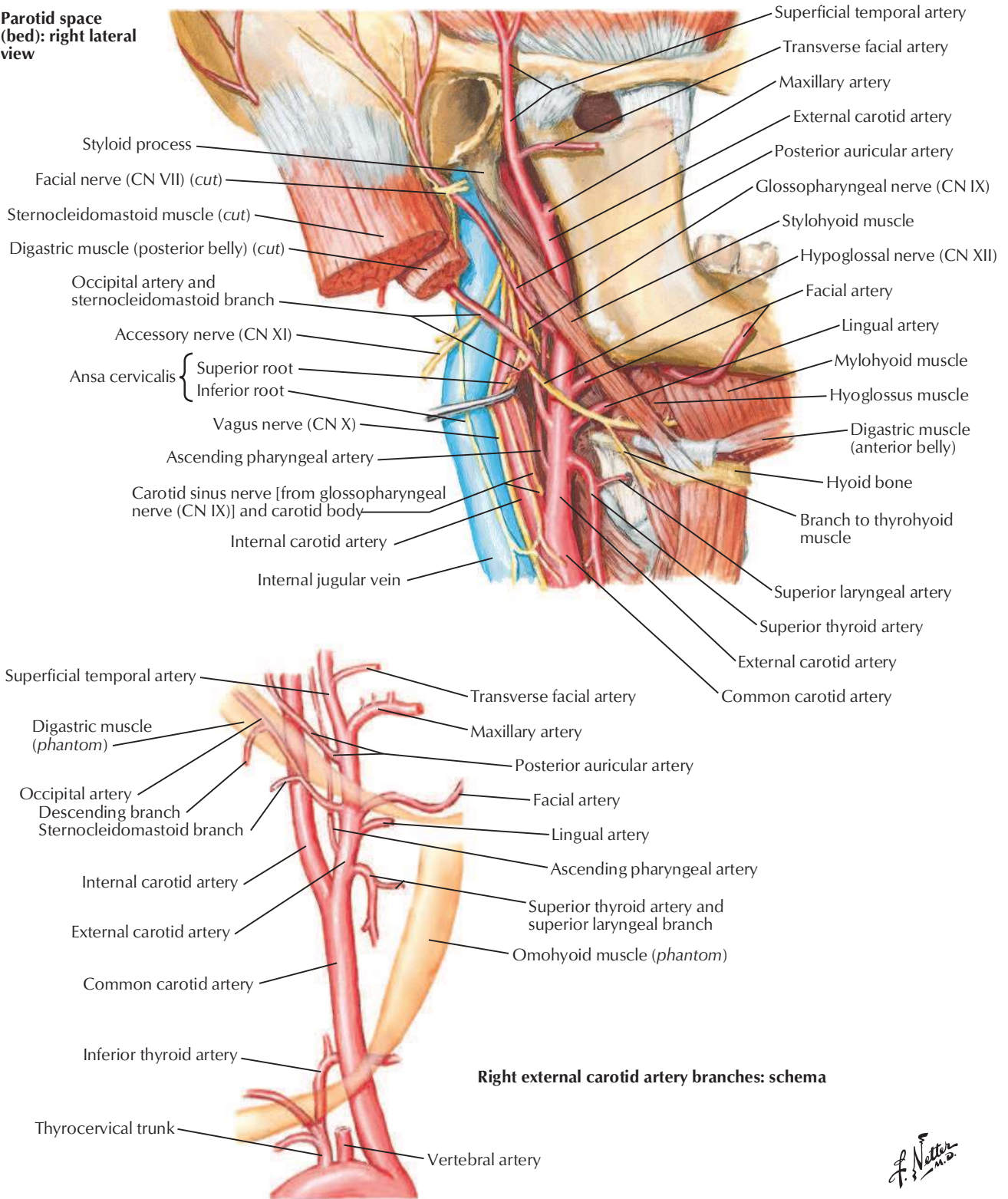
F. Netter M.D.



See also [Plate 140](#)

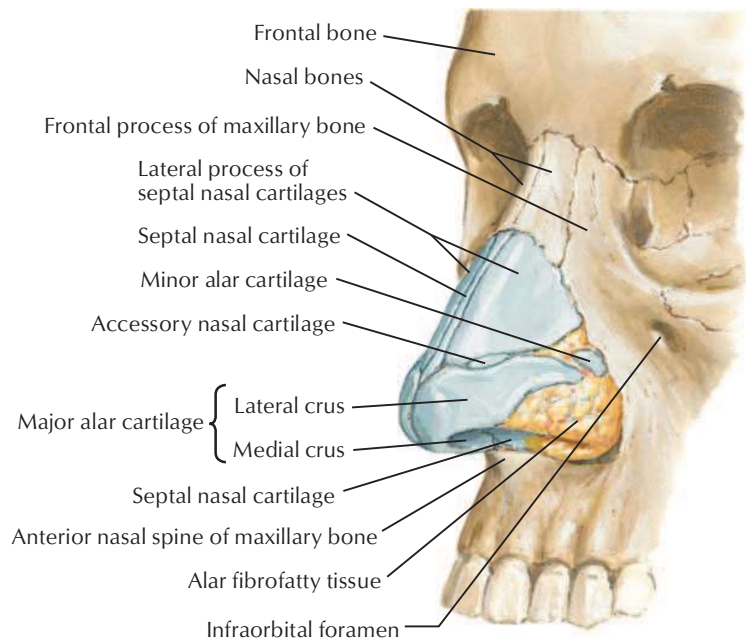


Parotid space (bed): right lateral view

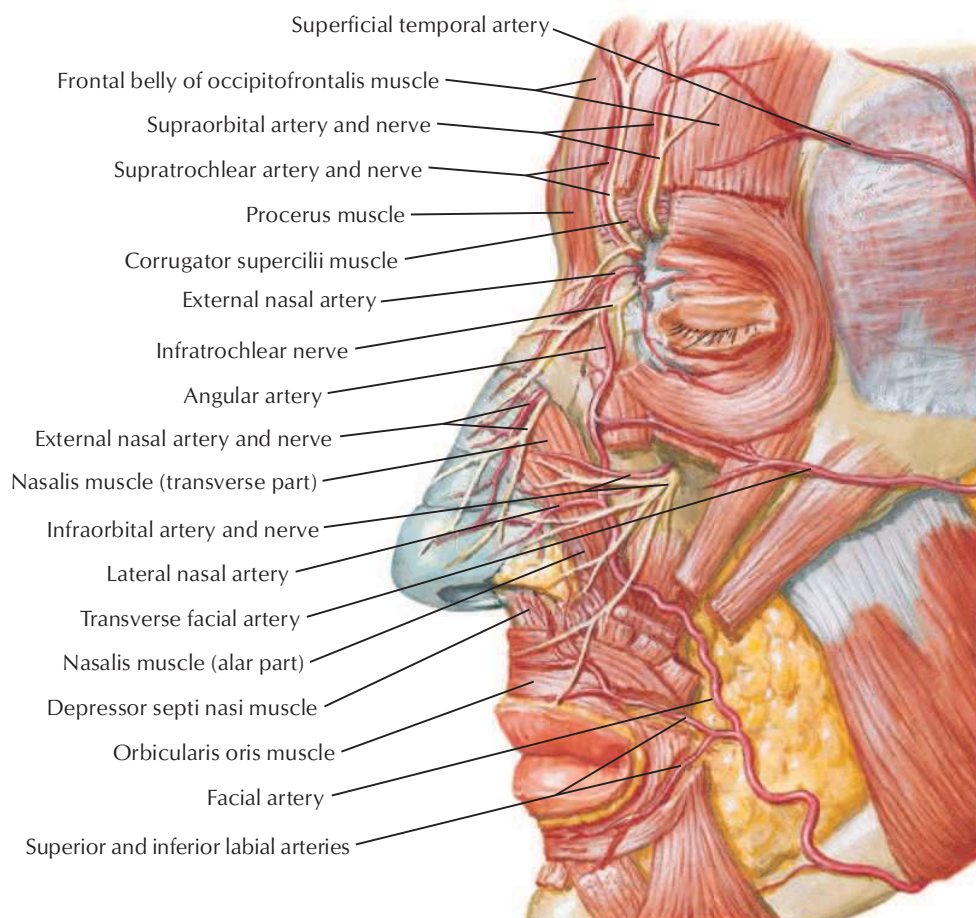
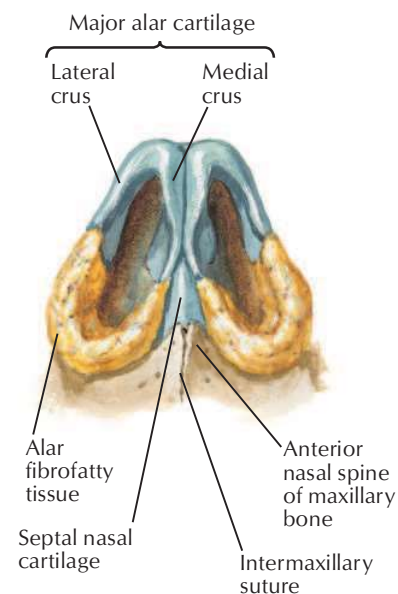


Right external carotid artery branches: schema

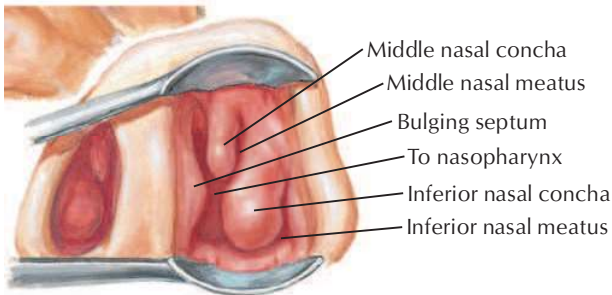
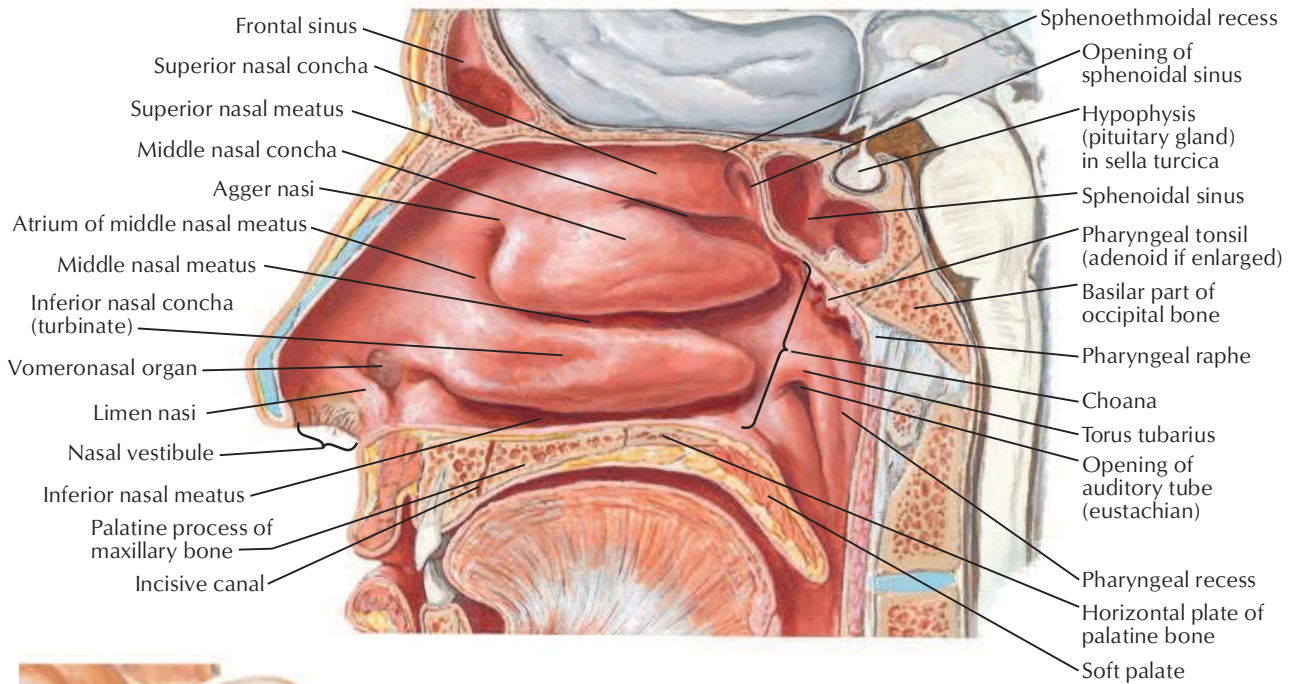
Anterolateral view



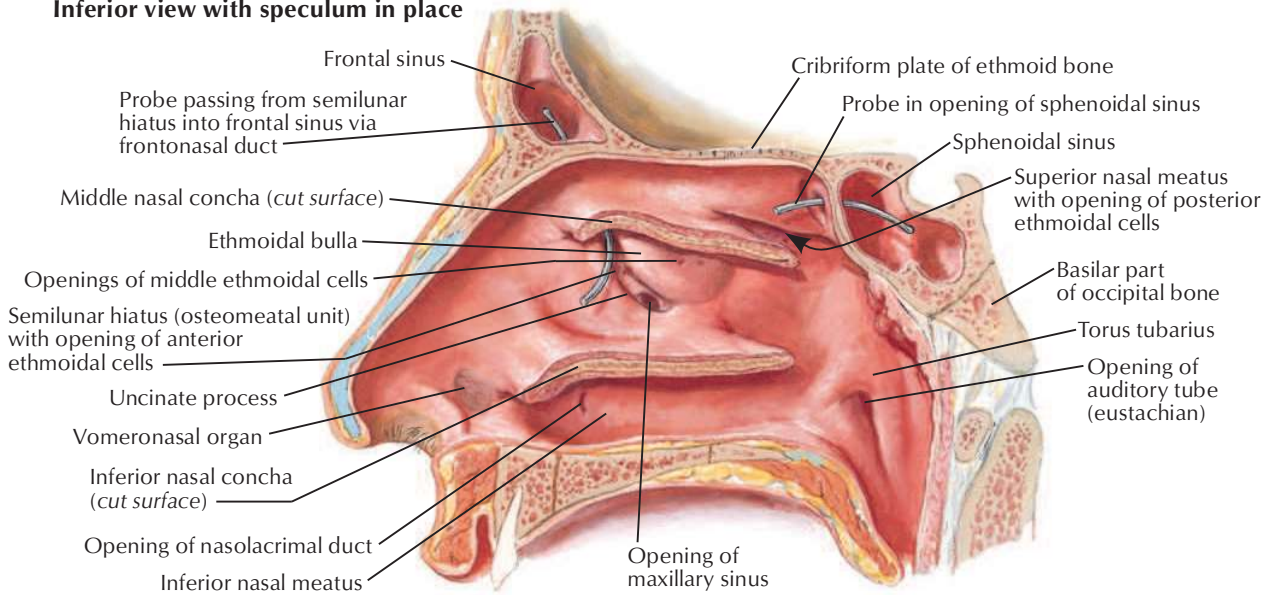
Inferior view

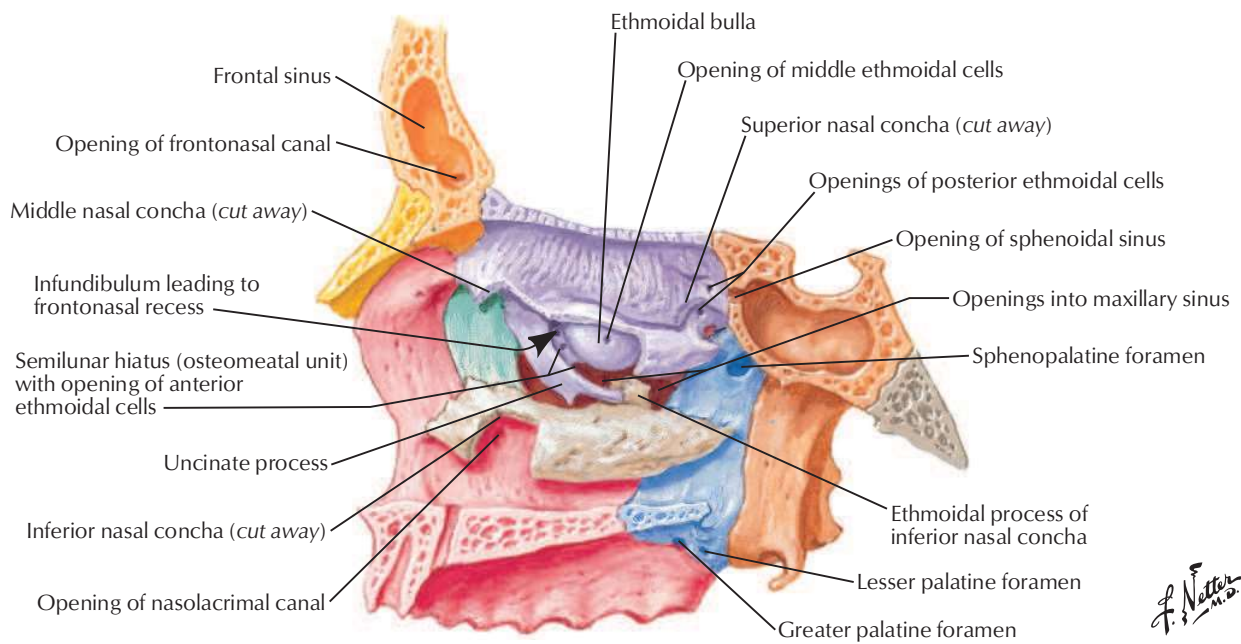
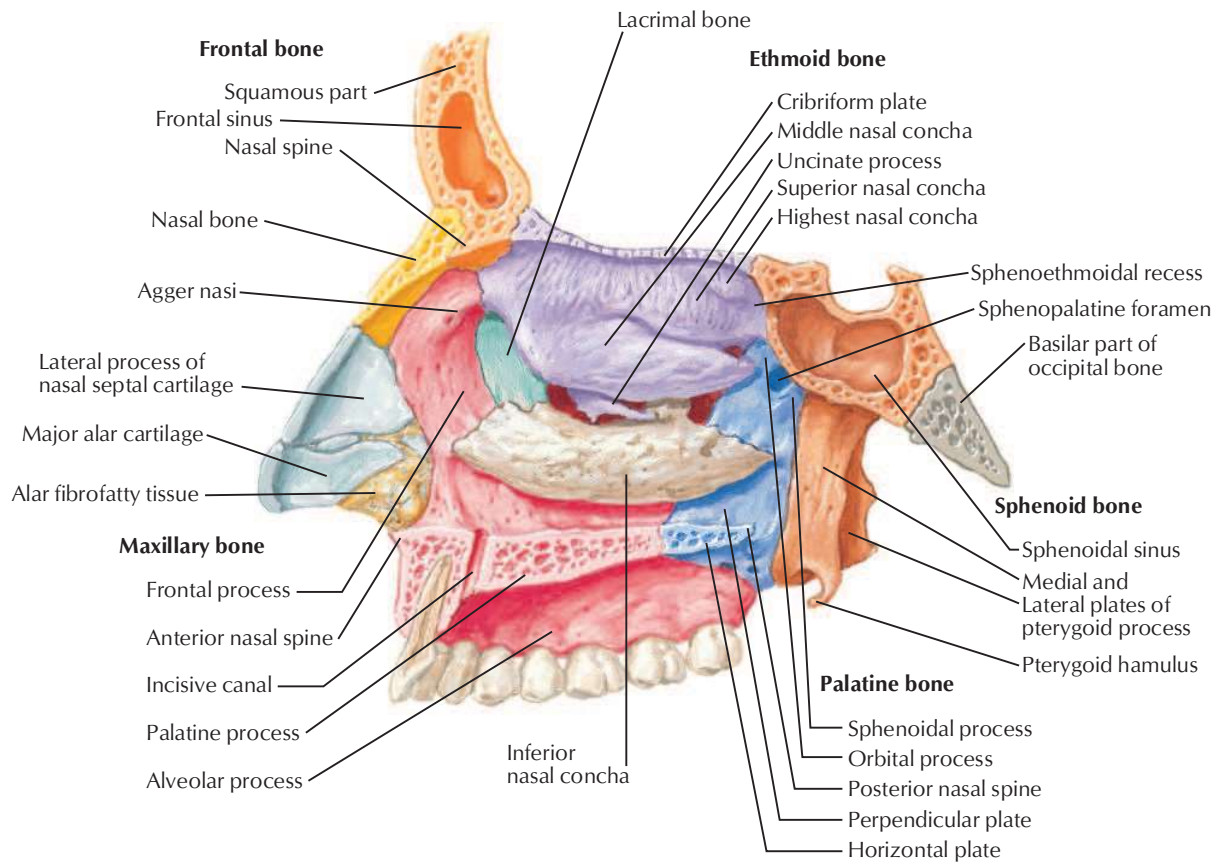


F. Netter M.D.



Inferior view with speculum in place

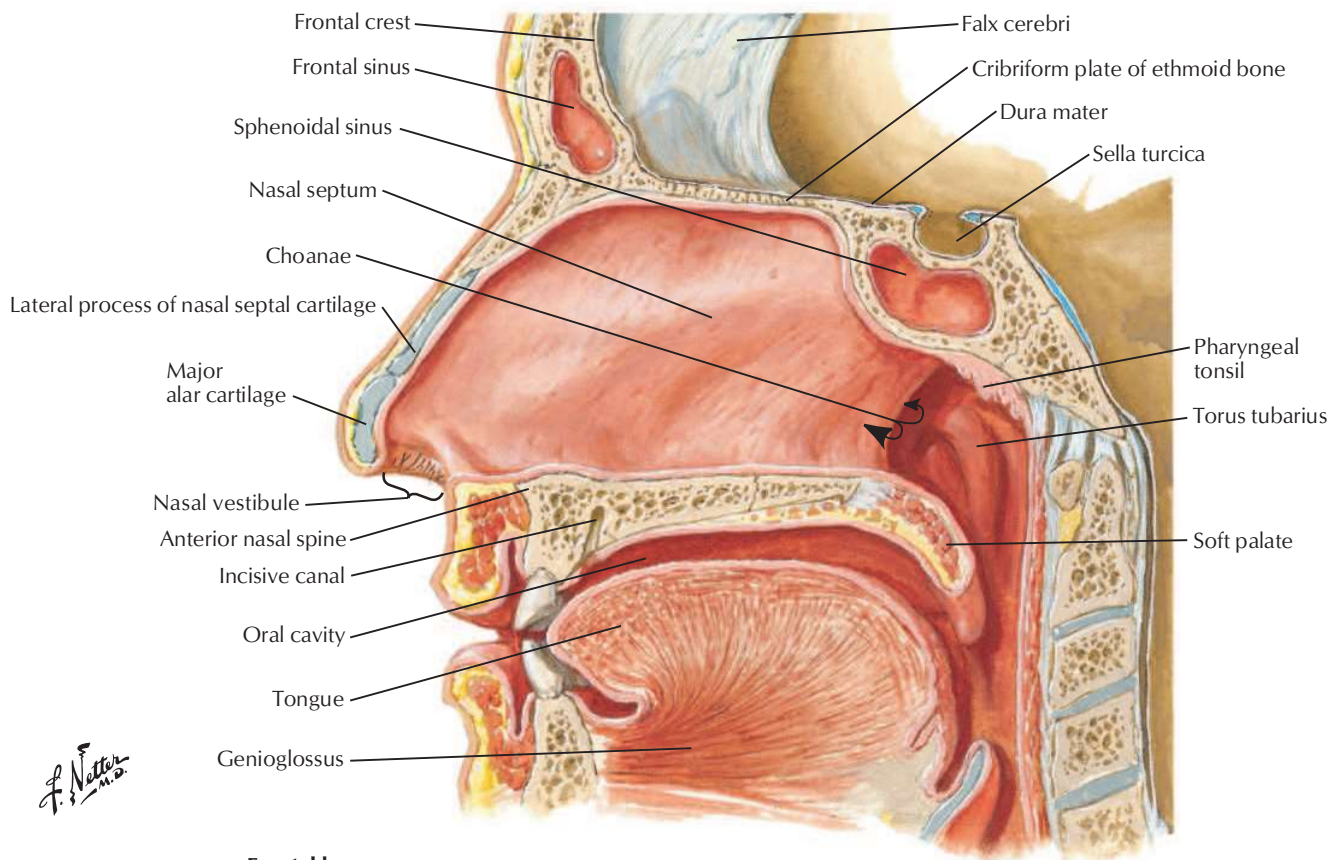
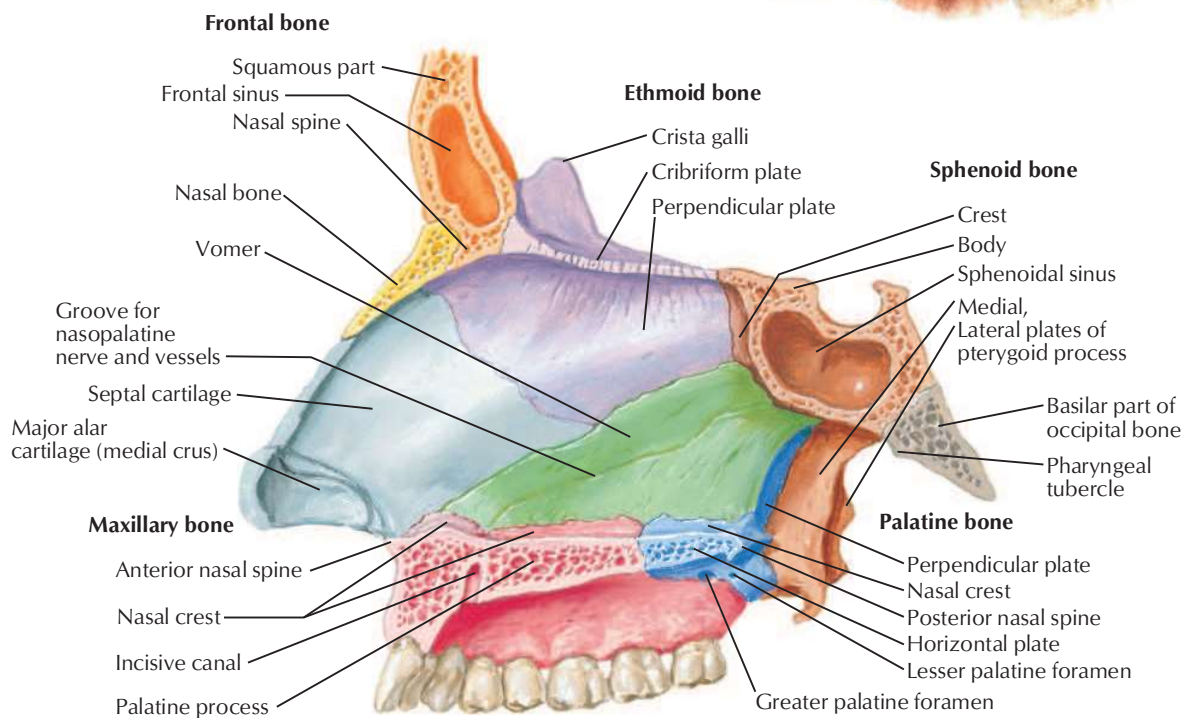




F. Netter M.D.

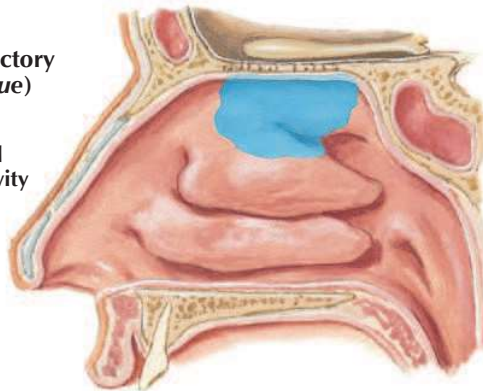
Medial Wall of Nasal Cavity (Nasal Septum)

See also [Plate 15](#)

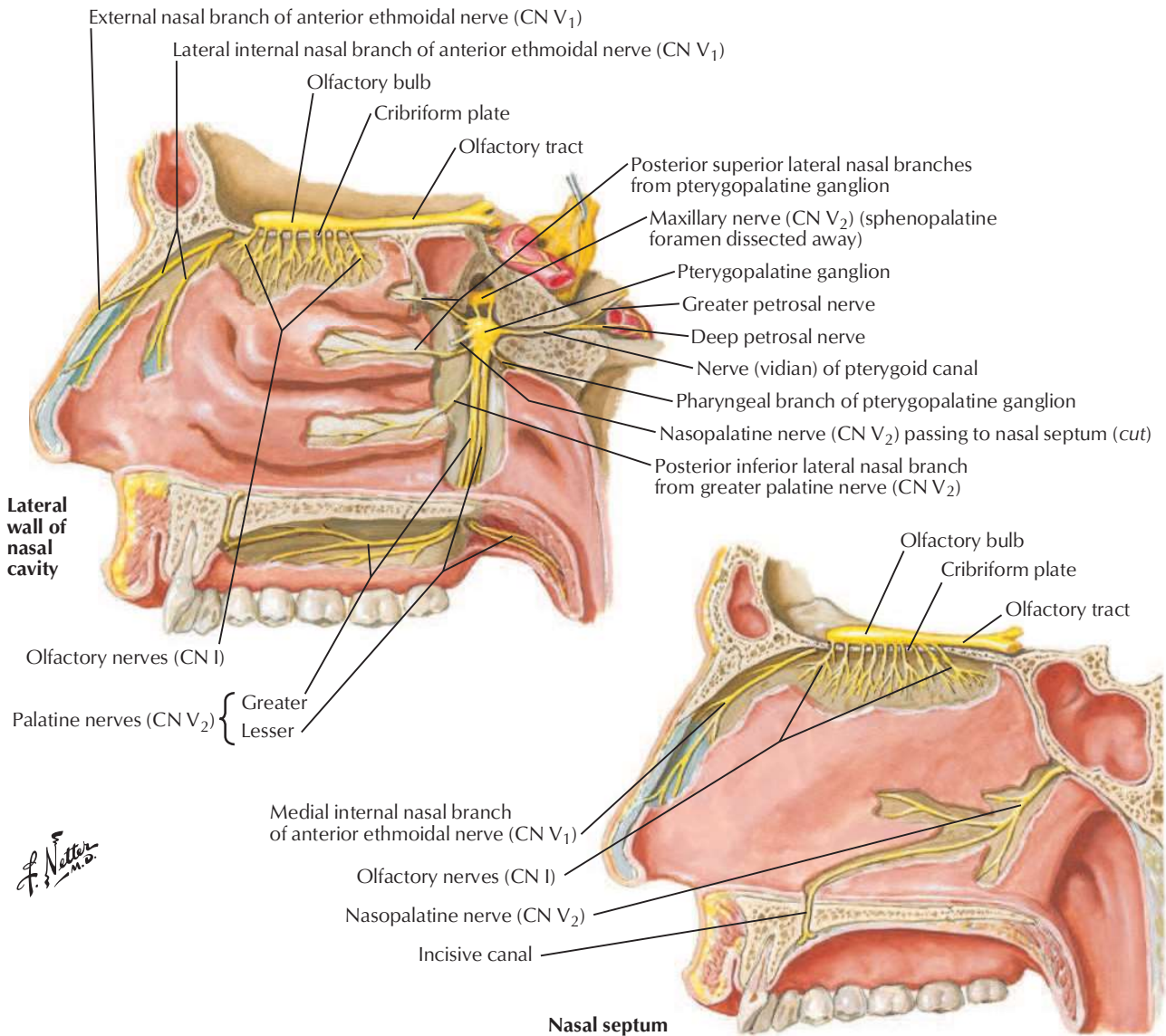
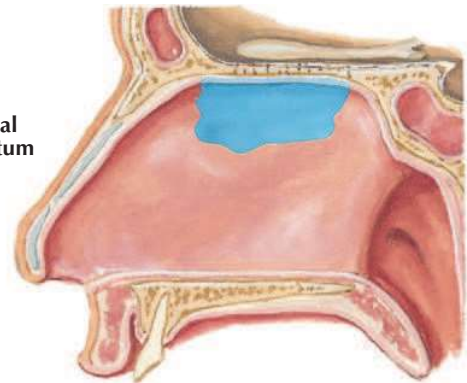



Distribution of olfactory mucosa (shaded blue)

Lateral wall of nasal cavity



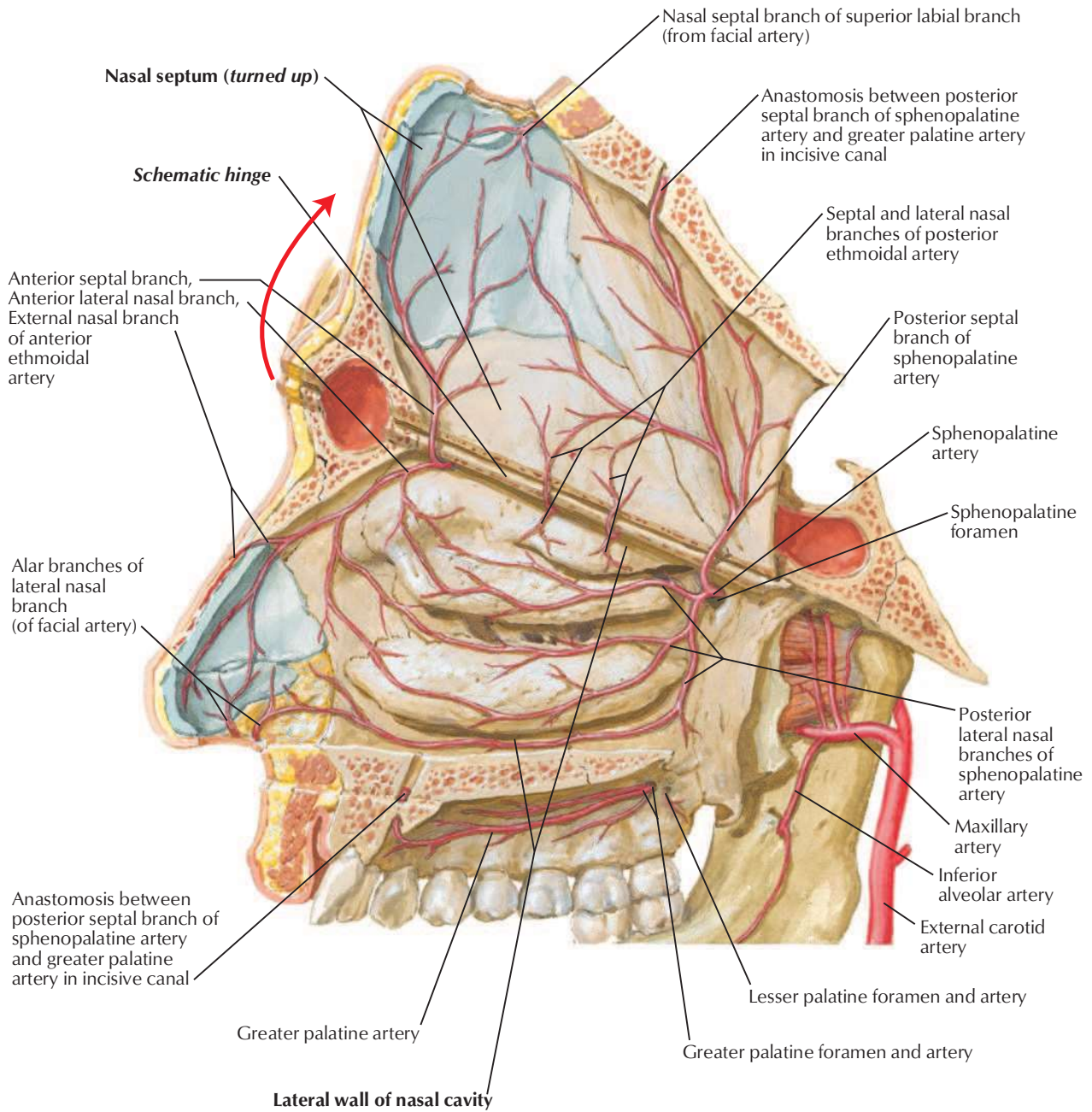
Nasal septum

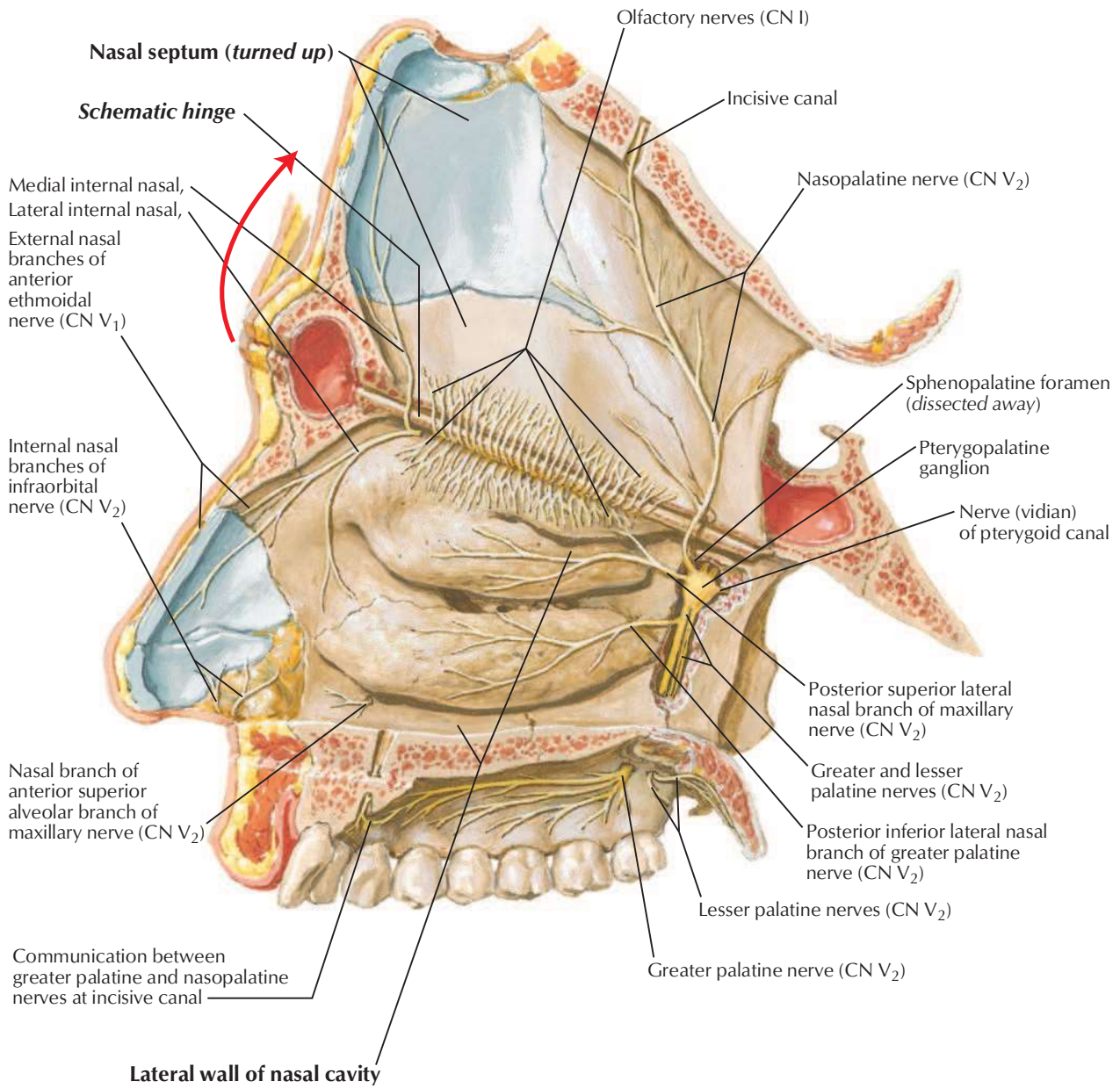


F. Netter M.D.

Arteries of Nasal Cavity: Bony Nasal Septum Turned Up

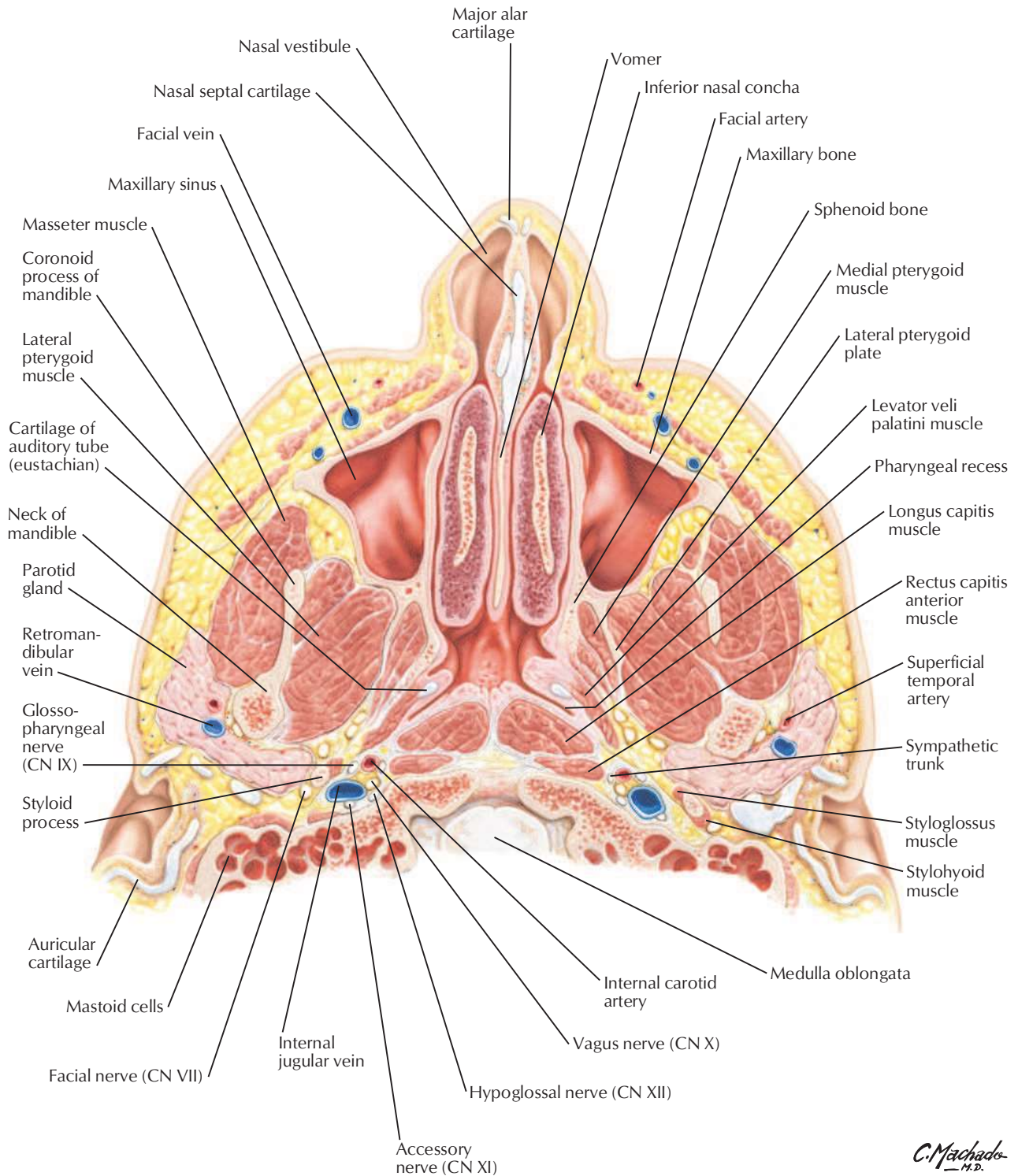
See also [Plates 57, 63](#)





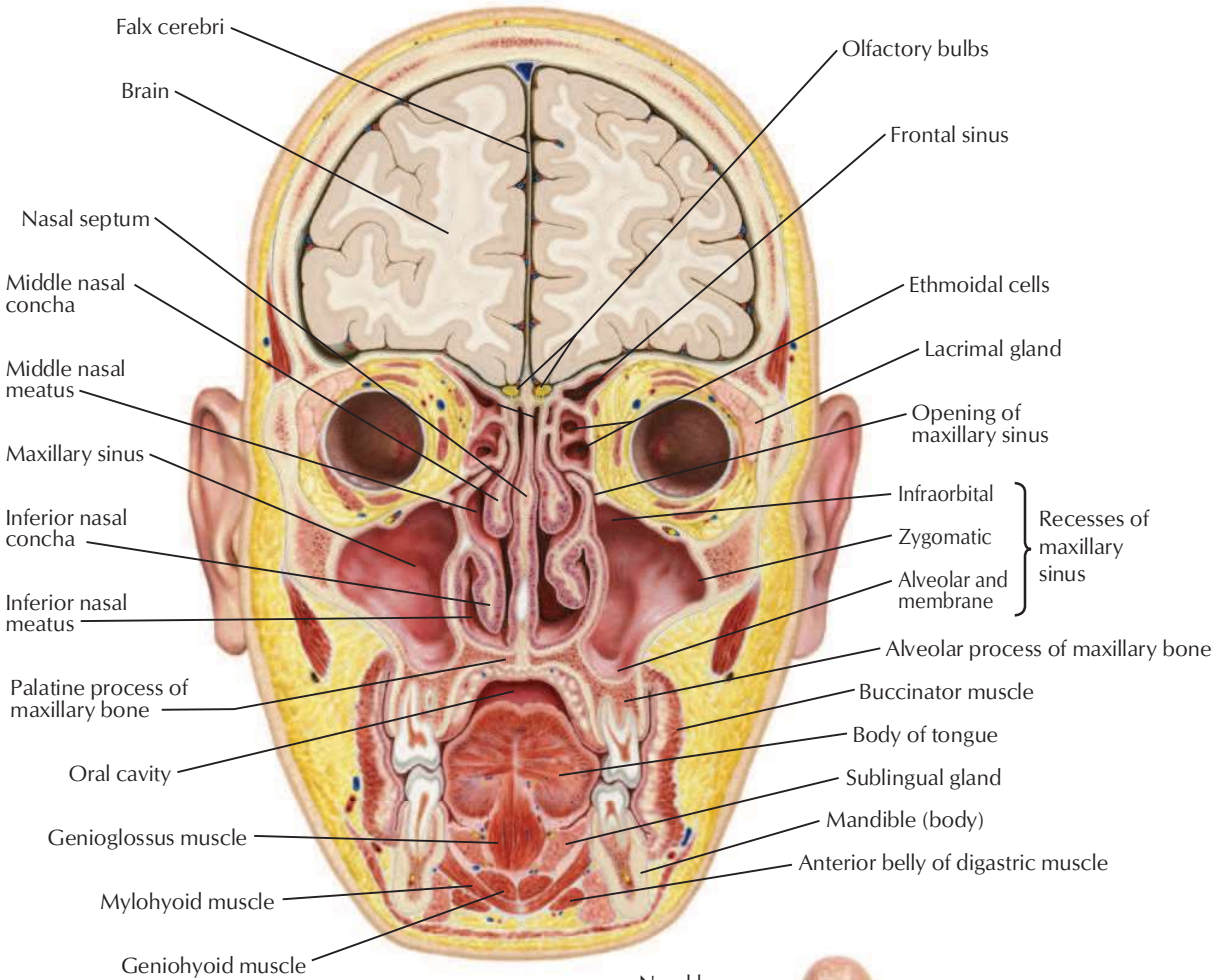
*F. Netter
M.D.*

Nose and Maxillary Sinus: Transverse Section

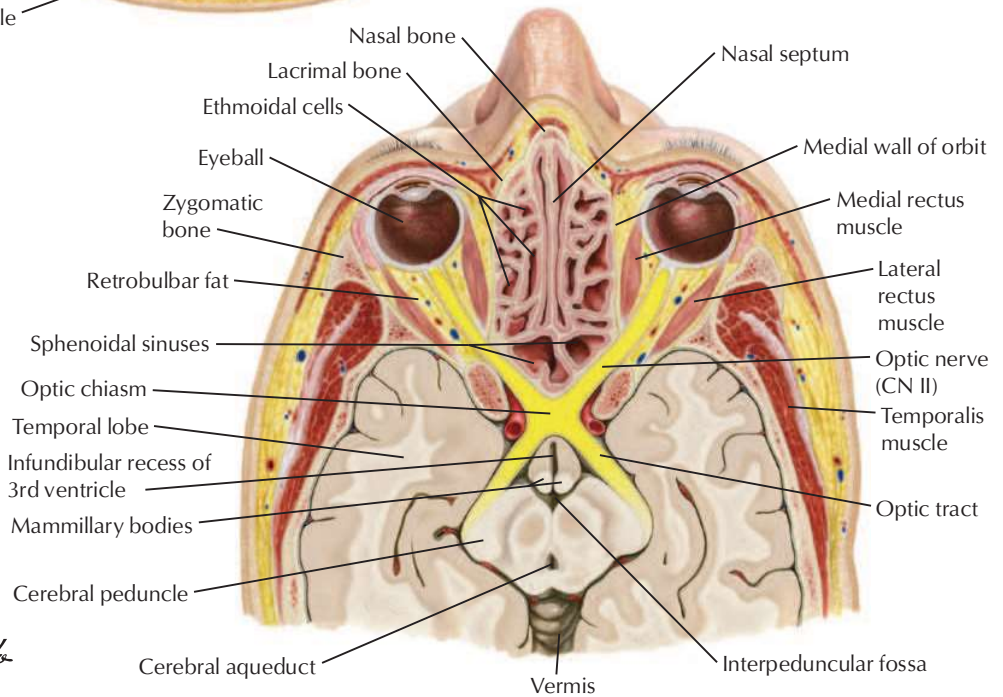


C. Machado
M.D.

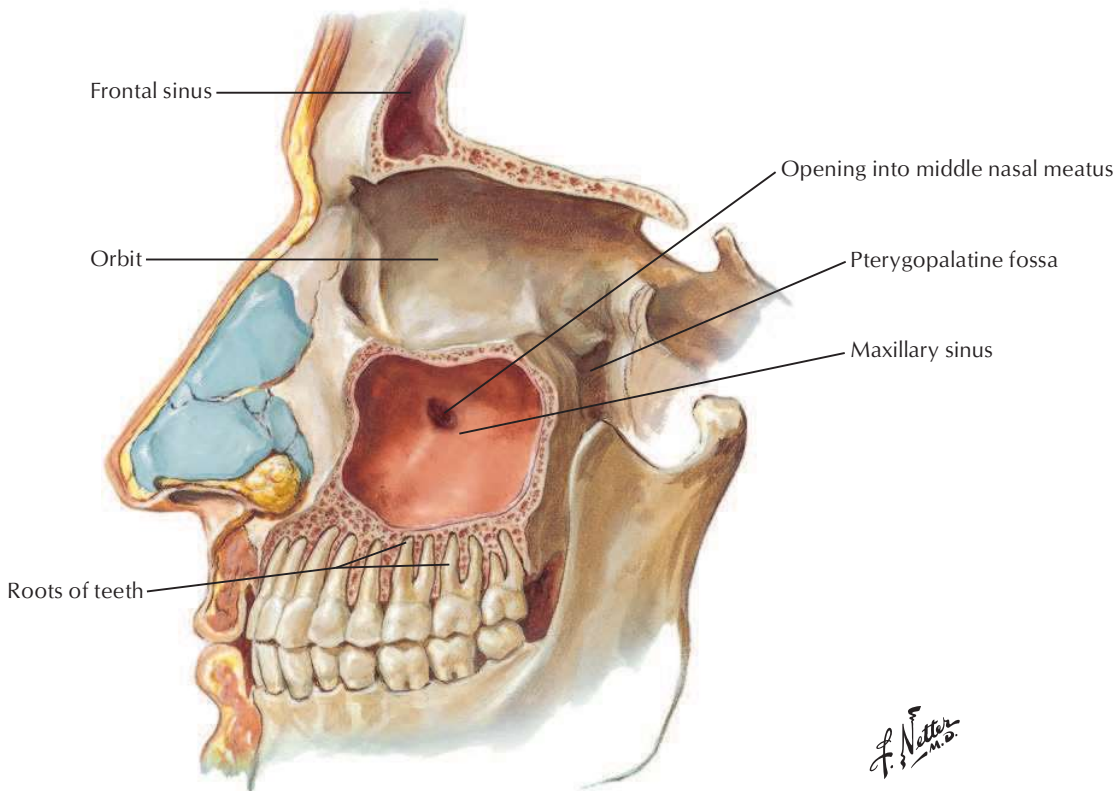
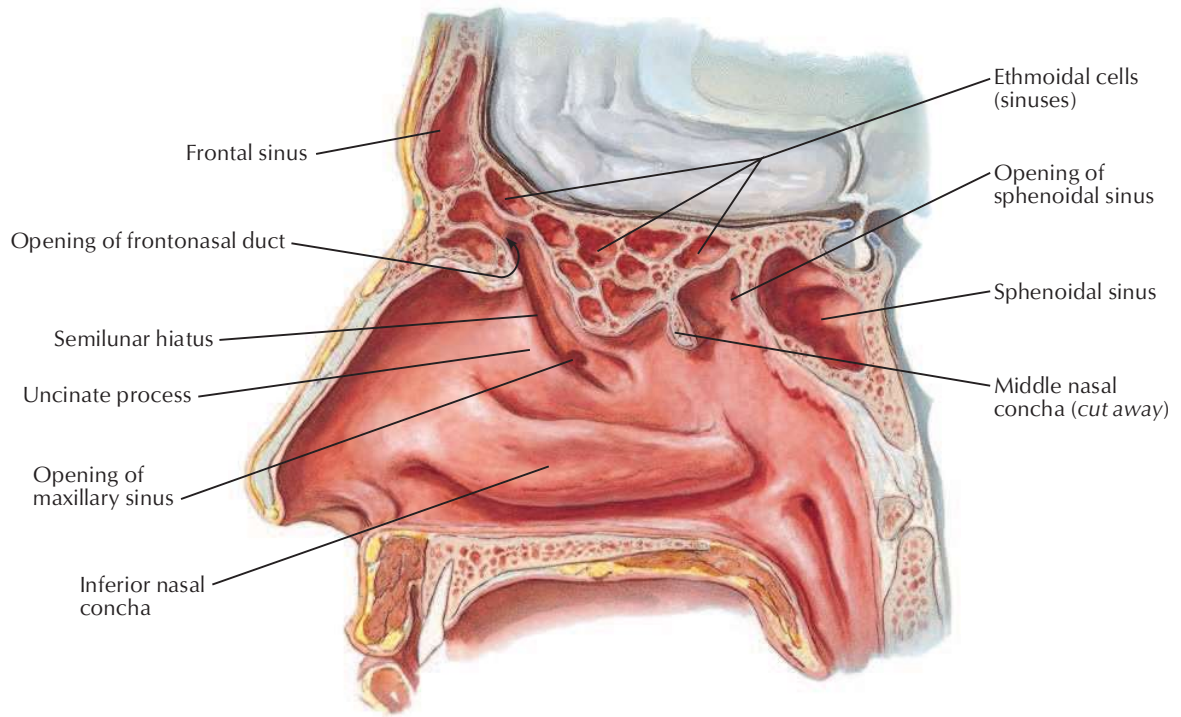
Coronal section



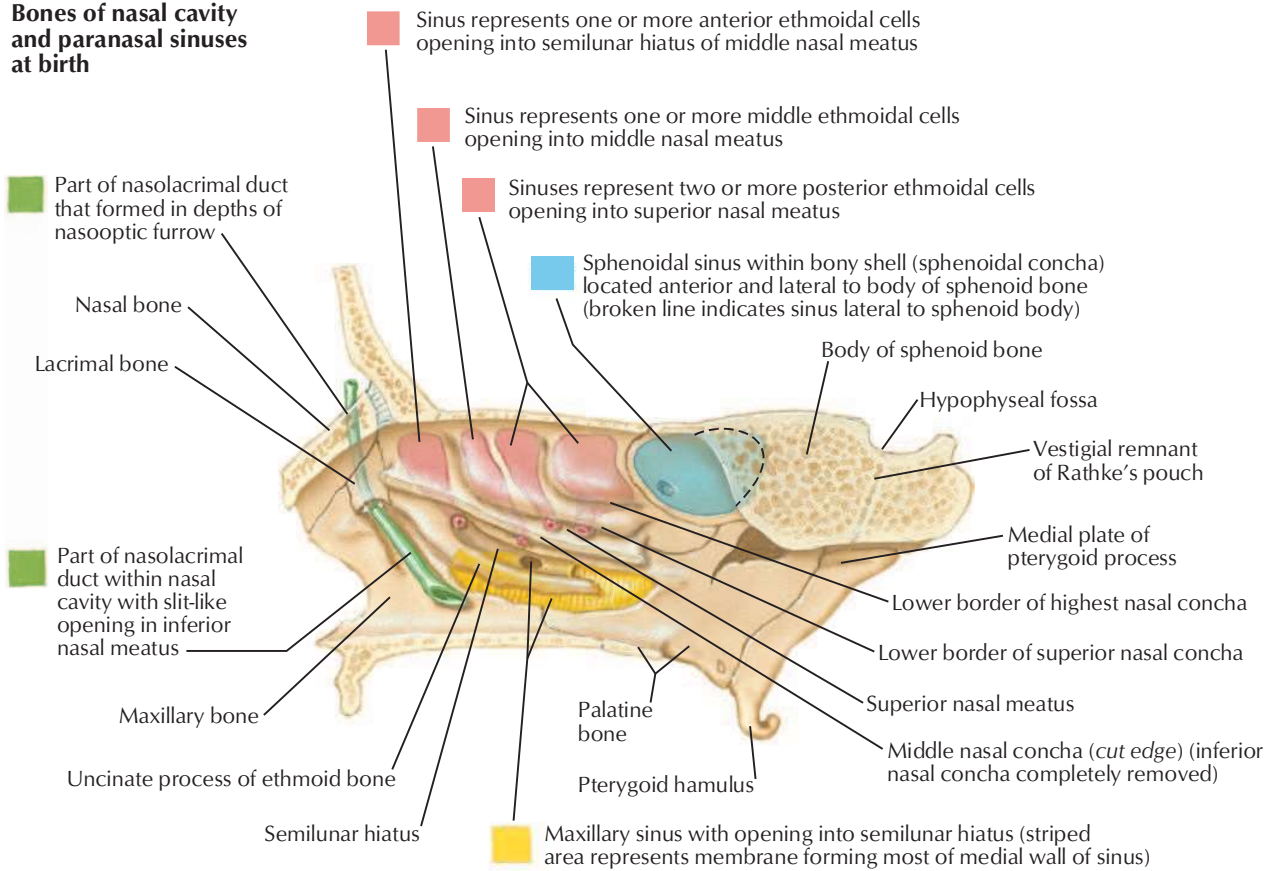
Transverse section



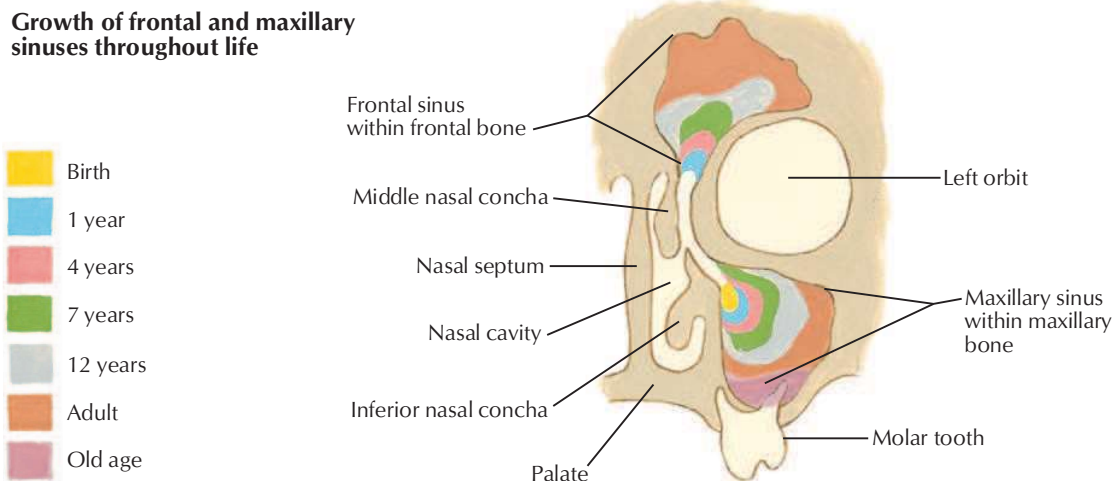
C. Machado
M.D.



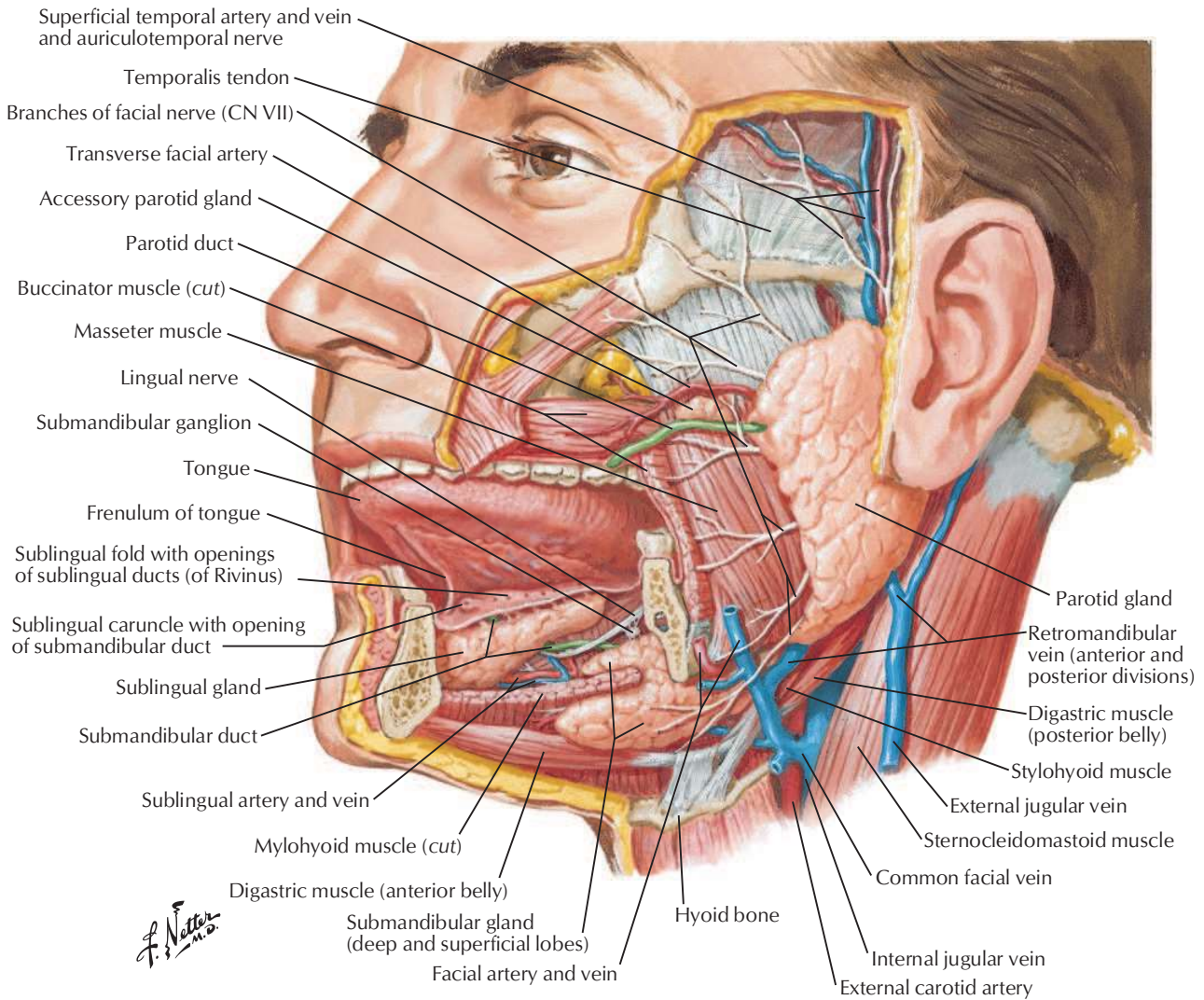
Bones of nasal cavity and paranasal sinuses at birth



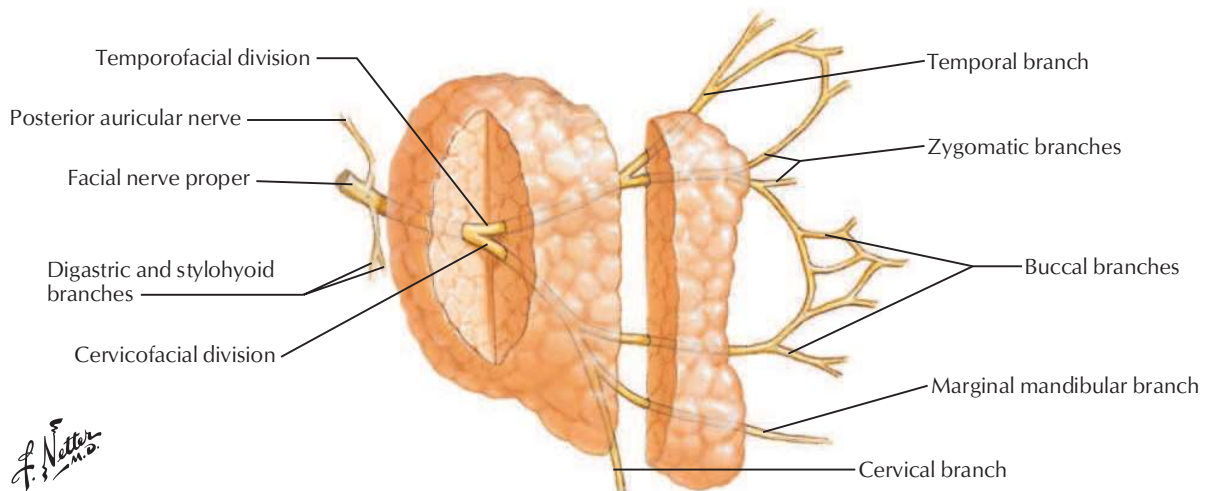
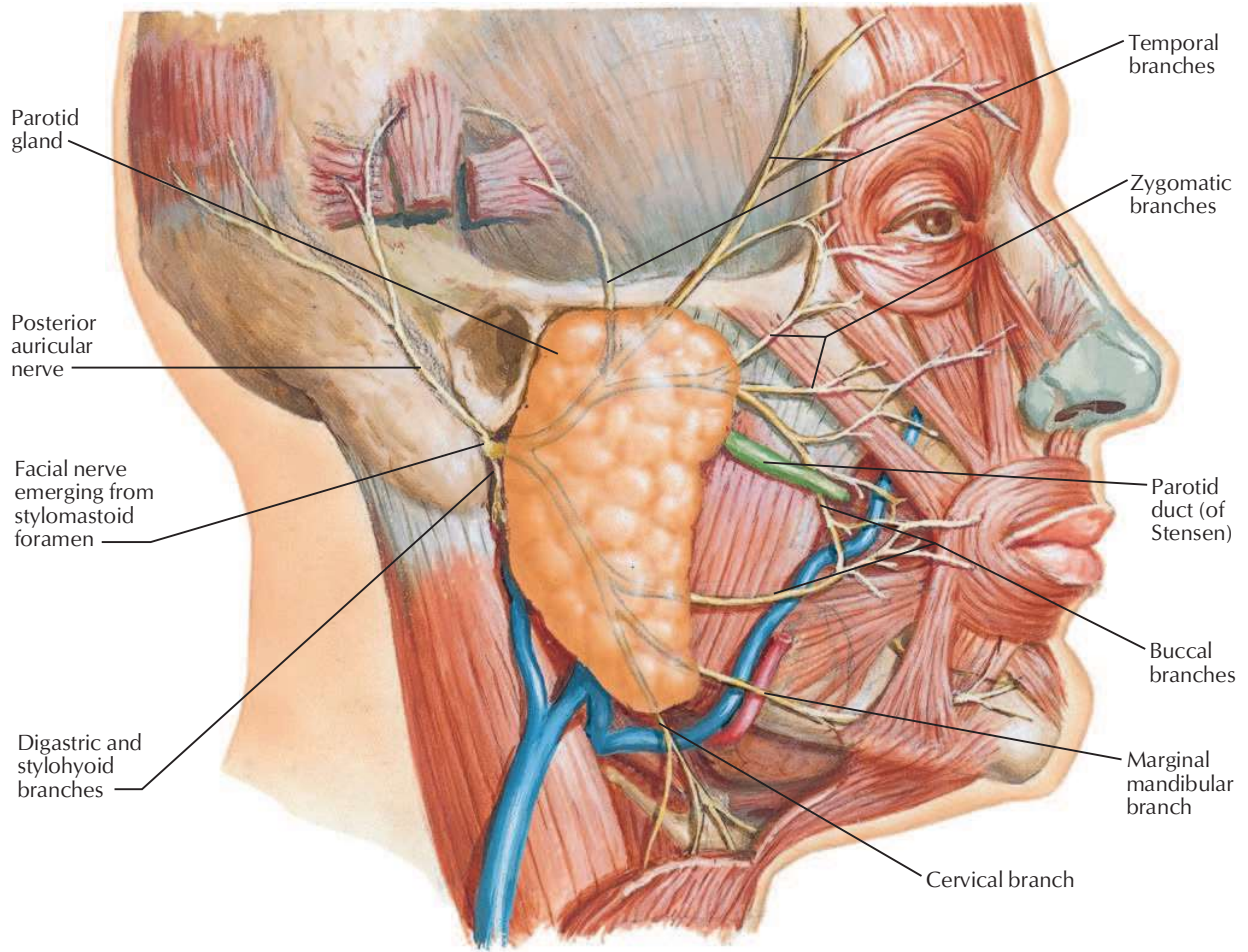
Growth of frontal and maxillary sinuses throughout life



F. Netter M.D.



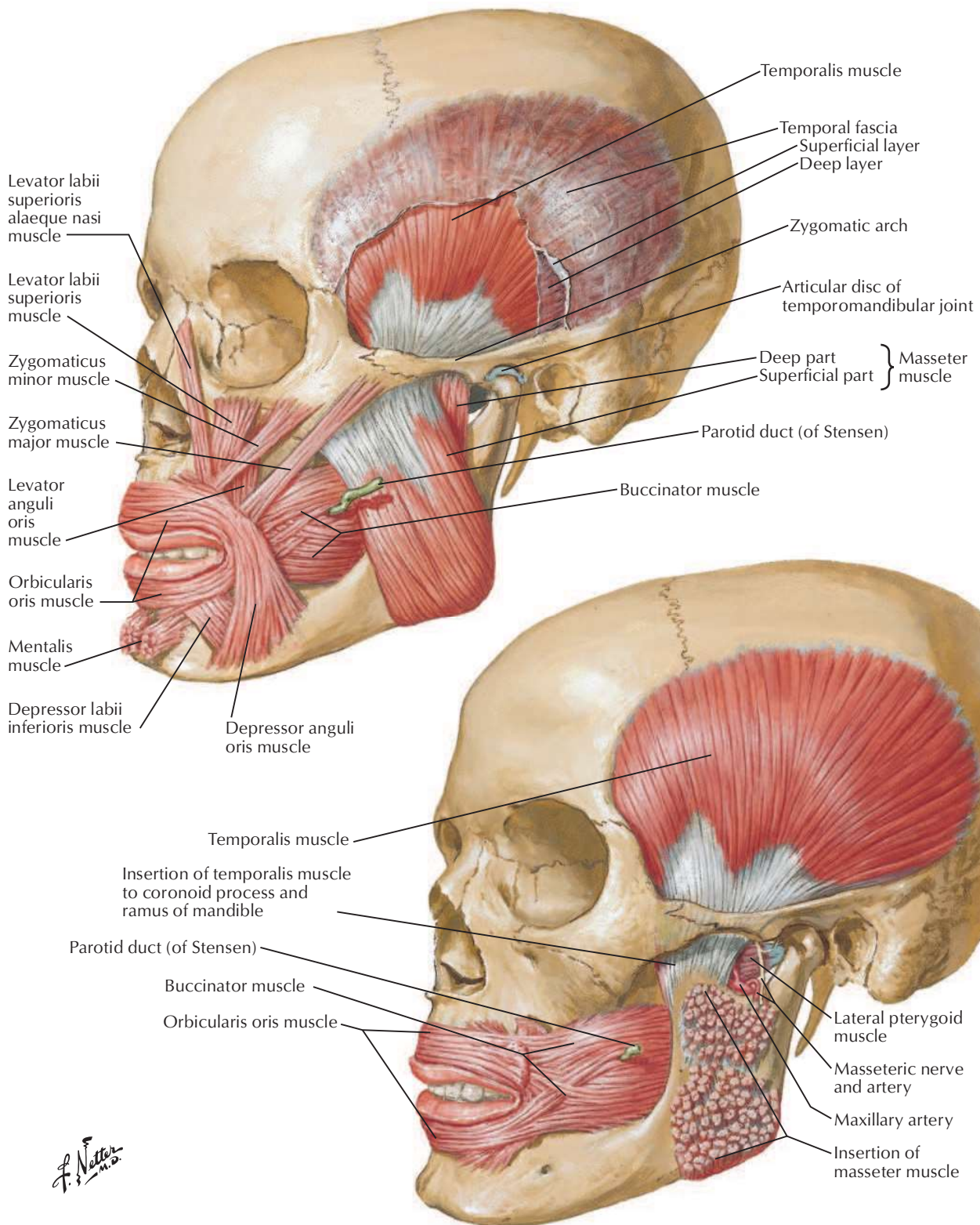
See also Plates 53, 134



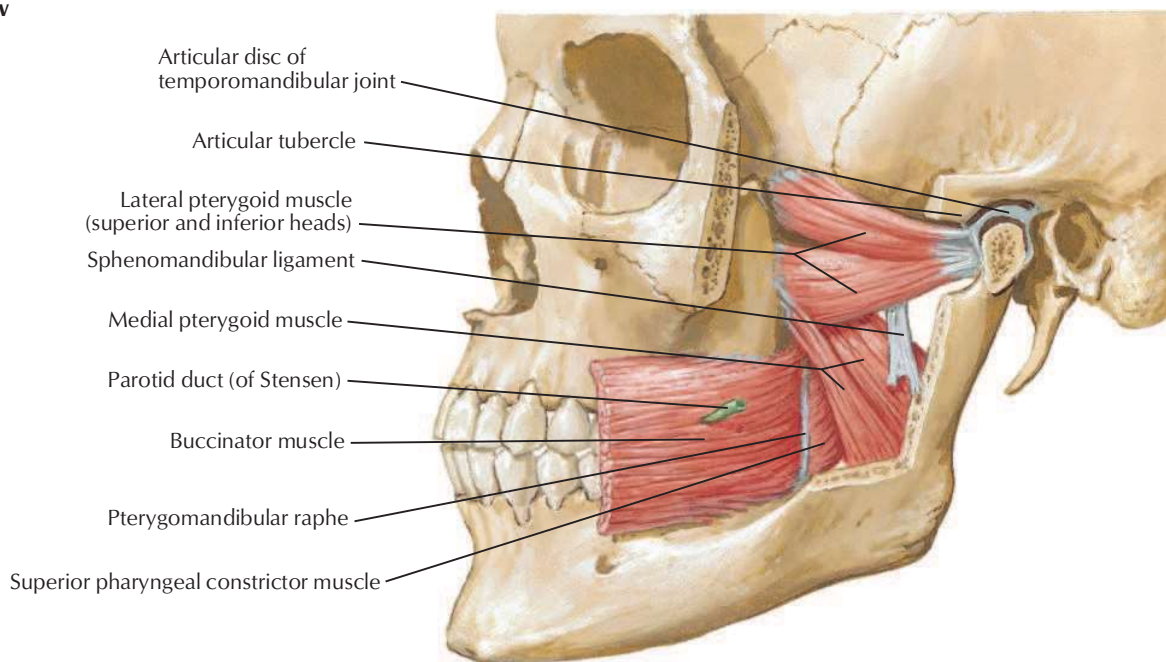
F. Netter M.D.

Muscles Involved in Mastication

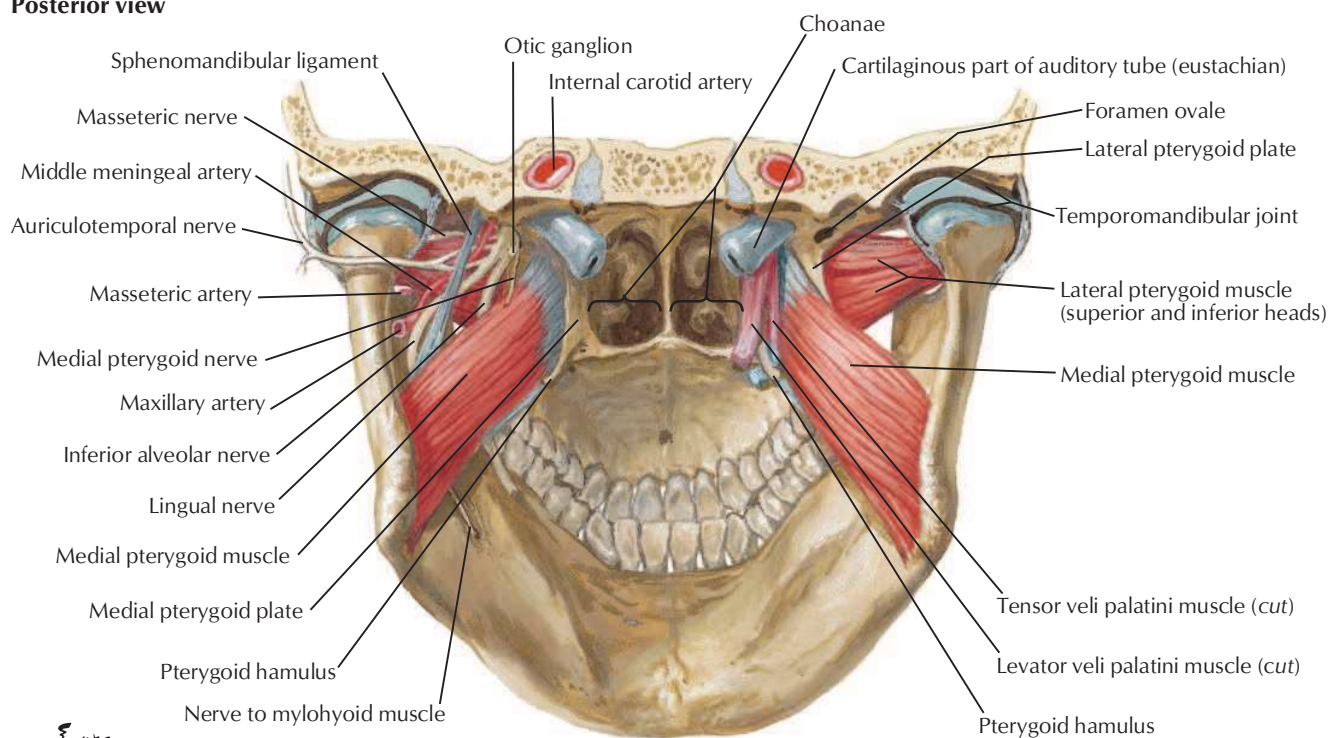
For facial muscles see [Plate 31](#)



Lateral view



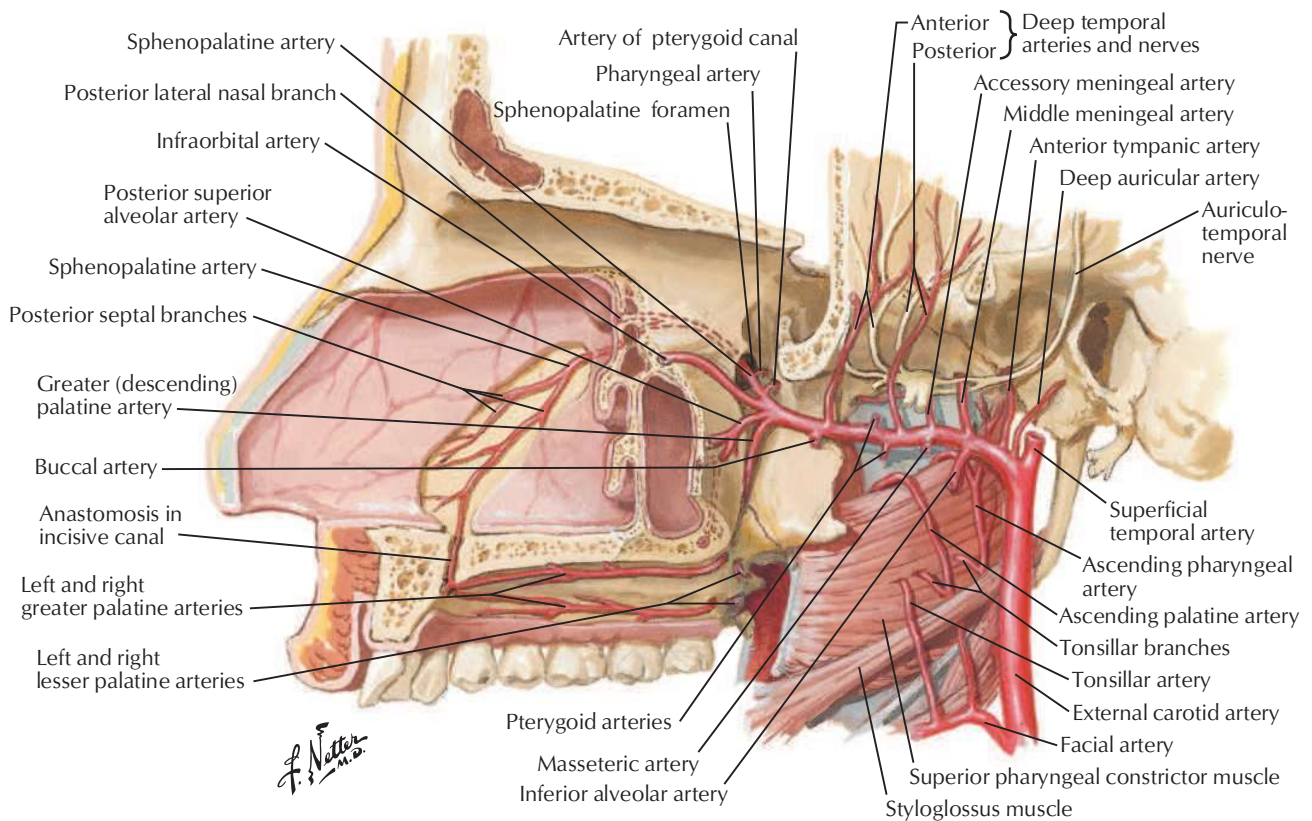
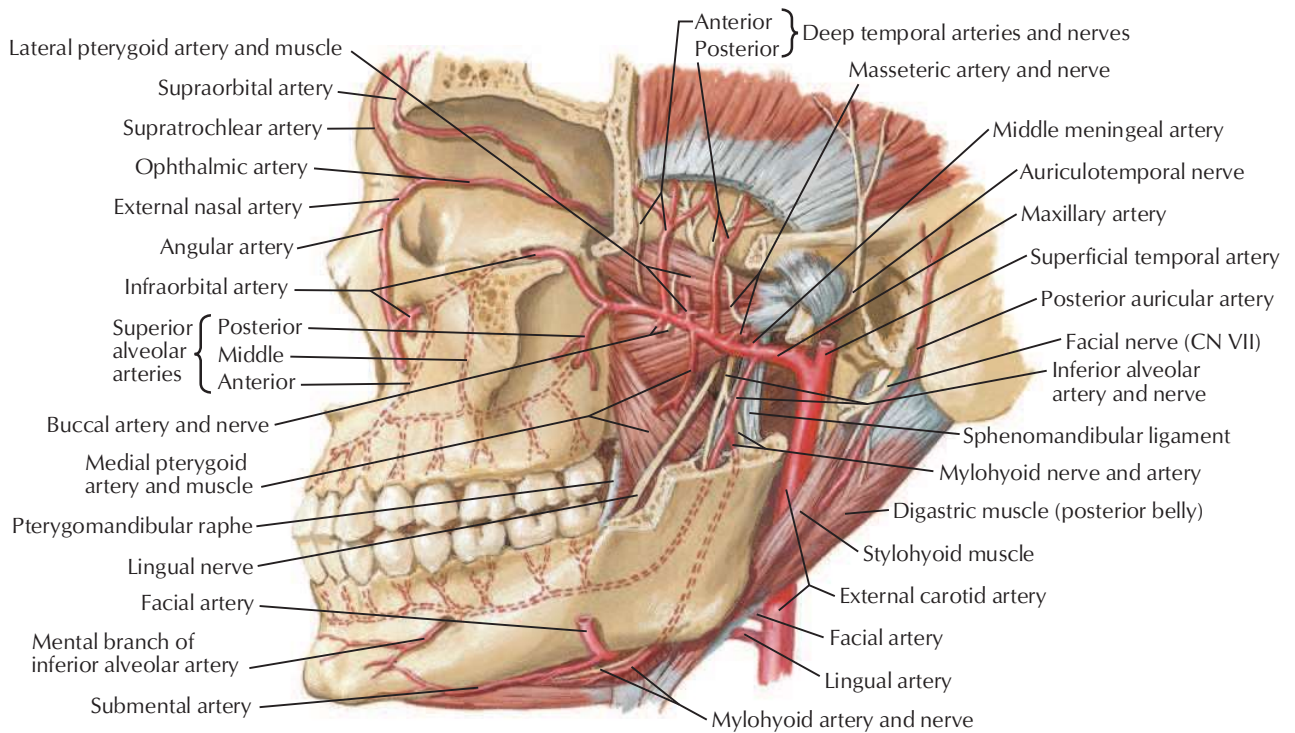
Posterior view



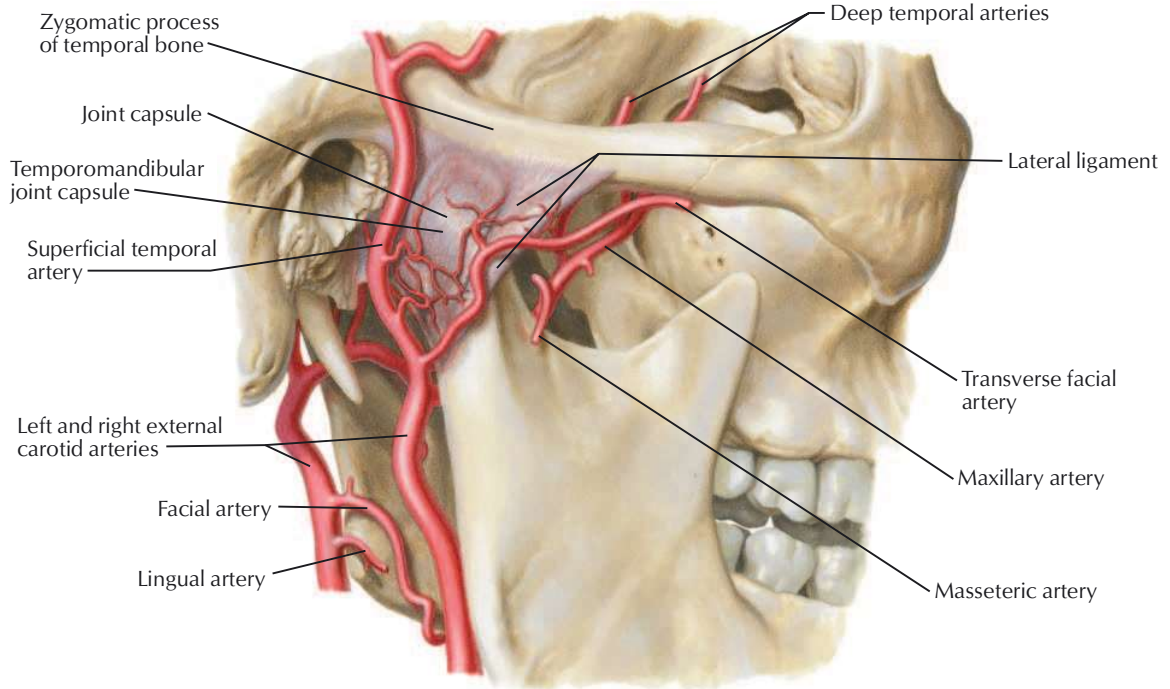
F. Netter M.D.

Maxillary Artery

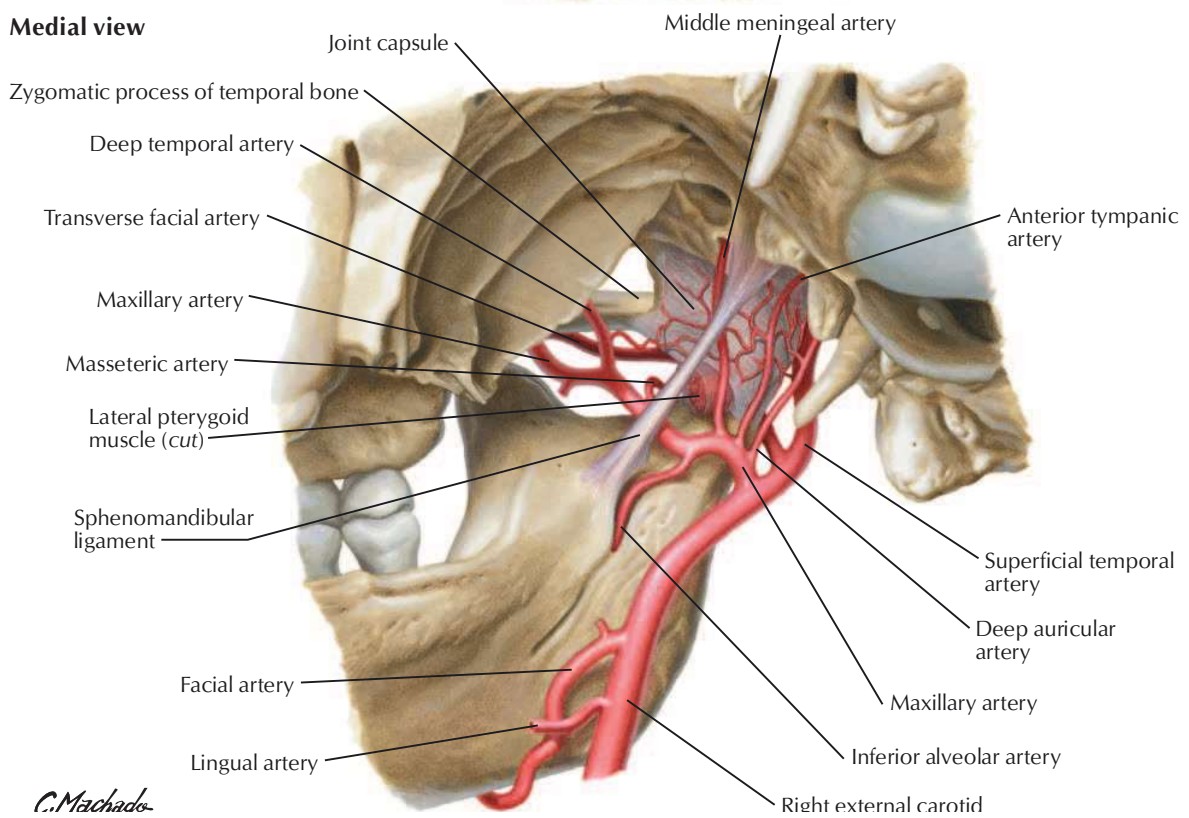
See also **Plates 63, 83**



Lateral view



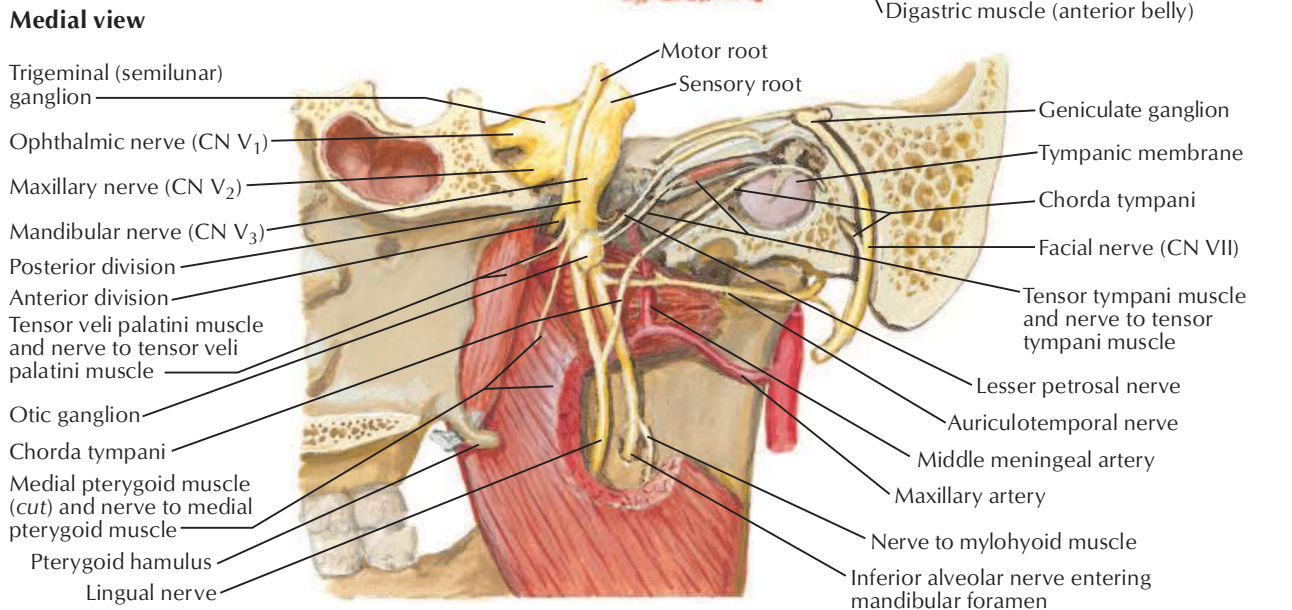
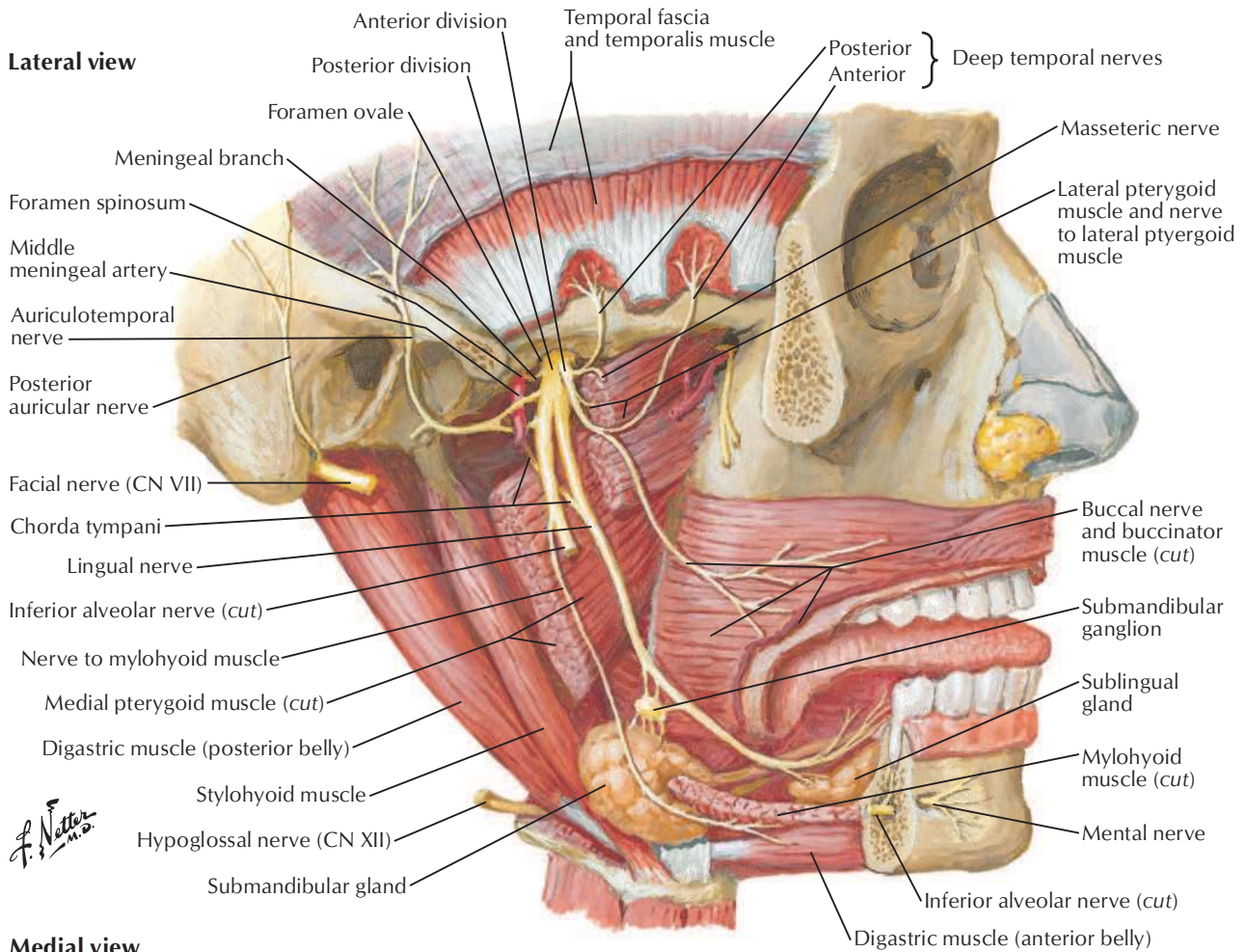
Medial view

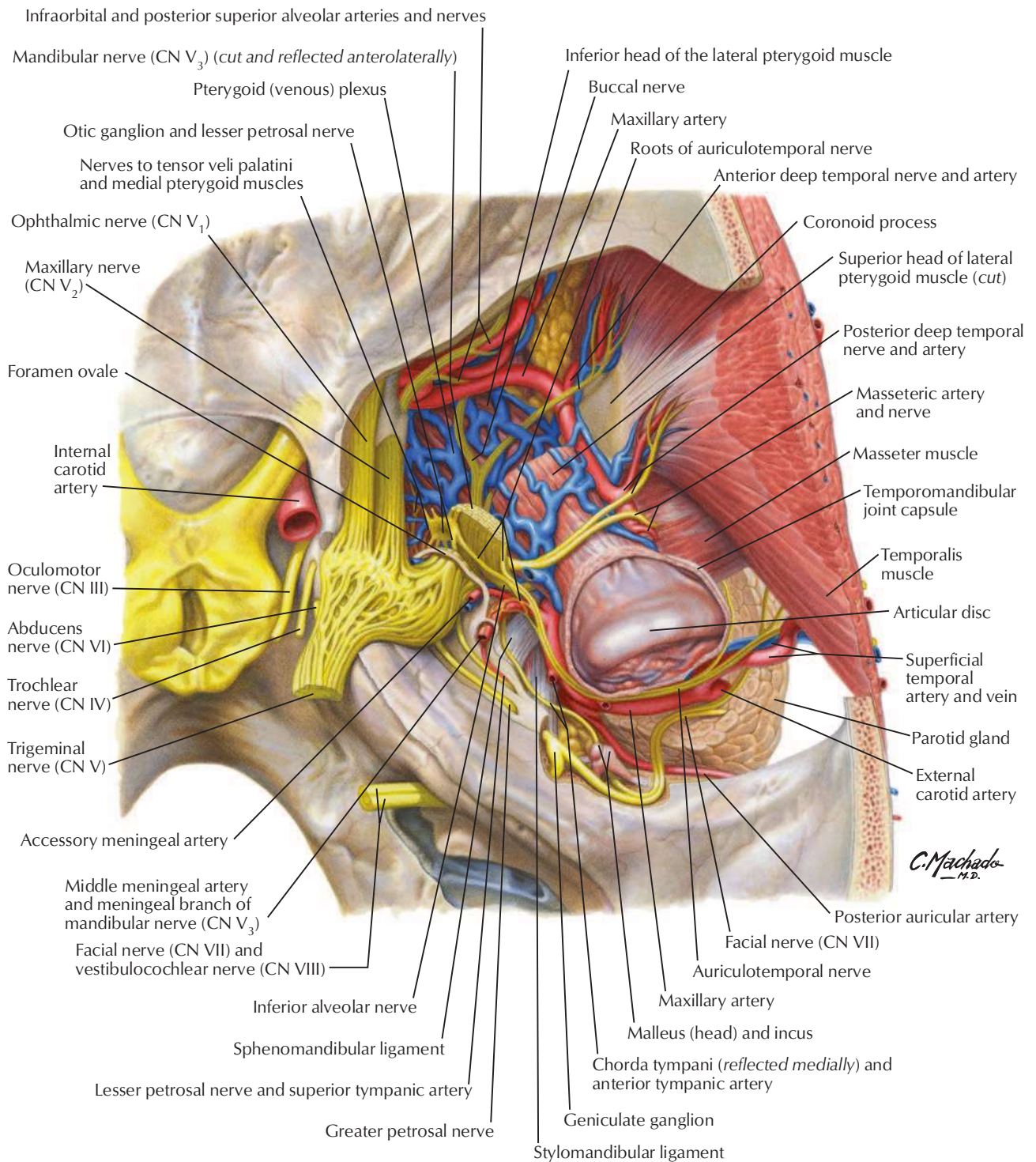


C. Machado

Mandibular Nerve (CN V₃)

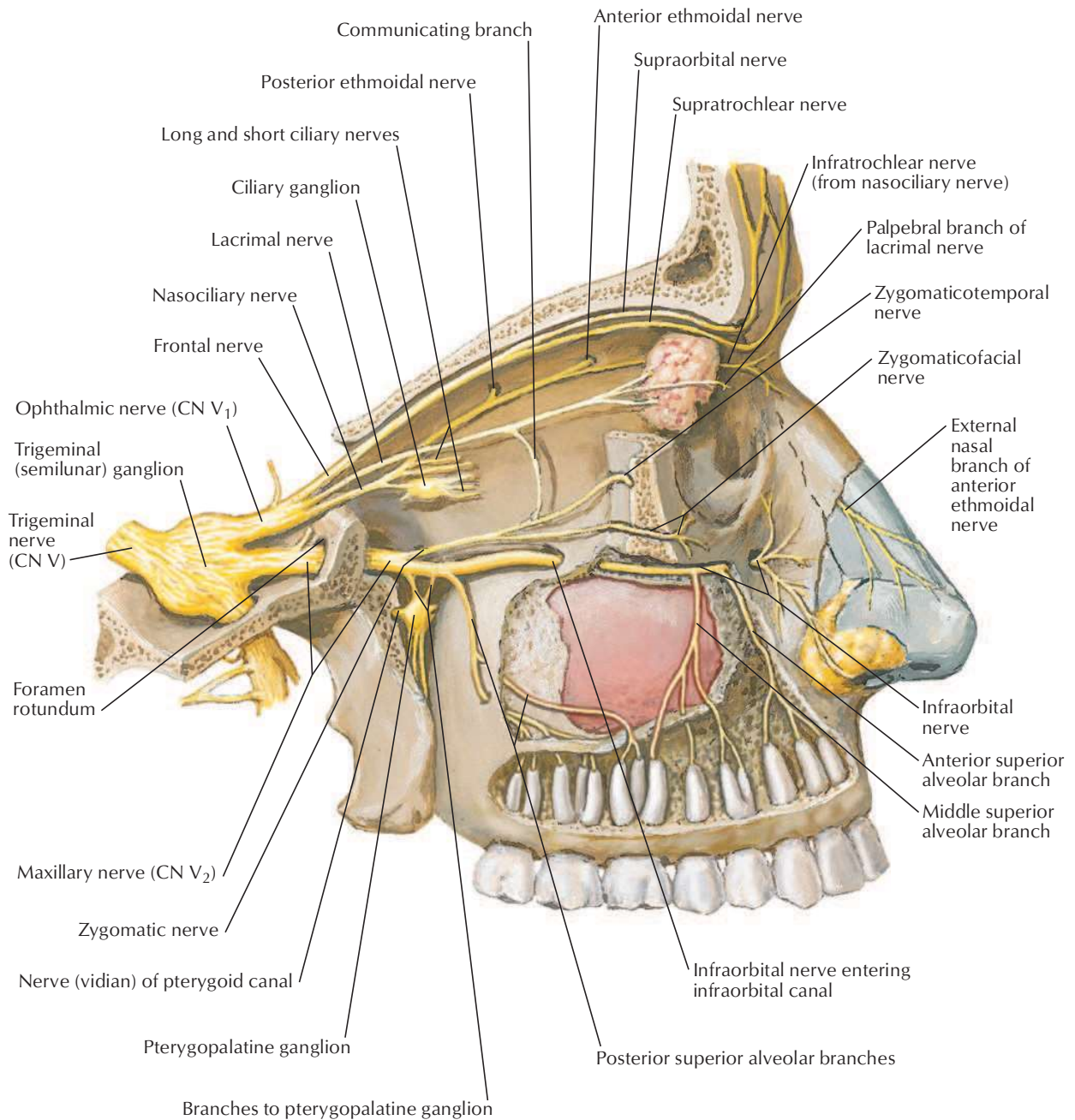
See also **Plates 82, 133**

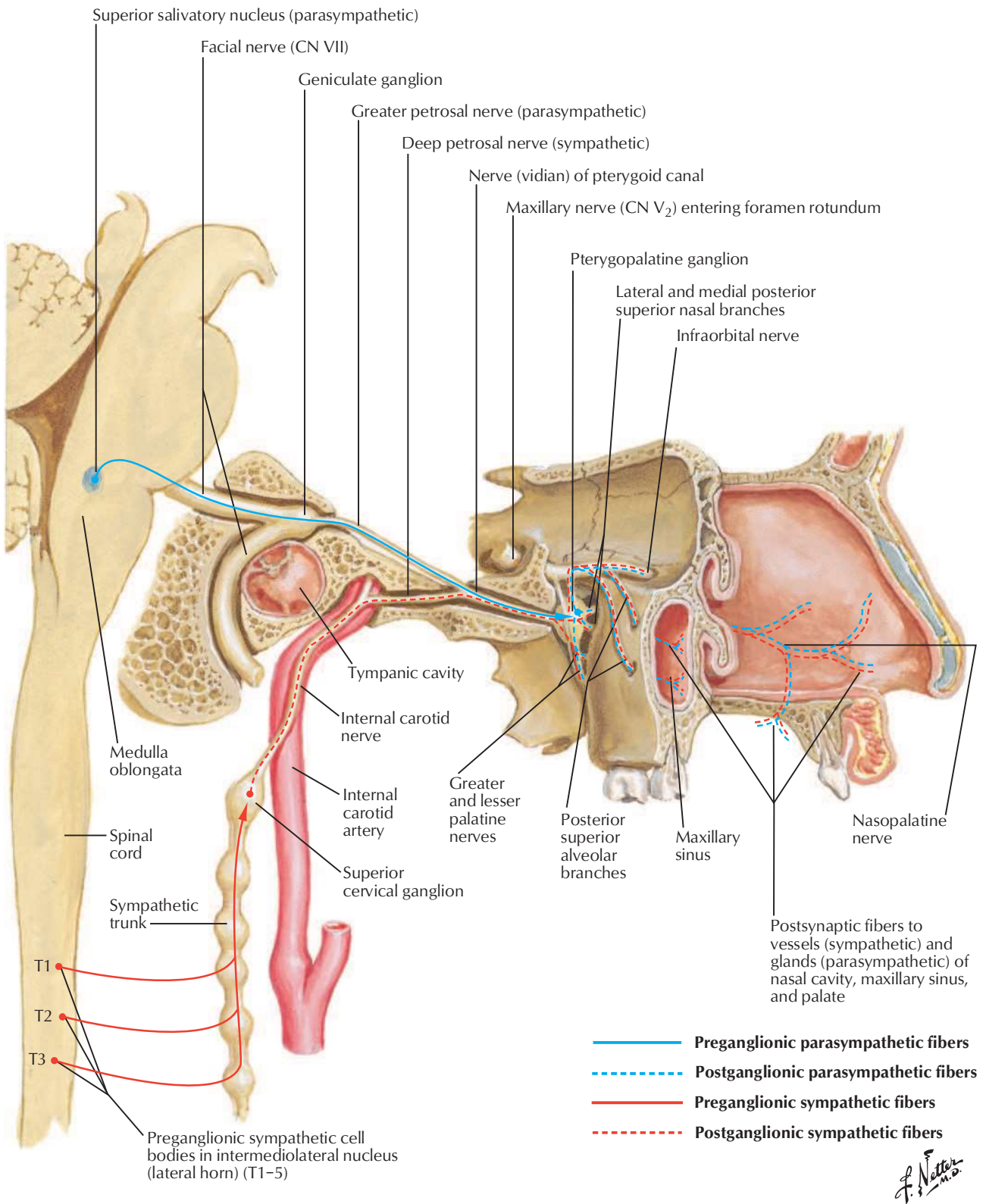




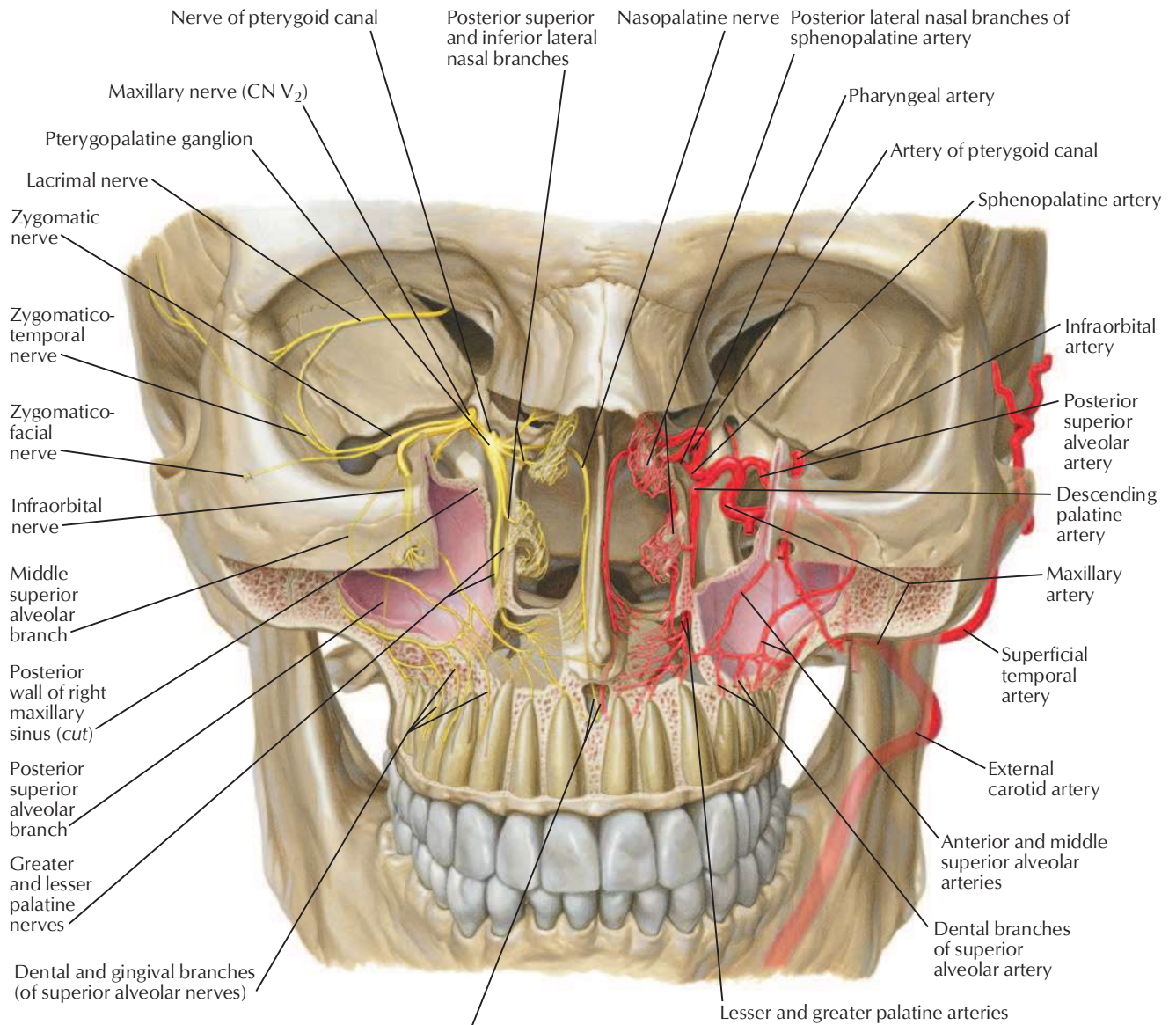
Ophthalmic (CN V₁) and Maxillary (CN V₂) Nerves

See also **Plates 63, 66**

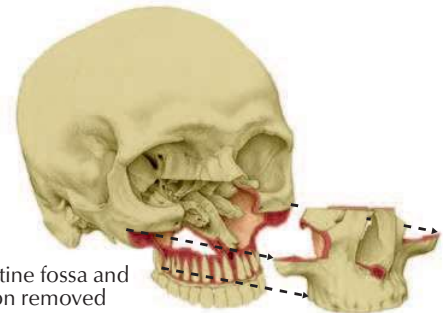




F. Netter M.D.

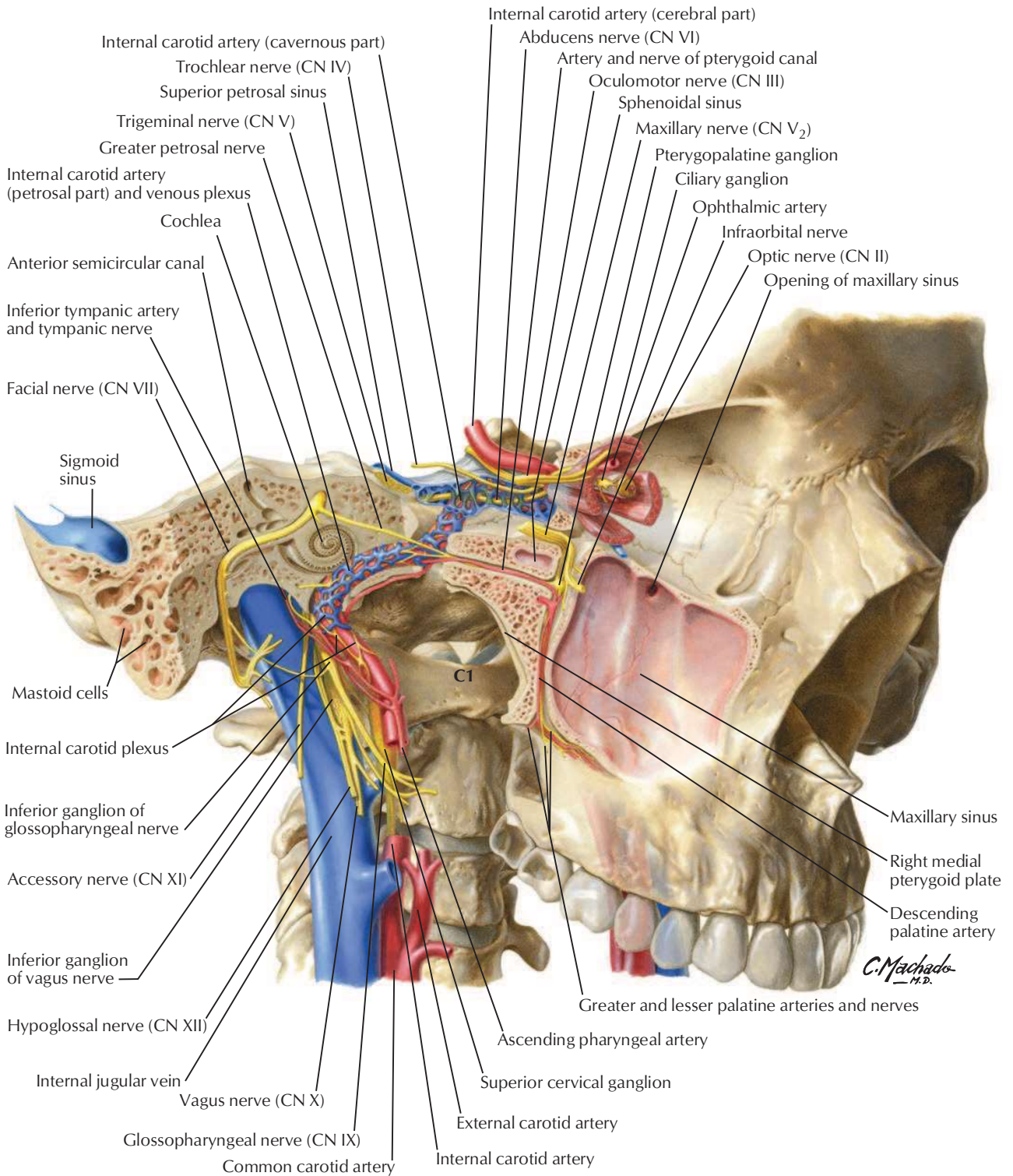


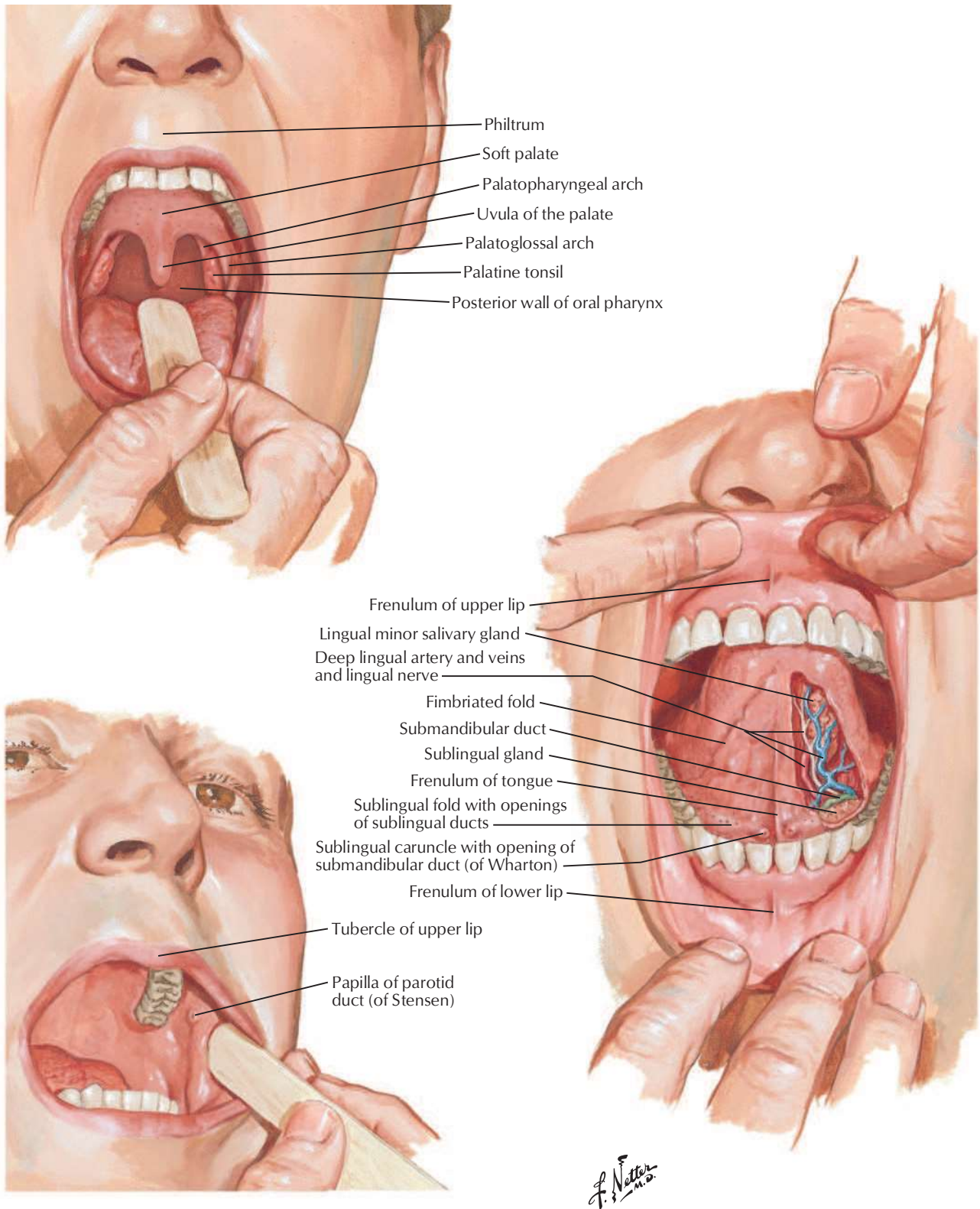
Communication between greater palatine and nasopalatine nerves, and anastomosis between posterior septal branch of sphenopalatine artery and greater palatine artery in incisive canal



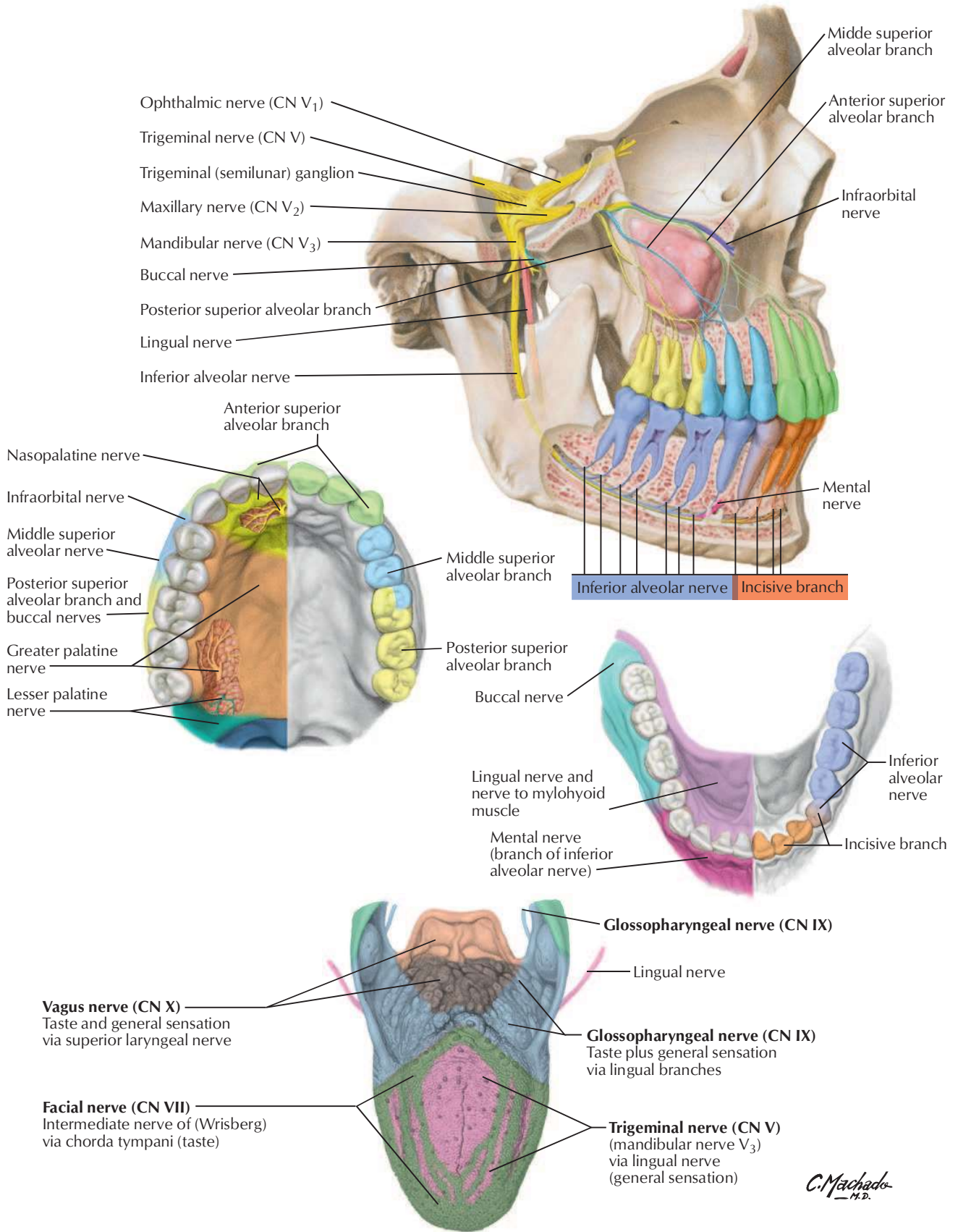
Anterior perspective of pterygopalatine fossa and nasal cavity with lower facial skeleton removed

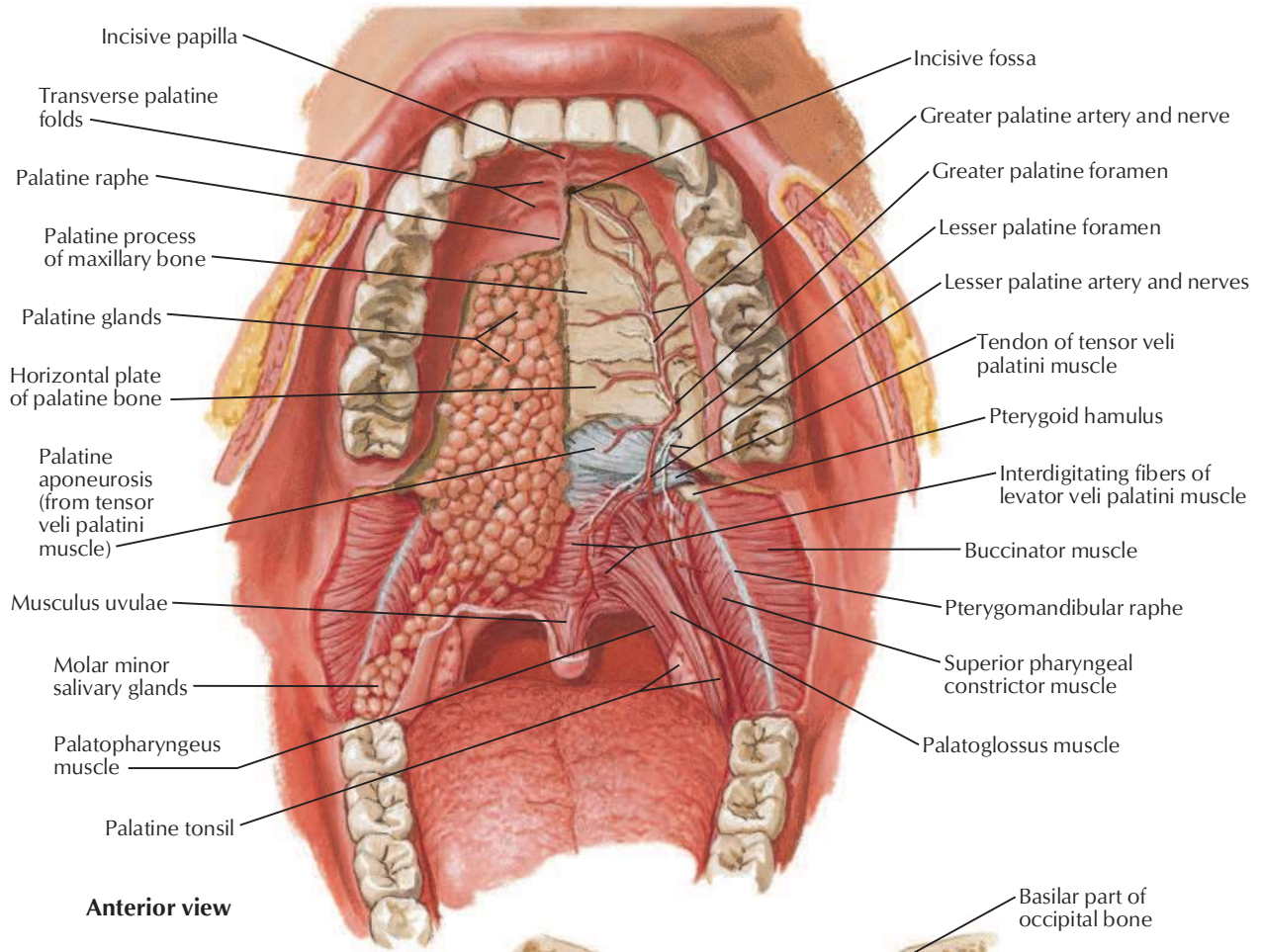
C. Machado
M.D.



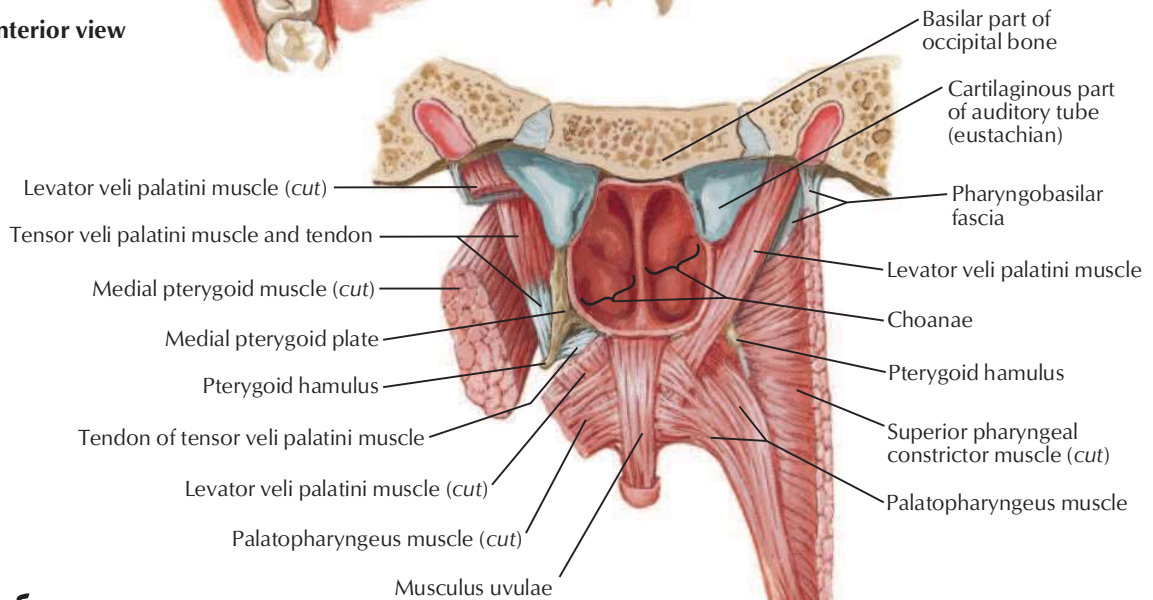


See also **Plates 144, 146**



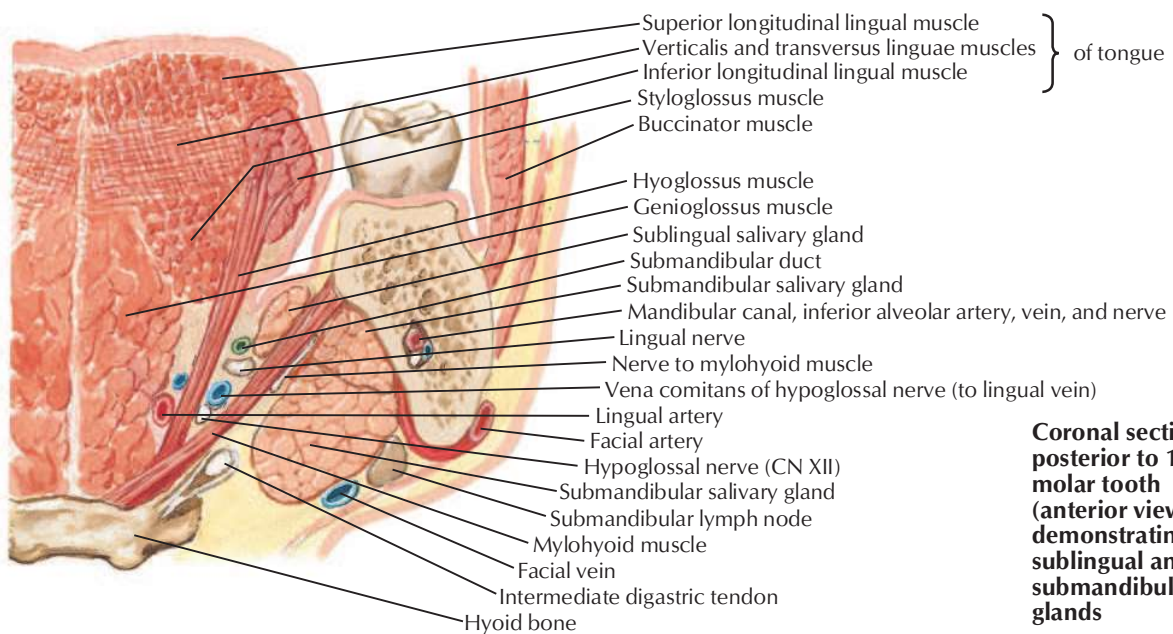
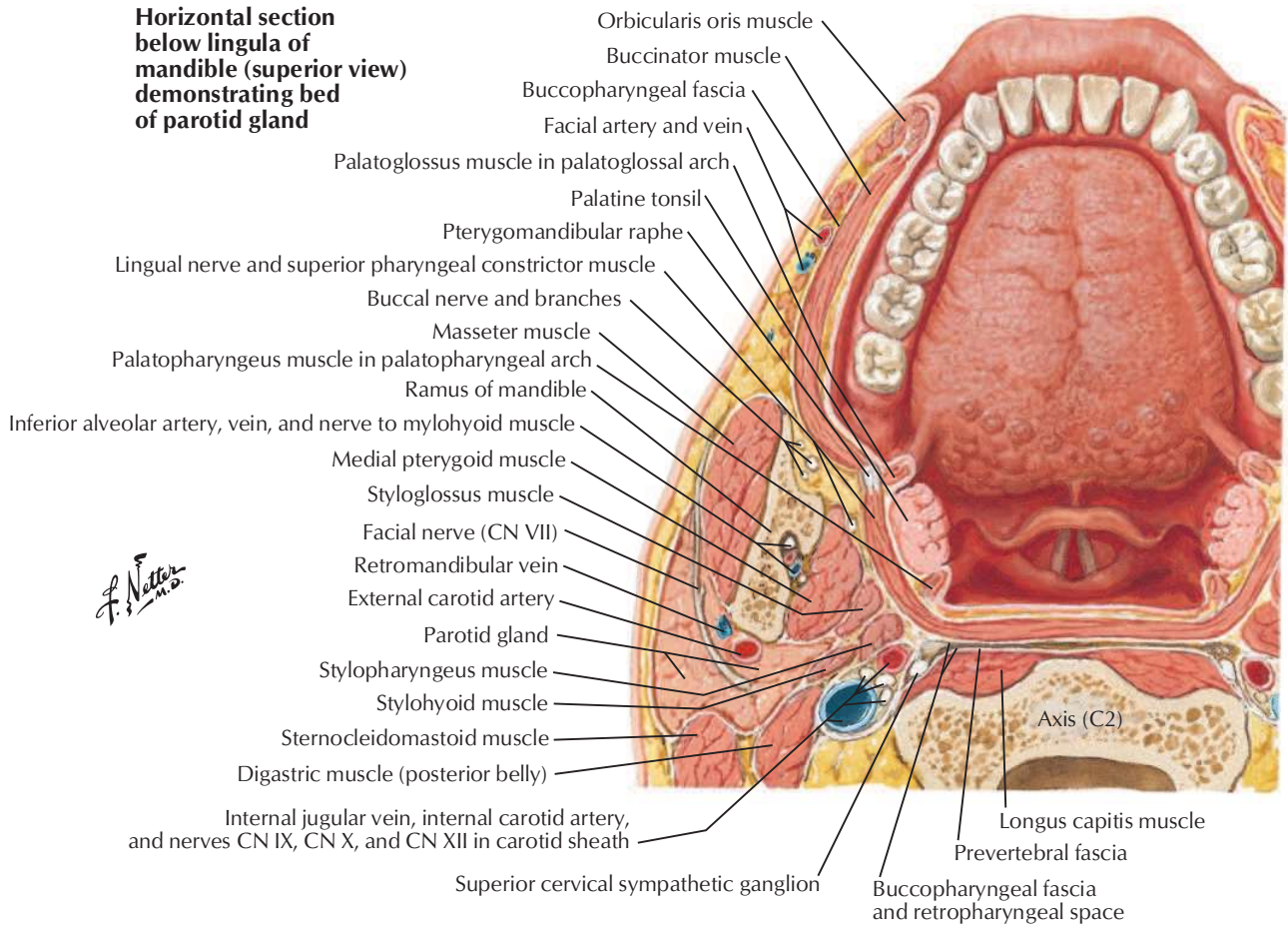


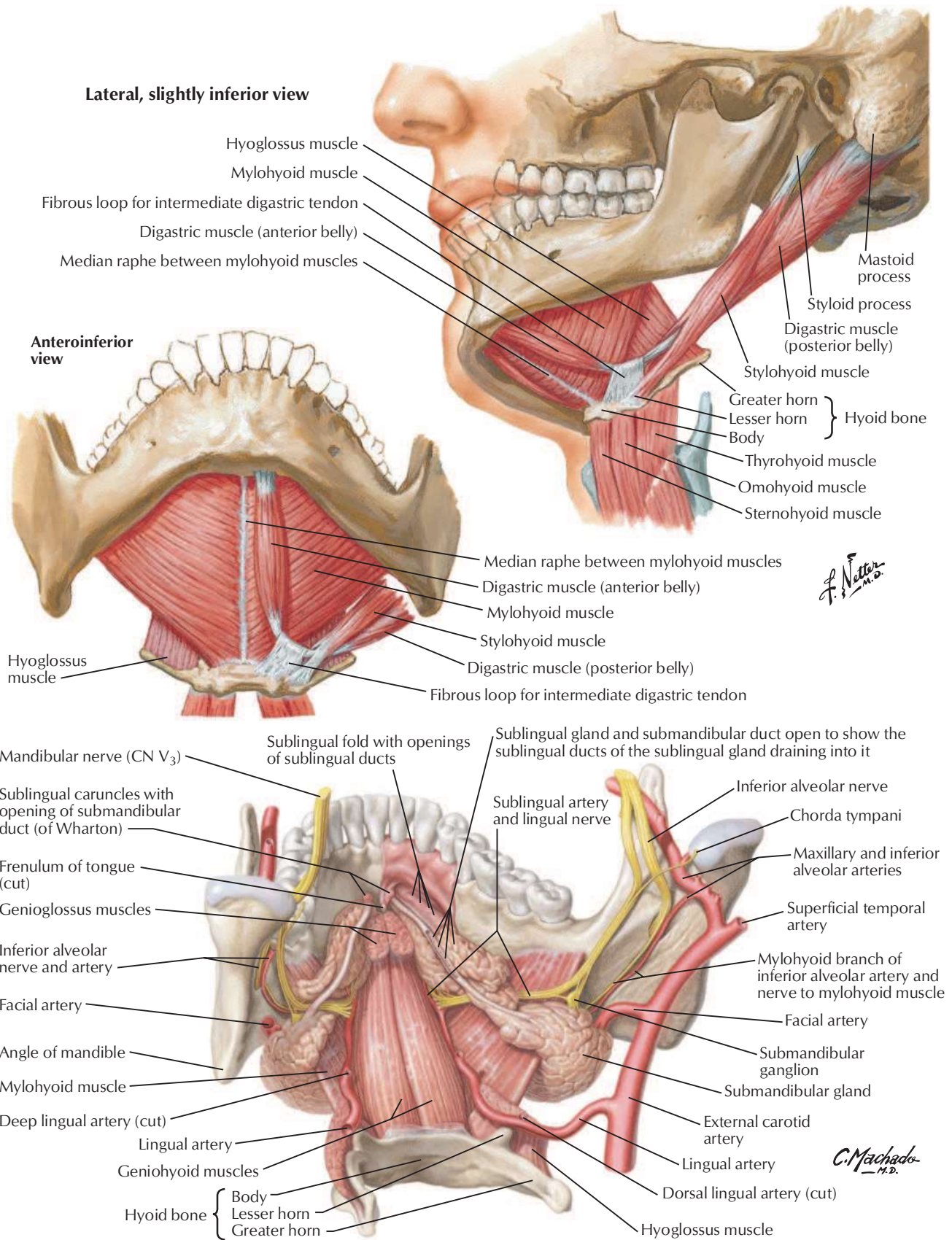
Anterior view

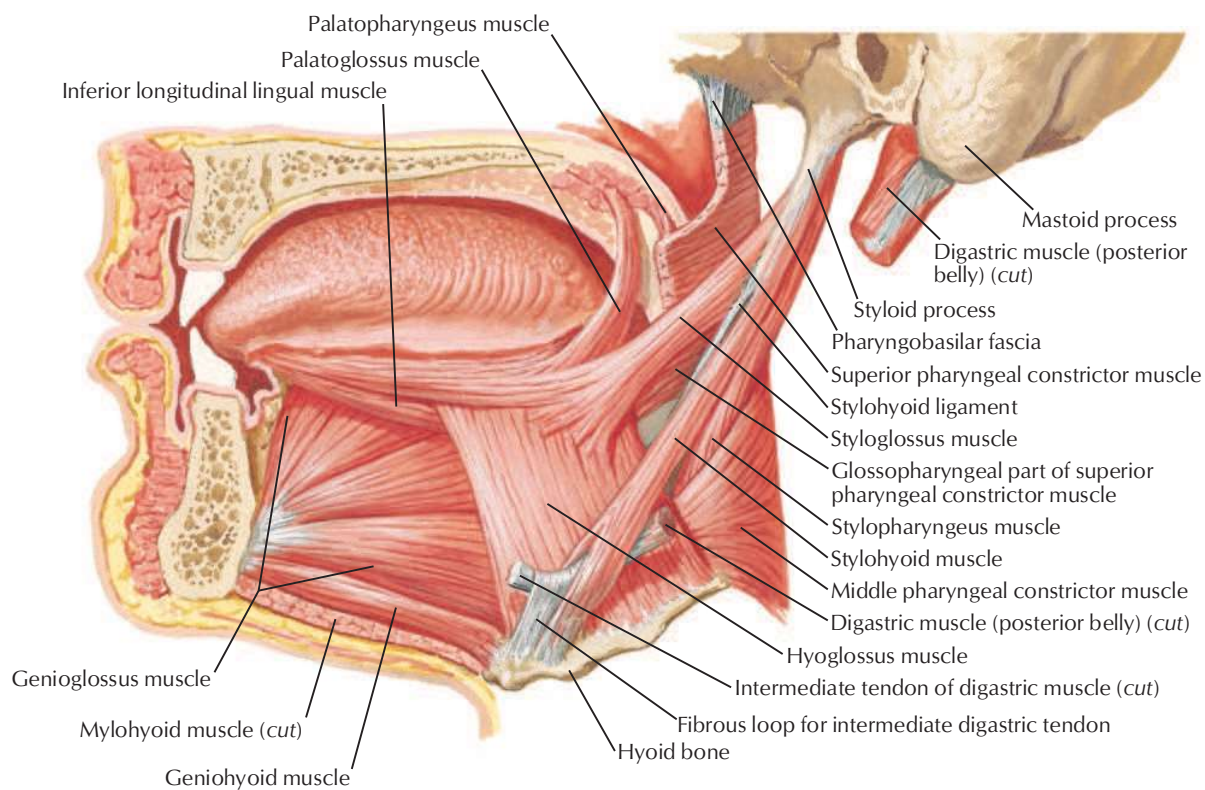


Posterior view

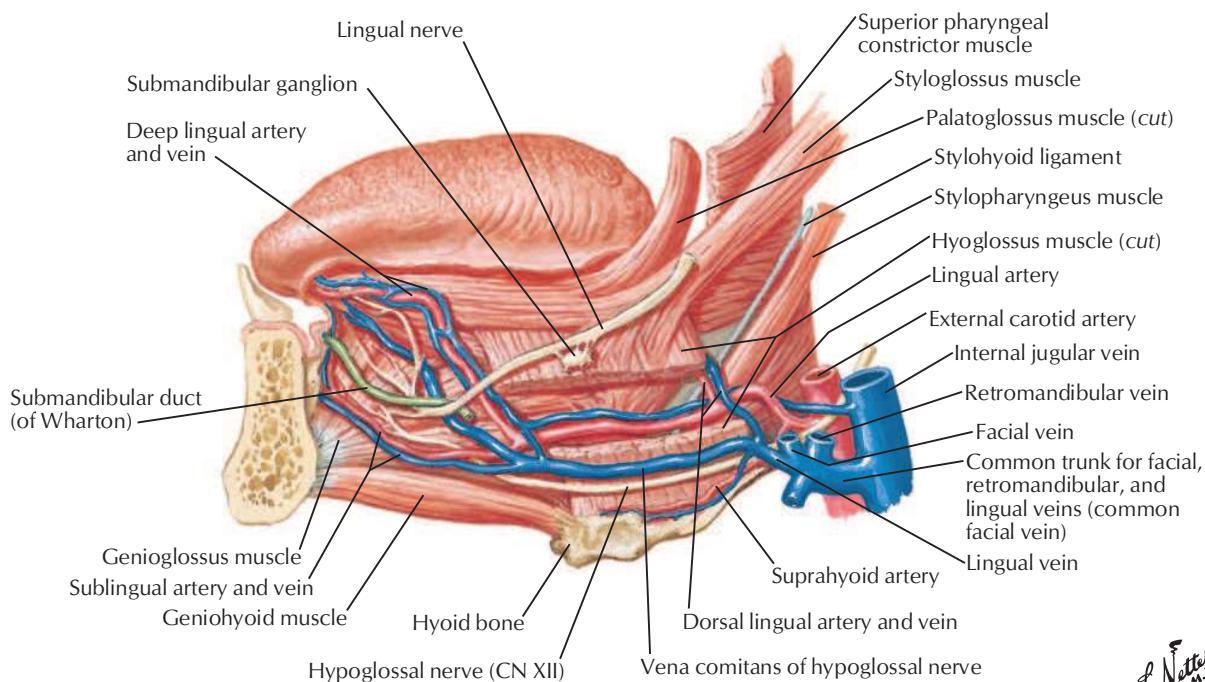
**Horizontal section
below lingula of
mandible (superior view)
demonstrating bed
of parotid gland**



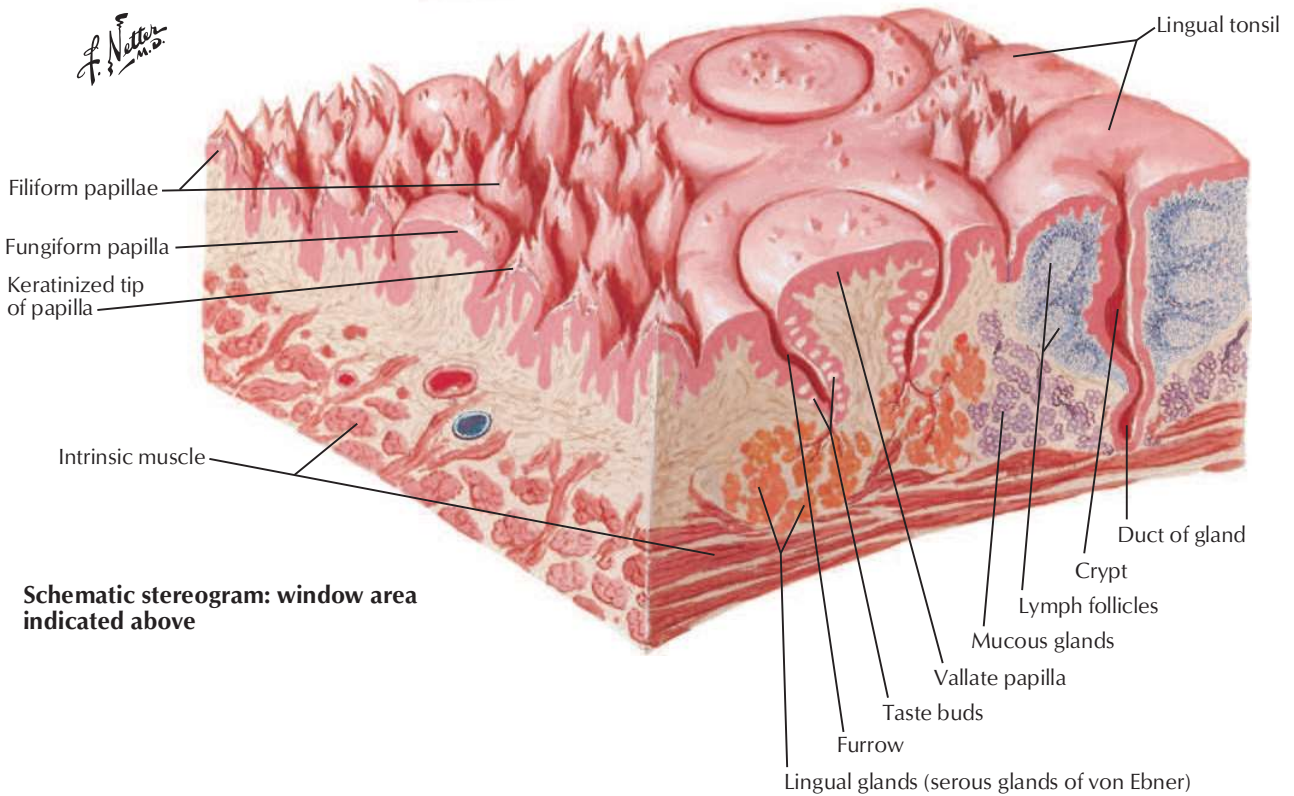
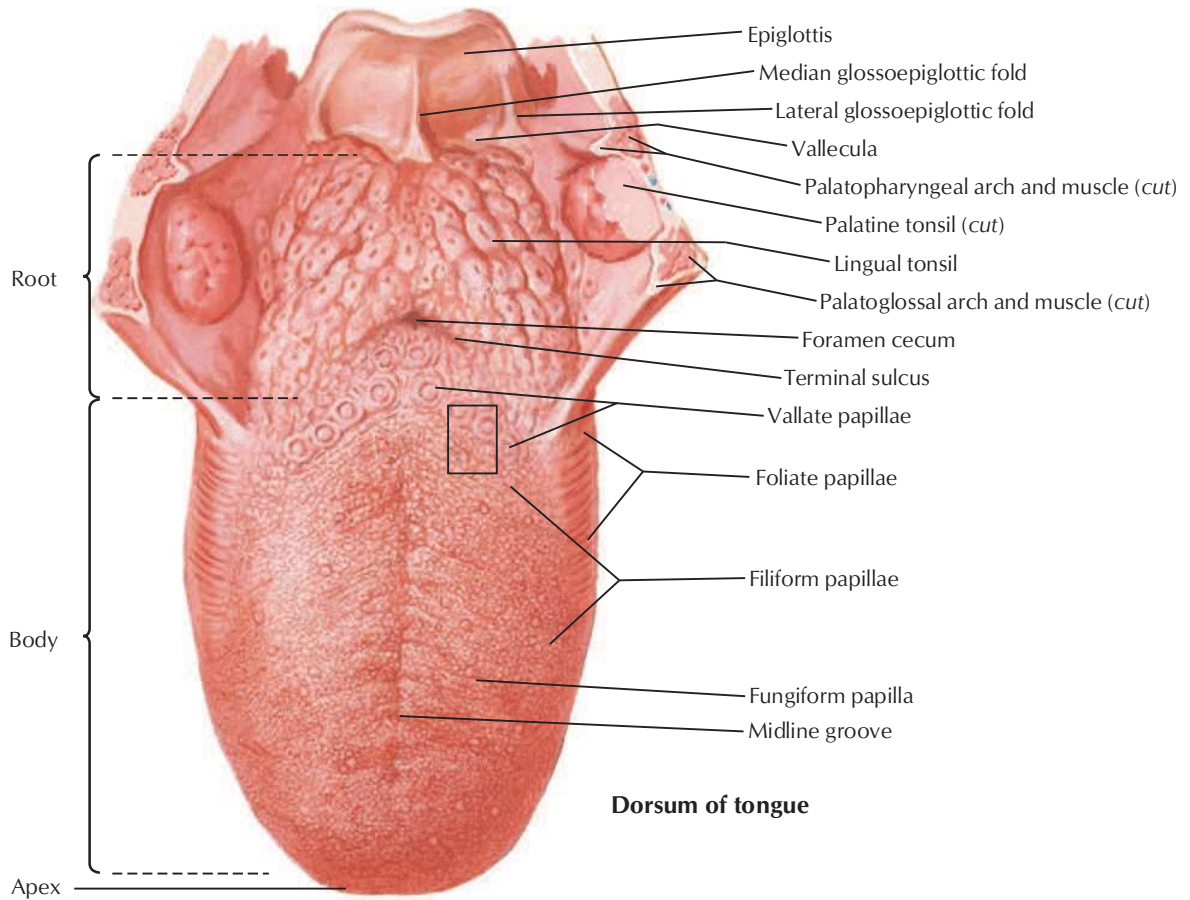




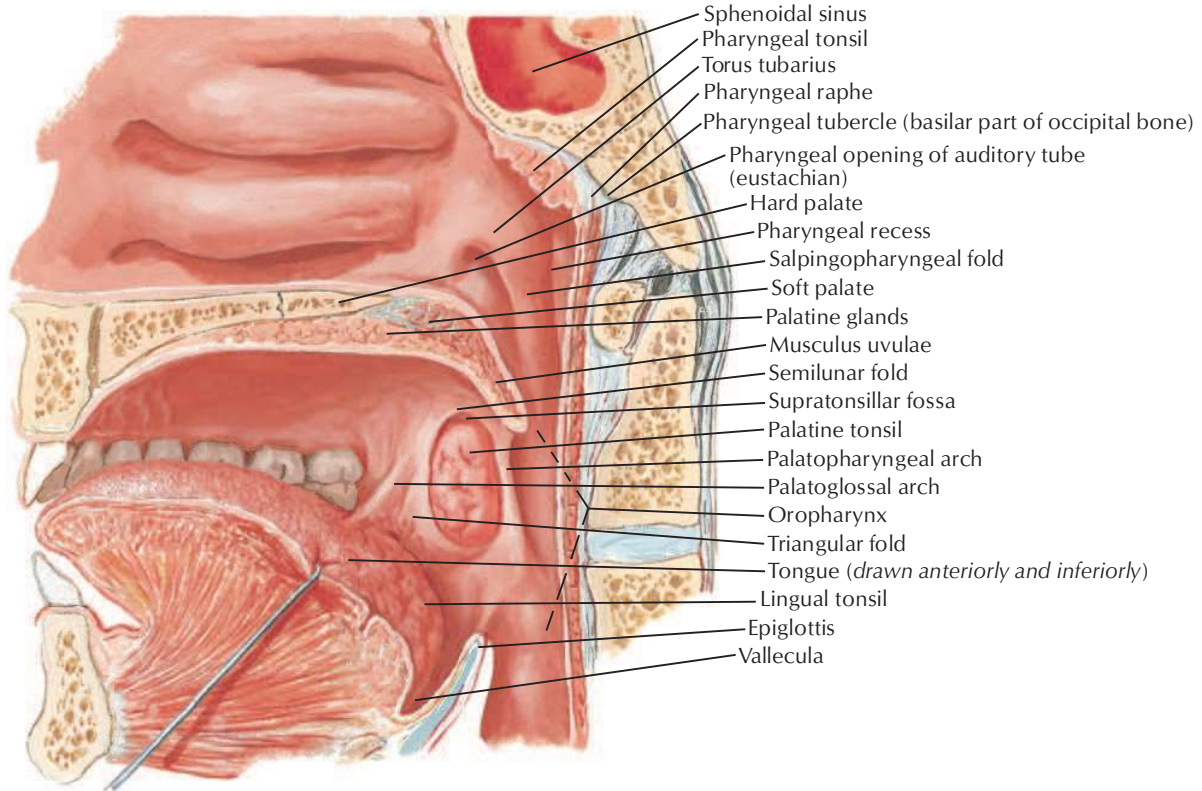
Lateral view (left side of mandible removed)



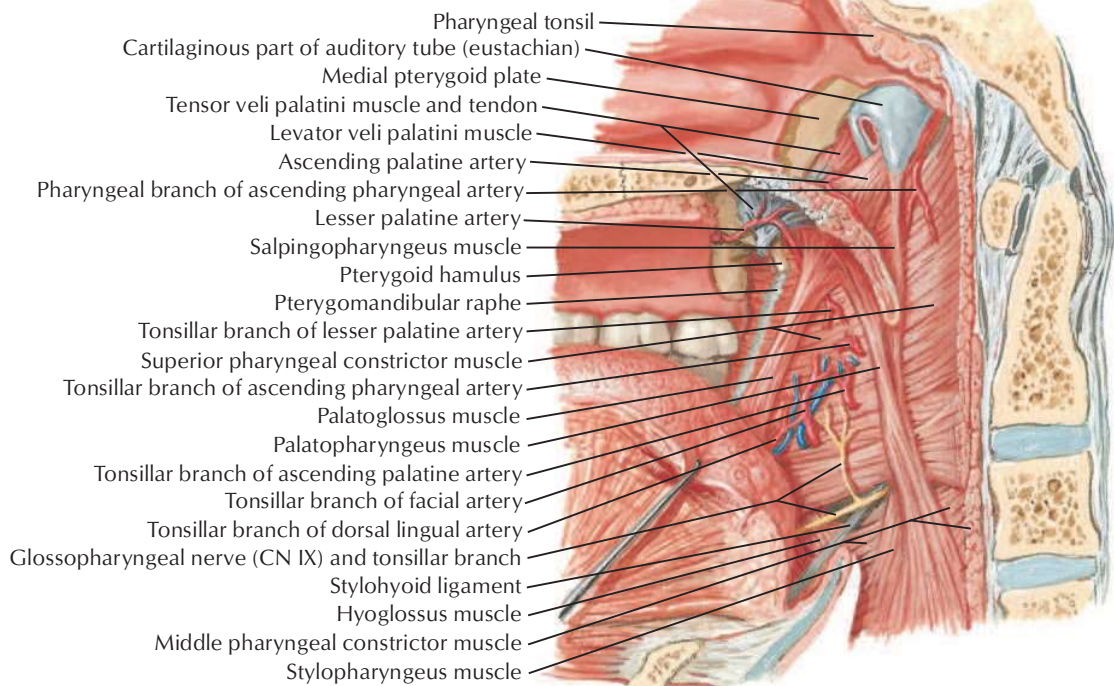
F. Netter M.D.



**Medial view
sagittal section**



Pharyngeal mucosa removed



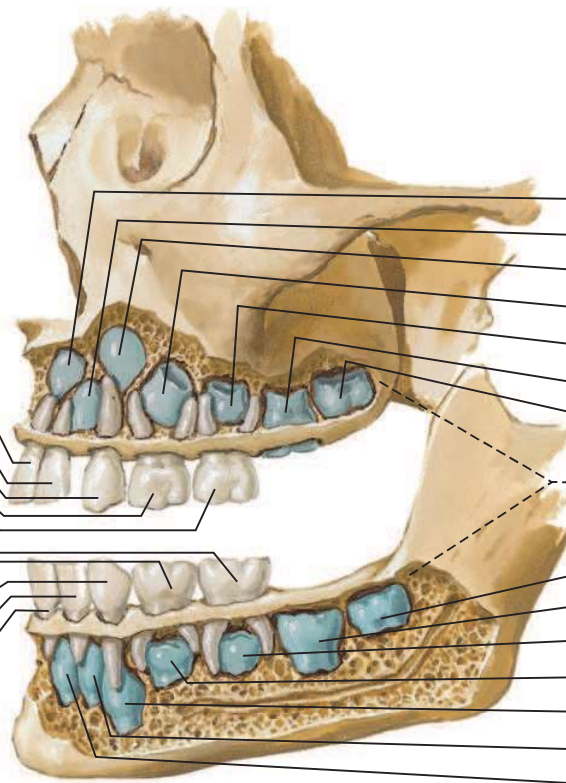
F. Netter M.D.

**Deciduous
(primary)
Usual age of
eruption**

**Permanent
(colored blue)
Usual age of
eruption**

- Central incisor (8–10 months)
- Lateral incisor (8–10 months)
- Canine (cuspid) (16–20 months)
- 1st molar (15–21 months)
- 2nd molar (20–24 months)
- 2nd molar (20–24 months)
- 1st molar (15–21 months)
- Canine (cuspid) (16–20 months)
- Lateral incisor (15–21 months)
- Central incisor (6–9 months)

- Central incisor (7th year)
- Lateral incisor (8th year)
- Canine (cuspid) (11th–12th year)
- 1st premolar (9th year)
- 2nd premolar (10th year)
- 1st molar (6th year)
- 2nd molar (12th–13th year)
- 3rd molars (17th–25th year)
- 2nd molar (12th–13th year)
- 1st molar (6th year)
- 2nd premolar (10th year)
- 1st premolar (9th year)
- Canine (cuspid) (11th–12th year)
- Lateral incisor (8th year)
- Central incisor (7th year)



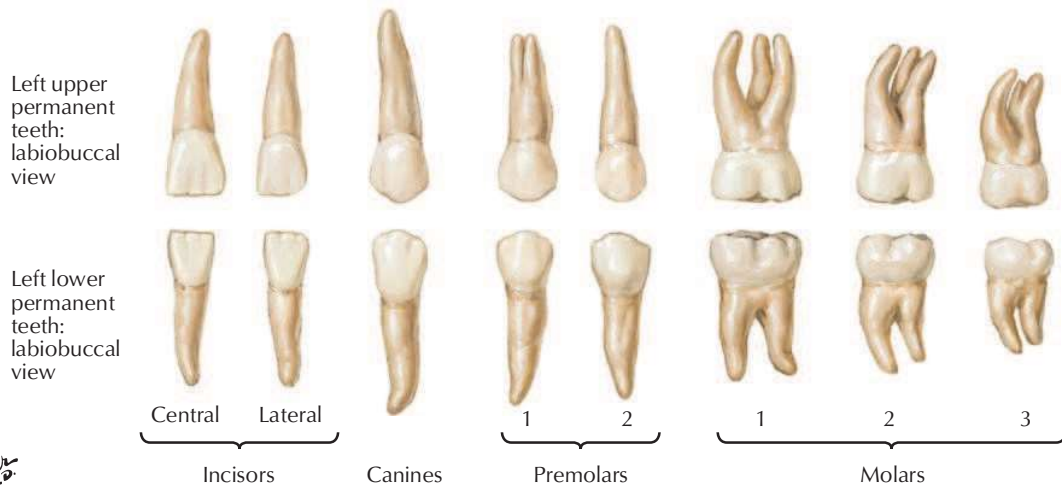
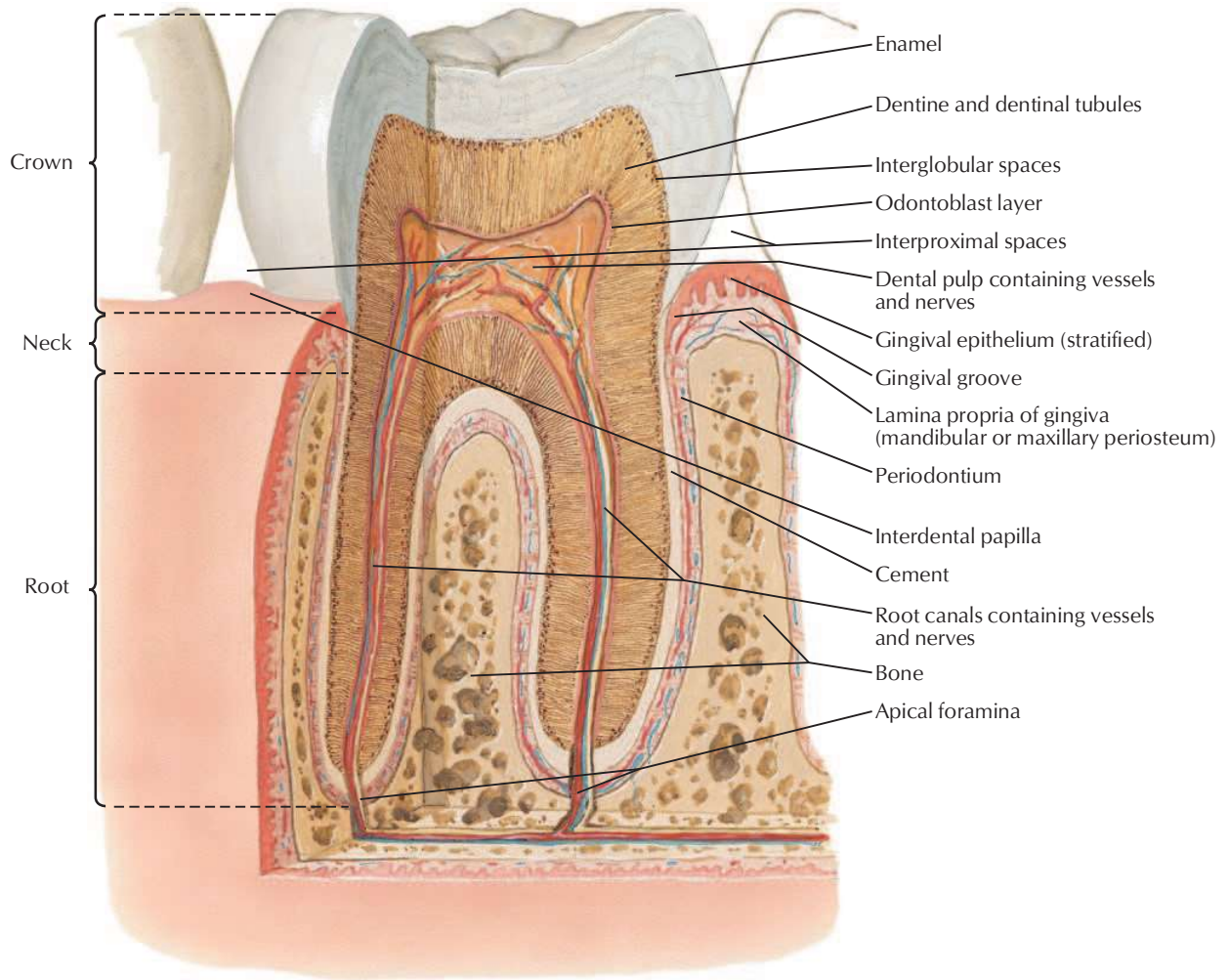
- Incisive fossa
- Palatine process of maxillary bone
- Horizontal plate of palatine bone

Greater and lesser palatine foramina

Upper permanent teeth

- Central incisors
- Lateral incisors
- Canines
- 1st premolars
- 2nd premolars
- 1st molars
- 2nd molars
- 3rd molars

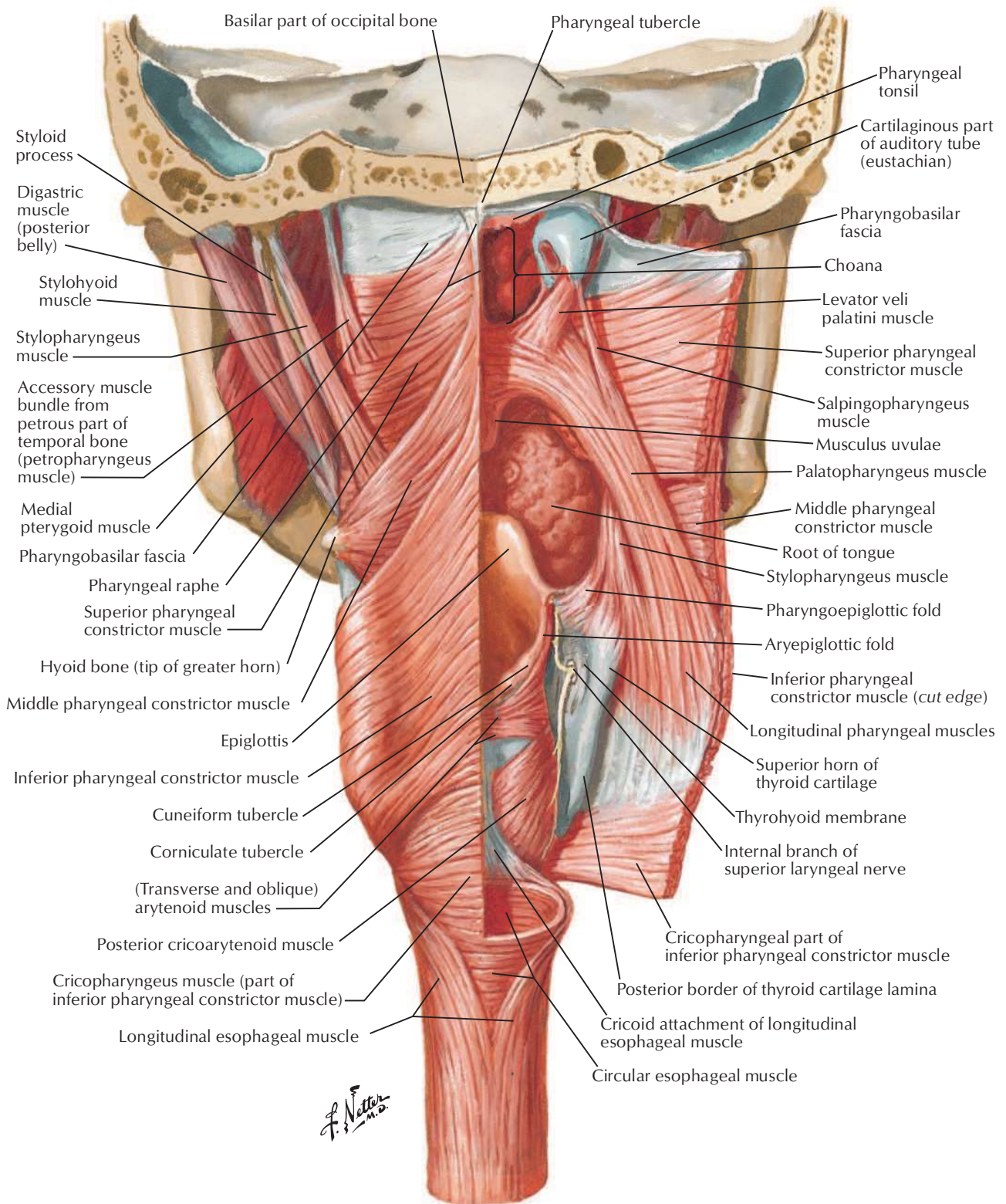
Lower permanent teeth



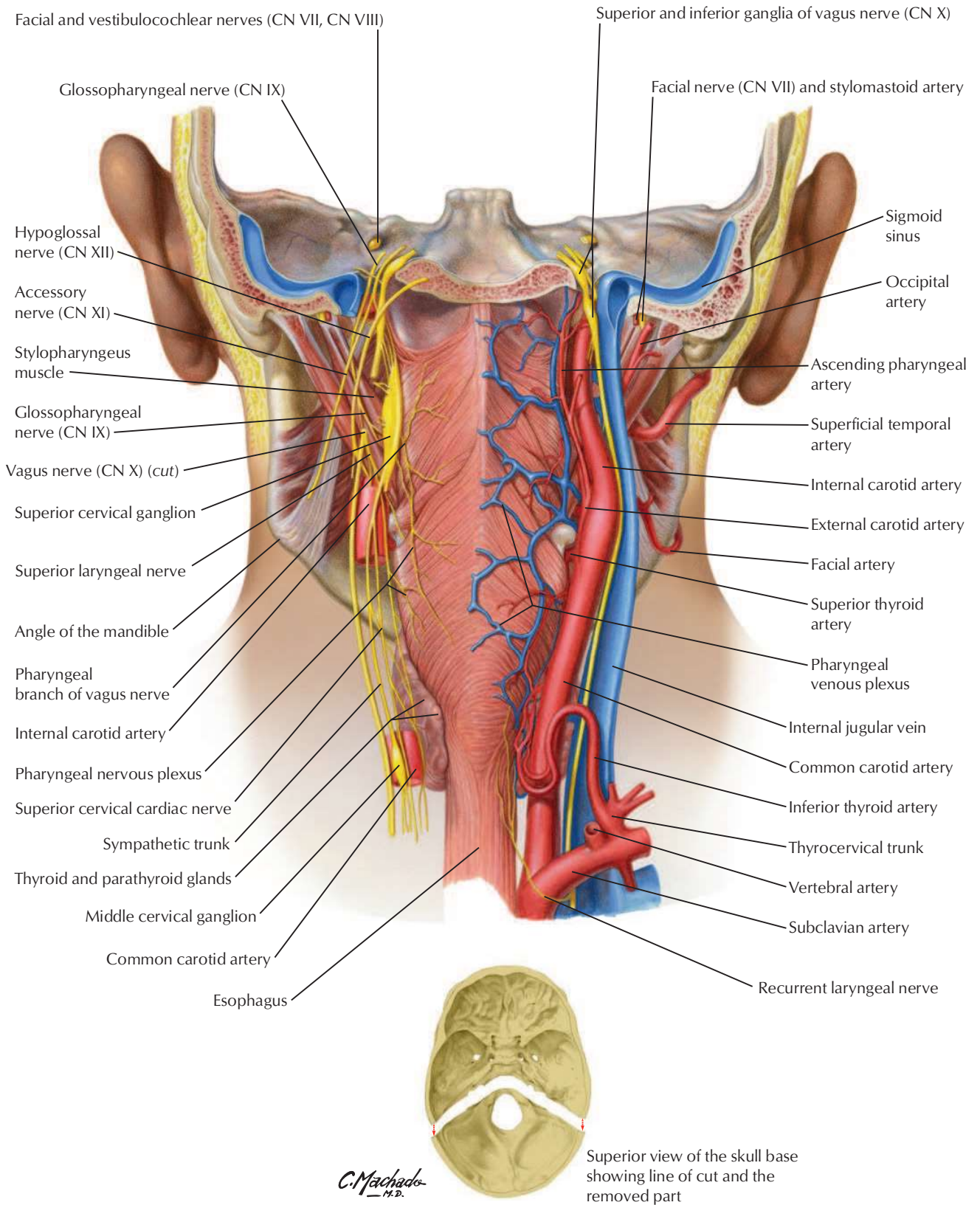
F. Netter M.D.

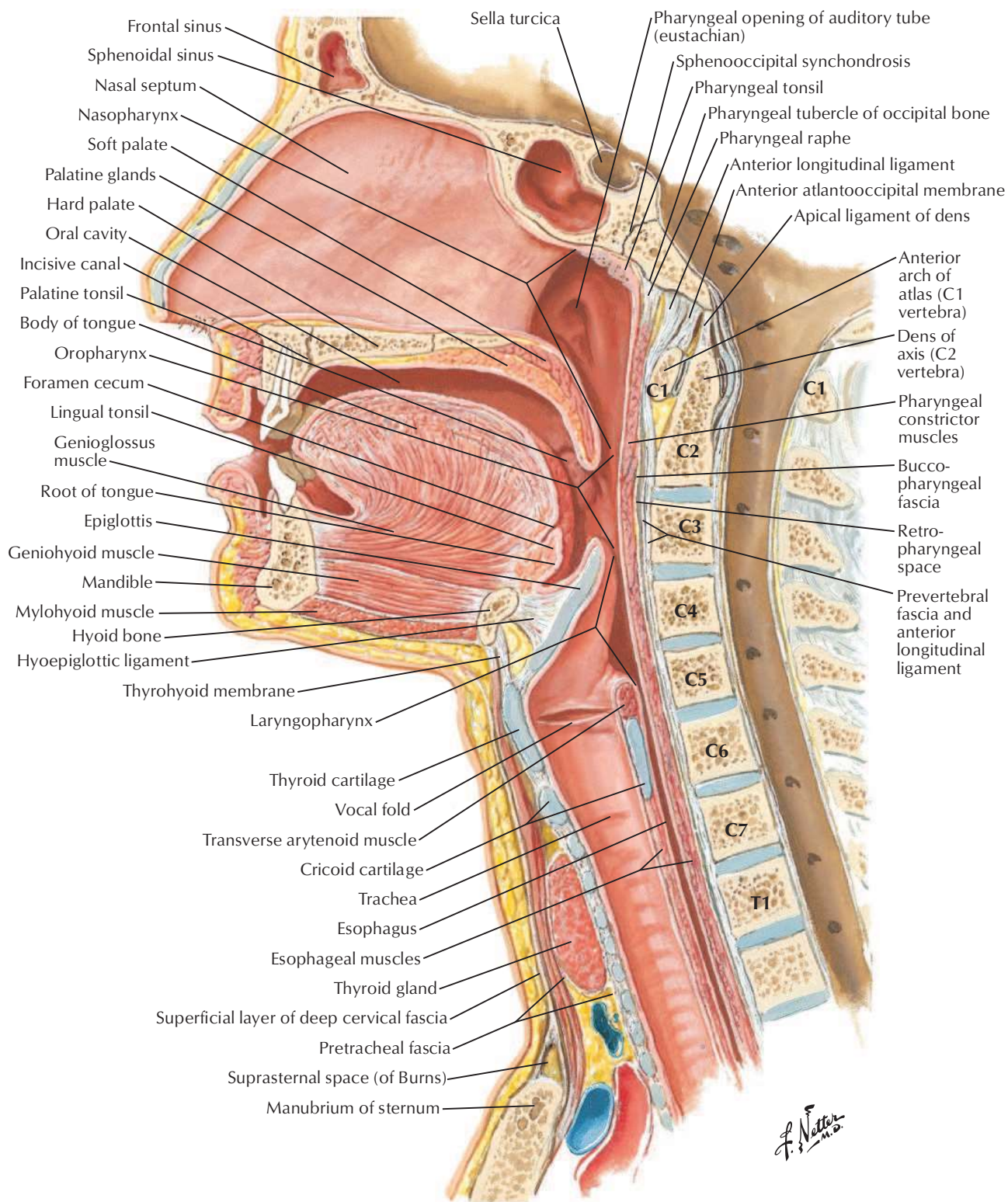
Muscles of Pharynx: Partially Opened Posterior View

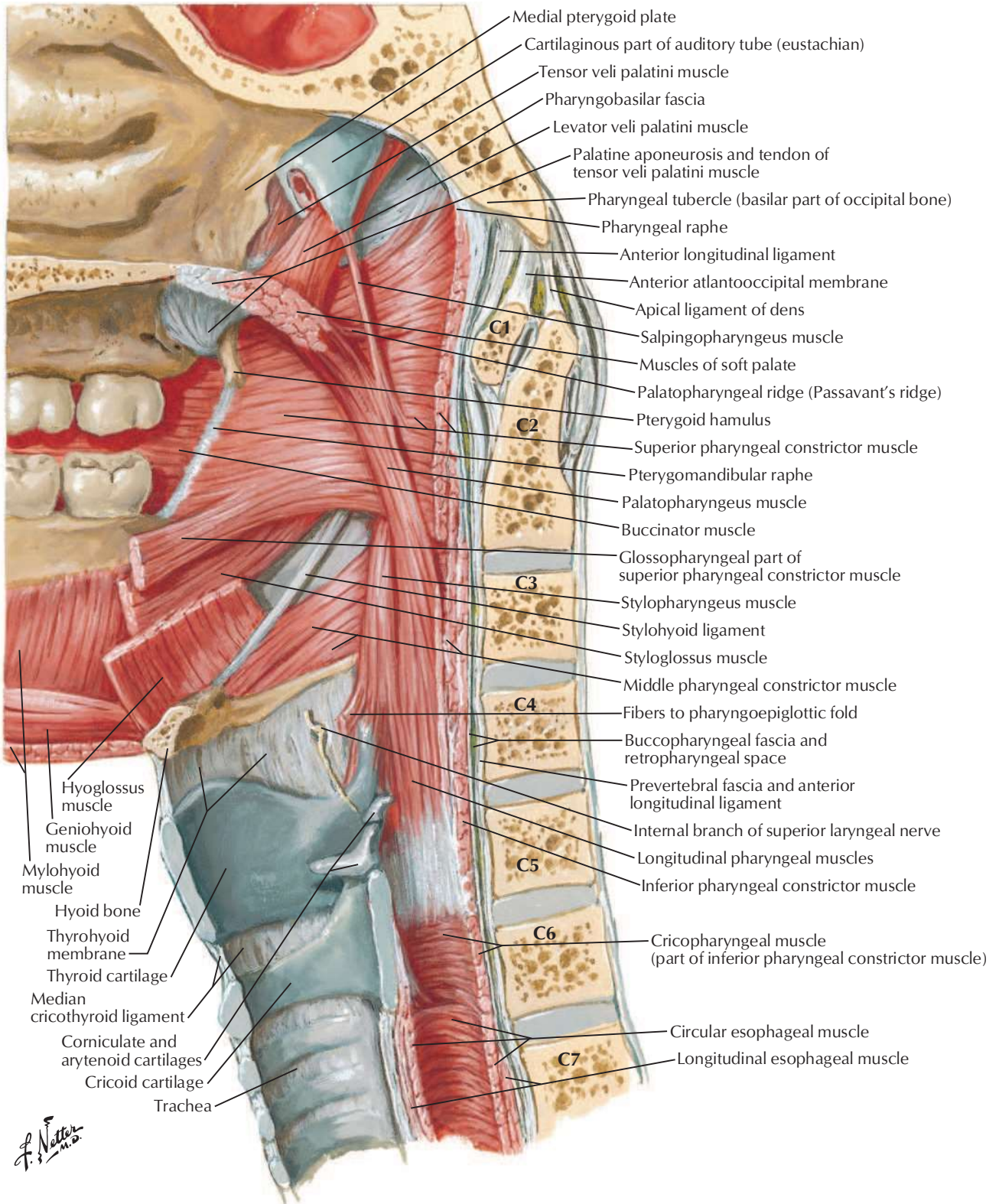
See also [Plates 76, 81](#)



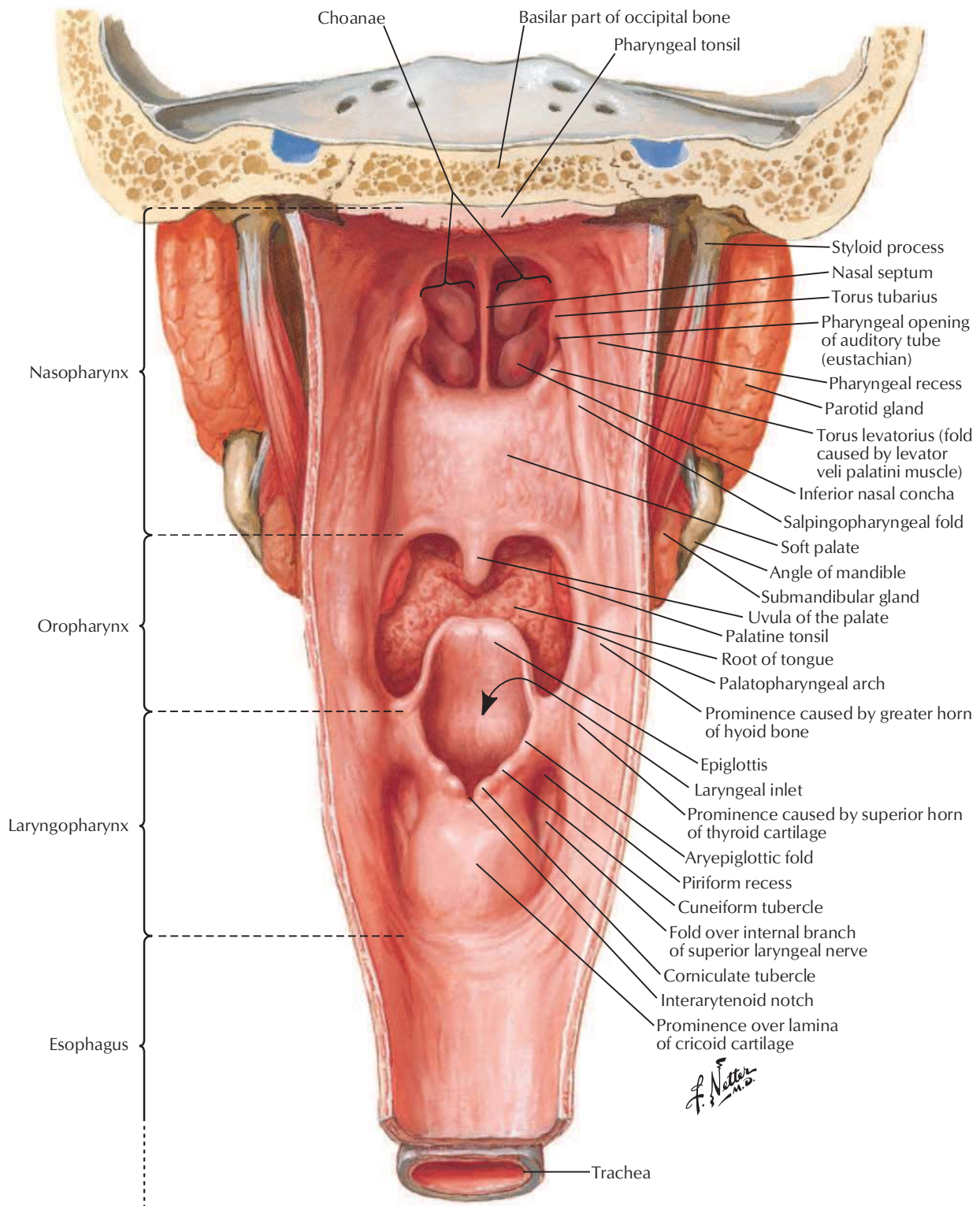
See also [Plates 75, 79, 82, 83](#)

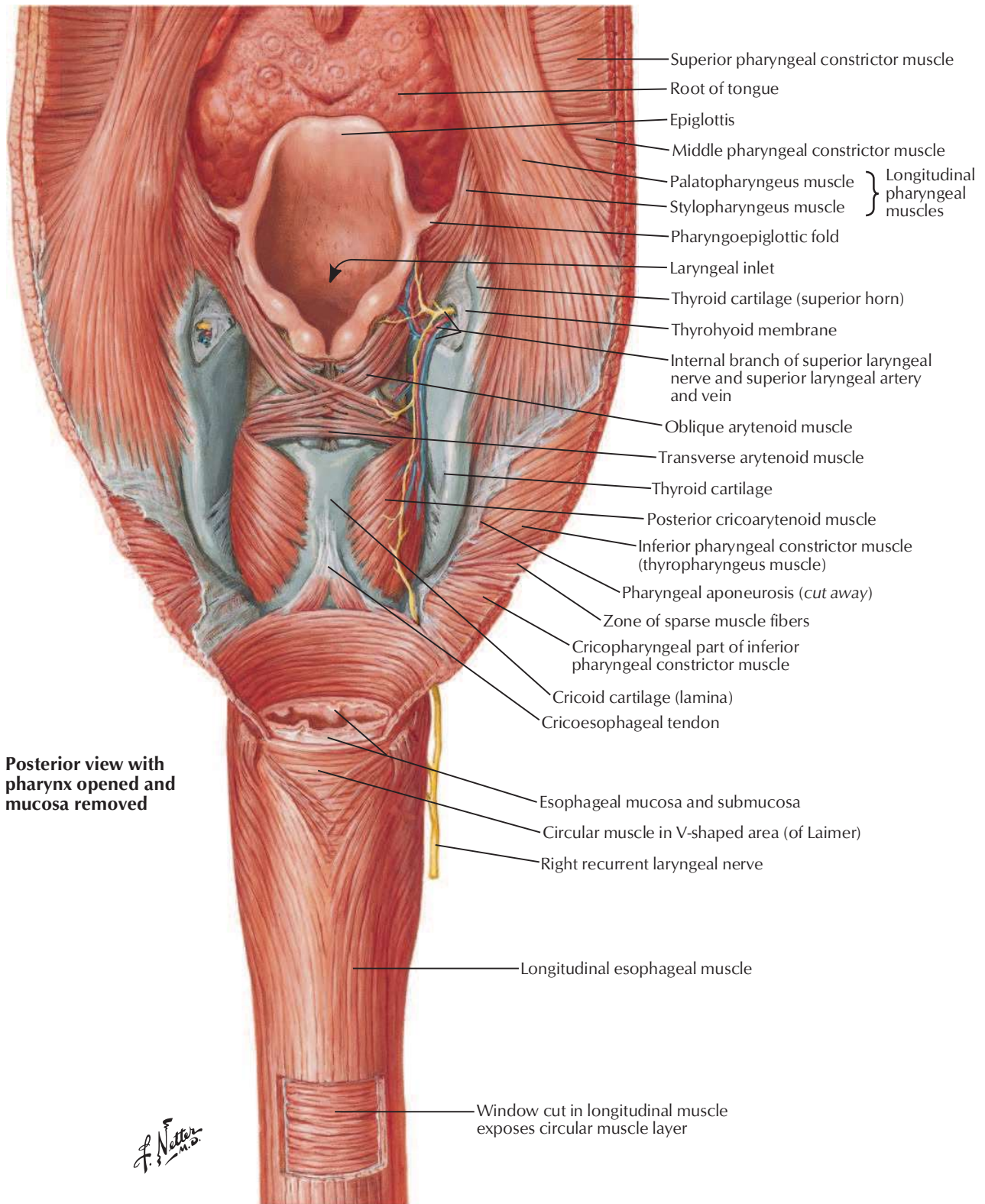






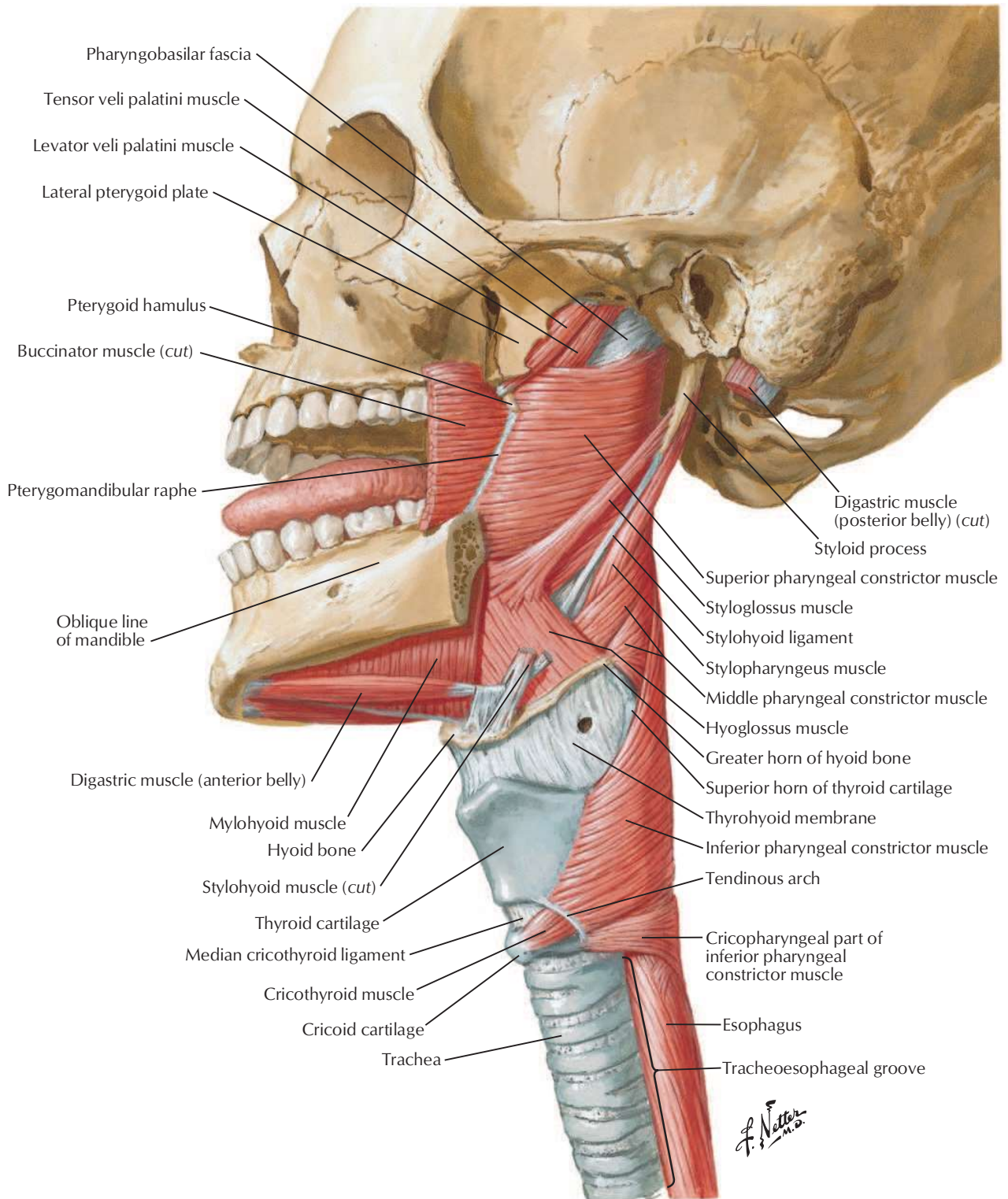
Pharynx: Opened Posterior View

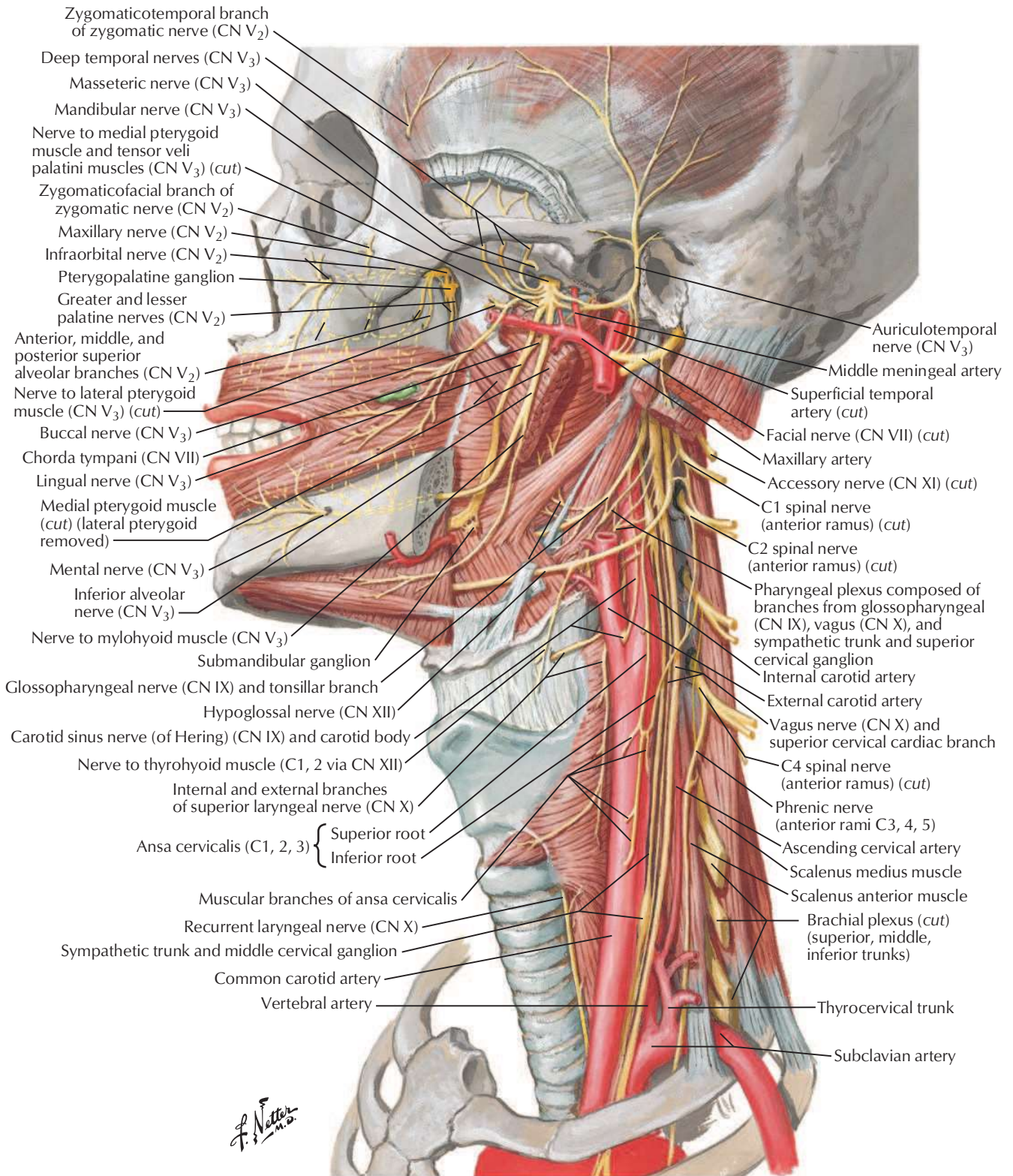




Muscles of Pharynx: Lateral View

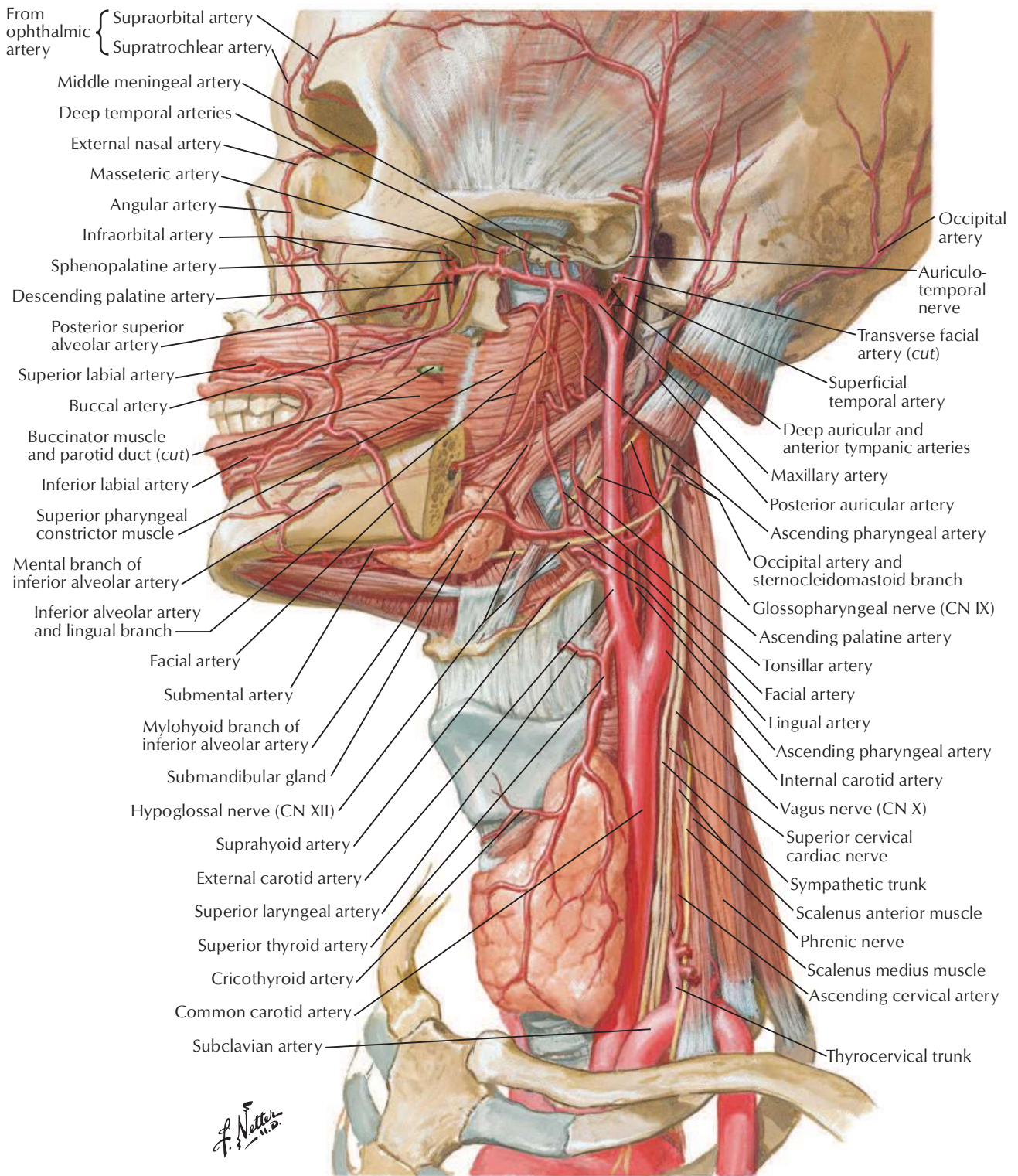
See also [Plate 75](#)

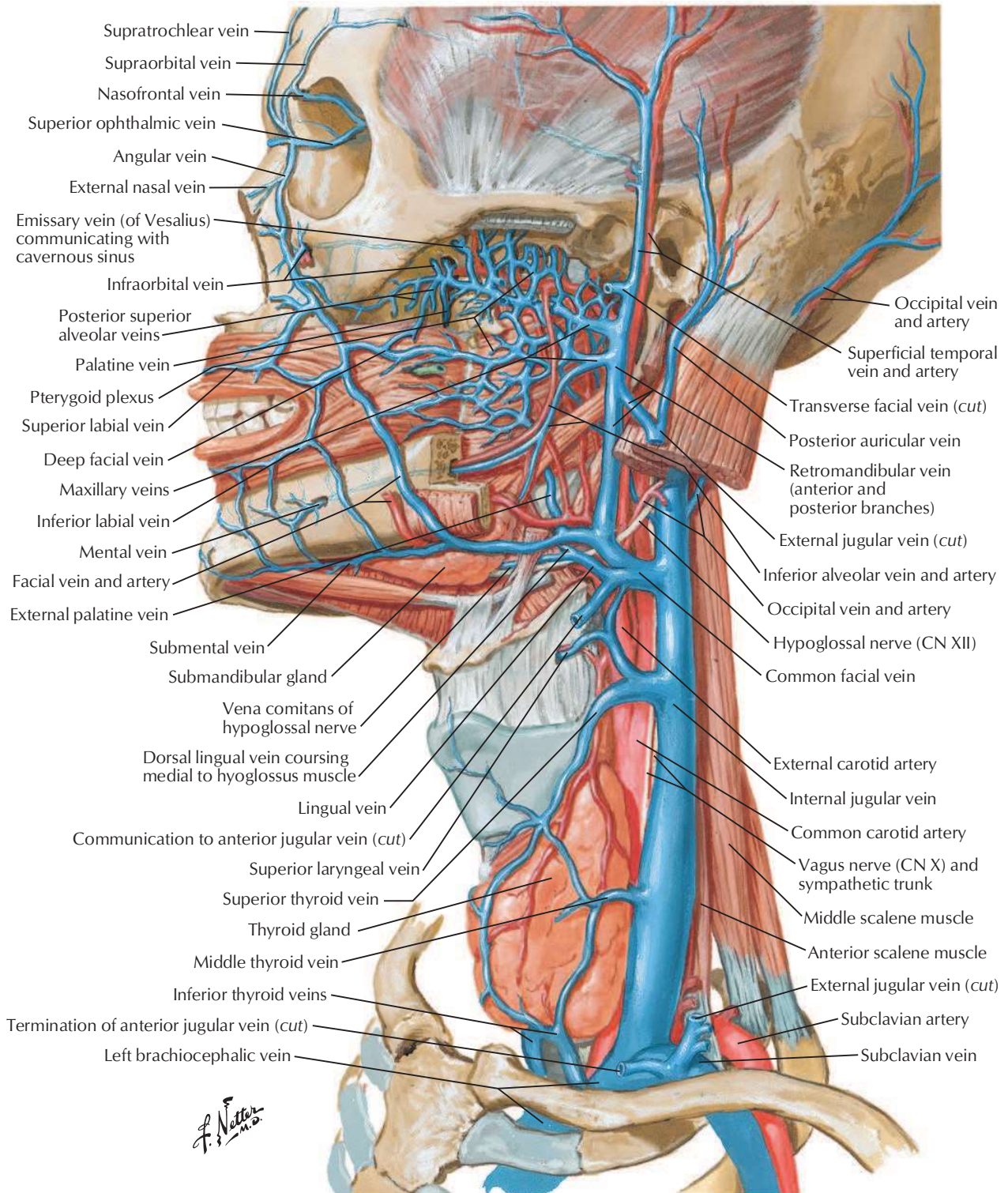


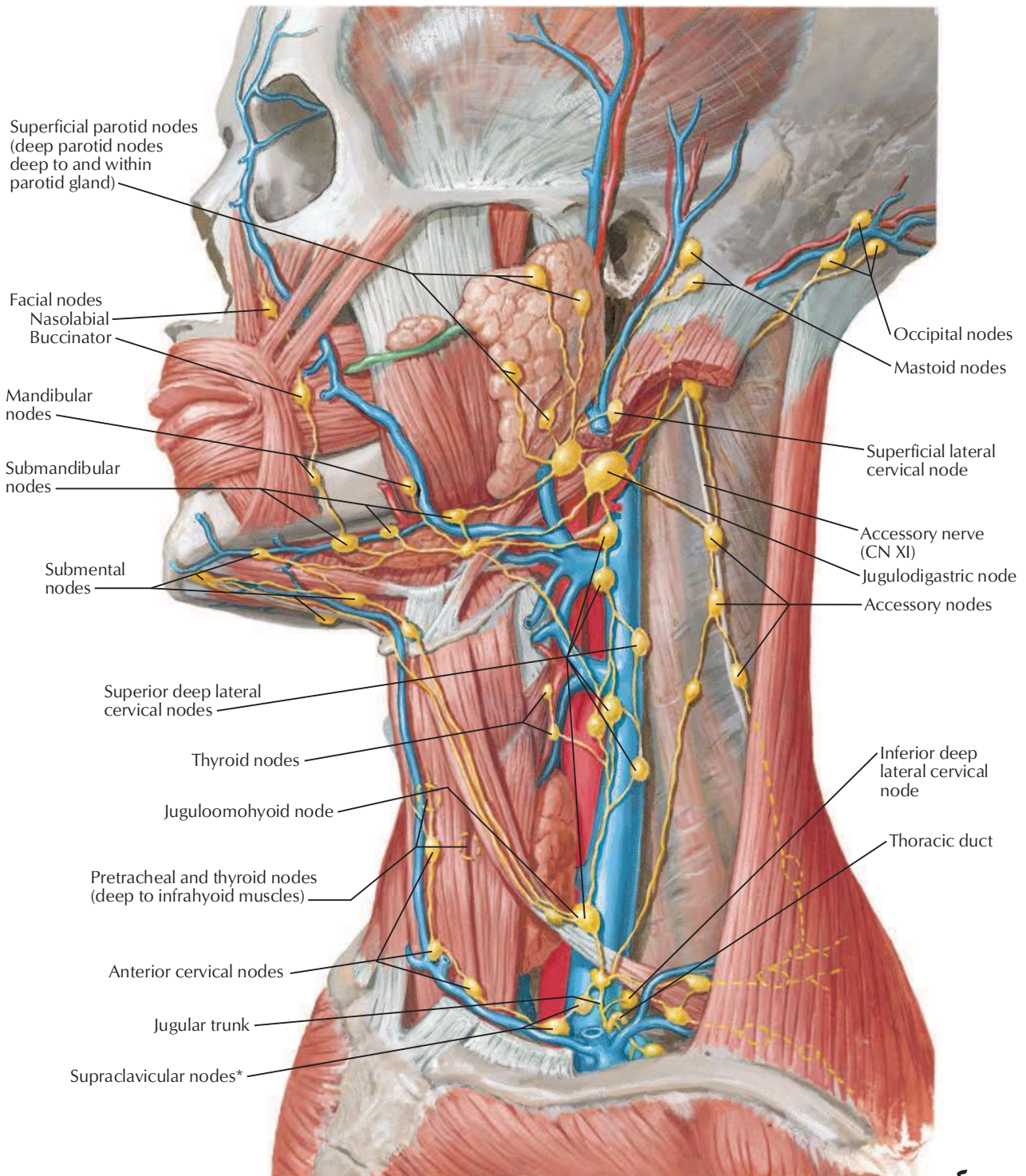


Arteries of Oral and Pharyngeal Regions

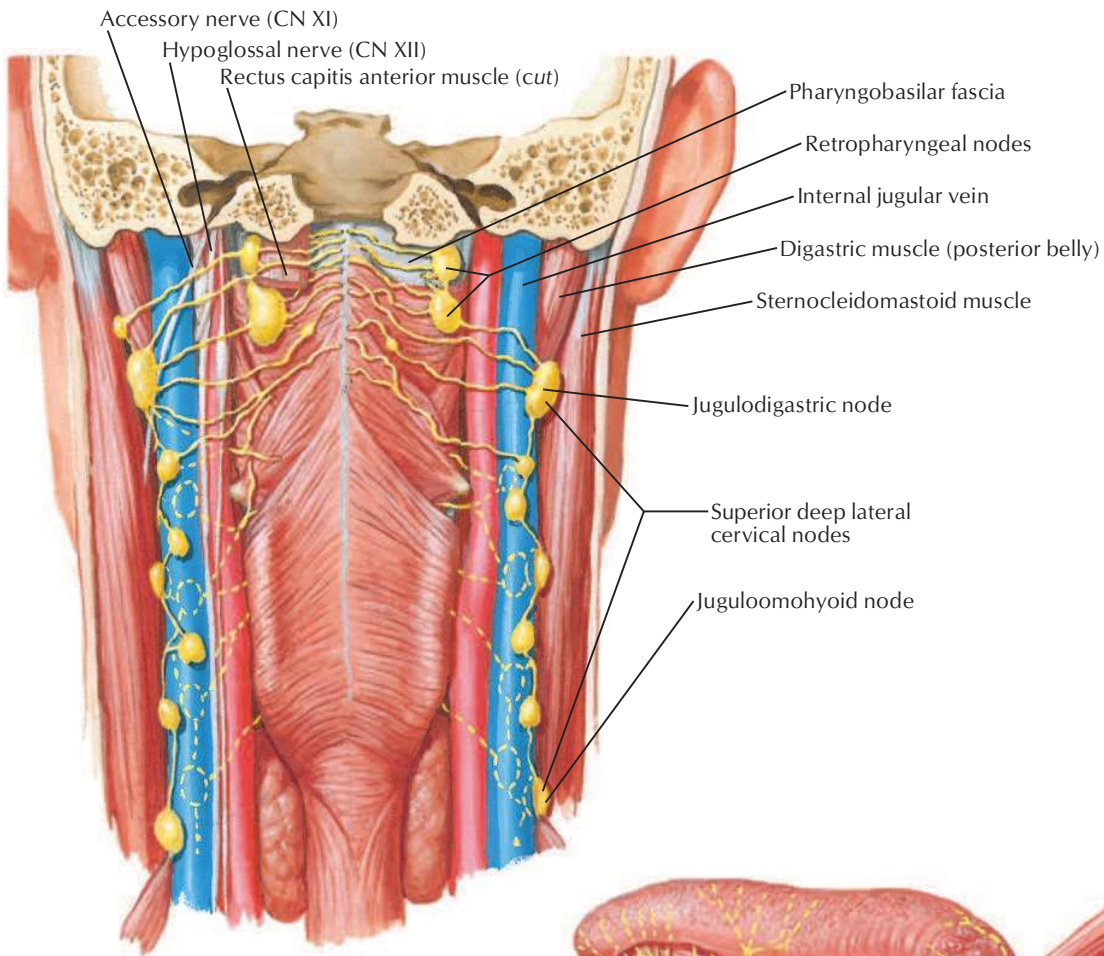
See also [Plates 41, 57](#)



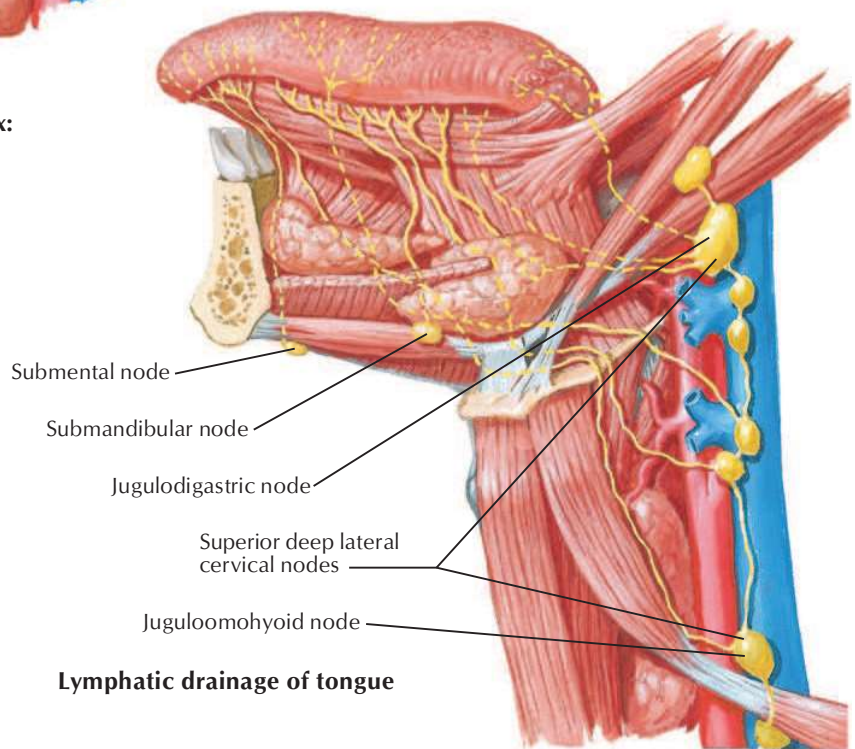




**The supraclavicular group of nodes, especially on the left, are also sometimes referred to as the signal or sentinel lymph nodes of Virchow or Troisier, especially when sufficiently enlarged and palpable. These nodes (or a single node) are so termed because they may be the first recognized presumptive evidence of malignant disease in the viscera.*



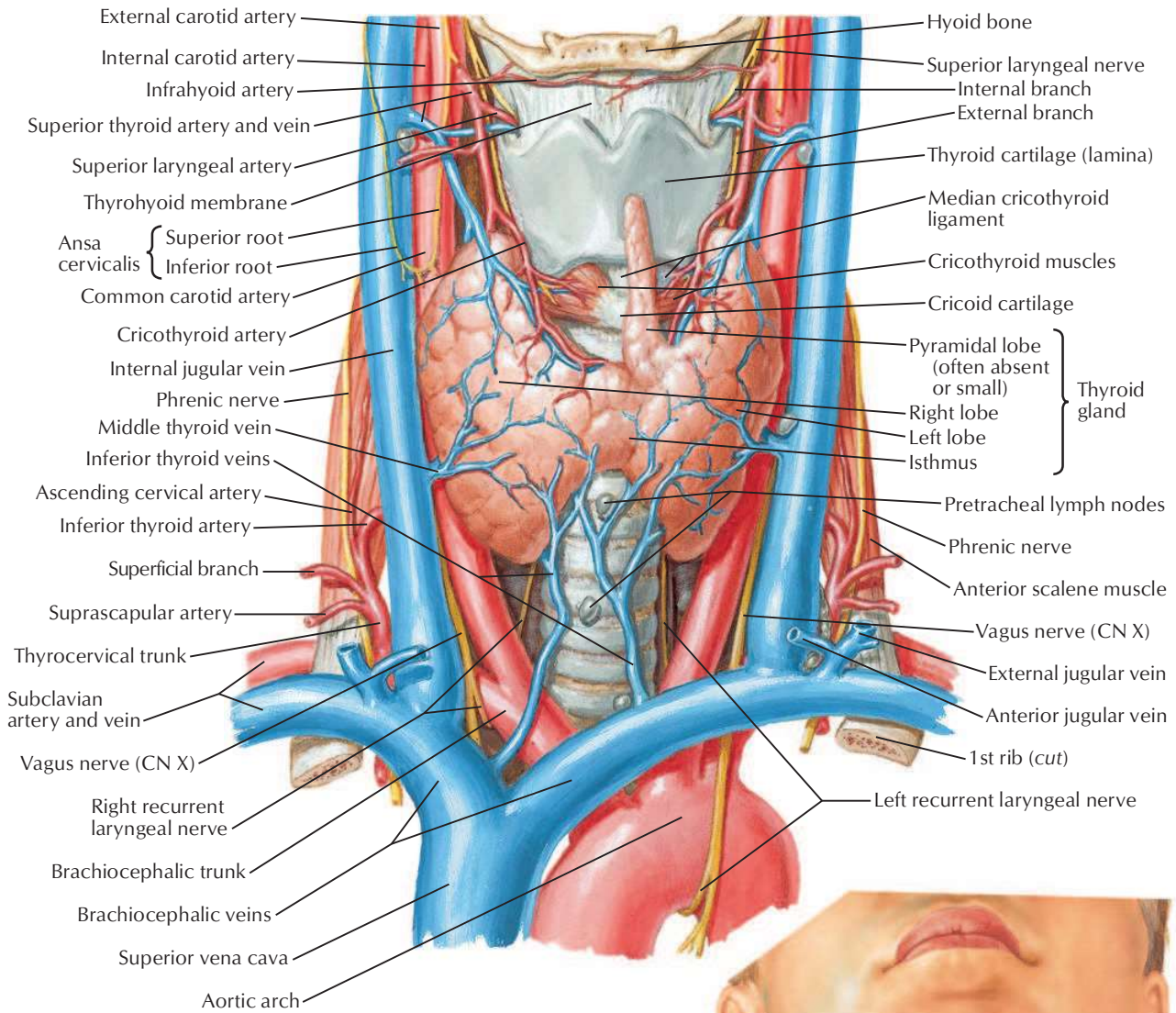
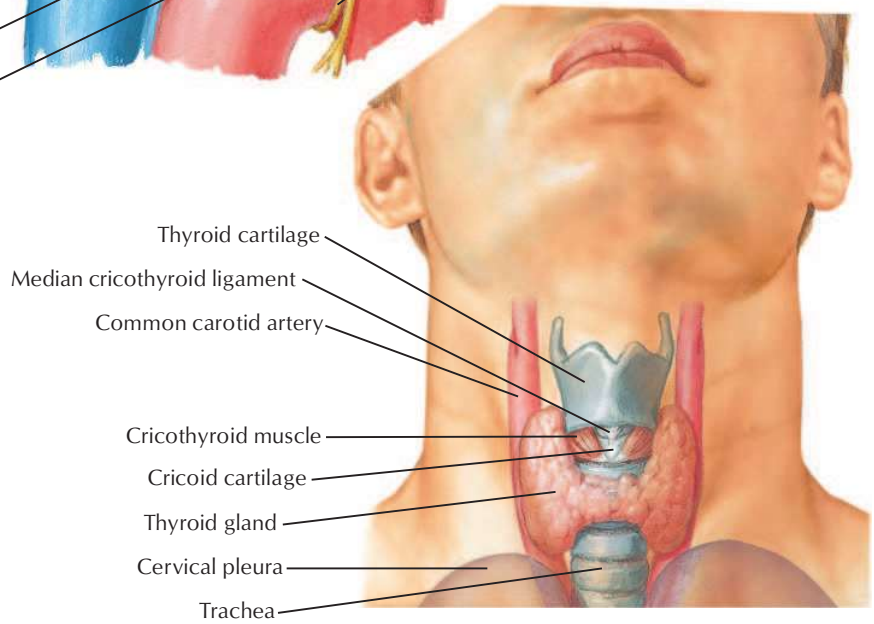
**Lymphatic drainage of pharynx:
 posterior view**

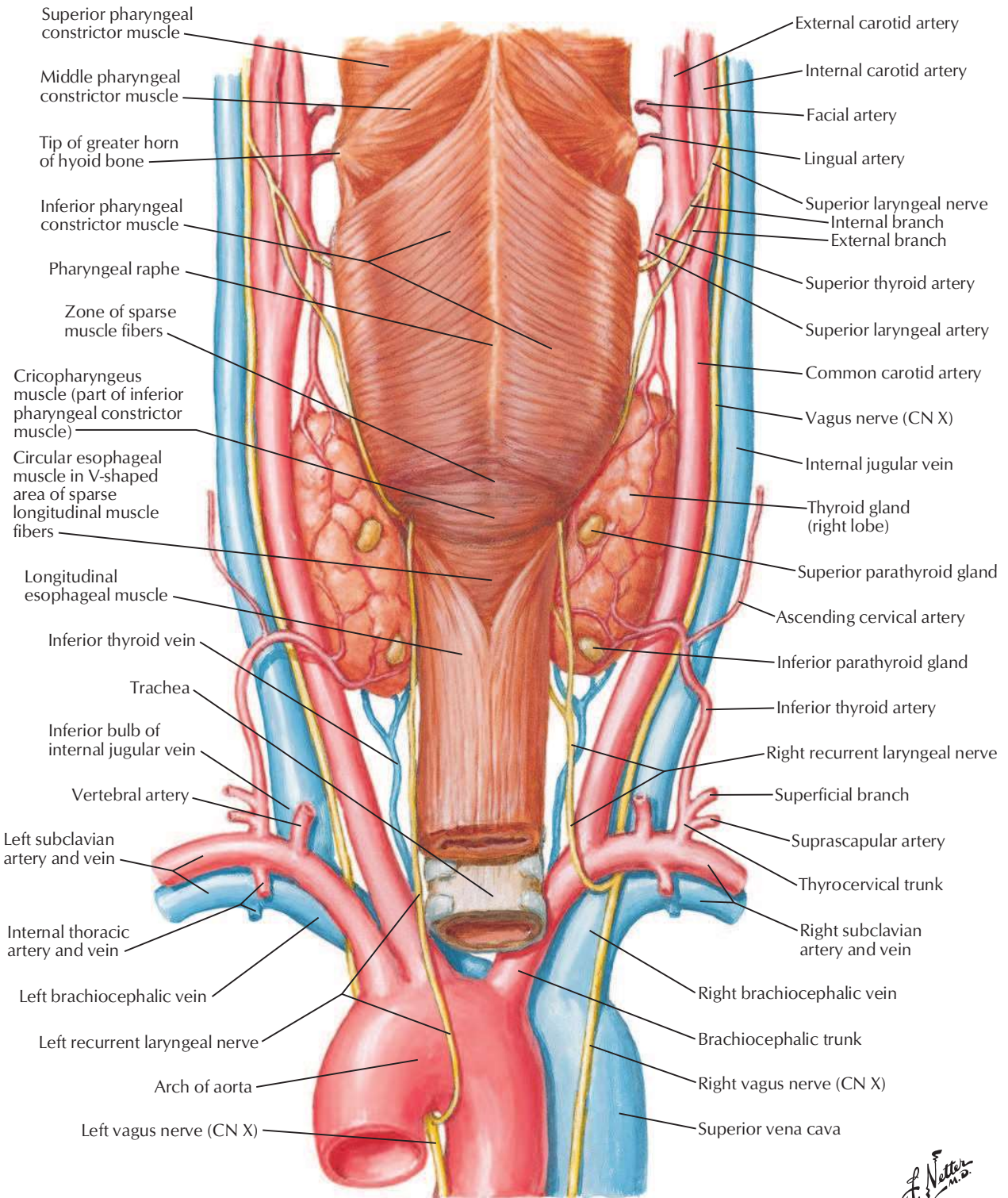


Lymphatic drainage of tongue

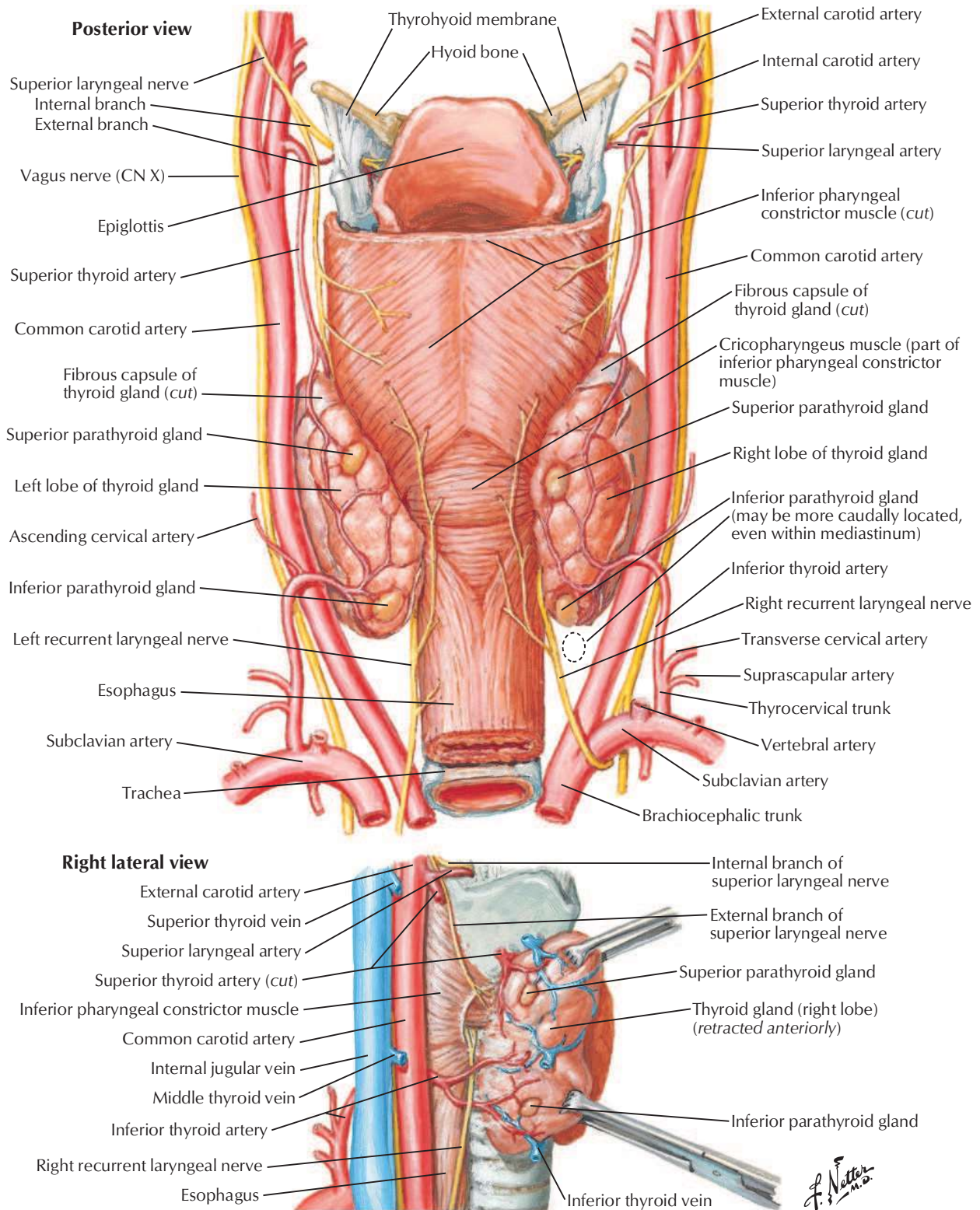
F. Netter M.D.

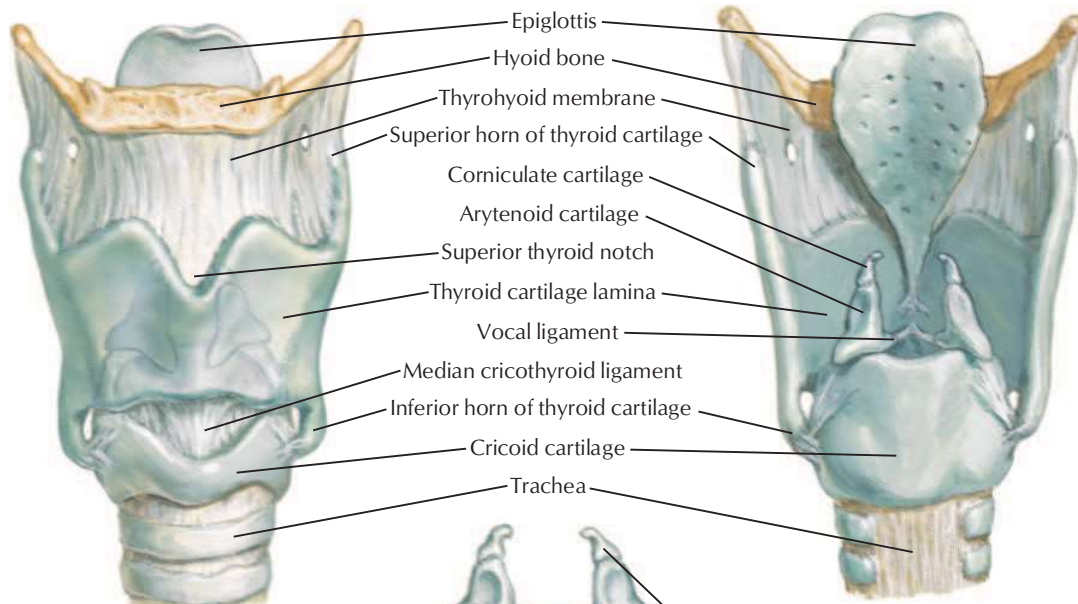
Thyroid Gland: Anterior View



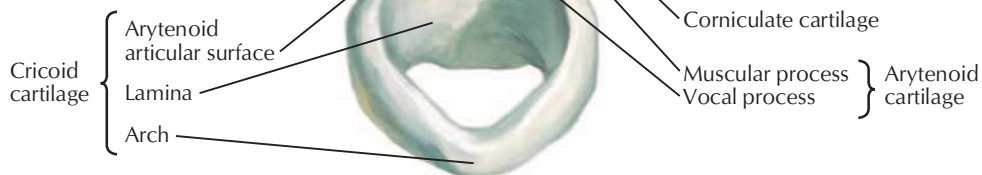F. Netter M.D.



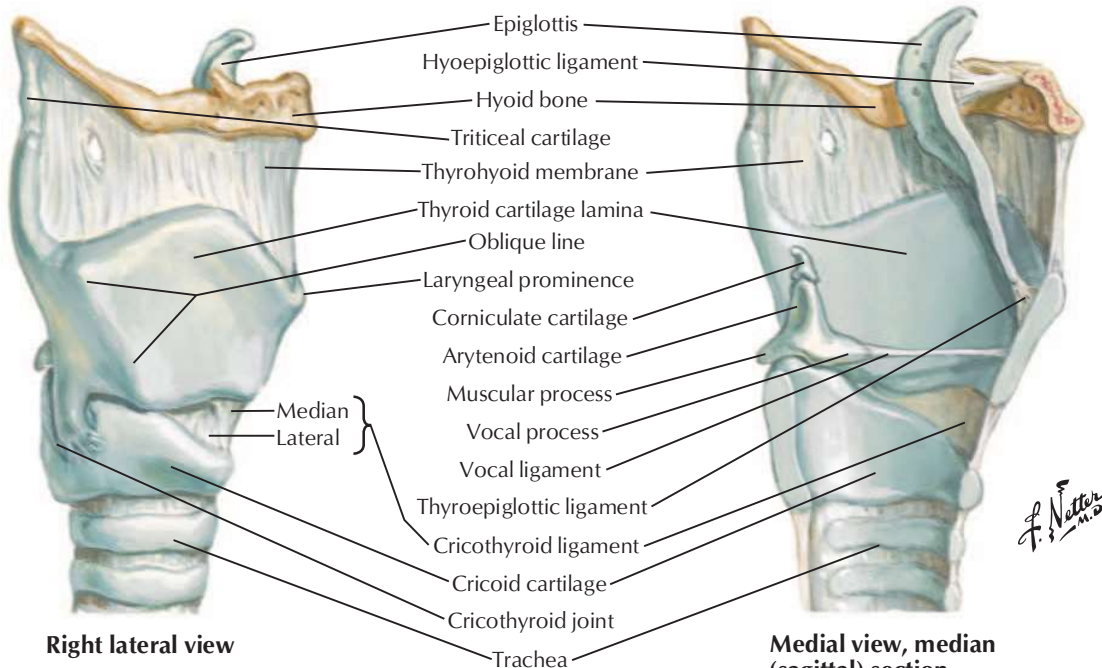


Anterior view

Posterior view



Anterosuperior view



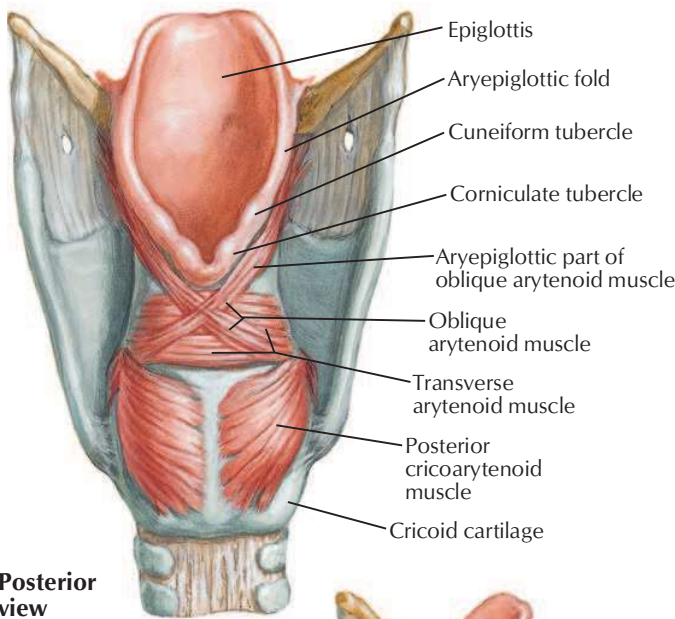
Right lateral view

Medial view, median (sagittal) section

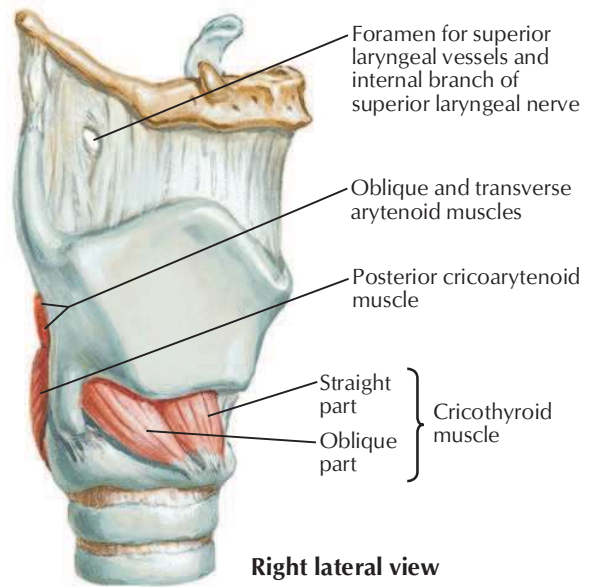
F. Netter M.D.

Intrinsic Muscles of Larynx

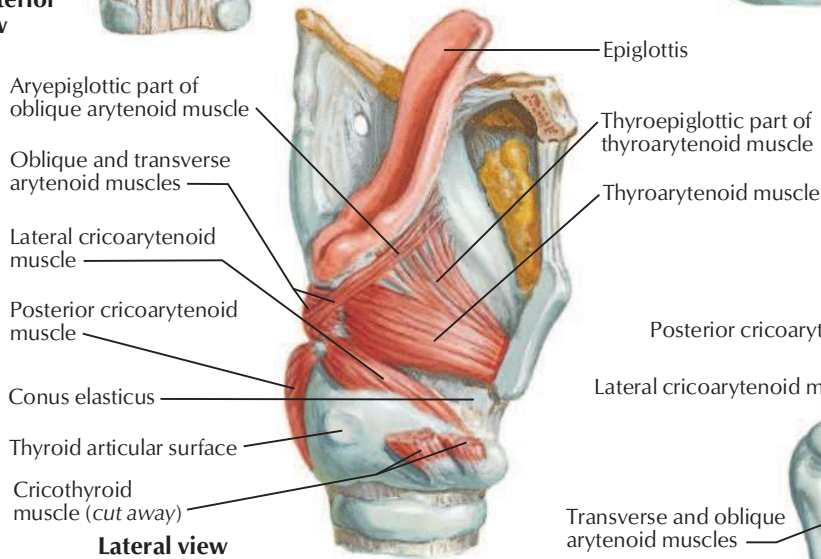
See also [Plates 90, 92, 93](#)



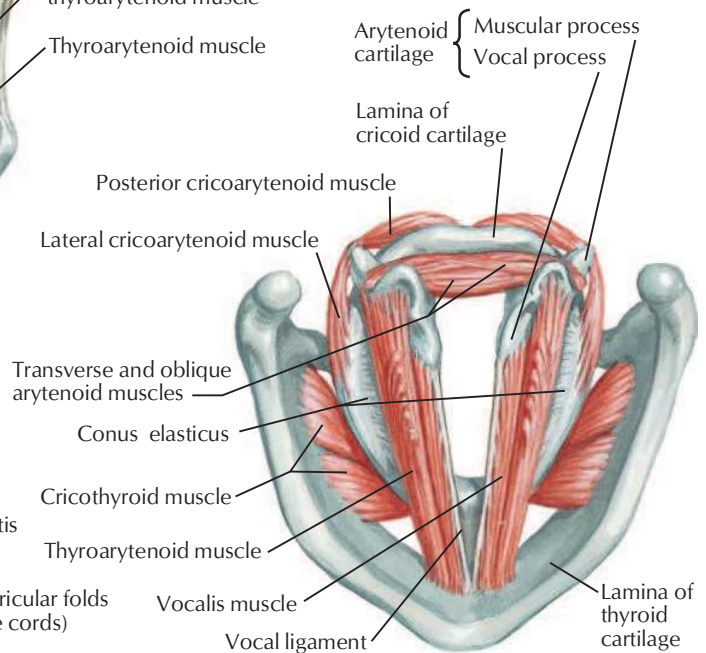
Posterior view



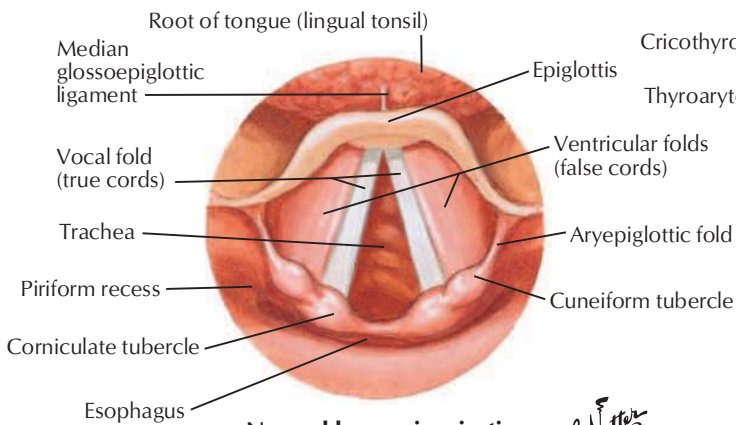
Right lateral view



Lateral view

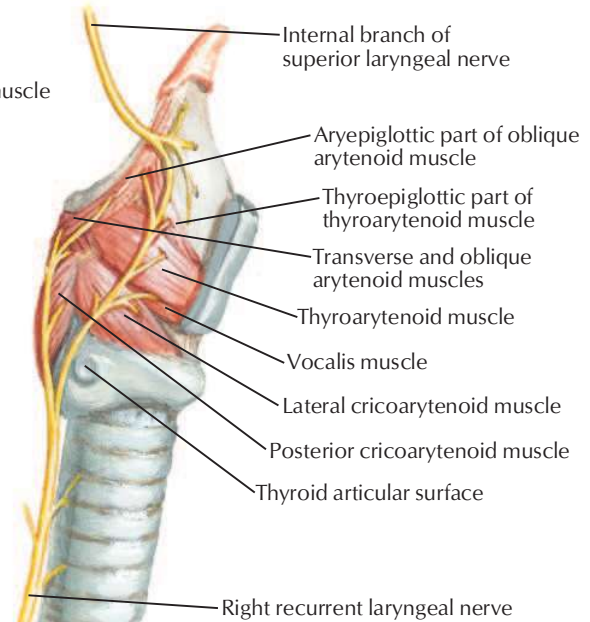
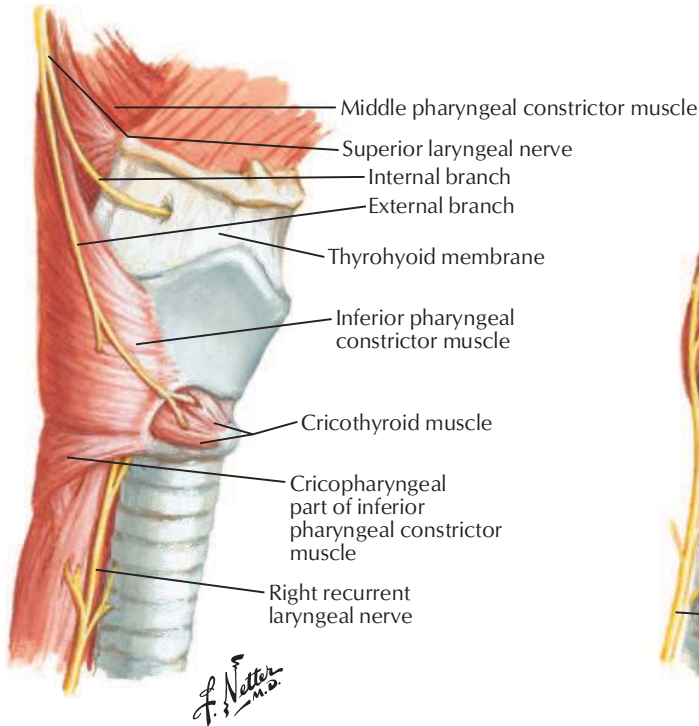


Superior view

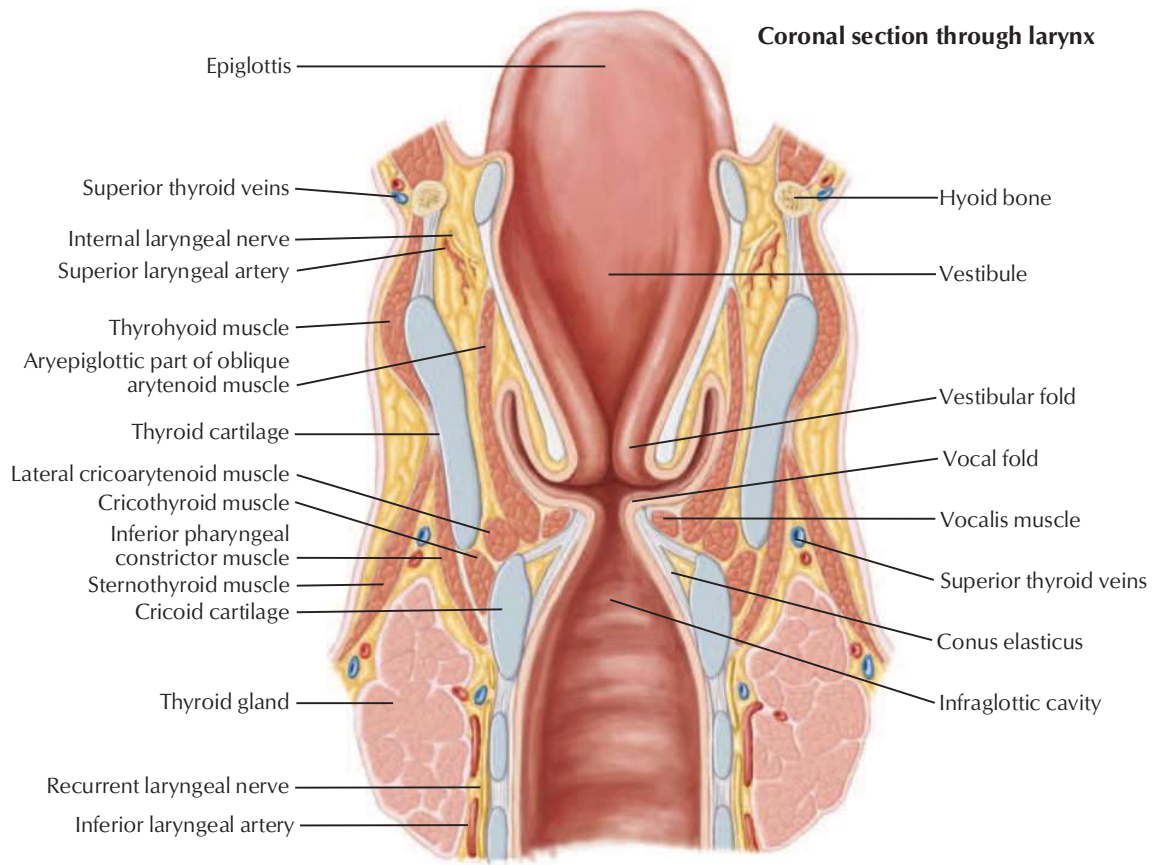


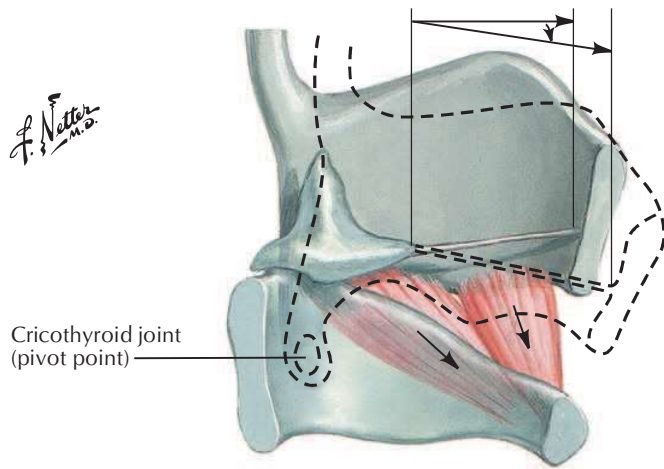
Normal larynx: inspiration

See also Plates 90, 91, 93



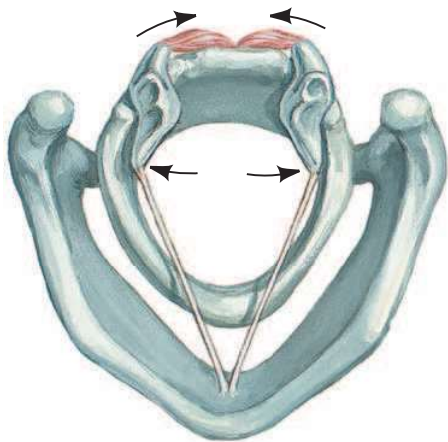
Right lateral view:
thyroid cartilage lamina removed



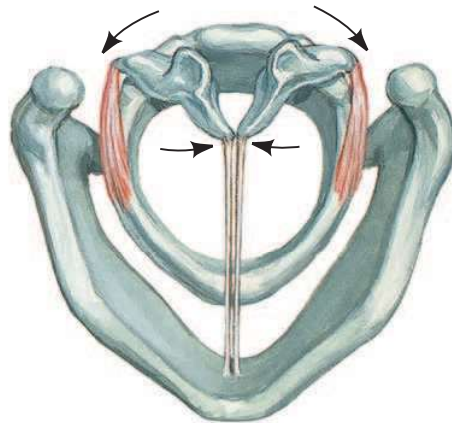


Cricothyroid joint (pivot point)

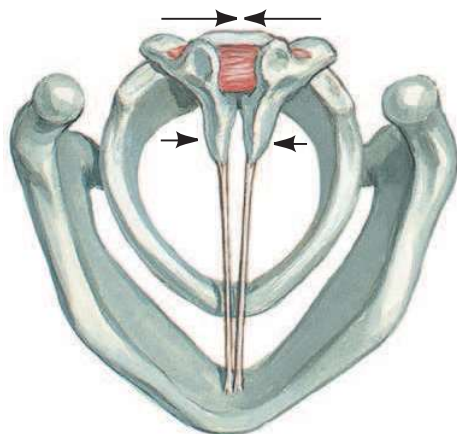
Action of cricothyroid muscles
Lengthening (increasing tension) of vocal ligaments



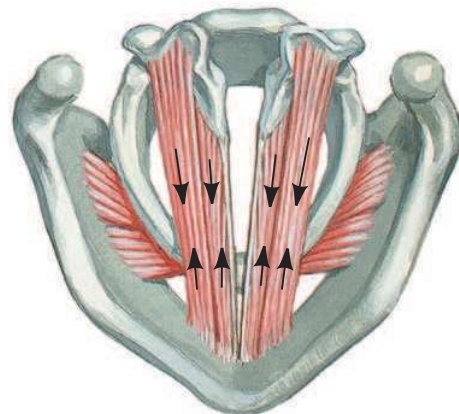
Action of posterior cricoarytenoid muscles
Abduction of vocal ligaments



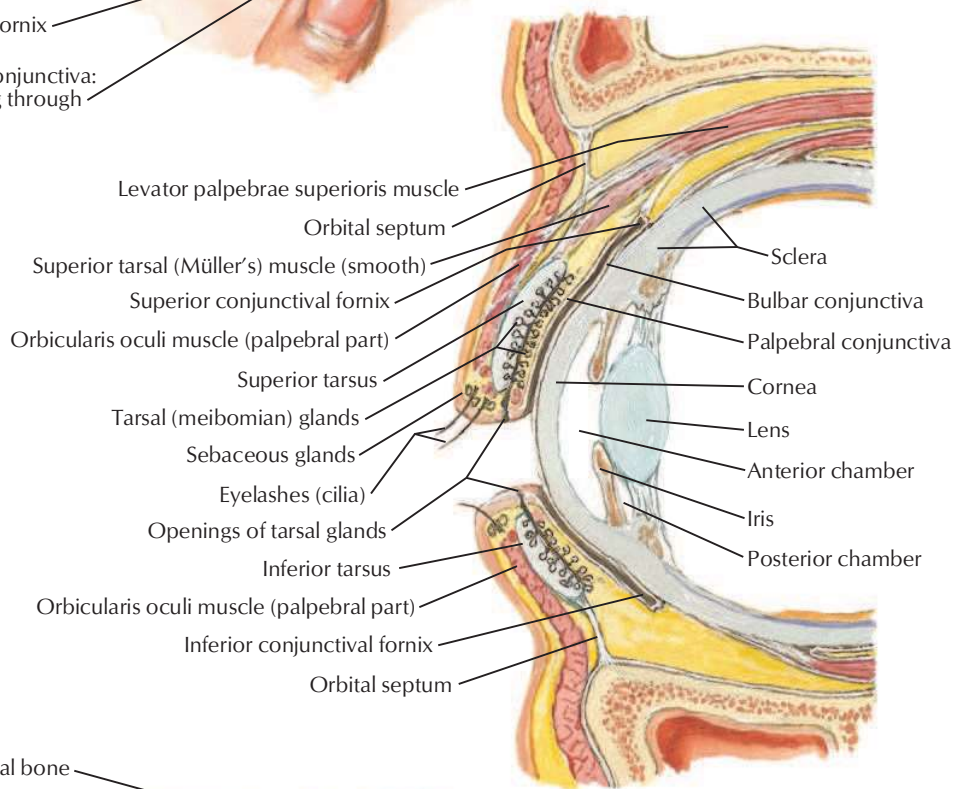
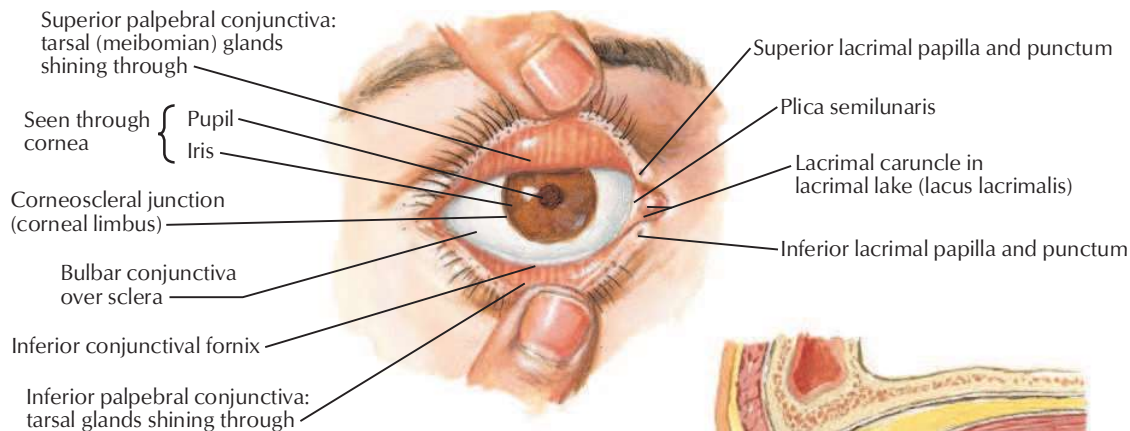
Action of lateral cricoarytenoid muscles
Adduction of vocal ligaments



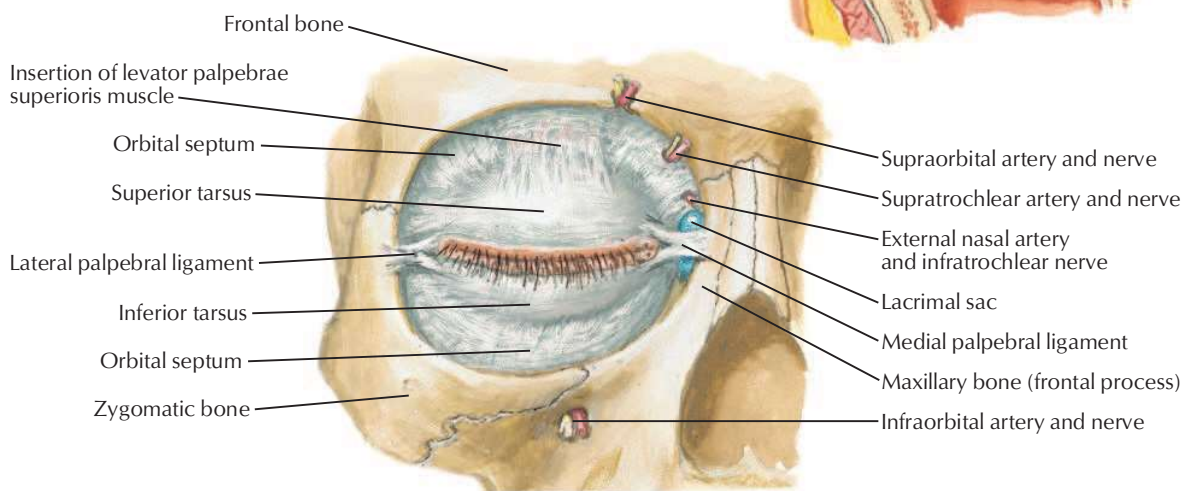
Action of transverse and oblique arytenoid muscles
Adduction of vocal ligaments



Action of vocalis and thyroarytenoid muscles
Shortening (relaxation) of vocal ligaments

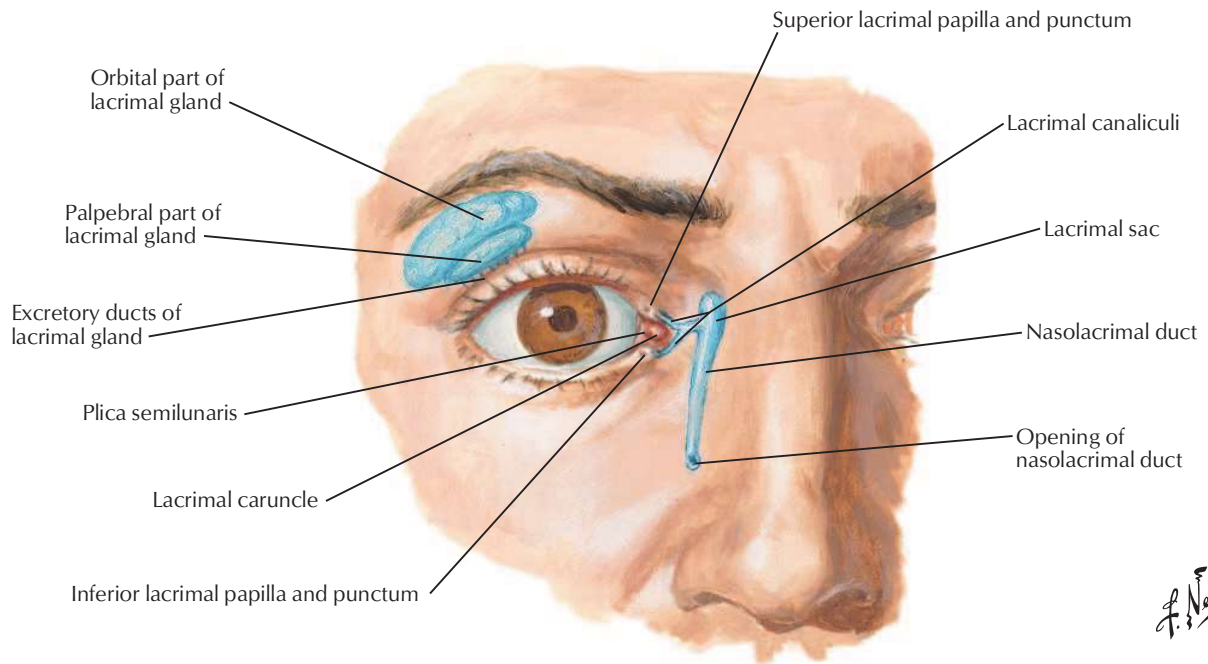


F. Netter M.D.

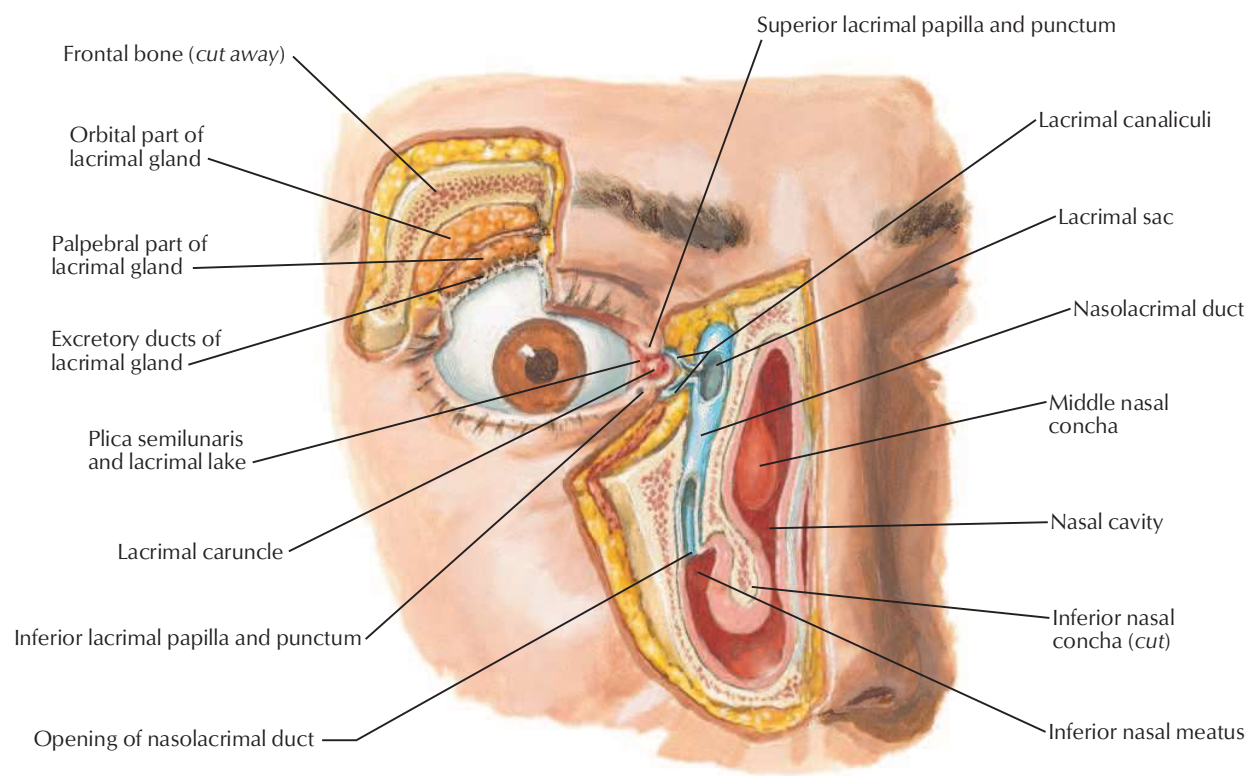


Lacrimal Apparatus

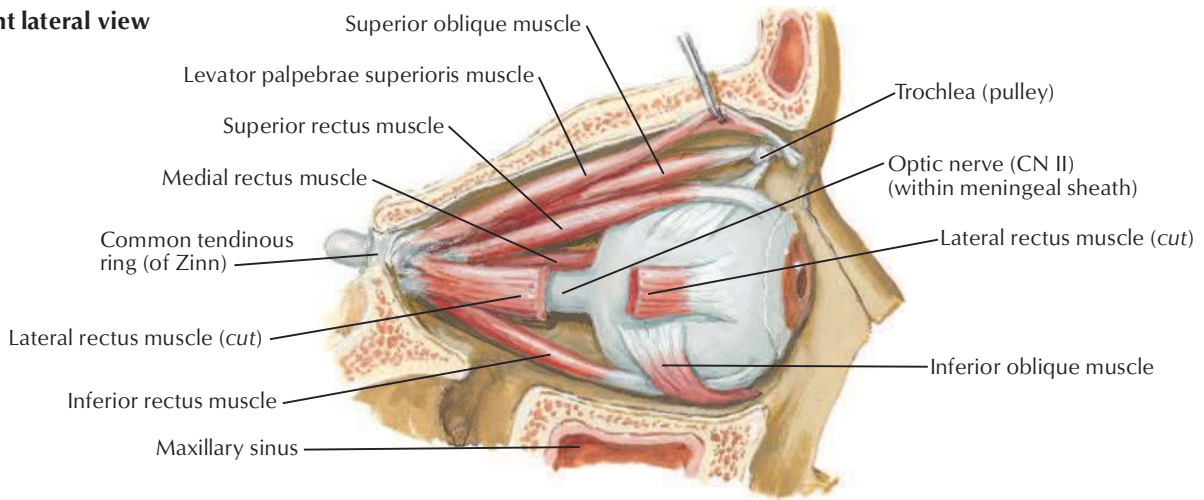
See also [Plate 144](#)



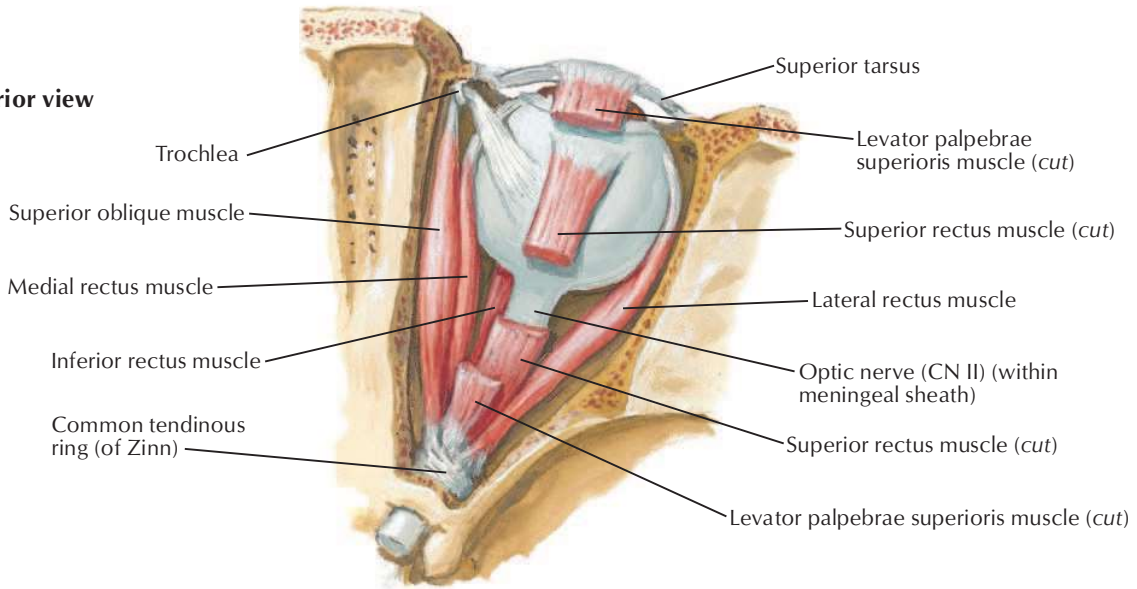
F. Netter M.D.



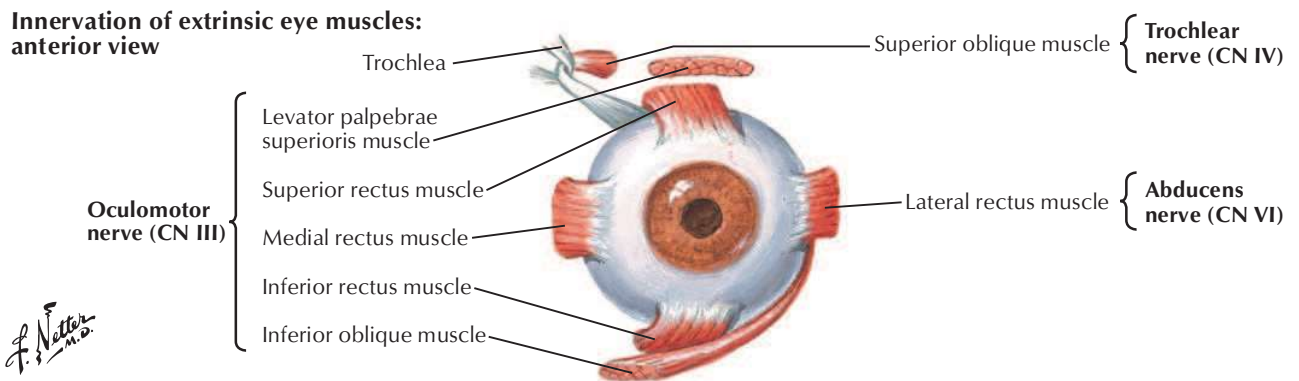
Right lateral view



Superior view

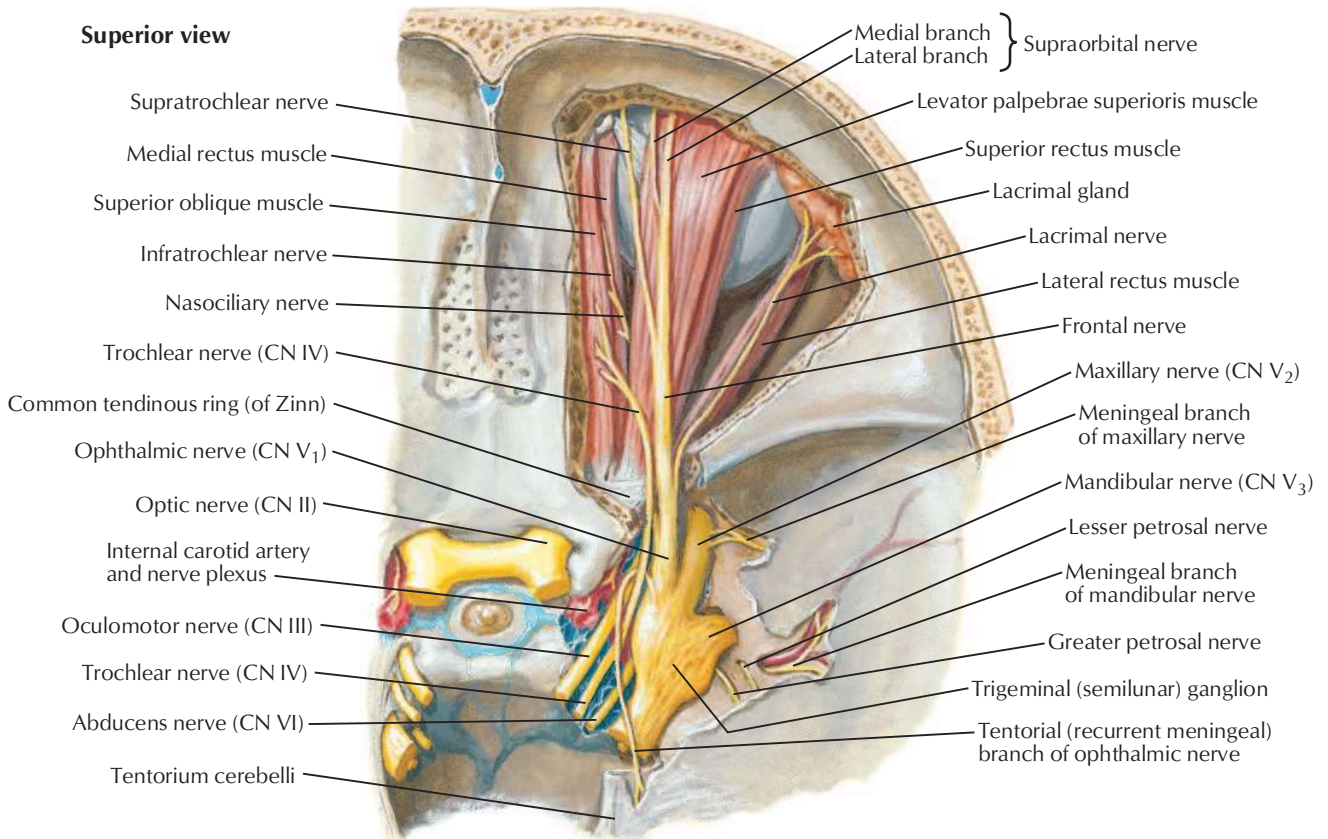


Innervation of extrinsic eye muscles: anterior view

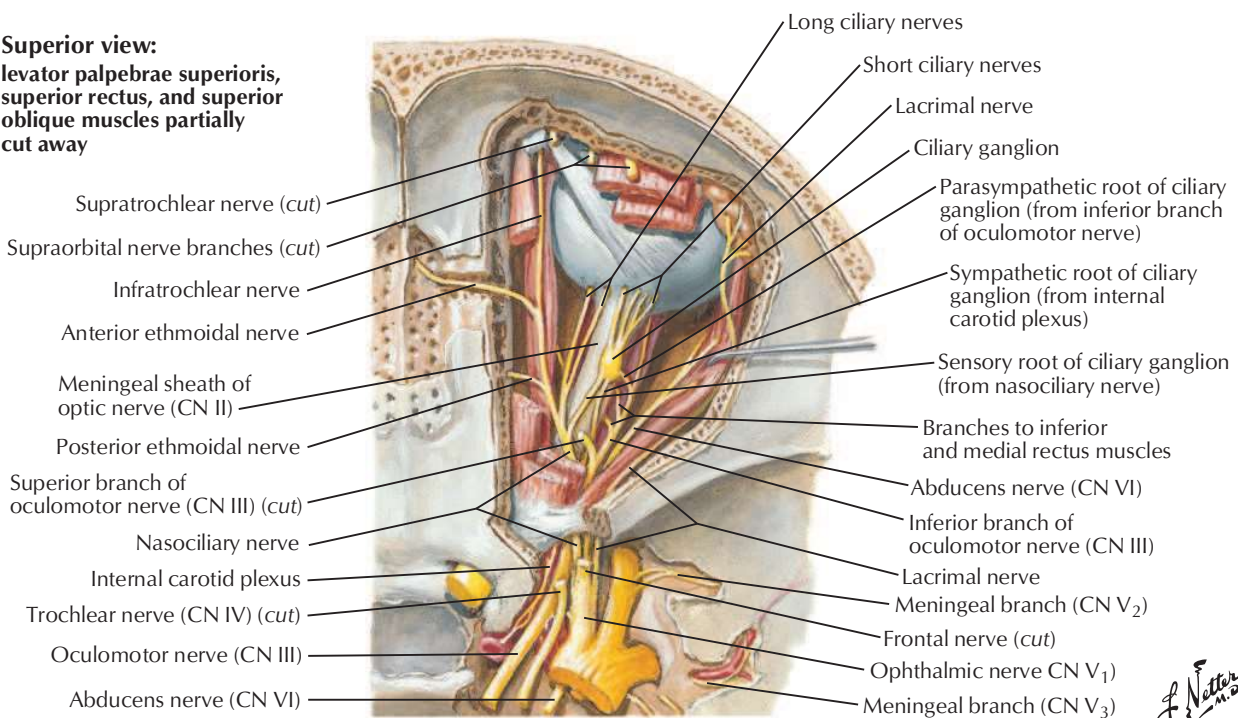


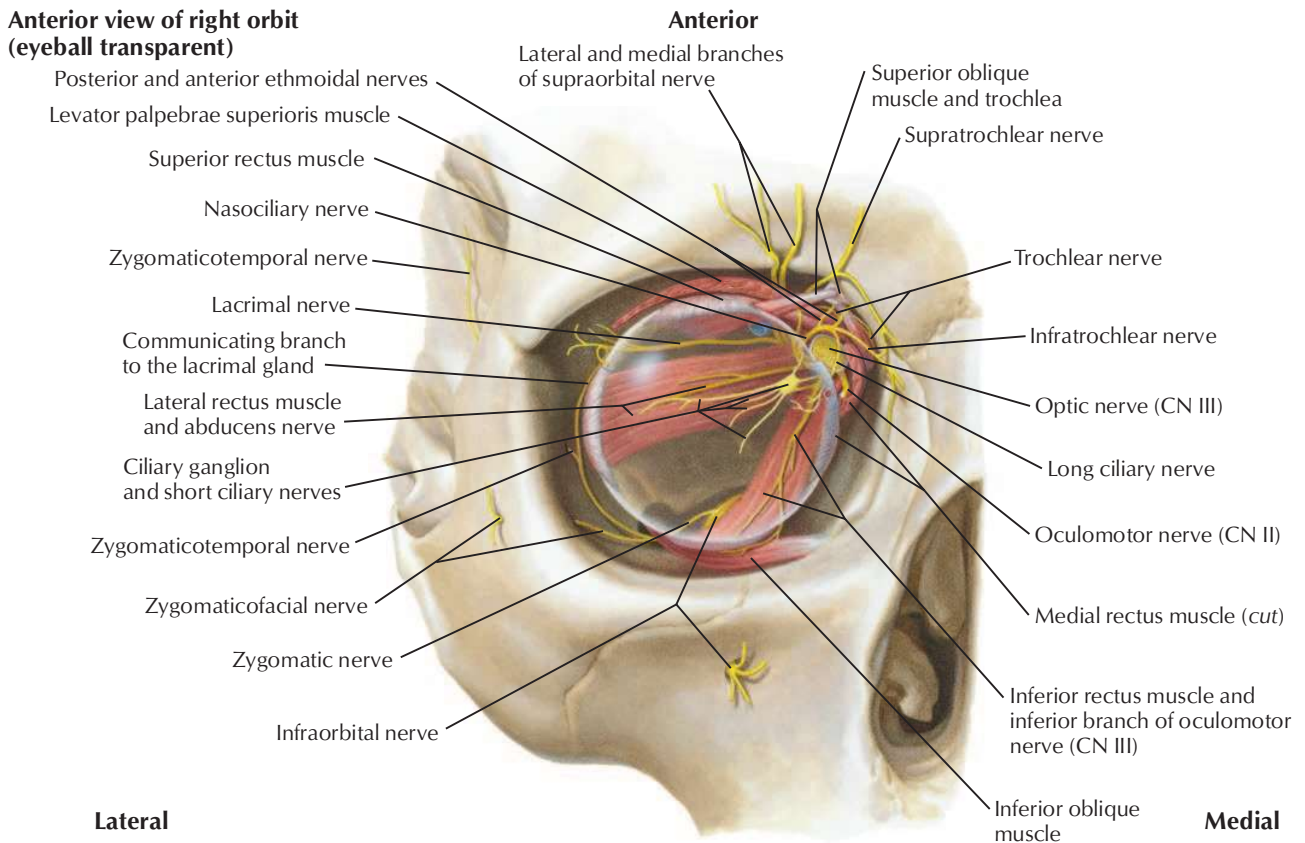
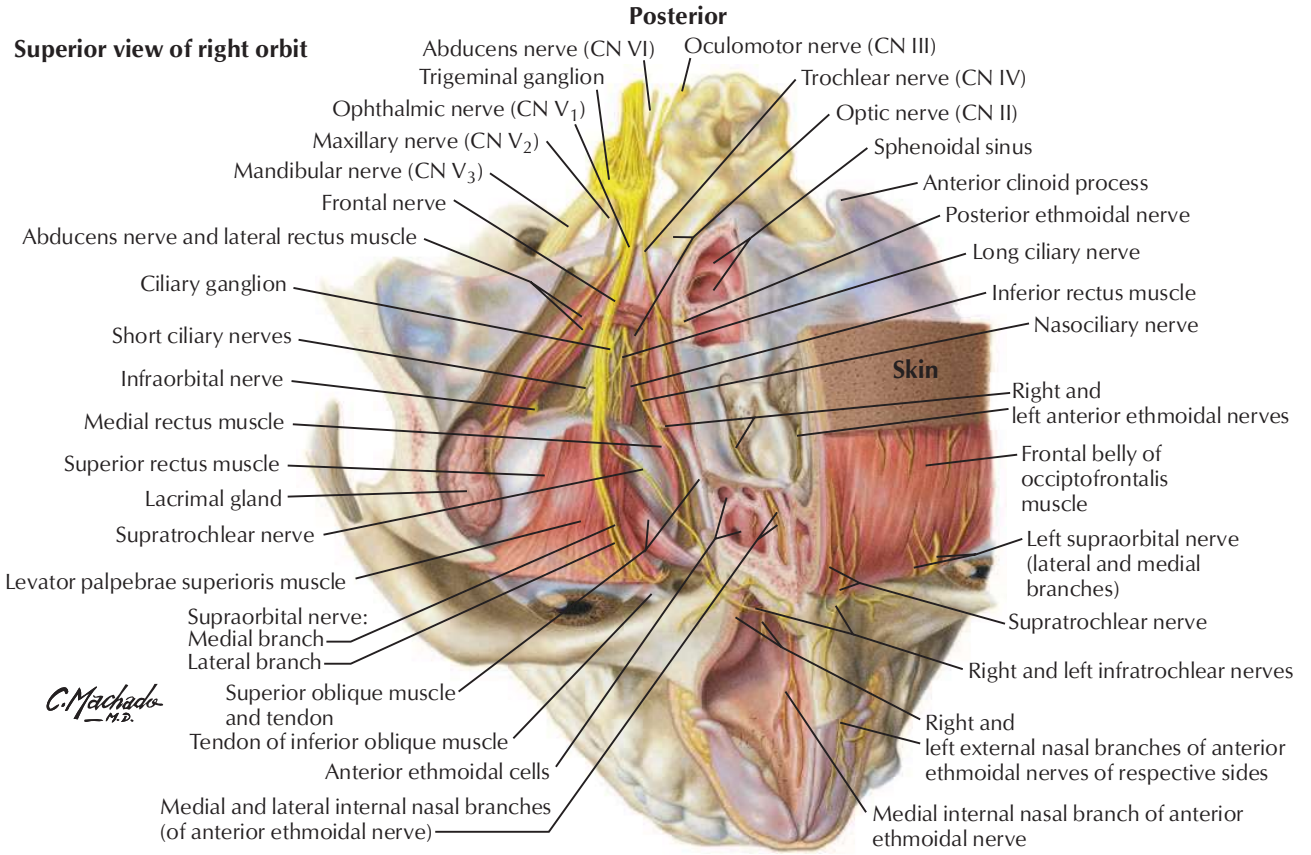
F. Netter M.D.

Superior view



Superior view: levator palpebrae superioris, superior rectus, and superior oblique muscles partially cut away

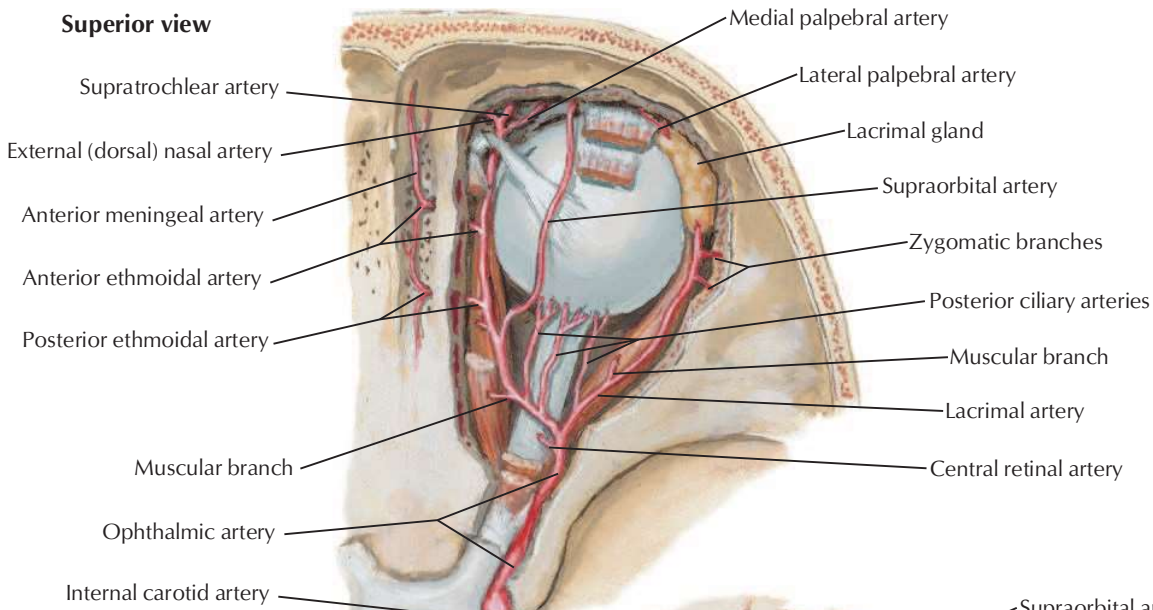




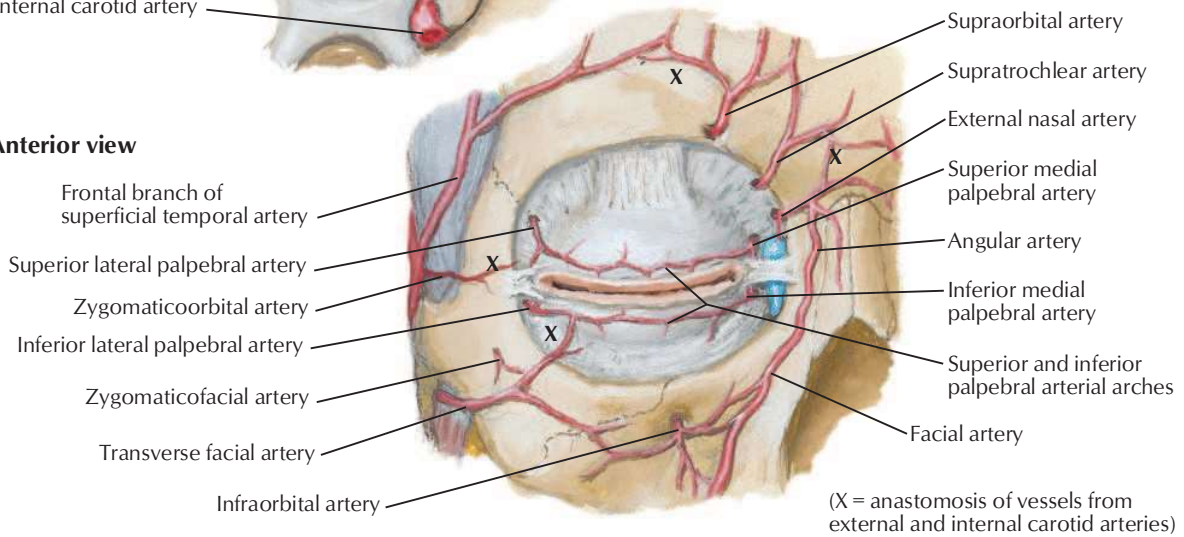
Arteries and Veins of Orbit and Eyelids

See also **Plates 10, 84**

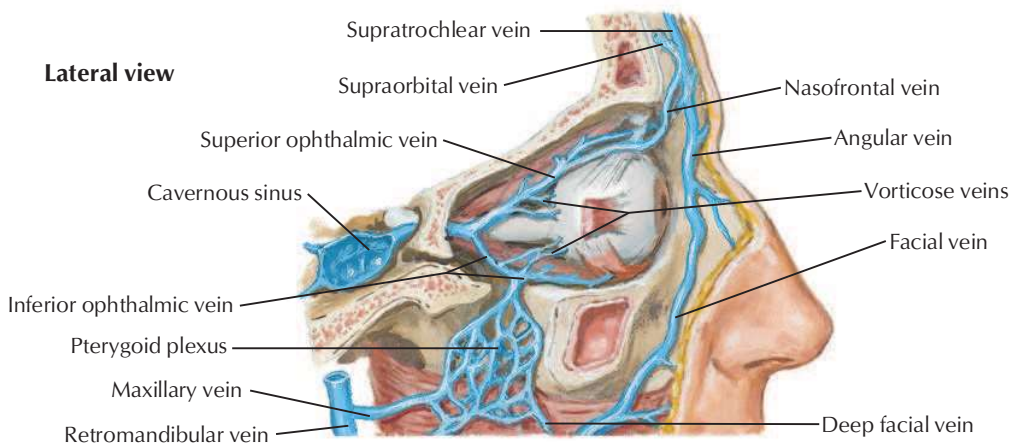
Superior view

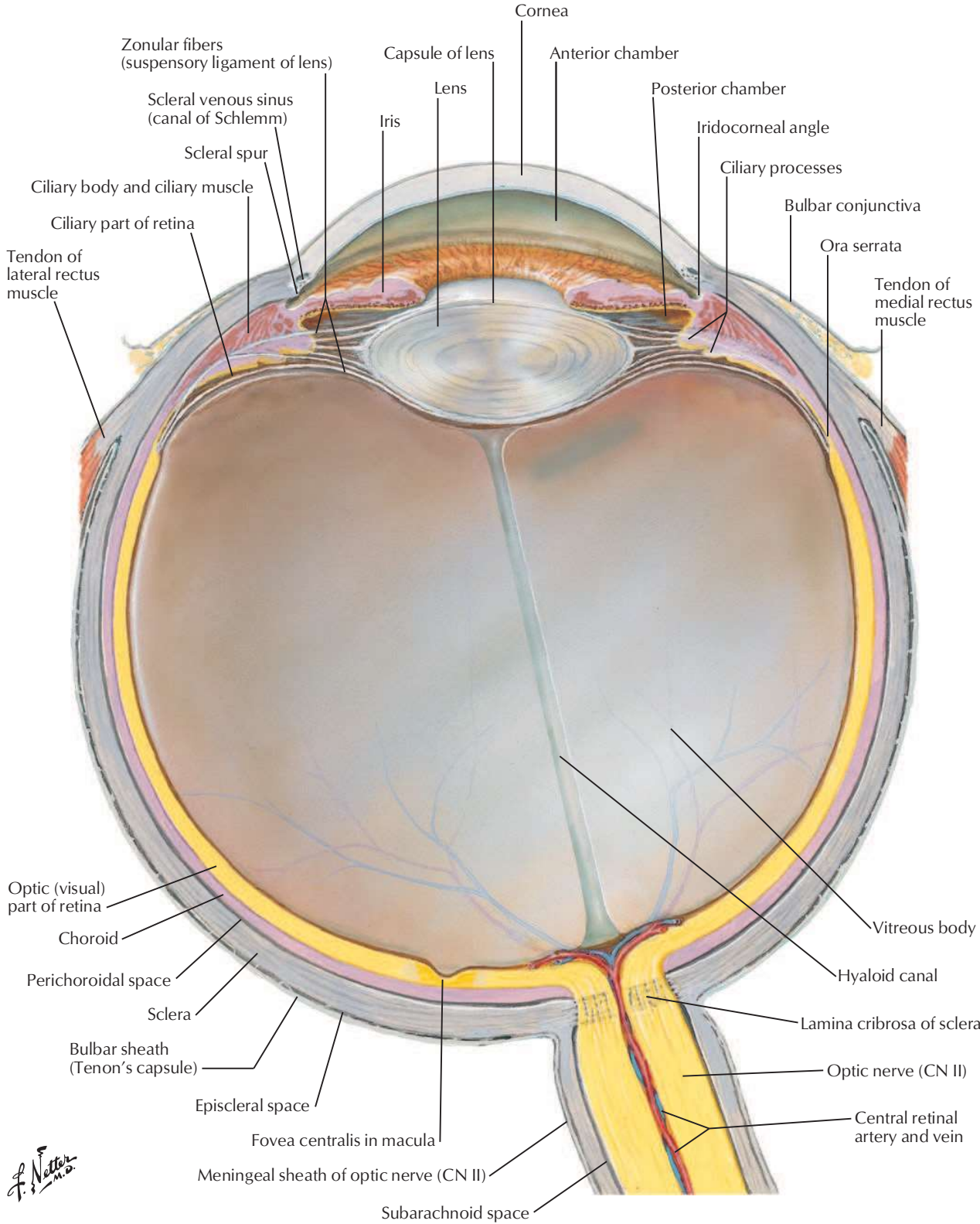


Anterior view



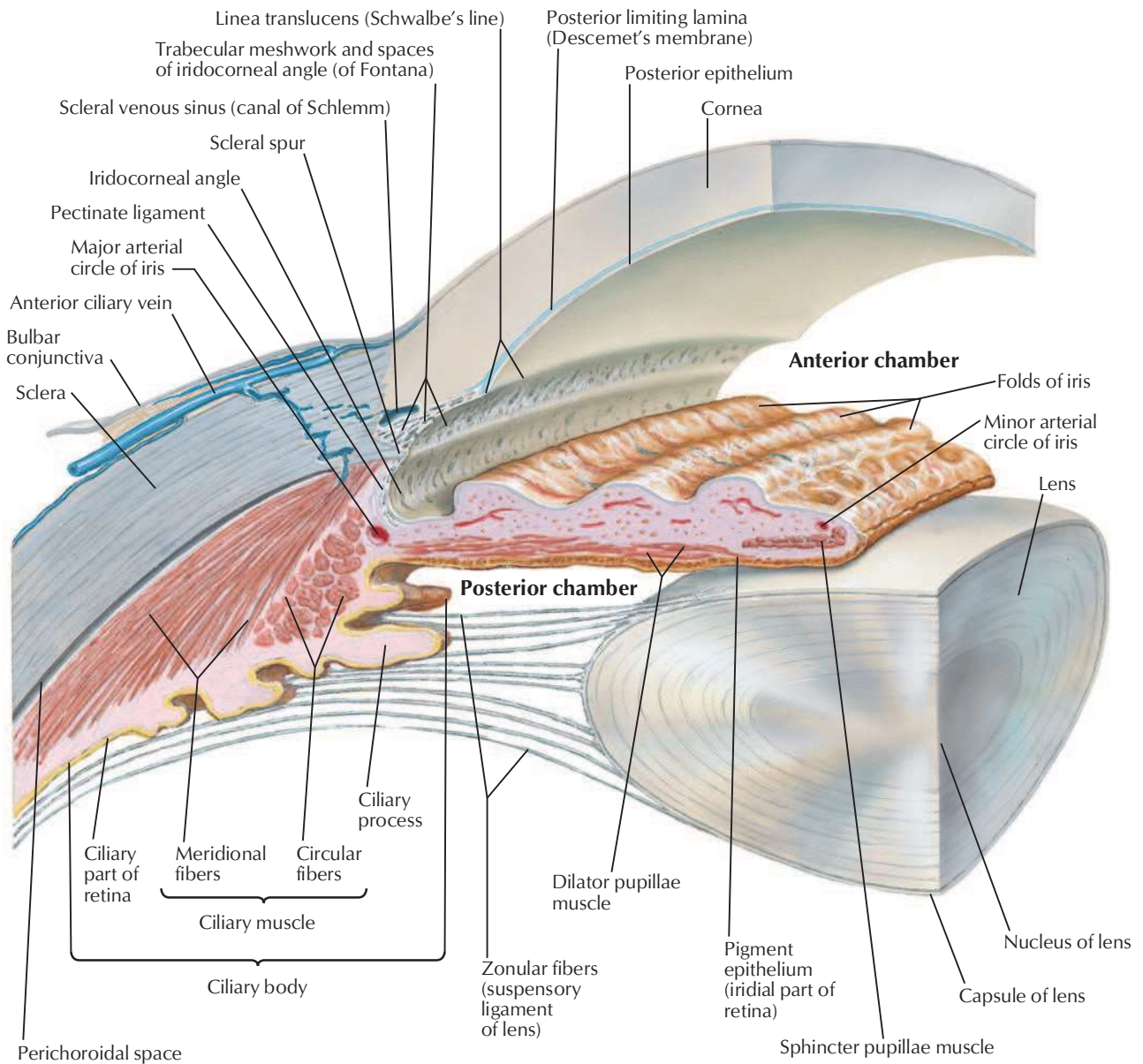
Lateral view



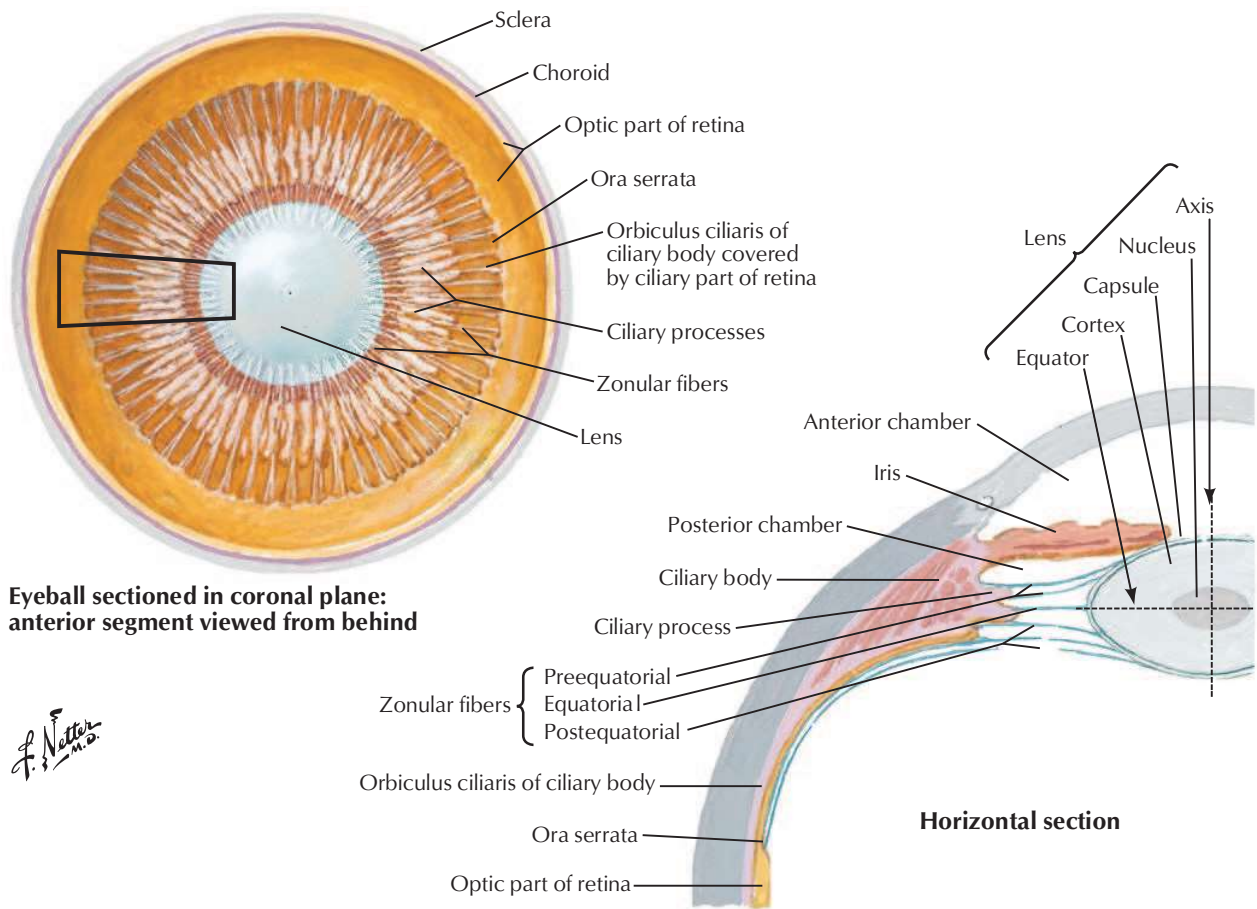


F. Netter M.D.

Anterior and Posterior Chambers of Eyeball



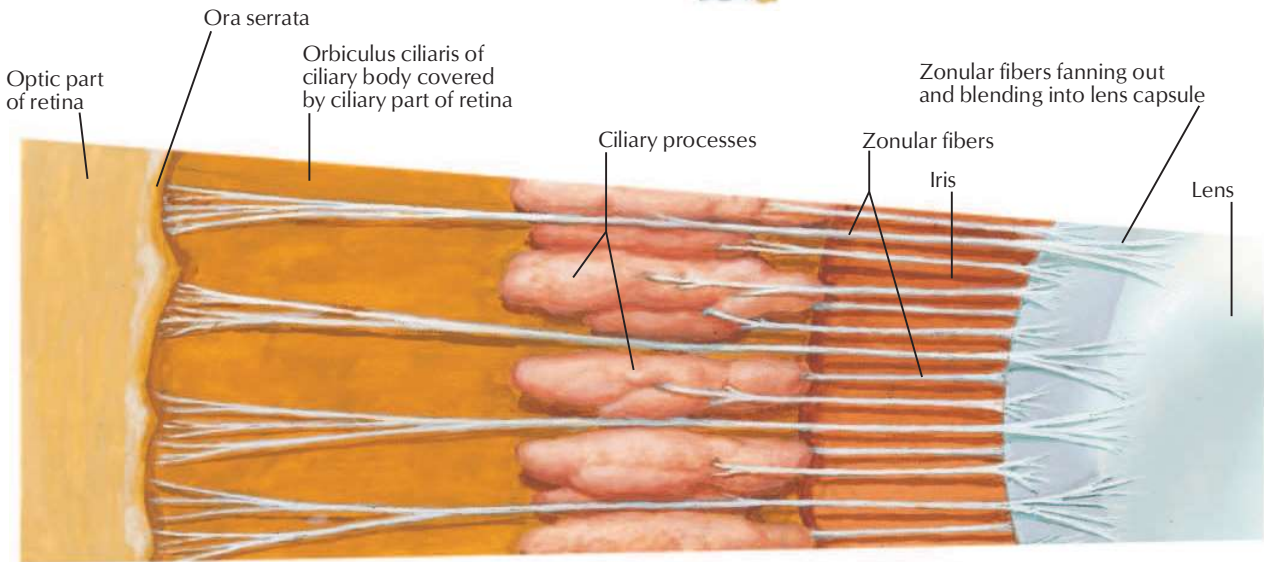
Note: For clarity, only single plane of zonular fibers shown; actually, fibers surround entire circumference of lens.



Eyeball sectioned in coronal plane: anterior segment viewed from behind

F. Netter M.D.

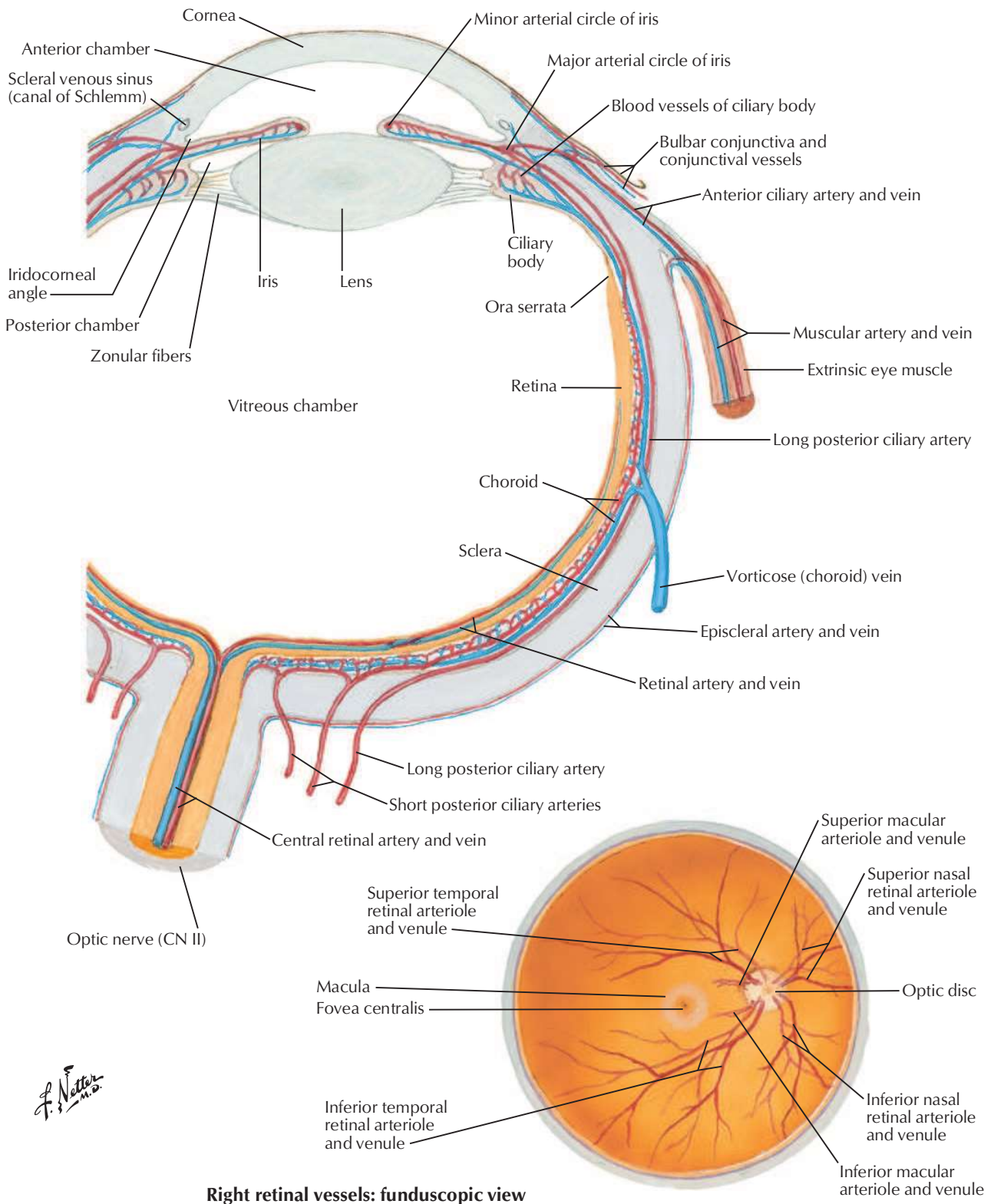
Horizontal section



Enlargement of segment outlined in top illustration (semischematic)

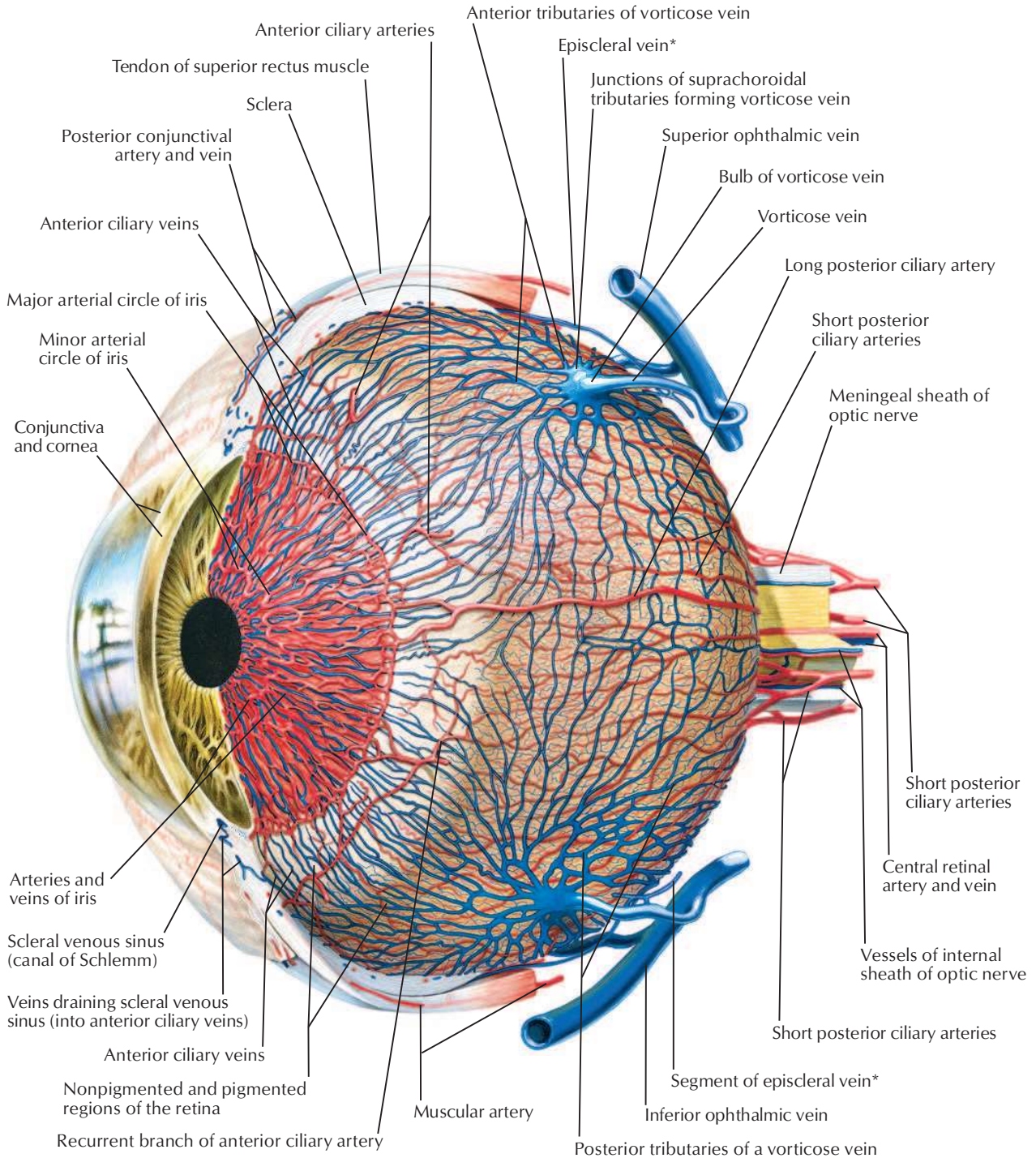
Intrinsic Arteries and Veins of Eye

See also [Plate 104](#)



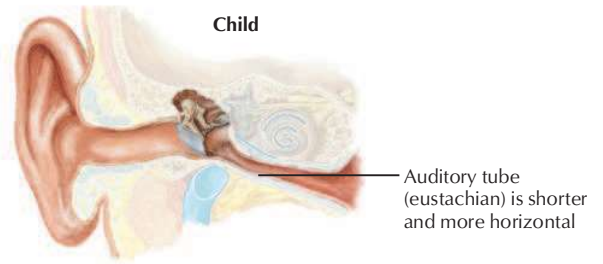
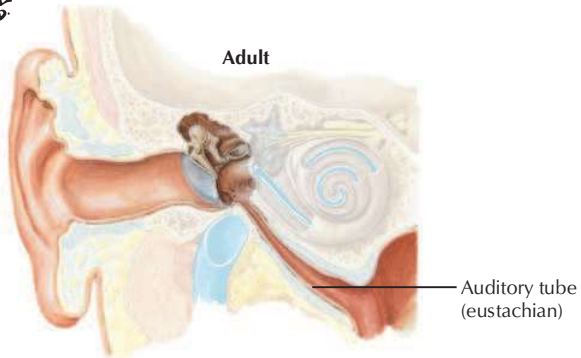
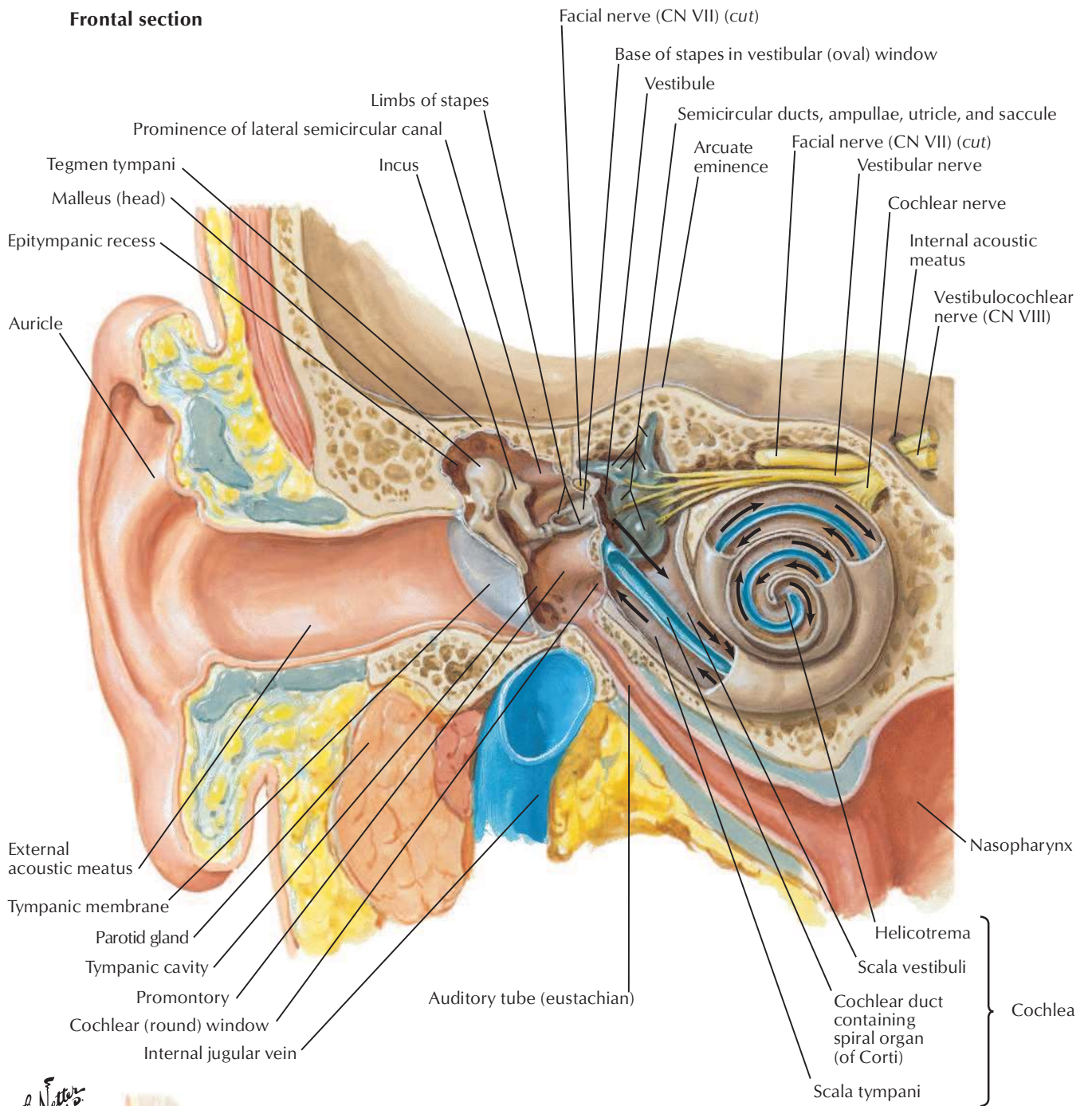
Right retinal vessels: fundus view

Vascular arrangements within the choroid (vascular tunic) of the eyeball



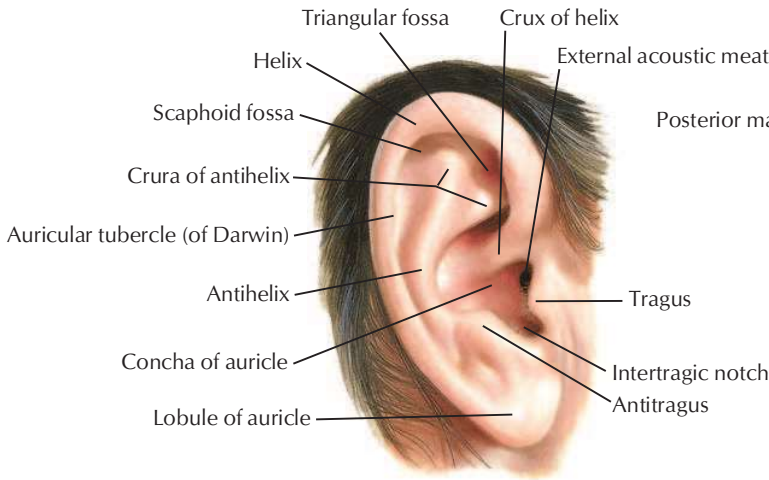
**The episcleral veins are shown here anastomosing with the vorticoses veins, which they do; however, they also drain into the anterior ciliary veins.*

C. Machado
—M.D.

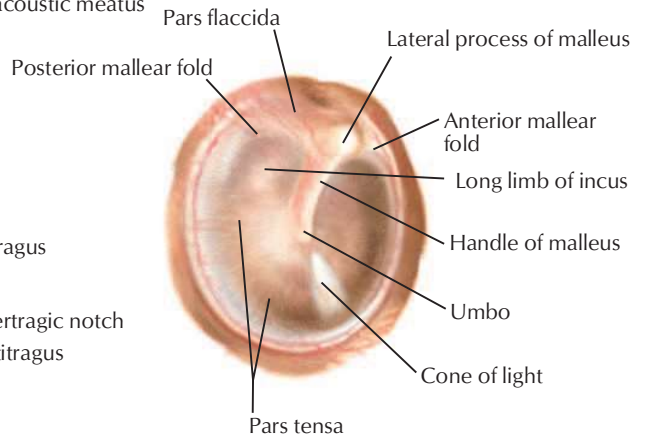


See also [Plate 107](#)

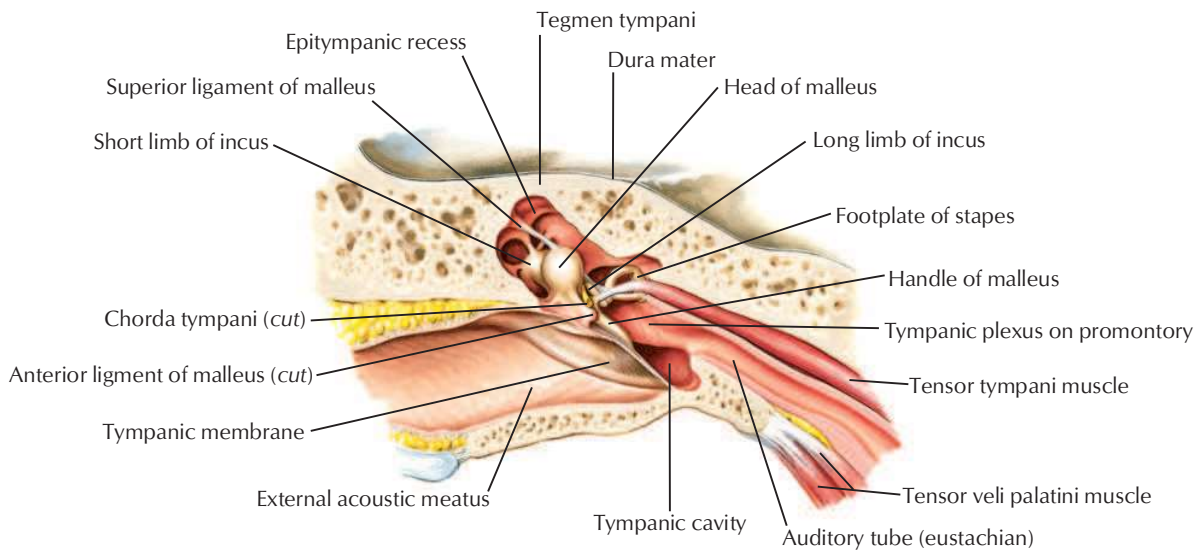
Right auricle (pinna)



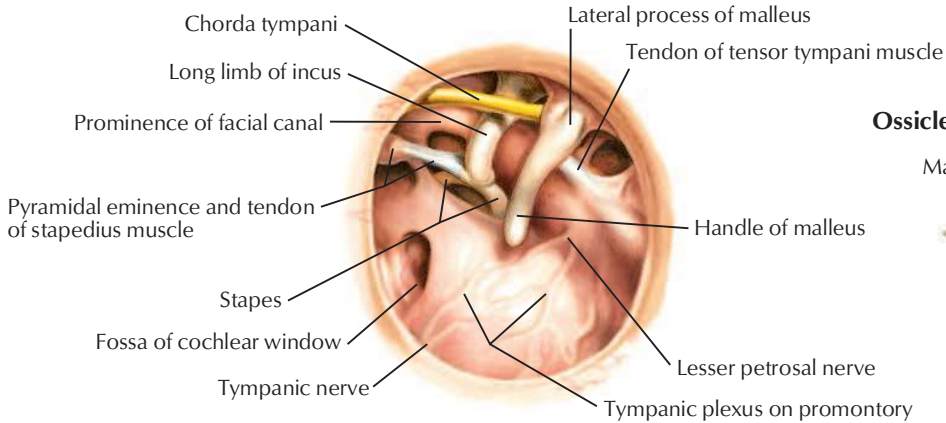
Otoscopic view of right tympanic membrane



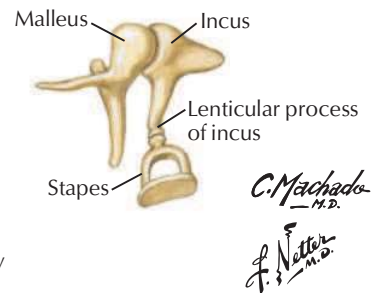
Coronal oblique section of external acoustic meatus and middle ear (tympanic cavity)



Right tympanic cavity after removal of tympanic membrane (lateral view)

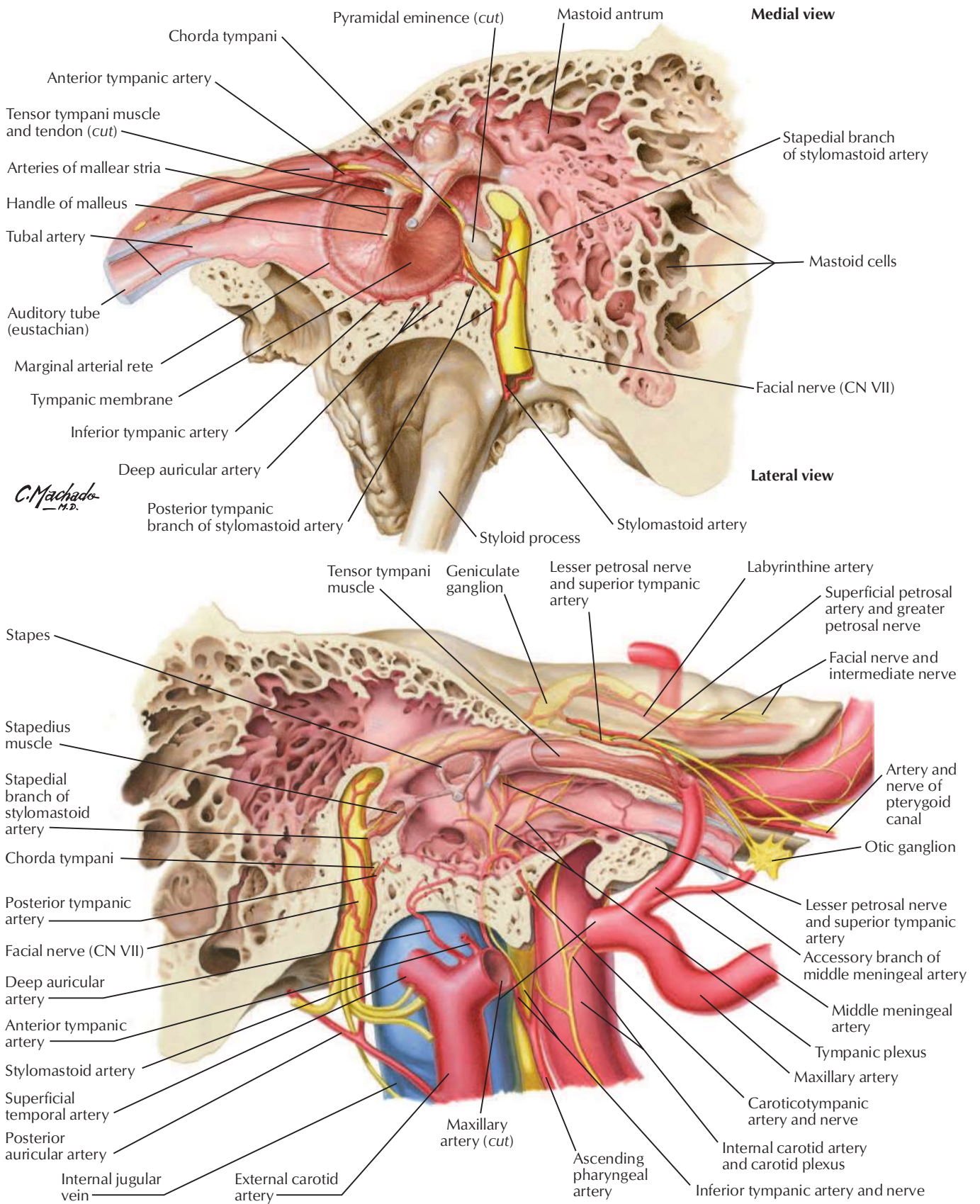


Ossicles articulated: medial view

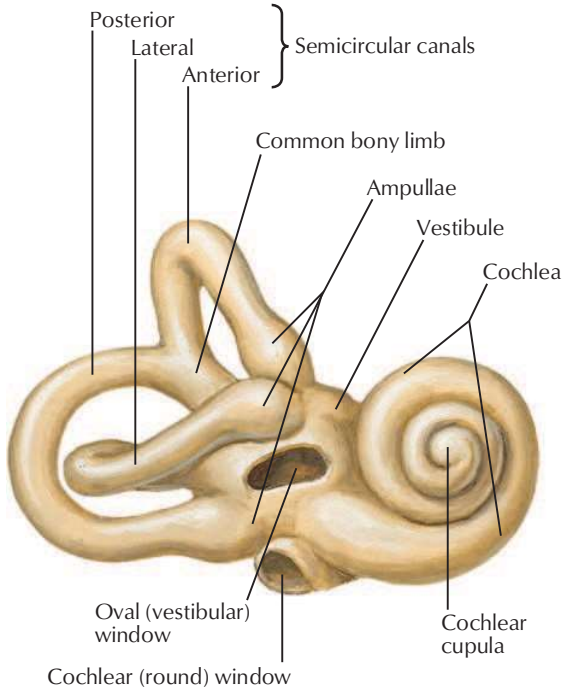


Tympanic Cavity

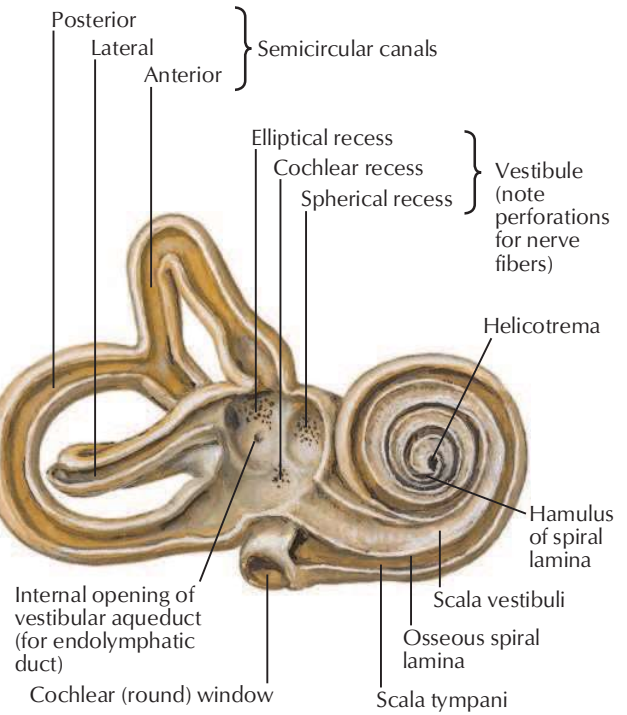
See also **Plates 59, 146**



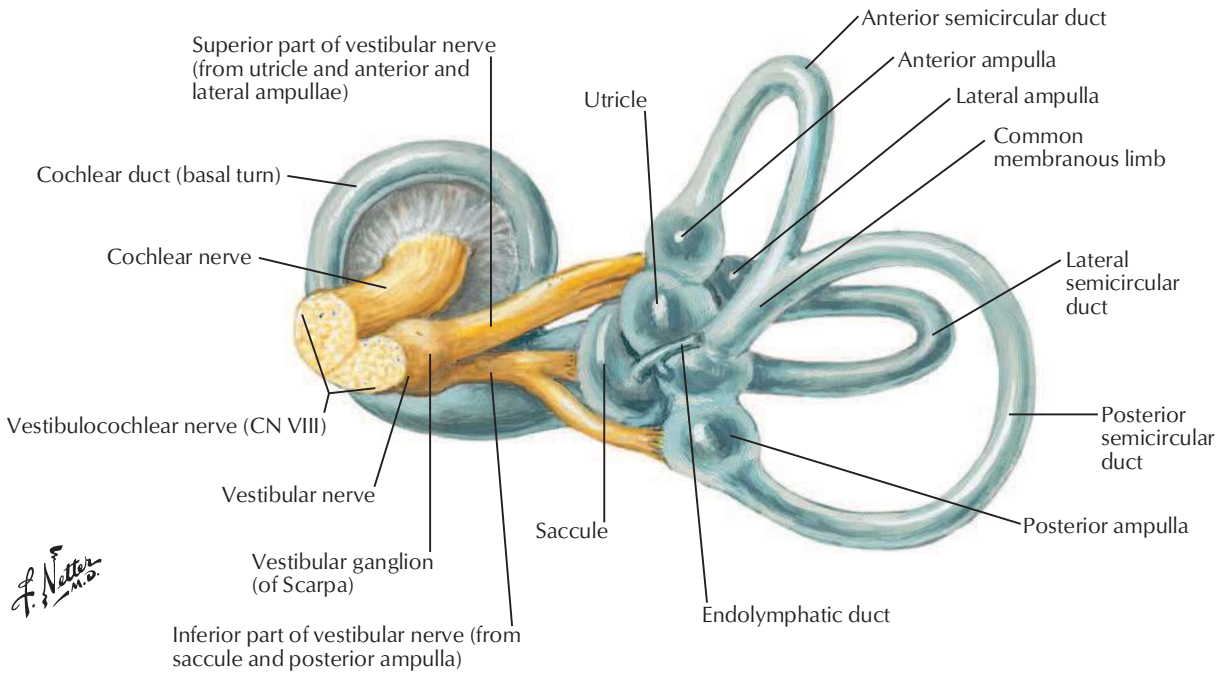
Right bony labyrinth (otic capsule), anterolateral view: surrounding cancellous bone removed



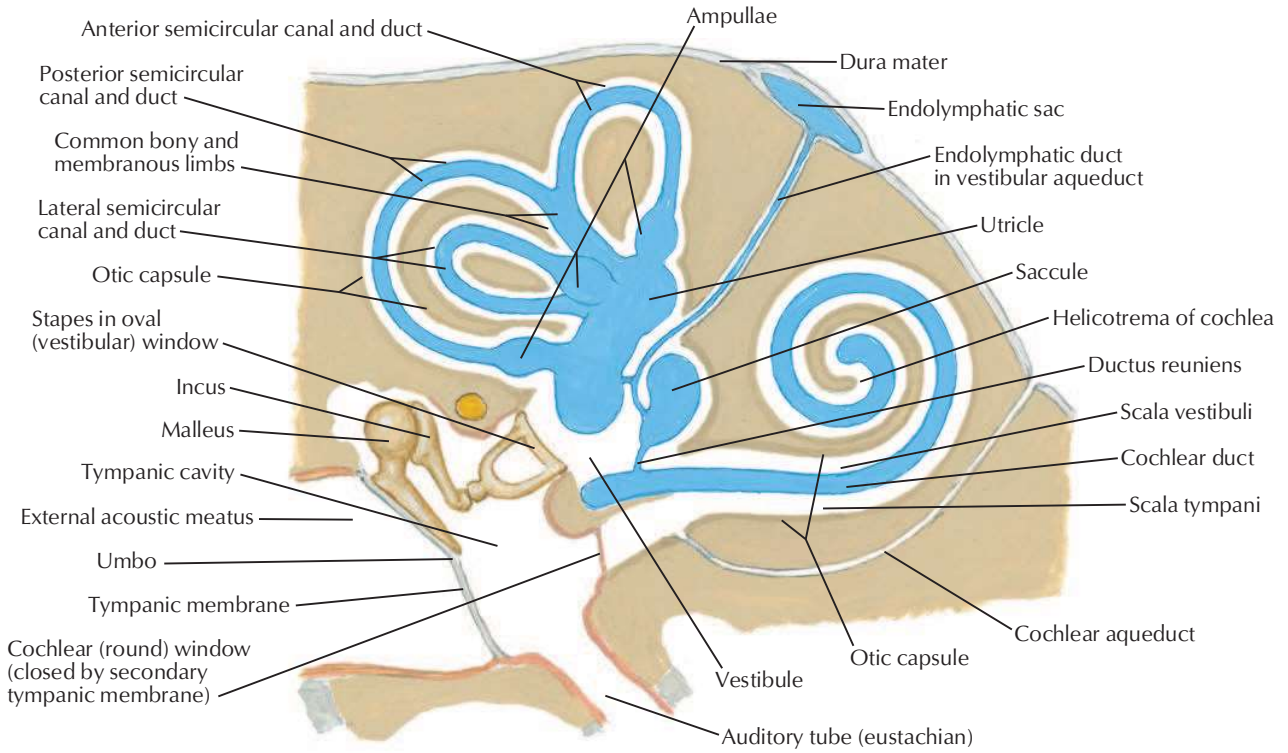
Dissected right bony labyrinth (otic capsule): membranous labyrinth removed



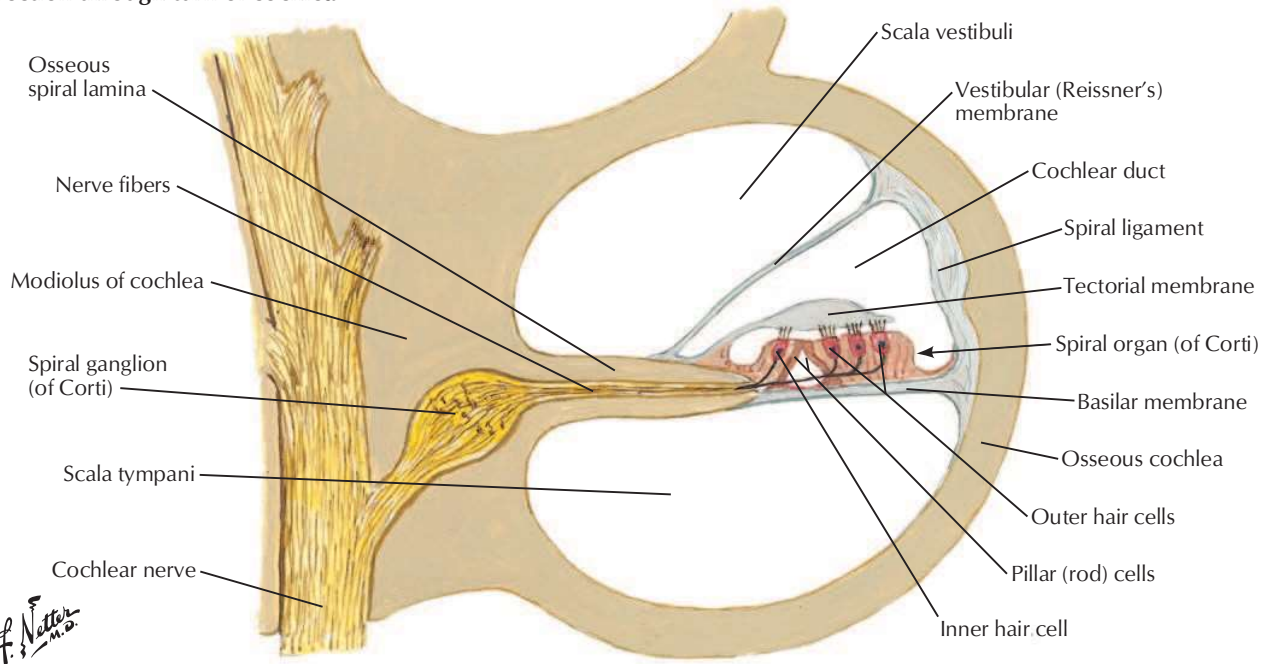
Right membranous labyrinth with nerves: medial view



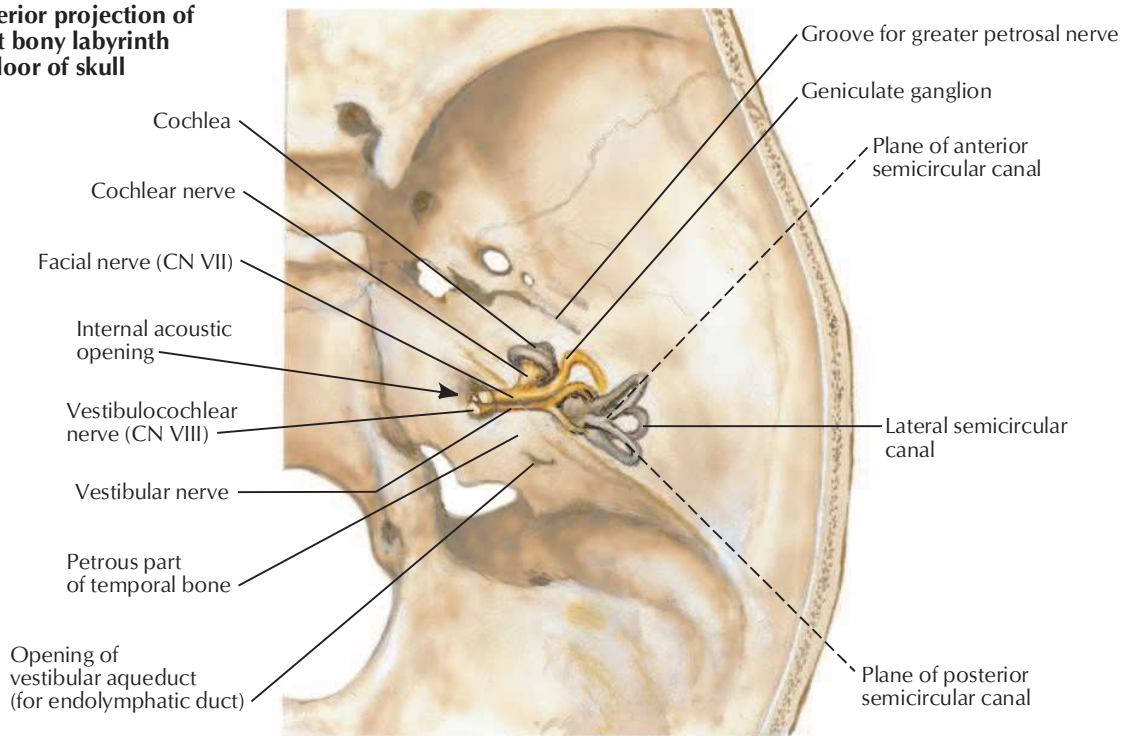
Bony and membranous labyrinths: schema



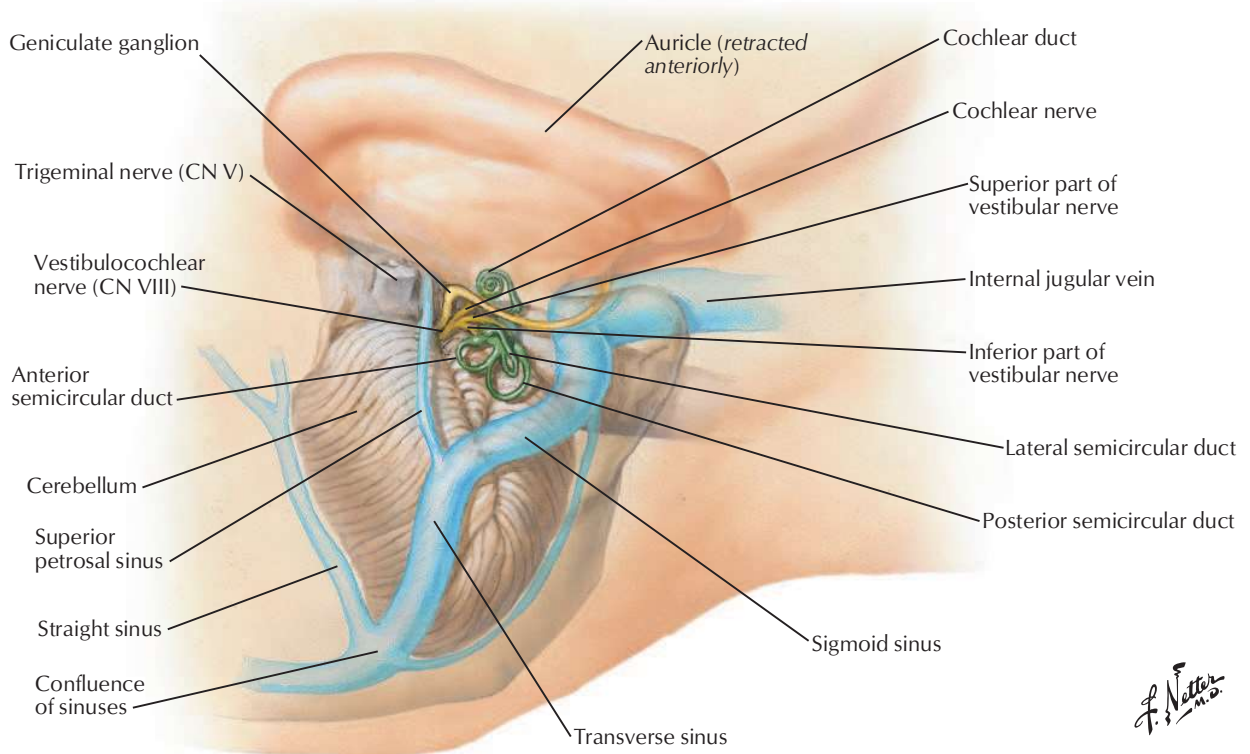
Section through turn of cochlea



Superior projection of right bony labyrinth on floor of skull



Lateral projection of right membranous labyrinth

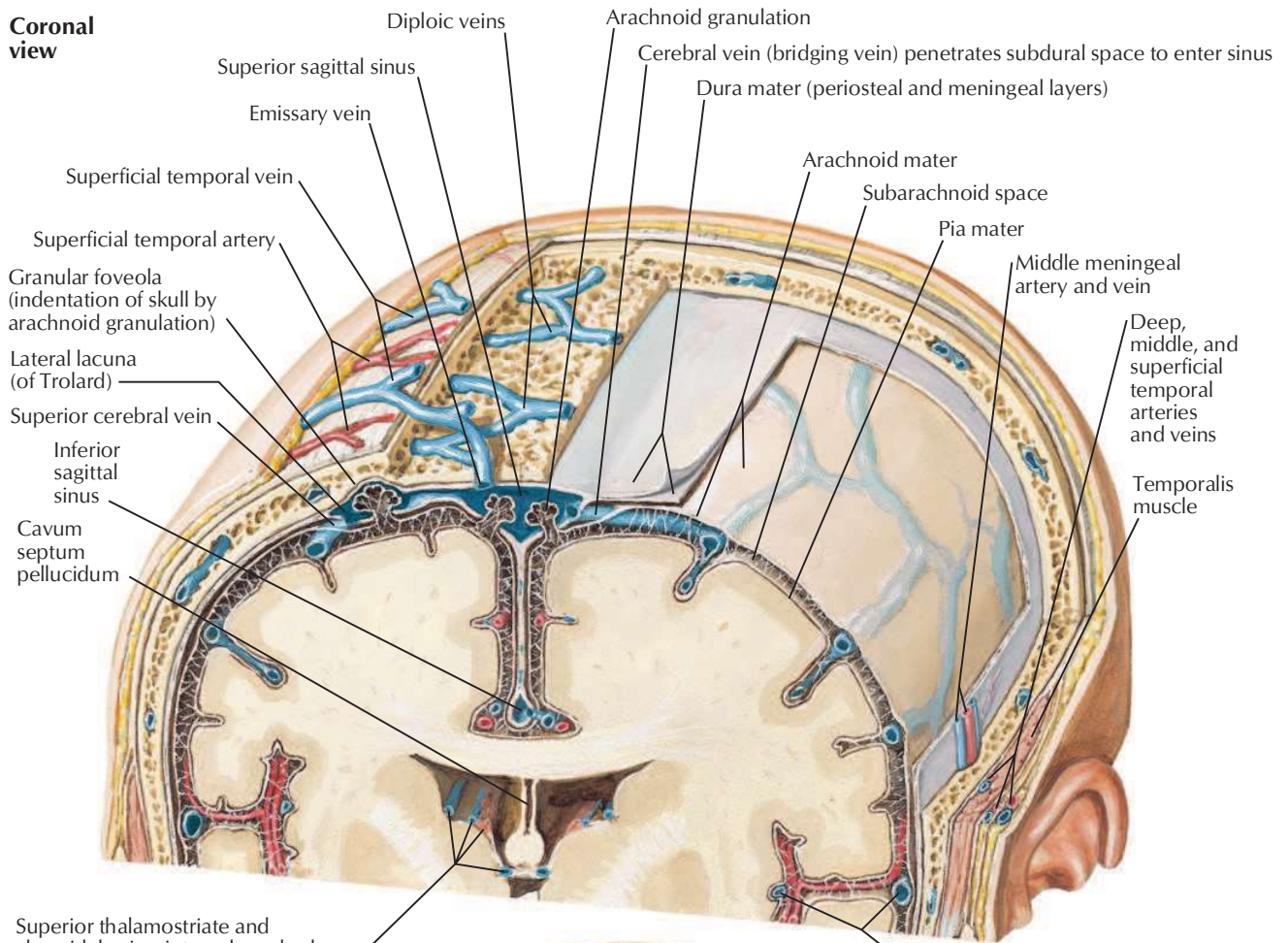


F. Netter M.D.

Meninges and Diploic Veins

See also [Plate 10](#)

Coronal view



Superior thalamostriate and choroidal veins, internal cerebral veins, and choroid plexus of lateral ventricle

Diploic and emissary veins of skull

Frontal diploic vein

Anterior temporal diploic vein

Deep and superficial middle cerebral veins

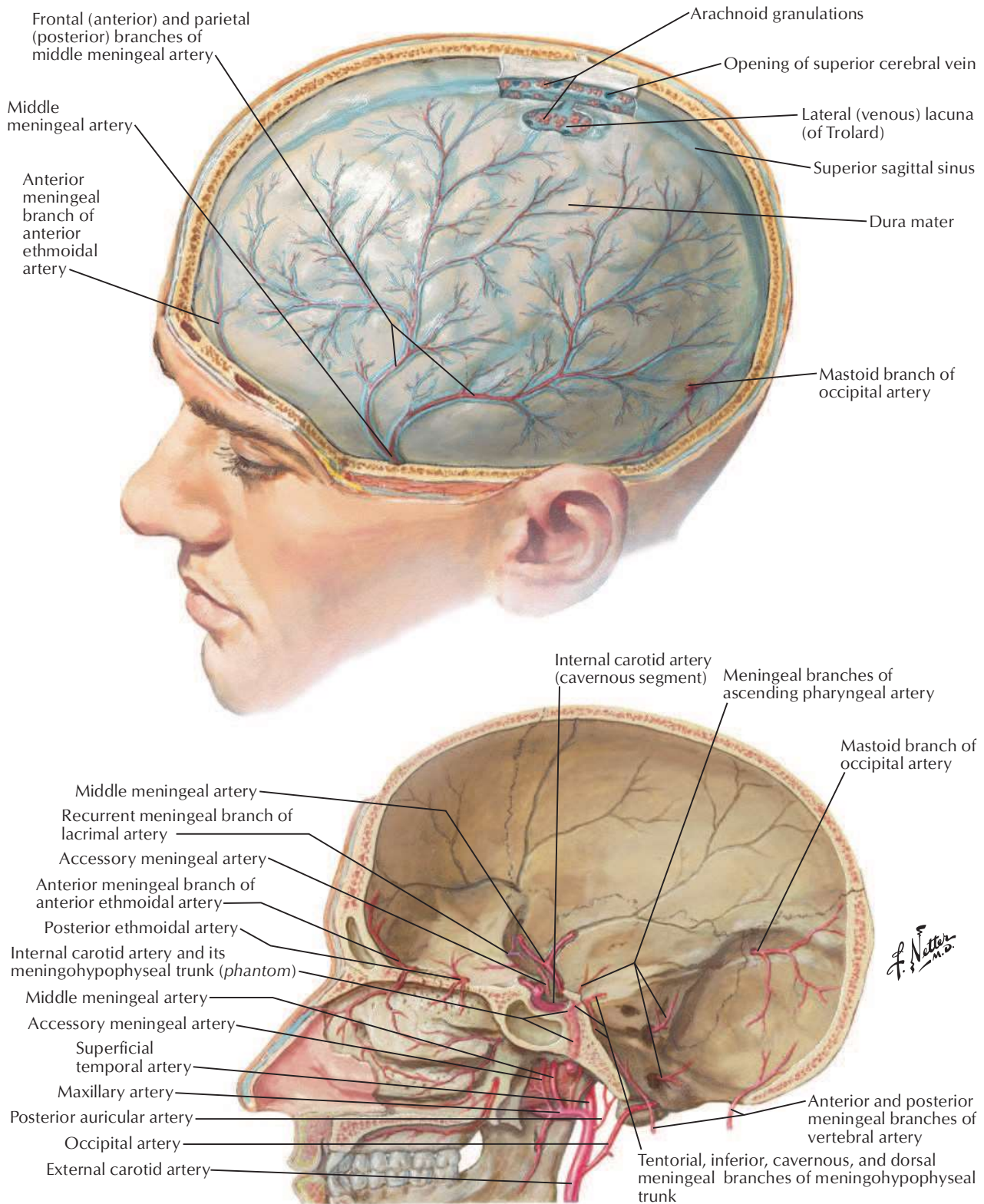
Parietal emissary vein

Posterior temporal diploic vein

Occipital emissary vein

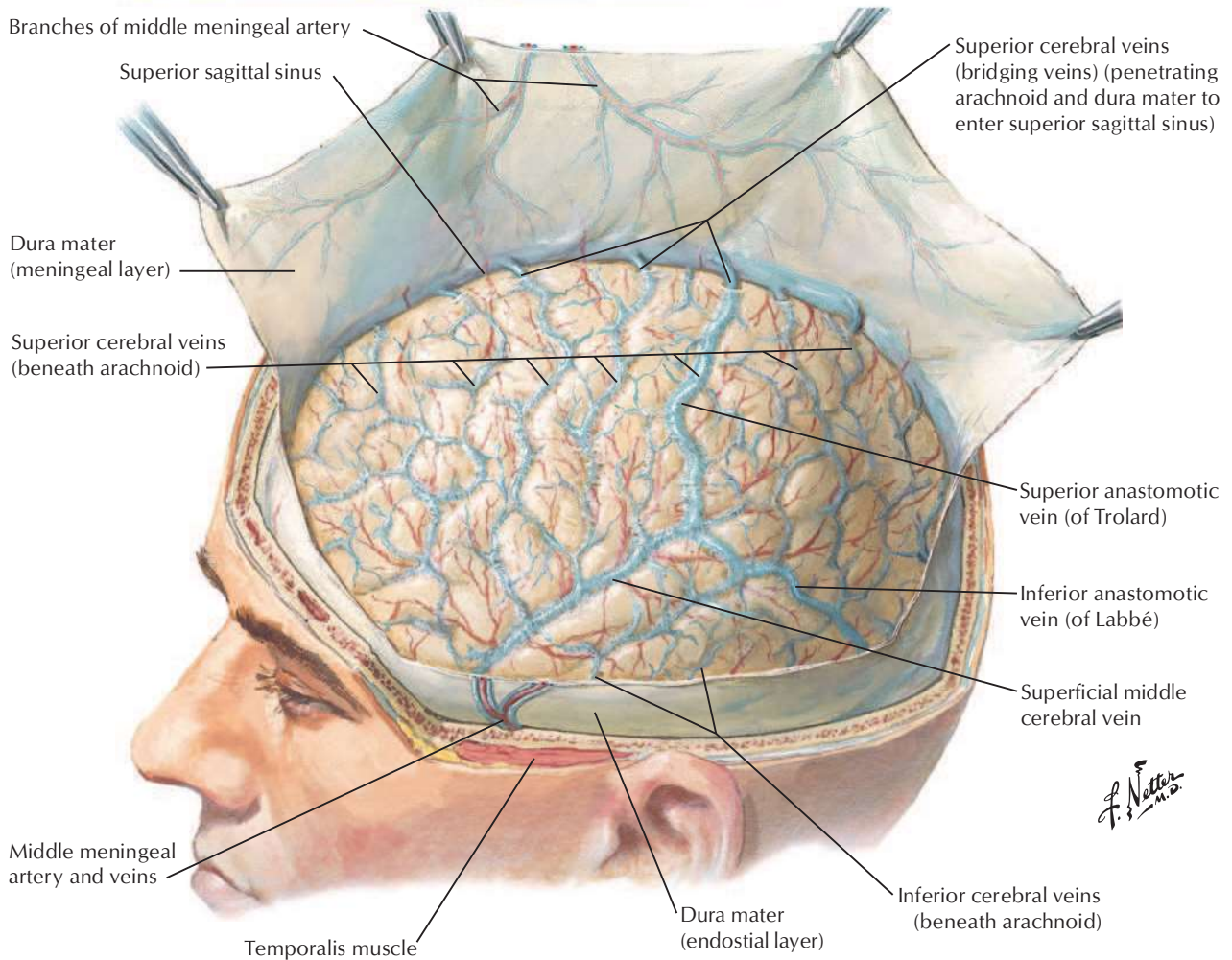
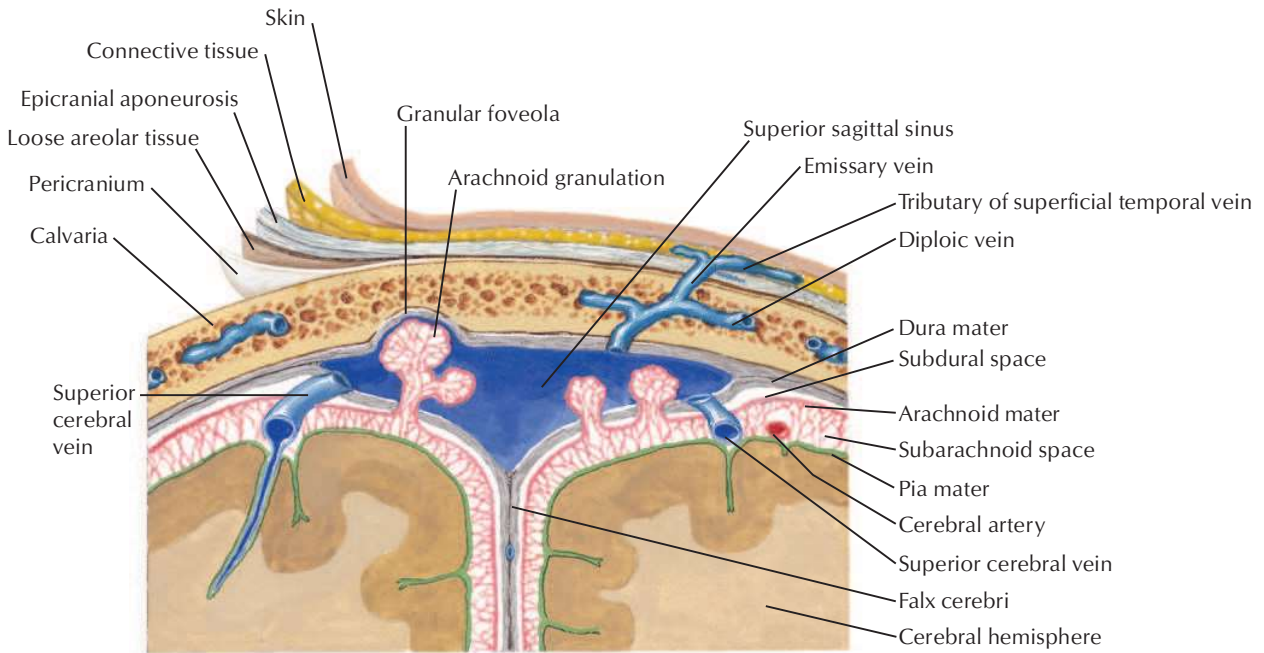
Occipital diploic vein

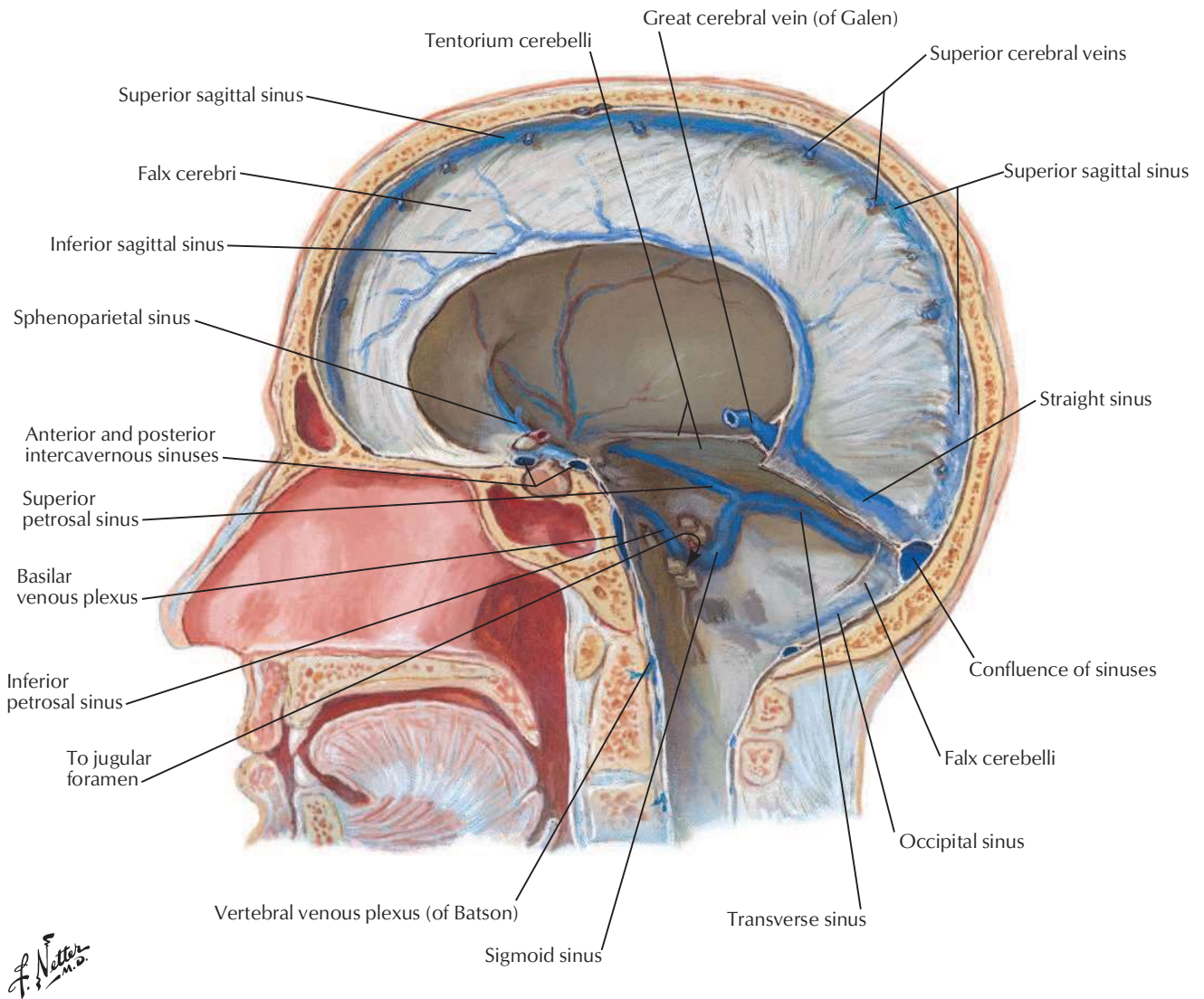
Mastoid emissary vein



Meninges and Superficial Cerebral Veins

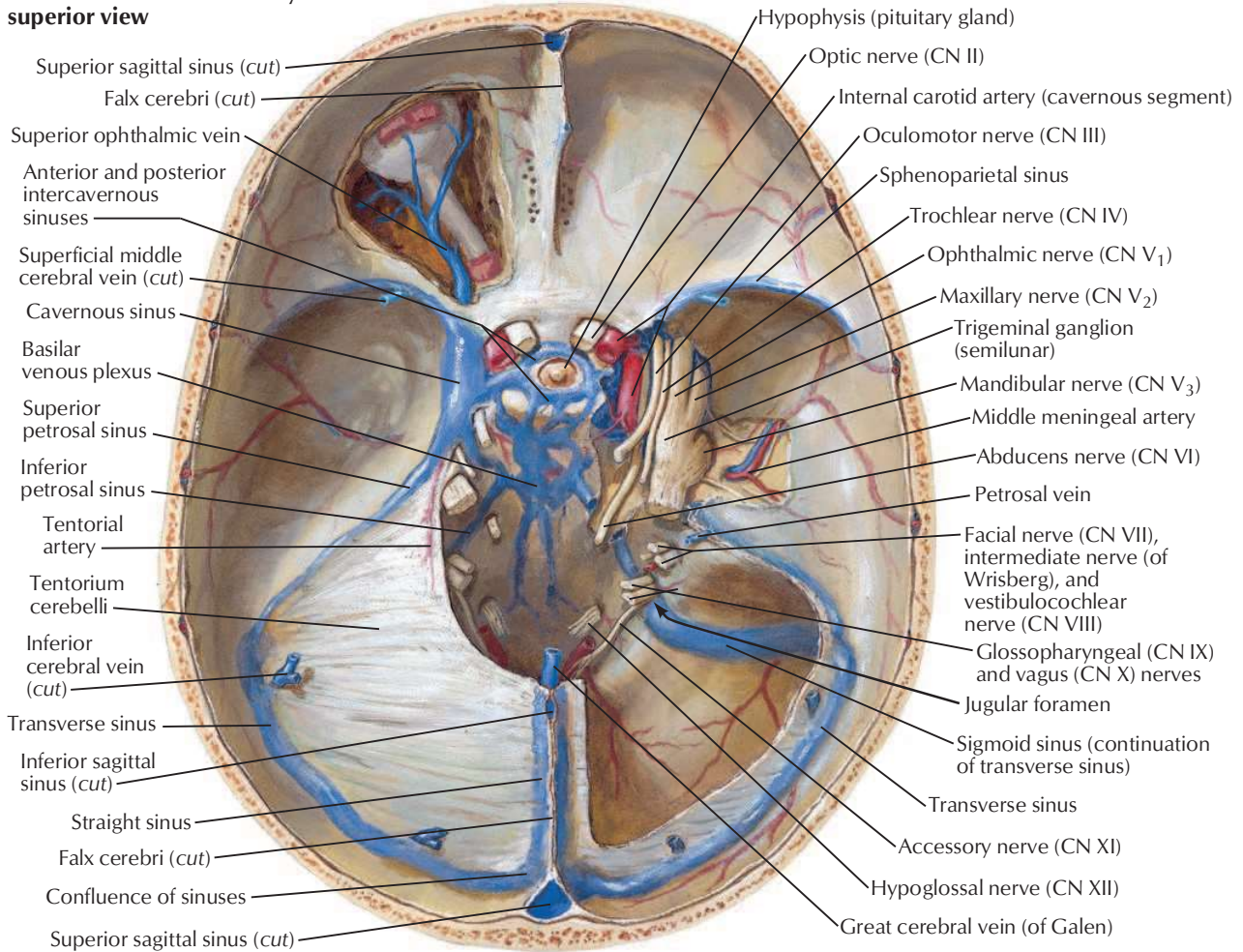
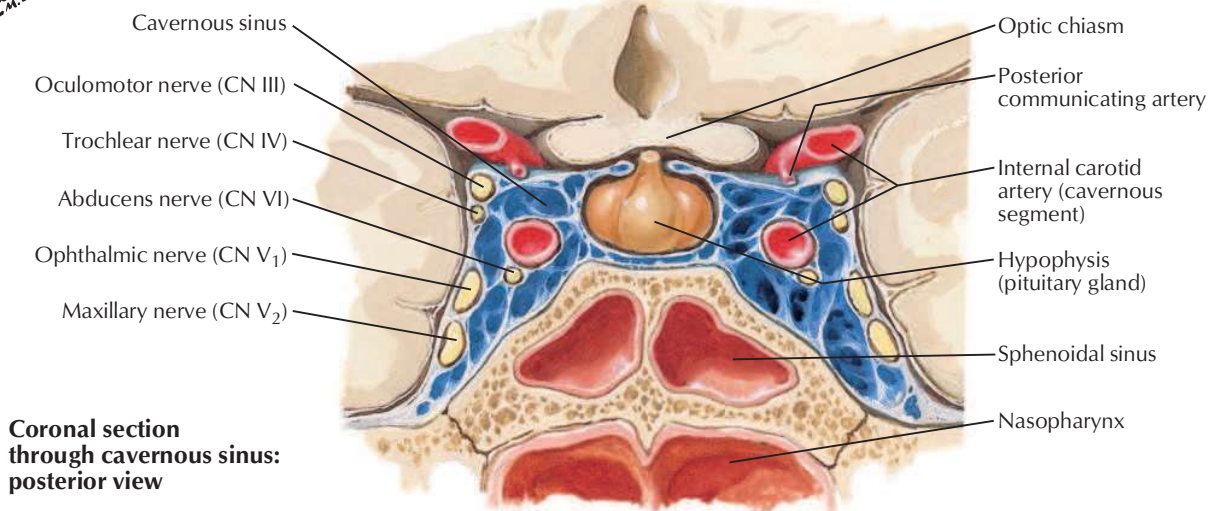
For deep veins of brain see [Plate 156](#)



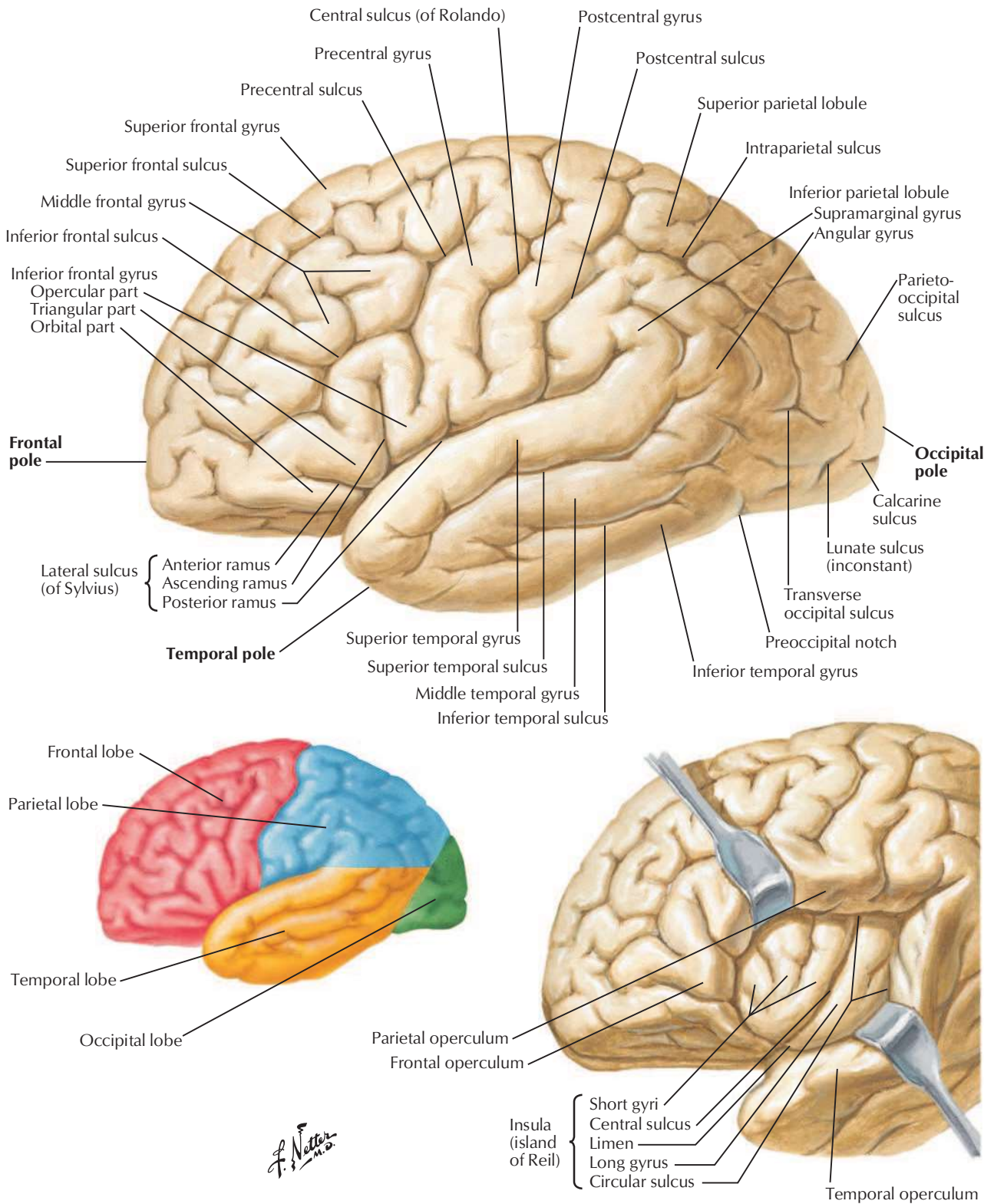


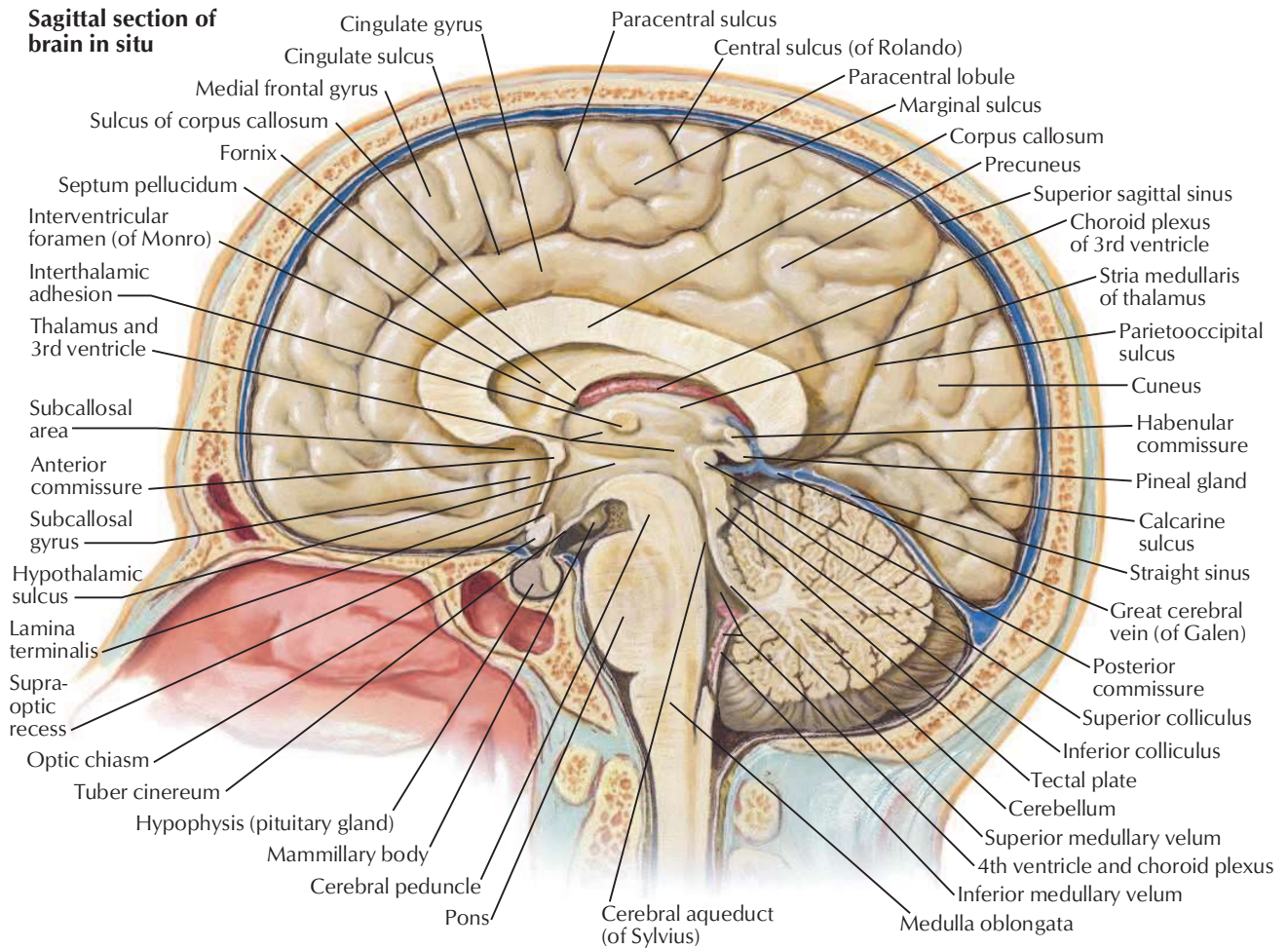
F. Netter M.D.

Skull sectioned horizontally: superior view

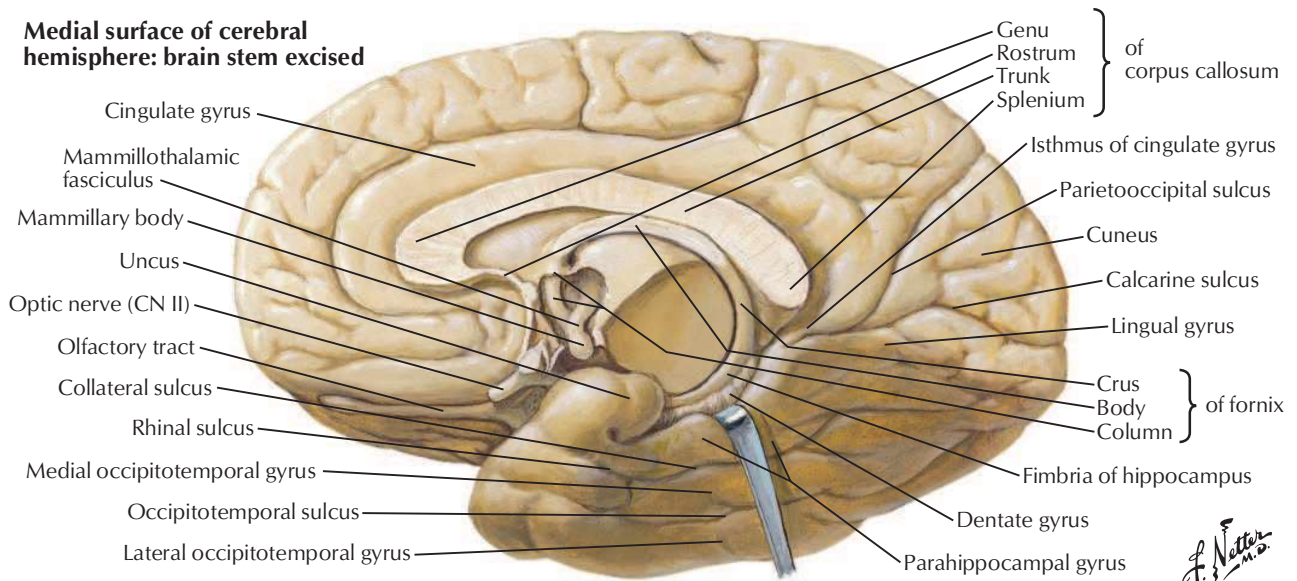



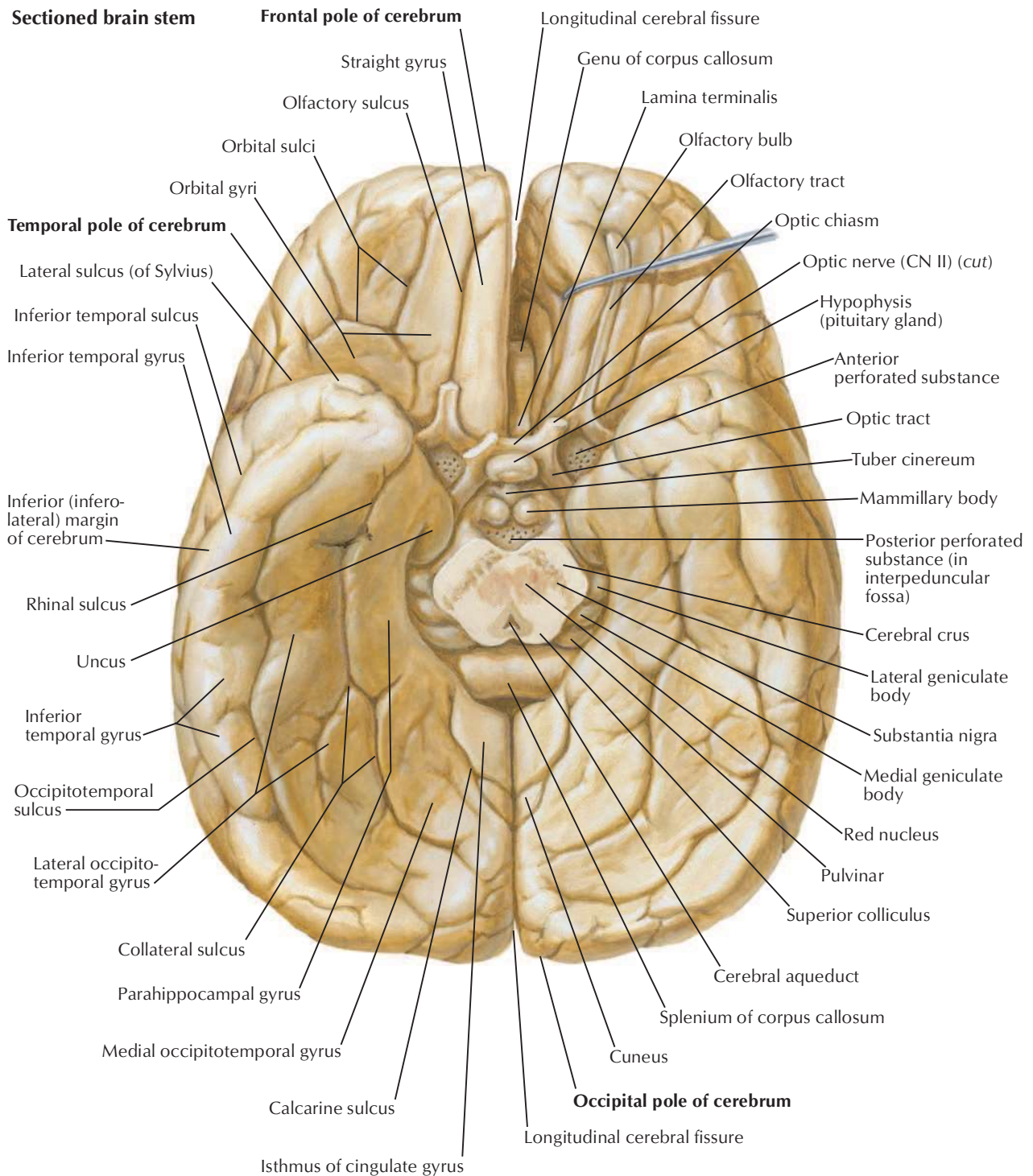
Coronal section through cavernous sinus: posterior view





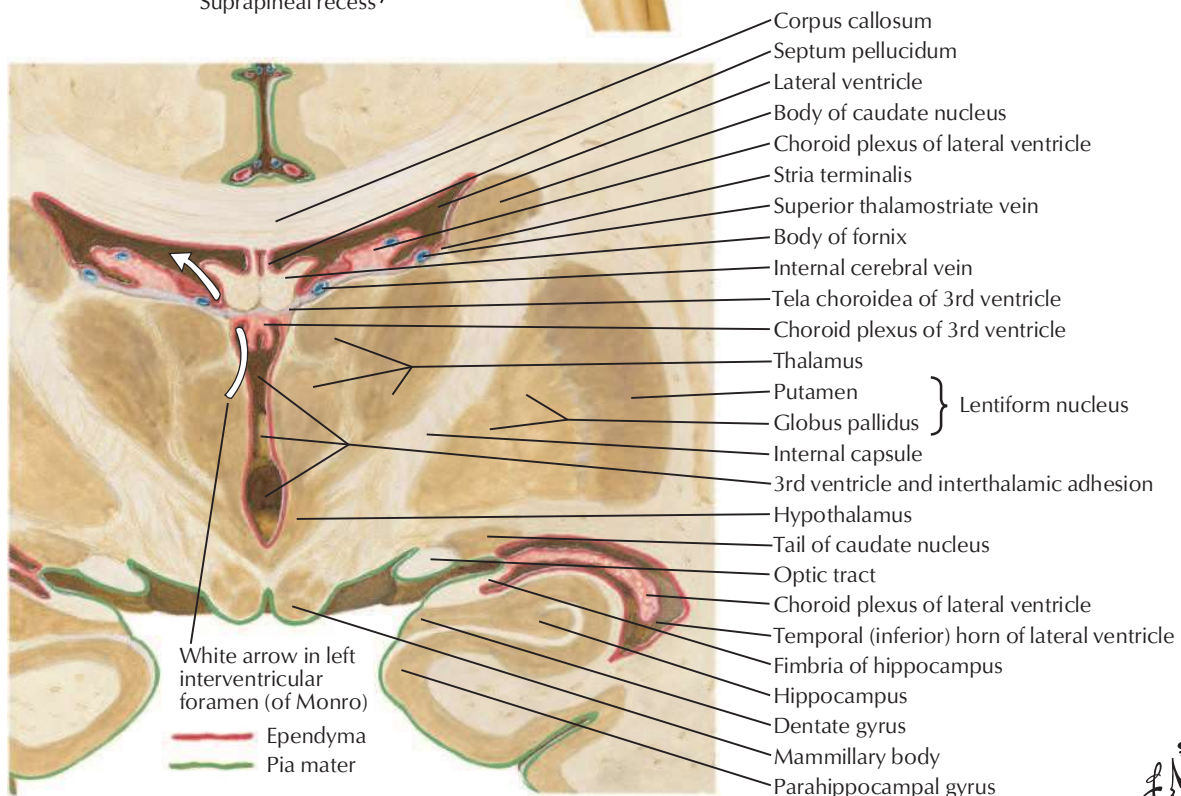
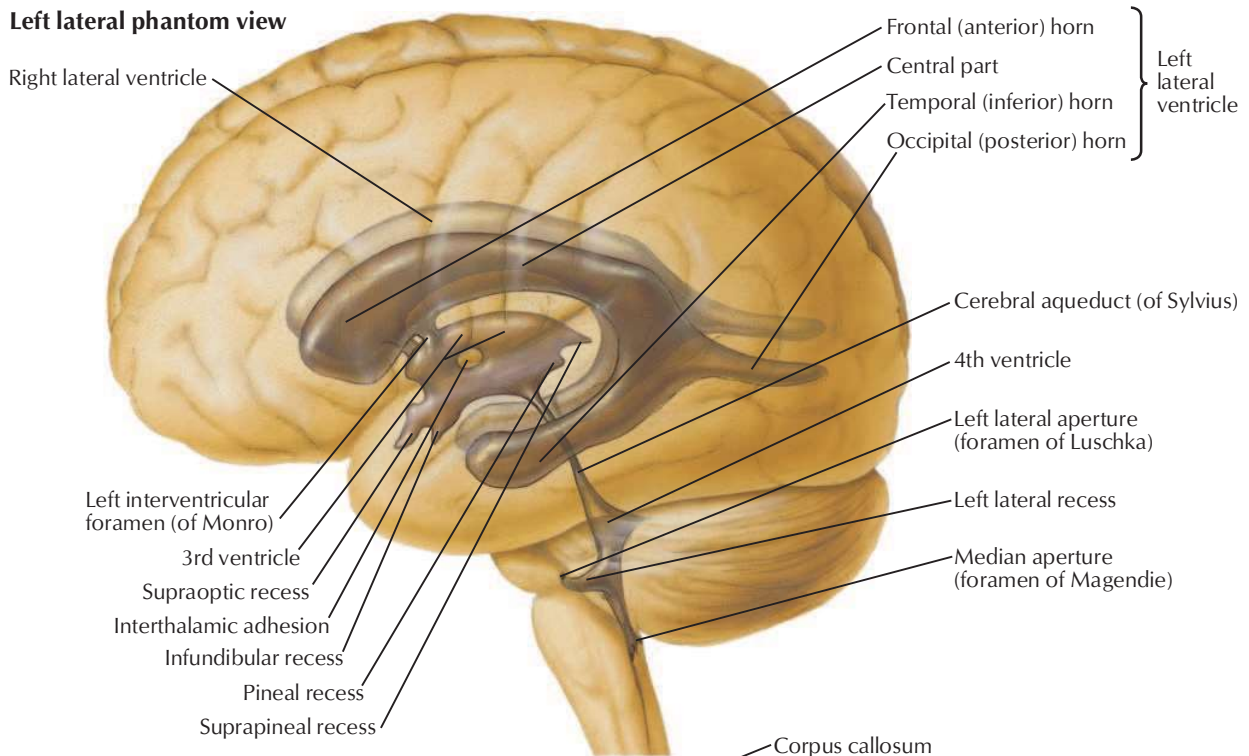
Medial surface of cerebral hemisphere: brain stem excised



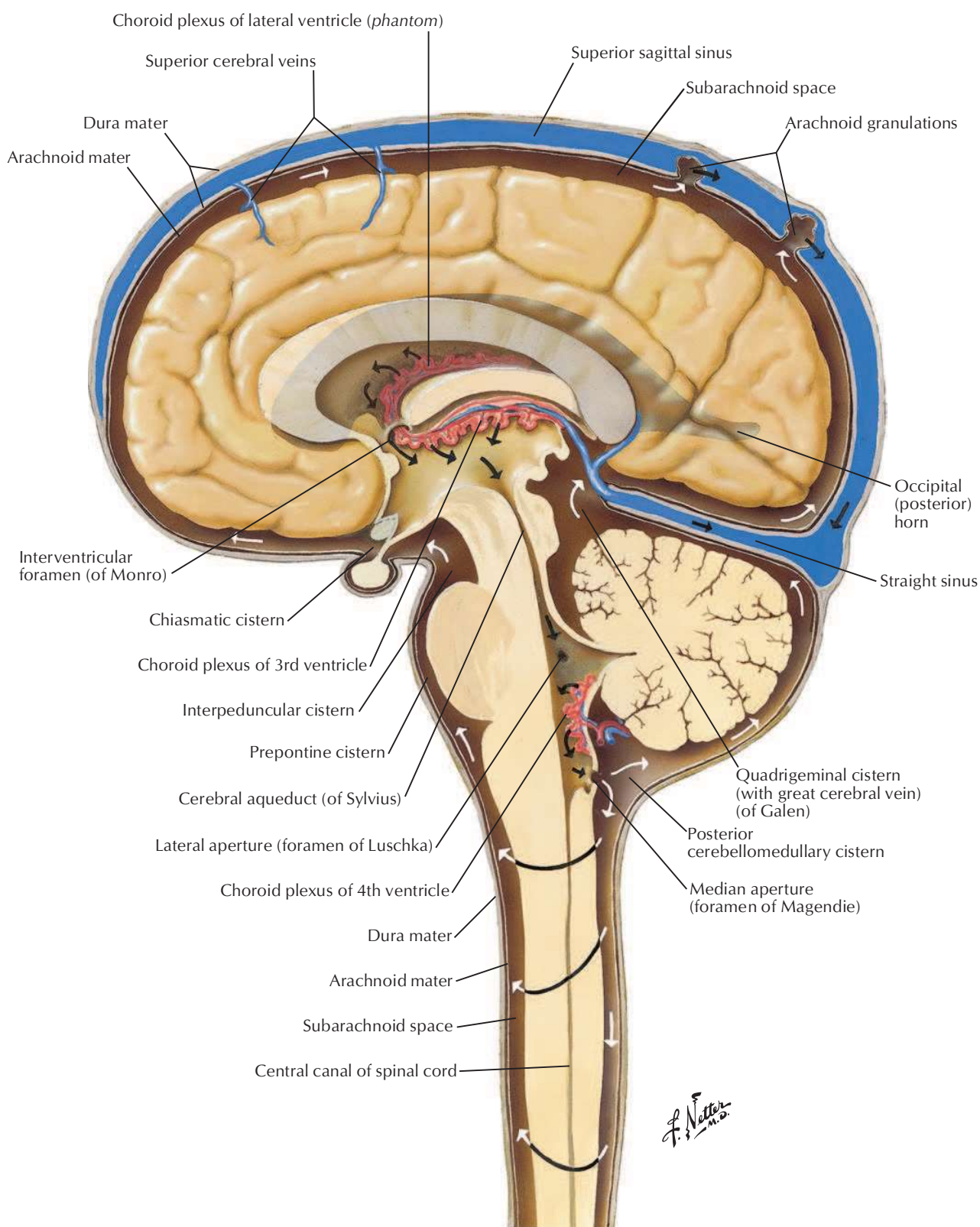


F. Netter M.D.

Left lateral phantom view

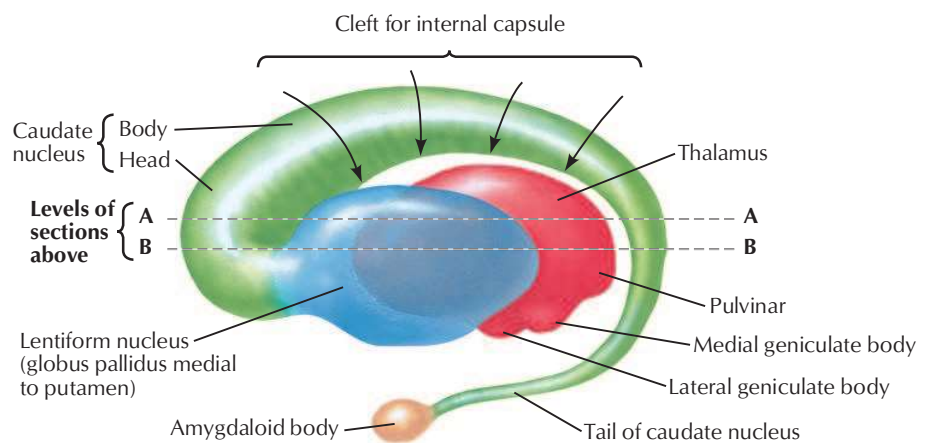
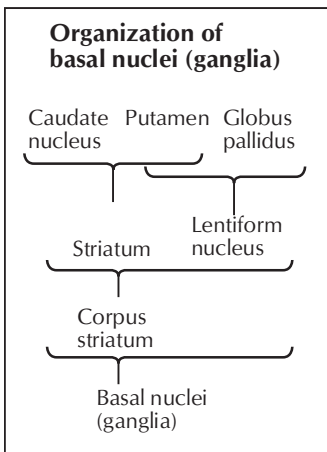
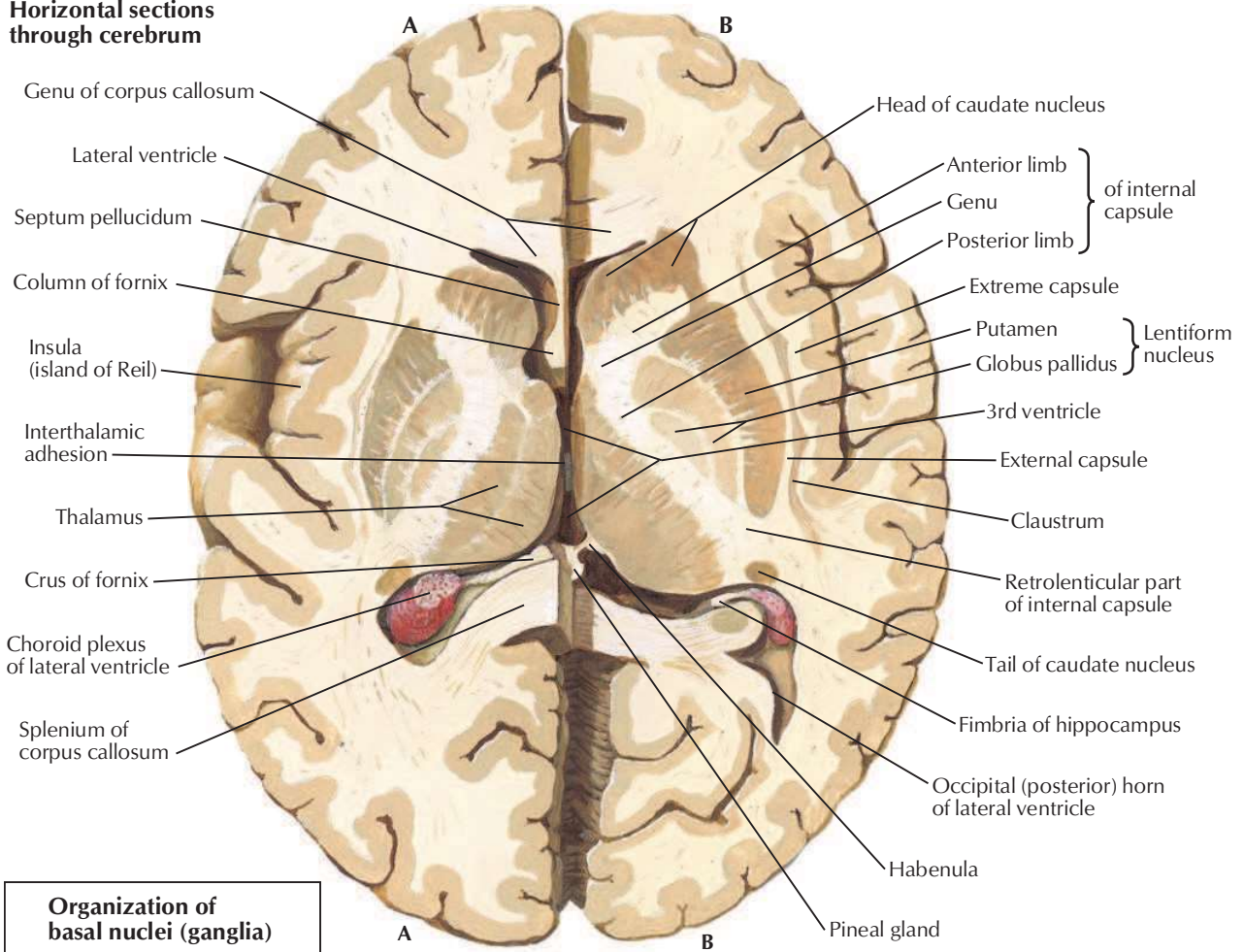


Coronal section of brain: posterior view

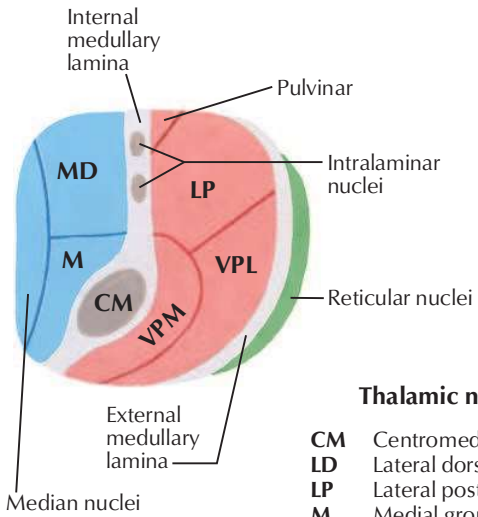
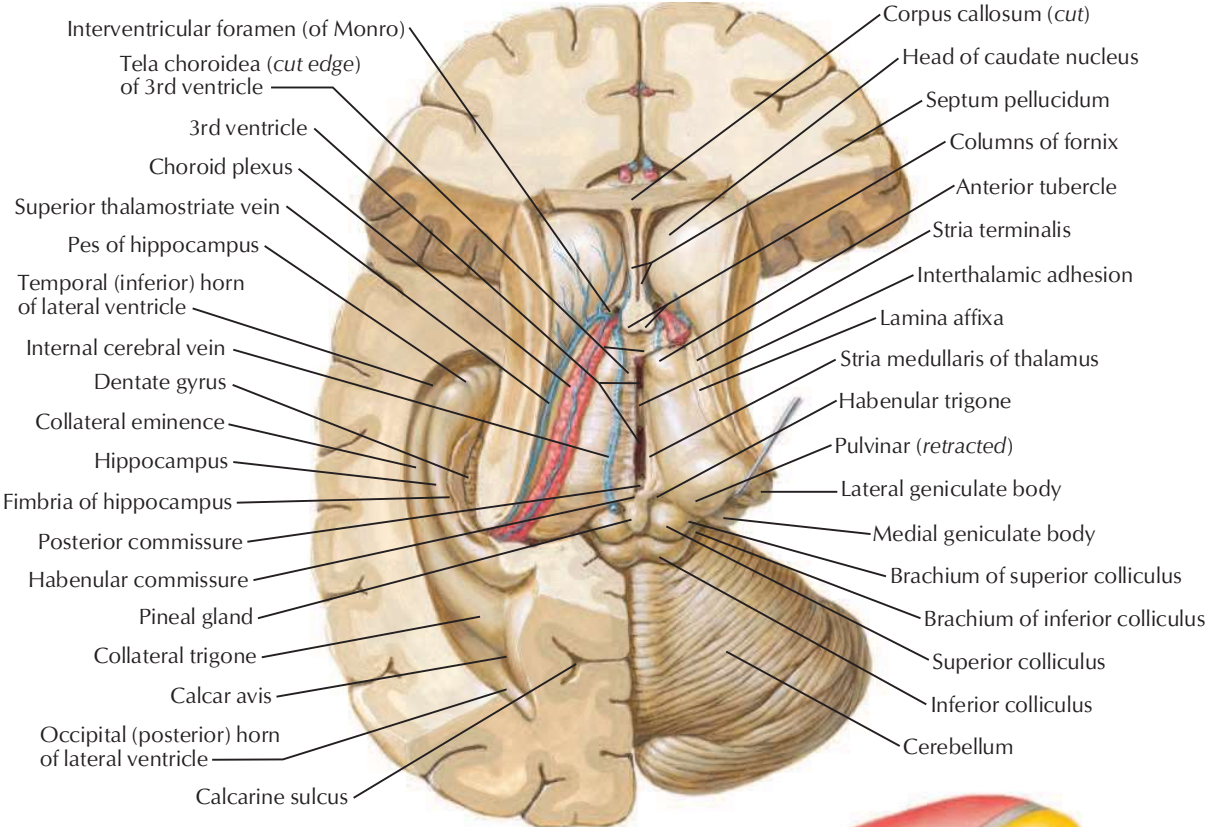


Basal Nuclei (Ganglia)

Horizontal sections through cerebrum

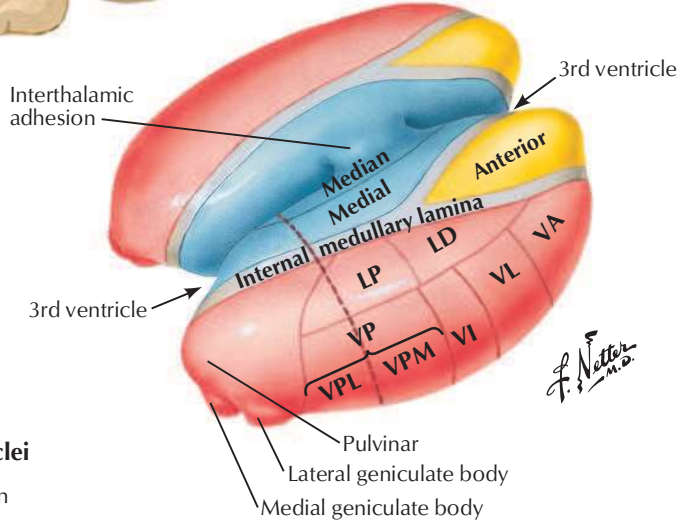


Interrelationship of thalamus, lentiform nucleus, caudate nucleus, and amygdaloid body (schema): left lateral view



Schematic section through thalamus
(at level of broken line shown in figure at right)

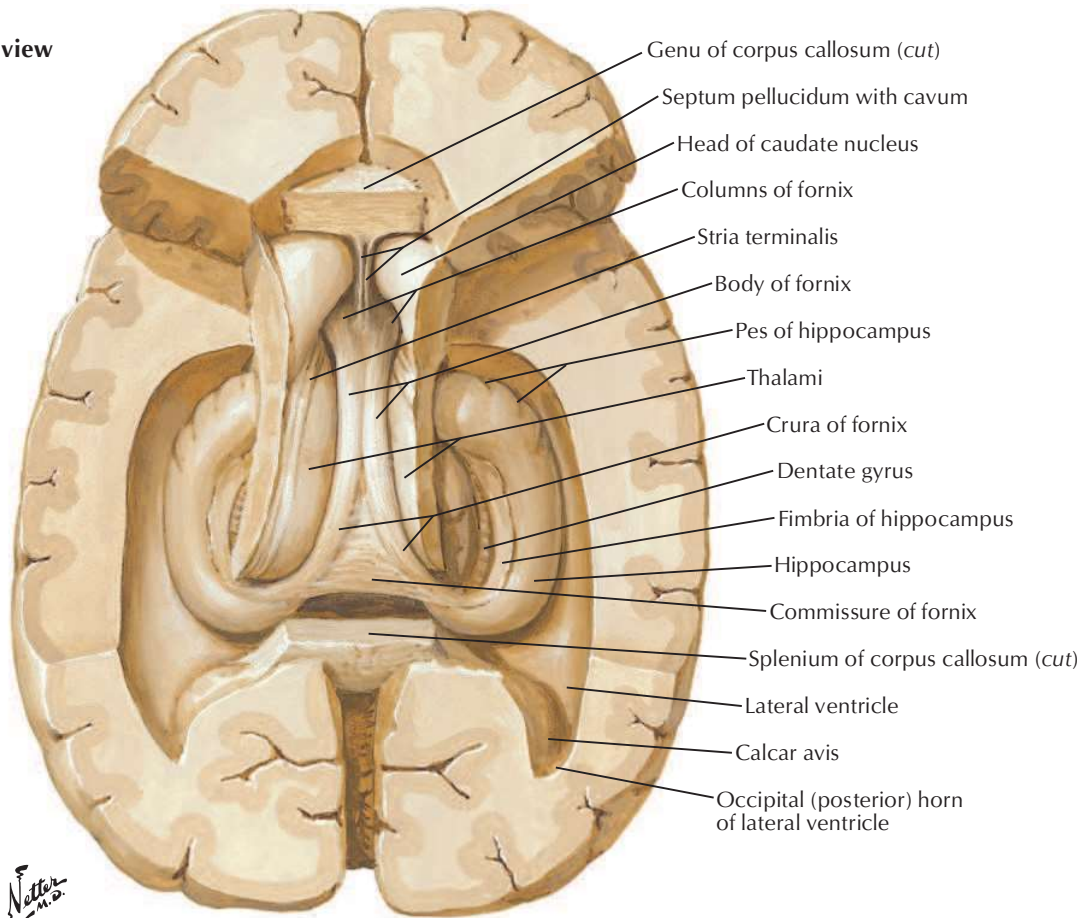
- Thalamic nuclei**
- CM Centromedian
 - LD Lateral dorsal
 - LP Lateral posterior
 - M Medial group
 - MD Medial dorsal
 - VA Ventral anterior
 - VI Ventral intermedial
 - VL Ventral lateral
 - VP Ventral posterior (ventrodorsal)
 - VPL Ventral posterolateral
 - VPM Ventral posteromedial



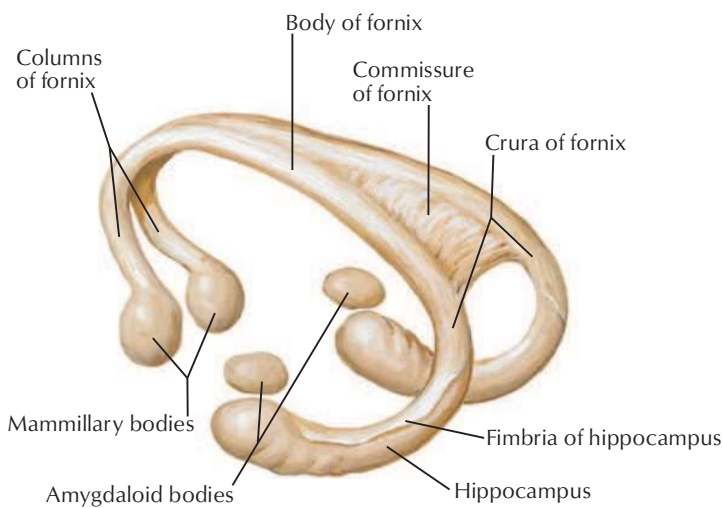
Schematic representation of thalamus
(external medullary lamina and reticular nuclei removed)

- Orange Lateral cell mass
- Blue Medial and median cell mass
- Yellow Anterior cell mass

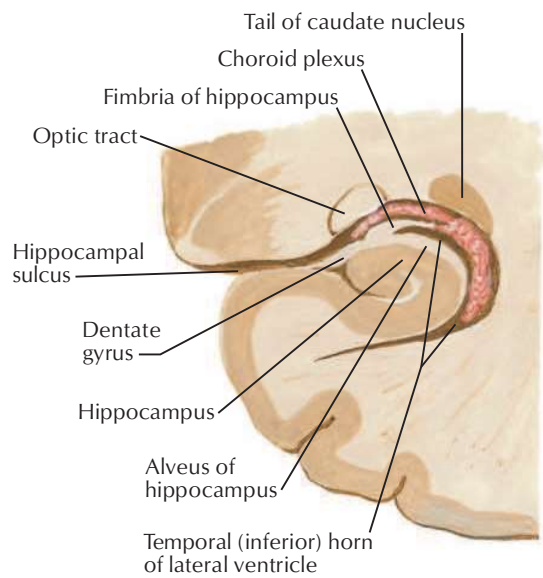
Superior view



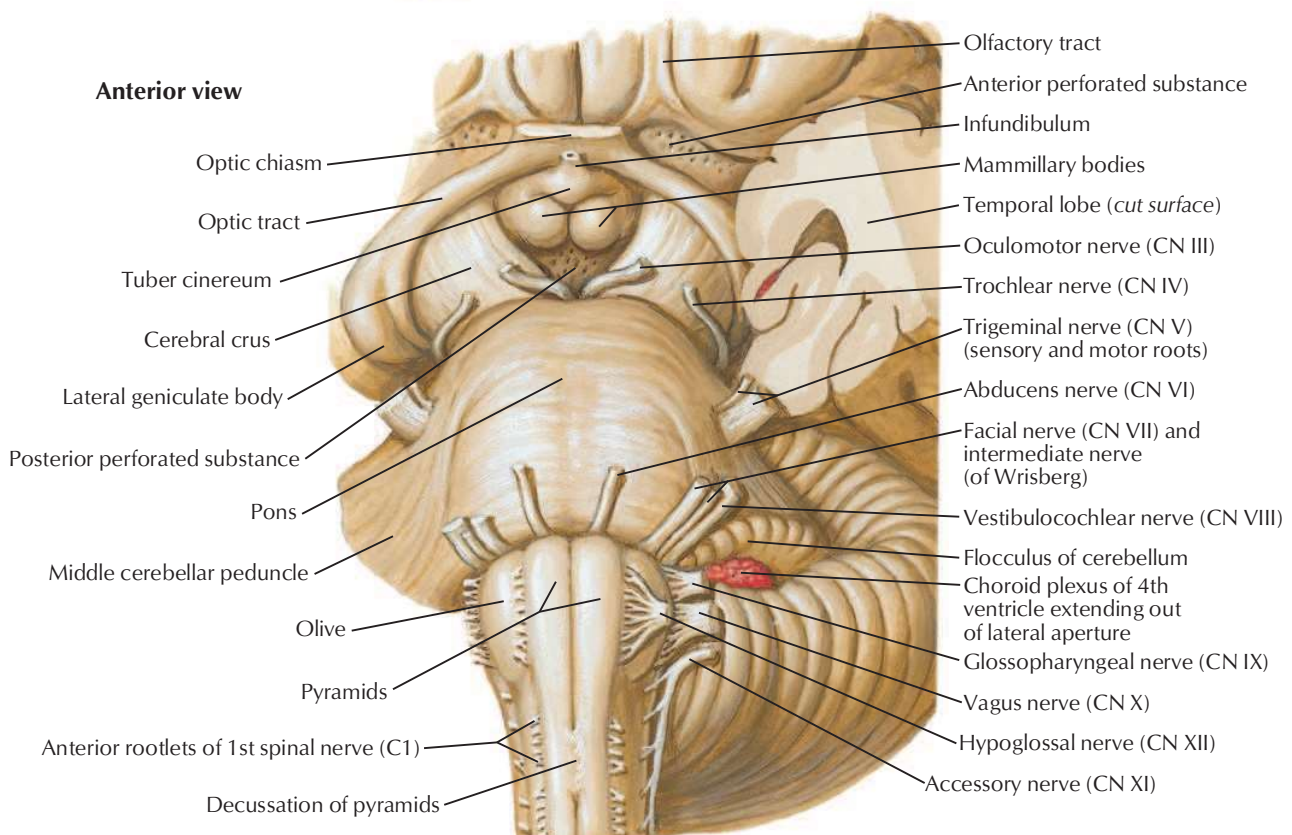
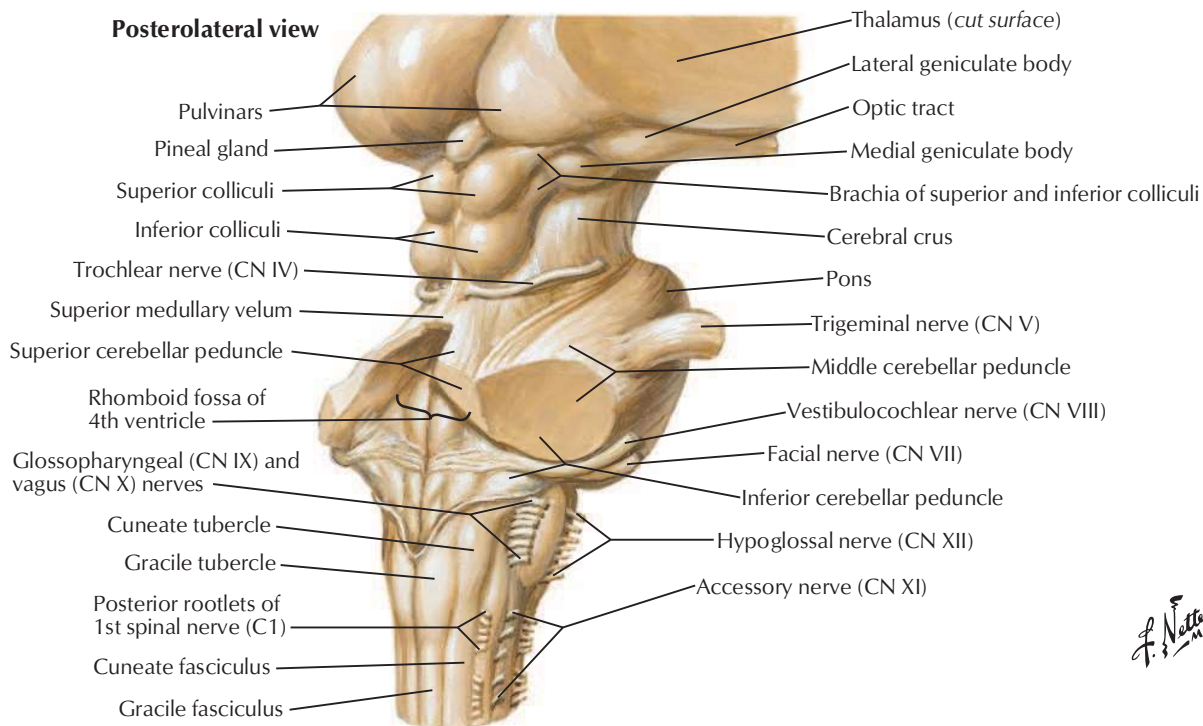
F. Netter M.D.

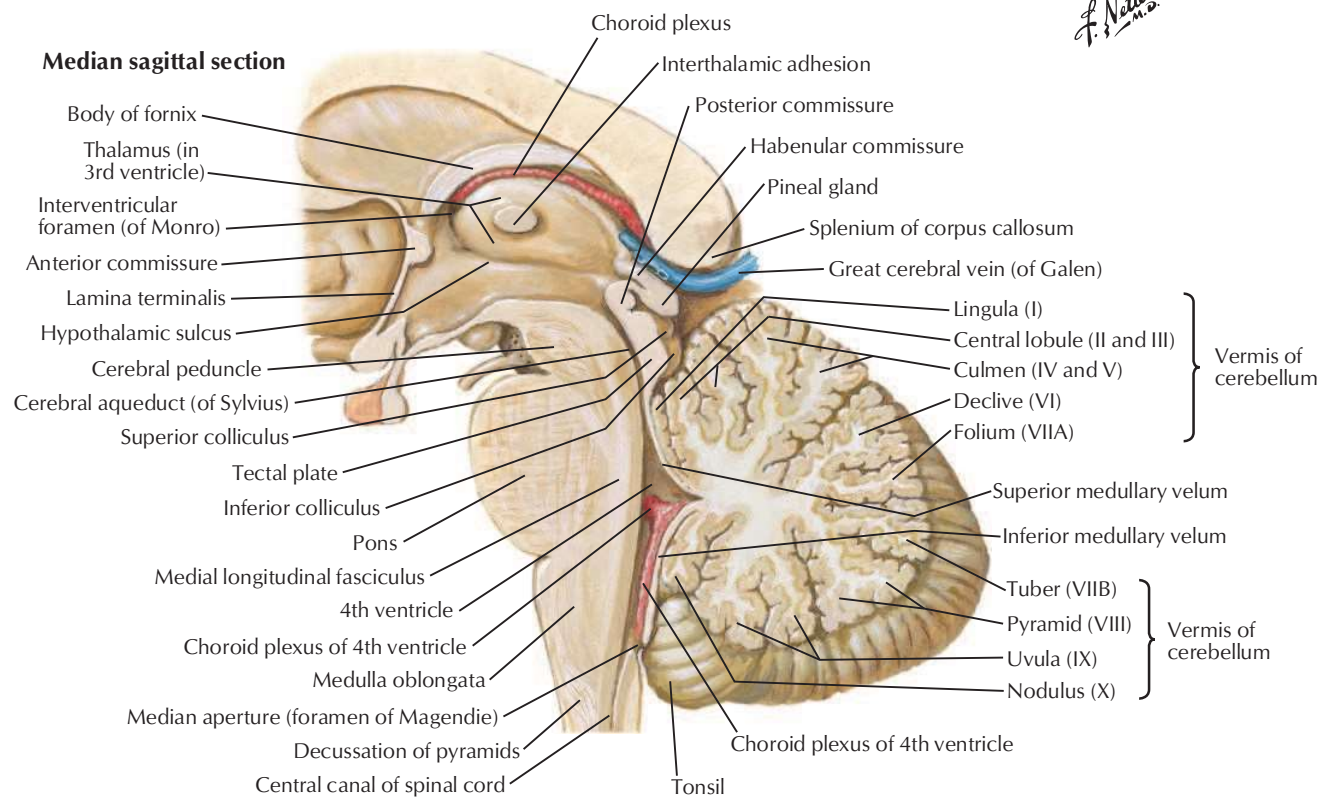
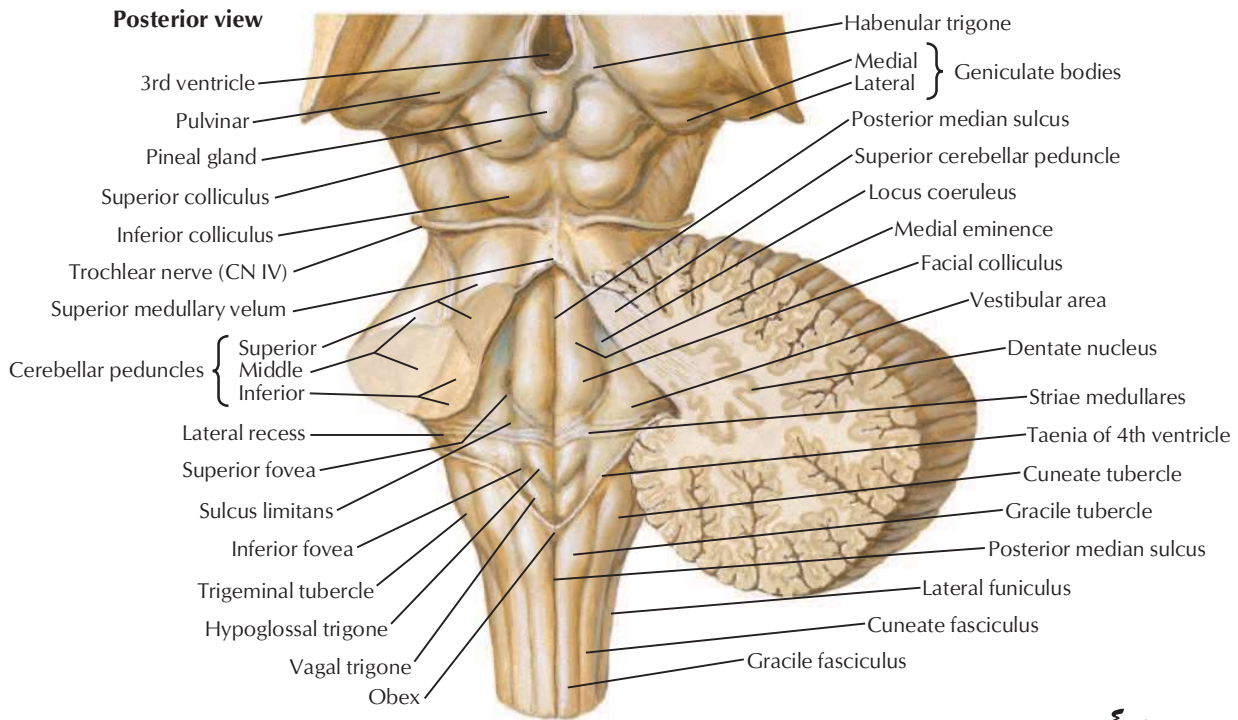


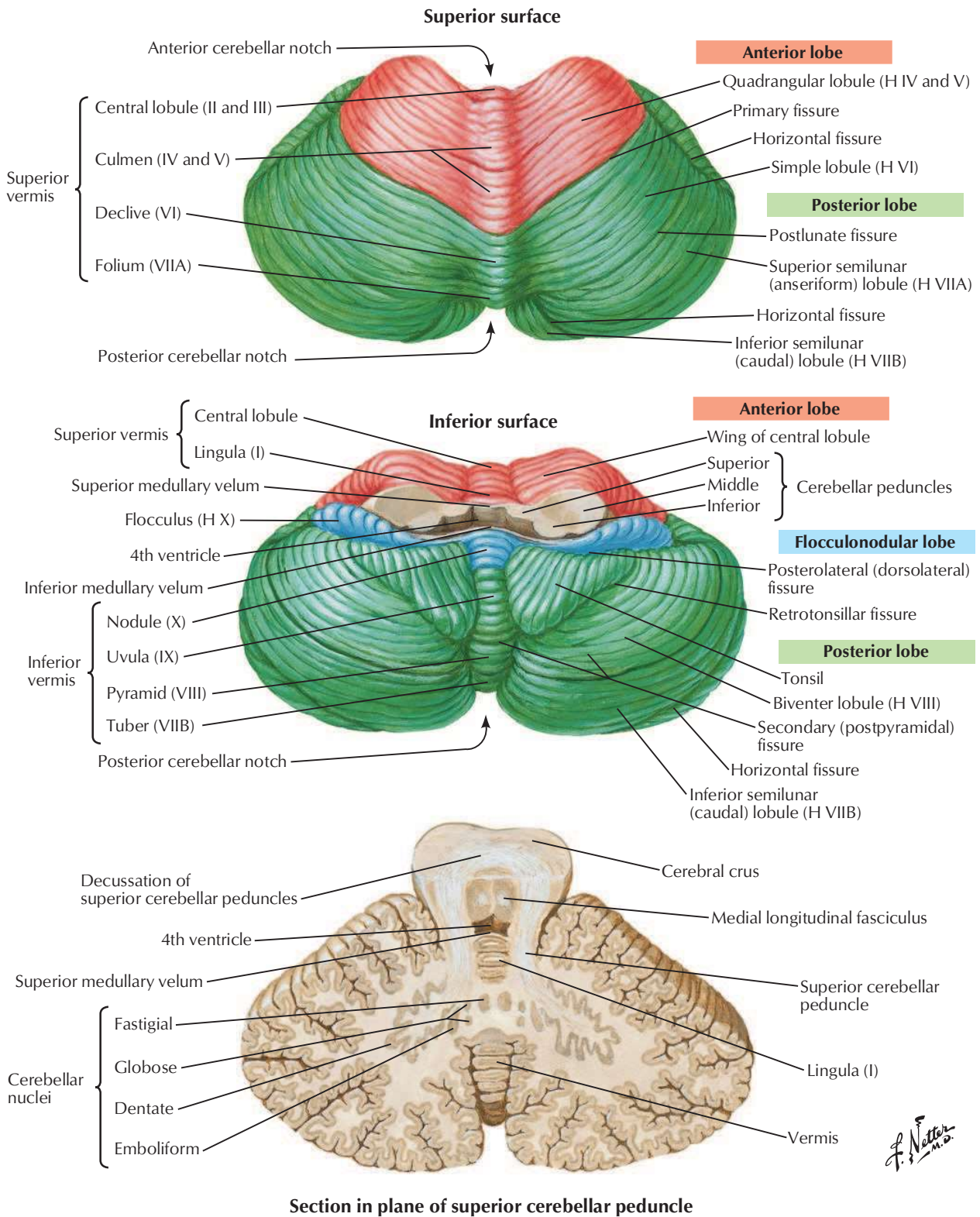
Fornix: schema



Coronal section: posterior view

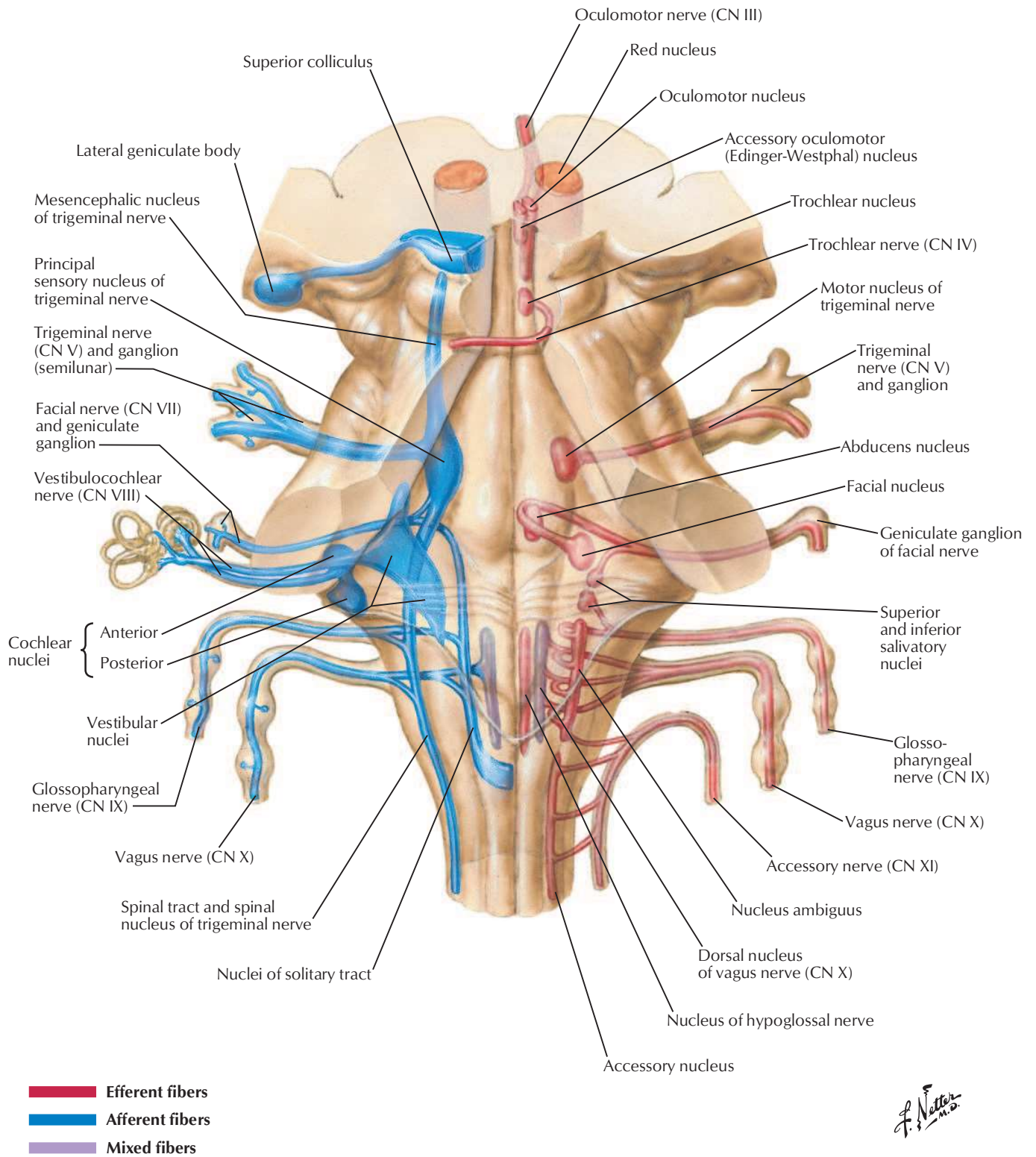


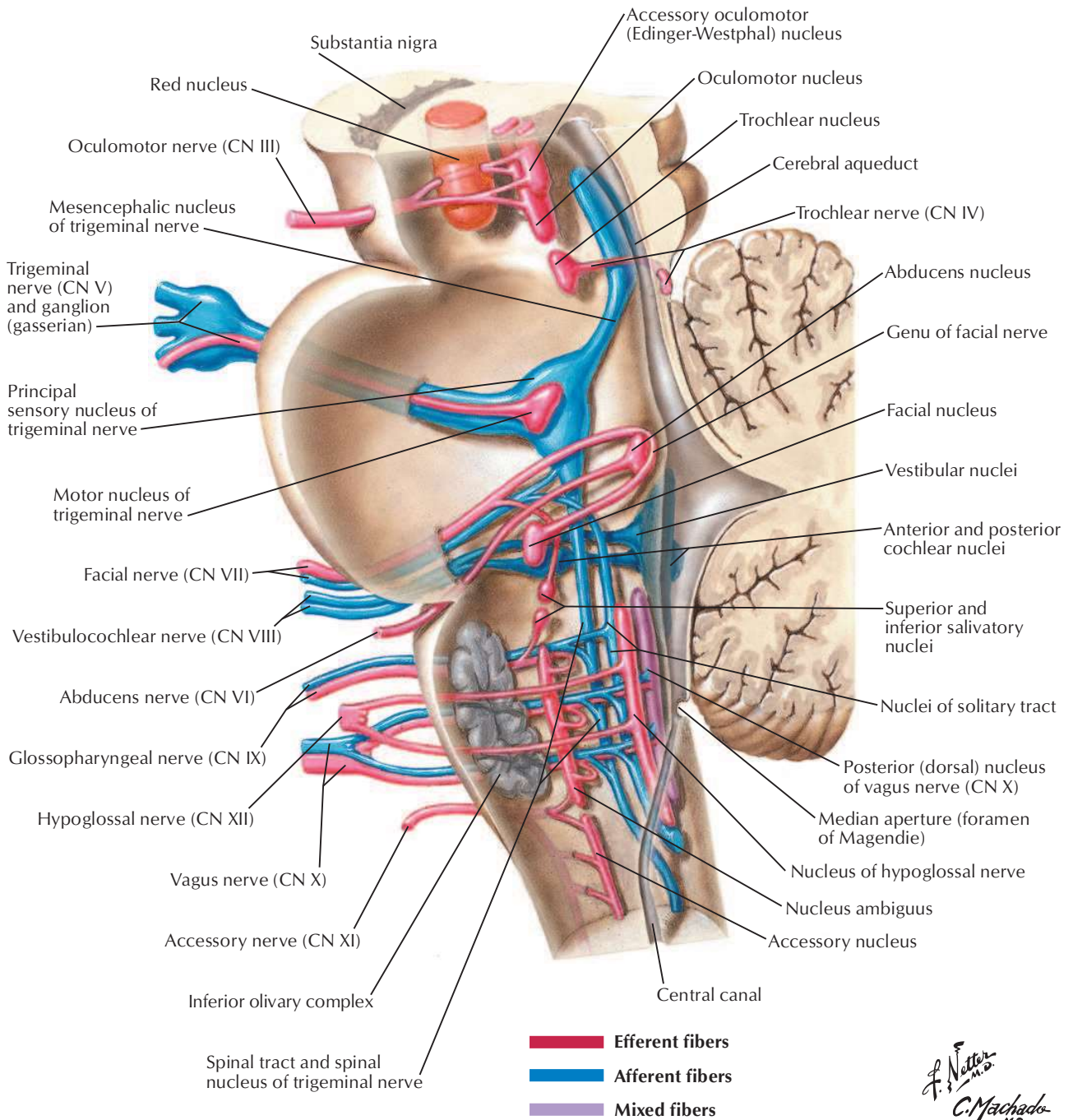




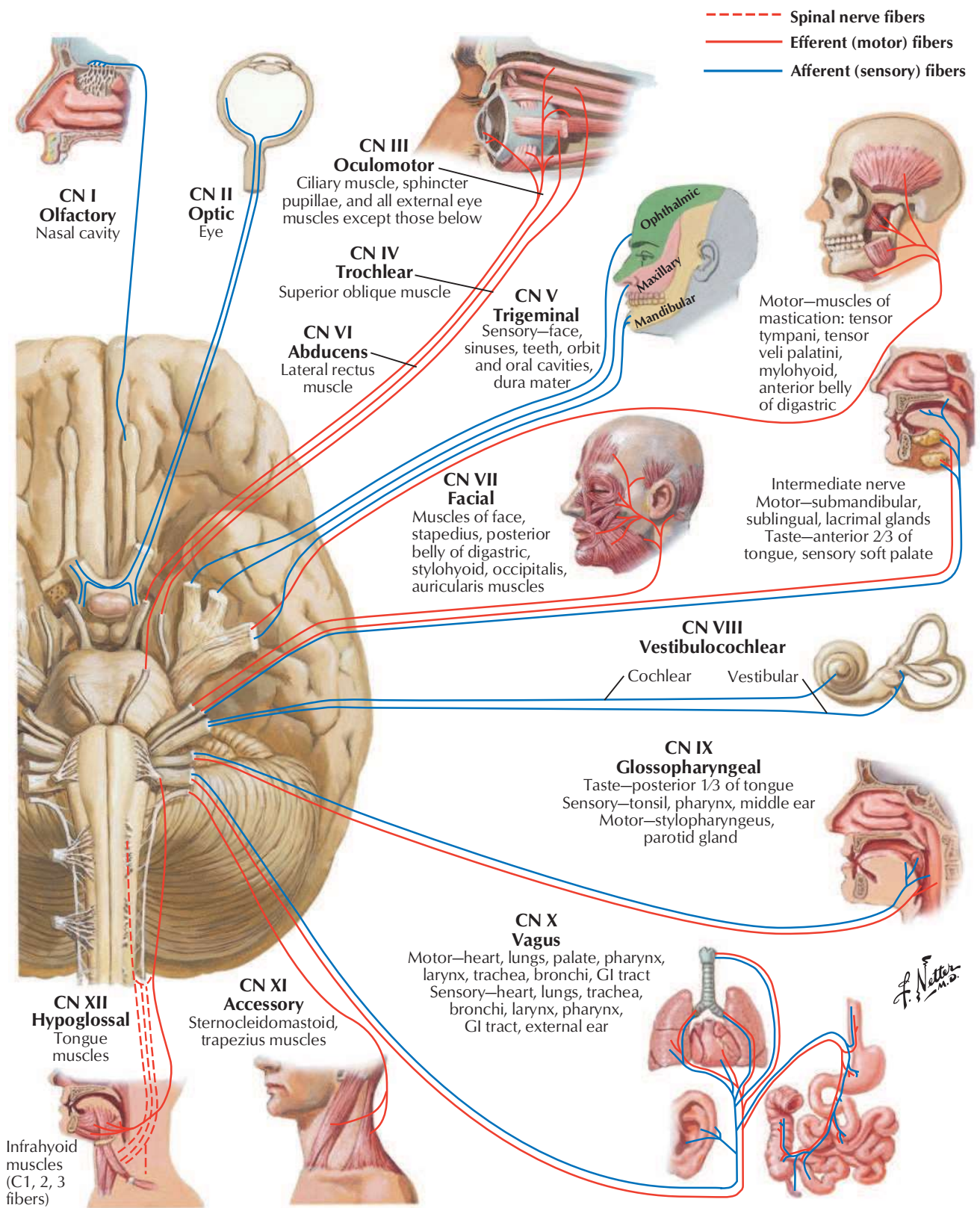
F. Netter M.D.

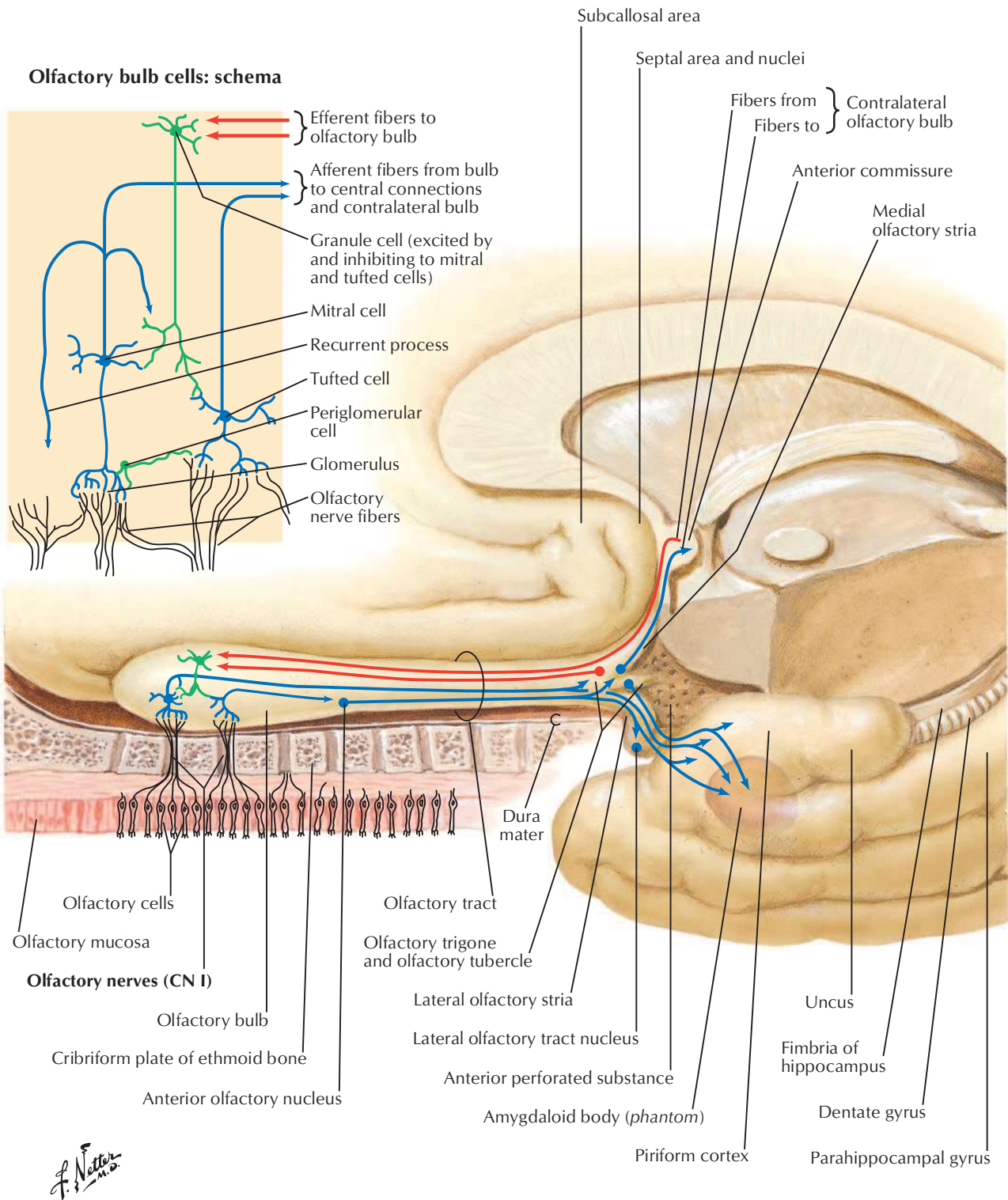
Cranial Nerve Nuclei in Brain Stem: Schema



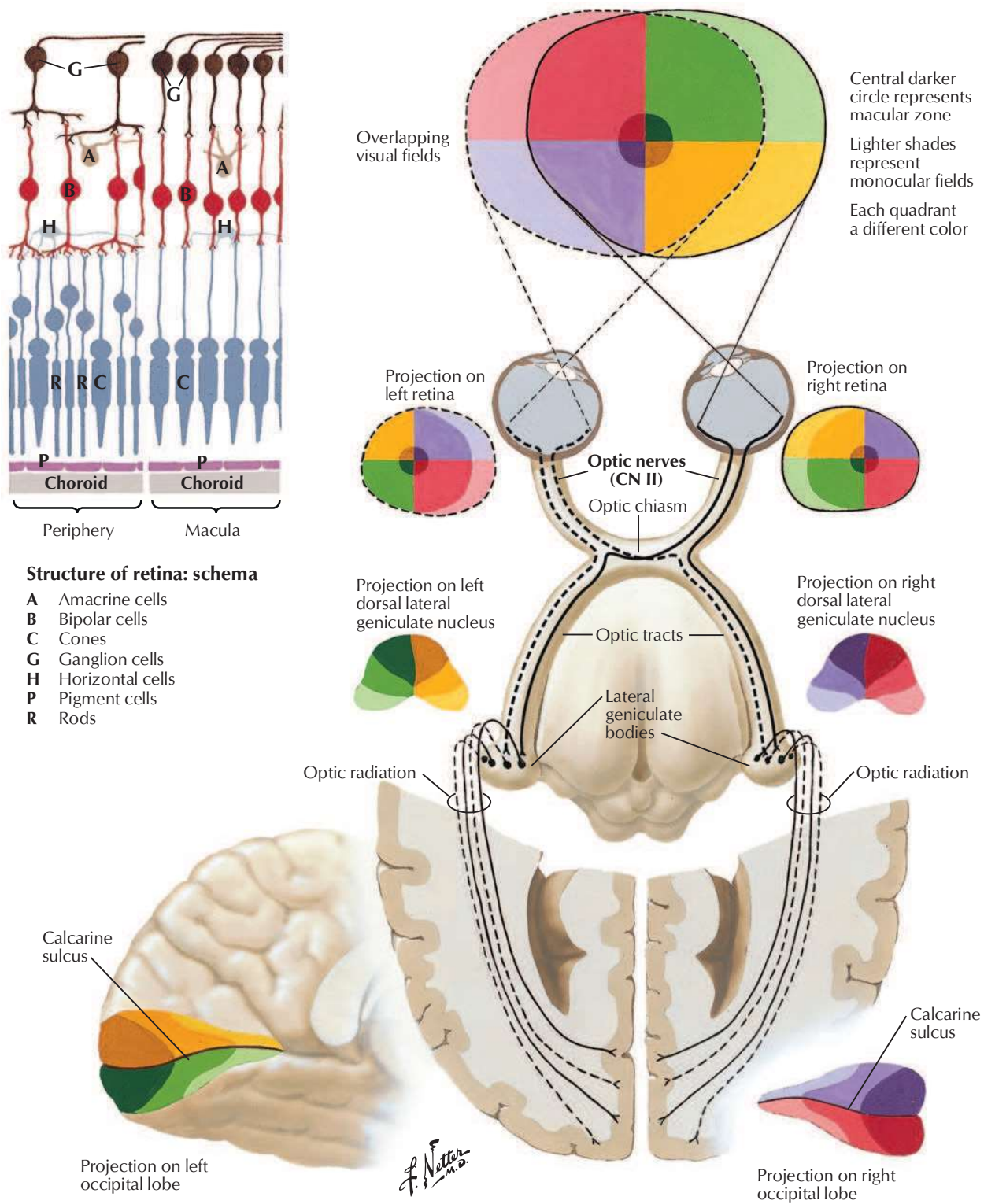


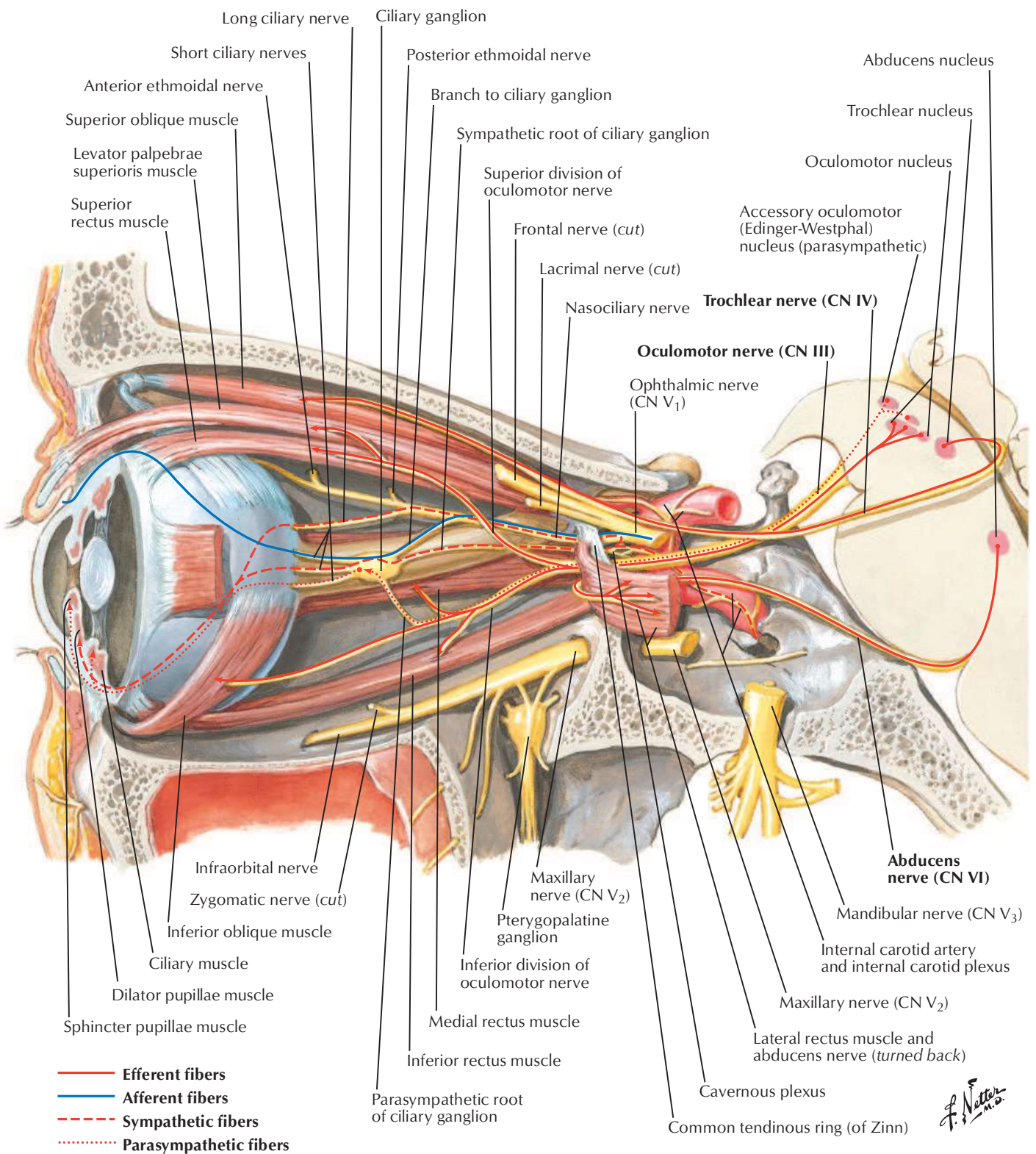
Cranial Nerves (Motor and Sensory Distribution): Schema





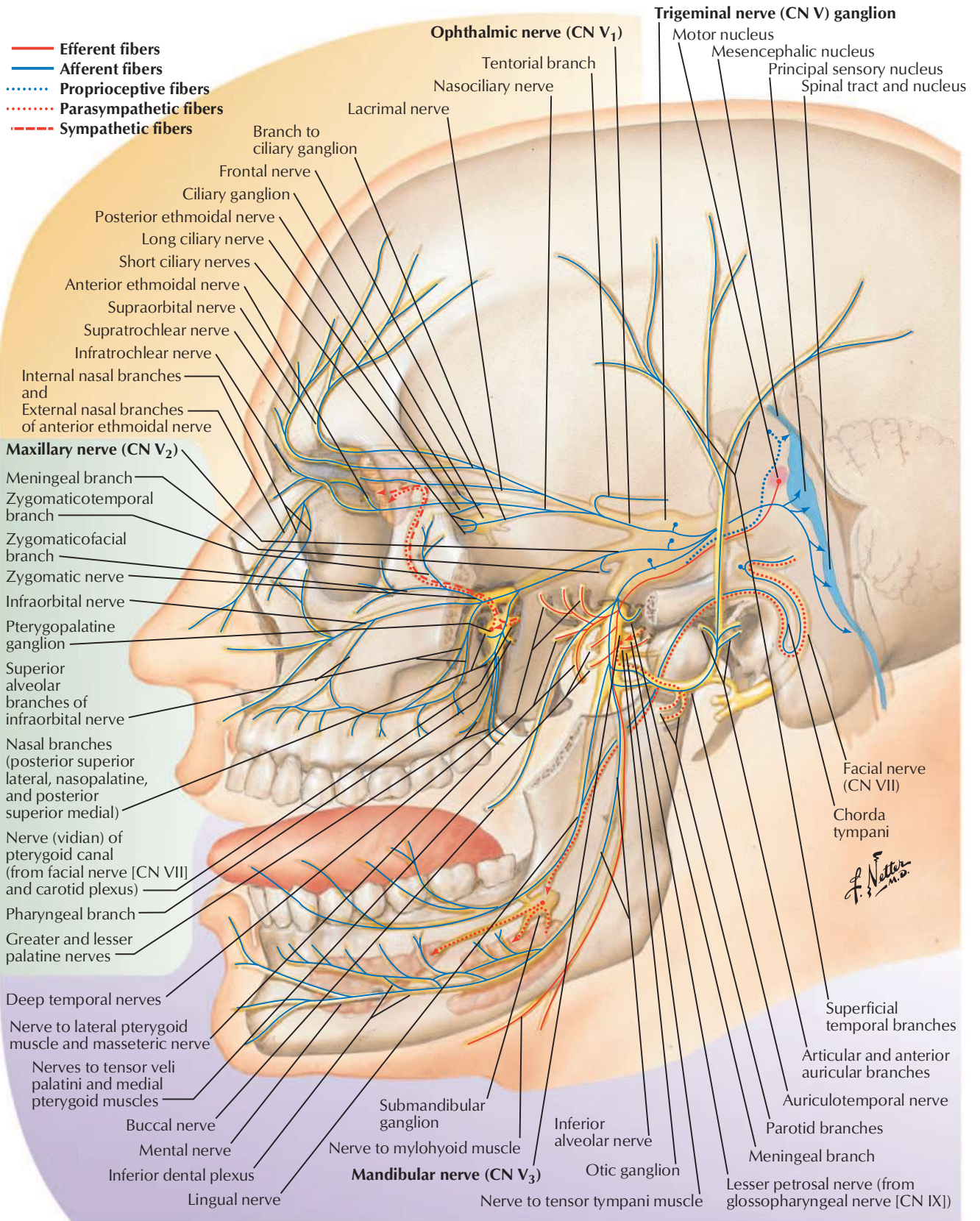
Optic Nerve (CN II) (Visual Pathway): Schema

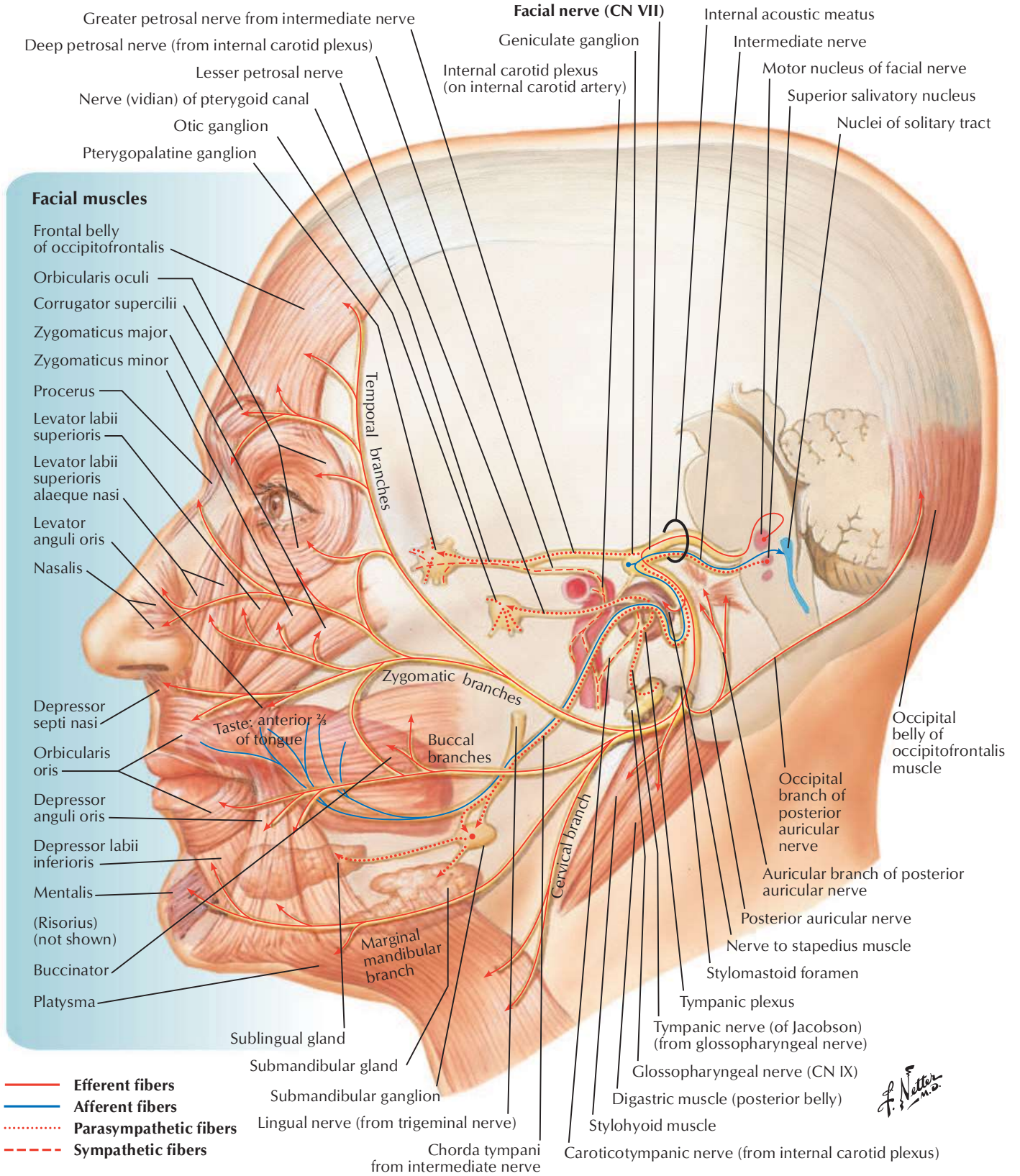




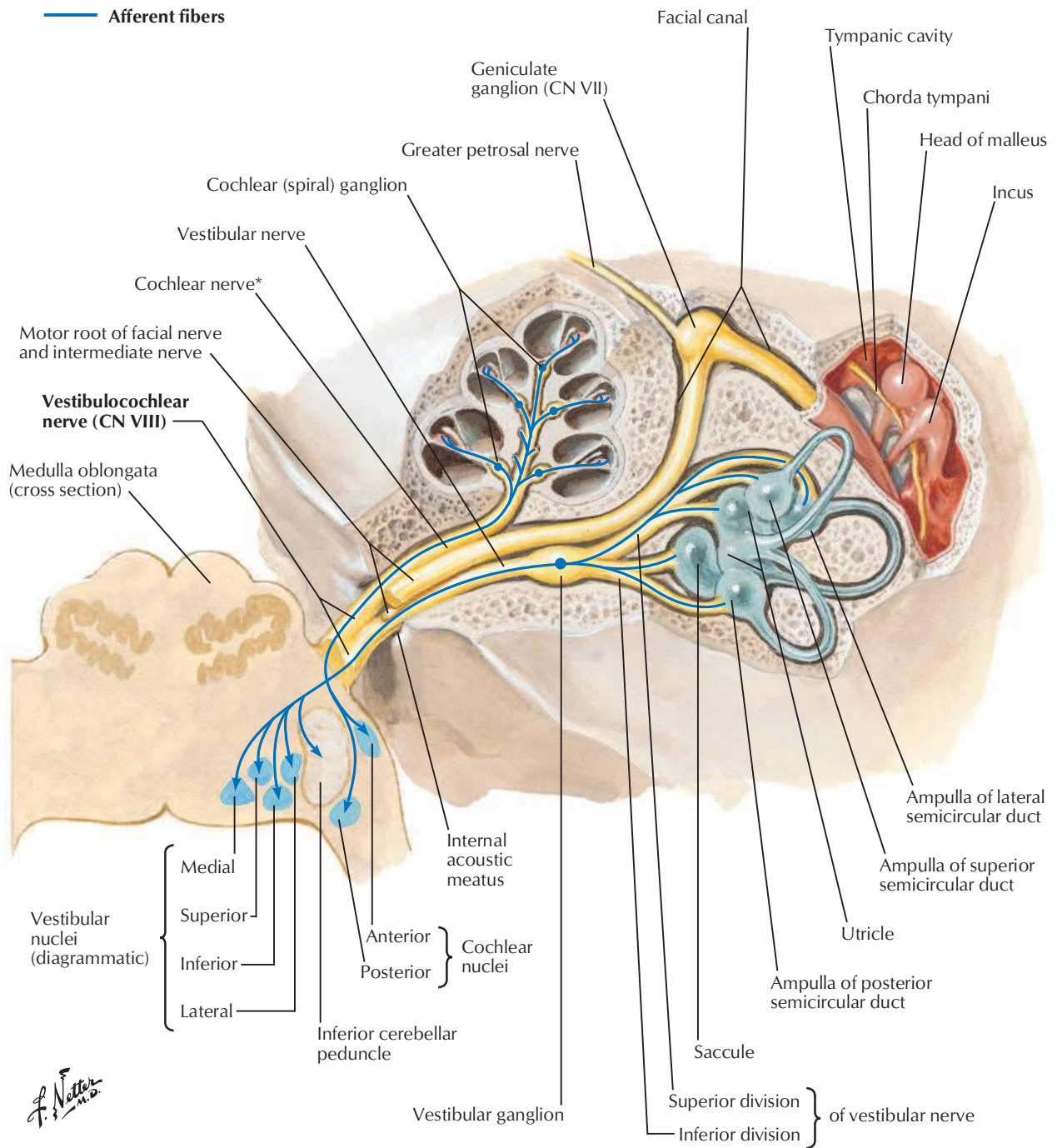
Trigeminal Nerve (CN V): Schema

See also [Plates 9, 59, 61](#)

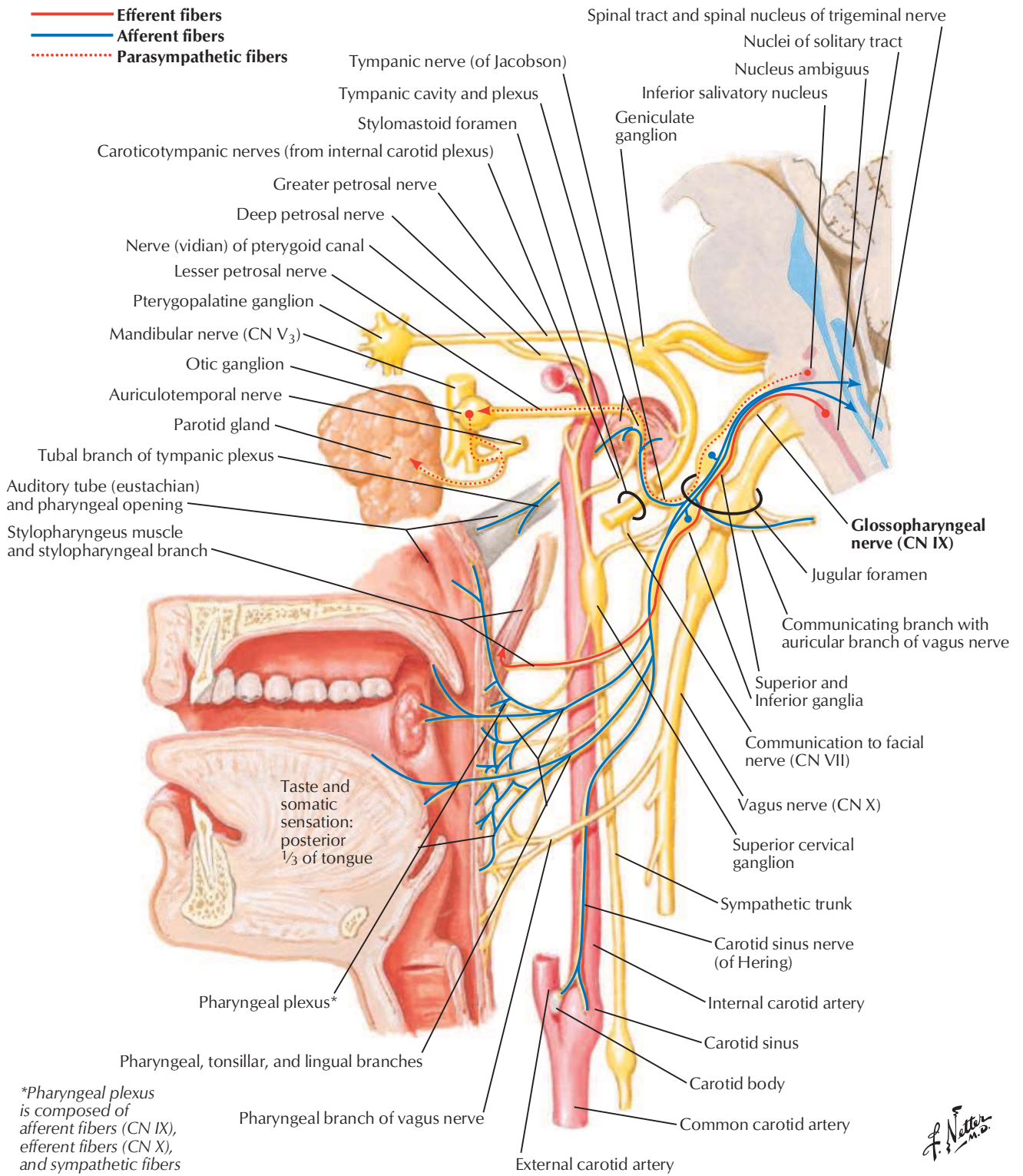




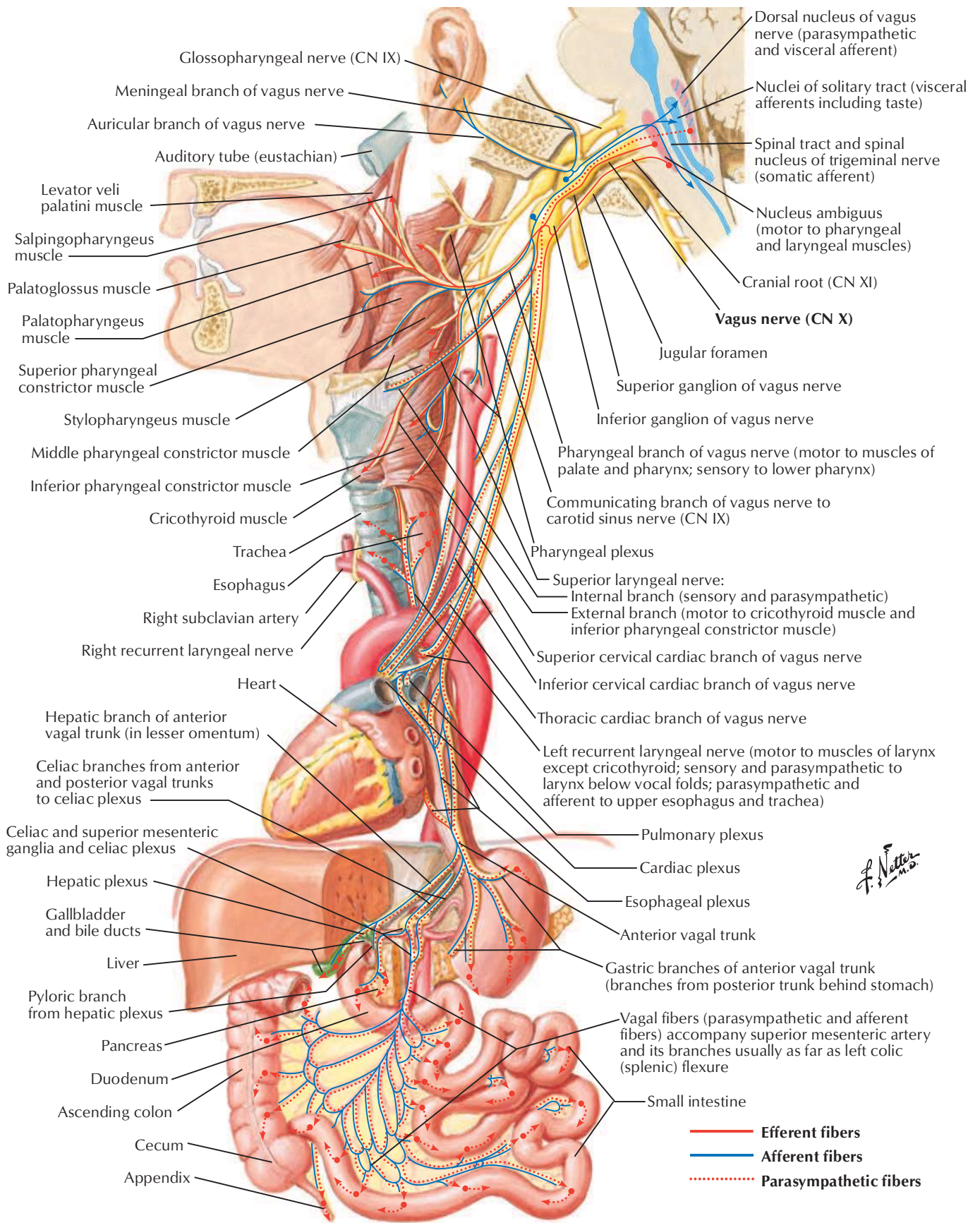
Vestibulocochlear Nerve (CN VIII): Schema

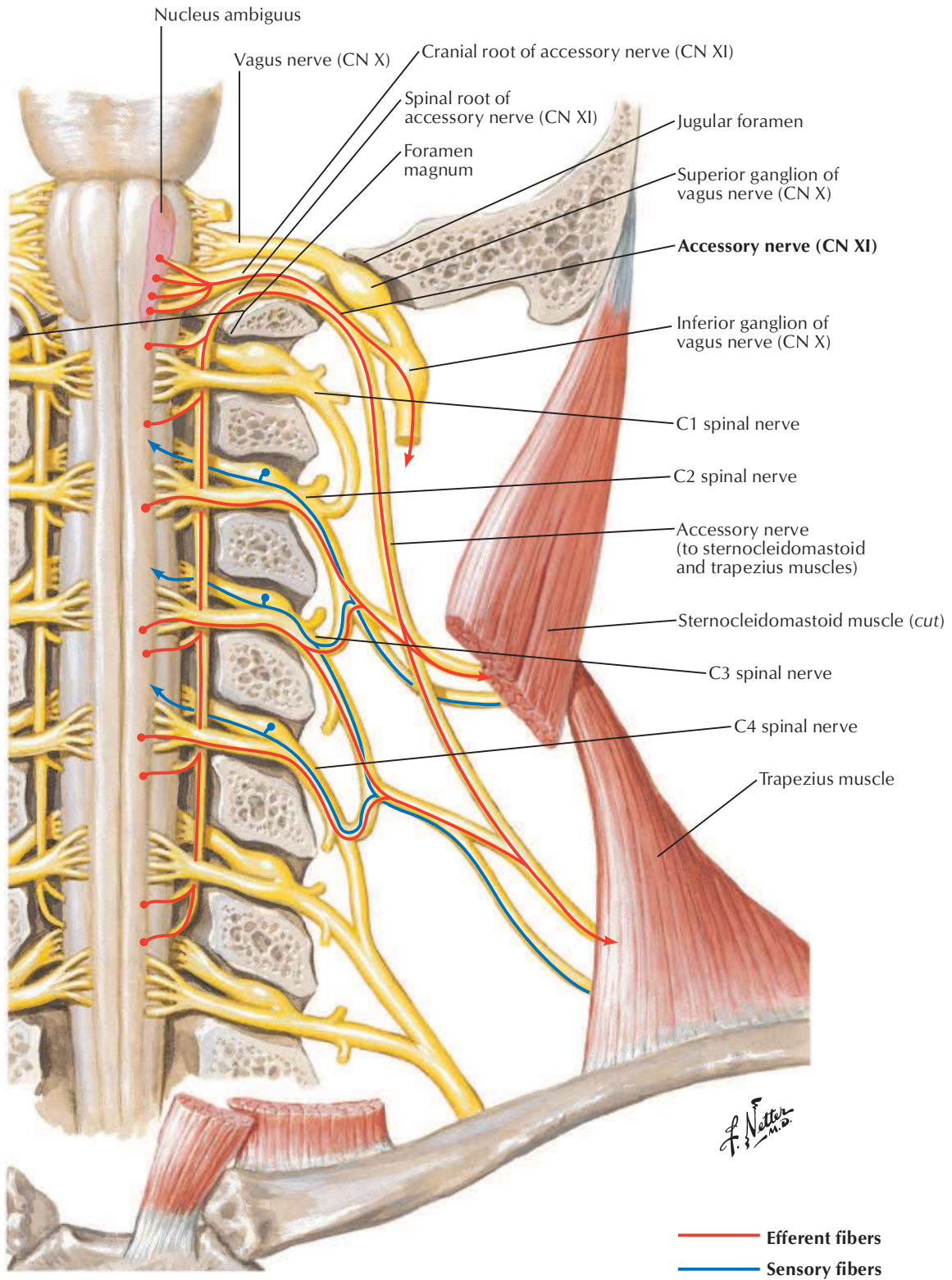


*Note: The cochlear nerve also contains efferent fibers to the sensory epithelium. These fibers are derived from the vestibular nerve while in the internal acoustic meatus.



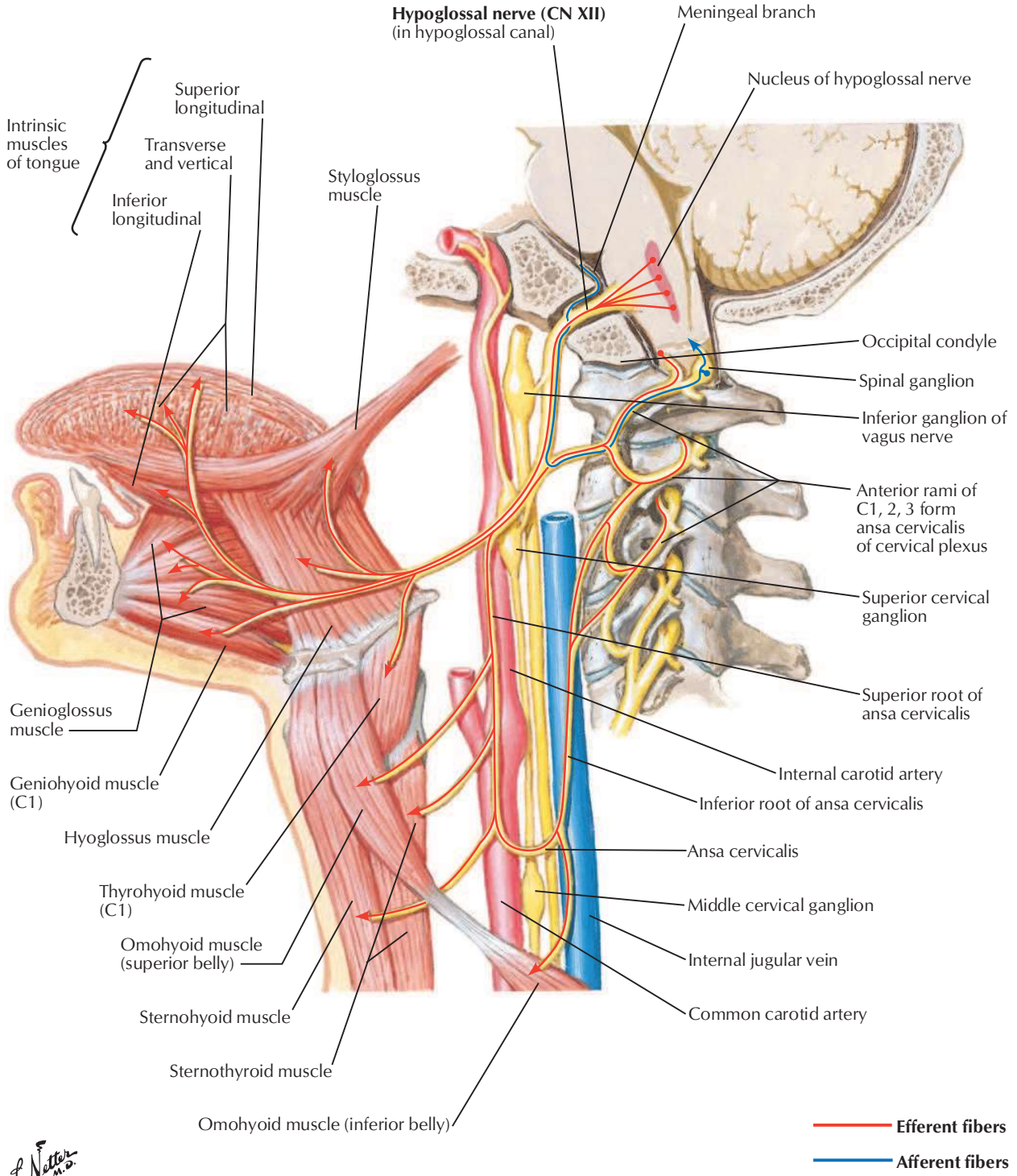
Vagus Nerve (CN X): Schema

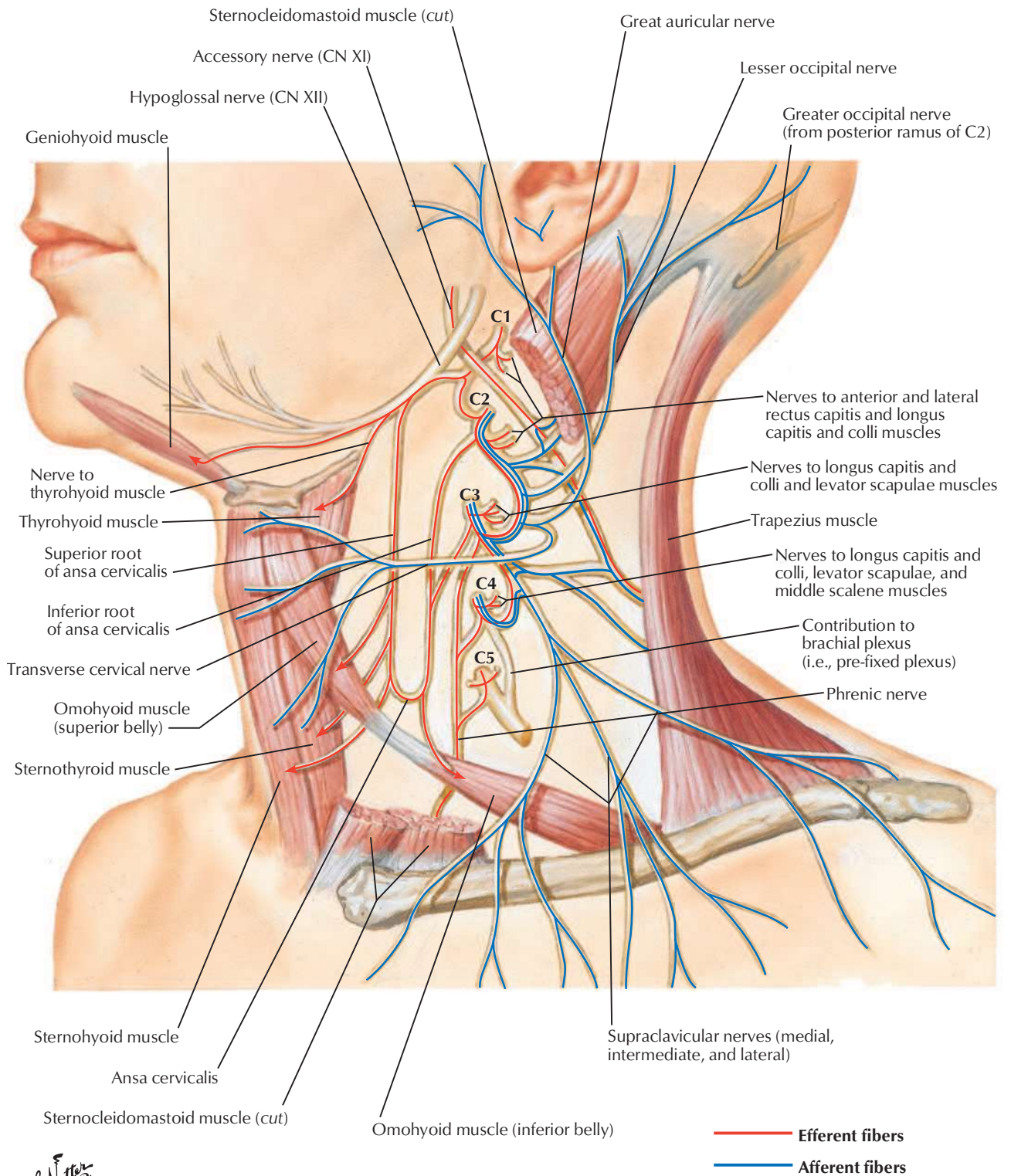




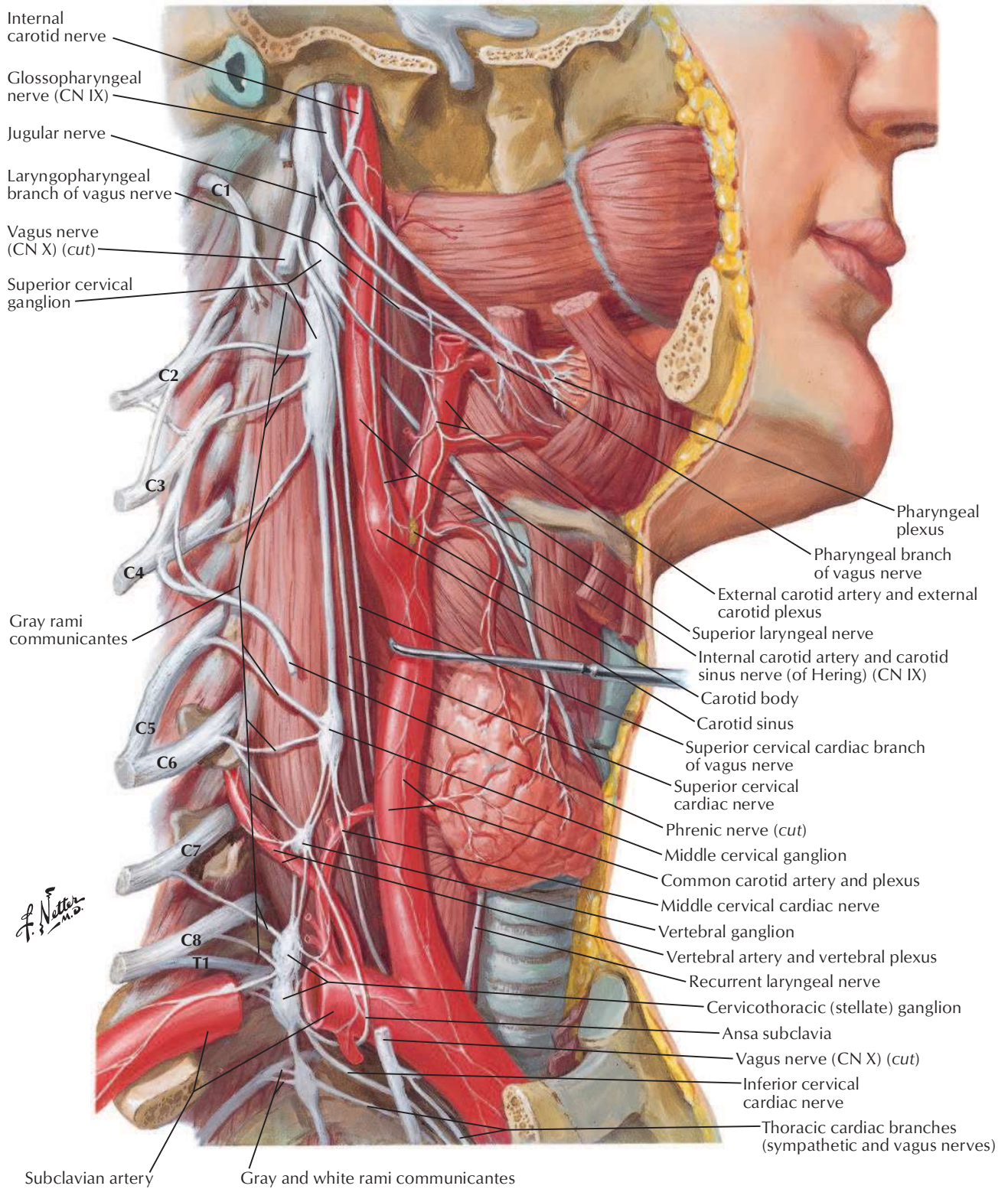
Hypoglossal Nerve (CN XII): Schema

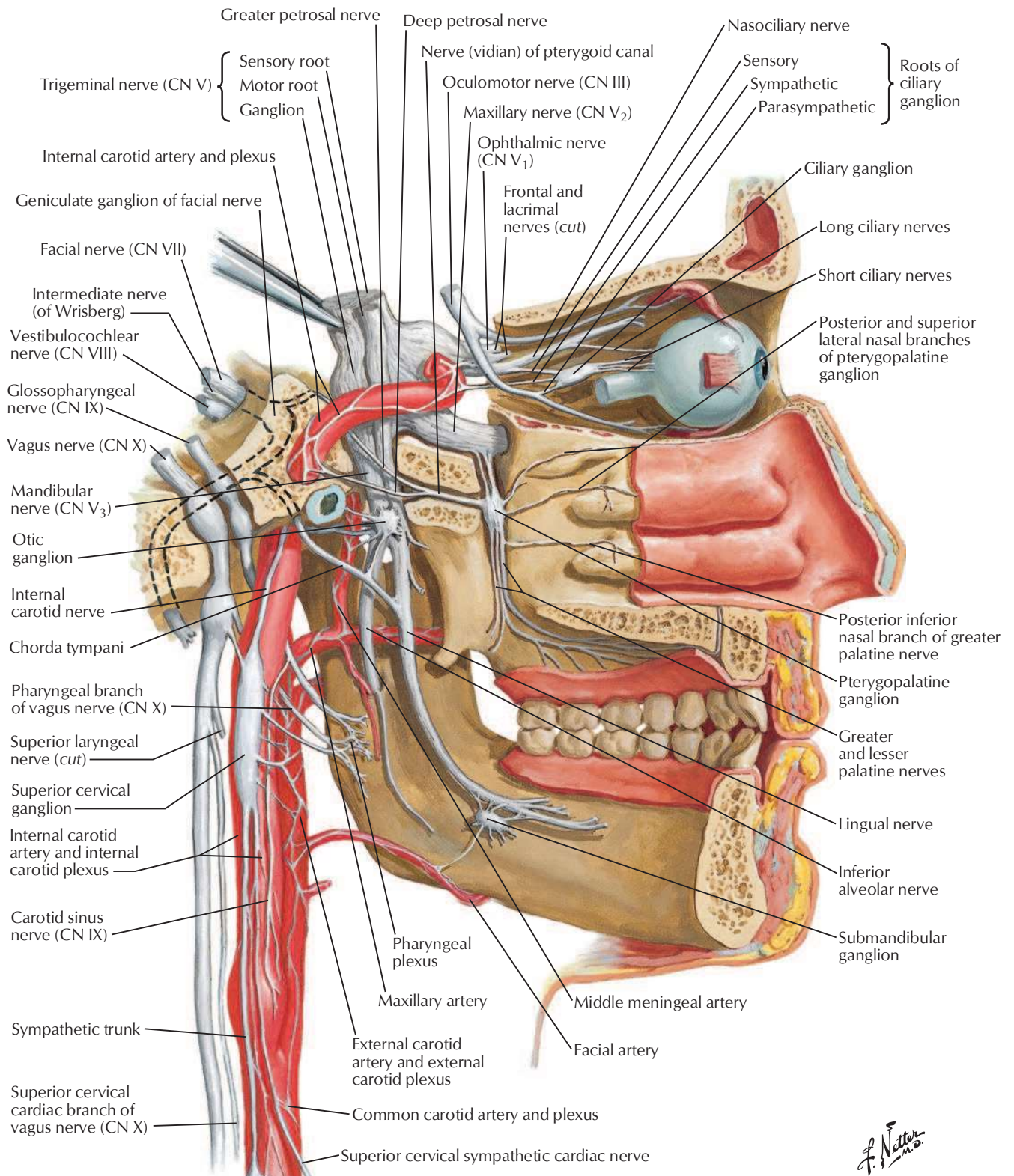
See also [Plate 39](#)





F. Netter M.D.

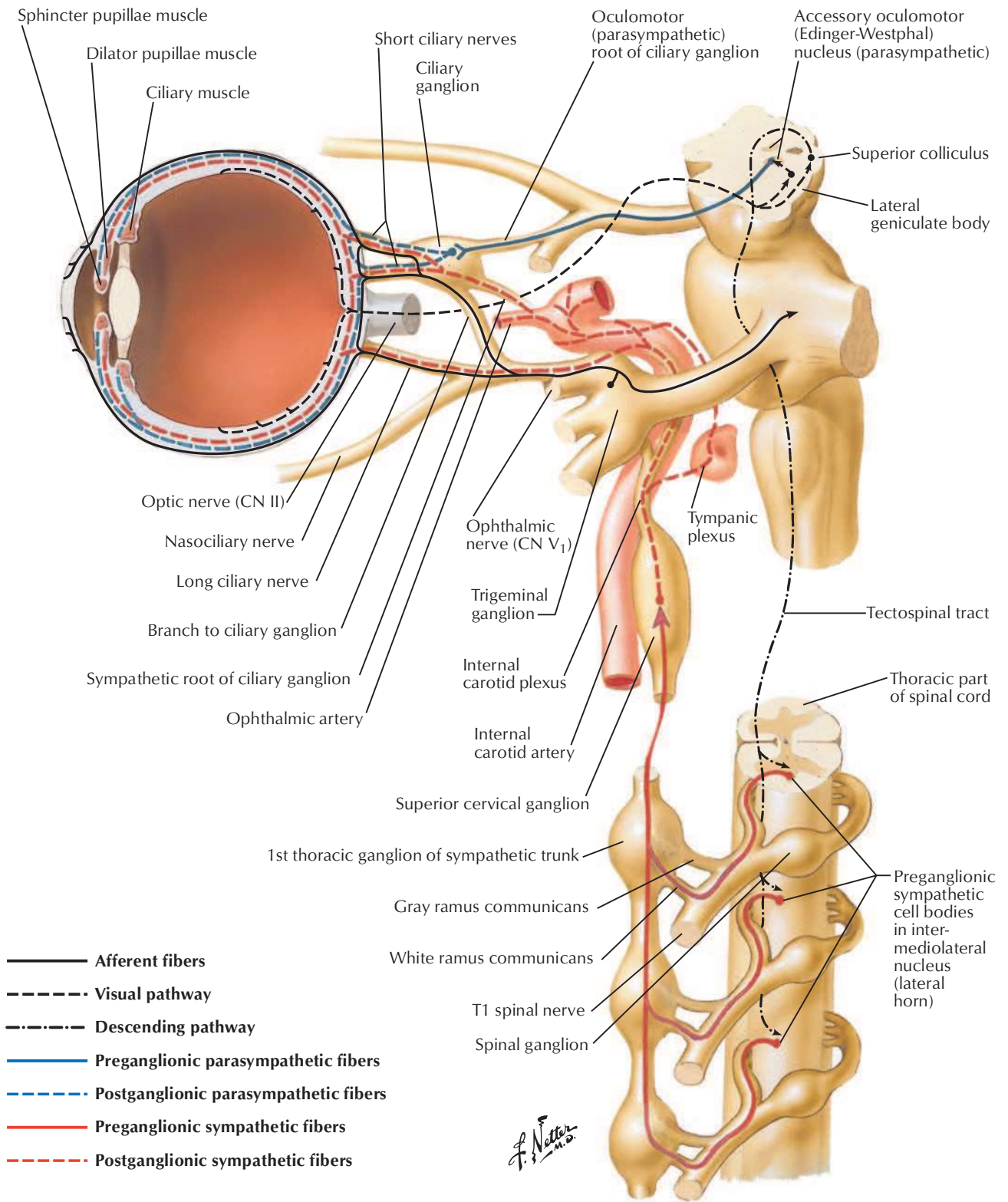


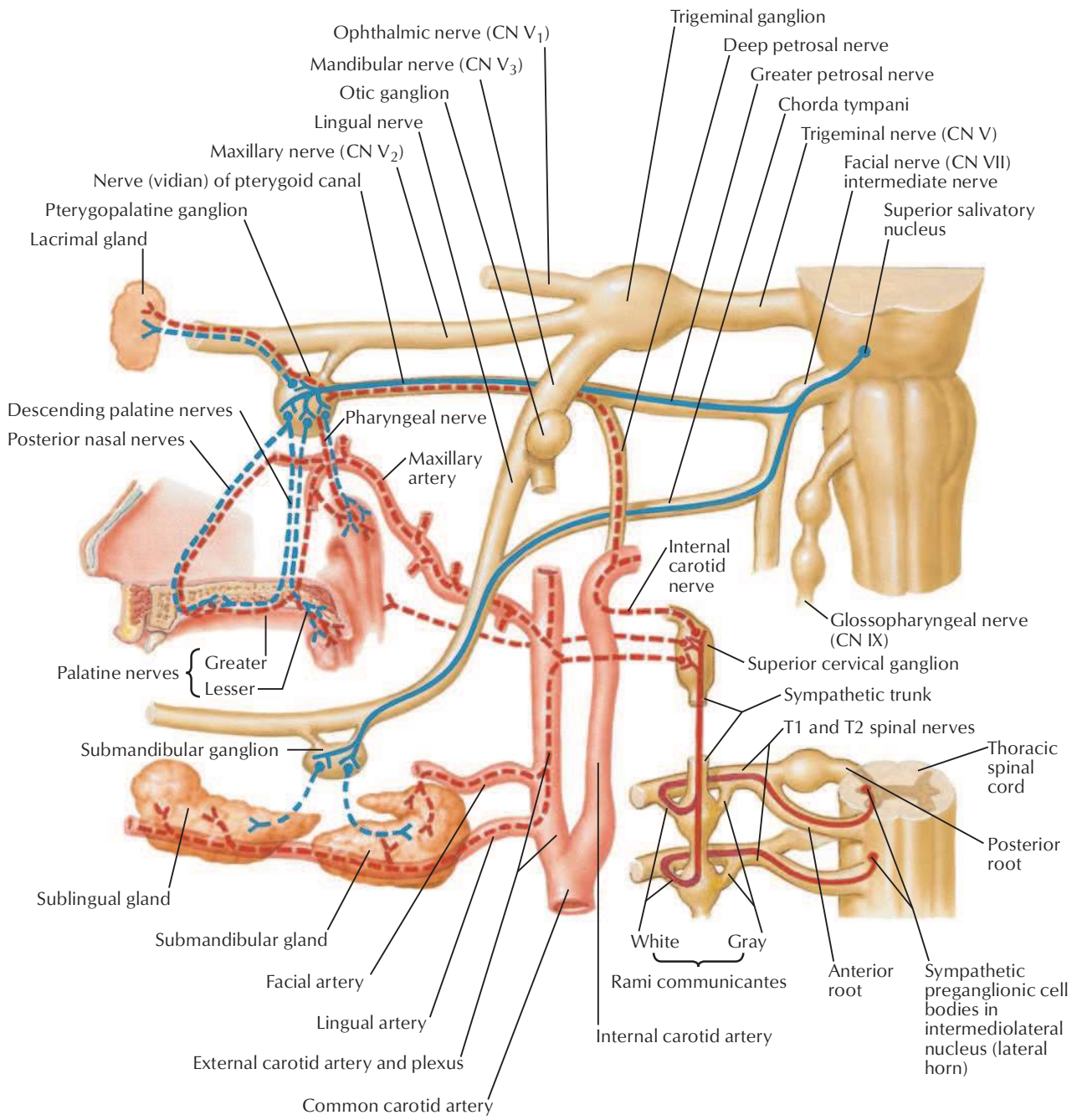


F. Netter M.D.

Ciliary Ganglion: Schema

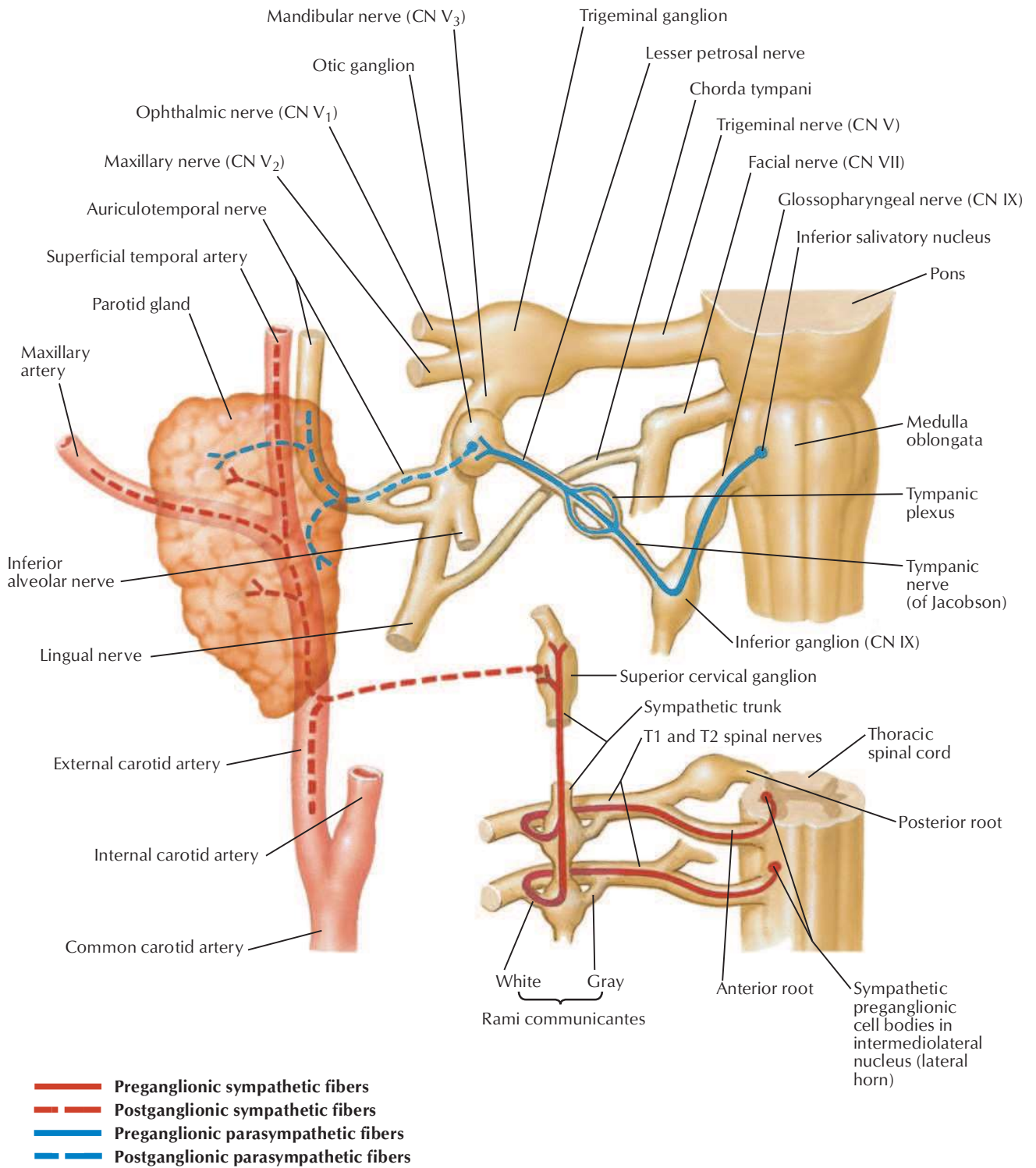
See also [Plate 62](#)

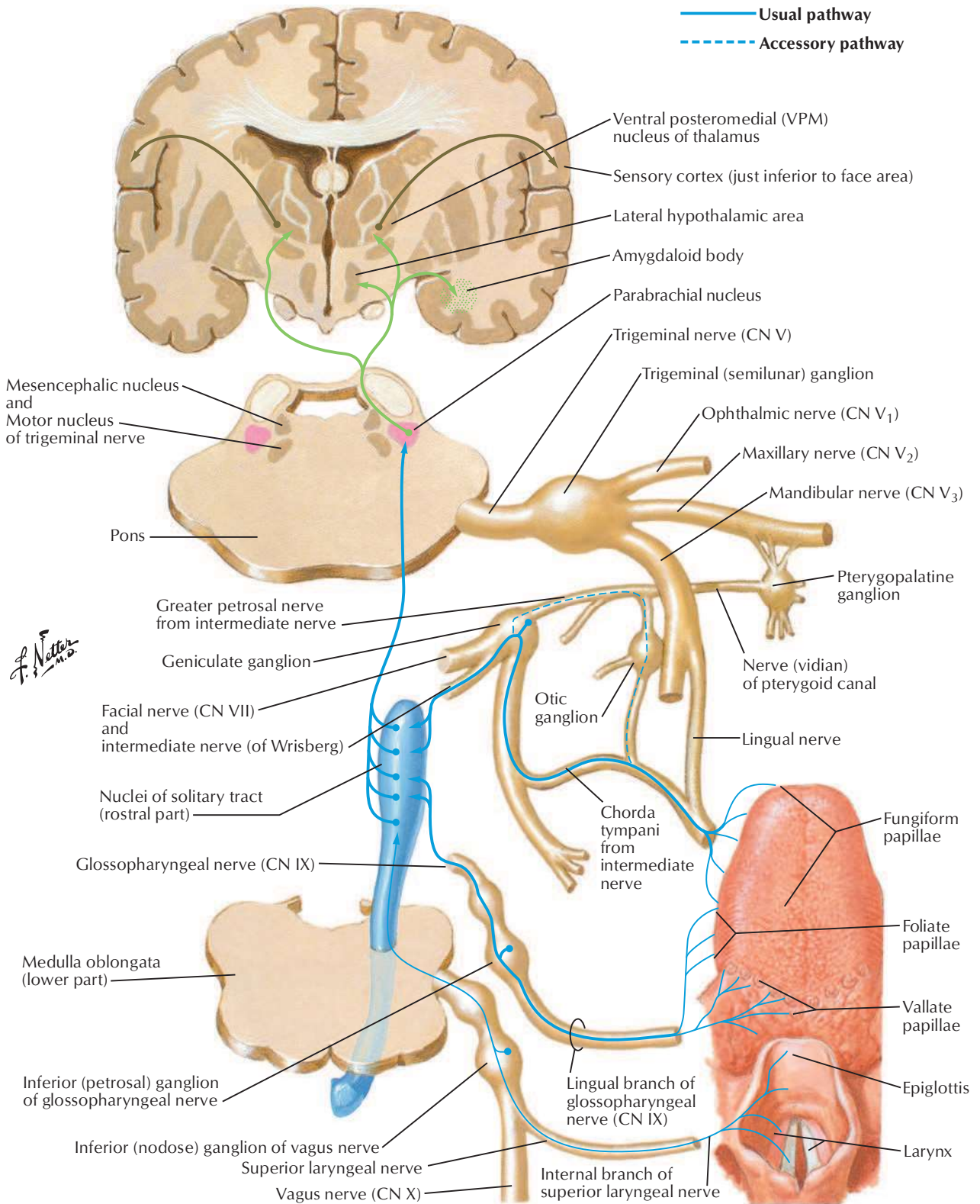




F. Netter M.D.

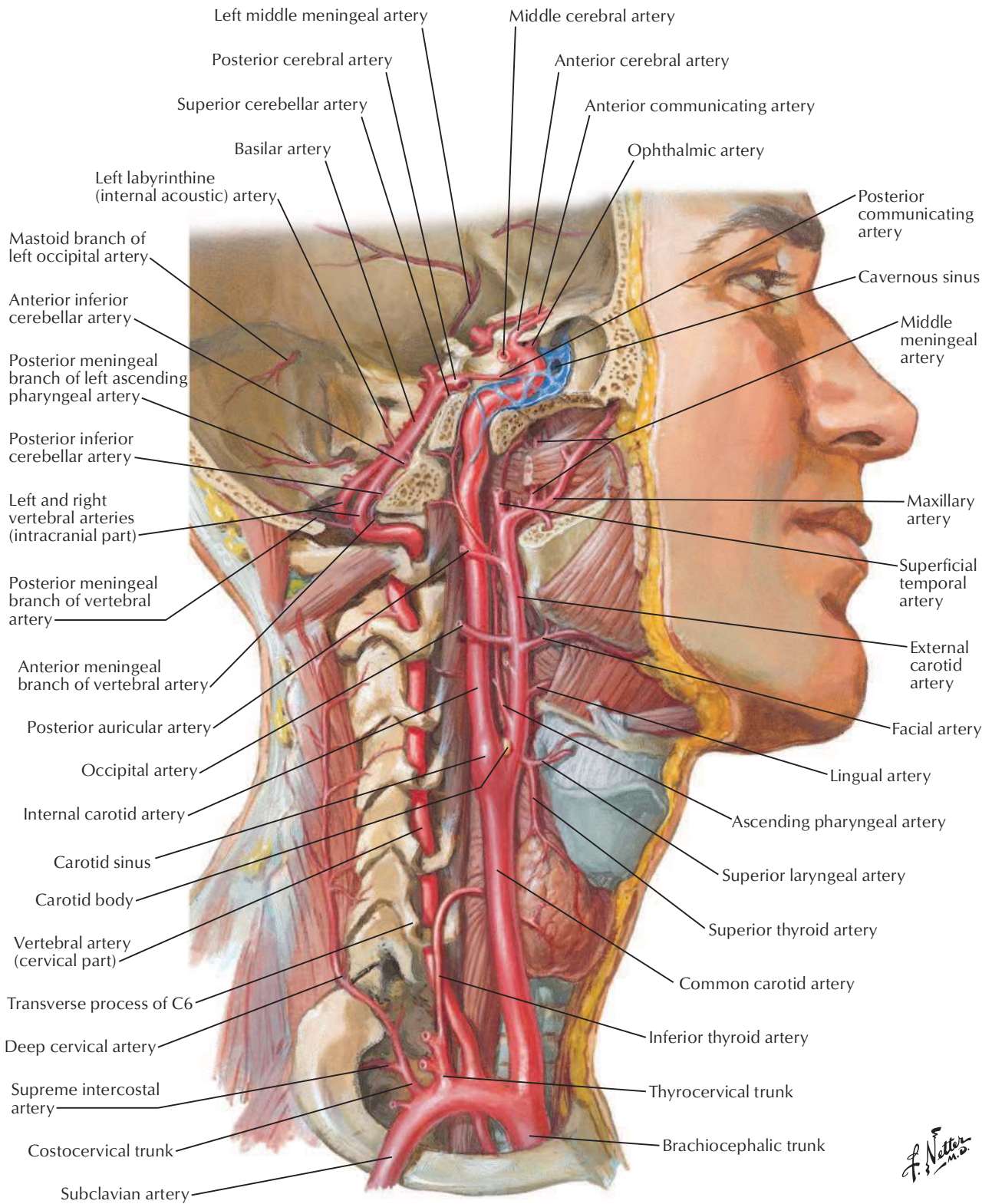
- Preganglionic sympathetic fibers
- - - Postganglionic sympathetic fibers
- Preganglionic parasympathetic fibers
- - - Postganglionic parasympathetic fibers

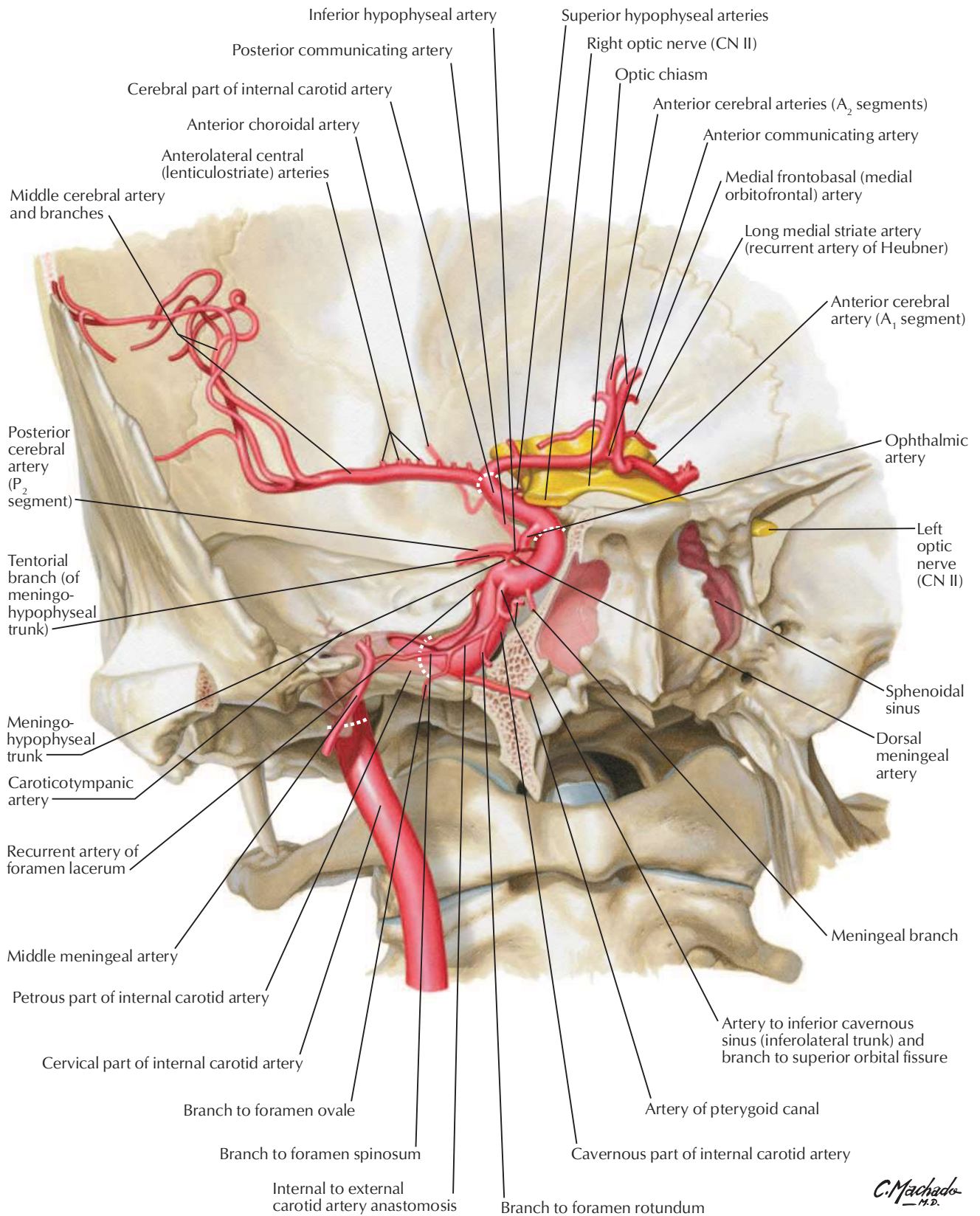




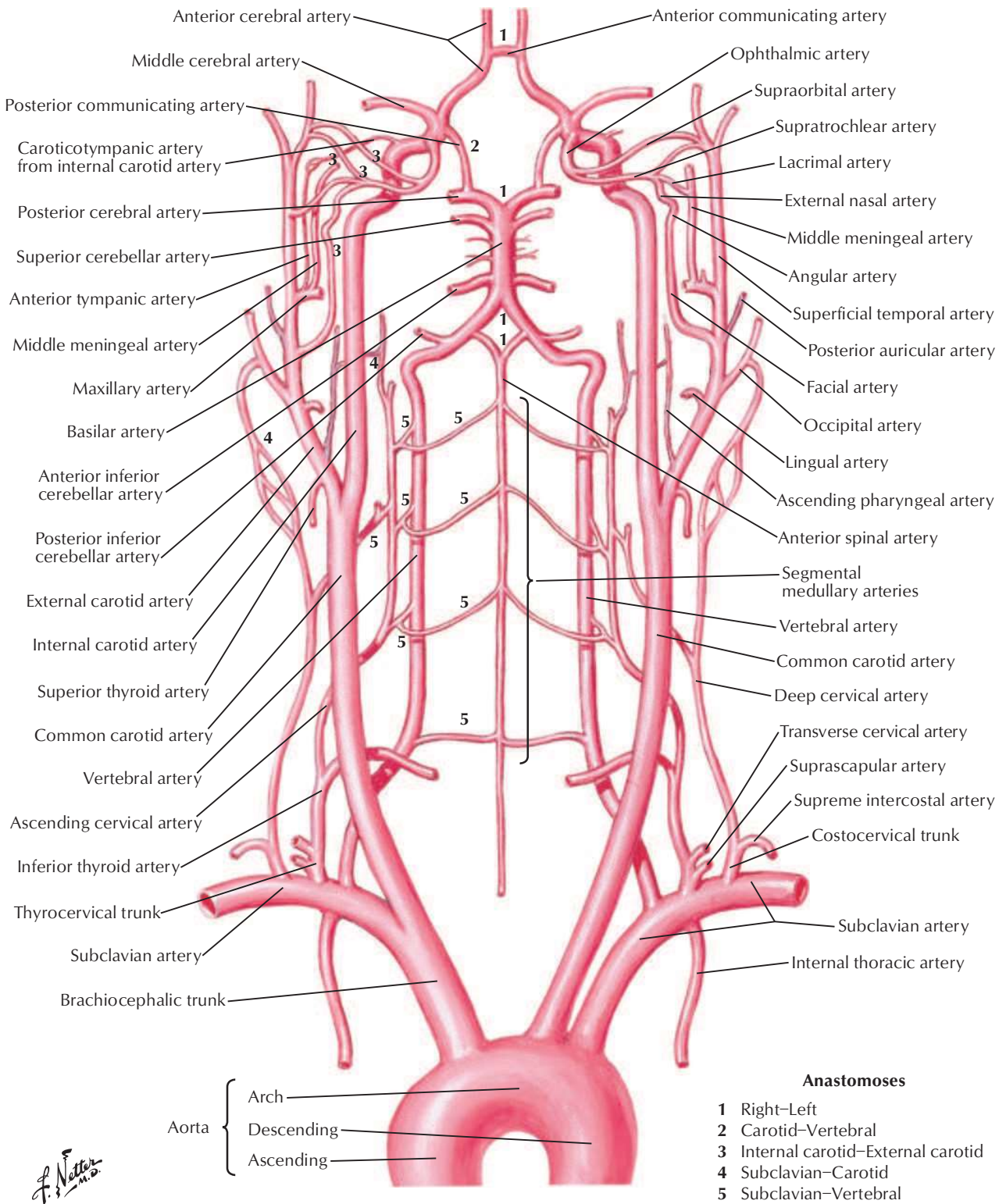
Arteries to Brain and Meninges

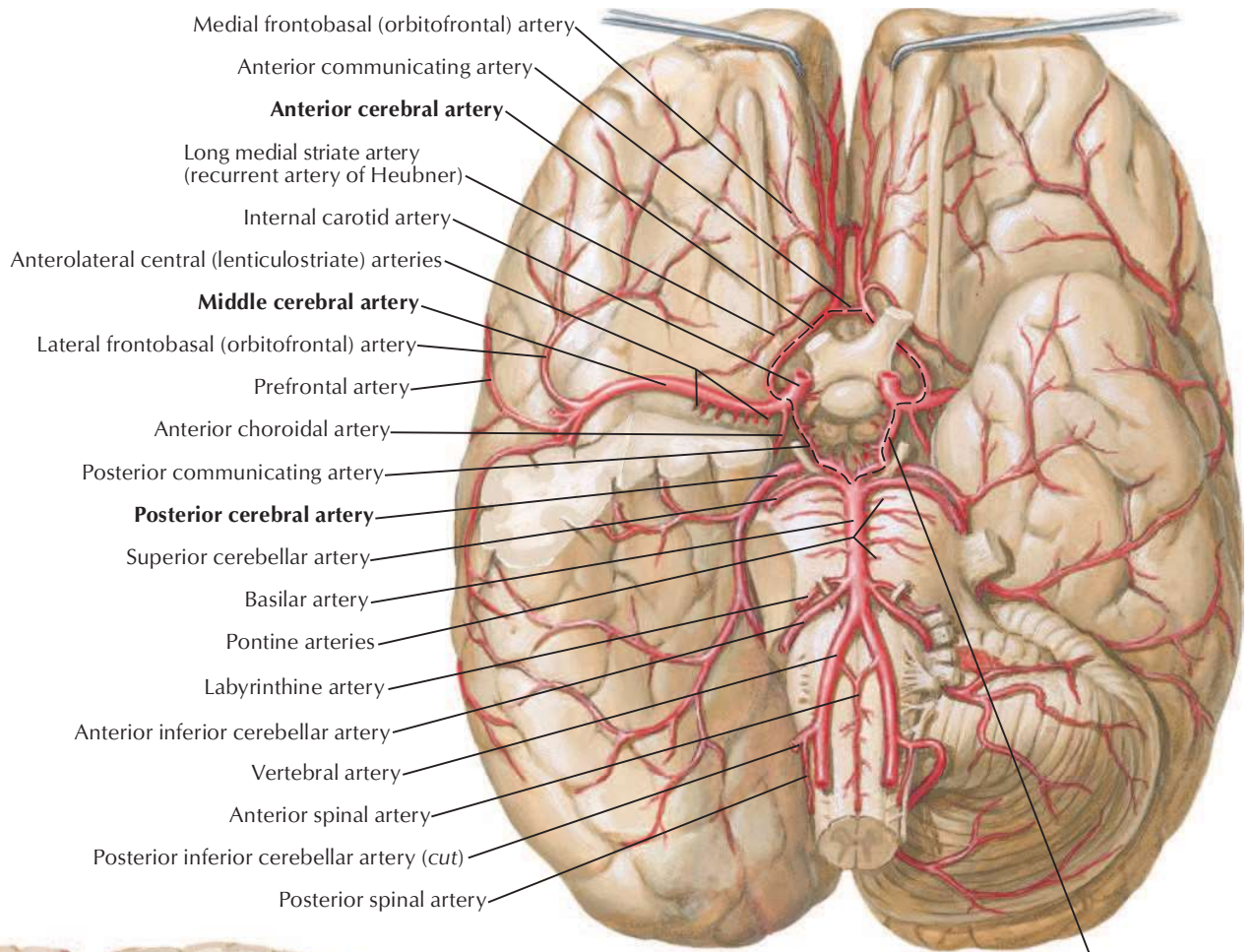
See also [Plates 41, 64, 148](#)



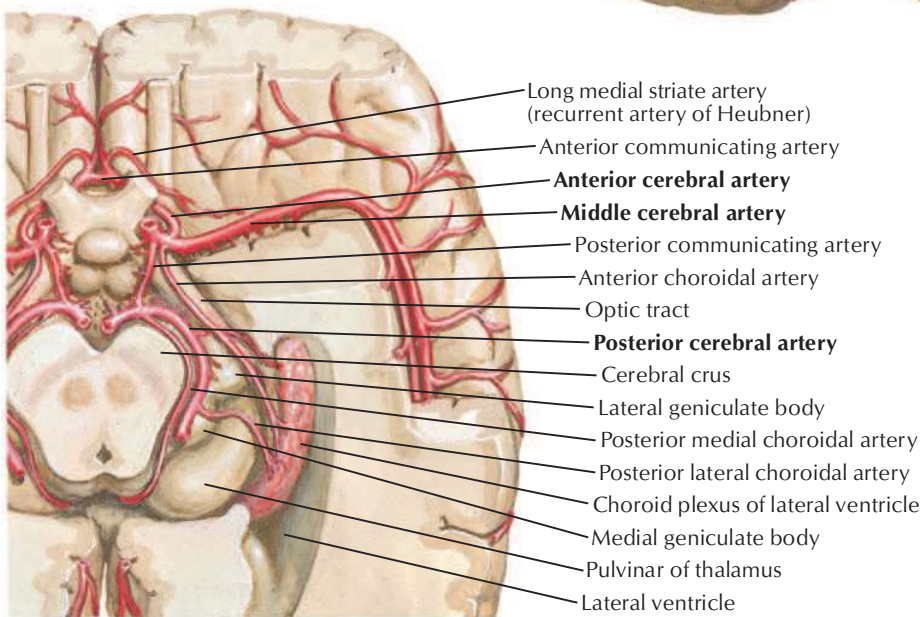


C. Machado
M.D.





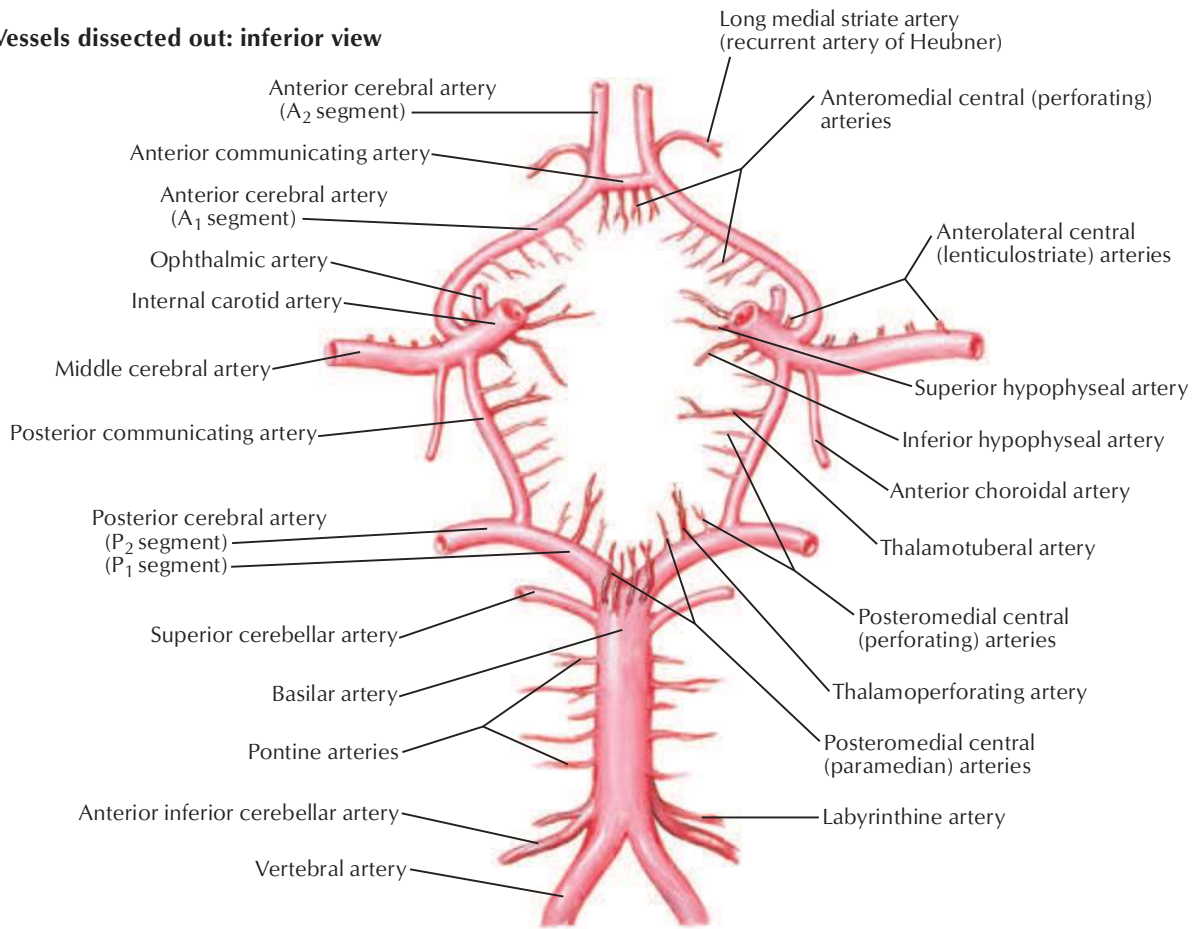
Cerebral arterial circle (of Willis)
(broken line)



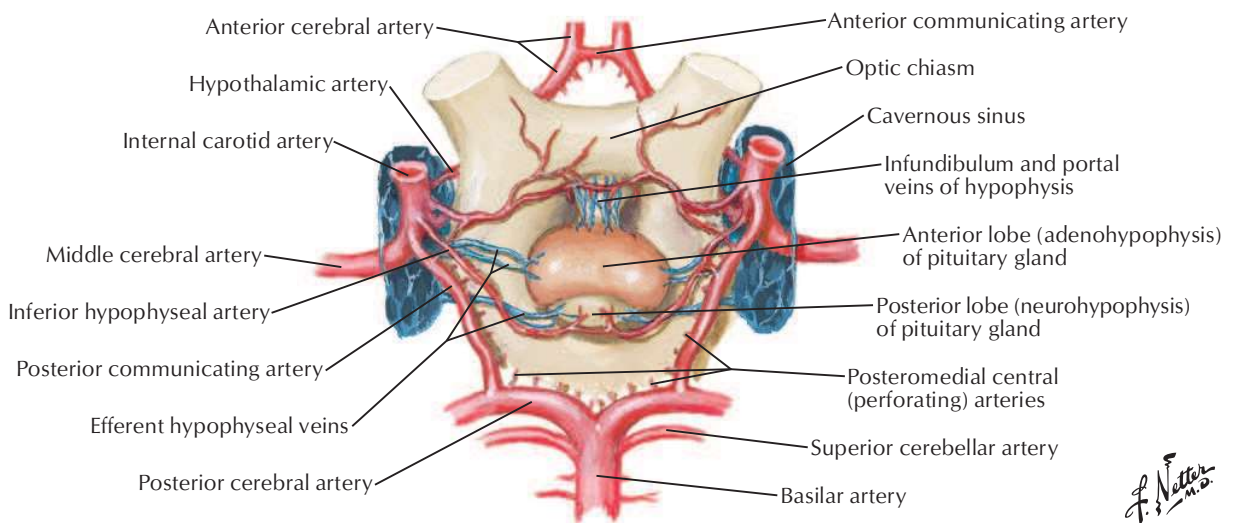
F. Netter M.D.

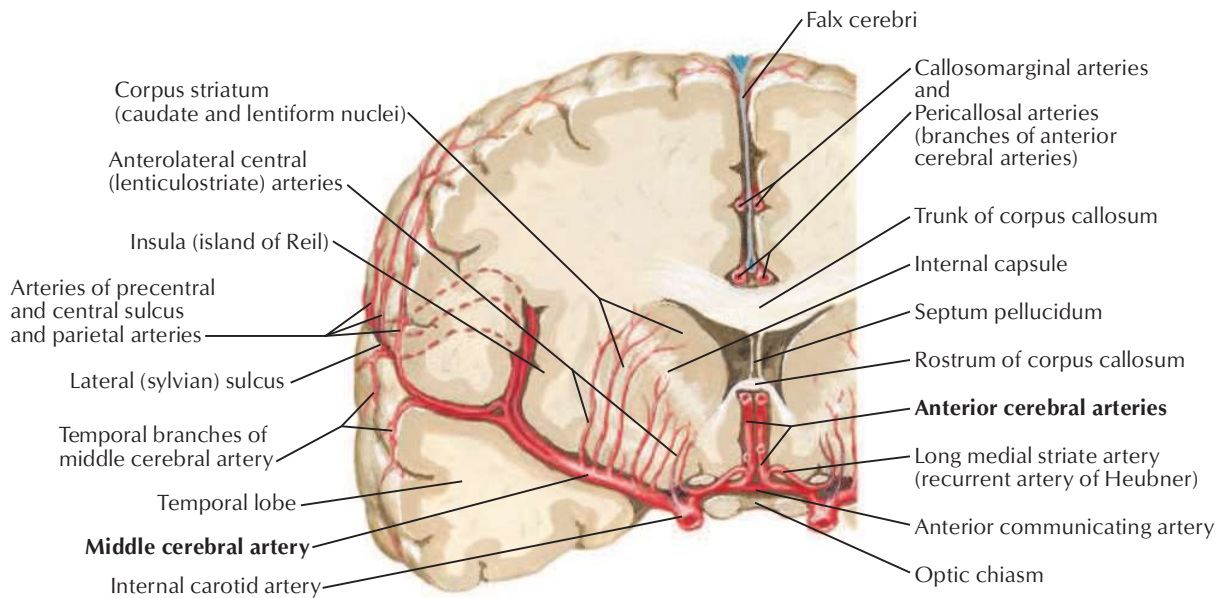
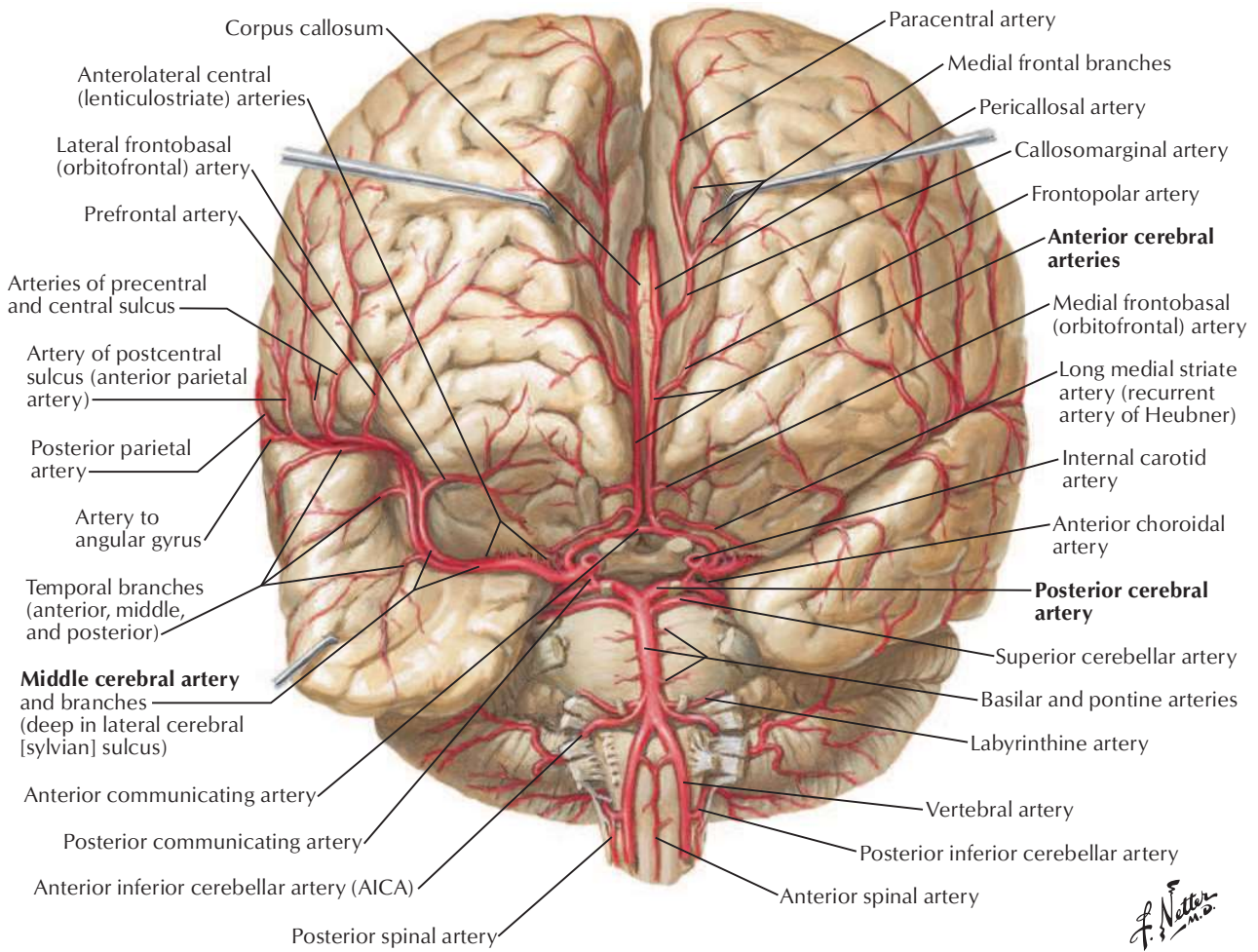
Cerebral Arterial Circle (of Willis)

Vessels dissected out: inferior view

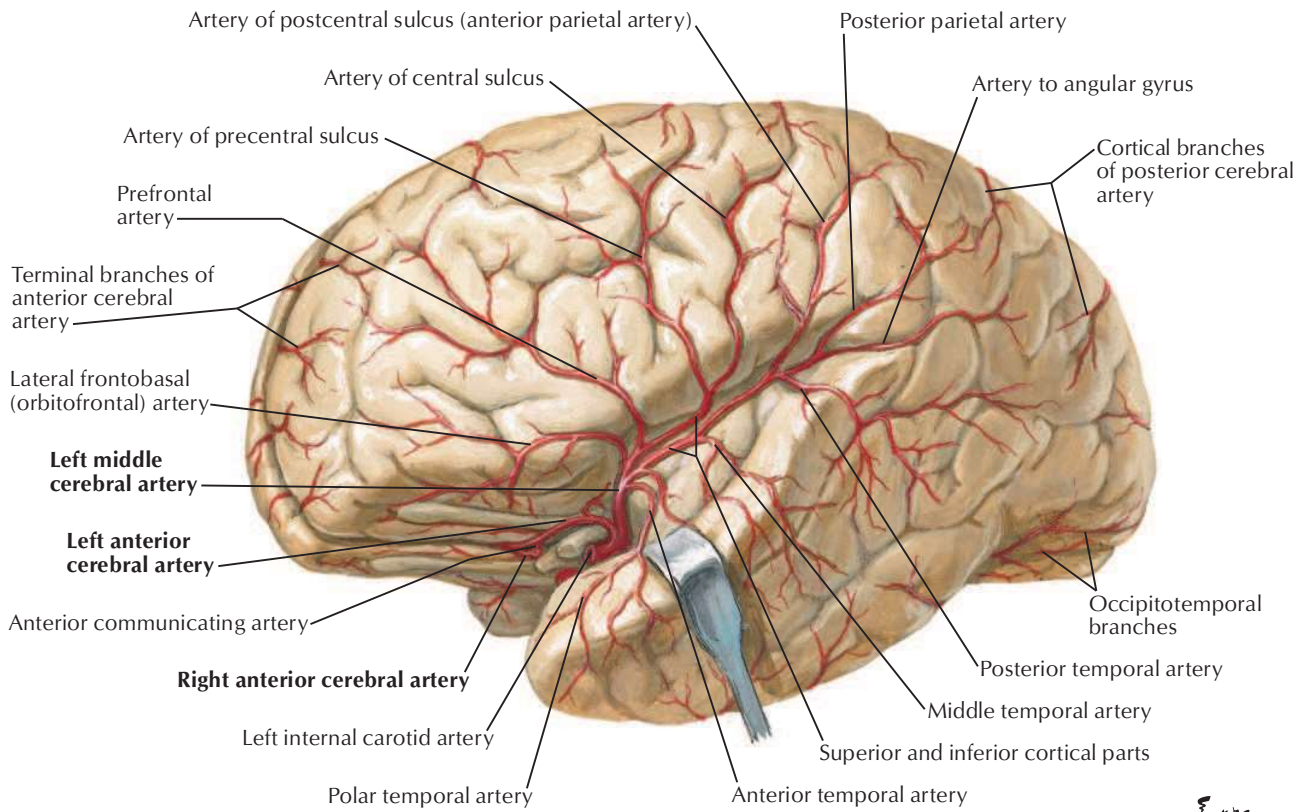
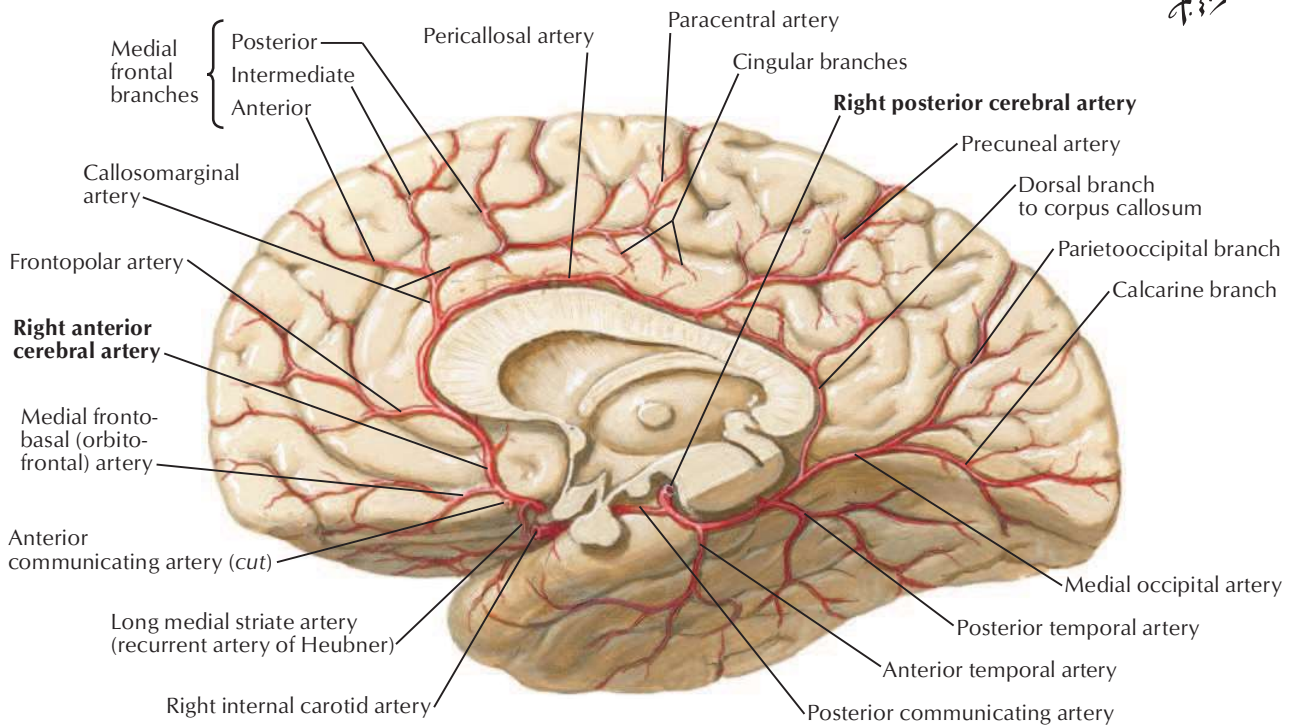


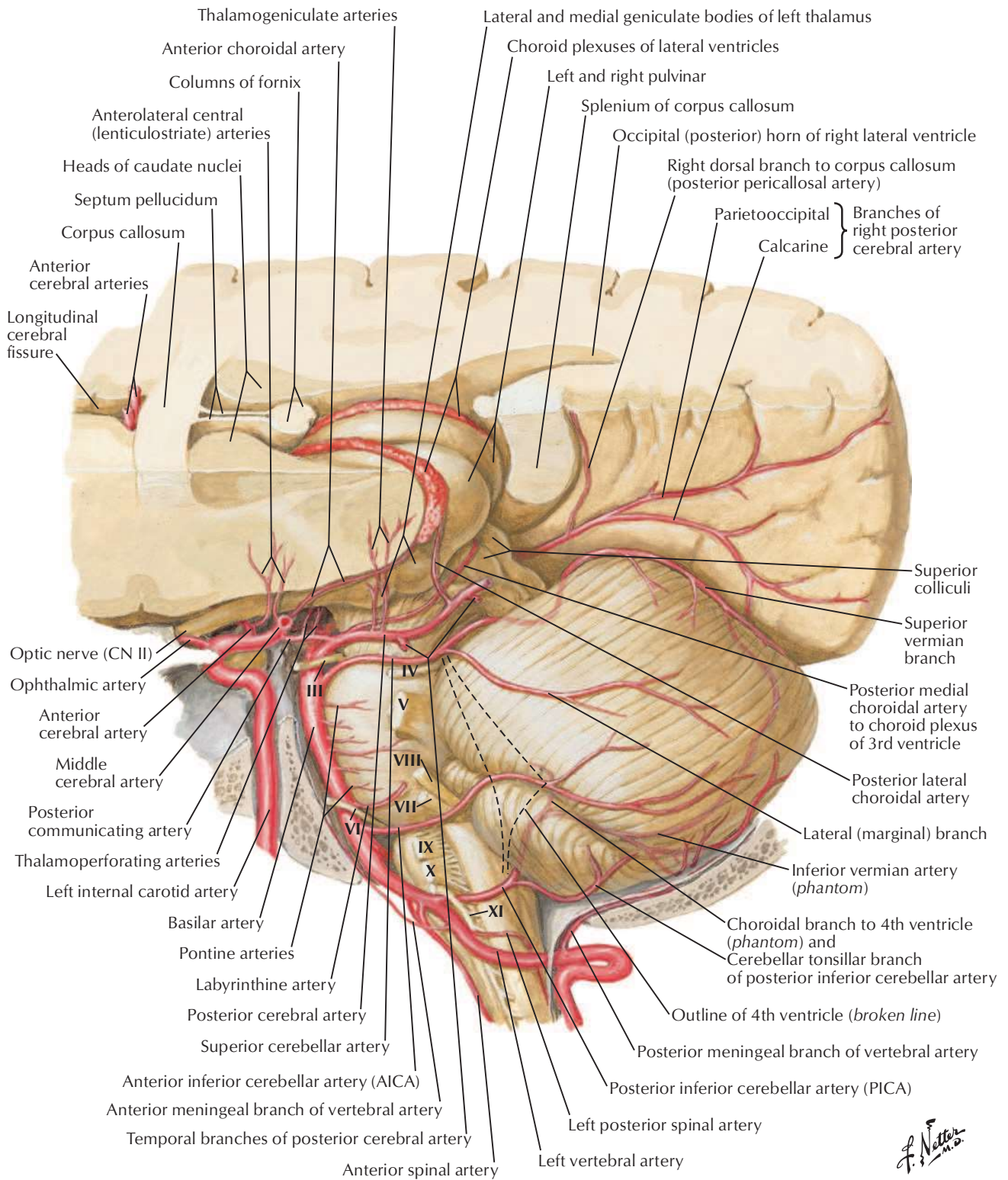
Vessels in situ: inferior view





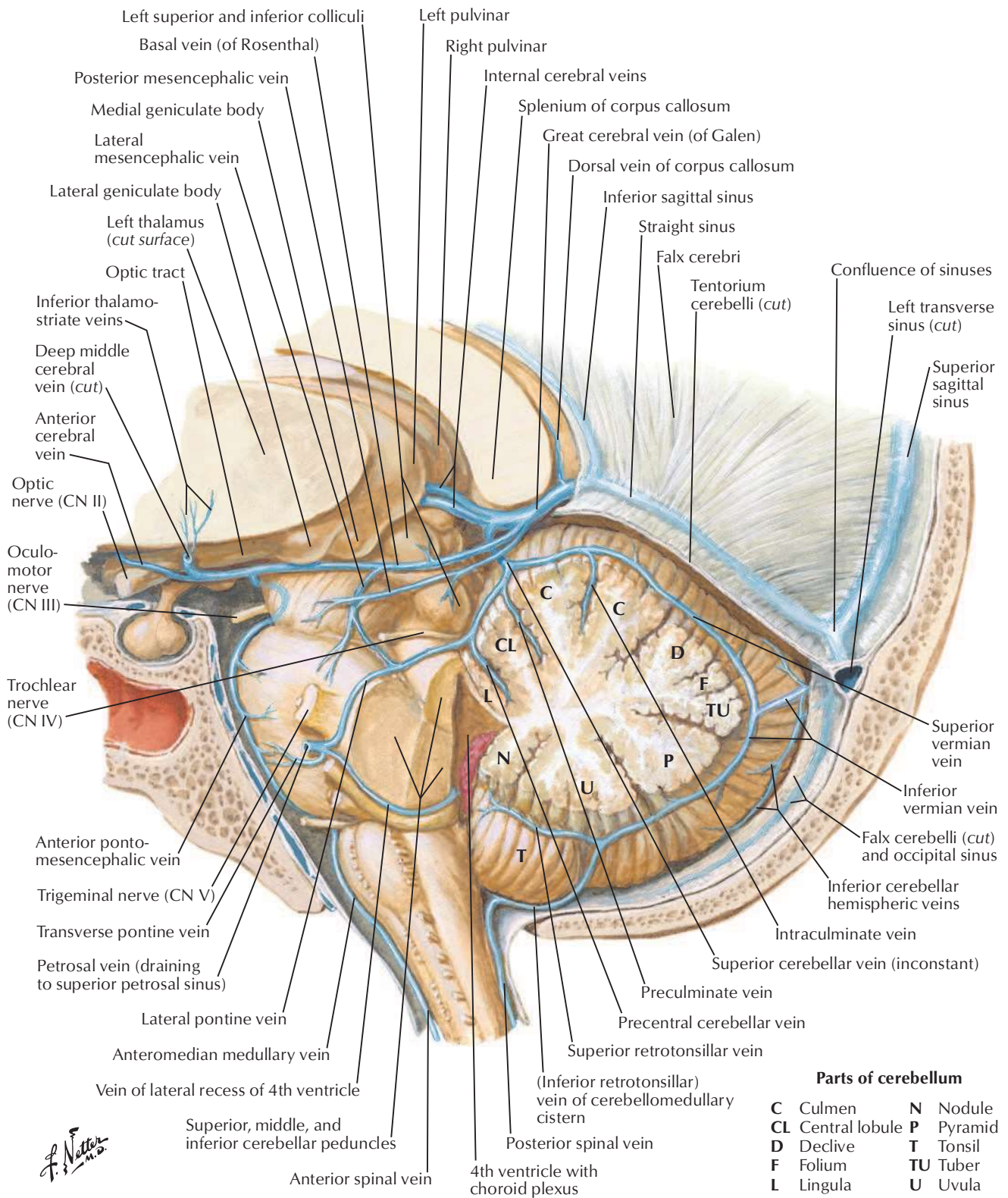
Arteries of Brain: Lateral and Medial Views

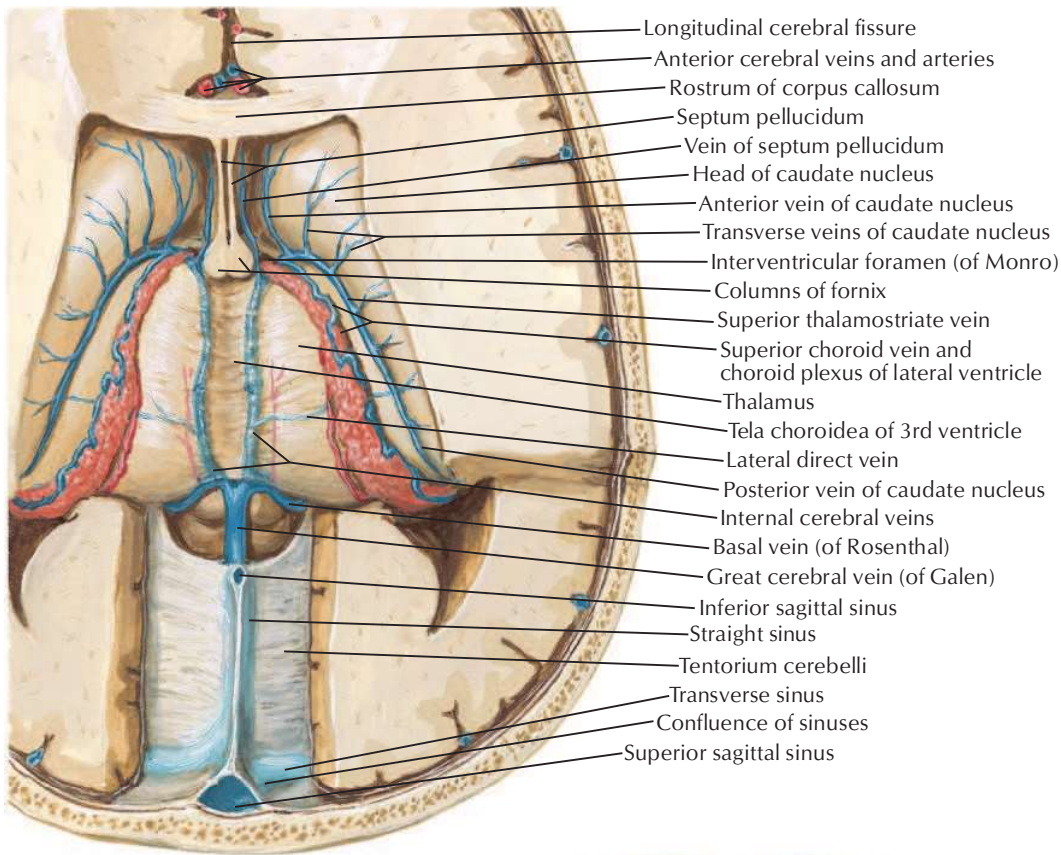





F. Netter M.D.

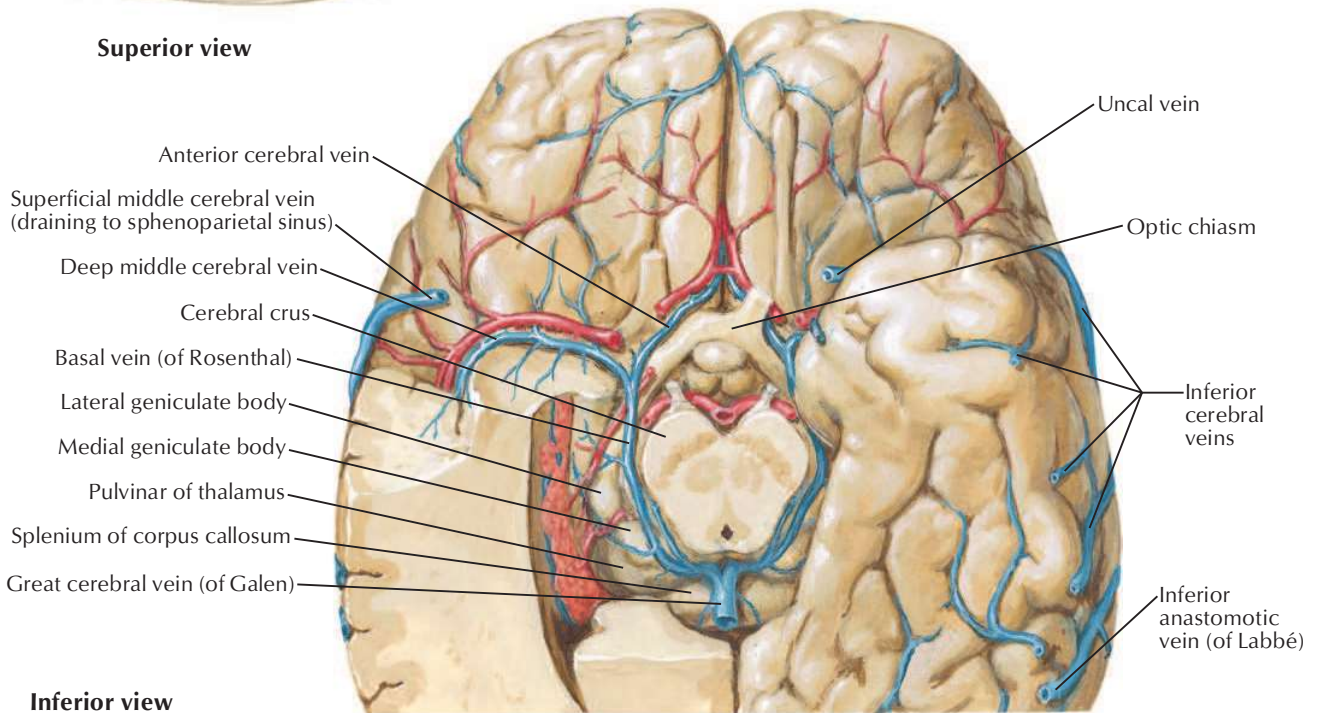
Veins of Posterior Cranial Fossa





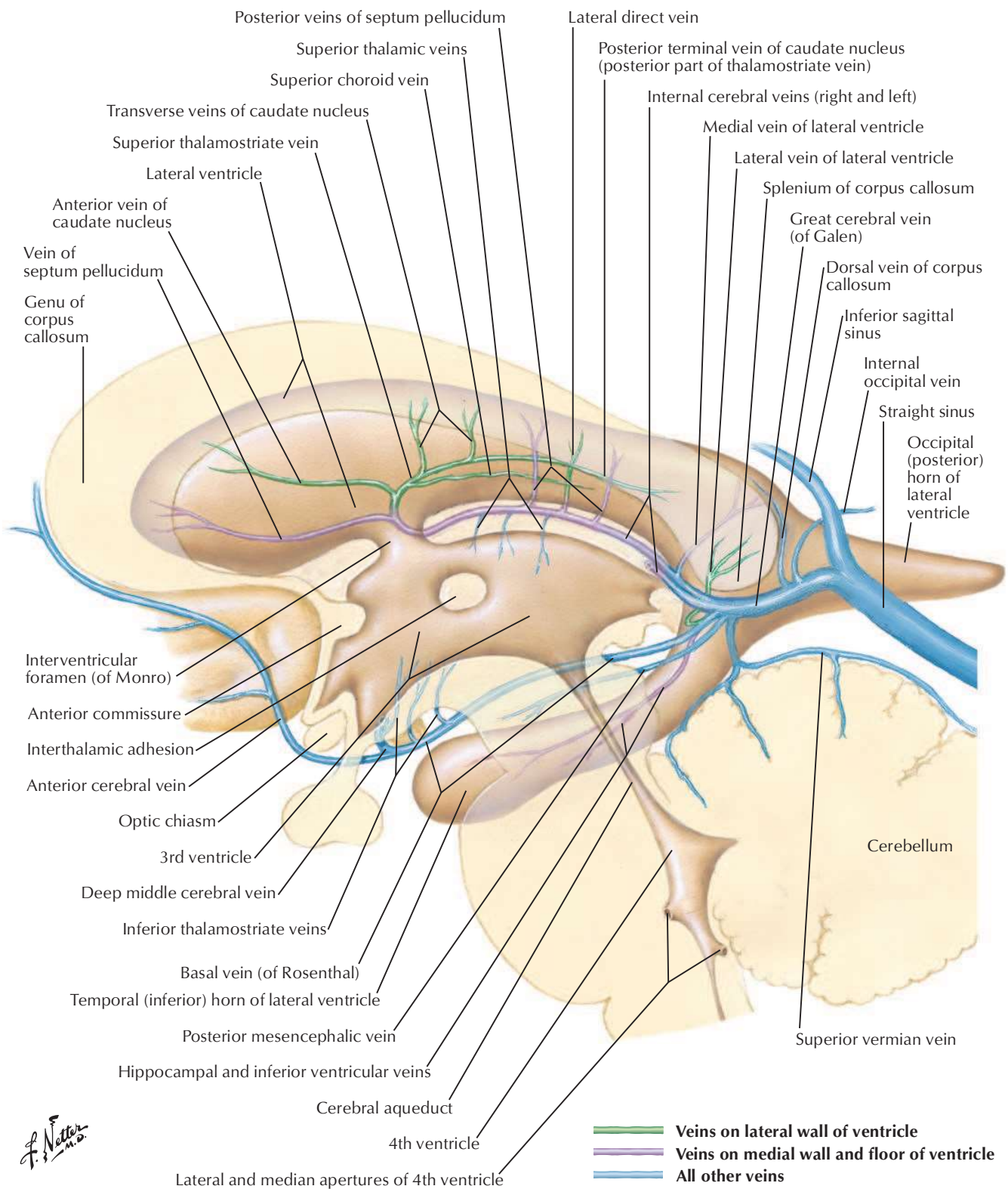
Superior view

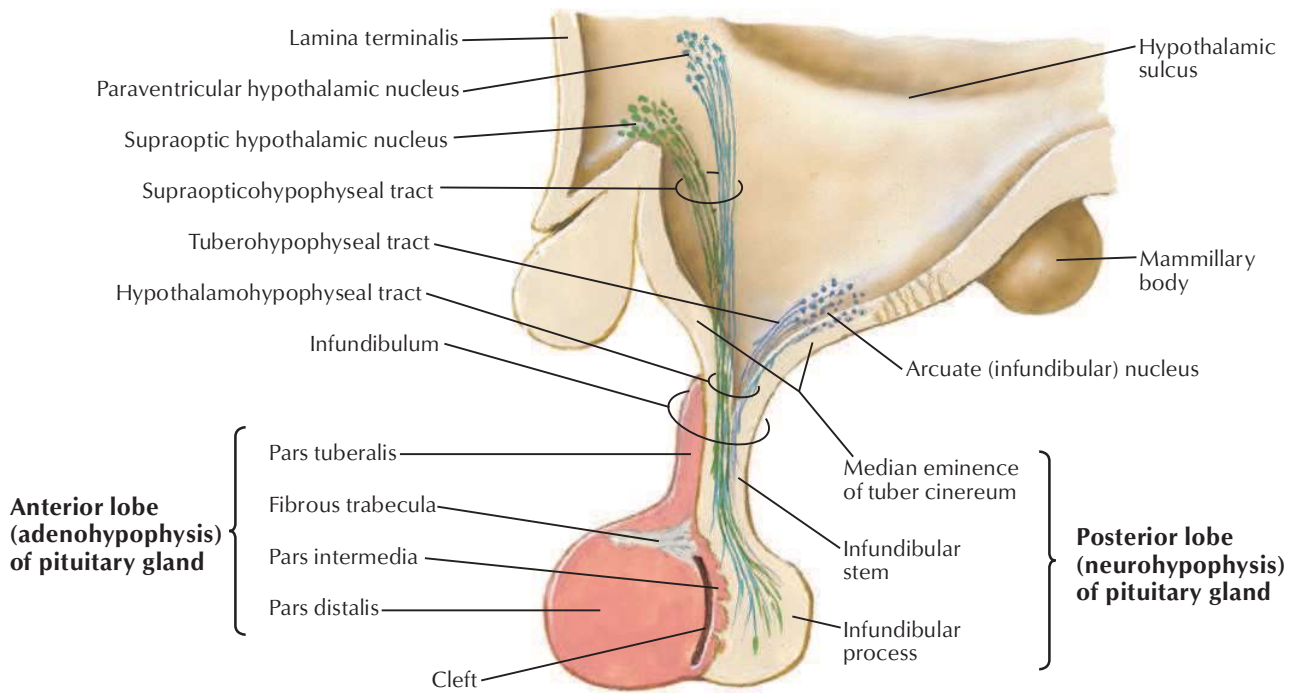
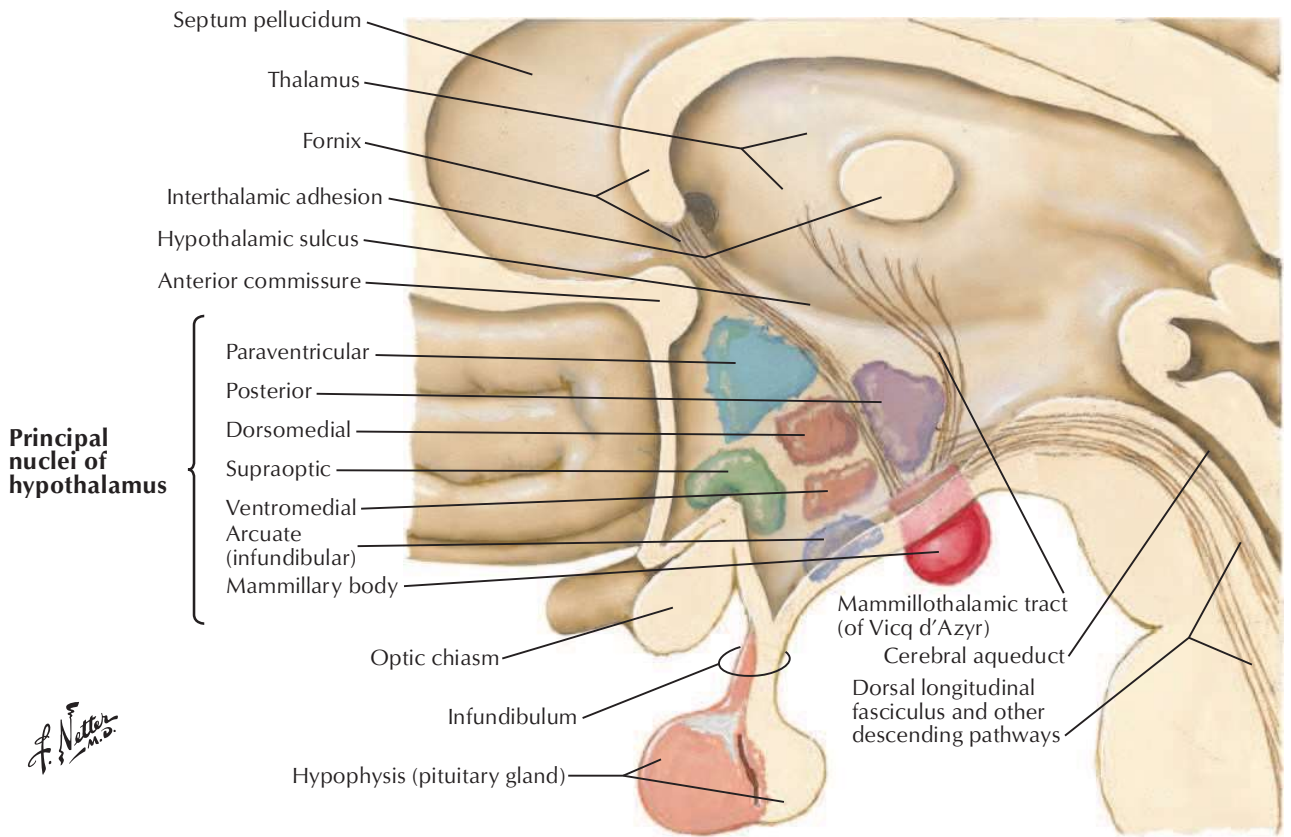
F. Netter M.D.



Inferior view

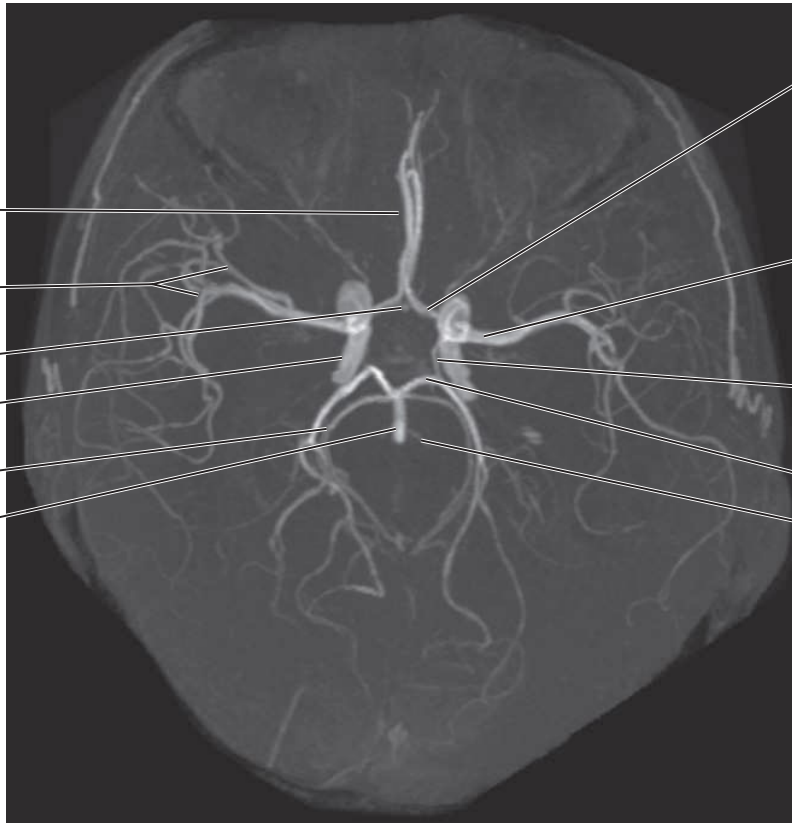
Subependymal Veins of Brain





Magnetic resonance angiography (MRA) at level of circle of Willis (3D time-of-flight image without contrast)

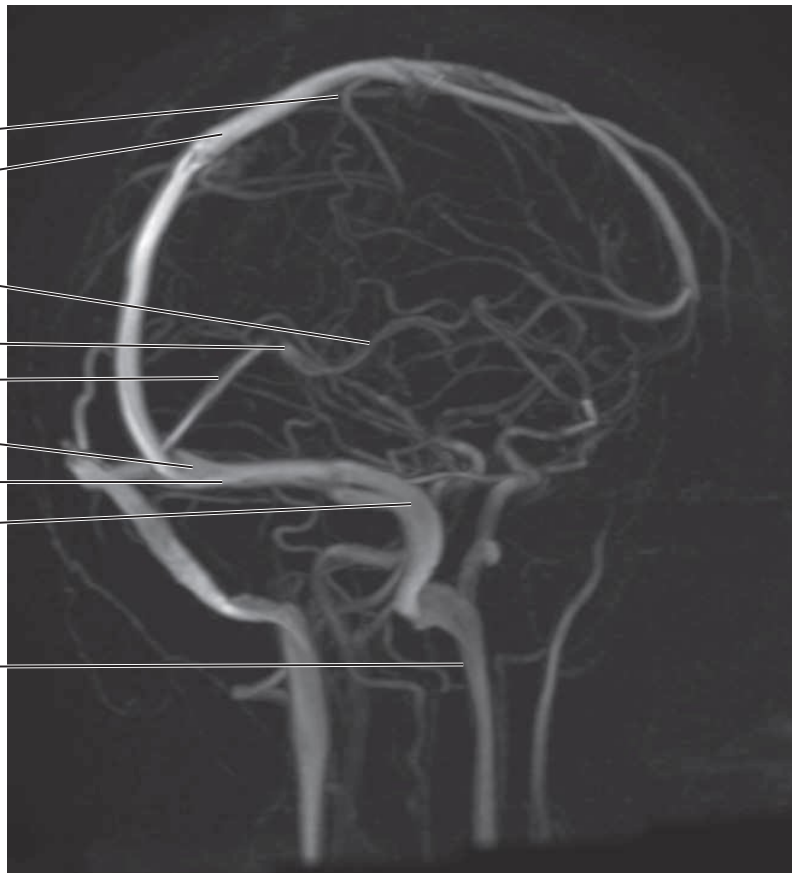
- Anterior cerebral artery (A2 segment)
- Middle cerebral artery (M2 segments)
- Anterior communicating artery
- Internal carotid artery
- Superior cerebellar artery
- Basilar artery



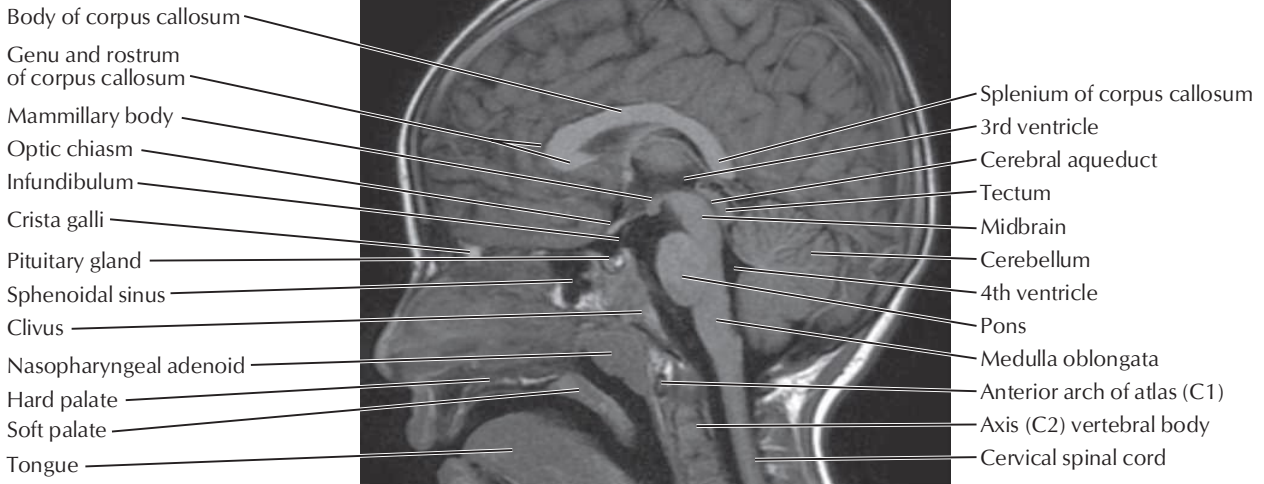
- Anterior cerebral artery (A1 segment)
- Middle cerebral artery (M1 segment)
- Posterior communicating artery
- Posterior cerebral artery
- Anterior inferior cerebellar artery

Magnetic resonance venography (MRV) (2D time-of-flight image without contrast)

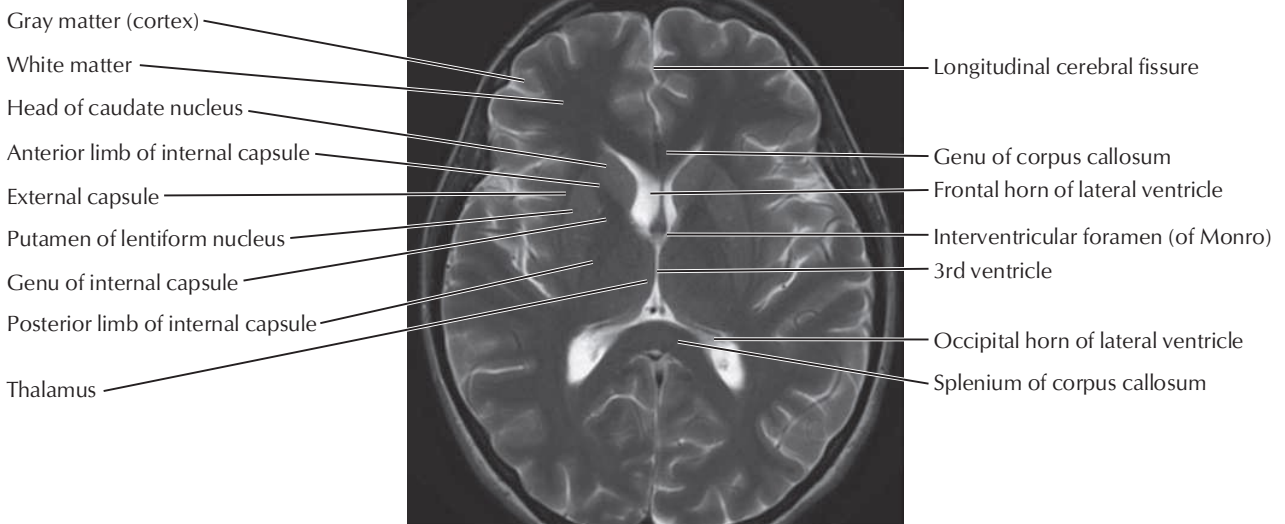
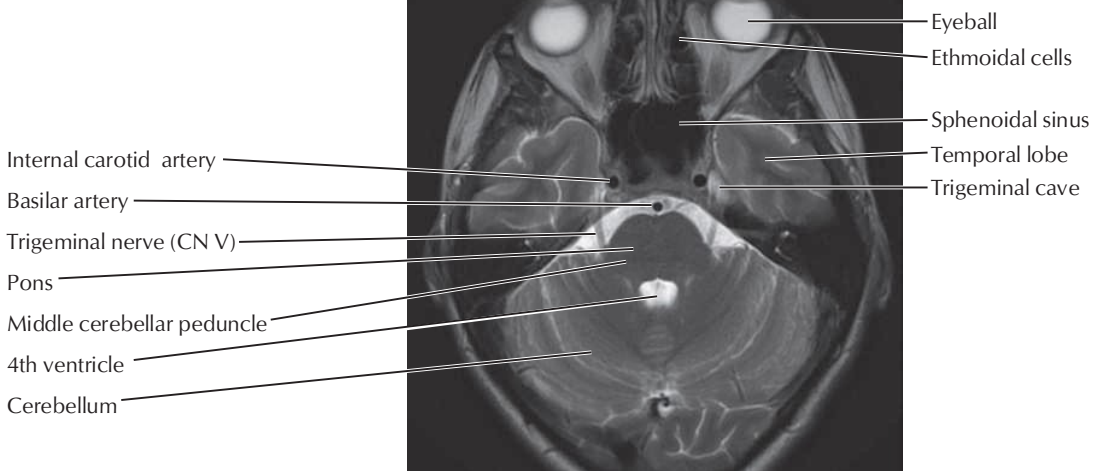
- Superior cerebral vein
- Superior sagittal sinus
- Internal cerebral vein
- Great cerebral vein (of Galen)
- Straight sinus
- Confluence of sinuses
- Transverse sinus
- Sigmoid sinus
- Internal jugular vein



T1-weighted MRI, sagittal view



T2-weighted, MRI axial views without contrast












ANATOMIC STRUCTURES	CLINICAL IMPORTANCE	PLATE NUMBERS
 SKELETAL SYSTEM		
Orbit	Direct trauma to eye may result in “blowout” fracture; margin remains intact, but medial and/or inferior walls of orbit have fractured	11, 50
Pterion	Weak area of skull that is common site of fracture	13
Temporomandibular joint	Temporomandibular disorders are common source of pain and joint dysfunction	25
Cervical vertebrae	Degenerative changes cause narrowing of intervertebral foramina that may cause cervical radiculopathy	26–28
Cervical vertebrae	Bilateral fracture of pars interarticularis of C2 (spondylolysis) results from hyperextension of head on neck and results in spondylolisthesis of C2 (hangman’s fracture); fractures (common) are due to motor vehicle, snowmobile, and all-terrain vehicle accidents	26
Thyroid cartilage, cricoid cartilage	Palpable landmarks used for cricothyrotomy and tracheostomy	87, 90
Ear ossicles	Pathologic conditions involving ossicles (e.g., otosclerosis) can cause conductive hearing loss	105, 106
 MUSCULAR SYSTEM		
Muscles of facial expression	Used to assess function of CN VII during cranial nerve examination; may become weak or paralyzed with CN VII dysfunction (e.g., Bell’s palsy)	31, 134
Sternocleidomastoid muscle	Palpated to identify “nerve point of neck” for administration of anesthesia to cervical plexus	39
Sternocleidomastoid, trapezius muscles	Used to assess function of CN XI during cranial nerve examination	39, 138
Muscles of mastication	Used to assess function of CN V (V ₃) during cranial nerve examination	55, 56
Levator veli palatini, musculus uvulae	Used to assess function of CN X during cranial nerve examination; contralateral deviation of uvula during elevation indicates CN X dysfunction	67
Genioglossus muscle	Used to assess CN XII function during cranial nerve examination; deviates to side of lesion when protruded following CN XII injury	70, 139
Levator palpebrae superioris, superior tarsal muscles	Muscles responsible for elevating eyelid; ptosis indicates pathologic change in CN III or sympathetics (superior tarsal muscle)	94, 96
Eye muscles	Used to assess function of CN III, CN IV, and CN VI during cranial nerve examination	96, 98
Dilator pupillae muscle	Important in assessment of sympathetic function in head; lack of dilation indicates interruption in sympathetic outflow (e.g., Horner’s syndrome)	101, 132
Sphincter pupillae muscle	Involved in pupillary light reflex and accommodation reflex	101, 132
 RESPIRATORY SYSTEM		
Paranasal sinuses	Cavities in skull; prone to mucosal inflammation due to bacterial or viral infection	49, 50
 DIGESTIVE SYSTEM		
Parotid gland	Swelling of gland due to infection (e.g., mumps) may compress branches of facial nerve, producing facial muscle weakness	53, 54

Table 2.1

ANATOMIC STRUCTURES	CLINICAL IMPORTANCE	PLATE NUMBERS
 ENDOCRINE SYSTEM		
Thyroid gland	Common site of cancer; removed with thyroidectomy	87
 NERVOUS SYSTEM		
Accessory nerve (CN XI)	Lymph node biopsy in posterior cervical triangle can cause iatrogenic injury of CN XI	39
Cervical plexus	Cervical plexus blocks are performed for neck procedures	39, 40
Trigeminal nerve (CN V)	Branches of CN V are anesthetized for procedures on face or anterior scalp	42, 133
Olfactory nerve (CN I)	One of most commonly injured cranial nerves; can be avulsed at cribriform plate following falls	46, 130
Facial nerve (CN VII)	Idiopathic unilateral facial nerve palsy (Bell's palsy) can result in inability to fully close eye and result in desiccated cornea ipsilaterally	54
Recurrent laryngeal nerve	May be compressed or damaged by procedures in neck (e.g., thyroidectomy), aortic arch aneurysm, or lung cancer, producing hoarseness of voice	88, 89
Oculomotor nerve (CN III), trochlear nerve (CN IV), and abducens nerve (CN VI)	Cavernous sinus thrombosis can result in dysfunction of extraocular muscles caused by compression of one, two, or all three nerves	115
Superior colliculus and cerebral aqueduct	Tumor of midbrain can result in compression of cerebral aqueduct, with resultant hydrocephalus	120
Optic nerve (CN II)	One early sign of growing pituitary gland mass is bitemporal hemianopsia	131, 151
Optic nerve (CN II)	One of first signs of ophthalmic artery aneurysm is visual loss due to compression of overlying optic nerve	148
 CARDIOVASCULAR SYSTEM		
Right internal and external jugular veins	Examined to assess jugular venous pulse; internal jugular vein is preferred because it is in line with superior vena cava; external jugular vein may be used instead as the internal jugular vein is very difficult to visualize	38
Internal jugular vein, subclavian vein	Used to obtain venous access via insertion of central venous catheter	38, 84
Inferior thyroid artery	At risk during thyroidectomy; must be preserved to maintain blood supply to parathyroid glands	40, 88
Common carotid artery	Palpated in neck to assess carotid pulse; prone to atherosclerotic thickening of vessel wall	41
Anterior ethmoidal, sphenopalatine, and facial arteries	Anastomosis site of these vessels in nasal vestibule is common site of nosebleed (epistaxis)	47
Pterygoid venous plexus	Common route for spread of infection due to connections between face, orbit, and venous sinuses	84, 99
Ophthalmic artery	Primary source of blood to retina; blindness may occur if artery is occluded	99, 103
Arteries of scalp	Lacerations bleed profusely owing to rich blood supply; vessels do not retract in dense connective tissue layer of scalp	111
Superior cerebral veins	May be torn from their junction with superior sagittal sinus, producing subdural hematoma	112, 113, 114, 120

Structures With High* Clinical Significance

ANATOMIC STRUCTURES	CLINICAL IMPORTANCE	PLATE NUMBERS
 CARDIOVASCULAR SYSTEM—Continued		
Middle meningeal artery	Trauma to skull can tear middle meningeal artery, causing epidural hematoma	112
Dural venous sinuses	Infections in head may spread to sinuses, causing dural sinus thrombosis; cavernous sinus is most common site	114, 115
Cavernous sinus	Fistula (anastomosis) between internal carotid artery and cavernous sinus may form, especially following trauma	115, 151
Carotid sinus	Compressed during carotid sinus massage	141
Cerebral arterial circle of Willis	Common site of aneurysms; rupture produces subarachnoid hemorrhage	150
 LYMPHATIC SYSTEM		
Thoracic duct	May be injured in neck at junction of internal jugular and subclavian veins	85
Superior and inferior deep nodes	Palpated during neck examination to assess size	85, 86

*Selections were based largely on clinical data and commonly discussed clinical correlations in gross anatomy courses.

MUSCLE	MUSCLE GROUP	PROXIMAL ATTACHMENT (ORIGIN)	DISTAL ATTACHMENT (INSERTION)	INNERVATION	BLOOD SUPPLY	MAIN ACTIONS
Auricularis anterior	External ear	Temporal fascia, epicranial aponeurosis	Anterior part of medial surface of helix of ear	Posterior auricular and temporal branches of facial nerve	Auricular branch of posterior auricular artery, parietal branch of superficial temporal artery	Elevates and draws auricle forward
Auricularis posterior	External ear	Base of mastoid process	Lower part of cranial surface of auricle	Posterior auricular and temporal branches of facial nerve	Auricular branch of posterior auricular artery, parietal branch of superficial temporal artery	Retracts and elevates auricle
Auricularis superior	External ear	Temporal fascia, epicranial aponeurosis	Upper part of medial surface of auricle	Posterior auricular and temporal branches of facial nerve	Auricular branch of posterior auricular artery, parietal branch of superficial temporal artery	Retracts and elevates auricle
Buccinator	Facial expression	Posterior portion of alveolar process of maxillary bone and mandible opposite sockets of molar teeth, anterior border of pterygomandibular raphe	Angle of mouth	Buccal branches of facial nerve	Muscular branches of facial artery, buccal branch of maxillary artery	Compresses cheeks, expels air between lips, aids in mastication
Ciliary	Intrinsic eye	Corneoscleral junction	Ciliary body	Parasympathetic fibers via short ciliary nerves (CN III)	Ophthalmic artery	Constricts ciliary body and lens rounds up (accommodation)
Corrugator supercilii	Facial expression	Medial part of supraorbital margin	Skin of medial half of eyebrow	Zygomatic and temporal branches of facial nerve	Zygomatic and anterior branches of superficial temporal artery	Draws eyebrows downward and medially, produces vertical wrinkles of skin between eyebrows
Cricothyroid	Laryngeal	Anterior cricoid cartilage	Inferior border of thyroid cartilage and its inferior horn	External branch of superior laryngeal nerve	Superior and inferior thyroid arteries	Lengthens and tenses vocal ligaments
Depressor anguli oris	Facial expression	Continuous with platysma muscle on oblique line of mandible	Angle of mouth into orbicularis oris muscle and skin	Mandibular and buccal branches of facial nerve	Inferior labial artery of facial artery	Depresses angle of mouth
Depressor labii inferioris	Facial expression	Lateral surface of mandible between symphysis and mental foramen deep to depressor anguli oris	Skin to lower lip, mingling with orbicularis oris muscle, medial fibers joining those of opposite side	Mandibular and buccal branches of facial nerve	Inferior labial artery of facial artery	Depresses lower lip and draws it lateralward
Depressor septi nasi	Facial expression	Incisive fossa of maxillary bone	Septum and posterior part of ala of nose	Zygomatic and buccal branches of facial nerve	Superior labial artery of facial artery	Narrows nostril, draws septum downward
Digastric	Suprahyoid	<i>Anterior belly:</i> digastric fossa of mandible <i>Posterior belly:</i> mastoid notch of temporal bone	Intermediate tendon attached to body of hyoid	<i>Anterior belly:</i> nerve to mylohyoid muscle <i>Posterior belly:</i> facial nerve	<i>Anterior belly:</i> branches of submental artery <i>Posterior belly:</i> muscular branches of posterior auricular artery, muscular branches of occipital artery	Raises hyoid bone and base of tongue, steadies hyoid bone, opens mouth by lowering mandible
Dilator pupillae	Intrinsic eye	Radial fibers in iris	Blends with sphincter pupillae fibers	Sympathetic fibers from superior cervical ganglion	Ophthalmic artery	Dilates pupil
Frontal belly of occipitofrontalis	Facial expression	Epicranial aponeurosis at level of coronal suture	Skin of frontal region, epicranial aponeurosis	Temporal branches of facial nerve	Frontal branch of superficial temporal artery	Horizontally wrinkles skin of forehead, raises eyebrows
Genioglossus	Extrinsic tongue	Mental spine of mandible	Dorsum of tongue, hyoid bone	Hypoglossal nerve (CN XII)	Sublingual and submental arteries	Depresses and protrudes tongue

Variations in spinal nerve contributions to the innervation of muscles, their arterial supply, their attachments, and their actions are common themes in human anatomy. Therefore, expect differences between texts and realize that anatomical variation is normal.

MUSCLE	MUSCLE GROUP	PROXIMAL ATTACHMENT (ORIGIN)	DISTAL ATTACHMENT (INSERTION)	INNERVATION	BLOOD SUPPLY	MAIN ACTIONS
Geniohyoid	Suprahyoid	Inferior genial tubercle on back of symphysis of mandible	Anterior surface of body of hyoid bone	Branch of C1 through hypoglossal nerve (CN XII)	Sublingual branch of lingual artery	Elevates hyoid bone and depresses mandible
Hyoglossus	Extrinsic tongue	Body and greater horn of hyoid bone	Lateral and inferior aspect of tongue	Hypoglossal nerve (CN XII)	Sublingual and submental arteries	Depresses and retracts tongue
Inferior longitudinal lingual muscle	Intrinsic tongue	Under surface of tongue between genioglossus and hyoglossus	Apex of tongue blending with styloglossus	Hypoglossal nerve (CN XII)	Deep lingual branch of lingual artery, branches from facial artery	Shortens tongue, turns tip and sides downward
Inferior oblique	Extraocular; eyelid	Anterior floor of orbit lateral to nasolacrimal canal	Lateral sclera deep to lateral rectus muscle	Oculomotor nerve (CN III), inferior division	Ophthalmic artery	Abducts, elevates, and laterally rotates eyeball
Inferior pharyngeal constrictor	Circular pharyngeal	Oblique line of thyroid cartilage and cricoid cartilage	Median raphe of pharynx	Vagus nerve via pharyngeal plexus	Ascending pharyngeal artery, branches of superior thyroid artery	Constricts wall of pharynx during swallowing
Inferior rectus	Extraocular; eyelid	Common tendinous ring	Inferior aspect of eyeball, posterior to corneoscleral junction	Oculomotor nerve (CN III), inferior division	Ophthalmic artery	Depresses, adducts, and laterally rotates eyeball
Lateral cricoarytenoid	Laryngeal	Arch of cricoid cartilage	Muscular process of arytenoid cartilage	Recurrent laryngeal nerve	Superior and inferior thyroid arteries	Adducts vocal folds
Lateral pterygoid	Mastication	<i>Superior head:</i> infratemporal surface of greater wing of sphenoid bone <i>Inferior head:</i> lateral pterygoid plate	Pterygoid fovea, capsule of temporomandibular joint, articular disc	Mandibular nerve (CN V ₃)	Muscular branches of maxillary artery	<i>Bilaterally:</i> protrudes mandible <i>Unilaterally and alternately:</i> produces side-to-side grinding
Lateral rectus	Extraocular; eyelid	Common tendinous ring	Lateral aspect of eyeball, posterior to corneoscleral junction	Abducens nerve (CN VI)	Ophthalmic artery	Abducts eyeball
Levator anguli oris	Facial expression	Canine fossa of maxillary bone immediately below infra-orbital foramen and under cover of zygomatic head of levator labii superioris	Angle of mouth; fibers intermingle with orbicularis oris, depressor anguli oris, zygomaticus	Zygomatic and buccal branches of facial nerve	Superior labial artery of facial artery	Elevates angle of mouth
Levator labii superioris alaeque nasi	Facial expression	Upper part of frontal process of maxillary bone	Into major alar cartilage, skin of nose, lateral upper lip	Zygomatic and buccal branches of facial nerve	Superior labial artery and angular branches of facial artery	Elevates upper lip and dilates nostril
Levator labii superioris	Facial expression	Maxillary bone above infraorbital foramen	Skin of upper lip	Zygomatic and buccal branches of facial nerve	Superior labial artery and angular branches of facial artery	Elevates upper lip, dilates nares
Levator palpebrae superioris	Extraocular; eyelid	Lesser wing of sphenoid bone, anterior to optic canal	Superior tarsal plate	Oculomotor nerve (CN III), superior division	Ophthalmic artery	Raises upper eyelid
Levator veli palatini	Palatal	Temporal bone (petrous portion) and auditory tube	Palatine aponeurosis	Vagus nerve via pharyngeal plexus	Ascending palatine artery branch of facial artery, descending palatine artery branch of maxillary artery	Elevates soft palate during swallowing

MUSCLE	MUSCLE GROUP	PROXIMAL ATTACHMENT (ORIGIN)	DISTAL ATTACHMENT (INSERTION)	INNERVATION	BLOOD SUPPLY	MAIN ACTIONS
Longus capitis	Anterior vertebral	Anterior tubercles of transverse processes of C3–C6	Inferior surface of basilar part of occipital bone	Anterior rami of cervical nerves (C1–C3)	Ascending cervical branch of inferior thyroid artery, ascending pharyngeal artery, muscular branches of vertebral artery	Flexes head
Longus colli	Anterior vertebral	<i>Vertical portion:</i> C5–T3 vertebrae <i>Inferior oblique portion:</i> T1–T3 vertebrae <i>Superior oblique portion:</i> anterior tubercles of transverse processes of C3–C5 vertebrae	<i>Vertical portion:</i> into C2–C4 vertebrae <i>Inferior oblique portion:</i> on anterior tubercles of transverse processes of C3–C6 vertebrae <i>Superior oblique portion:</i> tubercle of anterior arch of atlas	Anterior primary rami of cervical nerves (C2–C8)	Prevertebral branches of ascending pharyngeal artery, muscular branches of ascending cervical and vertebral arteries	<i>Bilaterally:</i> flex and assist in rotating cervical vertebrae and head <i>Unilaterally:</i> flexes vertebral column laterally
Masseter	Mastication	Zygomatic arch	Ramus of mandible, coronoid process	Mandibular nerve (CN V ₃), via masseteric nerve	Transverse facial artery; masseteric branch of maxillary and facial arteries	Elevates and protrudes mandible; deep fibers retract it
Medial pterygoid	Mastication	Medial surface of lateral plate of pterygoid, pyramidal process of palatine bone, maxillary tuberosity	Medial surface of ramus and angle of mandible inferior to mandibular foramen	Mandibular nerve (V ₃), nerve to medial pterygoid muscle	Facial and maxillary arteries	<i>Bilaterally:</i> protrudes and elevates mandible <i>Unilaterally and alternately:</i> produces side-to-side movements
Medial rectus	Extraocular; eyelid	Common tendinous ring	Medial aspect of eyeball, posterior to corneoscleral junction	Oculomotor nerve (CN III), inferior division	Ophthalmic artery	Adducts eyeball
Mentalis	Facial expression	Incisive fossa of mandible	Skin of chin	Marginal mandibular branch of facial nerve	Inferior labial artery of facial artery	Raises and protrudes lower lip
Middle pharyngeal constrictor	Circular pharyngeal	Stylohyoid ligament and horns of hyoid bone	Median raphe of pharynx	Vagus nerve via pharyngeal plexus	Ascending pharyngeal artery, ascending palatine and tonsillar branches of facial artery, dorsal lingual branches of lingual artery	Constricts wall of pharynx during swallowing
Musculus uvulae	Palatal	Nasal spine, palatine aponeurosis	Mucosa of uvula of the palate	Vagus nerve via pharyngeal plexus	Ascending palatine artery branch of facial artery, descending palatine artery branch of maxillary artery	Shortens, elevates, and retracts uvula of the palate
Mylohyoid	Suprahyoid	Mylohyoid line of mandible	Median raphe and body of hyoid bone	Nerve to mylohyoid muscle	Sublingual branch of lingual artery, submental branch of facial artery	Elevates hyoid bone, base of tongue, floor of mouth; depresses mandible
Nasalis	Facial expression	Canine eminence above and lateral to incisive fossa of maxillary bone	Aponeurosis on nasal cartilages	Zygomatic and buccal branches of facial nerve	Superior labial, septal, and lateral nasal branches of facial artery	Draws ala of nose toward nasal septum, compresses nostrils; alar part opens nostrils
Occipital belly (occipitofrontalis) muscle	Facial expression	Lateral 2/3 of superior nuchal line and mastoid process	Skin of occipital region, epicranial aponeurosis	Posterior auricular nerve of facial nerve	Occipital branch of posterior auricular artery, descending branch of occipital artery	Moves scalp backward

Muscle Tables

MUSCLE	MUSCLE GROUP	PROXIMAL ATTACHMENT (ORIGIN)	DISTAL ATTACHMENT (INSERTION)	INNERVATION	BLOOD SUPPLY	MAIN ACTIONS
Omohyoid	Infrahyoid	<i>Inferior belly:</i> from upper border of scapula and superior transverse scapular ligament, ending in intermediate tendon <i>Superior belly:</i> from this tendon	<i>Inferior belly:</i> to intermediate tendon <i>Superior belly:</i> to body of hyoid bone	Ansa cervicalis	Hyoid branch of lingual artery, sternocleidomastoid branch of superior thyroid artery	Steadies hyoid bone and depresses hyoid
Orbicularis oculi	Facial expression	Medial orbital margin, palpebral ligament, lacrimal bone	Skin around orbit, palpebral ligament, upper and lower eyelids	Facial nerve (CN VII)	Facial and superficial temporal arteries	Closes eyelids
Orbicularis oris	Facial expression	Maxillary bone above incisor teeth	Skin around lips	Zygomatic, buccal, and mandibular branches of facial nerve	Inferior and superior labial branches of facial artery	Compression, contraction, and protrusion of lips
Palatoglossus	Palatal	Palatine aponeurosis of soft palate	Lateral aspect of tongue	Vagus nerve via pharyngeal plexus	Ascending pharyngeal arteries, palatine branches of facial and maxillary arteries	Elevates posterior tongue, depresses palate
Palatopharyngeus	Longitudinal pharyngeal	Hard palate, superior palatine aponeurosis	Lateral pharyngeal wall	Vagus nerve via pharyngeal plexus	Ascending palatine artery branch of facial artery, descending palatine artery branch of maxillary artery	Tenses soft palate; pulls walls of pharynx superiorly, anteriorly, and medially during swallowing
Platysma	Facial expression	Skin below clavicle, upper thorax	Mandible, oral muscles	Facial nerve	Submental and suprascapular arteries	Tenses skin of neck
Posterior cricoarytenoid	Laryngeal	Posterior surface of lamina of cricoid cartilage	Muscular process of arytenoid cartilage	Recurrent laryngeal nerve	Superior and inferior thyroid arteries	Abducts vocal folds
Procerus	Facial expression	Fascia covering lower parts of nasal bone and upper part of lateral nasal cartilage	Skin between and above eyebrows	Temporal and zygomatic branches of facial nerve	Angular and lateral nasal branches of facial artery	Draws down medial angle of eyebrows, produces transverse wrinkles over bridge of nose
Rectus capitis anterior	Anterior vertebral	Lateral mass of atlas	Base of occipital bone in front of foramen magnum	Anterior rami of cervical nerves (C1–C2)	Muscular branches of vertebral artery, ascending pharyngeal artery	Flexes head
Rectus capitis lateralis	Anterior vertebral	Upper surface of transverse process of atlas	Inferior surface of jugular process of occipital bone	Anterior rami of cervical nerves (C1–C2)	Muscular branches of vertebral artery, occipital artery, ascending pharyngeal artery	Flexes head laterally to same side
Risorius	Facial expression	Fascia over masseter muscle superficial to platysma muscle	Skin at angle of mouth	Zygomatic and buccal branches of facial nerve	Superior labial artery of facial artery	Retracts angle of mouth
Salpingopharyngeus	Longitudinal pharyngeal	Pharyngotympanic (auditory, eustachian) tube	Side of pharyngeal wall	Vagus nerve via pharyngeal plexus	Pharyngeal branch of ascending pharyngeal artery	Elevates pharynx and larynx during swallowing and speaking
Scalenus anterior	Lateral vertebral	Anterior tubercles of transverse processes of C3–C6	Scalene tubercle on 1st rib	Anterior rami of cervical nerves (C5–C8)	Ascending cervical branch of inferior thyroid artery	Elevates 1st rib, bends neck
Scalenus medius	Lateral vertebral	Posterior tubercles of transverse processes of C2–C7	Upper surface of 1st rib (behind subclavian groove)	Anterior rami of cervical nerves (C3–C7)	Muscular branches of ascending cervical artery	Elevates 1st rib, bends neck
Scalenus posterior	Lateral vertebral	Posterior tubercles of transverse processes of C4–C6	Outer surface of 2nd rib	Anterior rami of cervical nerves (C5–C8)	Muscular branches of ascending cervical division of inferior thyroid artery, superficial branch of transverse cervical artery	Elevates 2nd rib, bends neck

Table 2.7

MUSCLE	MUSCLE GROUP	PROXIMAL ATTACHMENT (ORIGIN)	DISTAL ATTACHMENT (INSERTION)	INNERVATION	BLOOD SUPPLY	MAIN ACTIONS
Sphincter pupillae	Intrinsic eye	Circular smooth muscle of iris that passes around pupil	Blends with dilator pupillae fibers	Parasympathetic fibers via oculomotor nerve (CN III)	Ophthalmic artery	Constricts pupil
Stapedius	Middle ear	Pyramidal eminence of temporal bone	Stapes	Facial nerve	Posterior auricular, anterior tympanic, and middle meningeal arteries	Pulls stapes posteriorly to lessen oscillation of tympanic membrane
Sternocleidomastoid	Neck	<i>Sternal head:</i> anterior surface of manubrium <i>Clavicular head:</i> upper surface of medial 1/3 of clavicle	Lateral surface of mastoid process; lateral half of superior nuchal line of occipital bone	Accessory nerve (CN XI)	Sternocleidomastoid branch of superior thyroid and occipital arteries, muscular branch of suprascapular artery, occipital branch of posterior auricular artery	<i>Bilaterally:</i> flexes head, raises thorax <i>Unilaterally:</i> turns face toward opposite side
Sternohyoid	Infrahyoid	Posterior surface of manubrium sterni, posterior sternoclavicular ligament, medial end of clavicle	Medial part of lower border of body of hyoid bone	Ansa cervicalis	Sternocleidomastoid and hyoid branches of superior thyroid artery, hyoid branch of lingual artery	Depresses larynx and hyoid bone, steadies hyoid bone
Sternothyroid	Infrahyoid	Posterior surface of manubrium sterni below and deep to origin of sternohyoid, edge of 1st costal cartilage	Oblique line on lamina of thyroid cartilage	Ansa cervicalis	Cricothyroid branch of superior thyroid artery	Depresses larynx and thyroid cartilage
Styloglossus	Extrinsic tongue	Styloid process and stylohyoid ligament	Lateral and inferior aspect of tongue	Hypoglossal nerve (CN XII)	Sublingual artery	Retracts tongue and draws it up for swallowing
Stylohyoid	Suprahyoid	Posterior border of styloid process	Body of hyoid bone at junction with greater horn	Facial nerve	Muscular branches of facial artery, muscular branches of occipital artery	Elevates and retracts hyoid bone
Stylopharyngeus	Longitudinal pharyngeal	Medial aspect of styloid process	Pharyngeal wall and posterior border of thyroid cartilage	Glossopharyngeal nerve (CN IX)	Ascending pharyngeal artery, ascending palatine and tonsillar branches of facial artery, dorsal branches of lingual artery	Elevates pharynx and larynx during swallowing and speaking
Subclavius	Shoulder	Upper border of 1st rib and its cartilage	Inferior surface of middle third of clavicle	Nerve to subclavius muscle	Clavicular branch of thoracoacromial artery	Anchors and depresses clavicle
Superior longitudinal lingual muscle	Intrinsic tongue	Submucous fibers at back of tongue	Apex of tongue; unites with muscle of opposite side	Hypoglossal nerve (CN XII)	Deep lingual branch of lingual artery, branches from facial artery	Shortens tongue, turns tip and sides upward
Superior oblique	Extraocular; eyelid	Body of sphenoid bone (above optic canal), medial to origin of superior rectus	Passes through trochlea, attaches to superior sclera between superior and lateral recti muscles	Trochlear nerve (CN IV)	Ophthalmic artery	Abducts, depresses, and medially rotates eyeball
Superior pharyngeal constrictor	Circular pharyngeal	Hamulus, pterygomandibular raphe, mylohyoid line of mandible	Median raphe of pharynx	Vagus nerve via pharyngeal plexus	Ascending pharyngeal artery, ascending palatine and tonsillar branches of facial artery, dorsal branches of lingual artery	Constricts wall of pharynx during swallowing
Superior rectus	Extraocular; eyelid	Common tendinous ring	Superior aspect of eyeball, posterior to the corneoscleral junction	Oculomotor nerve (CN III), superior division	Ophthalmic artery	Elevates, adducts, and medially rotates eyeball

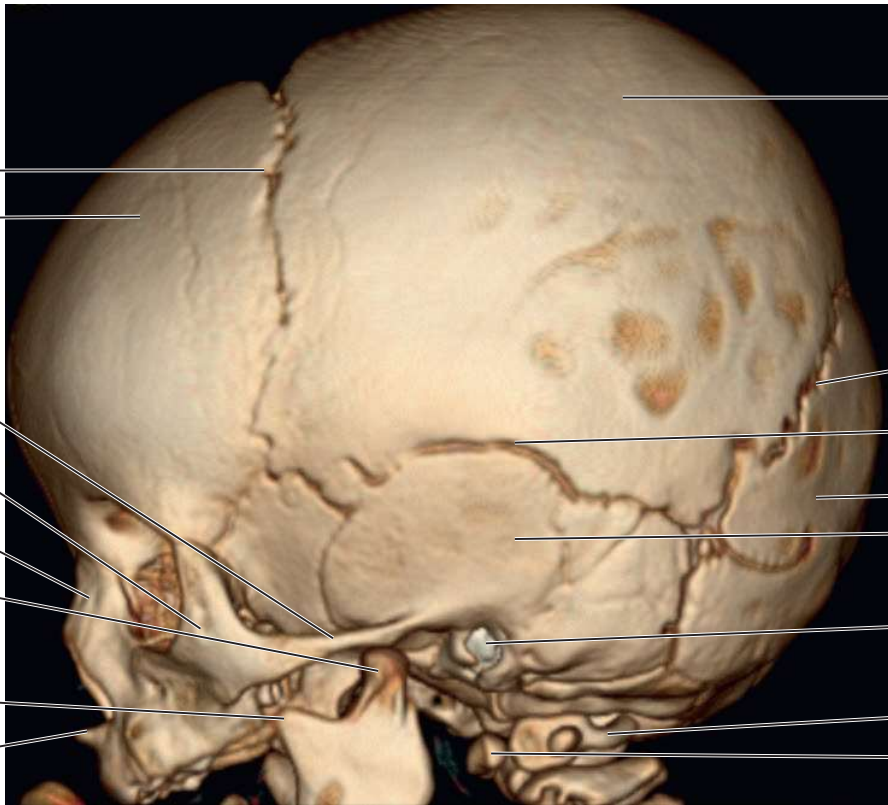
MUSCLE	MUSCLE GROUP	PROXIMAL ATTACHMENT (ORIGIN)	DISTAL ATTACHMENT (INSERTION)	INNERVATION	BLOOD SUPPLY	MAIN ACTIONS
Temporalis	Mastication	Floor of temporal fossa, deep temporal fascia	Coronoid process and ramus of mandible	Mandibular nerve (CN V ₃), deep temporal nerves	Superficial temporal and maxillary arteries, middle, anterior, and posterior deep temporal arteries	Elevates mandible; posterior fibers retract mandible
Tensor tympani	Middle ear	Cartilage of pharyngotympanic (auditory, eustachian) tube	Handle of malleus	Mandibular branch of trigeminal nerve (CN V ₃)	Superior tympanic branch of middle meningeal division of maxillary artery	Tenses tympanic membrane by drawing it medially
Tensor veli palatini	Palatal	Scaphoid fossa of medial pterygoid plate, spine of sphenoid bone, pharyngotympanic (auditory, eustachian) tube	Palatine aponeurosis	Mandibular nerve	Ascending palatine artery branch of facial artery, descending palatine artery branch of maxillary artery	Tenses soft palate, opens pharyngotympanic (auditory, eustachian) tube during swallowing and yawning
Thyroarytenoid	Laryngeal	Posterior aspect of thyroid cartilage	Muscular process of arytenoid cartilage	Recurrent laryngeal nerve	Superior and inferior thyroid arteries	Shortens and relaxes vocal cords, sphincter of vestibule
Thyrohyoid	Infrahyoid	Oblique line on lamina of thyroid cartilage	Lower border of body and greater horn of hyoid bone	Thyrohyoid branch of C1 nerve via hypoglossal nerve (CN XII)	Hyoid branch of superior thyroid artery	Depresses larynx and hyoid bone, elevates larynx when hyoid bone is fixed
Transverse and oblique arytenoid	Laryngeal	Arytenoid cartilage	Opposite arytenoid cartilage	Recurrent laryngeal nerve	Superior and inferior thyroid arteries	Closes intercartilaginous portion of rima glottides
Transverse (tongue)	Intrinsic tongue	Median fibrous septum of tongue	Dorsum and sides of tongue	Hypoglossal nerve (CN XII)	Deep lingual branch of lingual artery, branches from facial artery	Narrows and elongates tongue
Vertical (tongue)	Intrinsic tongue	Mucous membrane on dorsum of forepart of tongue	Fibers extend from dorsum to undersurface of tongue	Hypoglossal nerve (CN XII)	Deep lingual branch of lingual artery, branches from facial artery	Flattens and broadens tongue
Vocalis	Laryngeal	Vocal process of arytenoid cartilage	Vocal ligament	Recurrent laryngeal nerve	Superior and inferior thyroid arteries	Tenses anterior vocal ligament, relaxes posterior vocal ligament
Zygomaticus major	Facial expression	Zygomatic arch	Angle of mouth	Zygomatic and buccal branches of facial nerve	Superior labial artery of facial artery	Draws angle of mouth backward and upward
Zygomaticus minor	Facial expression	Zygomatic arch	Angle of mouth, upper lip	Zygomatic and buccal branches of facial nerve	Superior labial artery of facial artery	Elevates upper lip

CT 3D child skull reconstruction, lateral view

Coronal suture
Frontal bone

Zygomatic arch
Zygomatic bone
Nasal bone
Condyle of mandible

Coronoid process of mandible
Anterior nasal spine



Parietal bone

Lambdoid suture

Squamosal suture

Occipital bone

Temporal bone

External acoustic meatus of the temporal bone

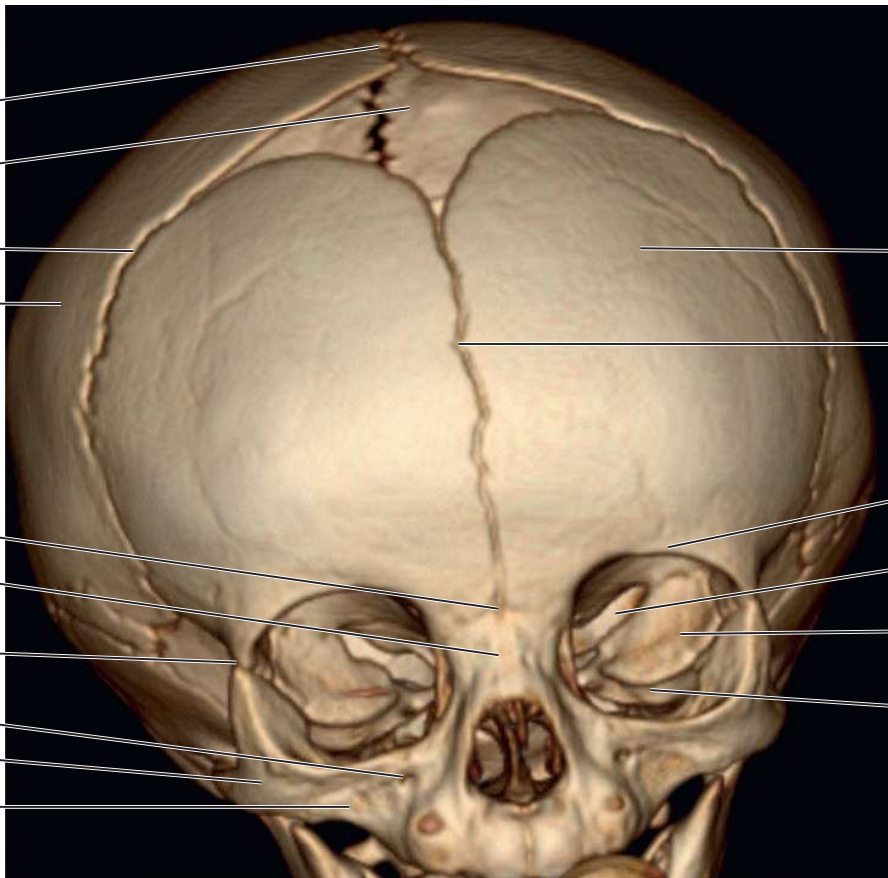
Posterior arch C1

Anterior arch C1

CT 3D child skull reconstruction, frontal view

Sagittal suture
Anterior fontanelle
Coronal suture
Parietal bone

Nasion
Nasal bone
Zygomaticofrontal suture
Infraorbital foramen
Zygomatic bone
Maxilla



Frontal bone

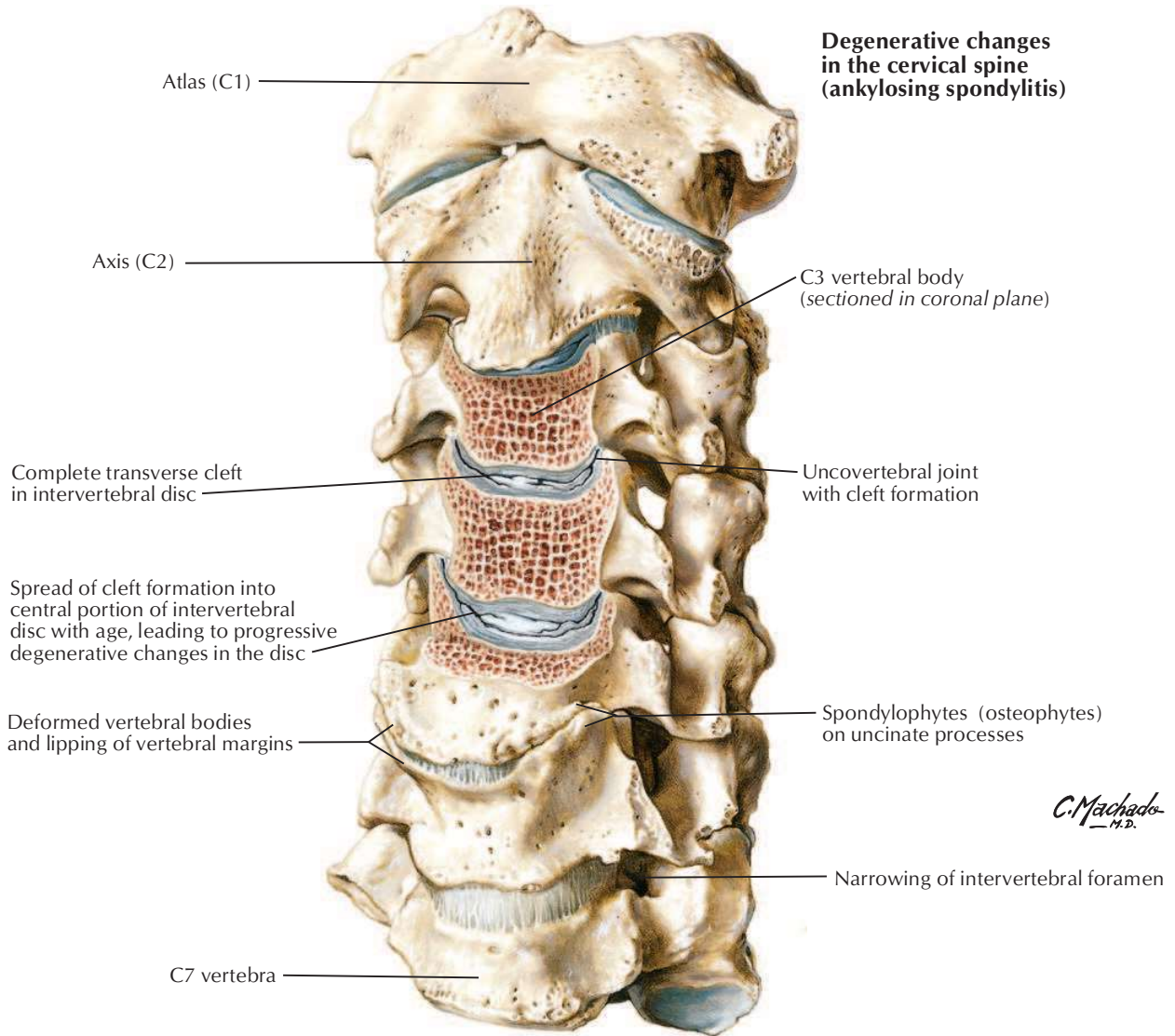
Metopic suture

Supraorbital margin

Superior orbital fissure

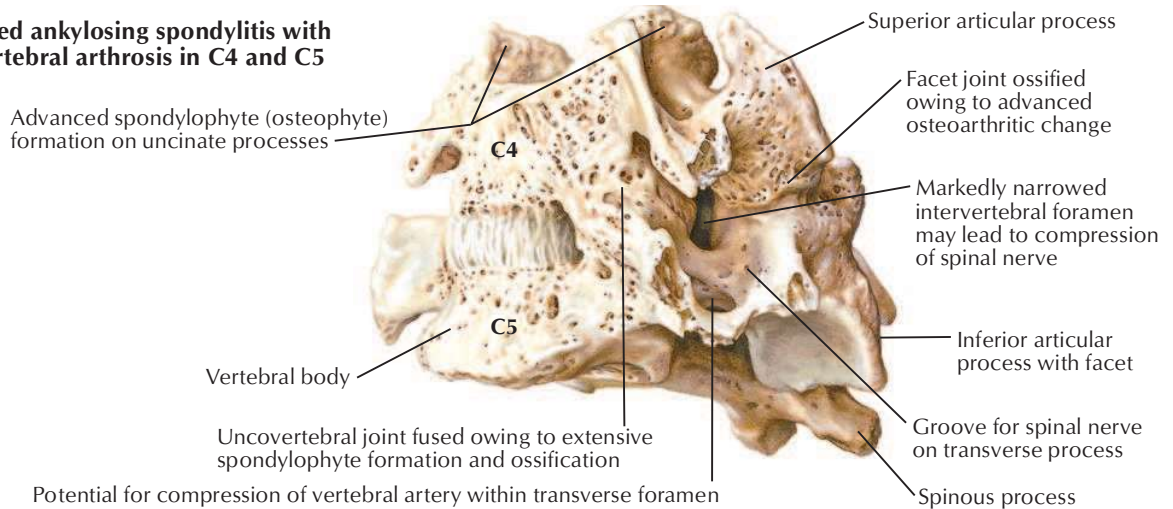
Greater wing of sphenoid

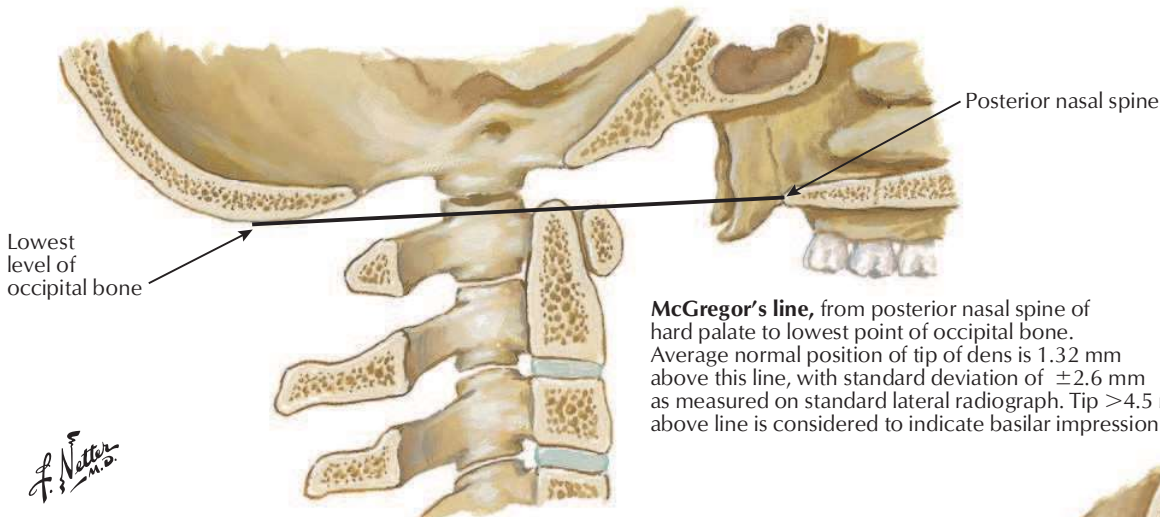
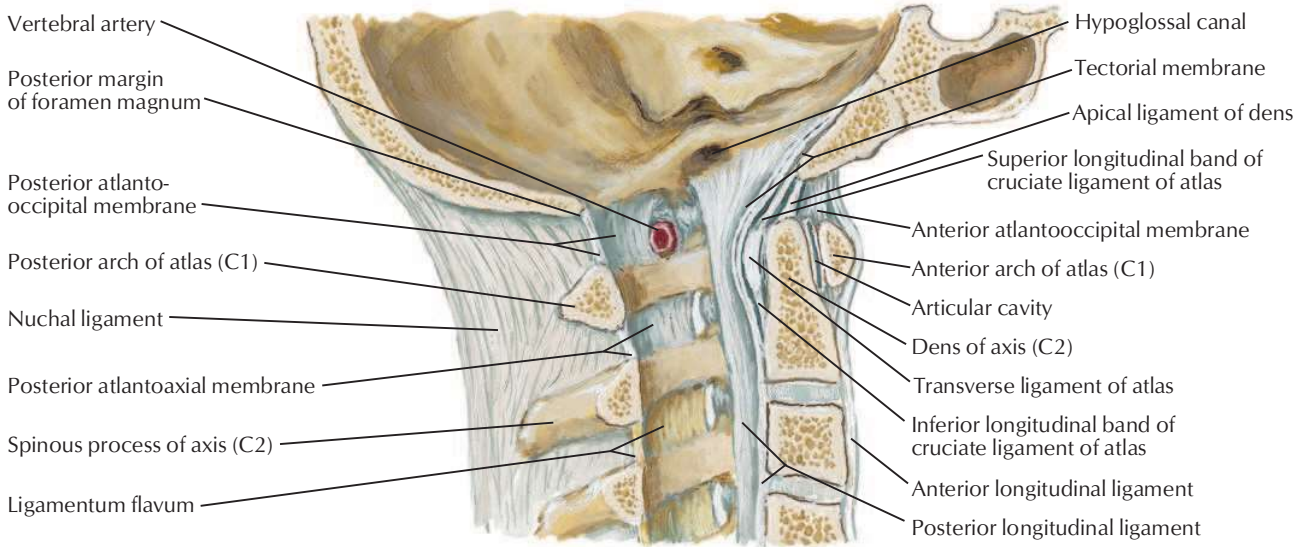
Inferior orbital fissure



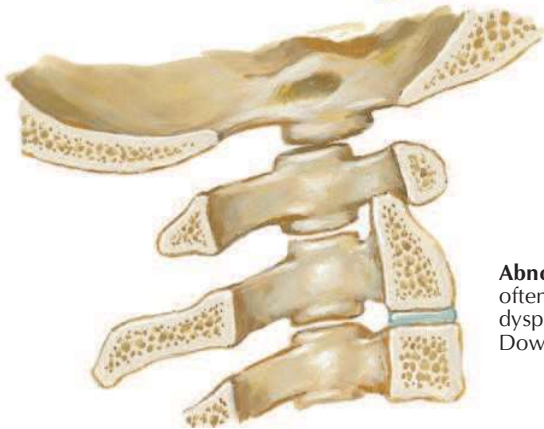C. Machado M.D.

Advanced ankylosing spondylitis with uncovertebral arthrosis in C4 and C5



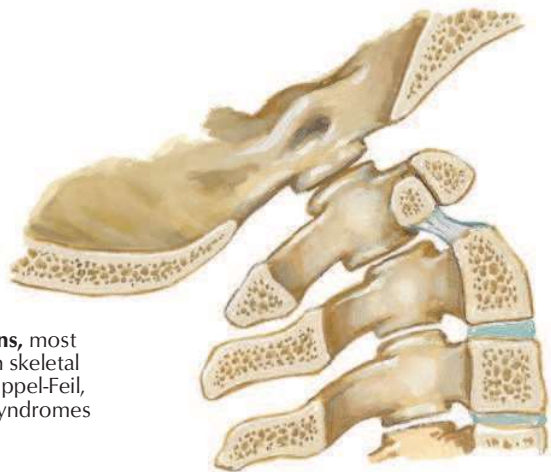


McGregor's line, from posterior nasal spine of hard palate to lowest point of occipital bone. Average normal position of tip of dens is 1.32 mm above this line, with standard deviation of ± 2.6 mm as measured on standard lateral radiograph. Tip >4.5 mm above line is considered to indicate basilar impression.



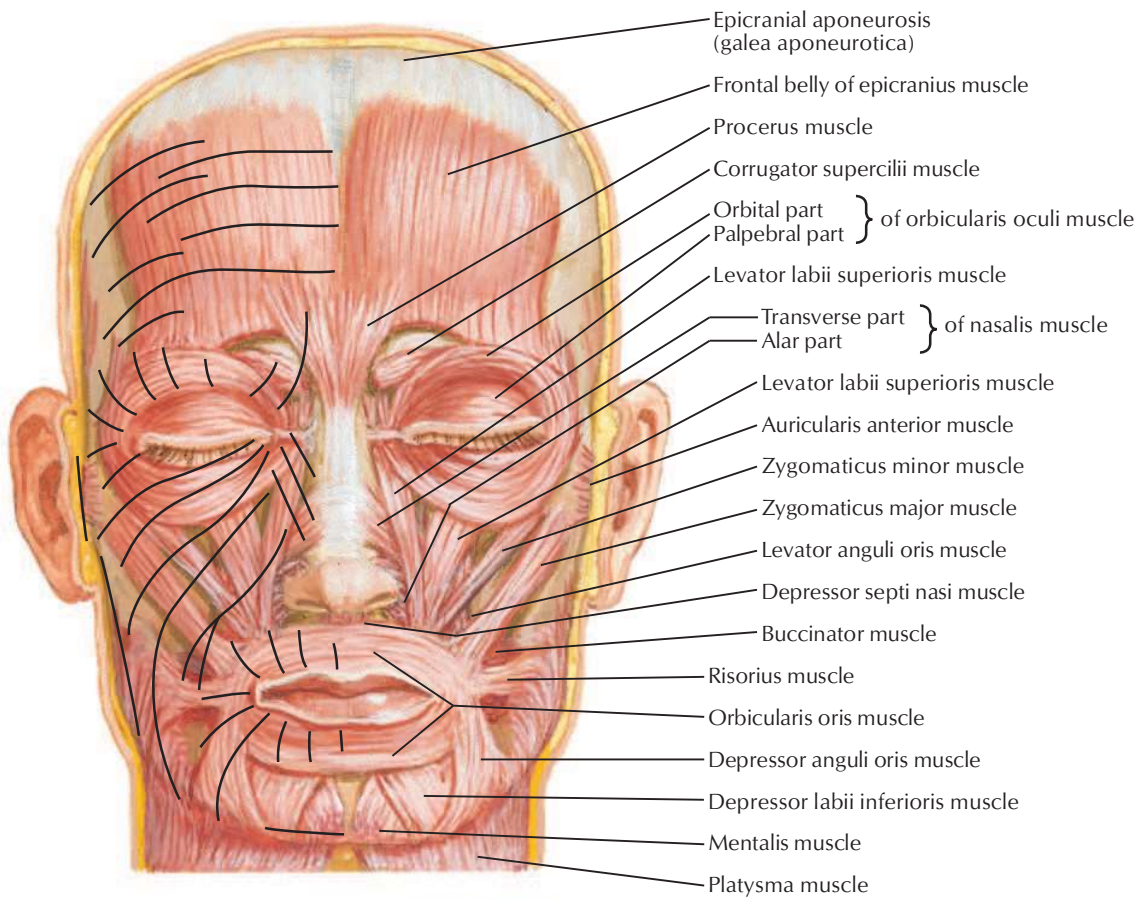
Hypoplastic dens

Abnormalities of dens, most often associated with skeletal dysplasias such as Klippel-Feil, Down, or Morquio syndromes

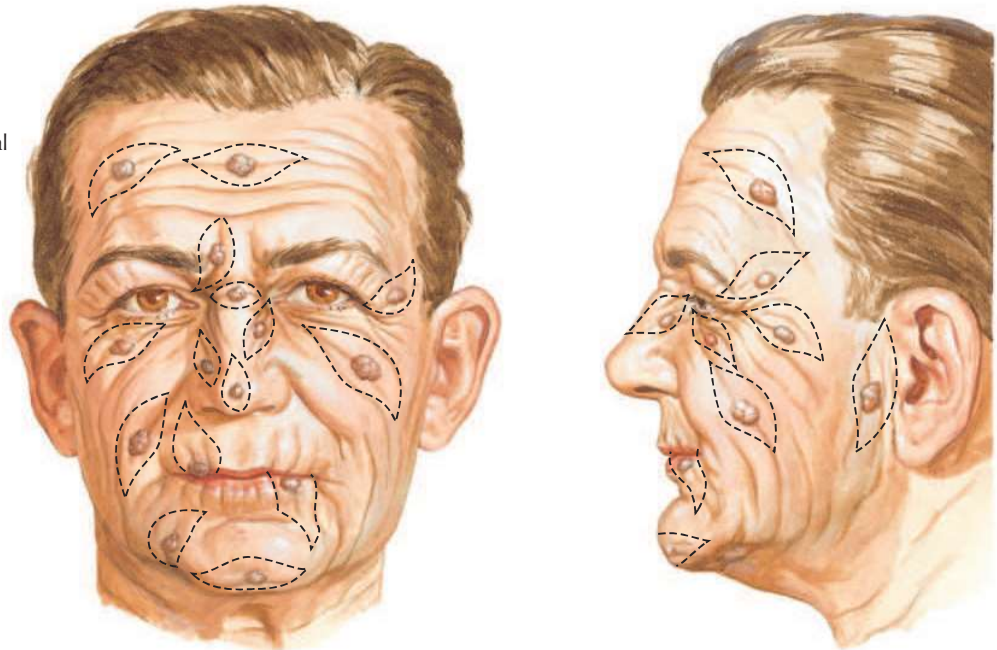


Os odontoideum with fibrous union and narrowing of vertebral canal with head in extension

Muscles of Facial Expression: Anterior View



Course of wrinkle lines (Langer's lines) of skin is transverse to fiber direction of facial muscles. Elliptical incisions for removal of skin tumors conform to direction of wrinkle lines.



Branches of facial nerve (CN VII)

Temporal branches

Posterior auricular nerve

Zygomatic branches

Buccal branches

Main trunk of facial nerve emerging from stylomastoid foramen

Marginal mandibular branches

Cervical branch

Frontal belly of epicranii muscle

Procerus muscle

Orbital part } Orbicularis oculi muscle
Palpebral part }

Levator labii superioris alaeque nasi muscle

Nasalis muscle

Levator labii superioris muscle

Zygomatic minor muscle

Zygomatic major muscle

Buccinator muscle

Orbicularis oris muscle

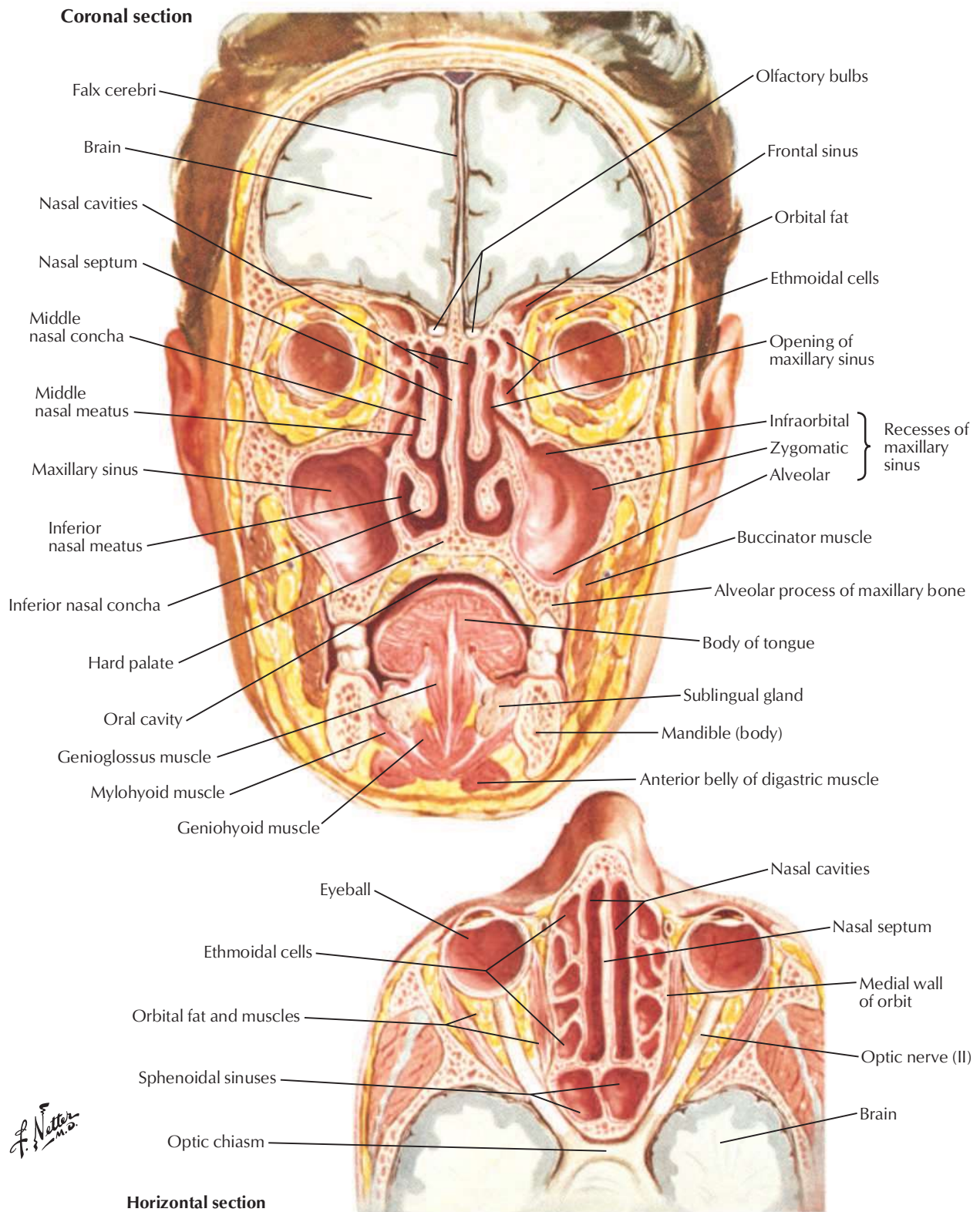
Risorius muscle

Depressor labii inferioris muscle

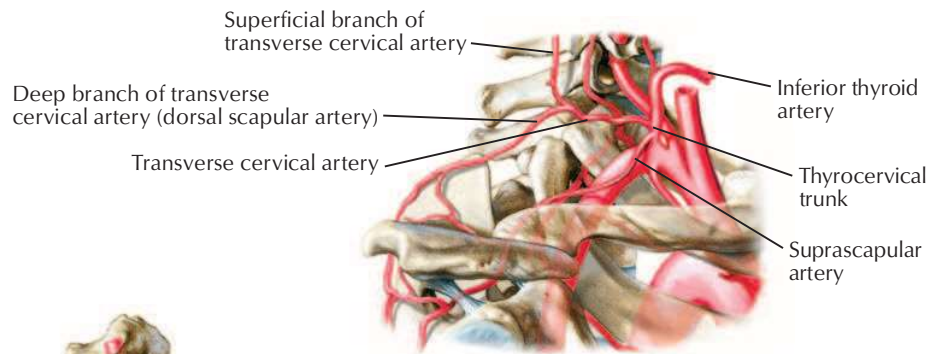
Depressor anguli oris muscle

Platysma muscle

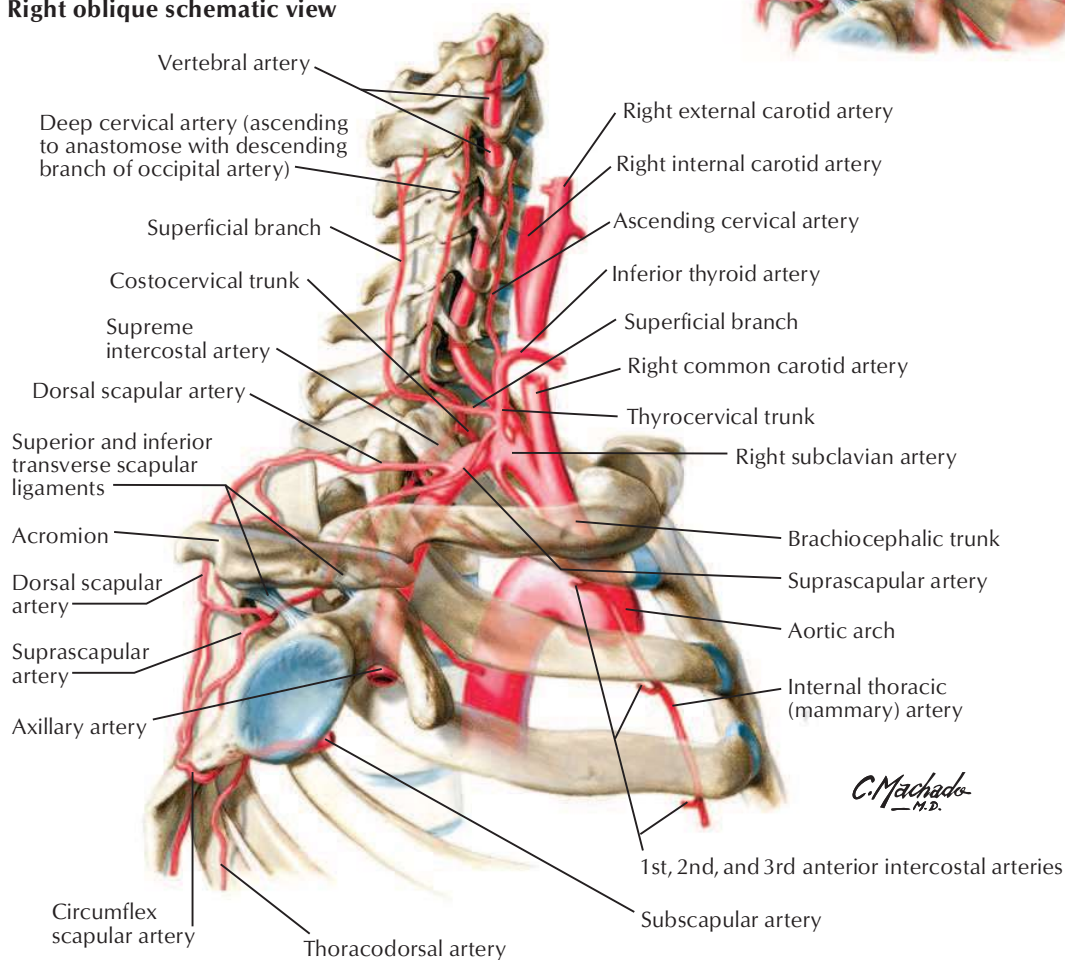
C. Machado
M.D.

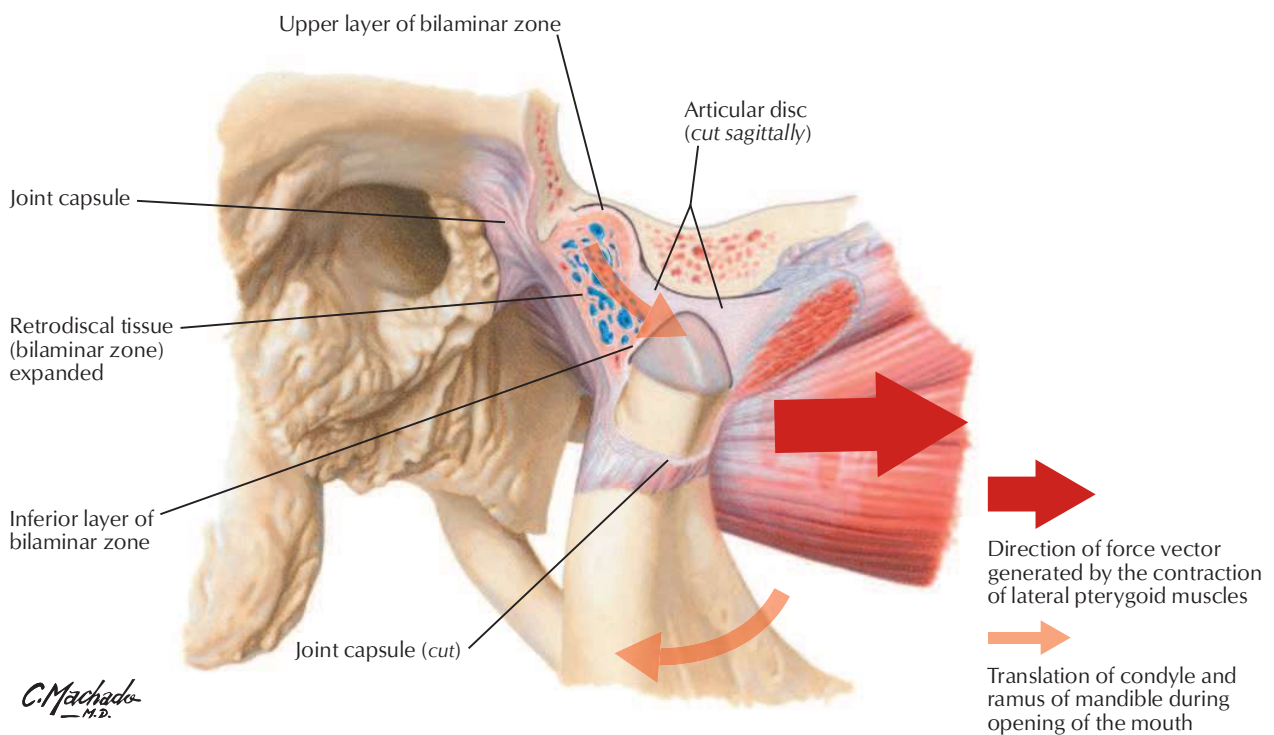
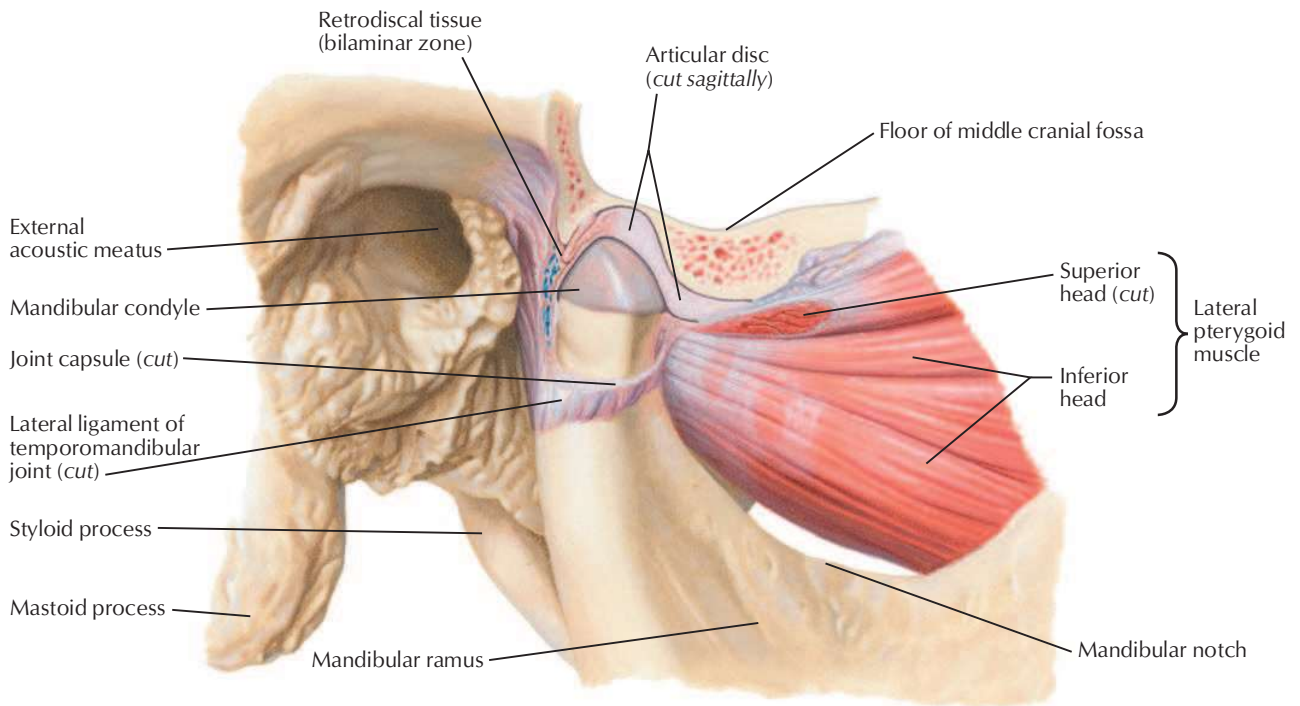


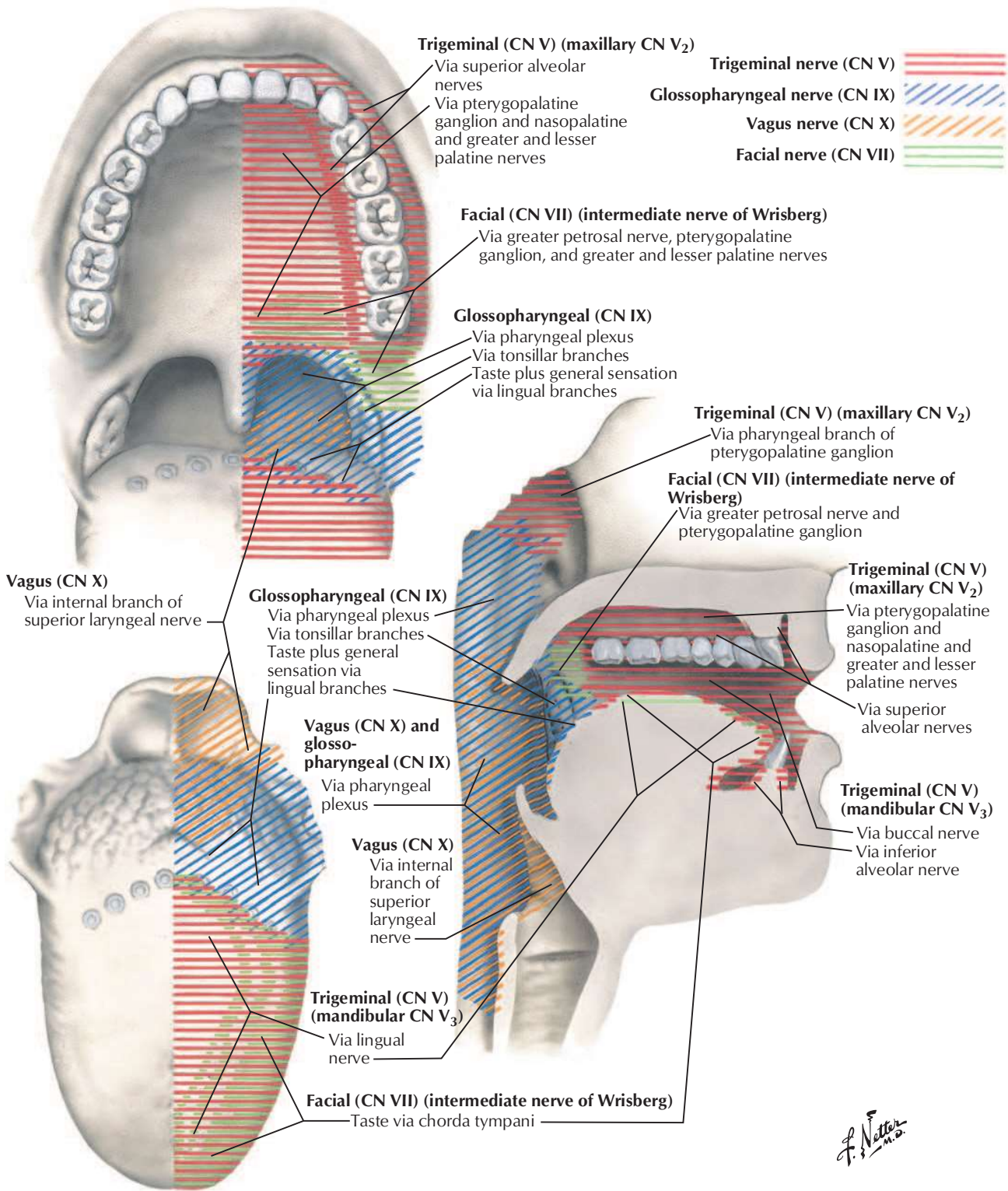
Common origin of superficial cervical and dorsal scapular arteries from transverse cervical artery (~30%)



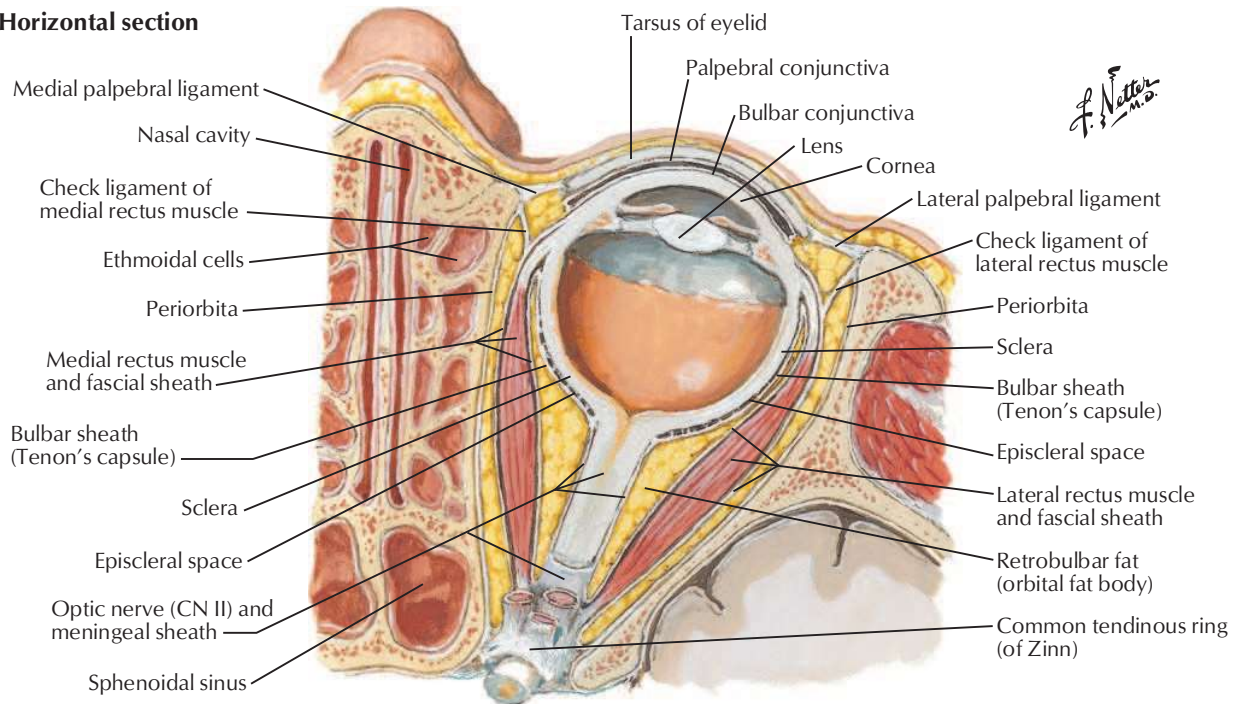
Right oblique schematic view



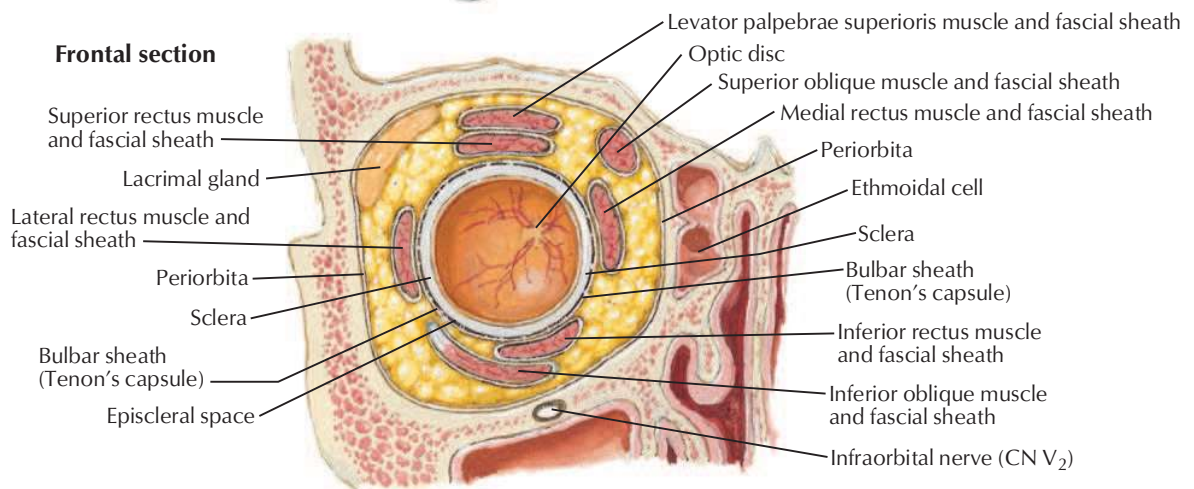




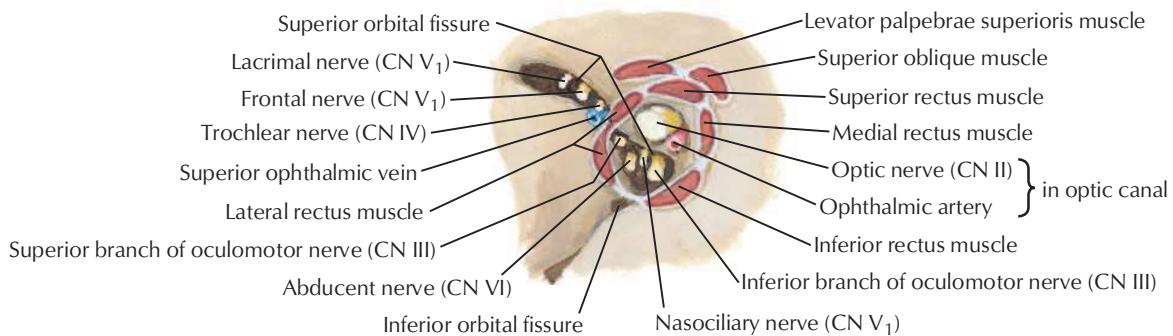
Horizontal section



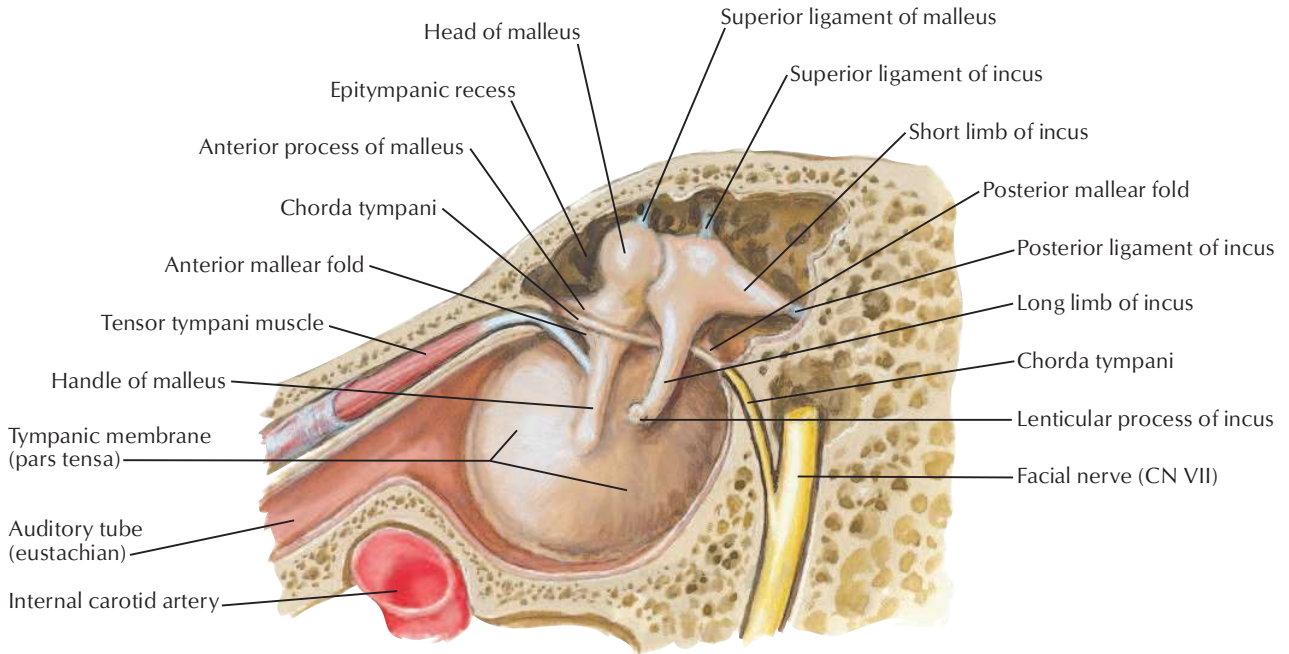
Frontal section



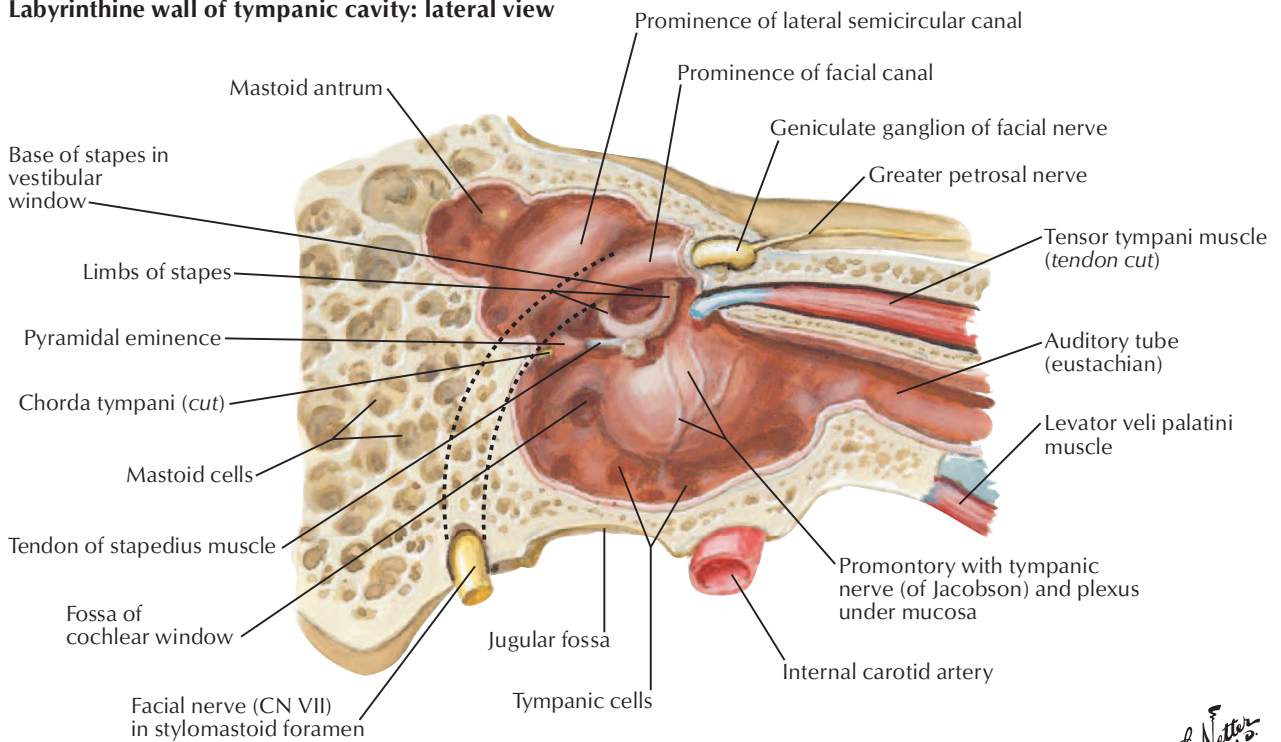
Muscle attachments and nerves and vessels entering orbit



Lateral wall of tympanic cavity: medial (internal) view

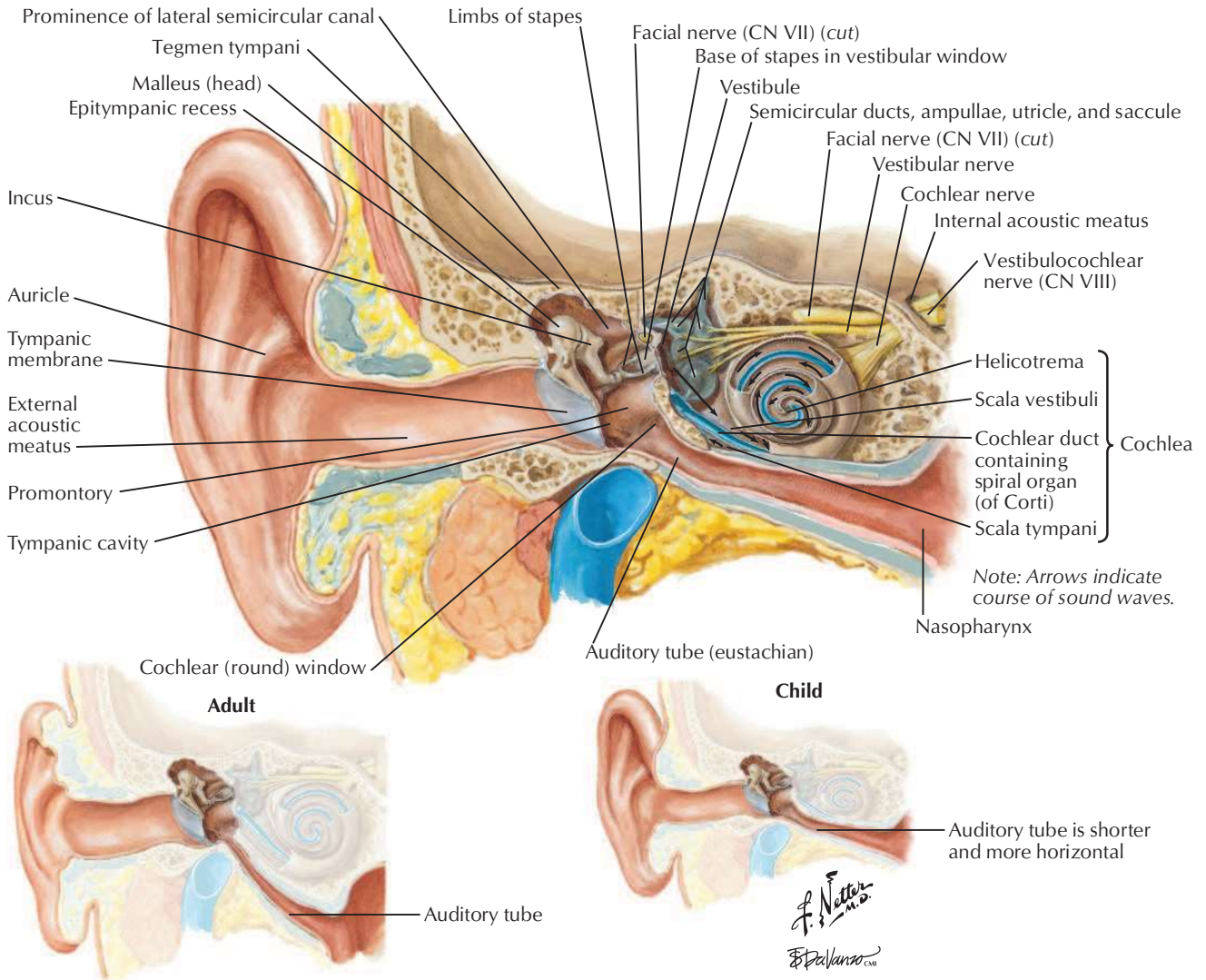


Labyrinthine wall of tympanic cavity: lateral view

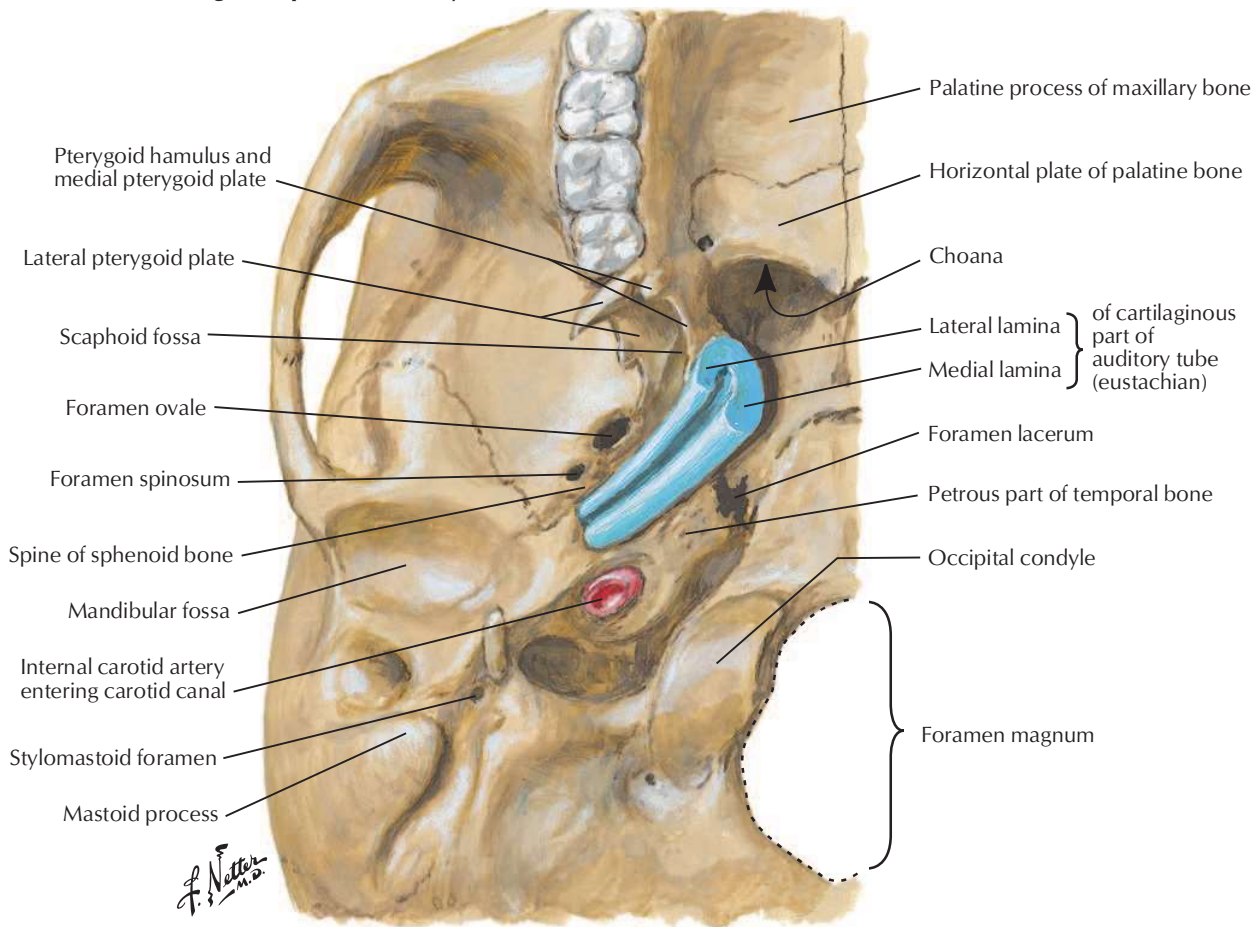


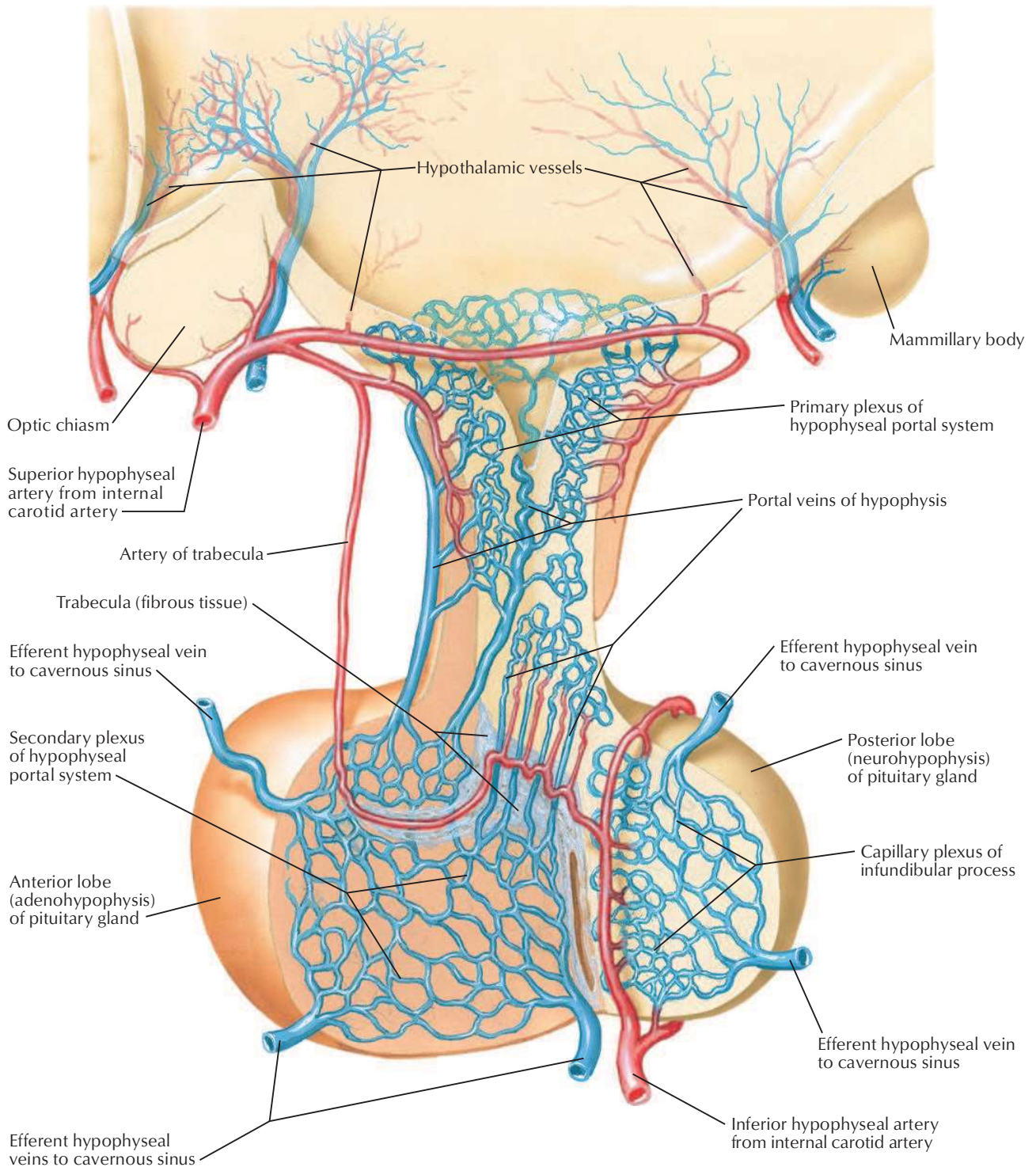
F. Netter M.D.

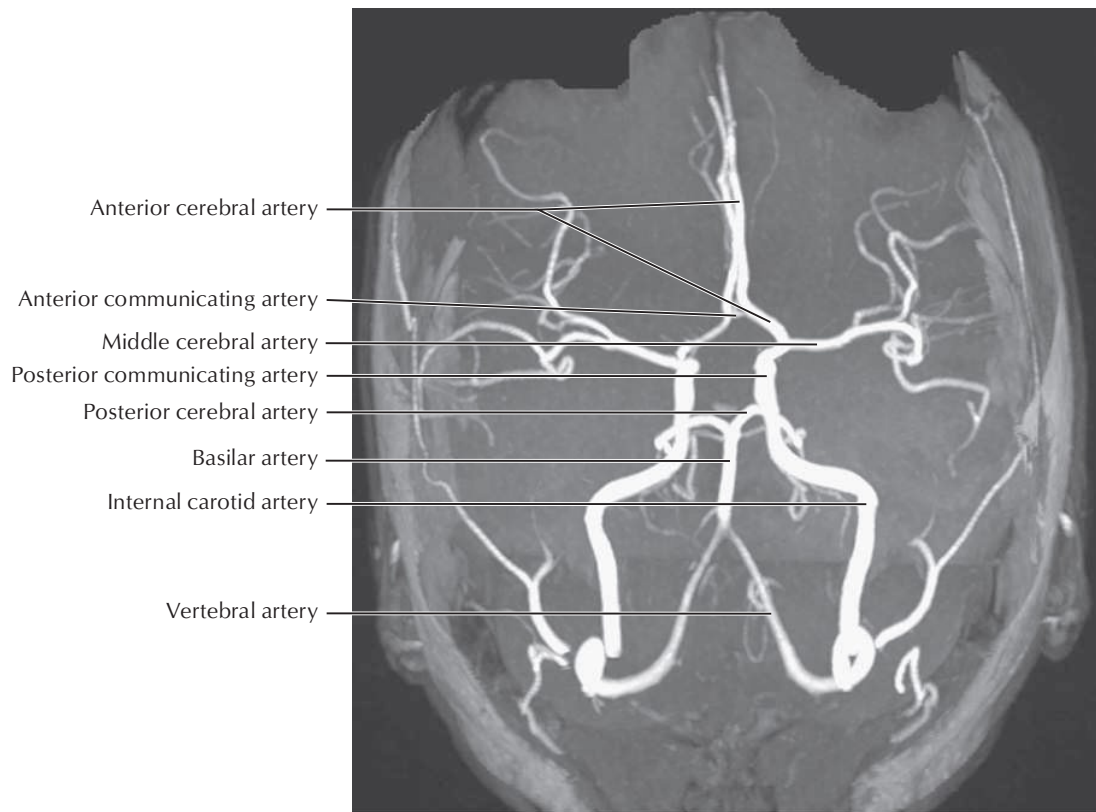
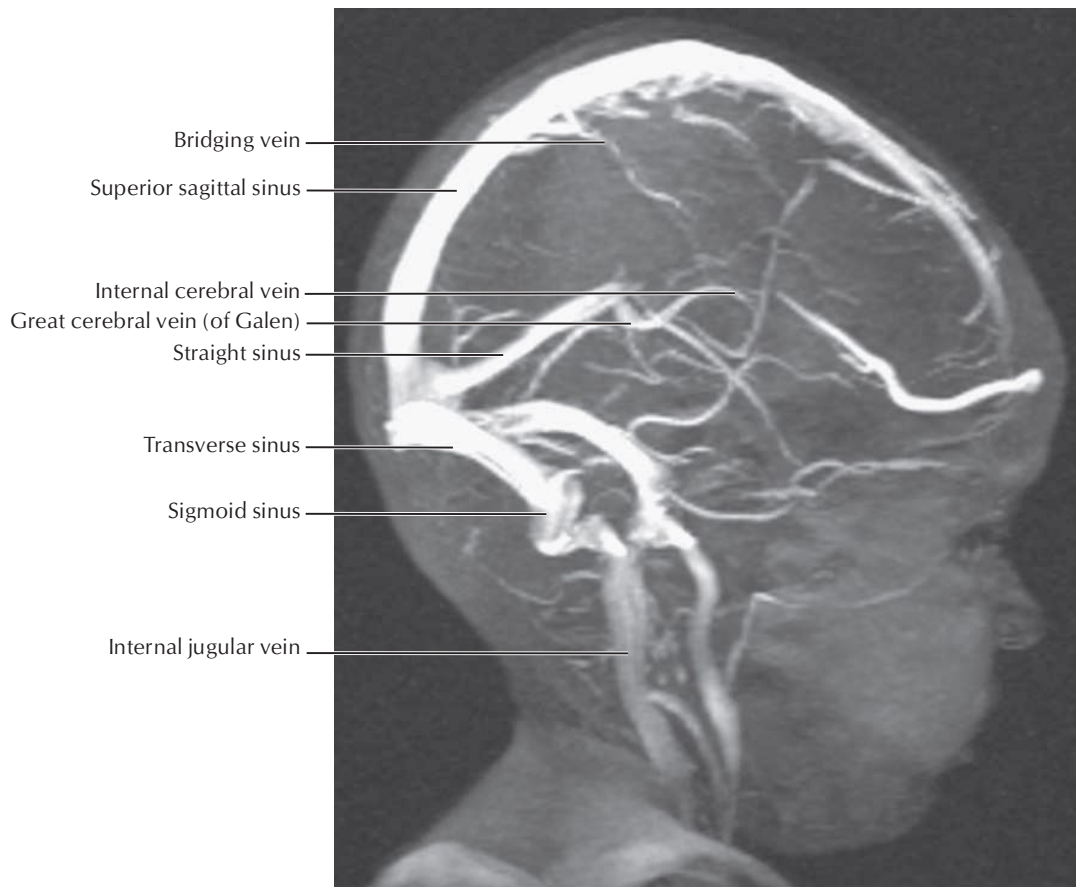
Pediatric ear: frontal section




Cartilaginous part of auditory tube (eustachian) at base of skull: inferior view








T2-weighted axial brain MRI without contrast



T2-weighted axial brain MRI without contrast



T2-weighted coronal brain MRI without contrast



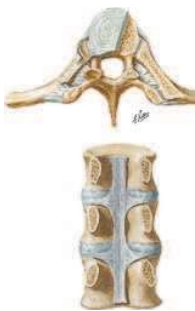BACK AND SPINAL CORD

3

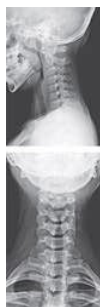Surface Anatomy	161
Bones and Ligaments	162-168
Spinal Cord	169-179
Muscles and Nerves	180-184
Cross-Sectional Anatomy	185-186

Structures With High Clinical Significance	Table 3.1
Muscle Tables	Tables 3.2-3.3
Electronic Bonus Plates	BP33-BP43

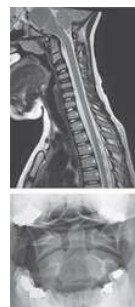ELECTRONIC BONUS PLATES



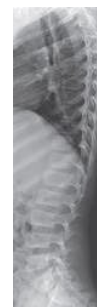BP33 Vertebral Ligaments



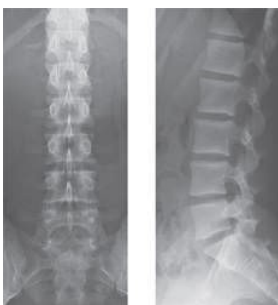BP34 Cervical Spine: Radiographs



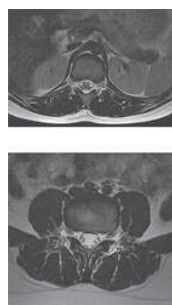
BP35 Cervical Spine: MRI and Radiograph



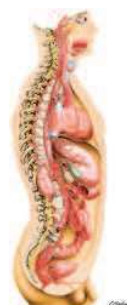BP36 Thoracolumbar Spine: Lateral Radiograph



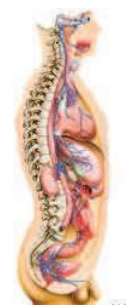BP37 Lumbar Vertebrae: Radiographs



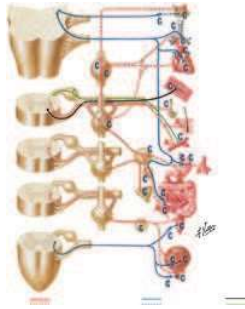
BP38 Lumbar Spine: MRIs



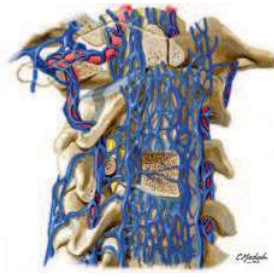BP39 Sympathetic Nervous System: General Topography



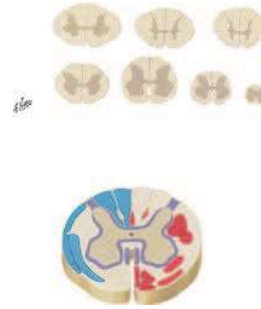
BP40 Parasympathetic Nervous System: General Topography

ELECTRONIC BONUS PLATES—*cont'd*

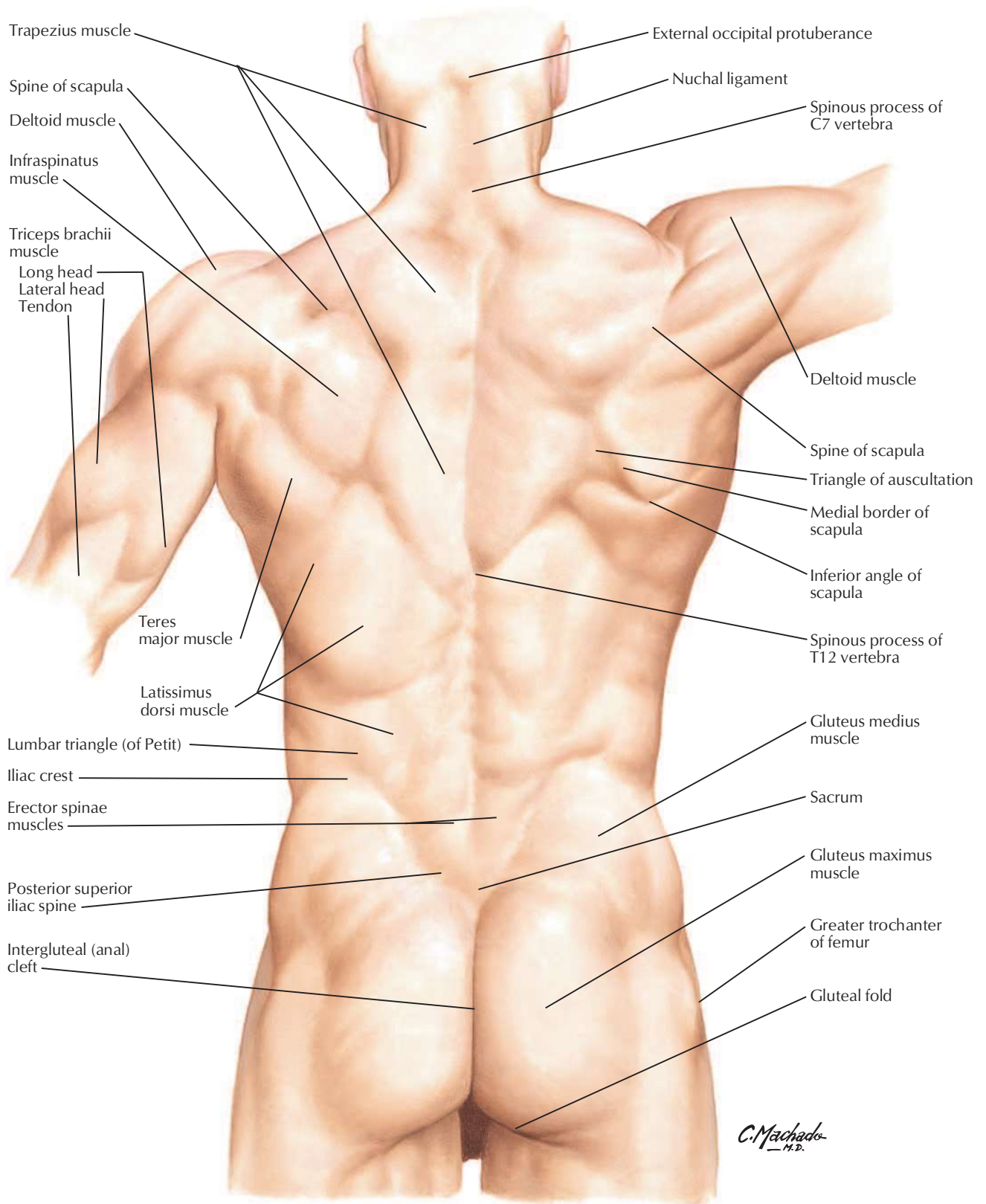
BP41 Cholinergic and Adrenergic Synapses: Schema

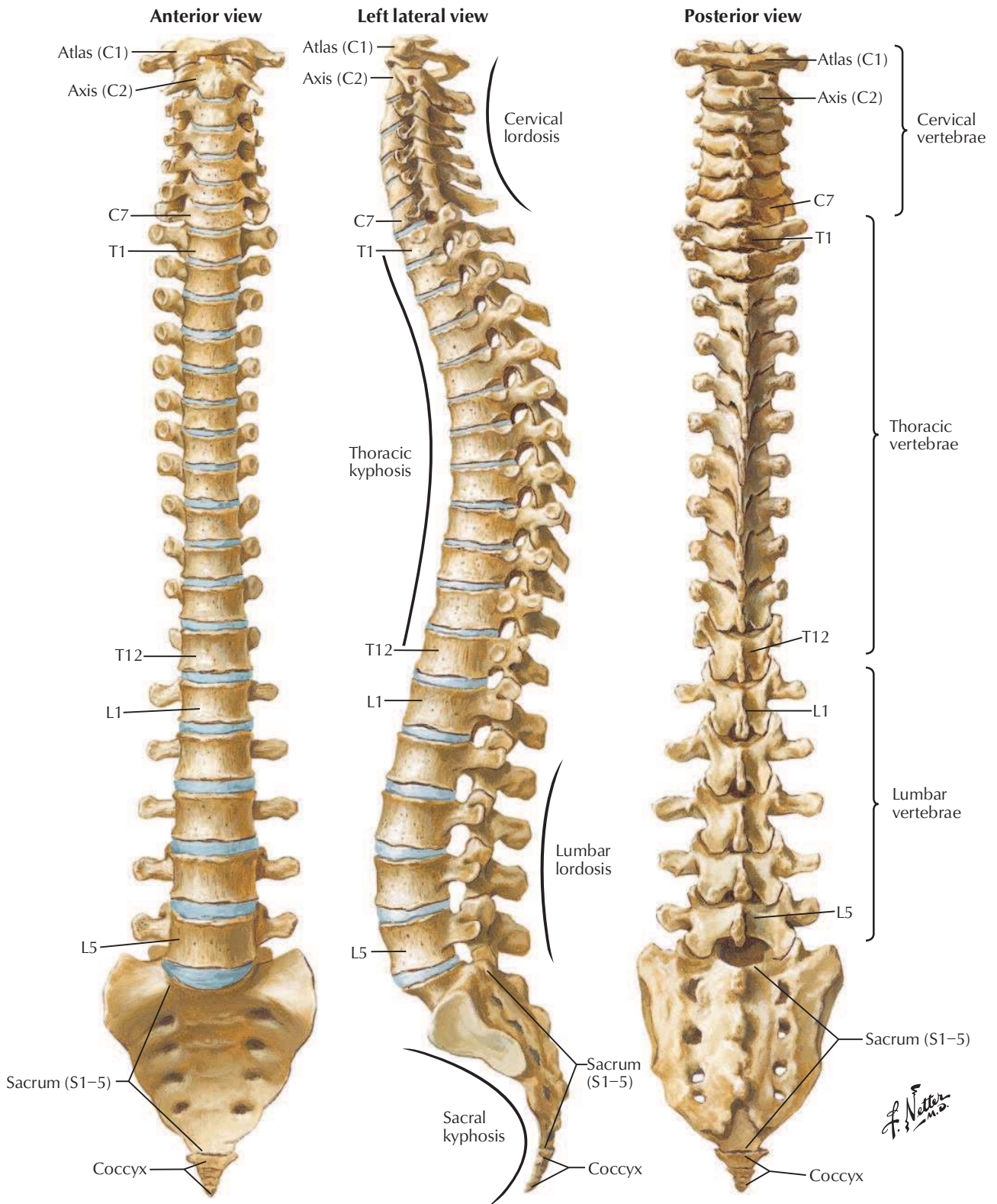


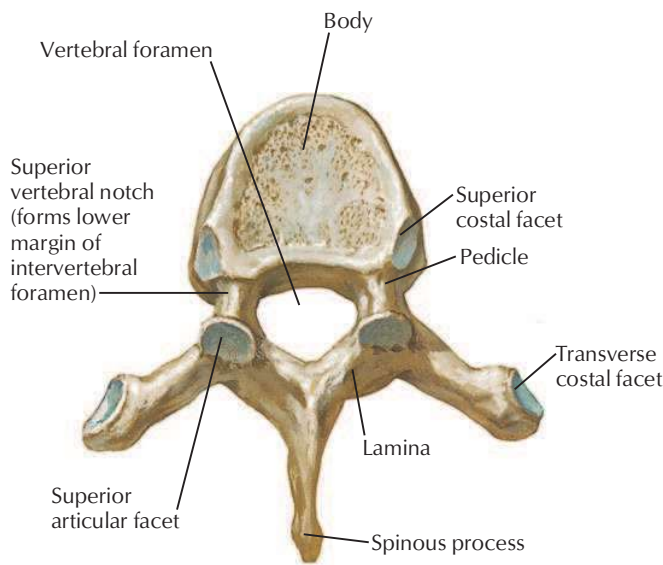
BP42 Vertebral Veins: Detail Showing Venous Communications



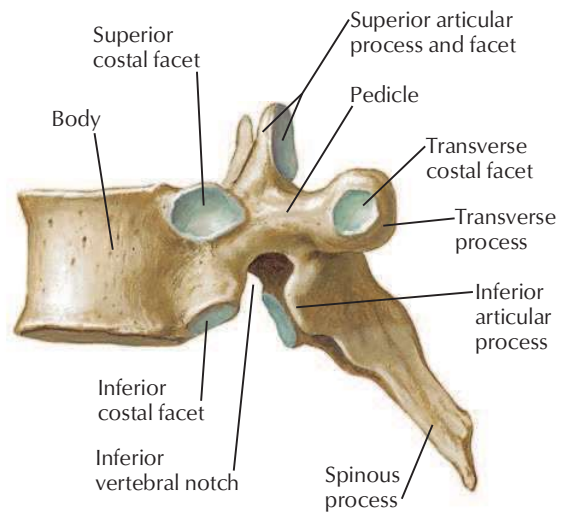
BP43 Spinal Cord Cross Sections: Fiber Tracts



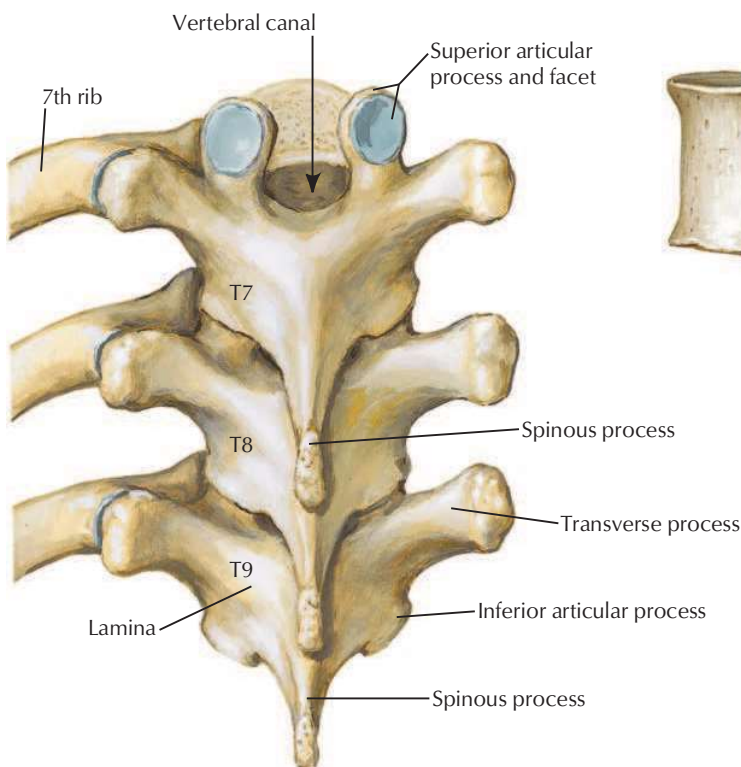




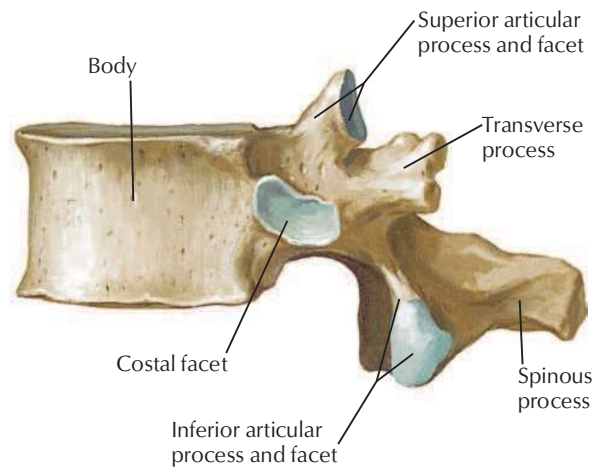
**T6 vertebra:
superior view**



**T6 vertebra:
lateral view**

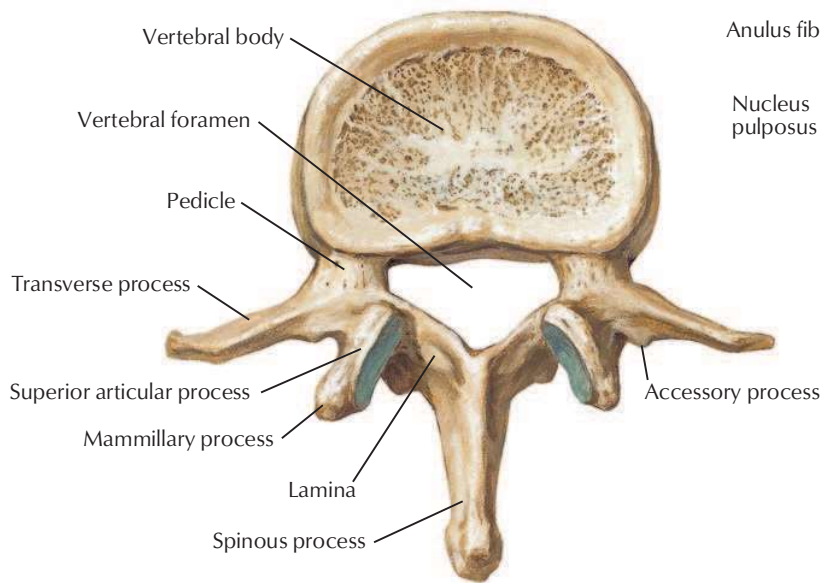


**T7, T8, and T9 vertebrae:
posterior view**

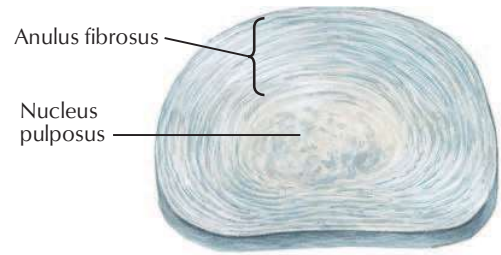


**T12 vertebra:
lateral view**

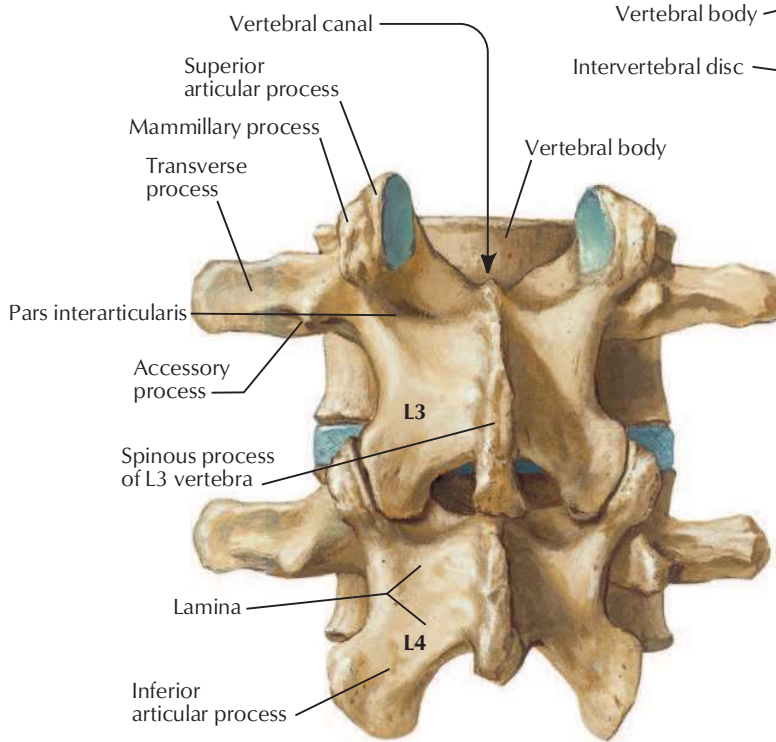
F. Netter M.D.



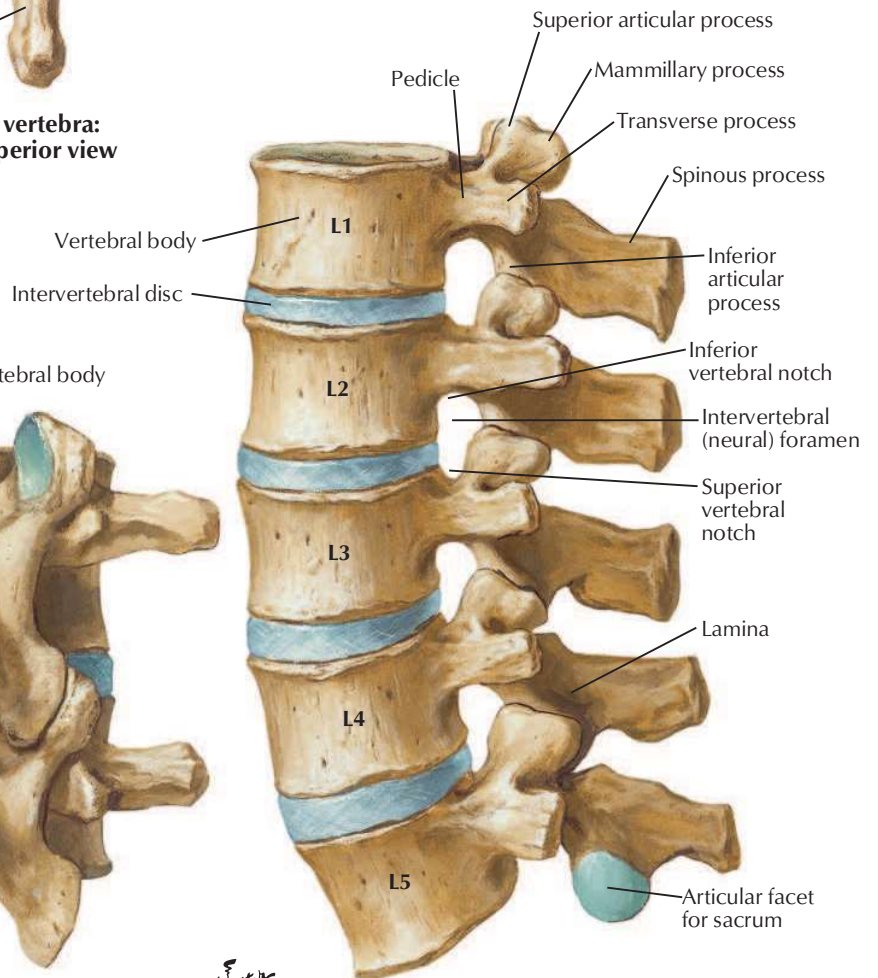
**L2 vertebra:
superior view**



Intervertebral disc



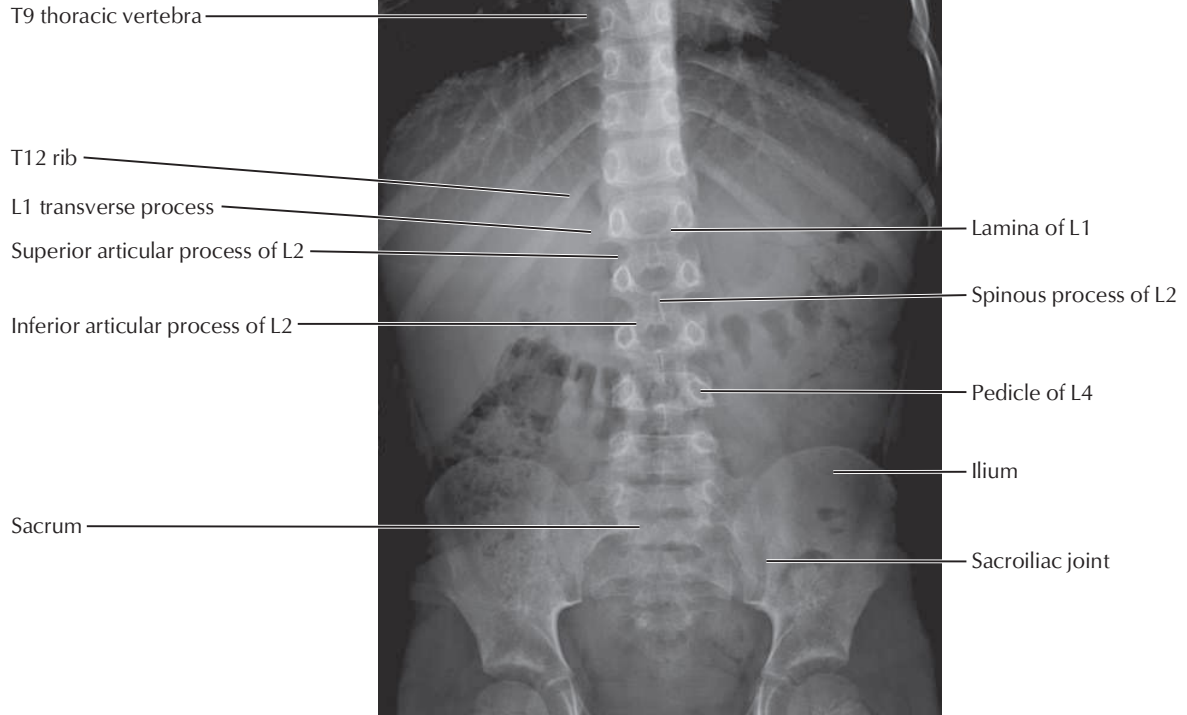
**L3 and L4 vertebrae:
posterior view**



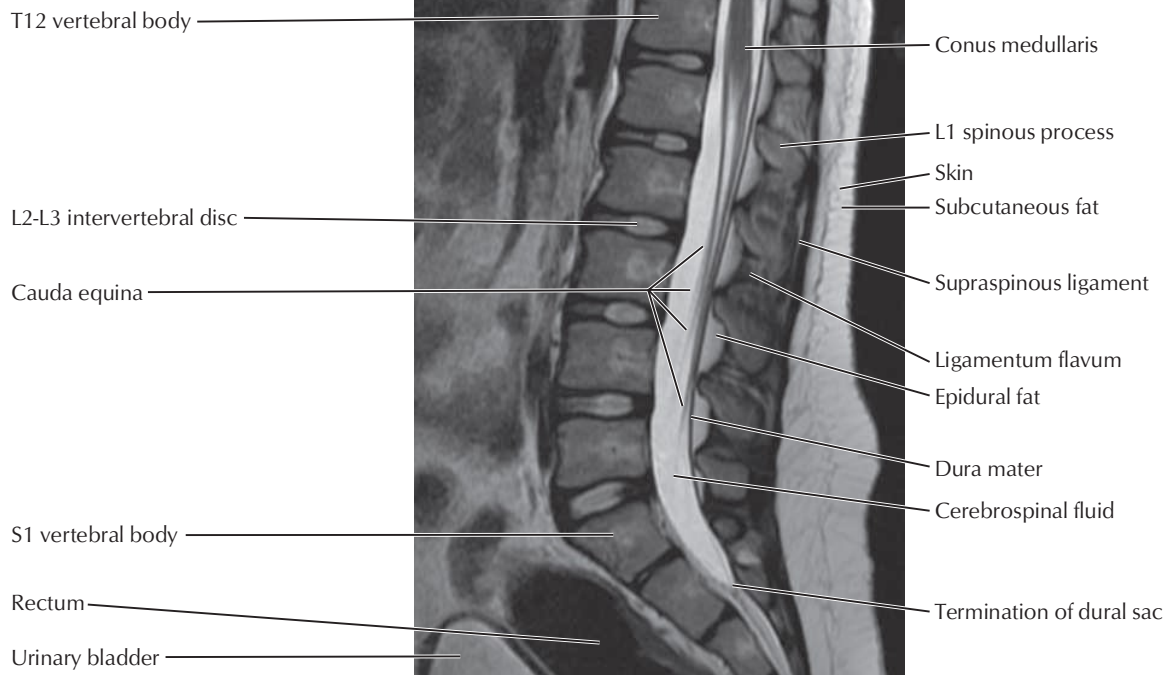
**Lumbar vertebrae, articulated:
left lateral view**

See also [Plates 162, 250](#)

Anteroposterior radiograph of thoracolumbar spine

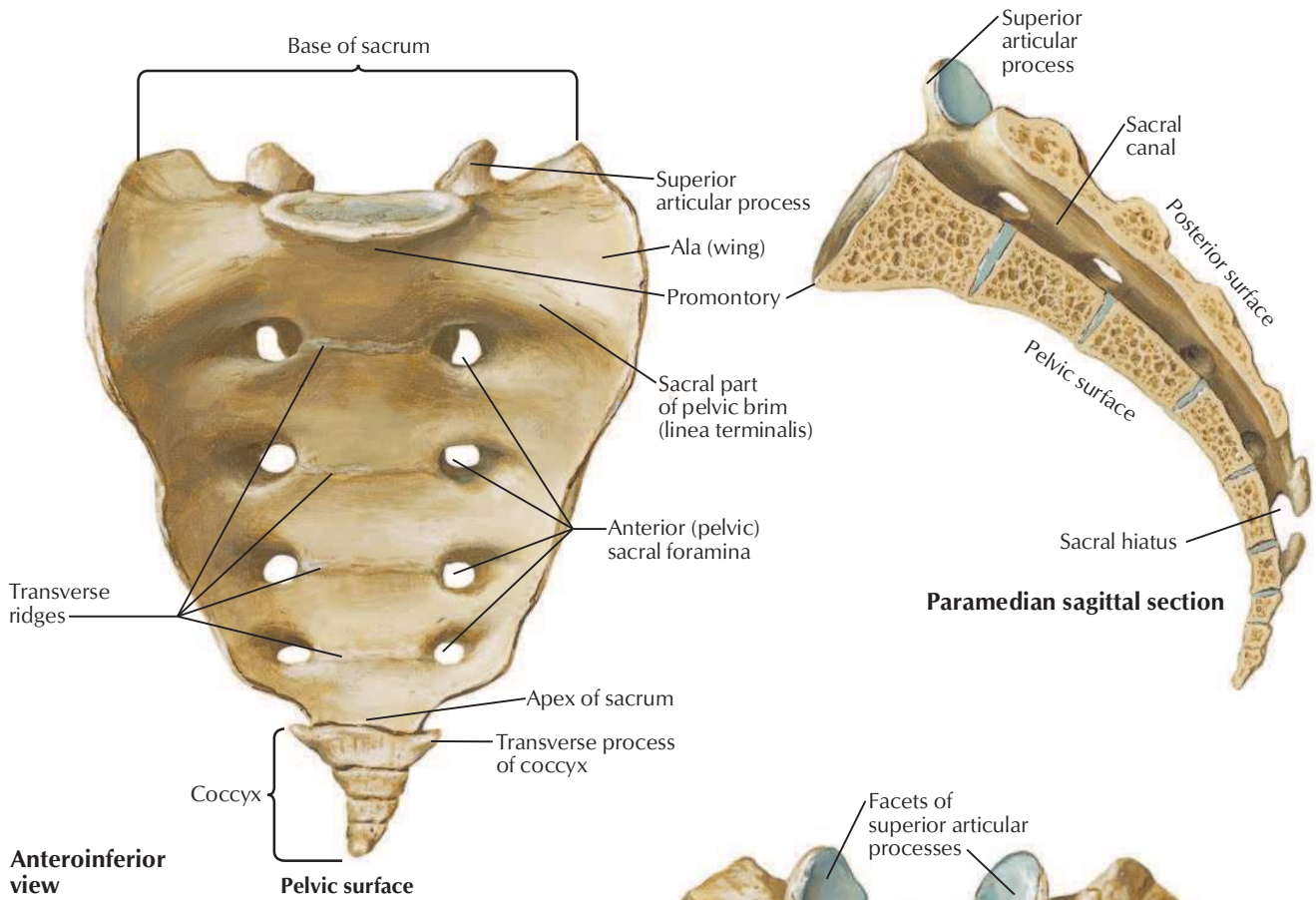


T2-weighted sagittal MRI of lumbar spine

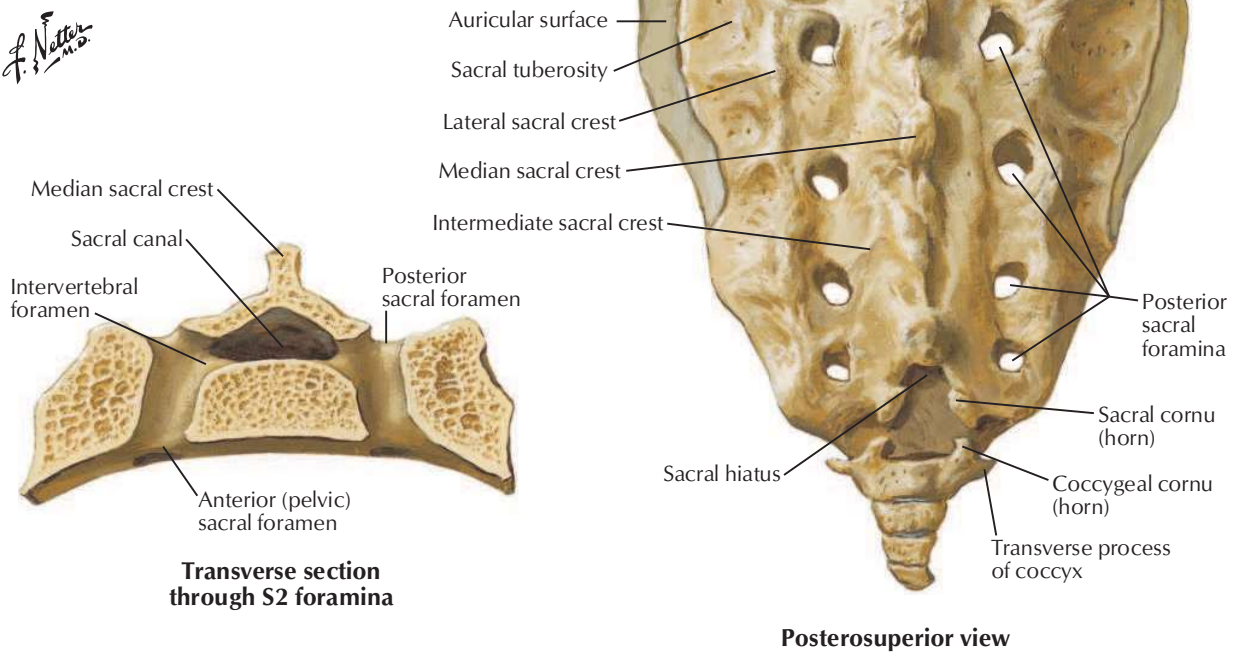


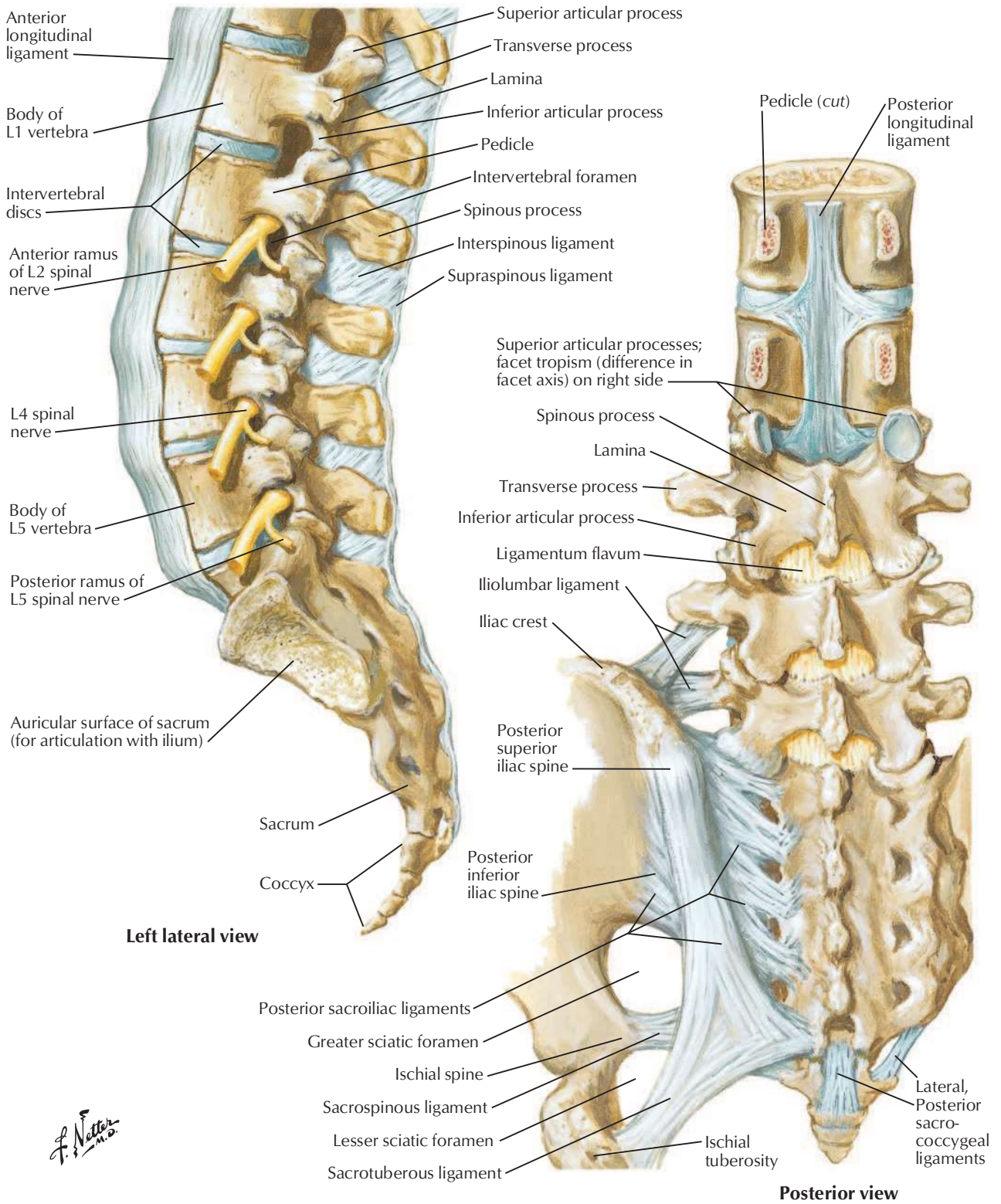
Sacrum and Coccyx

See also [Plates 334, 338](#)

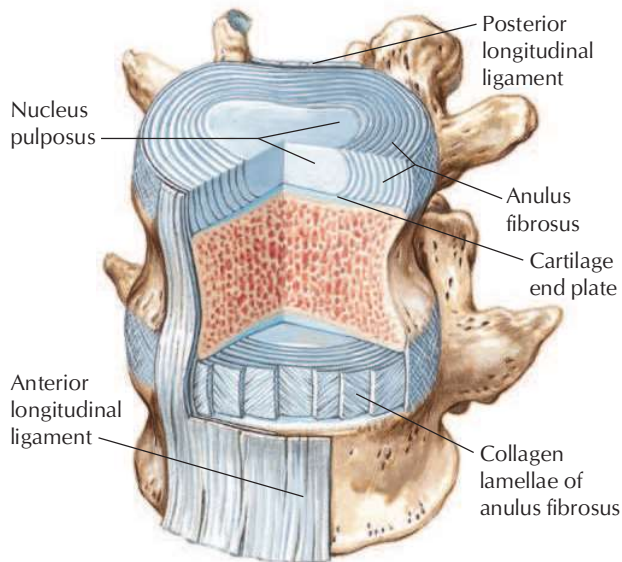
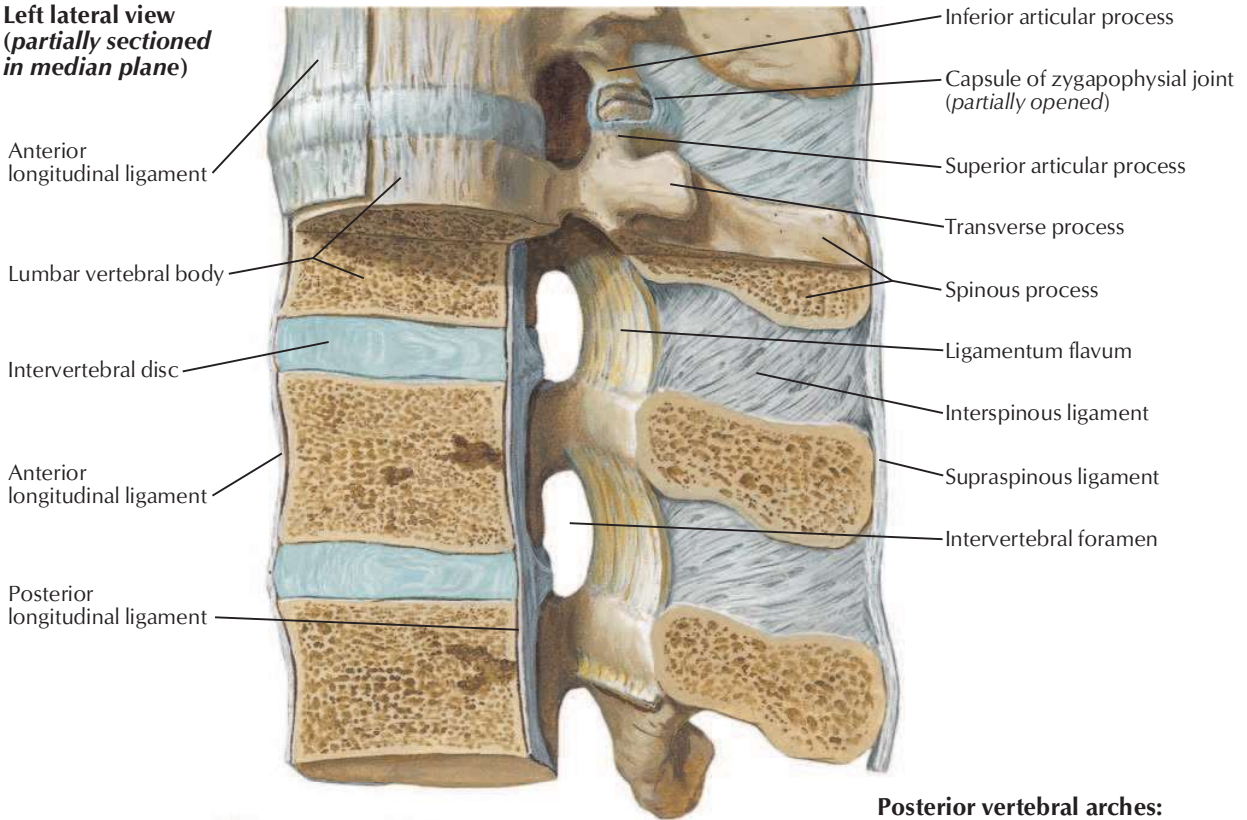


F. Netter M.D.





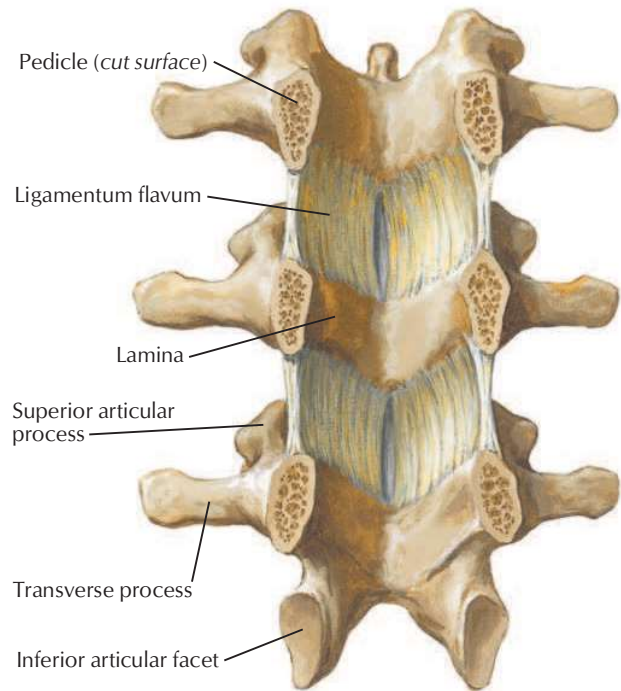
**Left lateral view
(partially sectioned
in median plane)**

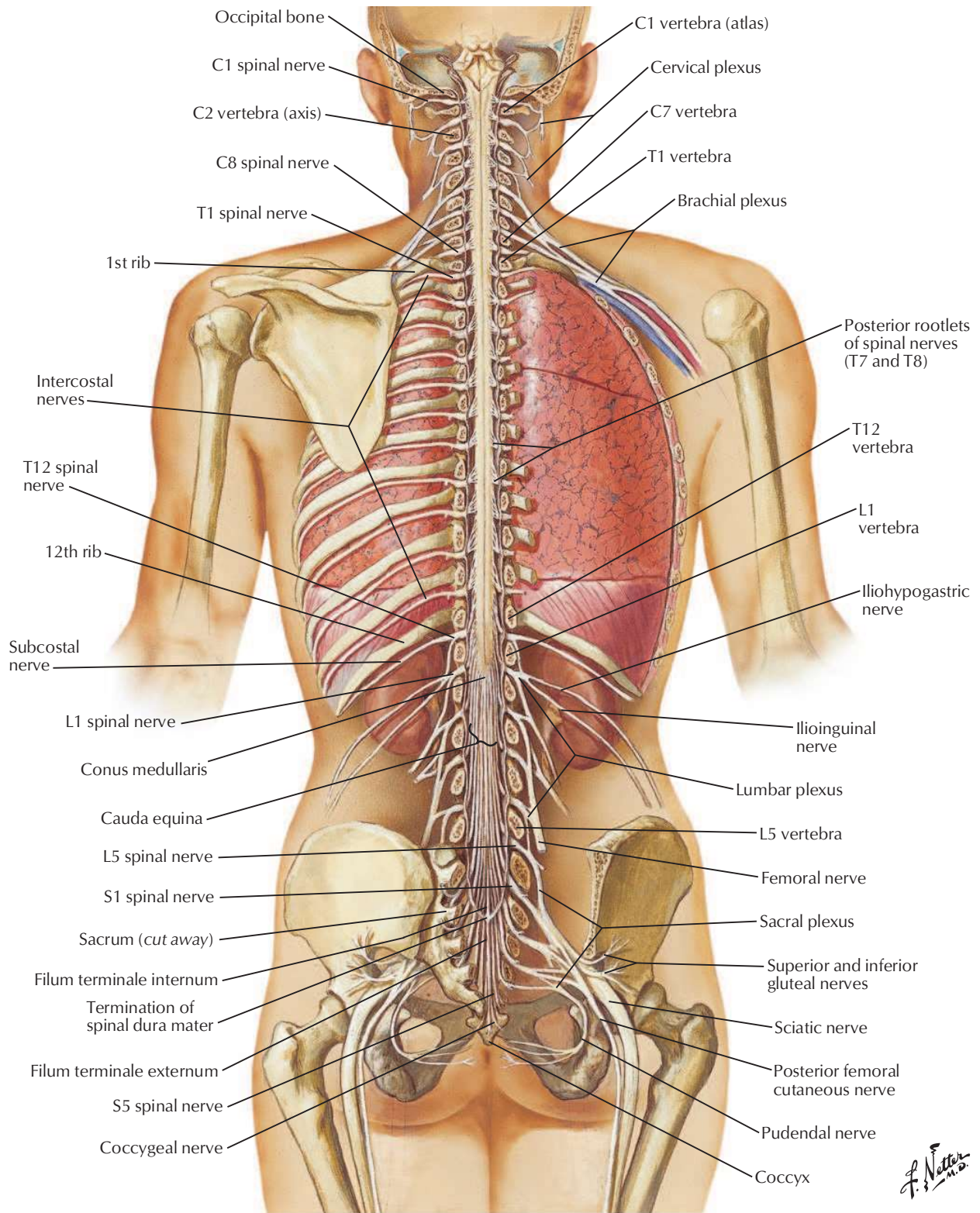


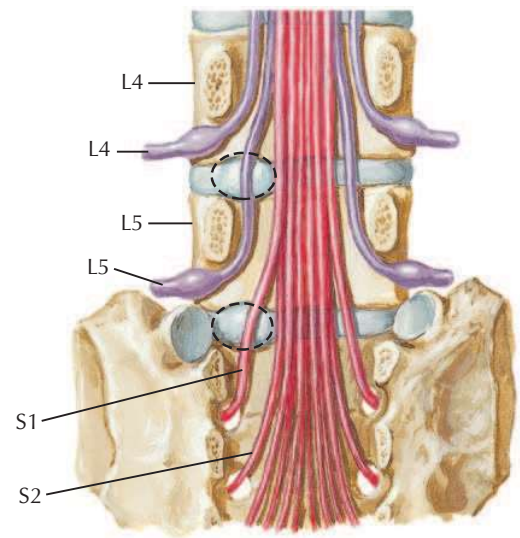
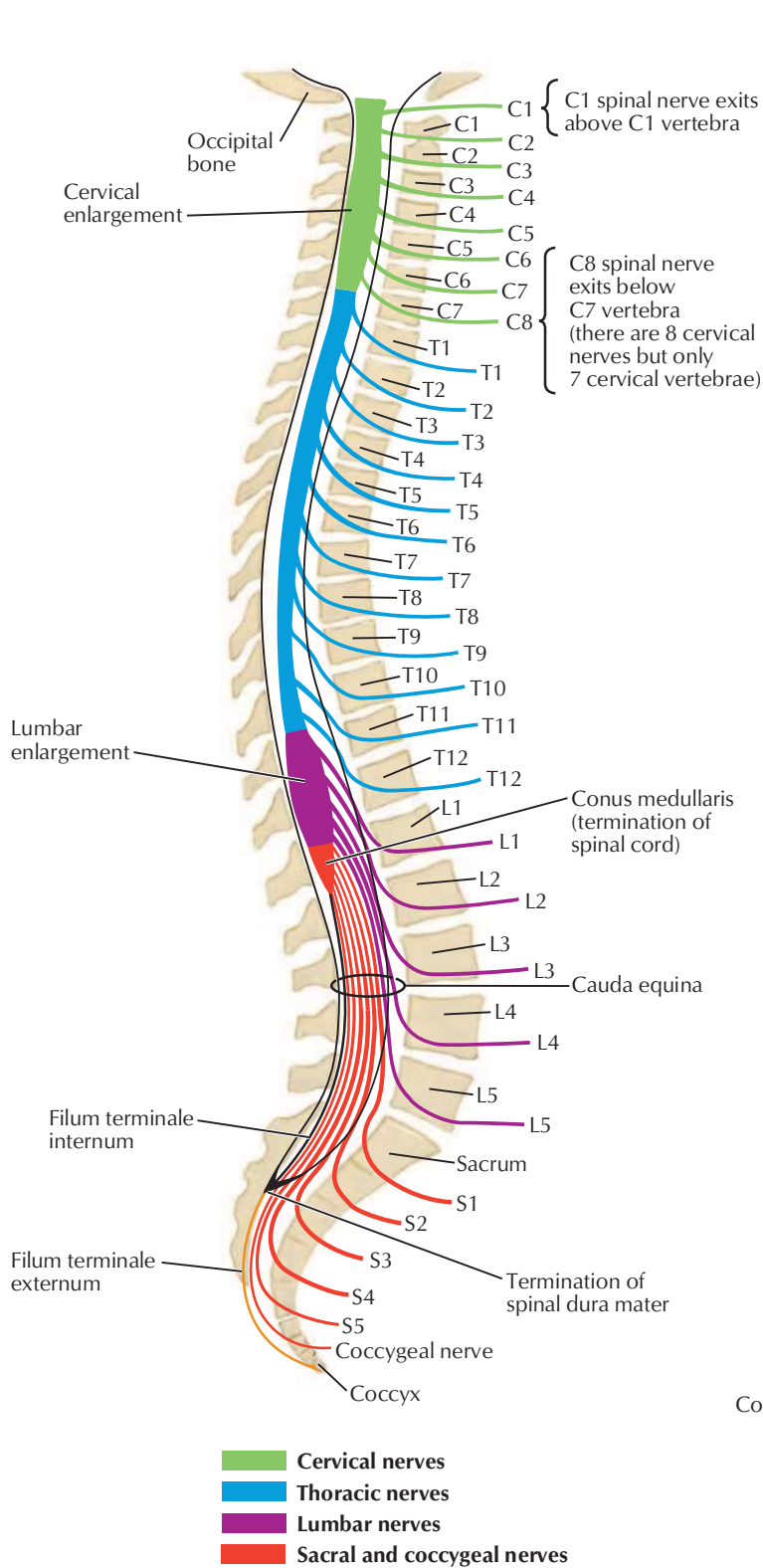
Intervertebral disc composed of central nuclear zone of collagen and hydrated proteoglycans surrounded by concentric lamellae of collagen fibers

F. Netter M.D. *C. Machado M.D.*

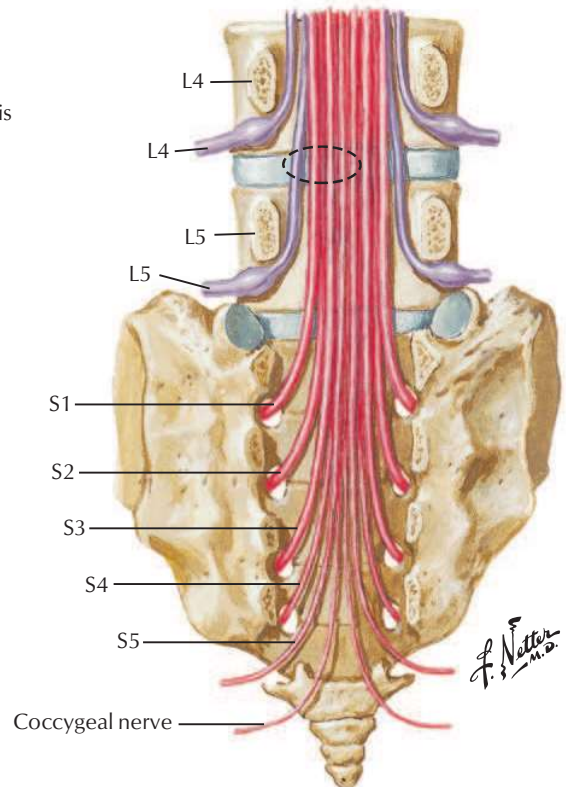
**Posterior vertebral arches:
anterior view**



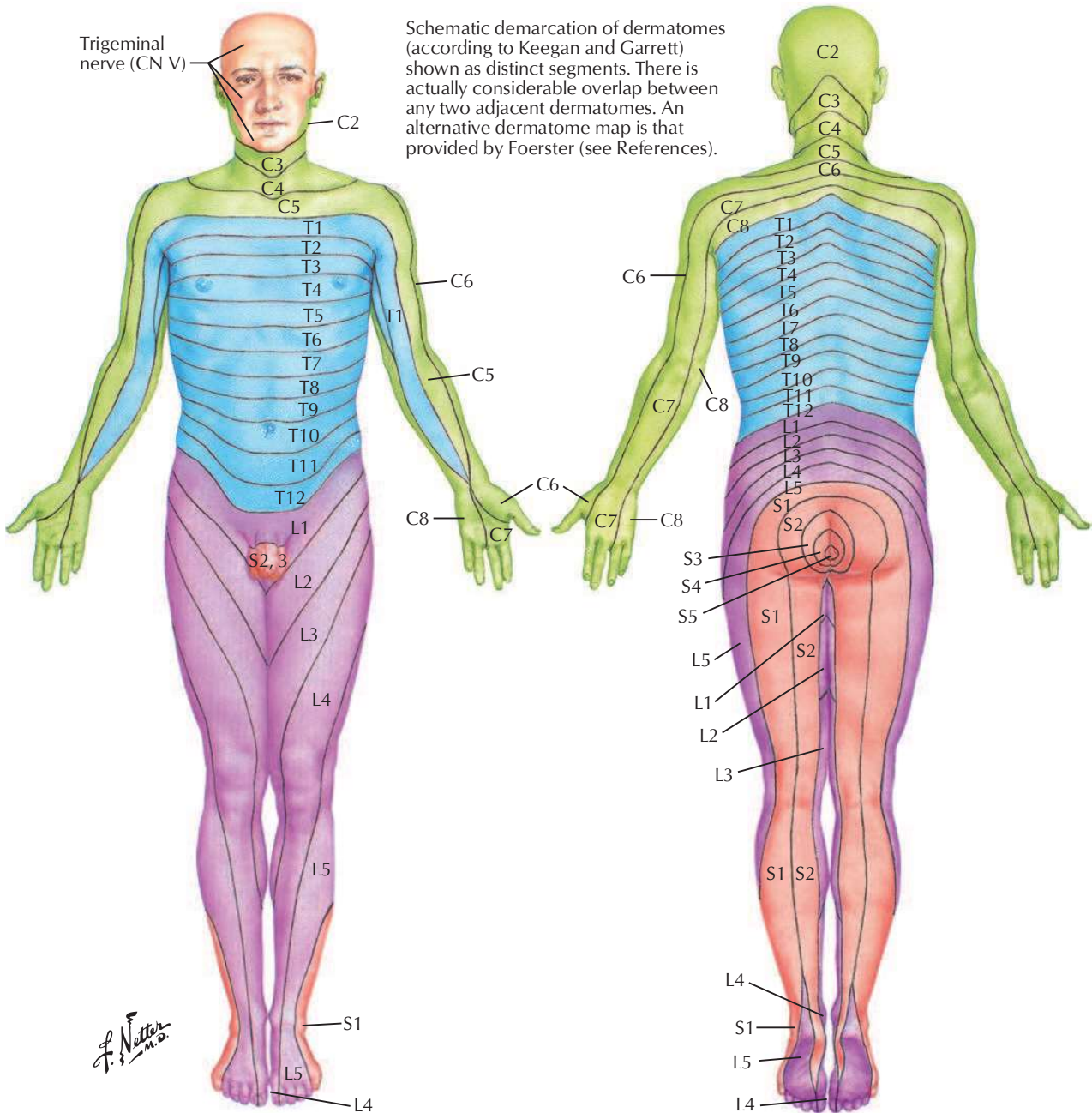




Lumbar disc protrusion (*dashed ovals*) does not usually affect nerve exiting above disc. Lateral protrusion at disc level L4-5 affects L5 spinal nerve, not L4 spinal nerve. Protrusion at disc level L5-S1 affects S1 spinal nerve, not L5 spinal nerve.



Medial protrusion at disc level L4-5 (*dashed oval*) rarely affects L4 spinal nerve but might affect L5 spinal nerve and sometimes S1-4 spinal nerves.



Schematic demarcation of dermatomes (according to Keegan and Garrett) shown as distinct segments. There is actually considerable overlap between any two adjacent dermatomes. An alternative dermatome map is that provided by Foerster (see References).

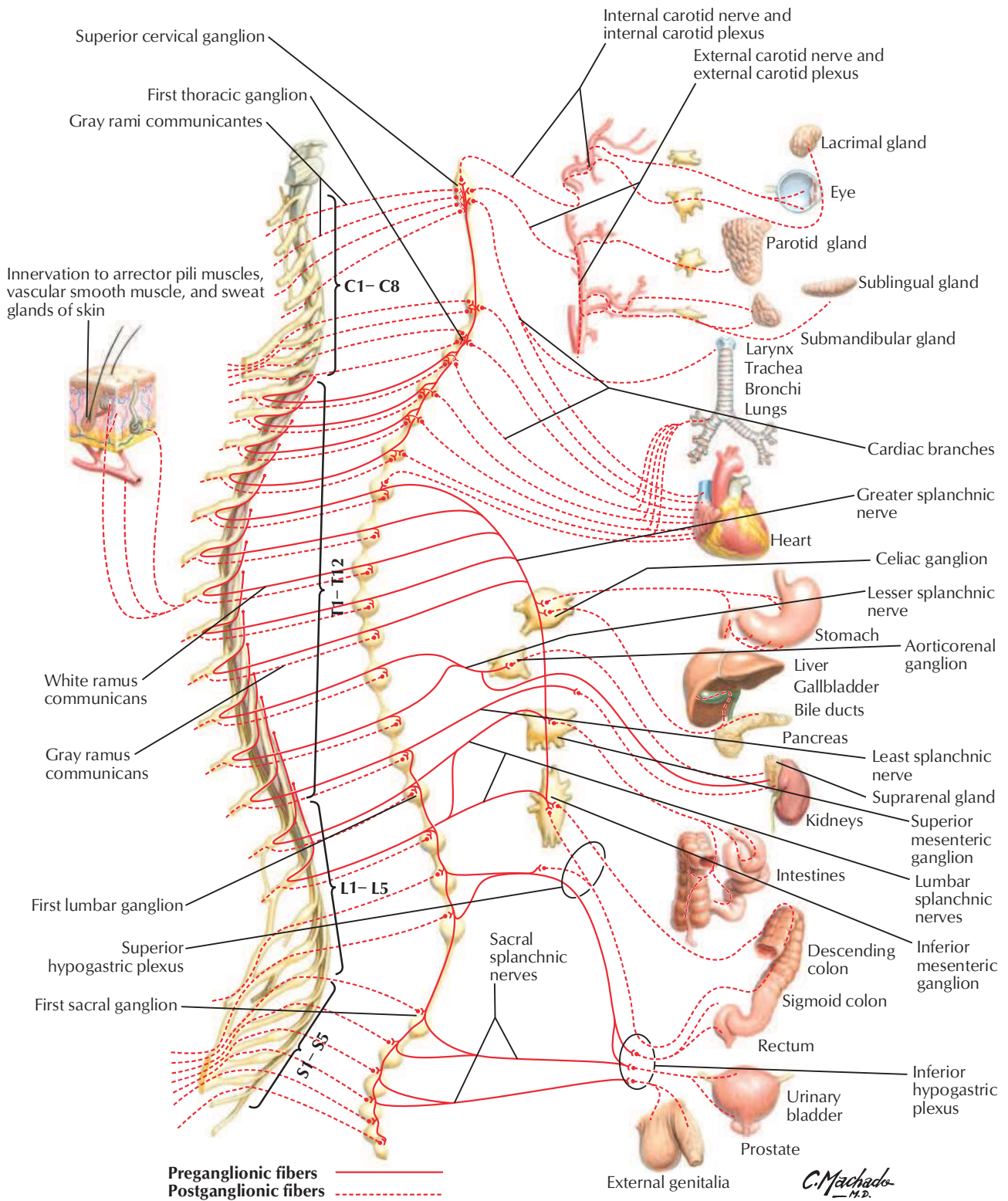
Levels of principal dermatomes

- C5** Level of clavicles
- C5, 6** Lateral sides of upper limbs
- C8, T1** Medial sides of upper limbs
- C6** Digit I (thumb)
- C6, 7, 8** Hand
- C8** Digits IV and V (ring and little fingers)
- T4** Level of nipples

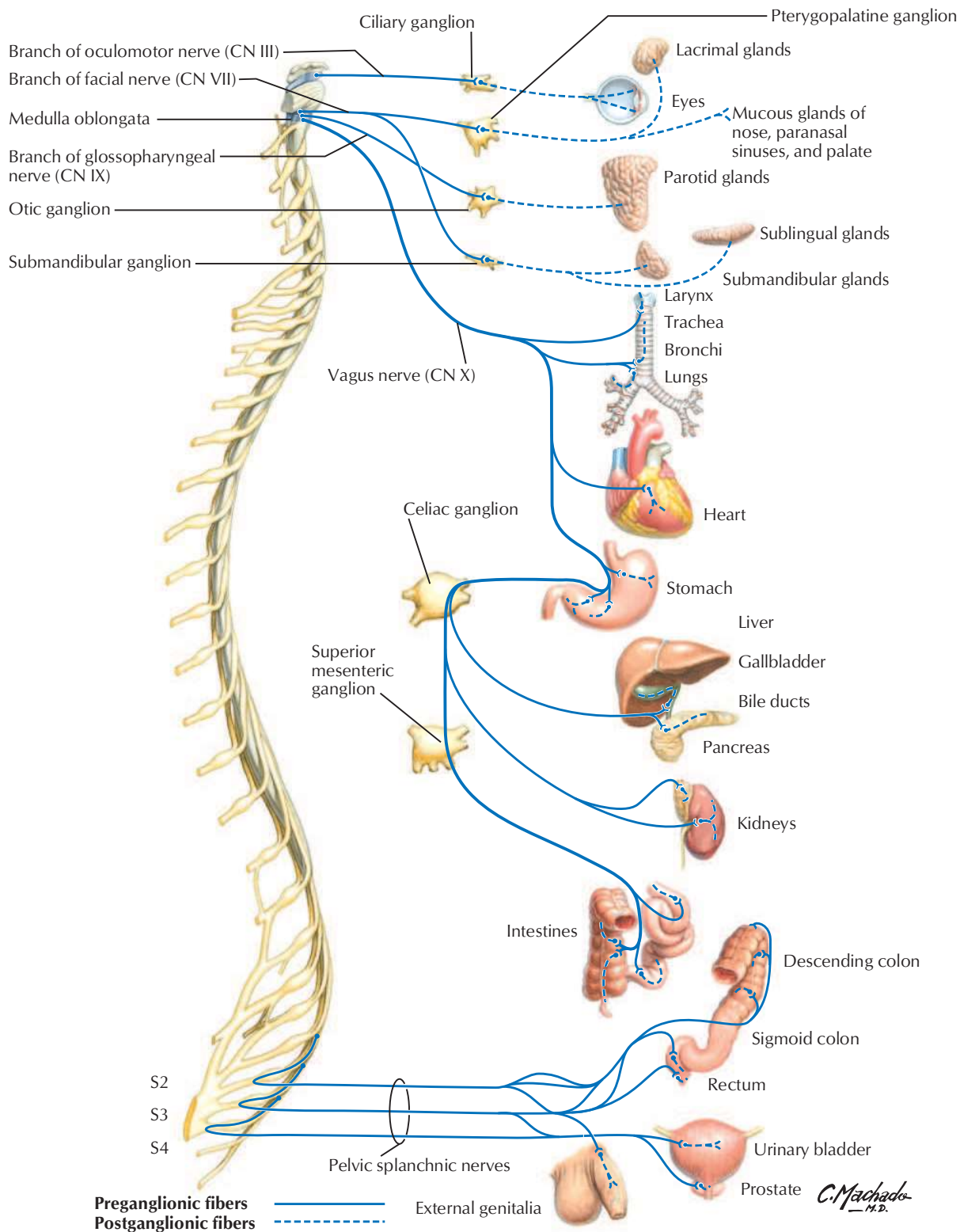
- T10** Level of umbilicus
- L1** Inguinal region
- L1, 2, 3, 4** Anterior and medial surfaces of lower limbs
- L4, 5, S1** Foot
- L4** Medial side digit I (great toe)
- L5, S1, 2** Lateral and posterior surfaces of lower limbs
- S1** Lateral margin of foot and digit V (little toe)
- S2, 3, 4** Perineum

Sympathetic Nervous System: Schema

See also [Plates 213, 320, 322](#)

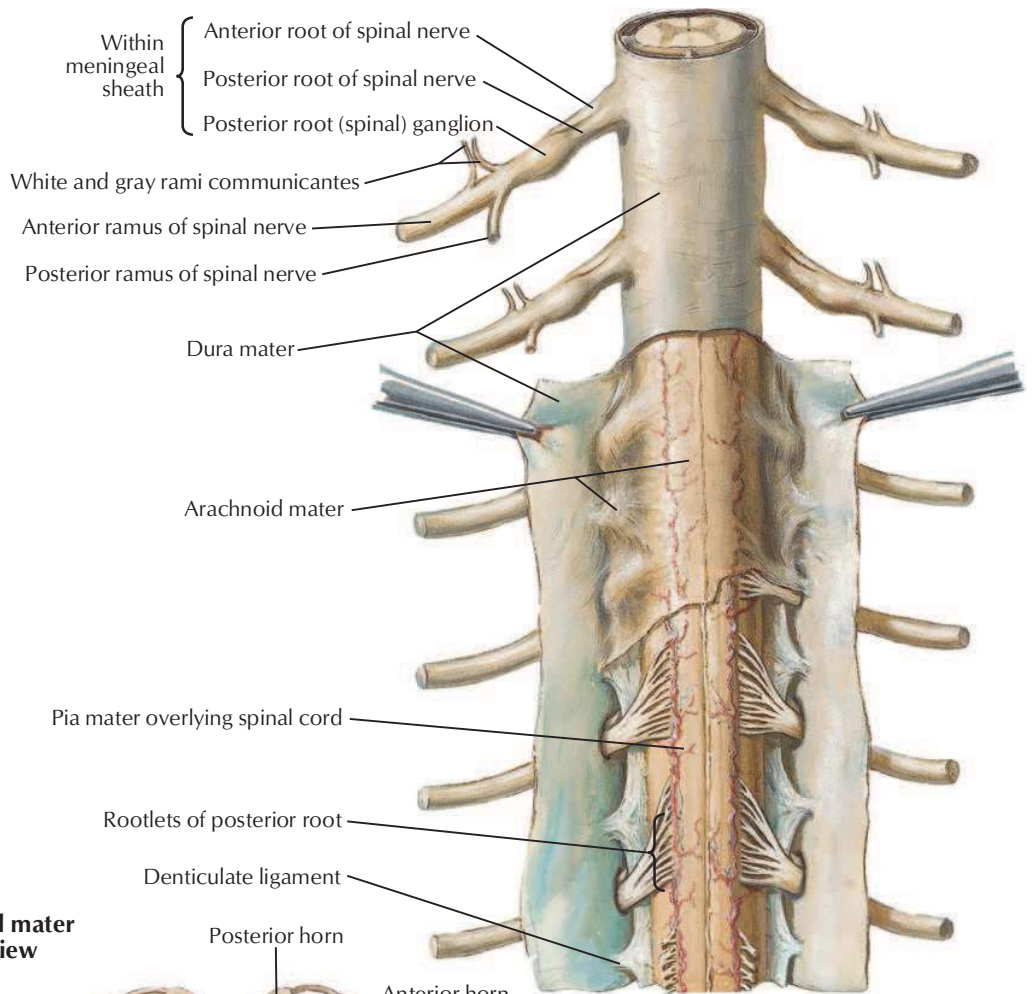


See also [Plates 306, 394](#)

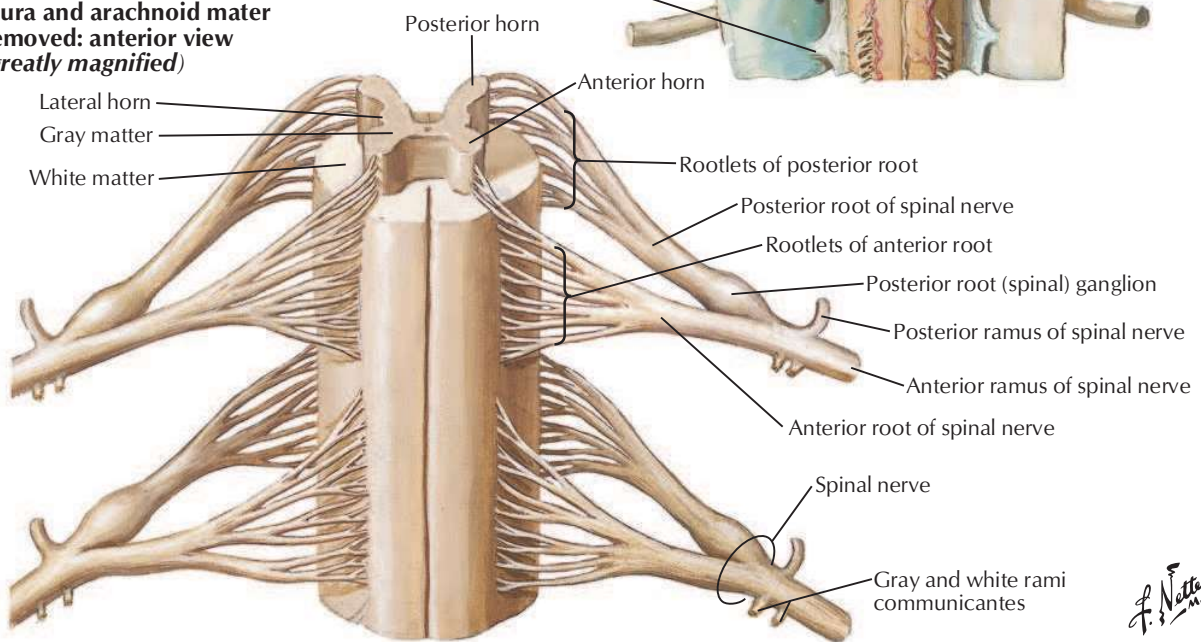


C. Machado
—M.D.

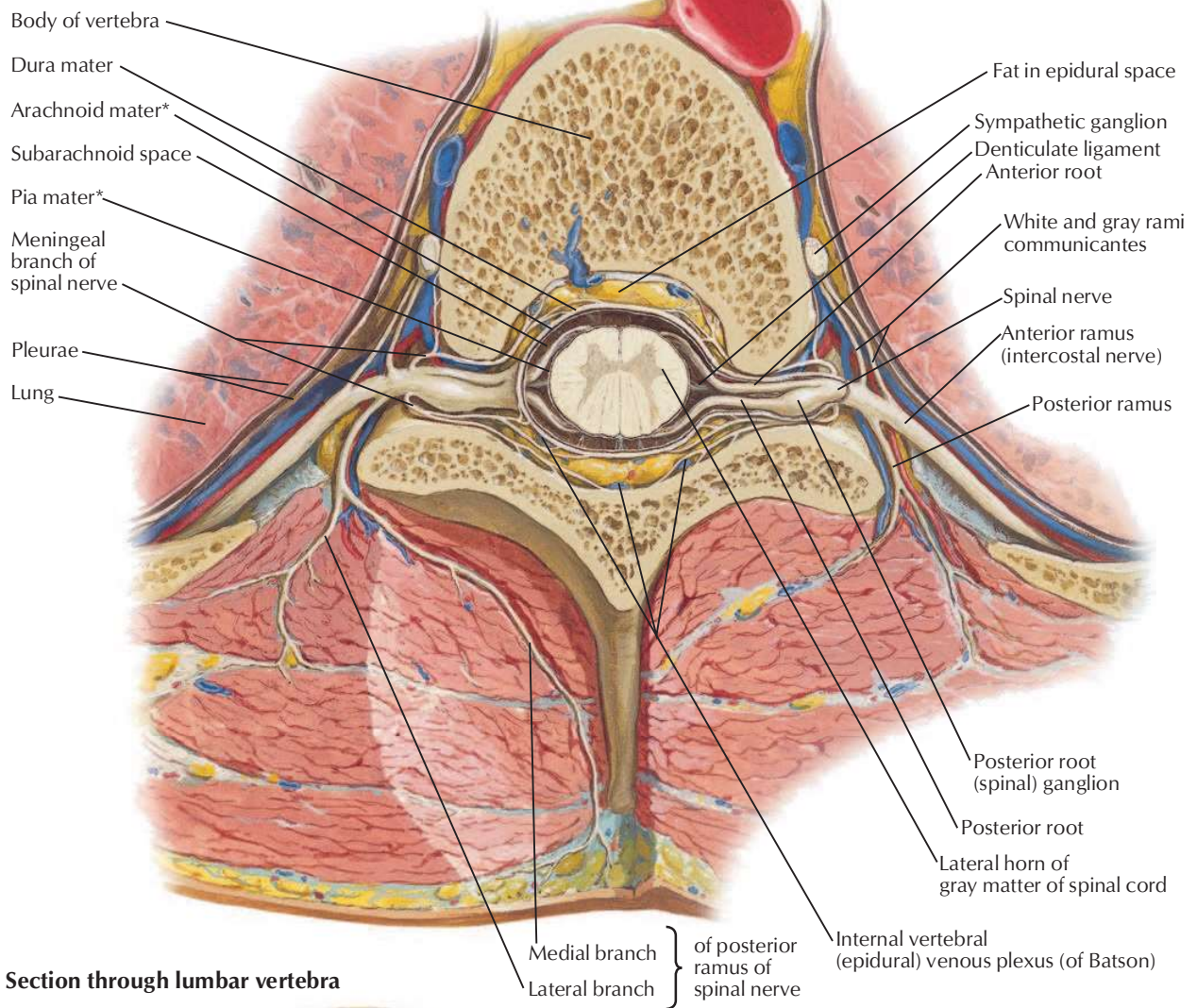
Posterior view



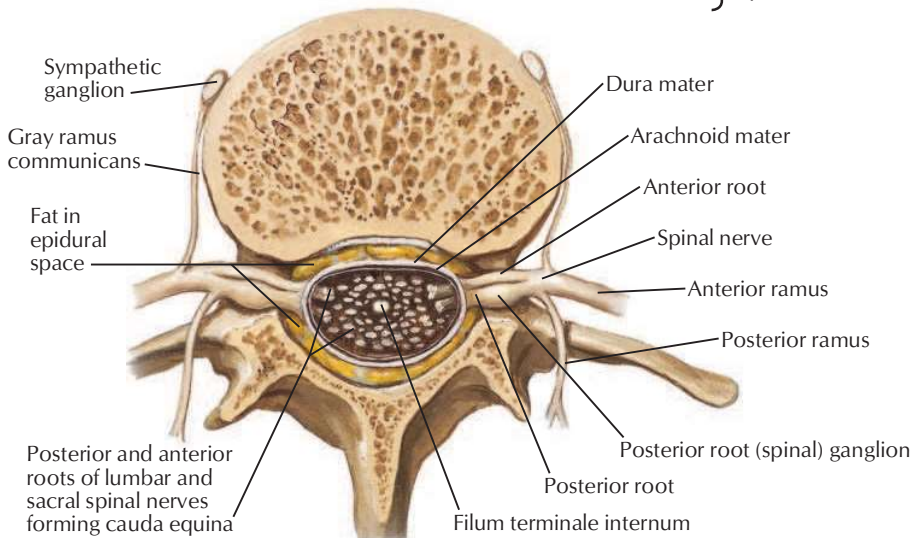
Dura and arachnoid mater removed: anterior view (greatly magnified)



Section through thorax



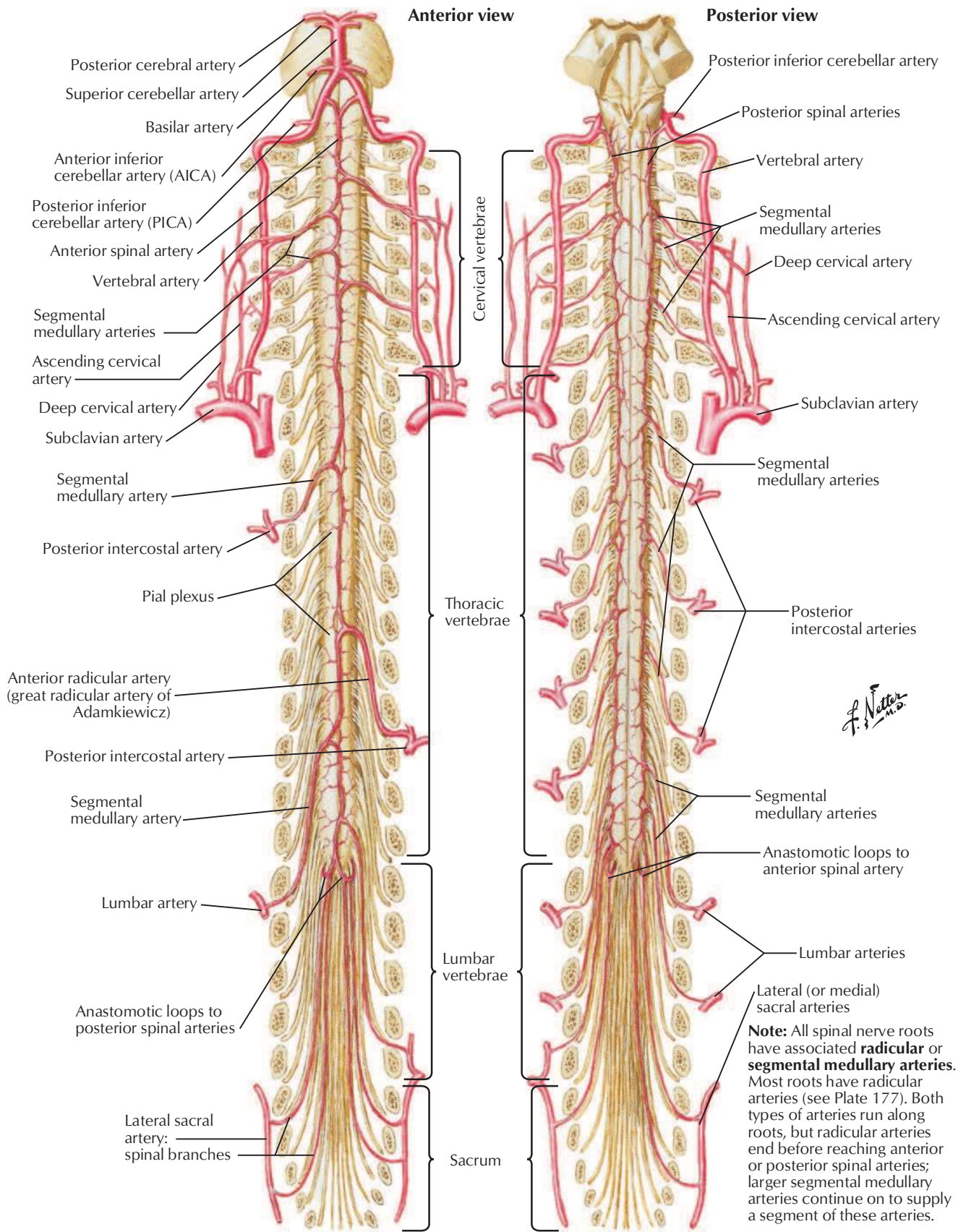
Section through lumbar vertebra

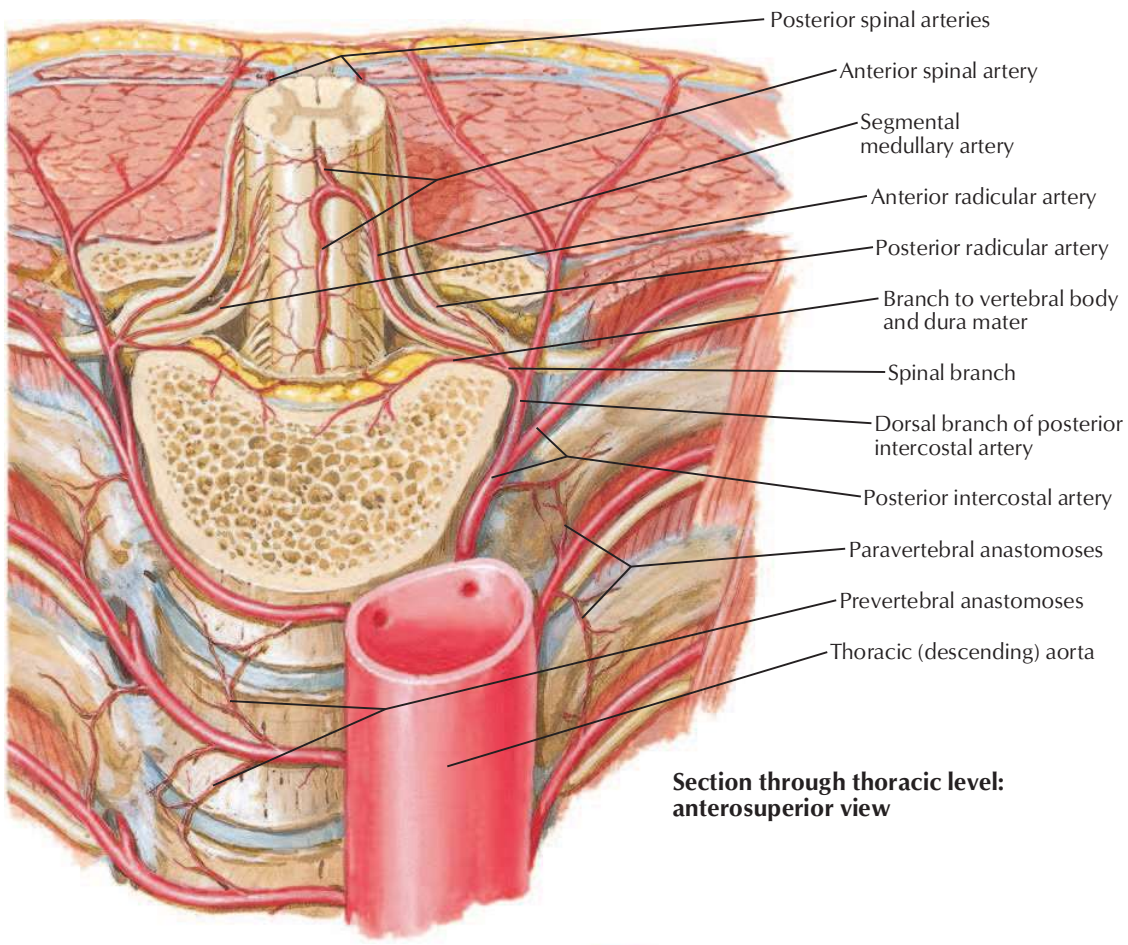


F. Netter M.D.

*Leptomeninges

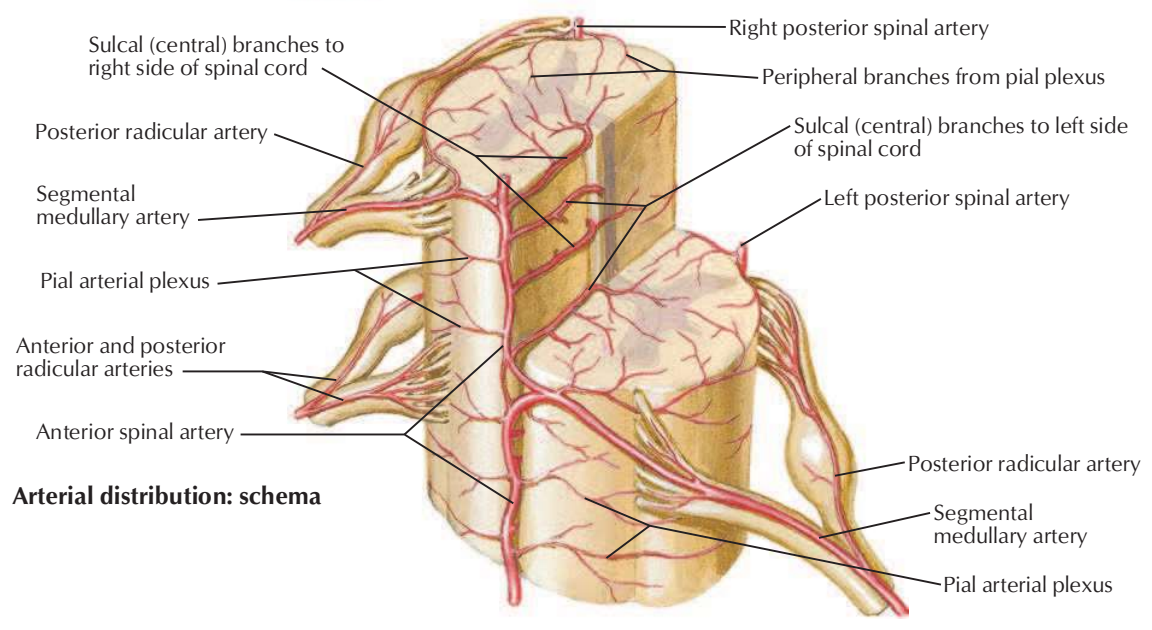
Arteries of Spinal Cord: Schema



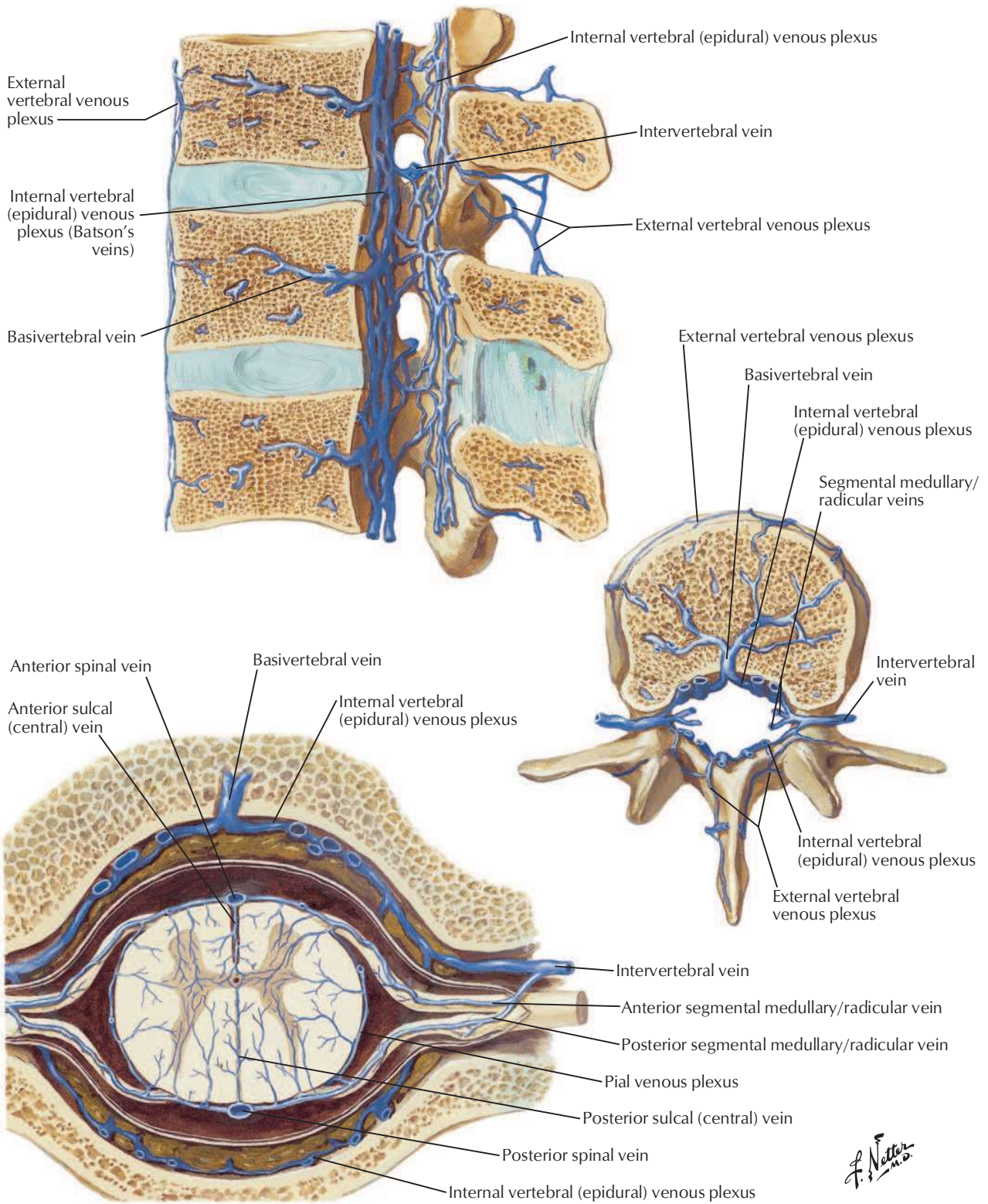


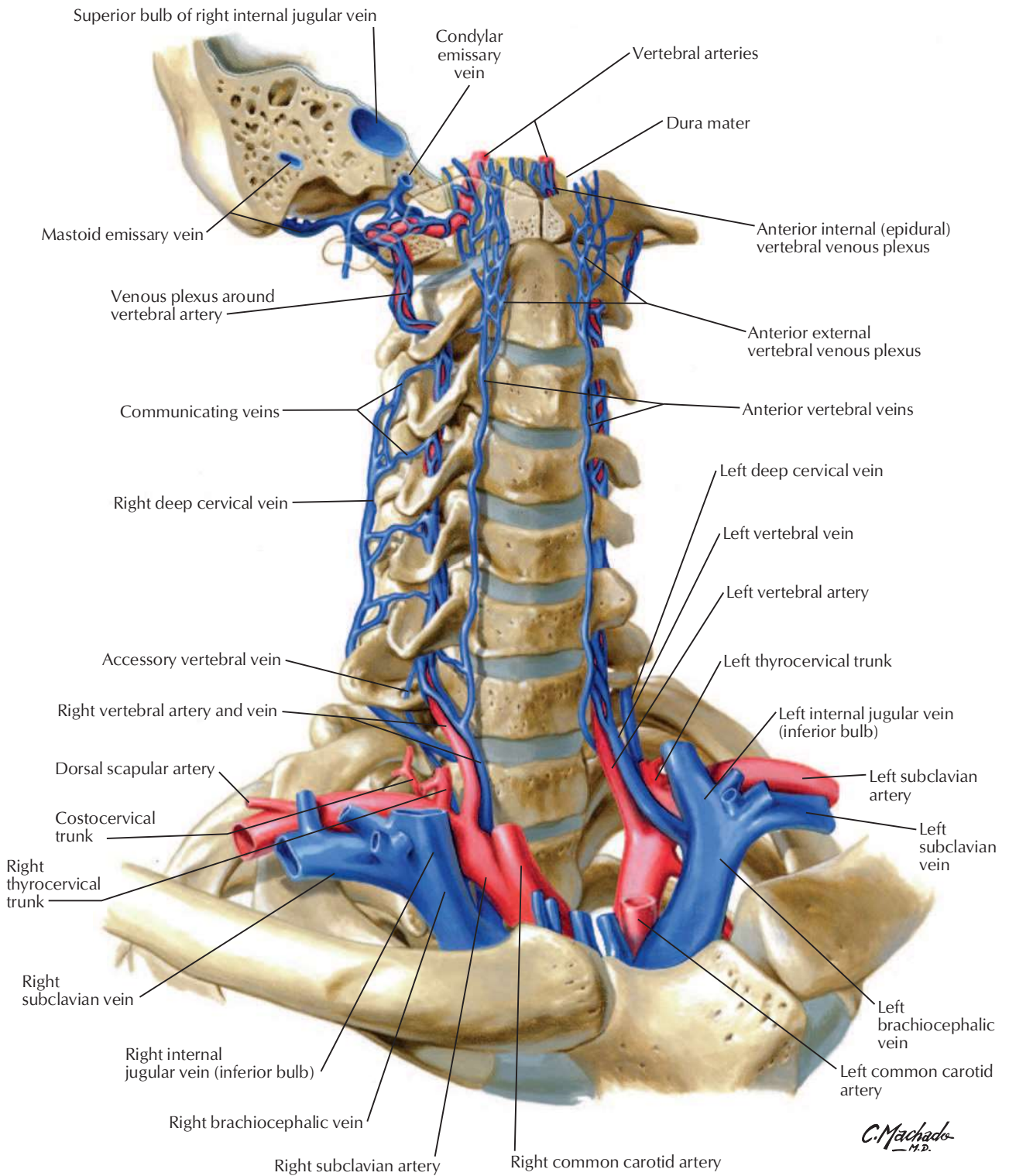
Section through thoracic level: anterosuperior view

F. Netter M.D.



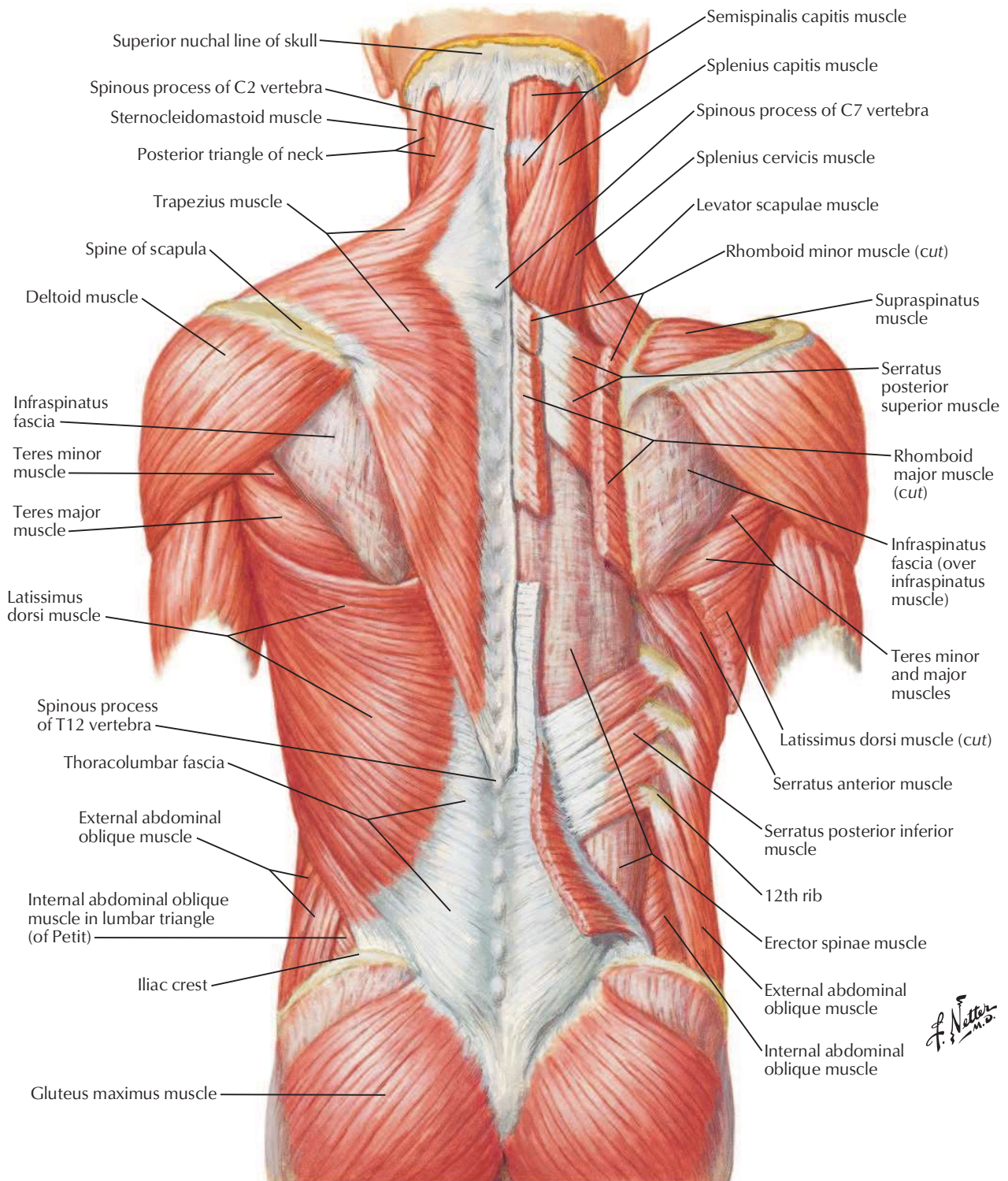
Arterial distribution: schema

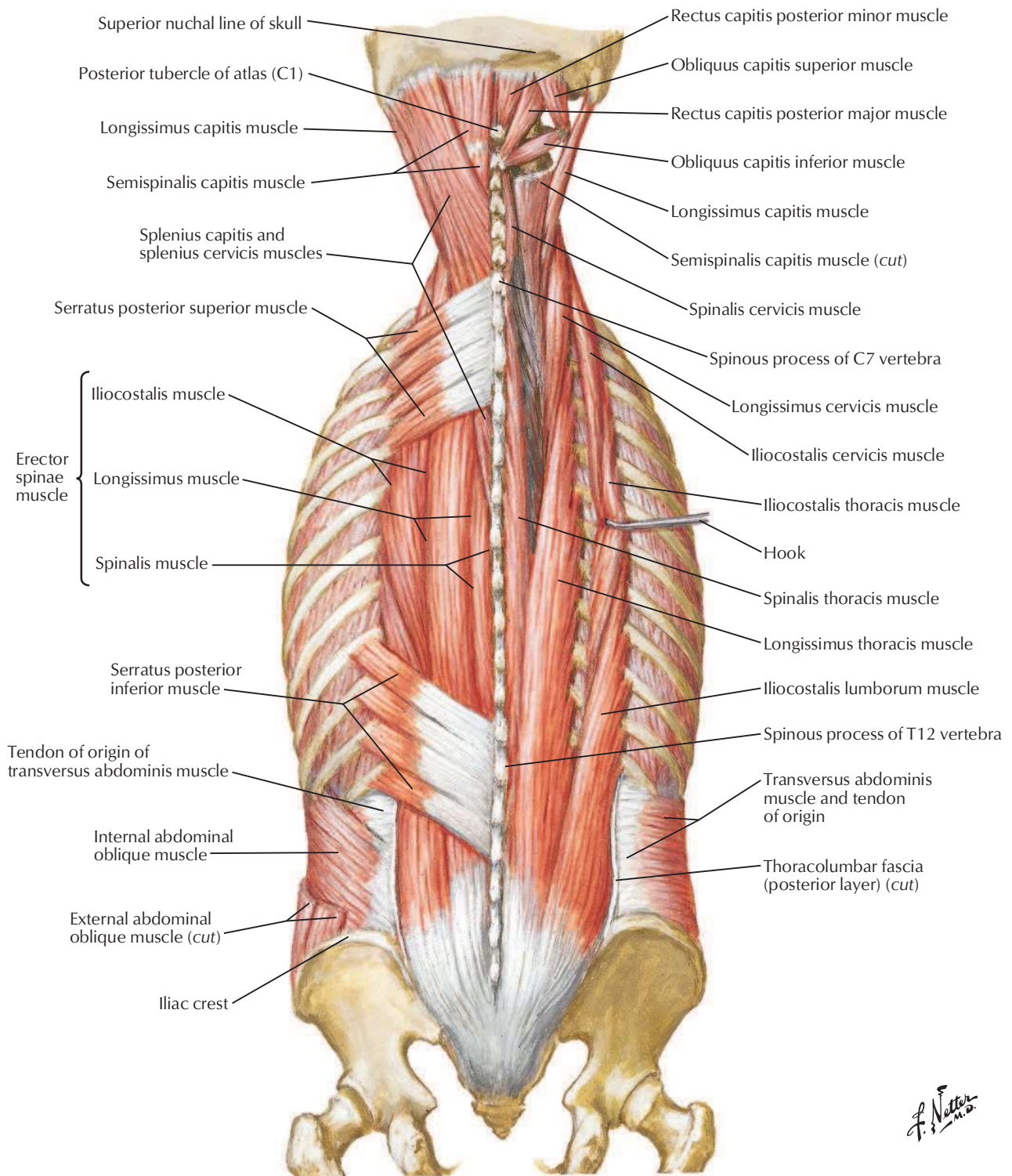




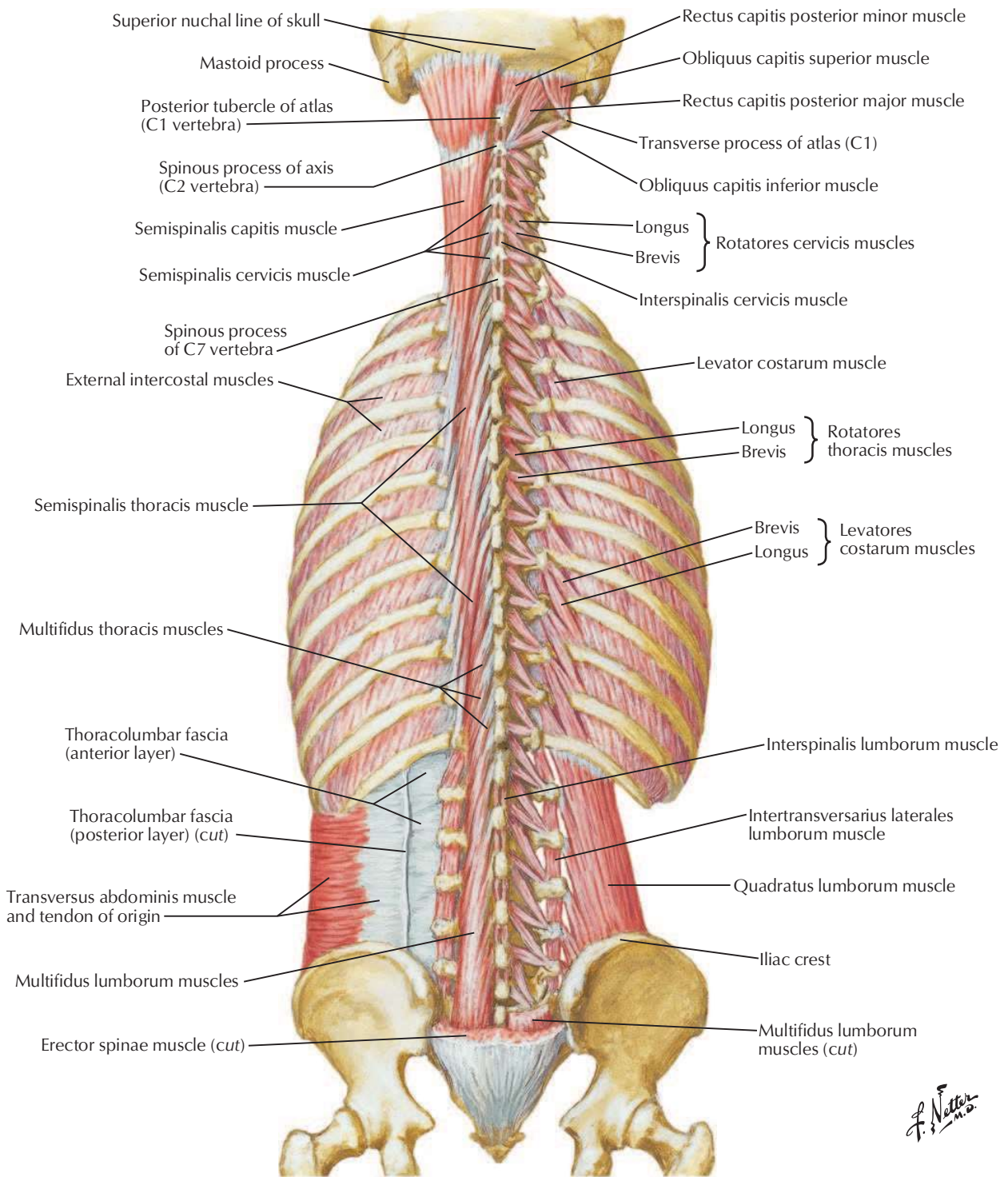
Muscles of Back: Superficial Layer

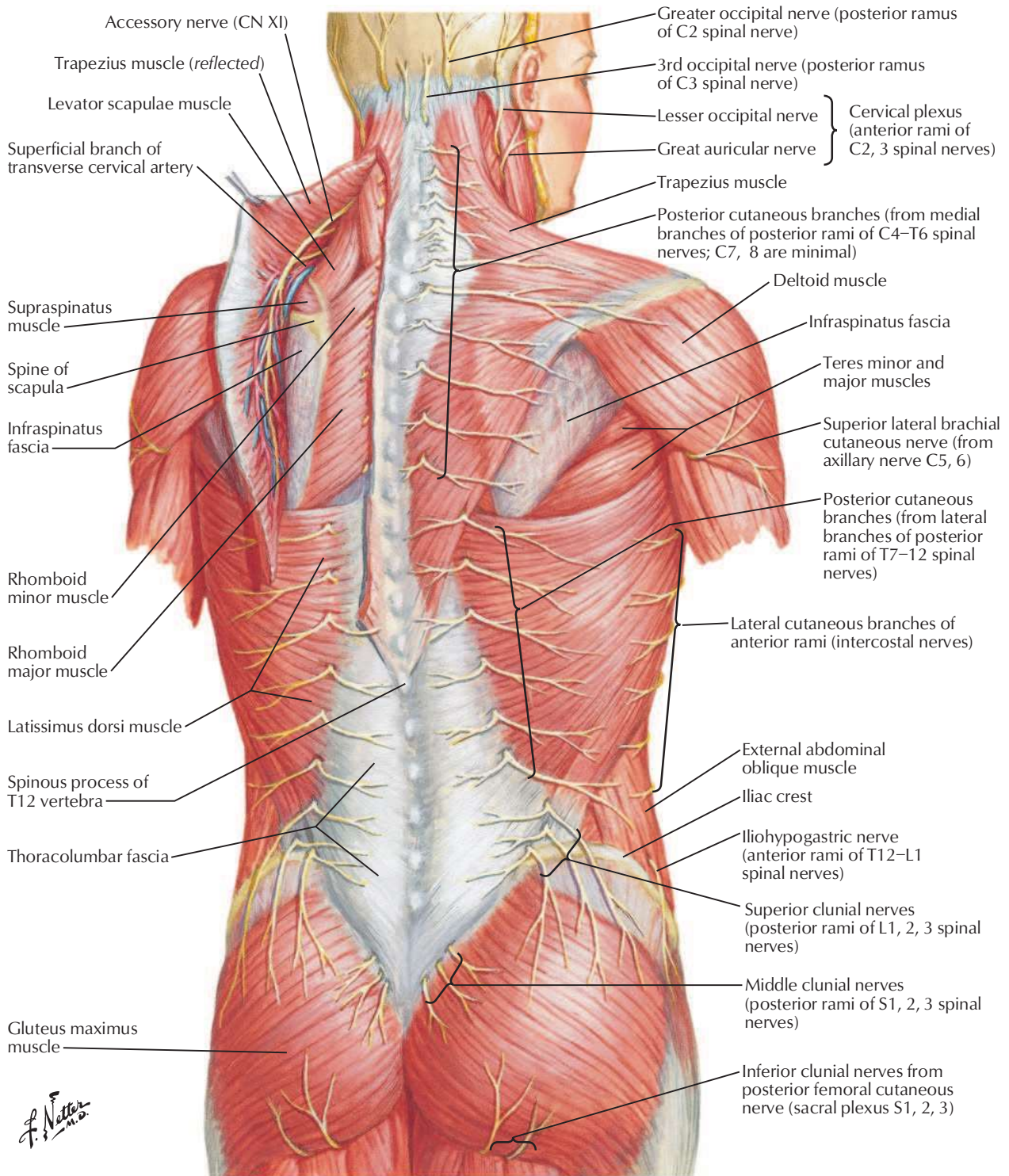
See also **Plates 36, 257**





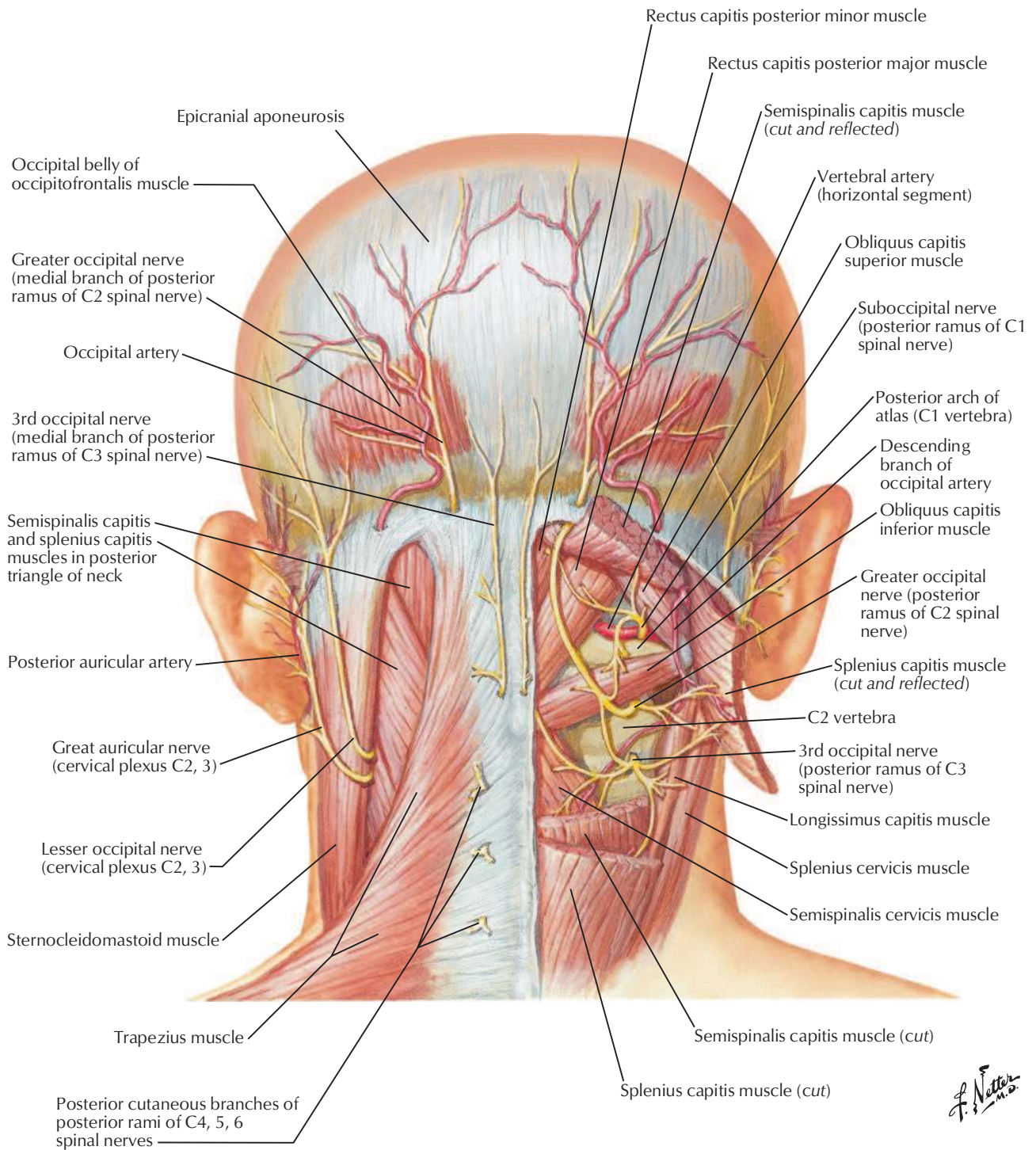
Muscles of Back: Deep Layer

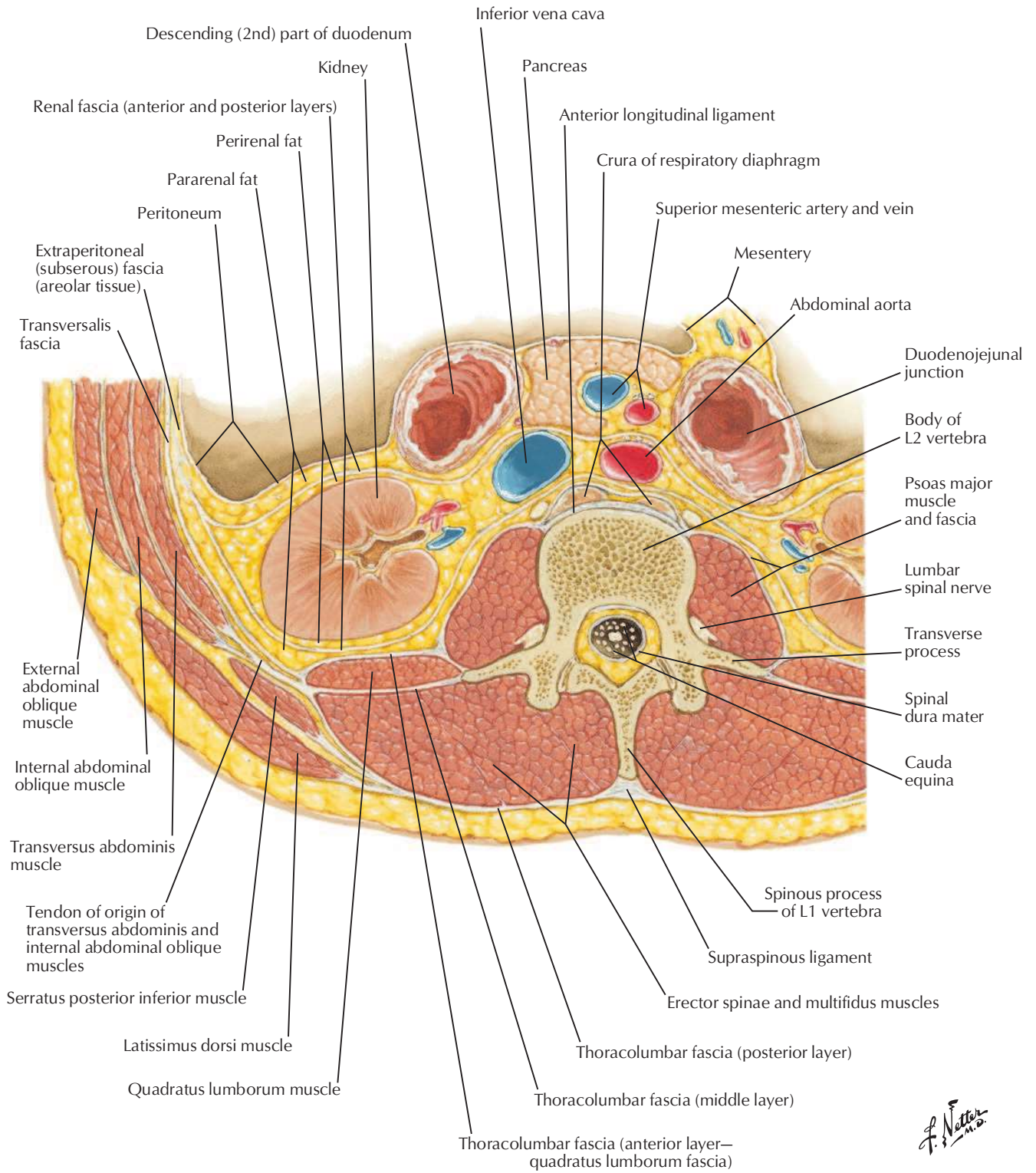




Suboccipital Triangle

See also **Plates 36, 39**

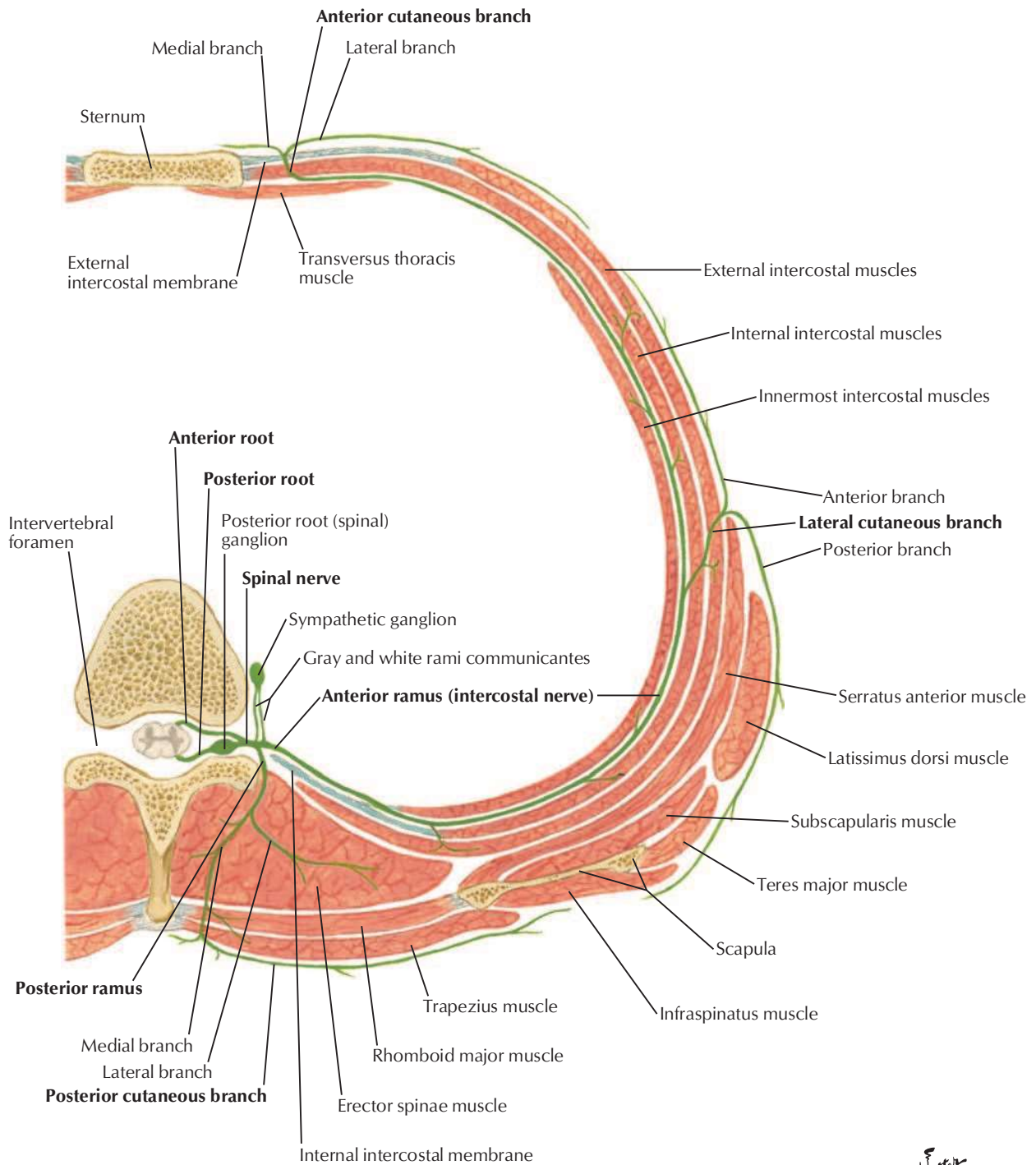








F. Netter M.D.

Typical Thoracic Spinal Nerve: Cross Section

See also [Plate 261](#)



Note: In lower thoracic region, lateral branch of posterior ramus is longer, motor, and cutaneous; medial branch is shorter and motor only.

ANATOMIC STRUCTURES	CLINICAL IMPORTANCE	PLATE NUMBERS
 SKELETAL SYSTEM		
Spinous processes	Palpable landmarks used to assess spinal curvatures and determine location of spinal cord for procedures such as lumbar puncture and injection of spinal anesthesia	161, 180
C7 spinous process	Most prominent spinous process (vertebra prominens); often used to begin counting vertebrae	161, 163
Intervertebral disc	Age-related changes may produce herniation of nucleus pulposus, causing back pain; occurs most commonly in lower lumbar regions of vertebral column	164, 170
Lamina	Surgically removed in laminectomy to gain access to vertebral canal and spinal cord	164
Intervertebral foramen	May become narrowed by age-related changes (e.g., osteophyte formation) or changes in intervertebral disc height, producing compression of its contents	164, 167, 168
Sacral hiatus	Provides access to epidural space to administer caudal epidural anesthesia	166
5th lumbar vertebra	Spondylolysis is clinical condition in which vertebral body separates from the part of its vertebral arch bearing inferior articulating process; if this occurs bilaterally, L5 body and transverse process may slide forward over sacrum, giving rise to spondylolisthesis	167
L5/S1 vertebrae	Most common level of intervertebral disc herniation	167, 170
Vertebral foramen	May become narrowed by arthritic changes in lumbar vertebrae, resulting in spinal stenosis; can lead to back pain, sciatica, numbness or tingling, and weakness in lower limbs	163, 164
 MUSCULAR SYSTEM		
Trapezius muscle	Responsible for holding scapula against thoracic wall against gravity; drooping of shoulder indicates weakness of or injury to accessory nerve	180
Intrinsic back muscles	Microscopic stretching or tearing of muscle fibers produces back strain, a common cause of low back pain	181, 182
 NERVOUS SYSTEM		
Conus medullaris	Indicates inferior limit of spinal cord; it is necessary to locate this point in procedures such as lumbar puncture	169
Cauda equina	Lumbar and sacral nerve roots may be anesthetized with anesthesia injected into subarachnoid space (spinal block)	169, 170
Spinal meninges	Access to epidural and subarachnoid spaces is necessary for clinical procedures such as epidural anesthesia and lumbar puncture	165, 175
 CARDIOVASCULAR SYSTEM		
Segmental medullary arteries	Narrowing or damage to these arteries caused by atherosclerosis, vertebral fractures, or vertebral dislocations may cause ischemia of spinal cord	176
Vertebral venous plexuses	Venous conduits for metastasis of cancer cells to spine, lungs, and brain	178

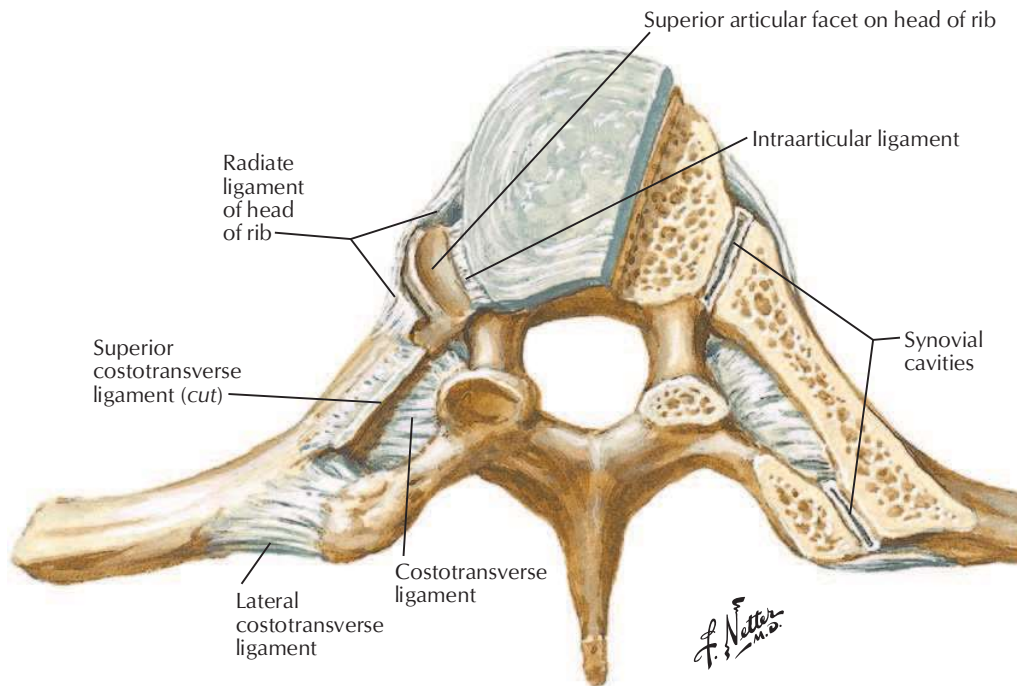
*Selections were based largely on clinical data as well as commonly covered clinical correlations in gross anatomy courses.

MUSCLE	MUSCLE GROUP	PROXIMAL ATTACHMENT (ORIGIN)	DISTAL ATTACHMENT (INSERTION)	INNERVATION	BLOOD SUPPLY	MAIN ACTIONS
Erector spinae	Sacrospinalis	Posterior sacrum, iliac crest, sacrospinous ligament, supraspinous ligament, spinous processes of lower lumbar vertebrae and sacrum	<i>Iliocostalis</i> : angles of lower ribs, cervical transverse processes <i>Longissimus</i> : between tubercles and angles of ribs, transverse processes of thoracic and cervical vertebrae, mastoid process <i>Spinalis</i> : spinous processes of upper thoracic and midcervical vertebrae	Posterior rami of each region	<i>Cervical portions</i> : occipital, deep cervical, and vertebral arteries <i>Thoracic portions</i> : dorsal branches of posterior intercostal, subcostal, and lumbar arteries <i>Sacral portions</i> : dorsal branches of lateral sacral arteries	Extends and laterally bends vertebral column and head
Interspinales (cervical, thoracic, lumbar)	Segmental	Spinous process	Adjacent spinous process	Posterior rami of spinal nerves	<i>Cervical portions</i> : occipital, deep cervical, and vertebral arteries <i>Thoracic portions</i> : dorsal branches of posterior intercostal arteries <i>Lumbar portions</i> : dorsal branches of lumbar arteries	Aid in extension of vertebral column
Intertransversarii (cervical, thoracic, lumbar)	Segmental	Extend between adjacent transverse processes of vertebrae	Extend between adjacent transverse processes of vertebrae	Posterior rami of spinal nerves	<i>Cervical portions</i> : occipital, deep cervical, and vertebral arteries <i>Thoracic portions</i> : dorsal branches of posterior intercostal, subcostal, and lumbar arteries <i>Lumbar portions</i> : dorsal branches of lateral lumbar arteries	Assist in lateral flexion of vertebral column
Latissimus dorsi	Superficial back	Spinous processes of T7–L5, thoracolumbar fascia, iliac crest, and last three ribs	Intertubercular sulcus of humerus	Thoracodorsal nerve	Thoracodorsal artery, dorsal perforating branches of 9th, 10th, and 11th posterior intercostal, subcostal, and first three lumbar arteries	Extends, adducts, and medially rotates humerus
Levator scapulae	Superficial back	Posterior tubercles of transverse processes of C1–C4	Medial border of scapula from superior angle to spine	Anterior rami of C3–C4 and dorsal scapular nerve	Dorsal scapular artery, transverse cervical artery, ascending cervical artery	Elevates scapula medially, inferiorly rotates glenoid fossa
Multifidus	Transversospinales	Sacrum, ilium, transverse processes of T1–T12, and articular processes of C4–C7	Spinous processes of vertebrae above, spanning two to four segments	Posterior rami of each region	<i>Cervical portions</i> : occipital, deep cervical, and vertebral arteries <i>Thoracic portions</i> : dorsal branches of posterior intercostal, subcostal, and lumbar arteries <i>Sacral portions</i> : dorsal branches of lateral sacral arteries	Stabilizes spine
Obliquus capitis inferior	Suboccipital	Spine of axis	Transverse process of atlas	Suboccipital nerve	Vertebral artery, descending branch of occipital artery	Rotates atlas to turn face to same side
Obliquus capitis superior	Suboccipital	Transverse process of atlas	Occipital bone	Suboccipital nerve	Vertebral artery, descending branch of occipital artery	Extends and bends head laterally
Rectus capitis posterior major	Suboccipital	Spine of axis	Inferior nuchal line	Suboccipital nerve	Vertebral artery, descending branch of occipital artery	Extends and rotates head to same side

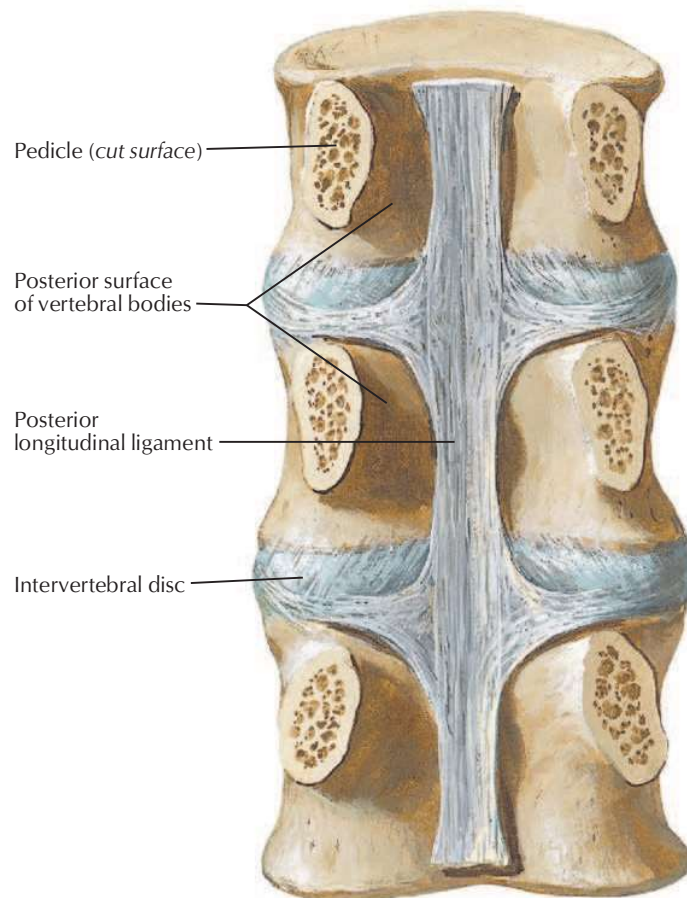
Variations in spinal nerve contributions to the innervation of muscles, their arterial supply, their attachments, and their actions are common themes in human anatomy. Therefore, expect differences between texts and realize that anatomical variation is normal.

MUSCLE	MUSCLE GROUP	PROXIMAL ATTACHMENT (ORIGIN)	DISTAL ATTACHMENT (INSERTION)	INNERVATION	BLOOD SUPPLY	MAIN ACTIONS
Rectus capitis posterior minor	Suboccipital	Tubercle of posterior arch of atlas	Median inferior nuchal line	Suboccipital nerve	Vertebral artery, descending branch of occipital artery	Extends head
Rhomboid major	Superficial back	Spinous processes of T2–T5 vertebrae	Medial border of scapula below base of spine of scapula	Dorsal scapular nerve	Dorsal scapular <i>OR</i> deep branch of transverse cervical artery, dorsal perforating branches of upper five or six posterior intercostal arteries	Fixes scapula to thoracic wall and retracts and rotates it to depress glenoid cavity
Rhomboid minor	Superficial back	Nuchal ligament, spines of C7 and T1 vertebrae	Medial border of scapula at spine of scapula	Dorsal scapular nerve	Dorsal scapular <i>OR</i> deep branch of transverse cervical artery, dorsal perforating branches of upper five or six posterior intercostal arteries	Fixes scapula to thoracic wall and retracts and rotates it to depress glenoid cavity
Rotatores	Transversospinales	Transverse processes of cervical, thoracic, and lumbar regions	Lamina and transverse process of spine above, spanning one or two segments	Posterior rami of spinal nerves	Dorsal branches of segmental arteries	Stabilizes, extends, and rotates spine
Semispinalis	Transversospinales	Transverse processes of C4–T12	Spinous processes of cervical and thoracic regions	Posterior rami of spinal nerves	<i>Cervical portions:</i> occipital, deep cervical, and vertebral arteries <i>Thoracic portions:</i> dorsal branches of posterior intercostal arteries	Extends head, neck, and thorax and rotates them to opposite side
Serratus posterior inferior	Intermediate back	Spinous processes of T11–L2	Inferior aspect of ribs 9–12	Anterior rami of lower thoracic nerves	Posterior intercostal arteries	Depresses ribs
Serratus posterior superior	Intermediate back	Nuchal ligament, spinous processes of C7–T3	Superior aspect of ribs 2–5	Anterior rami of upper thoracic nerves	Posterior intercostal arteries	Elevates ribs
Splenius capitis	Spinotransverse	Nuchal ligament, spinous processes of C7–T4	Mastoid process of temporal bone, lateral third of superior nuchal line	Posterior rami of middle cervical nerves	Descending branch of occipital artery, deep cervical artery	<i>Bilaterally:</i> extends head <i>Unilaterally:</i> laterally bends (flexes) and rotates face to same side
Splenius cervicis	Spinotransverse	Spinous processes of T3–T6	Transverse processes (C1–C3)	Posterior rami of lower cervical nerves	Descending branch of occipital artery, deep cervical artery	<i>Bilaterally:</i> extends neck <i>Unilaterally:</i> laterally bends (flexes) and rotates neck toward same side
Trapezius	Superficial back	Superior nuchal line, external occipital protuberance, nuchal ligament, spinous processes of C7–T12	Lateral third of clavicle, acromion, spine of scapula	Accessory nerve (CN XI)	Transverse cervical artery, dorsal perforating branches of posterior intercostal arteries	Elevates, retracts, and rotates scapula; lower fibers depress scapula

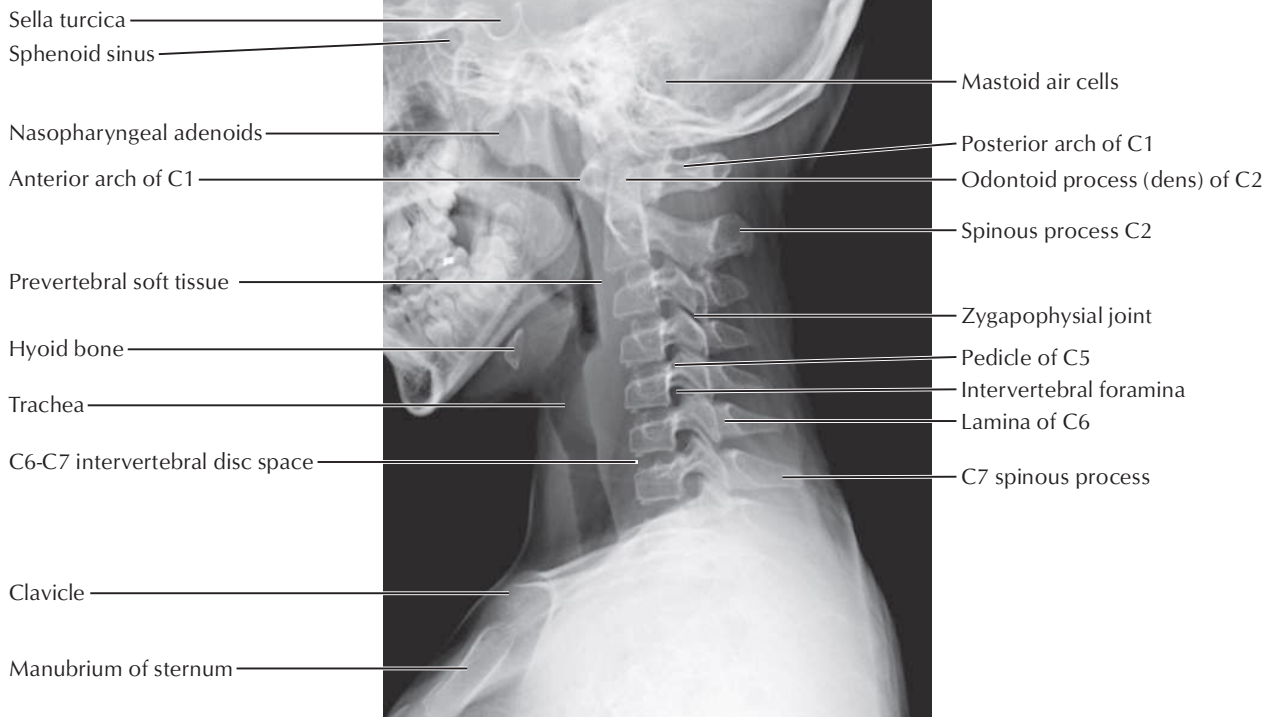
Thoracic vertebrae, transverse section: superior view



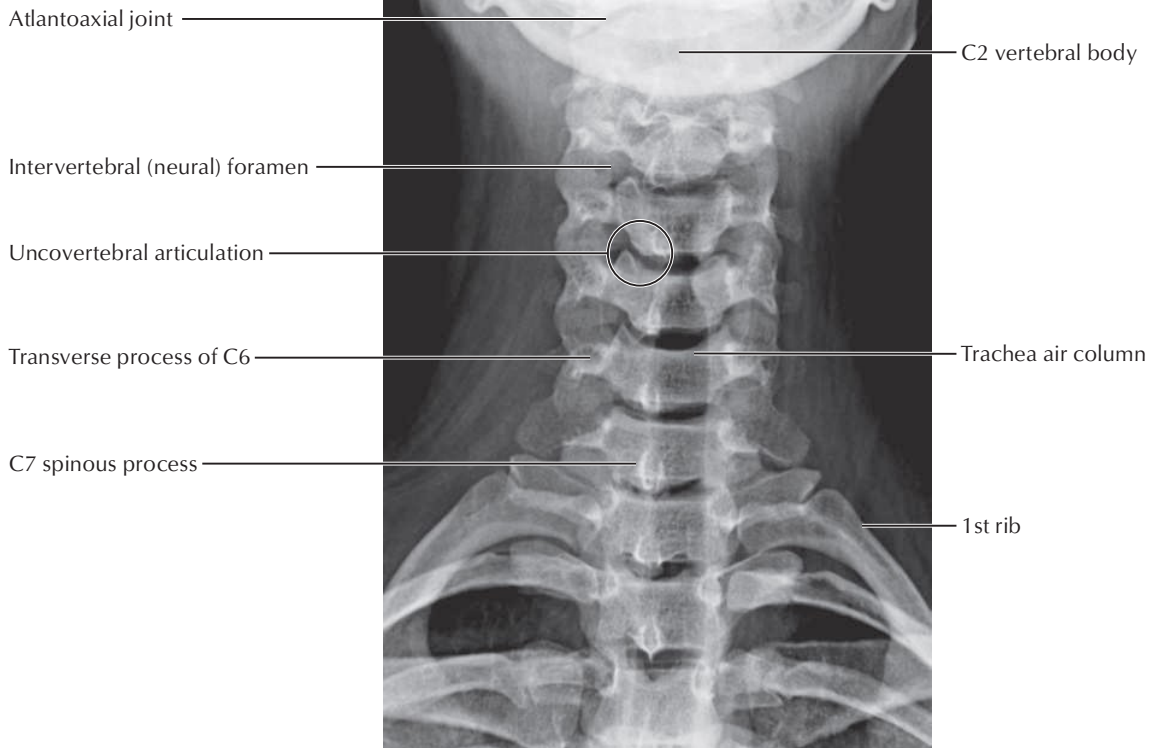
Lumbar anterior vertebral segments: posterior view (pedicles sectioned)



Lateral view

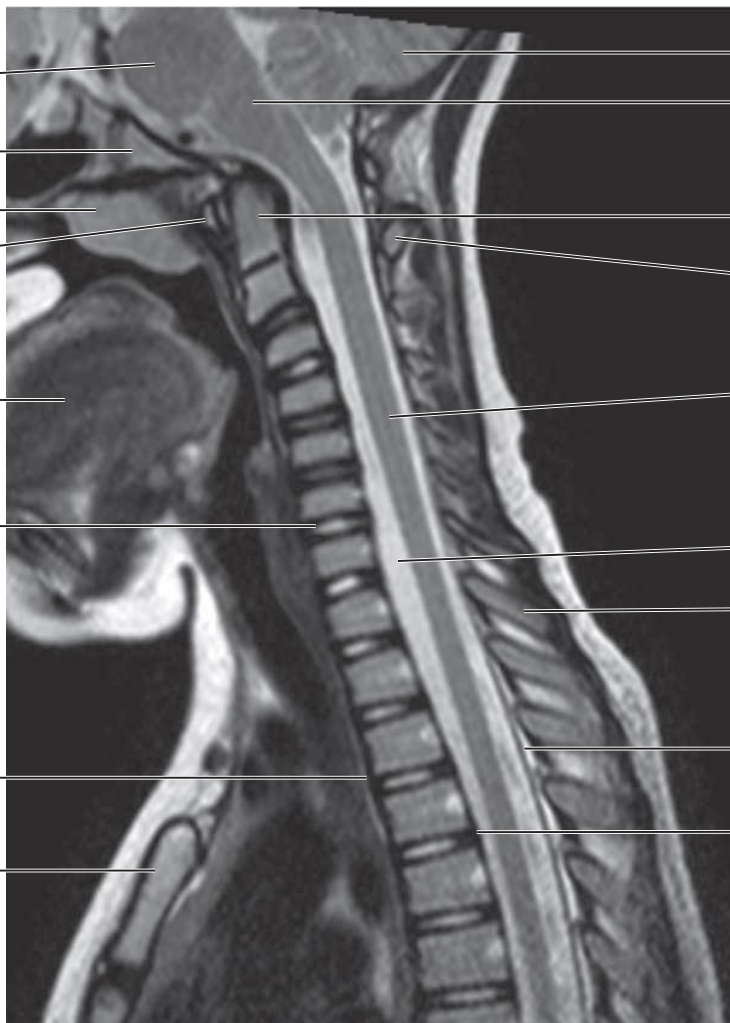


Anteroposterior view



Sagittal T2-weighted MRI of cervical spine, without contrast

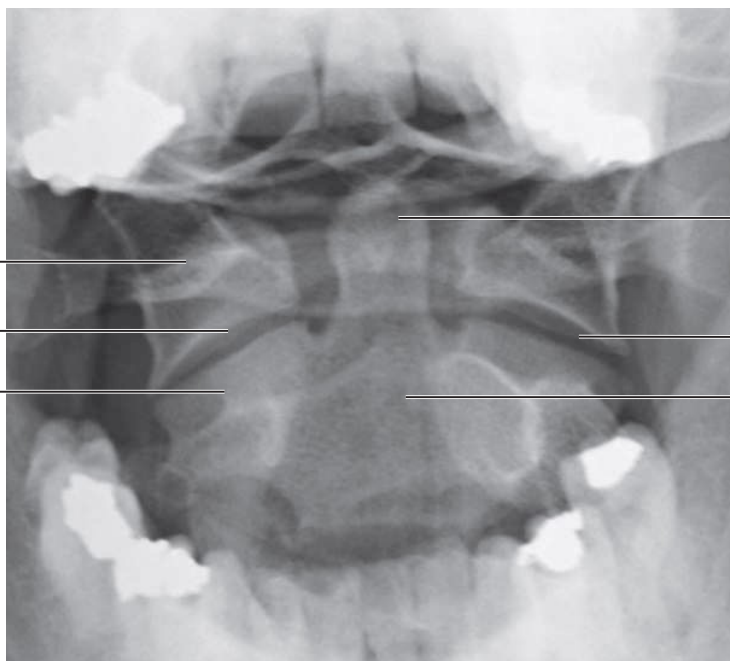
- Pons
- Clivus
- Nasopharyngeal adenoids
- Anterior arch of C1
- Tongue
- C6-C7 intervertebral disc
- Anterior longitudinal ligament
- Manubrium of sternum



- Cerebellum
- Medulla oblongata
- Odontoid process of C2 (dens)
- Posterior arch C1
- Cervical spinal cord
- Cerebral spinal fluid within the thecal sac
- Spinous process of C7
- Dura mater
- Posterior longitudinal ligament

Open-mouth radiograph of cervical spine

- Superior articular surface of the atlas
- Inferior articular surface of the atlas
- Superior articular facet of the axis



- Odontoid process C2 (dens)
- Atlantoaxial articulation
- Body of C2



Thoracolumbar Spine: Lateral Radiograph

Lateral radiograph of thoracolumbar spine

Air within the trachea

Level of carina

Diaphragm silhouette

T12 vertebra

Superior end plate of L3

Inferior end plate of L3

L4-L5 intervertebral disc space

Air within the esophagus

Posterior ribs of T9

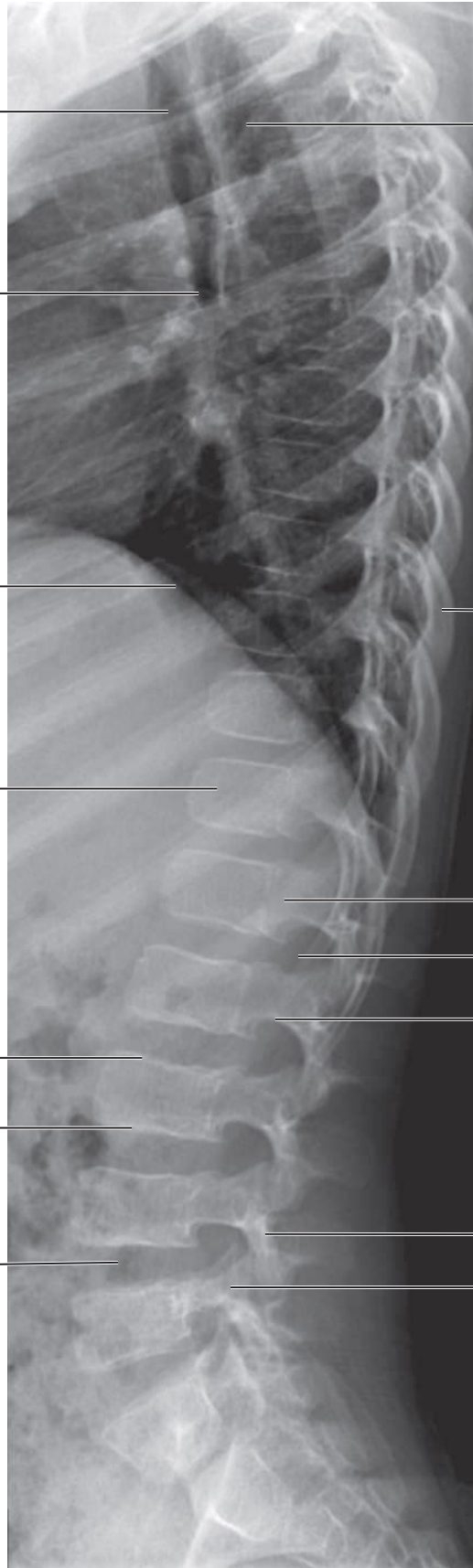
Pedicle of L1

Intervertebral foramina

Inferior vertebral notch of L2

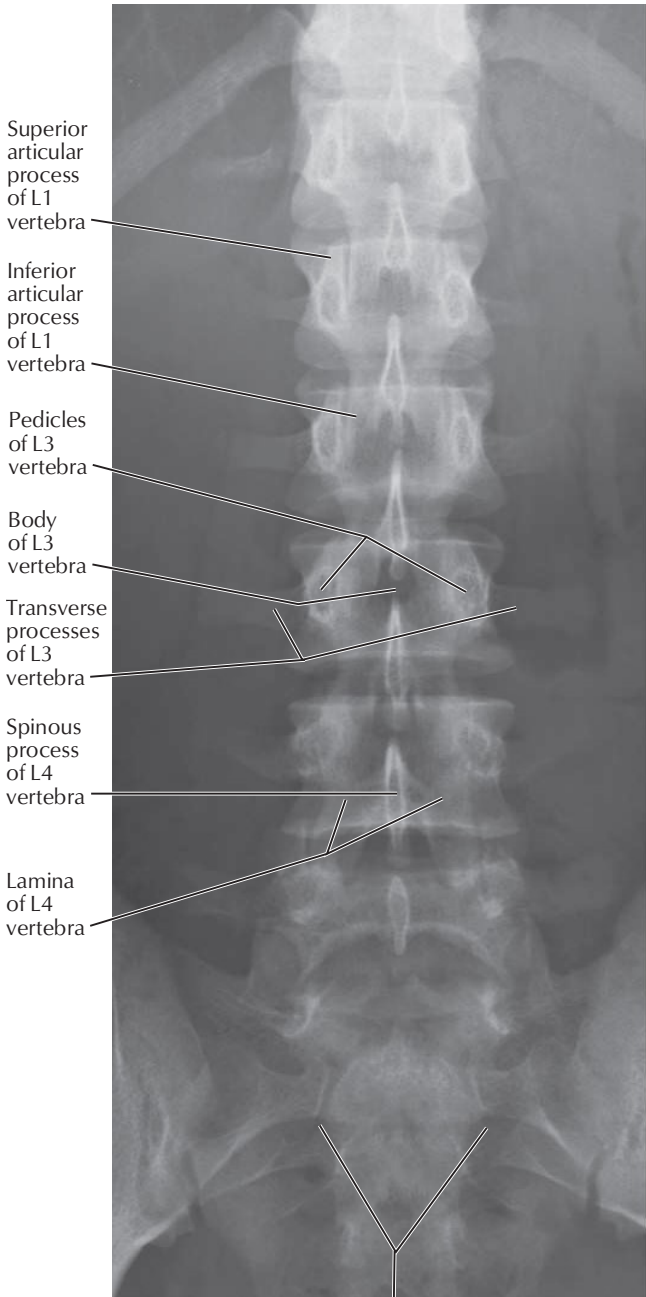
Inferior articular facet of L4

Superior articular facet of L5



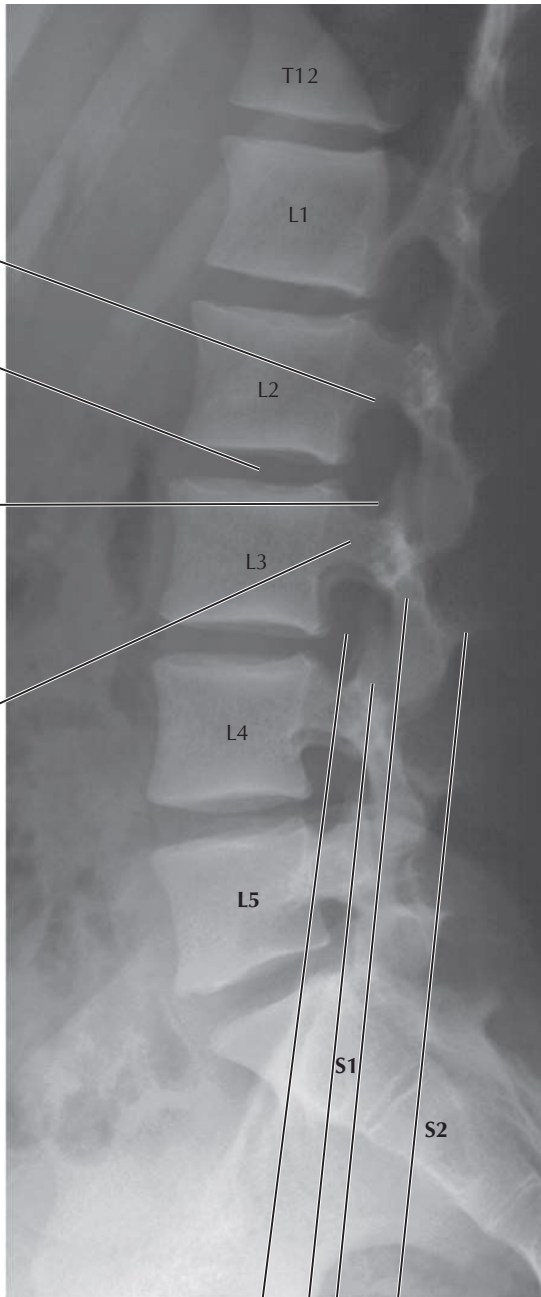
Radiographs of lumbar vertebrae

Anteroposterior radiograph



Sacral foramina

Lateral radiograph



Inferior vertebral notch of L2 vertebra

Inter-vertebral disc space

Superior vertebral notch of L3 vertebra

Pedicle of L3 vertebra

Intervertebral foramen

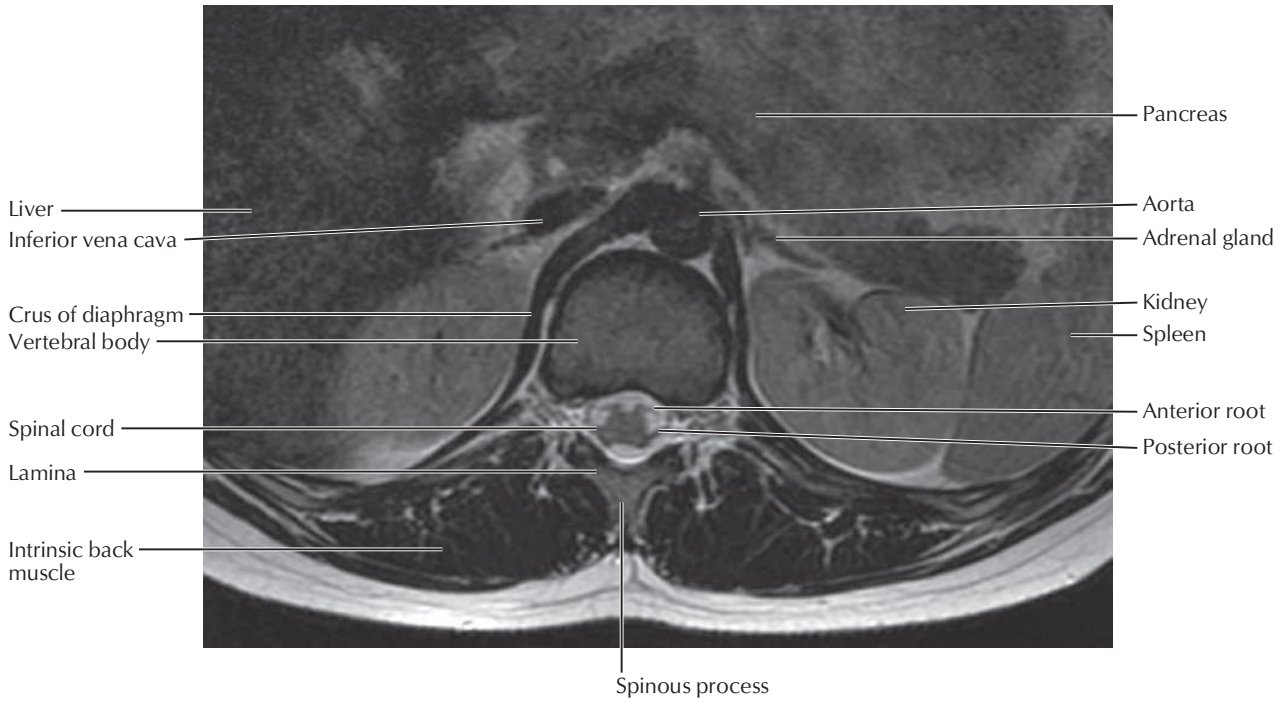
Superior articular process of L4 vertebra

Inferior articular process of L3 vertebra

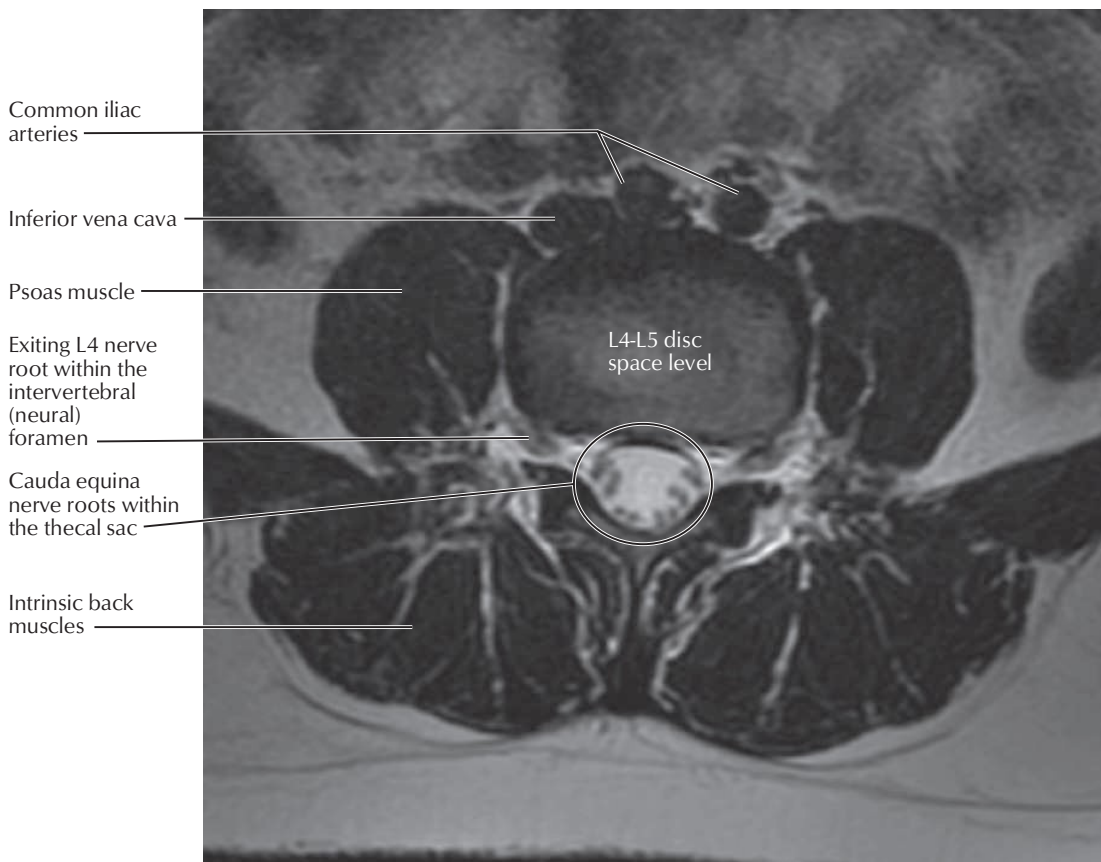
Spinous process of L3 vertebra

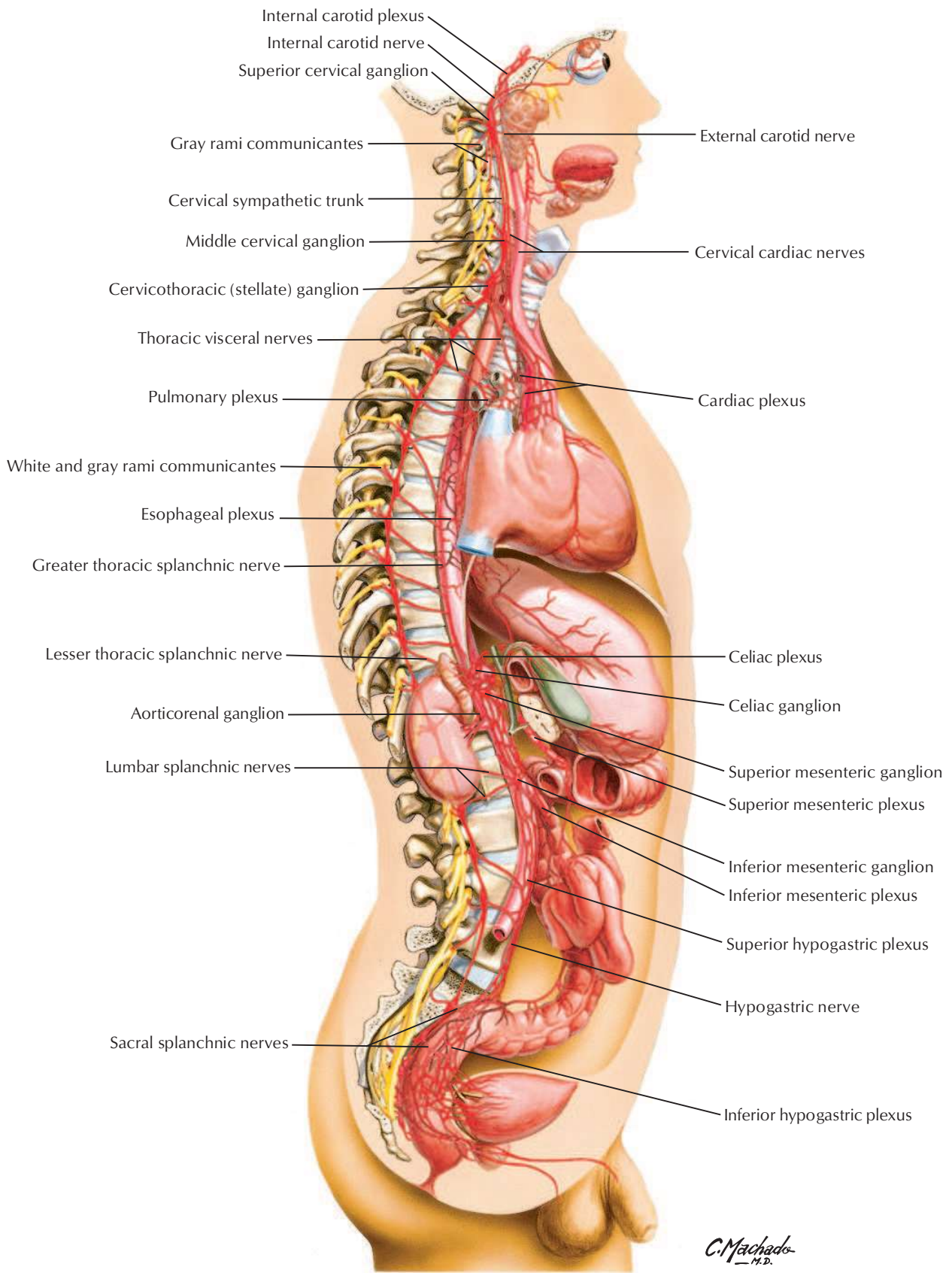
Note: The vertebral bodies are numbered.

Axial T2-weighted MRI section through upper lumbar level, without contrast

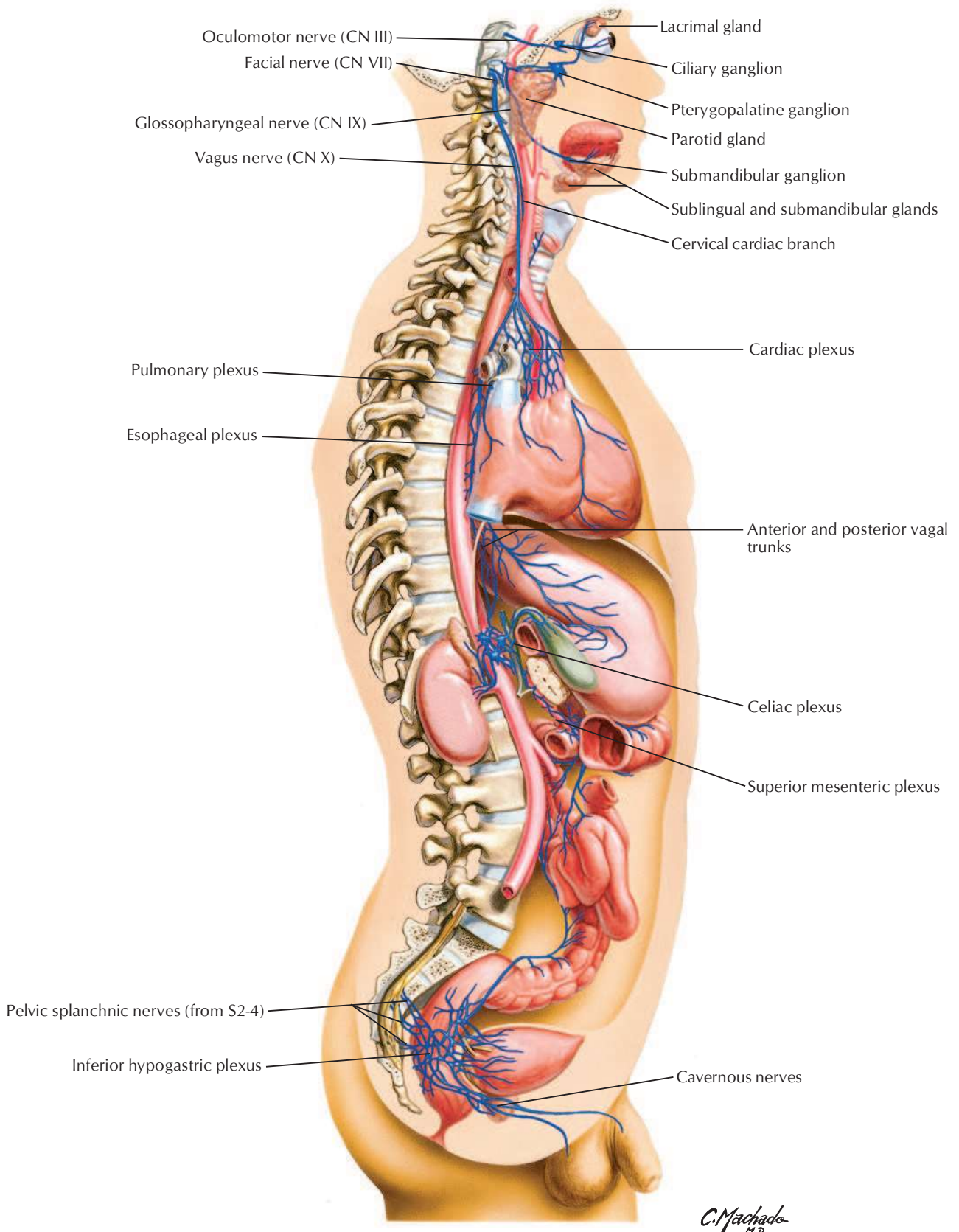


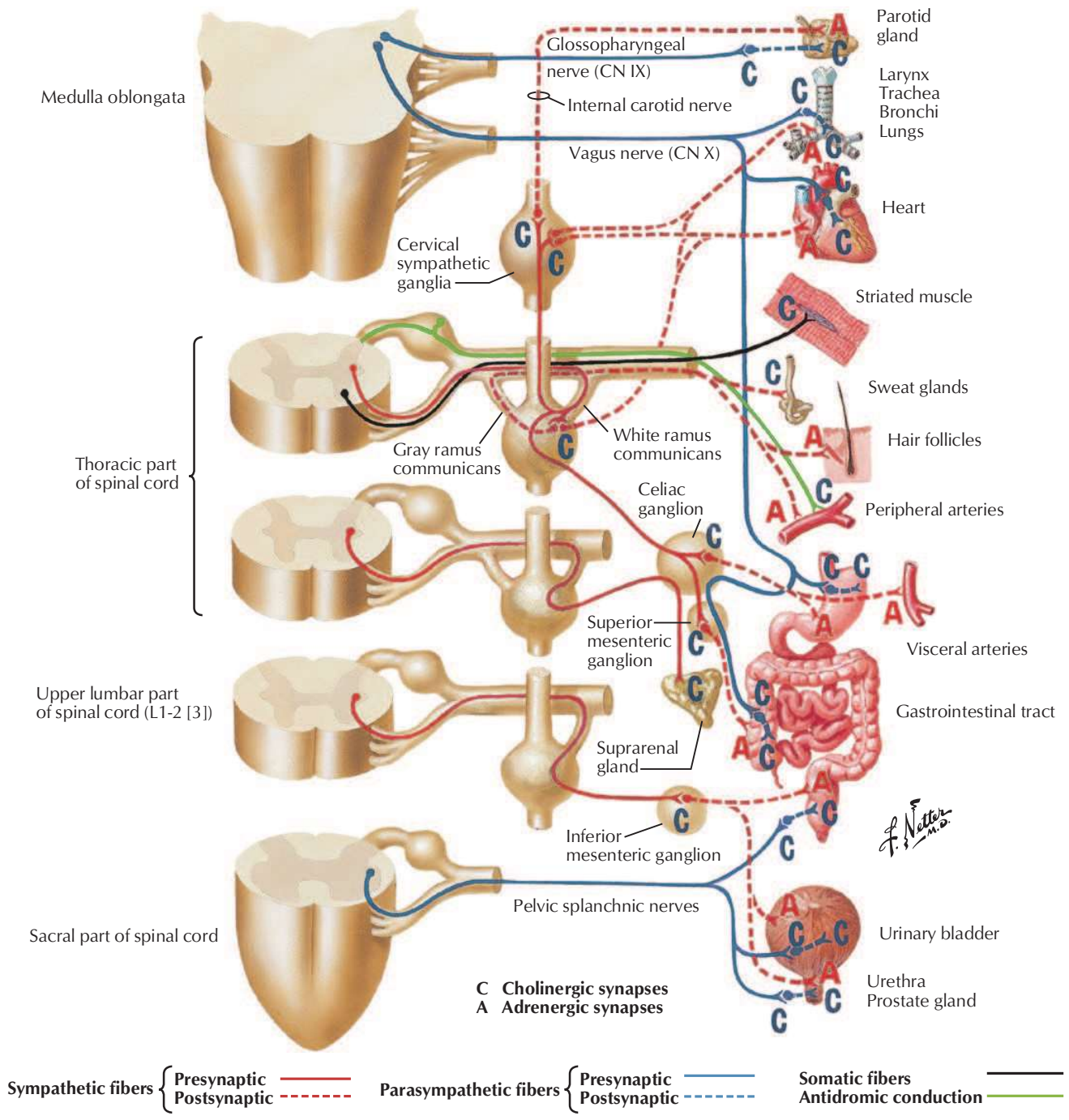
Axial T2-weighted MRI section through lower lumbar level, without contrast

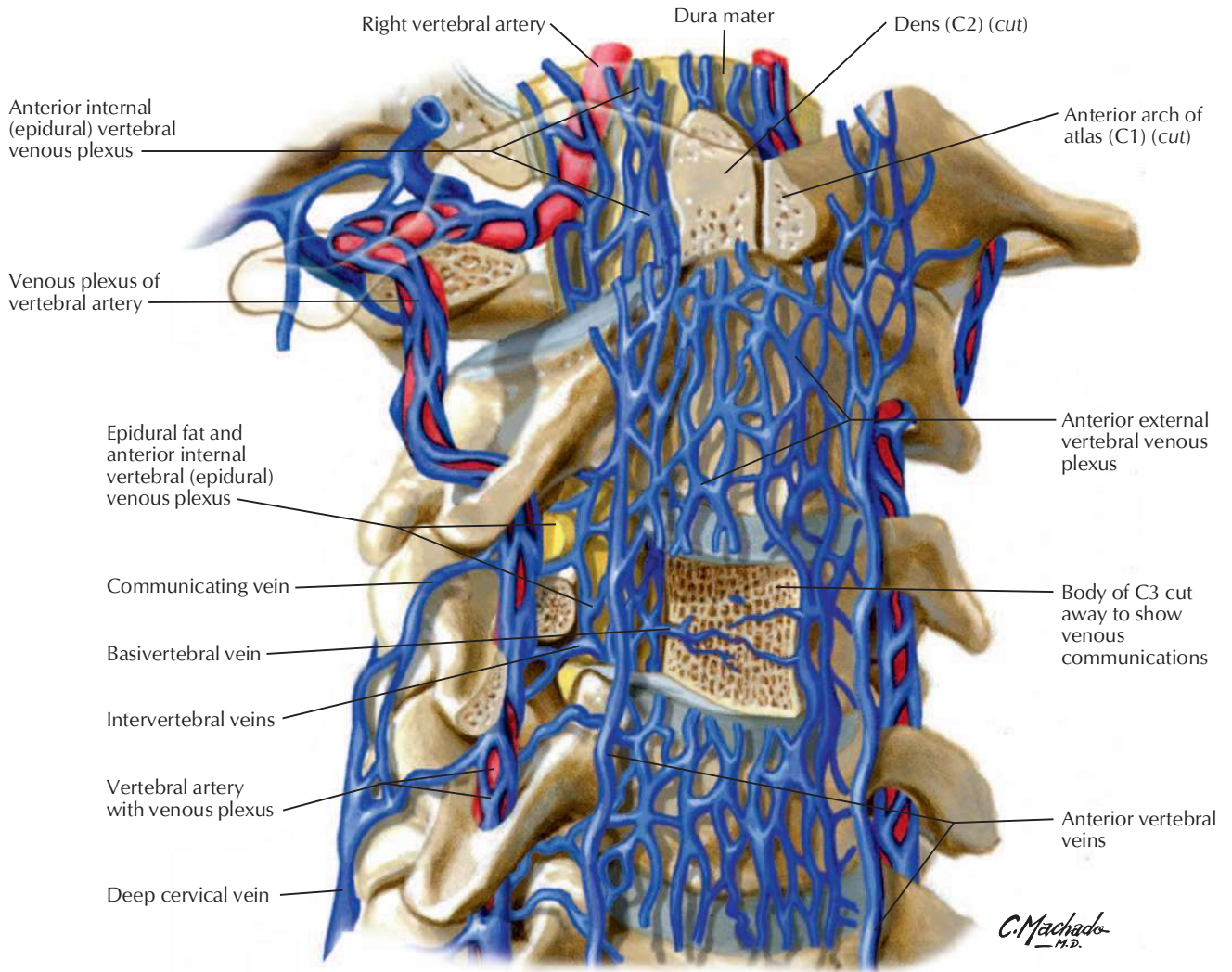




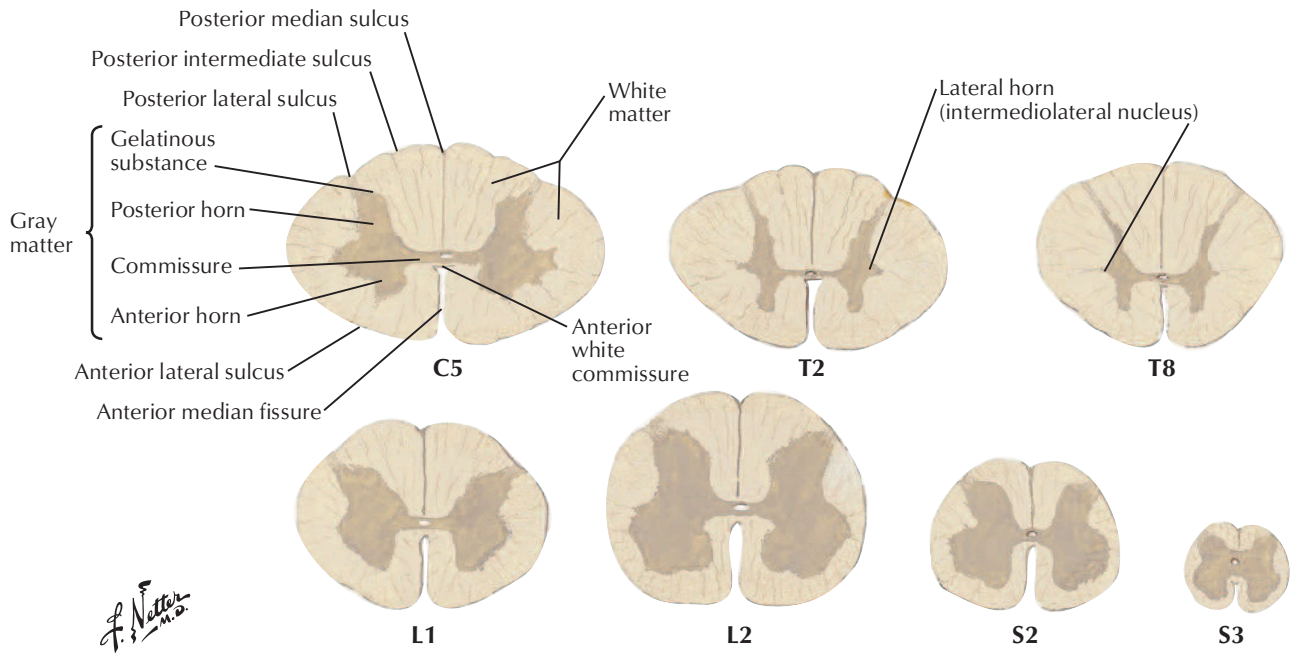
Parasympathetic Nervous System: General Topography





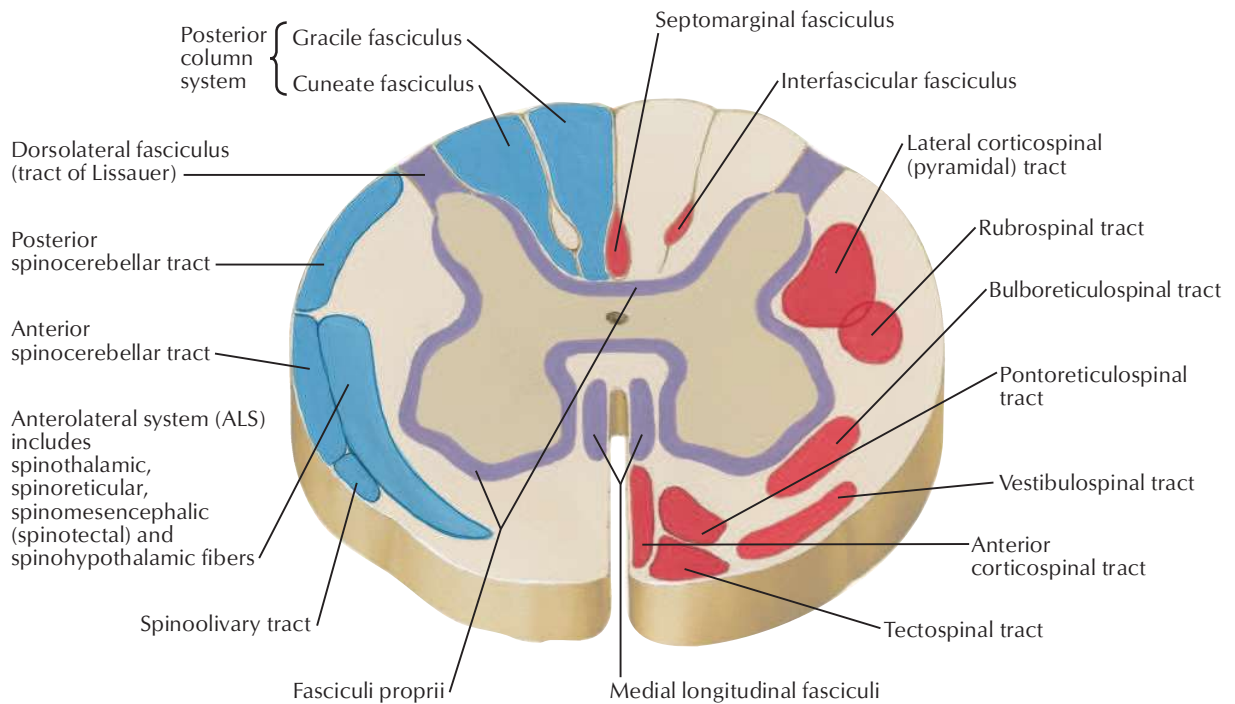


Sections through spinal cord at various levels



Principal fiber tracts of spinal cord

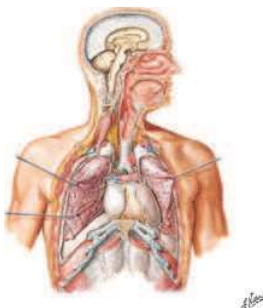- Ascending pathways
- Descending pathways
- Fibers passing in both directions



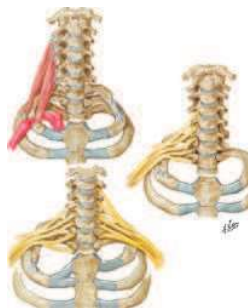This page intentionally left blank

Surface Anatomy	187	Regional Scans	244
Mammary Gland	188-191	Cross-Sectional Anatomy	245-248
Body Wall	192-201	Structures with High Clinical Significance	Tables 4.1-4.2
Lungs	202-214	Muscle Table	Table 4.3
Heart	215-233	Electronic Bonus Plates	BP44-BP57
Mediastinum	234-243		

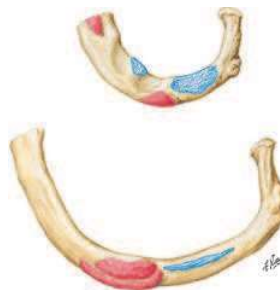
ELECTRONIC BONUS PLATES



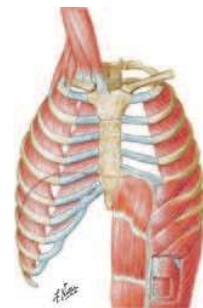BP44 Respiratory System



BP45 Cervical Ribs and Related Anomalies



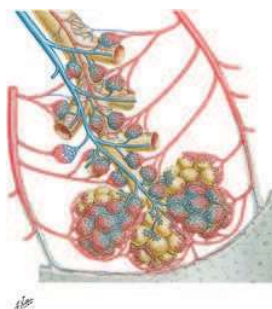
BP46 Muscle Attachments of Ribs



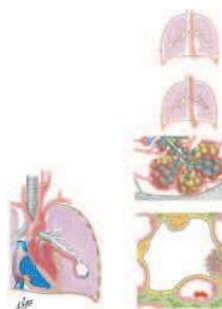BP47 Muscles of Respiration



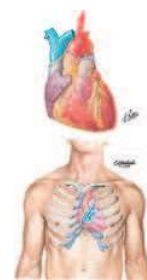BP48 Intrapulmonary Airways: Schema



BP49 Intrapulmonary Blood Circulation: Schema

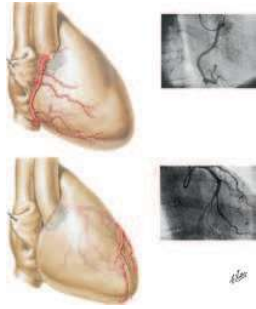


BP50 Gas Exchange

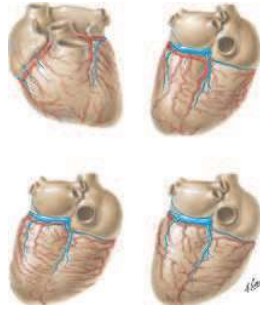


BP51 Anterior Aspect of Heart

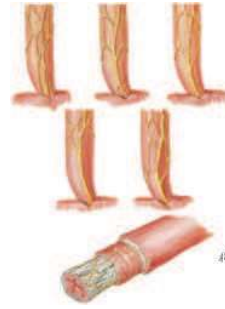ELECTRONIC BONUS PLATES—*cont'd*



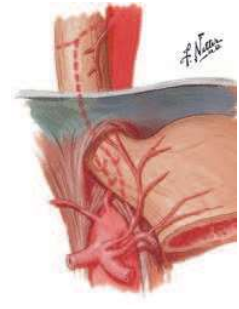
BP52 Coronary Arteries:
Right Anterior Oblique
Views with Arteriograms



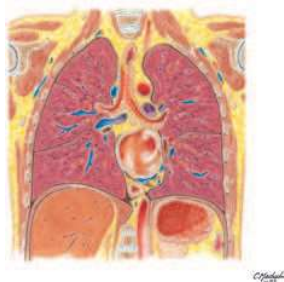BP53 Coronary Arteries
and Cardiac Veins:
Variations



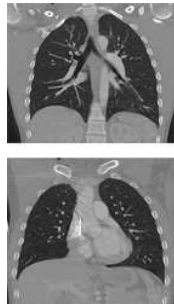
BP54 Intrinsic Nerves and
Variations in Nerves of
Esophagus



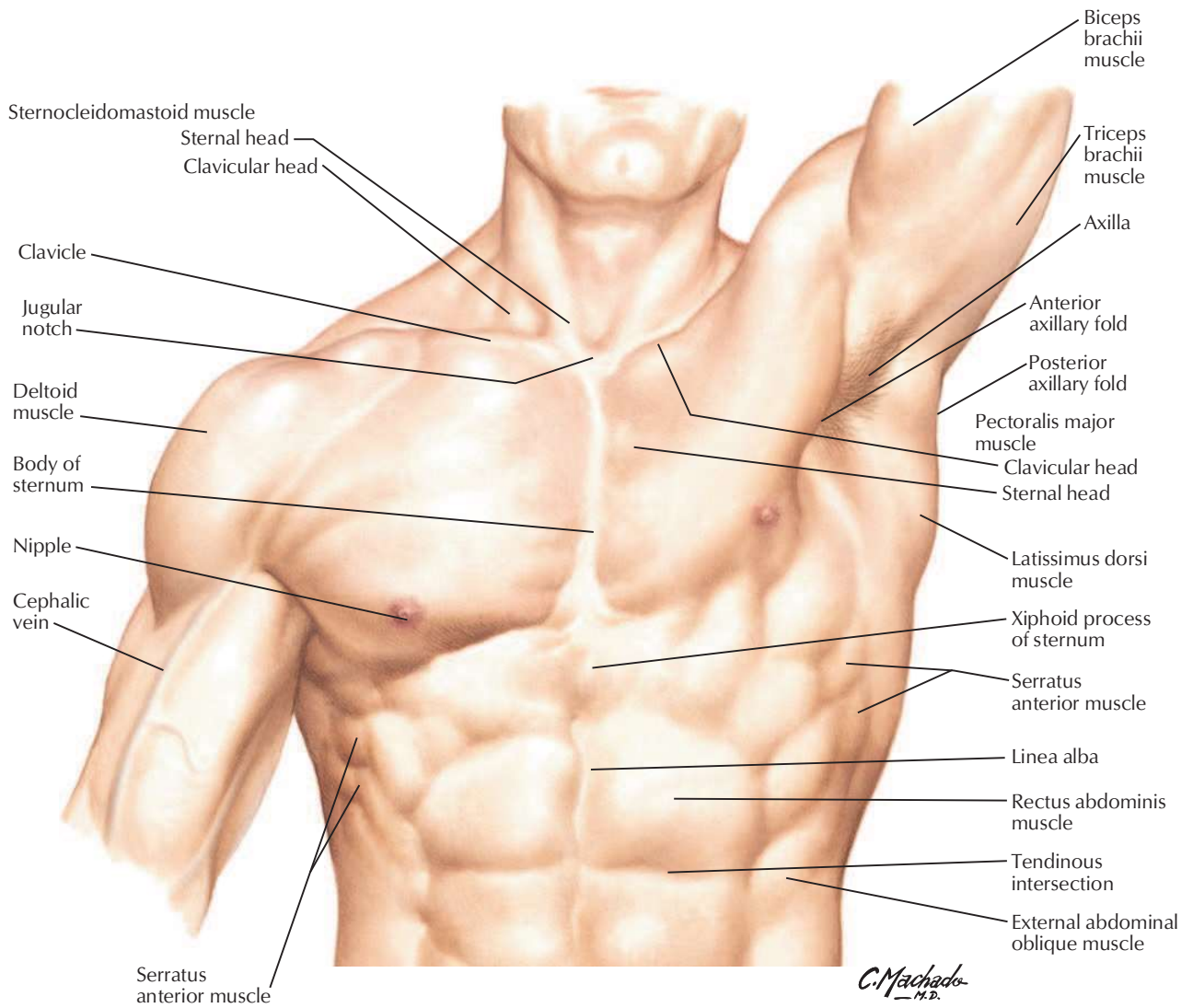
BP55 Arteries of
Esophagus: Variations



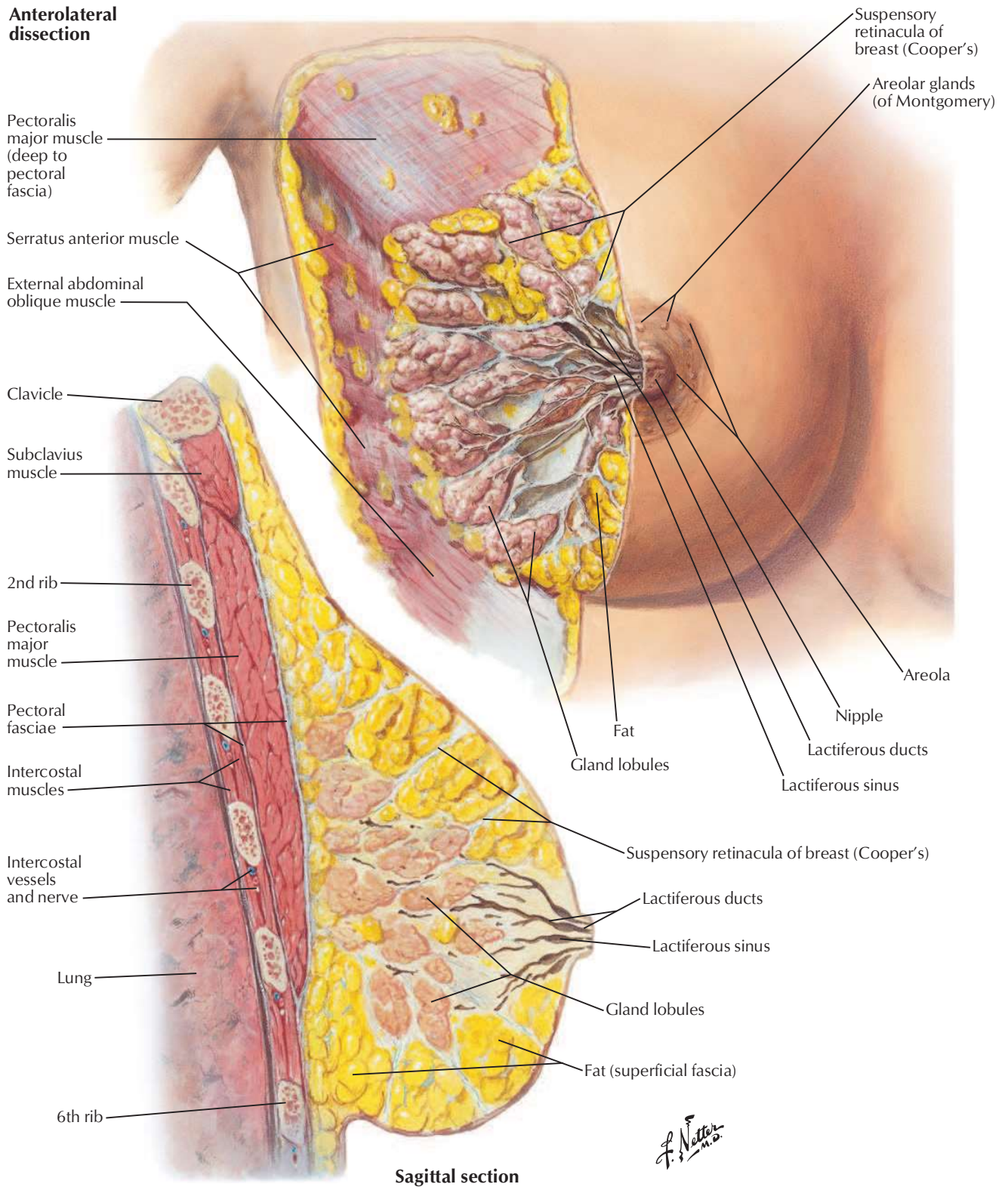
BP56 Thorax: Coronal
Section (Midaxillary Line,
Tracheal Bifurcation, Left
Atrium)

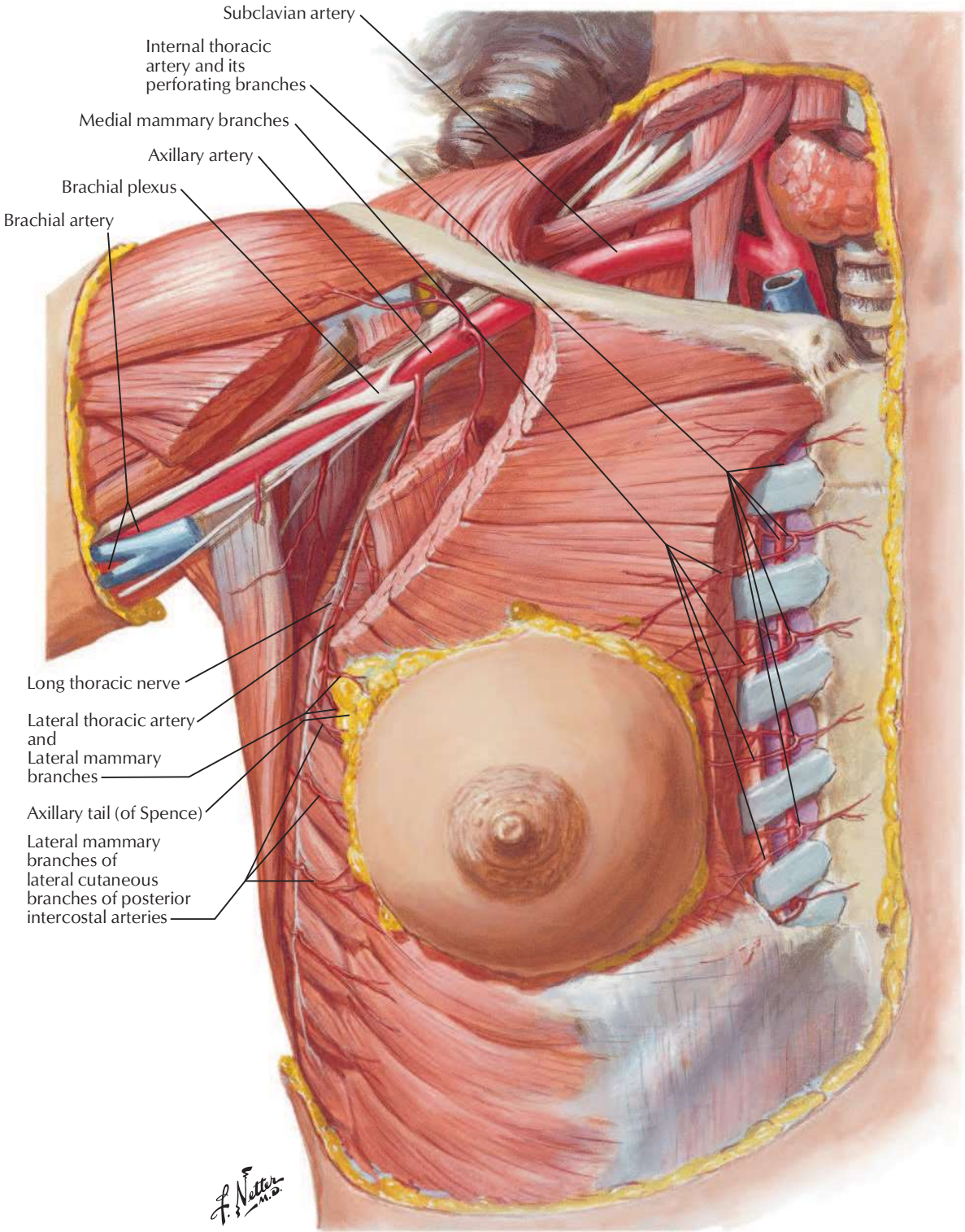


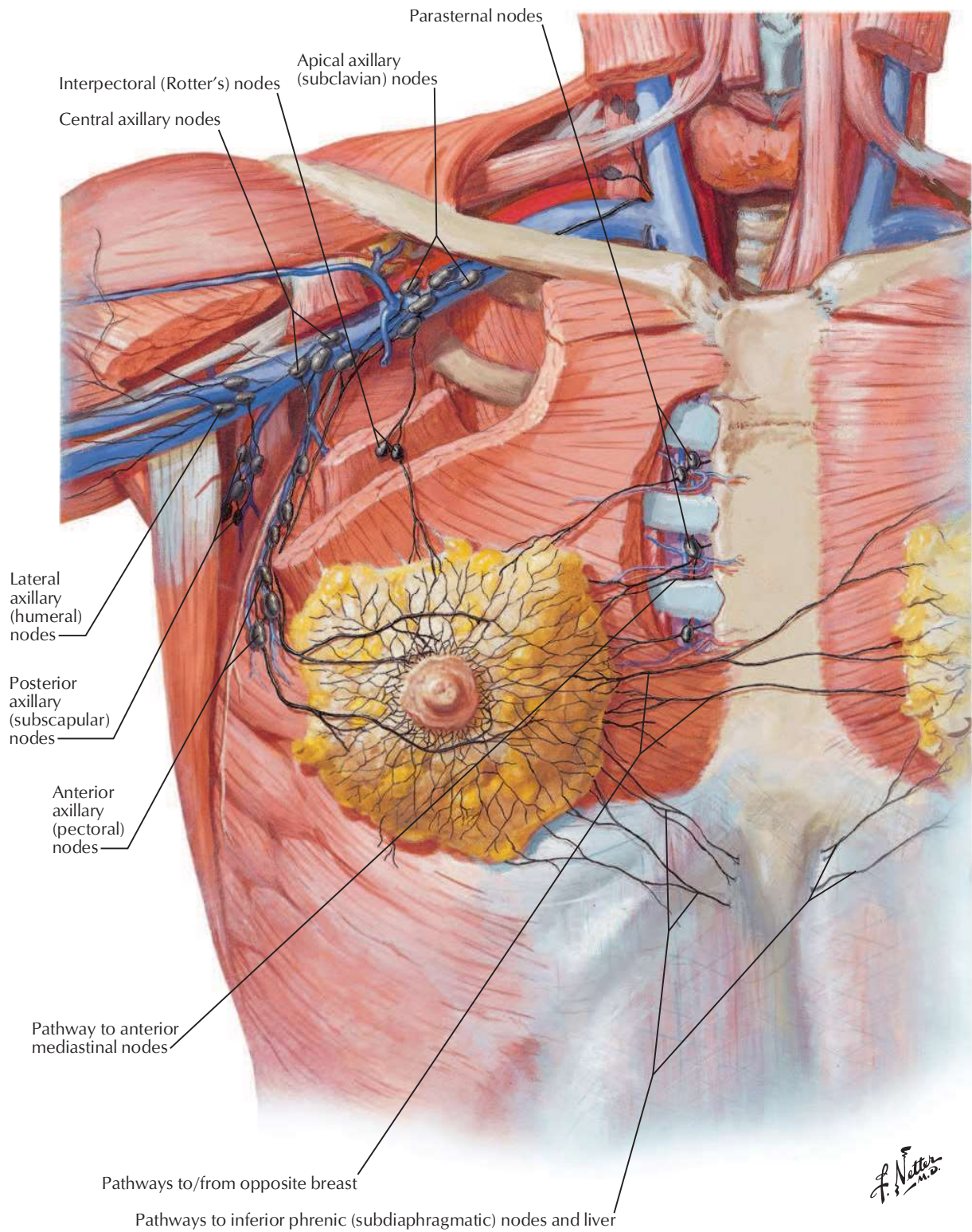
BP57 Thorax: Coronal CTs

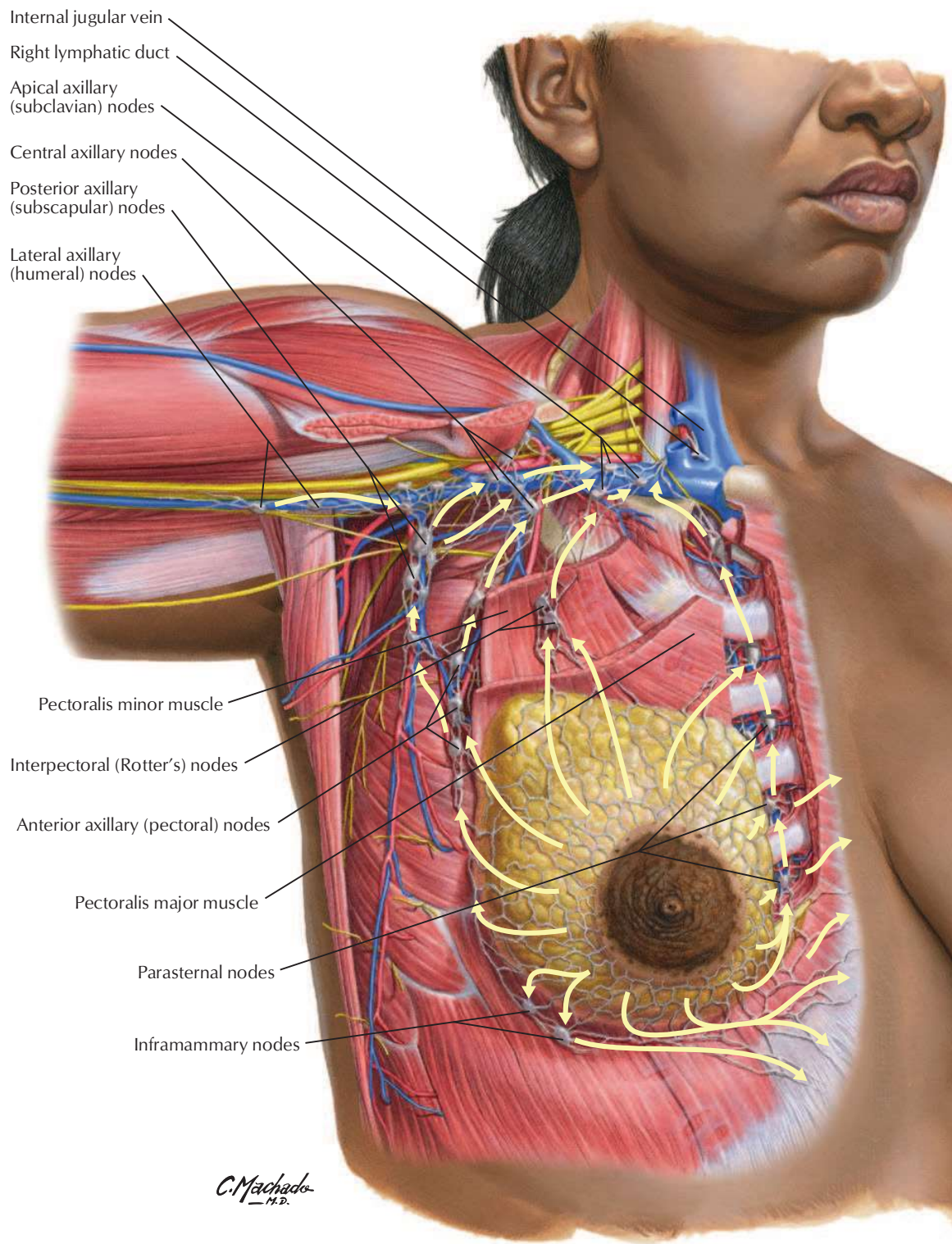


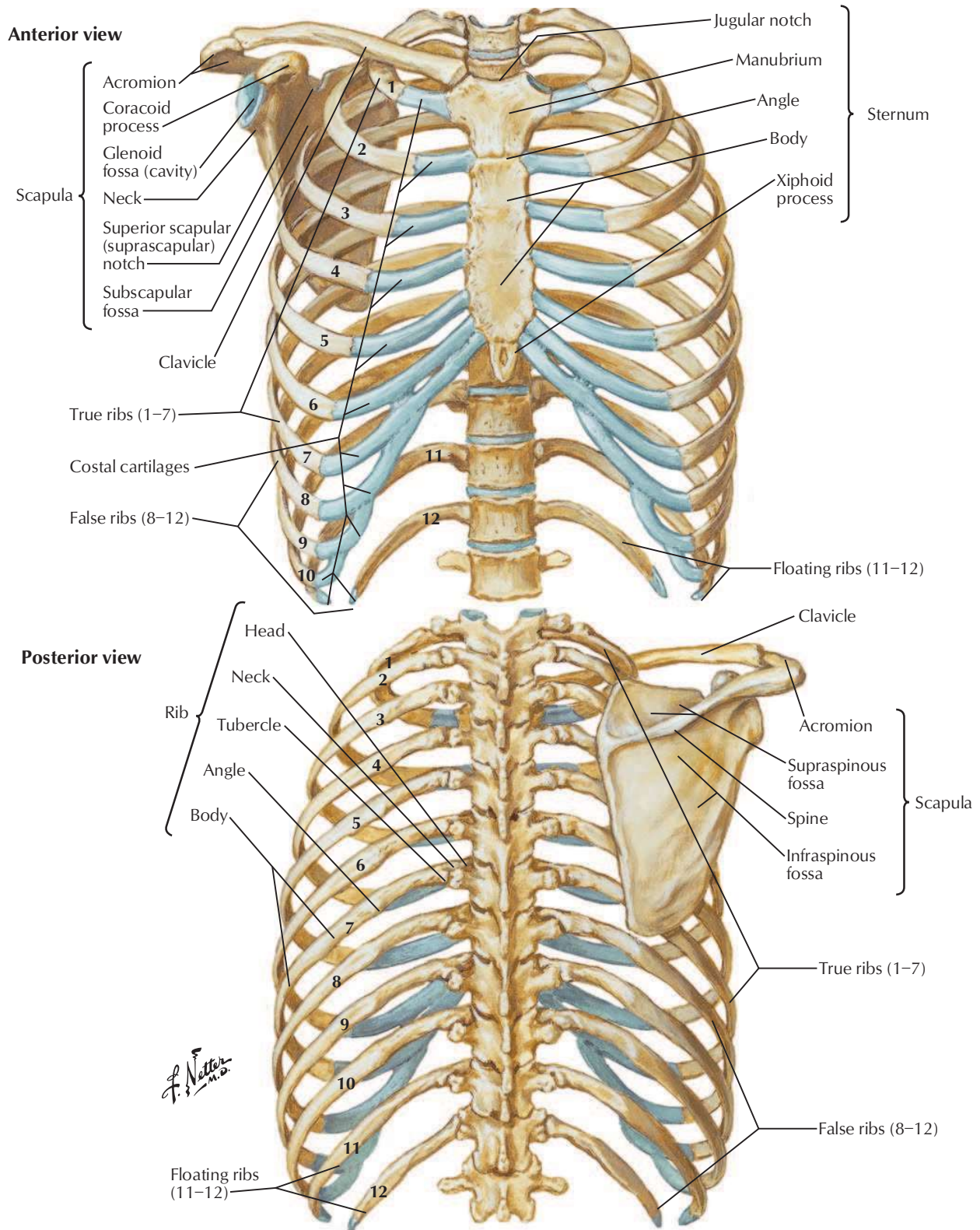
Anterolateral dissection

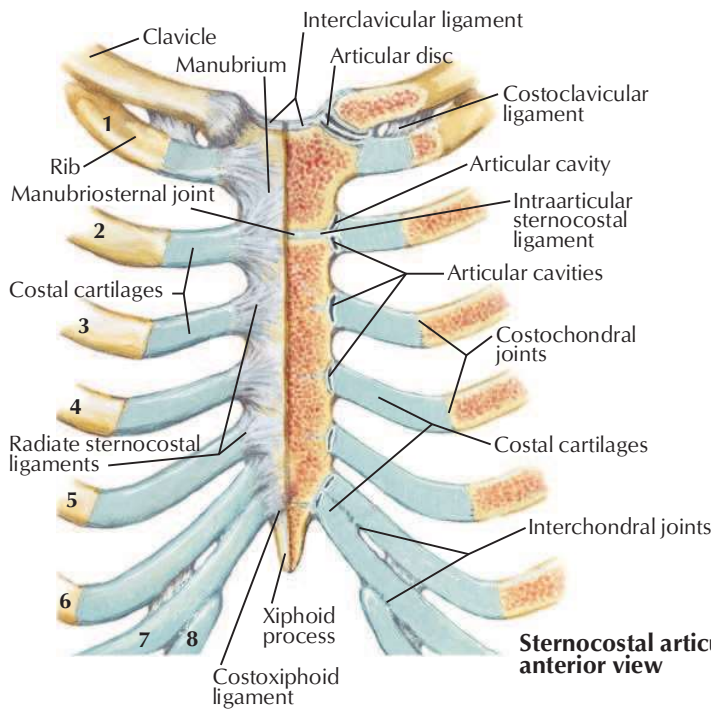




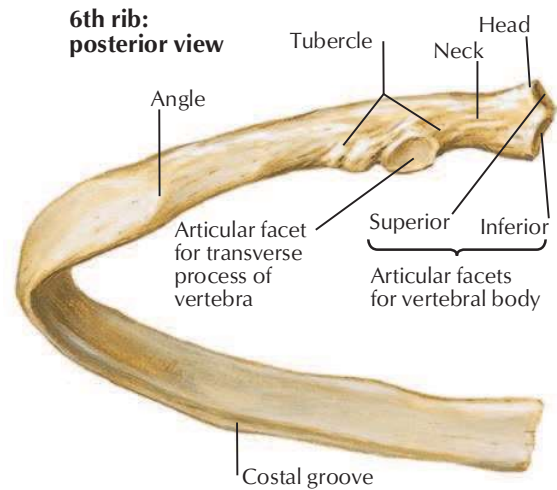








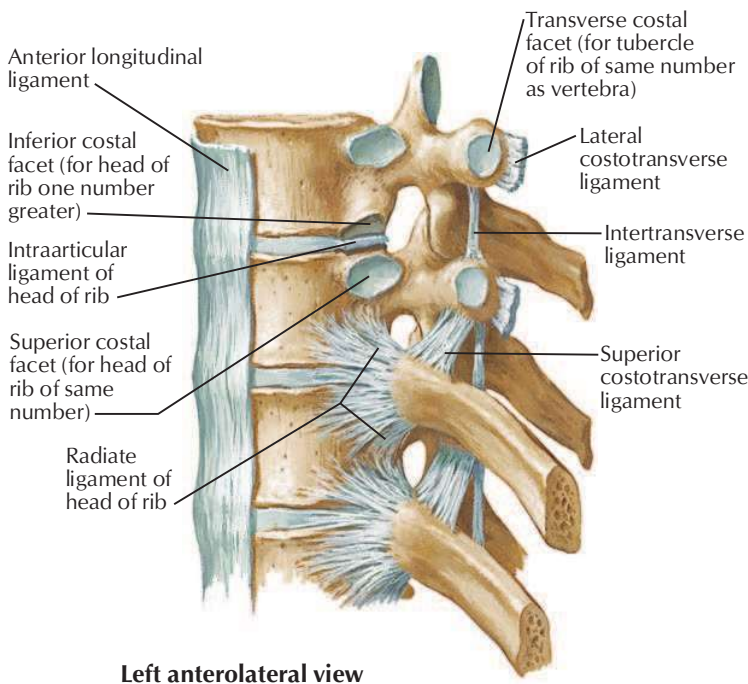
Sternocostal articulations: anterior view



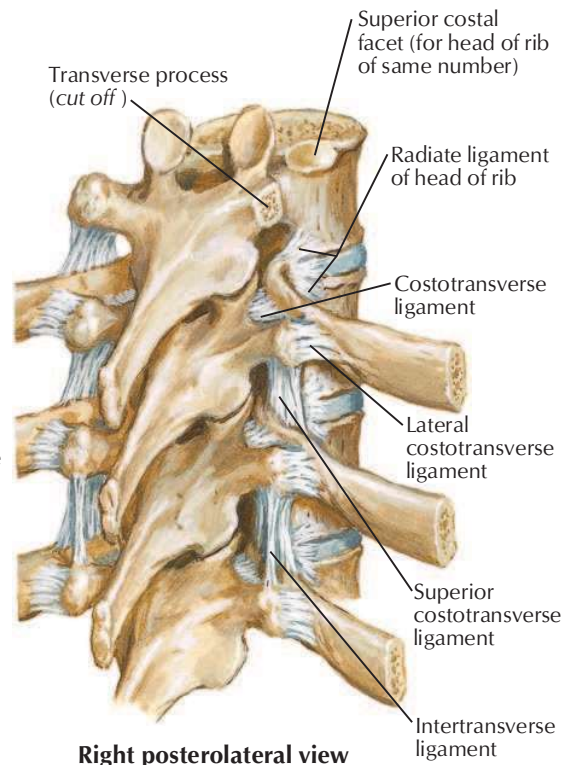
6th rib: posterior view

F. Netter M.D.

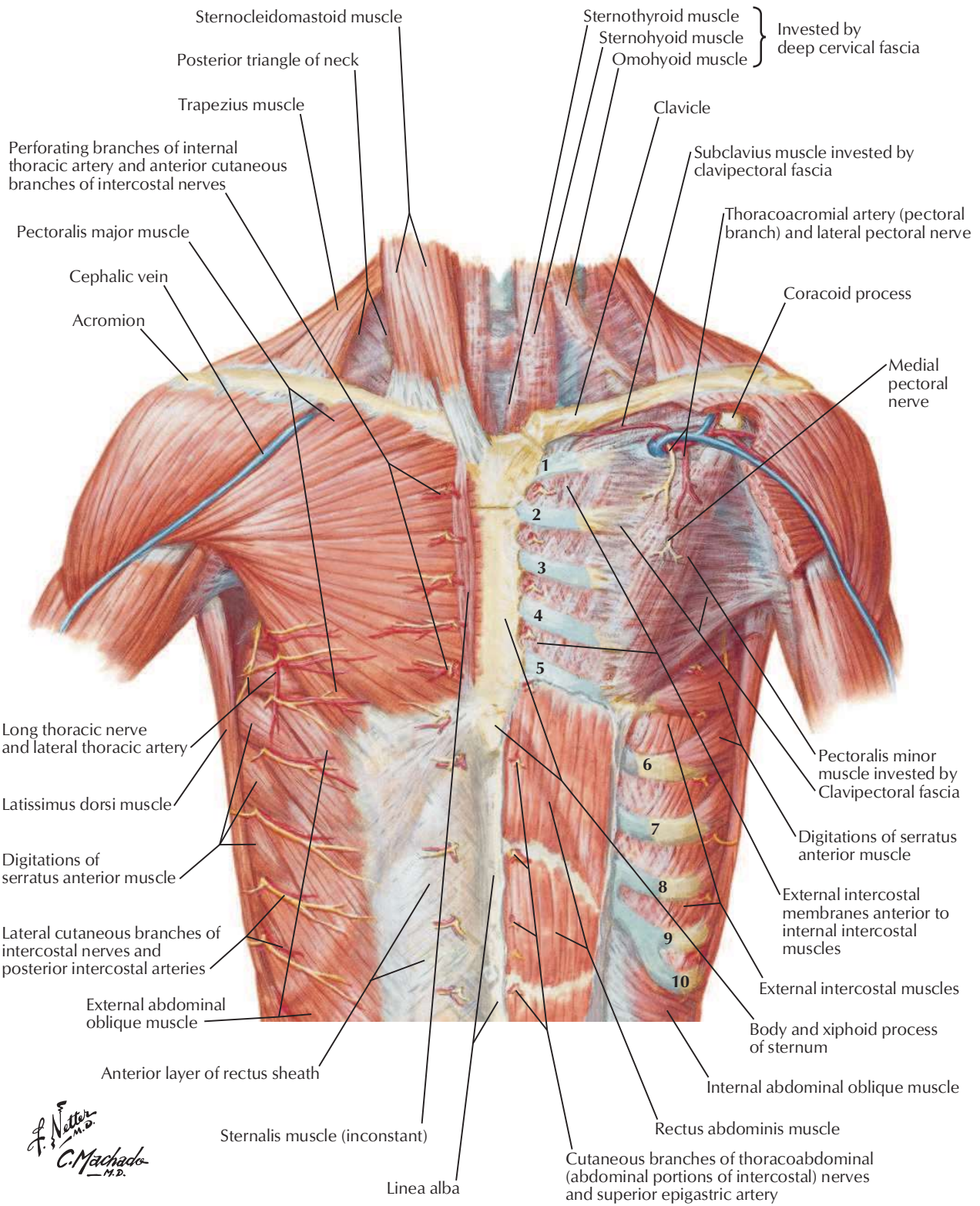
Note: The head of a typical rib articulates with the superior costal facet of the thoracic vertebra of the same number (by its inferior articular facet), the inferior costal facet of the vertebra above (by its superior articular facet), and the intervertebral disc between the two vertebrae. The costal tubercle articulates with the transverse process of the vertebra of the same number.



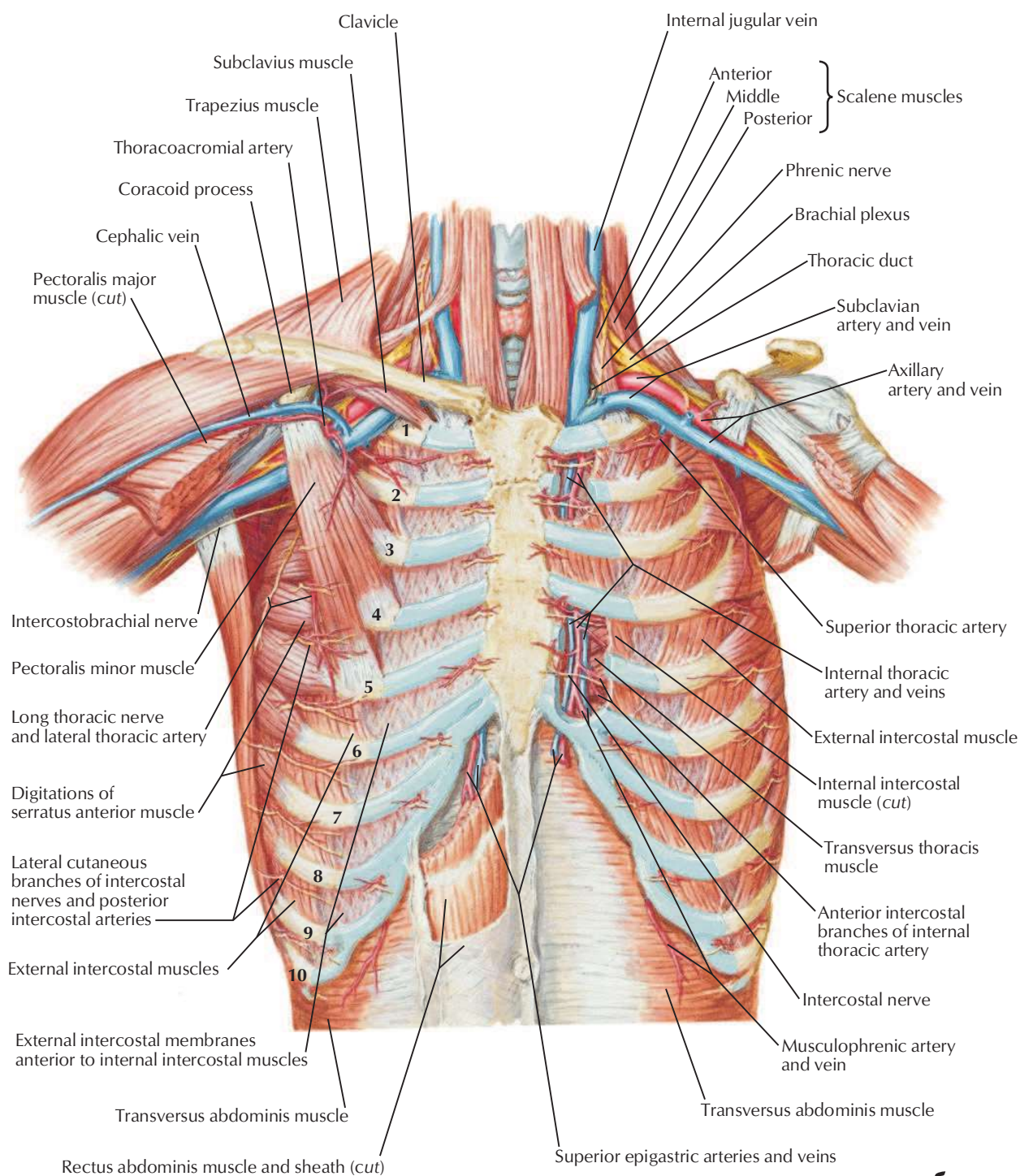
Left anterolateral view



Right posterolateral view

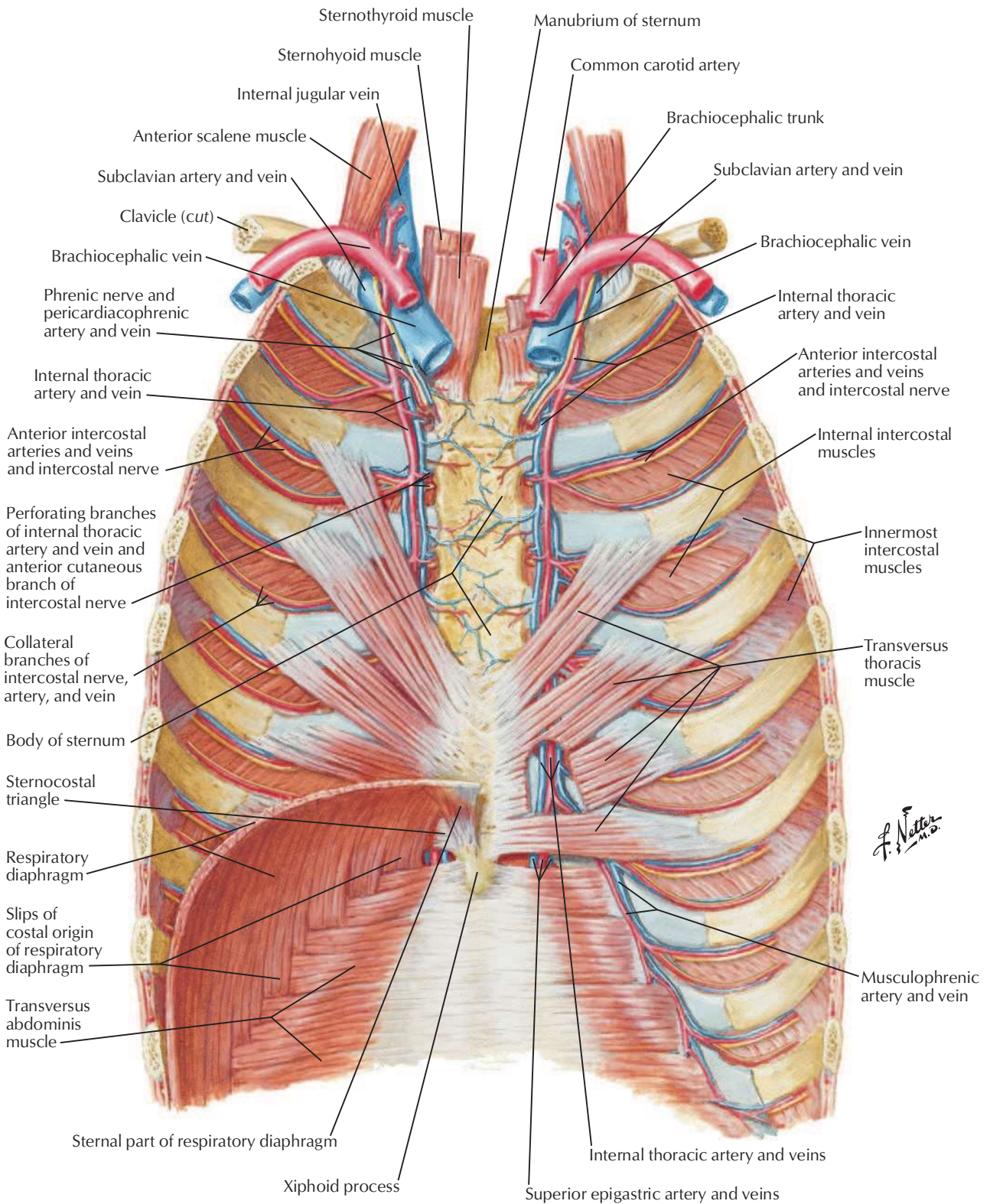


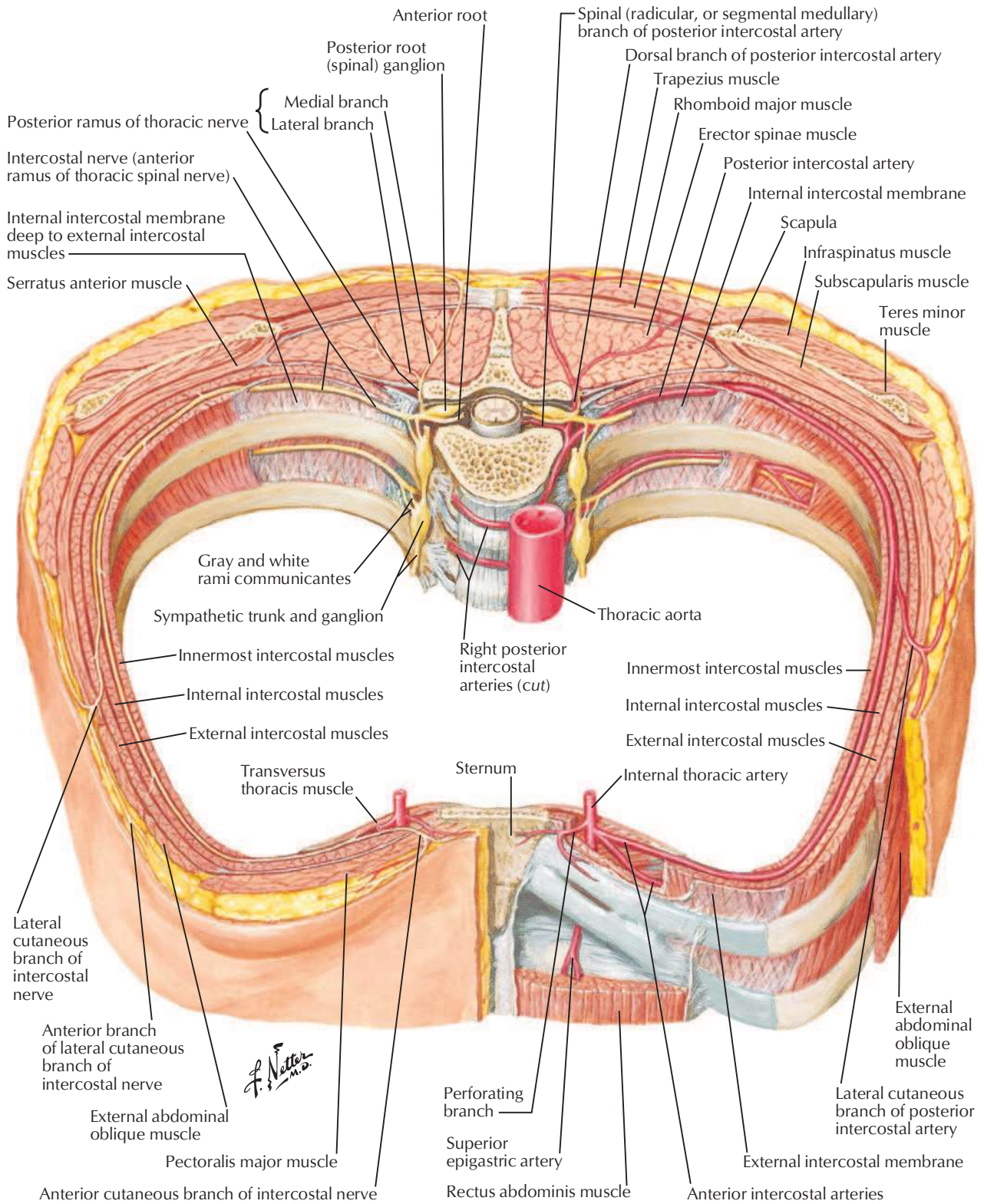
F. Netter
 M.D.
 C. Machado
 M.D.



F. Netter M.D.

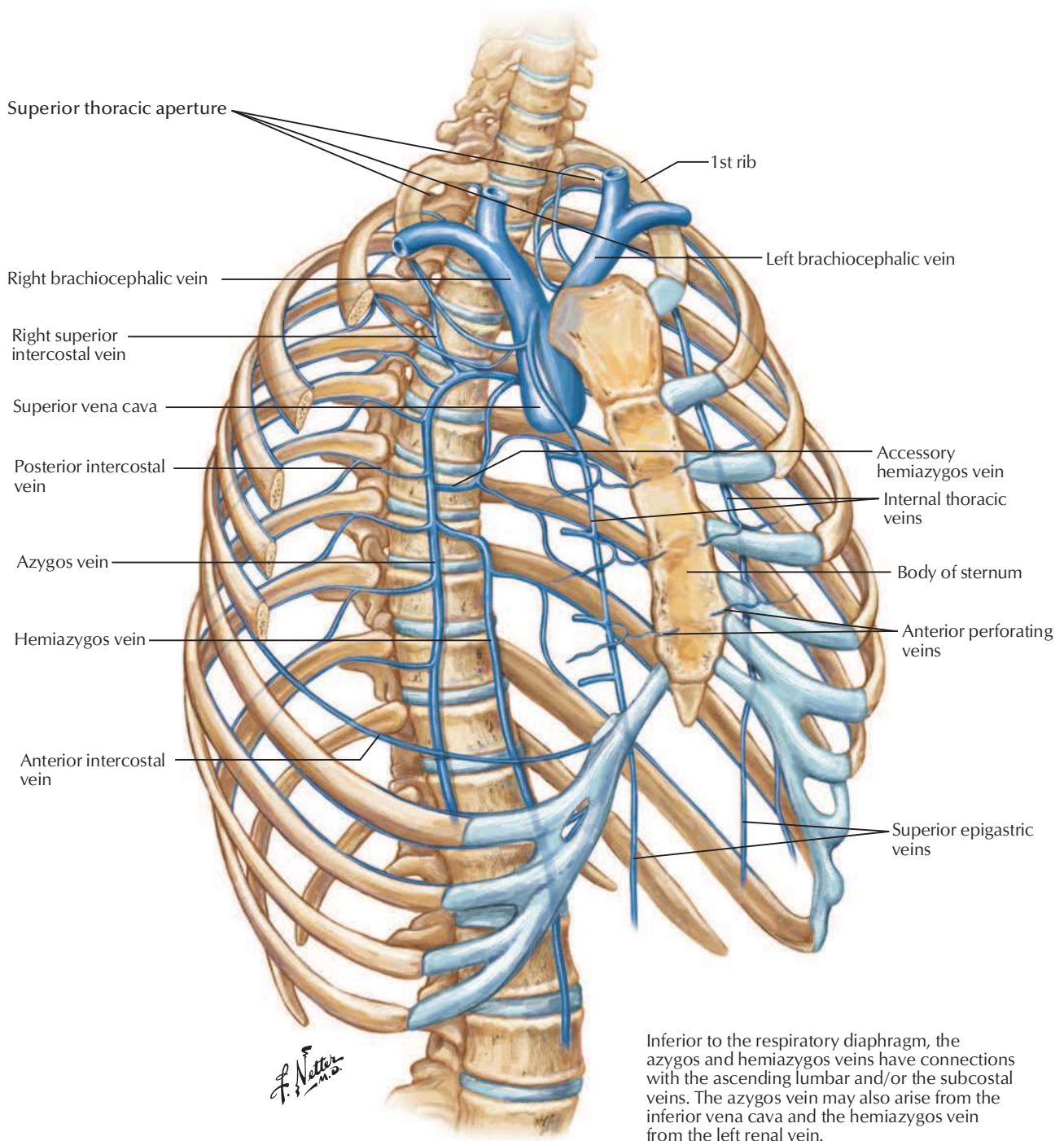
Anterior Thoracic Wall: Internal View

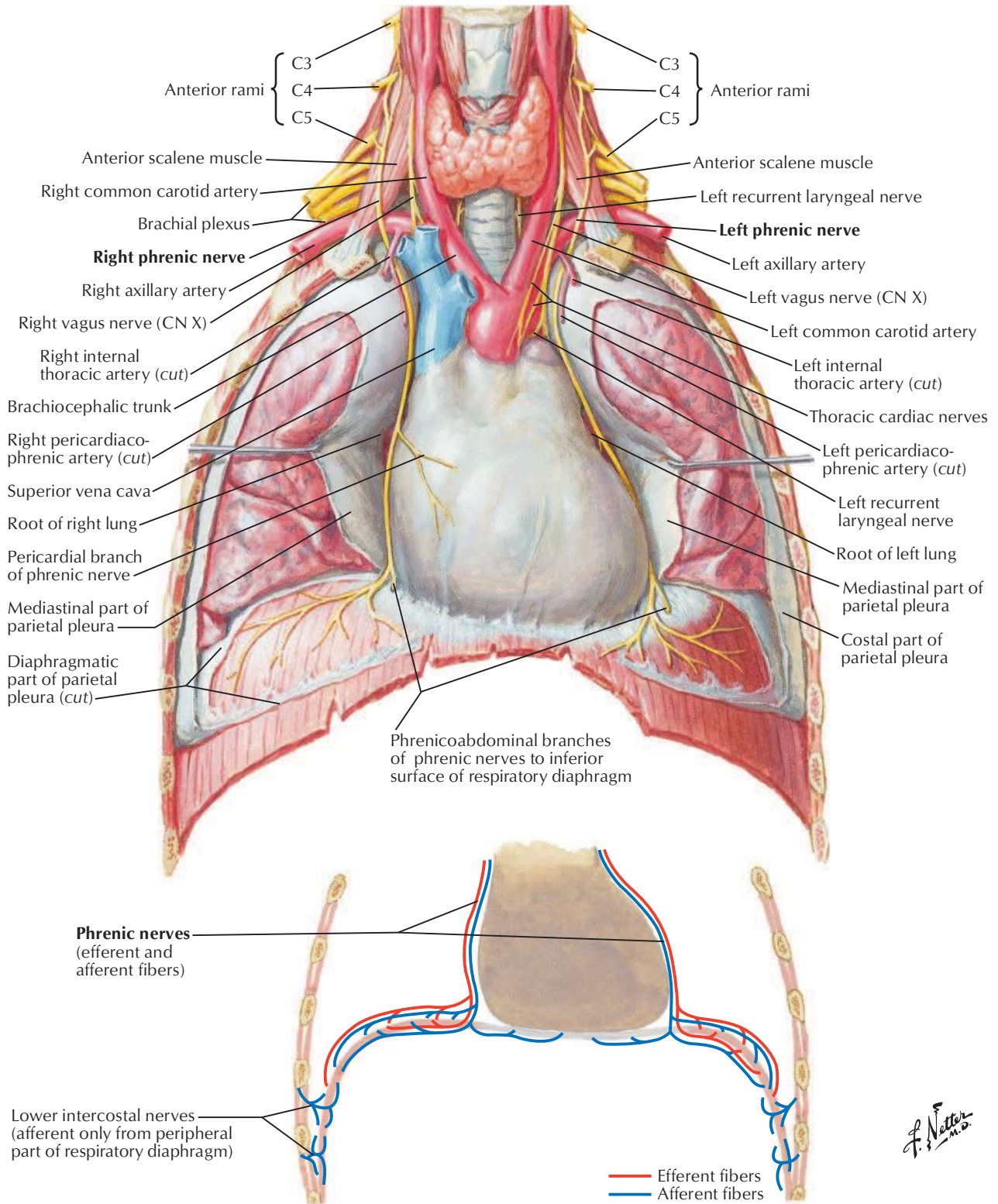




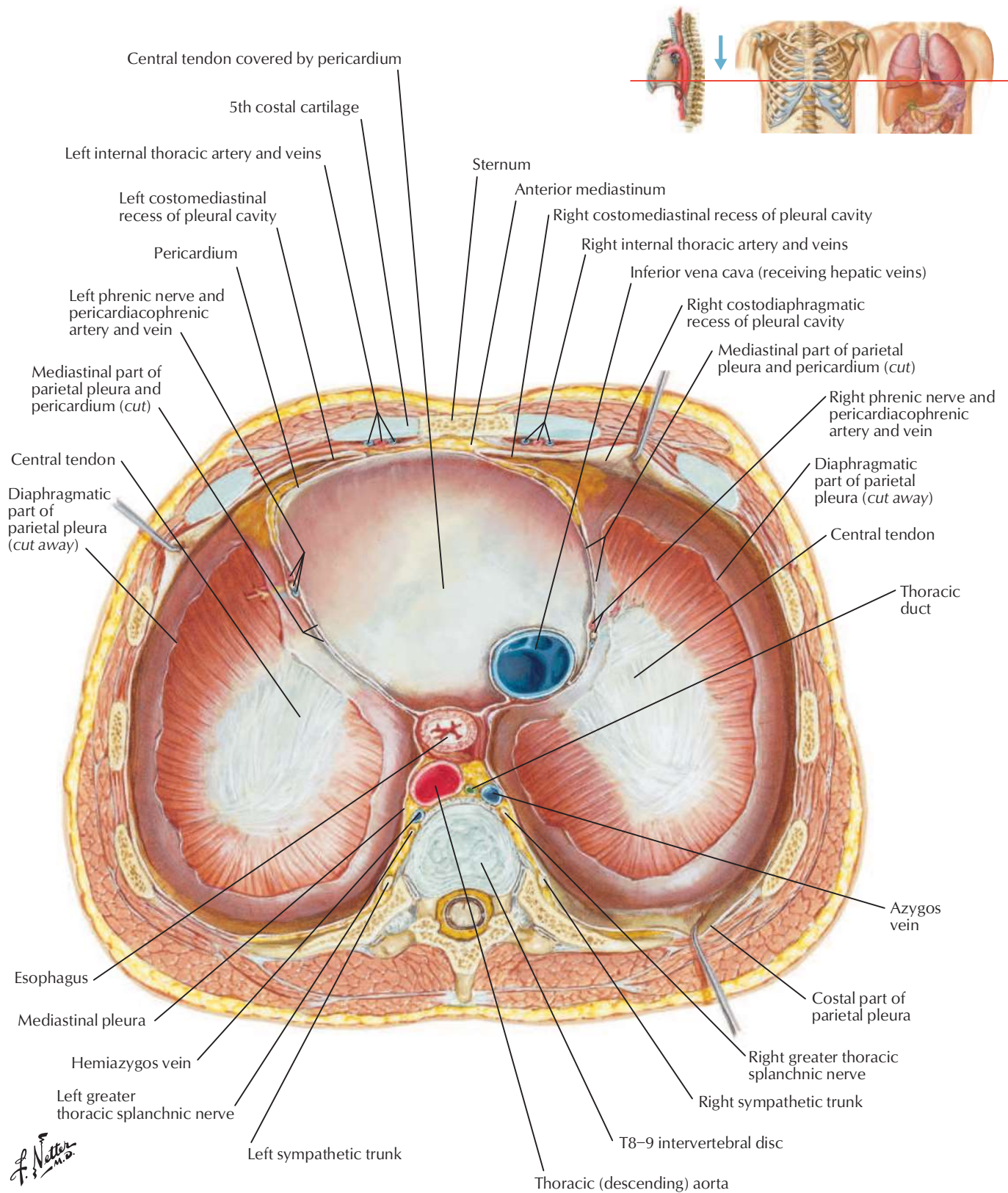
Veins of Internal Thoracic Wall

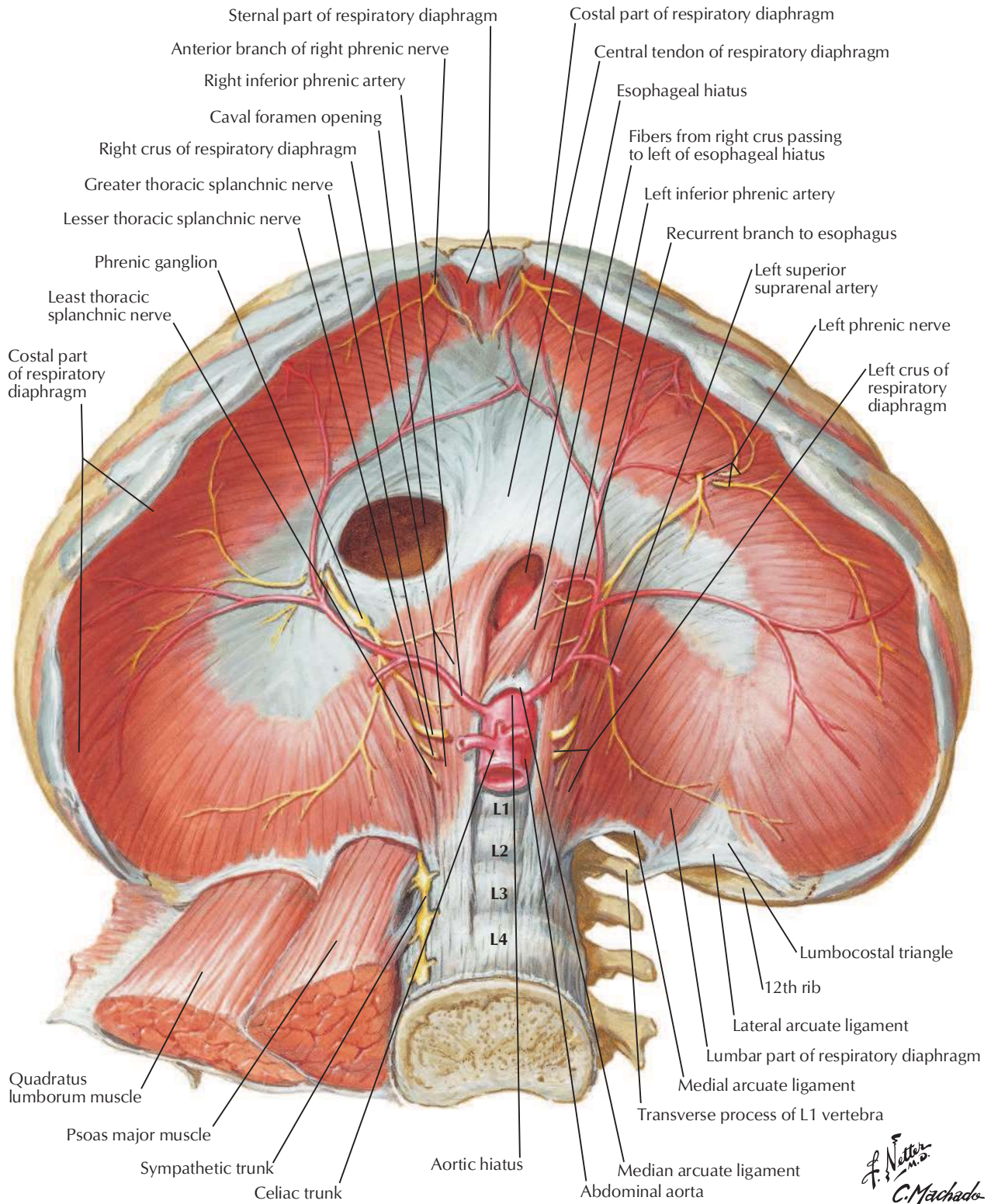
See also [Plates 234, 241, 259](#)



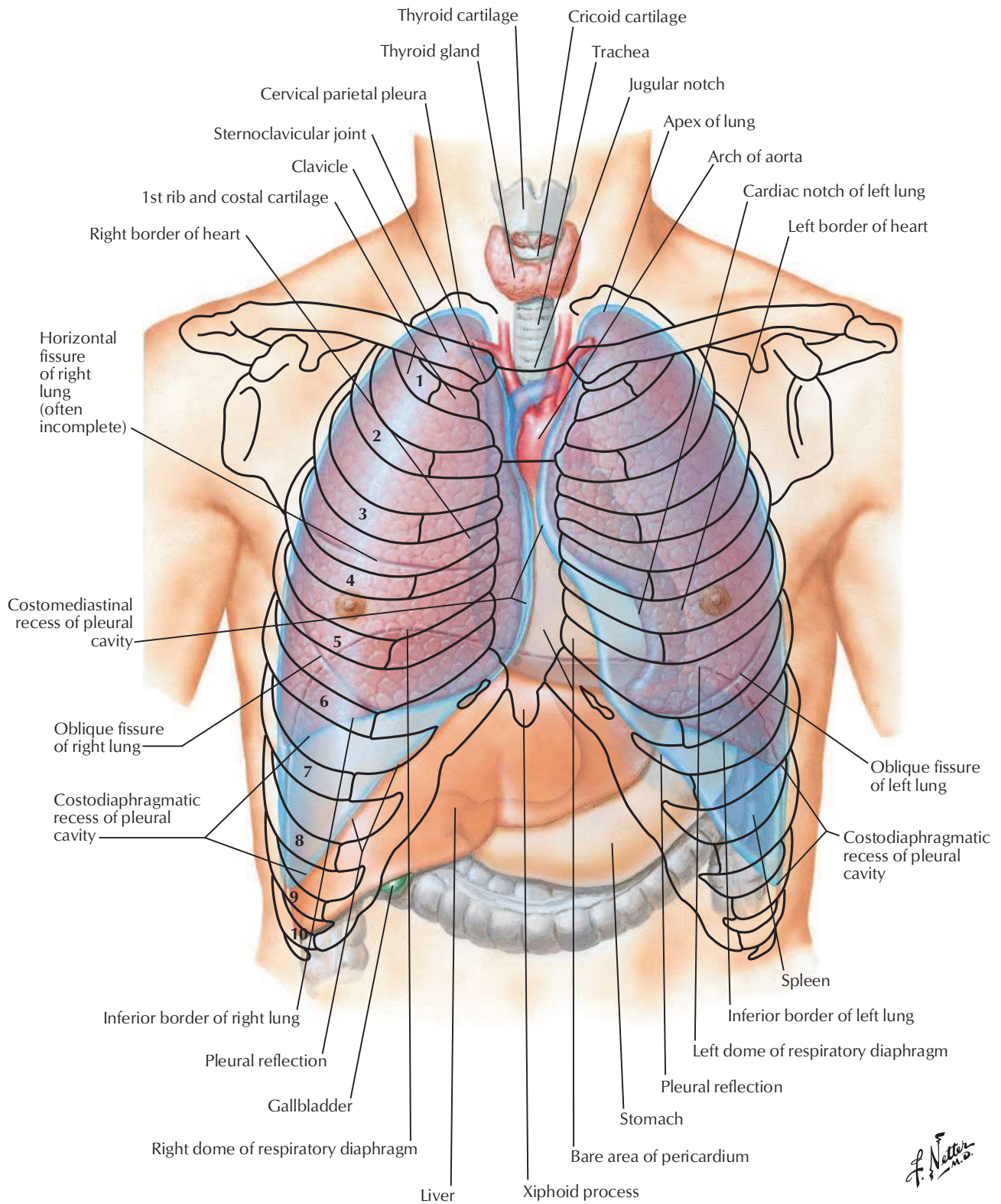


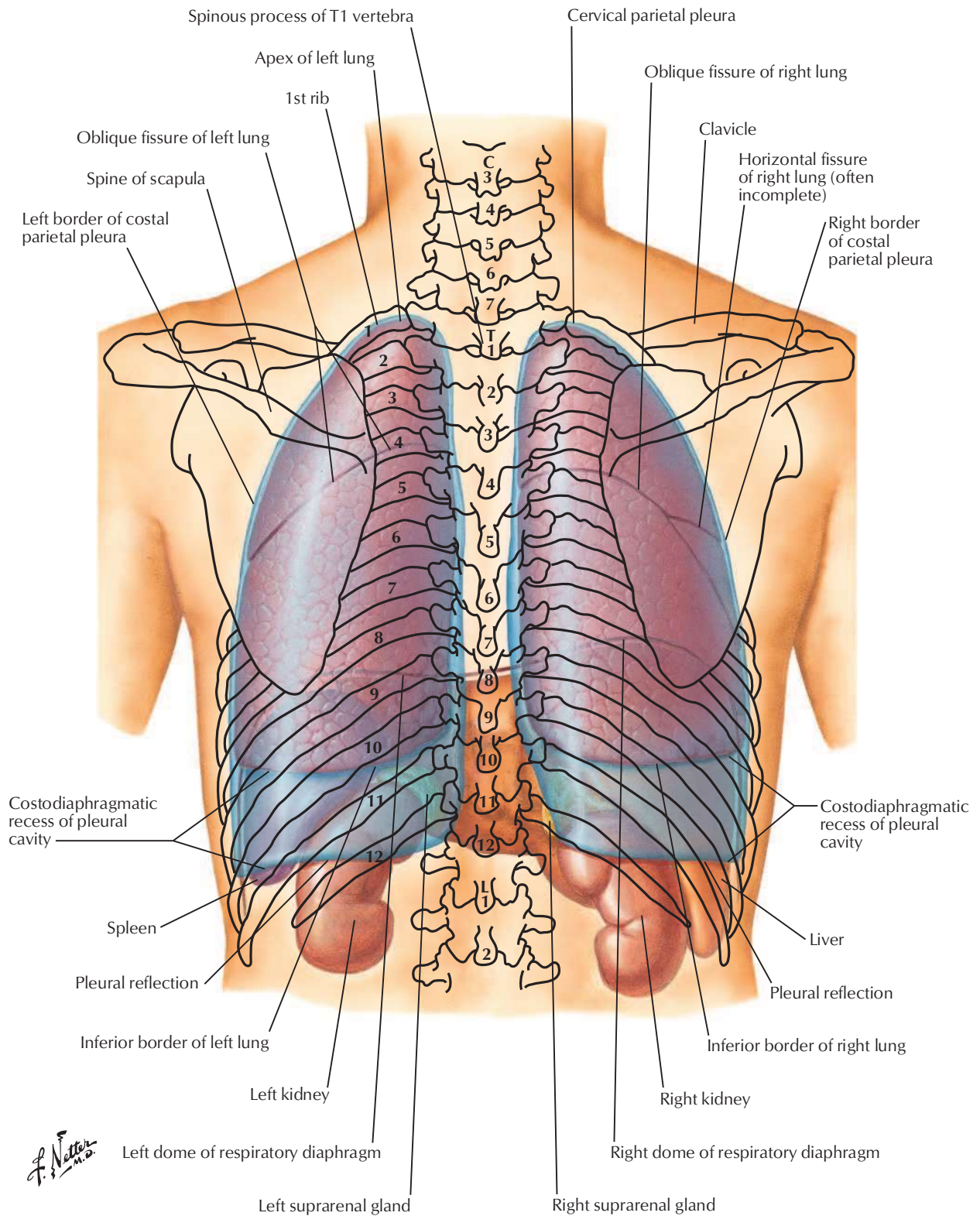
F. Netter M.D.

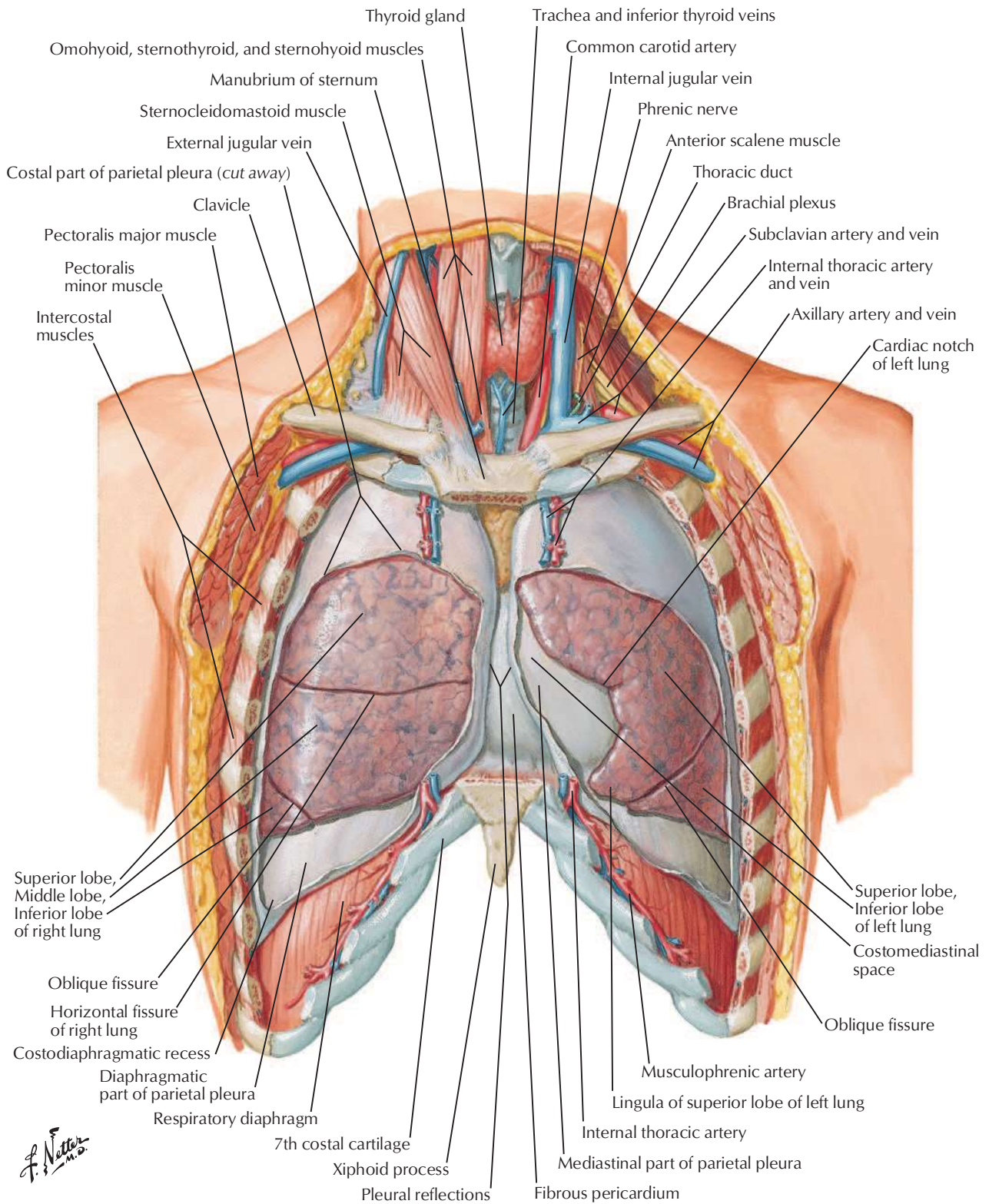


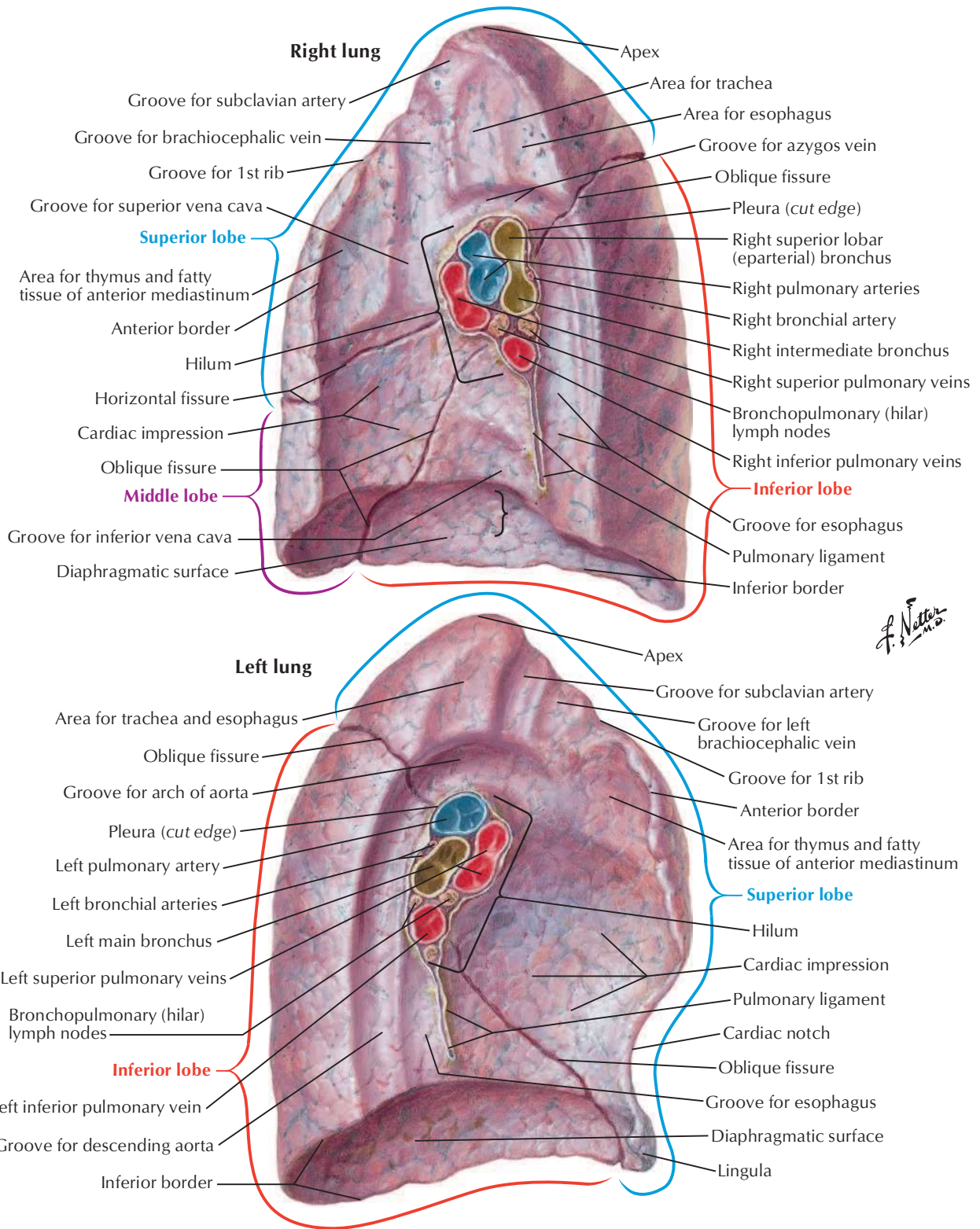


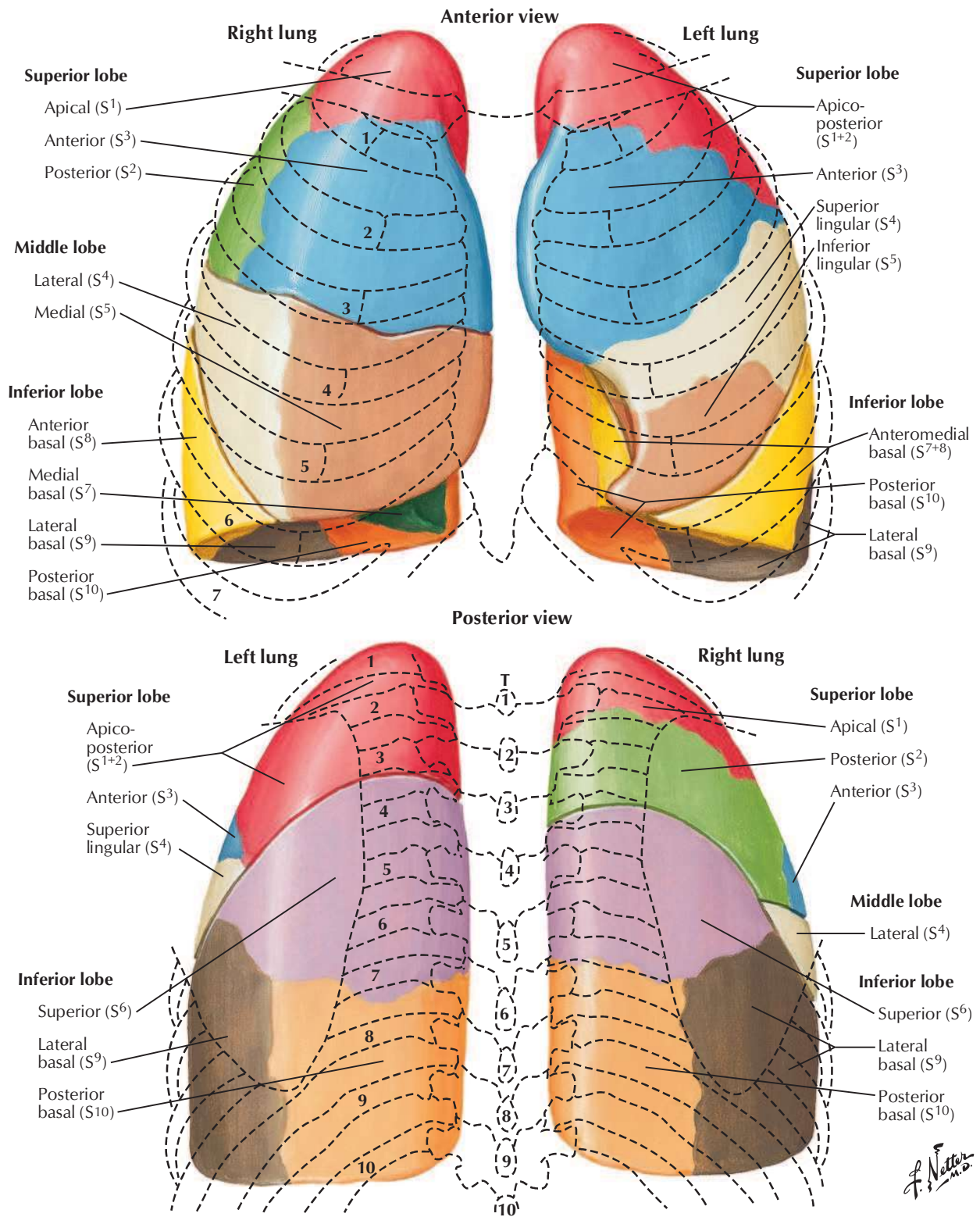
Topography of Lungs: Anterior View



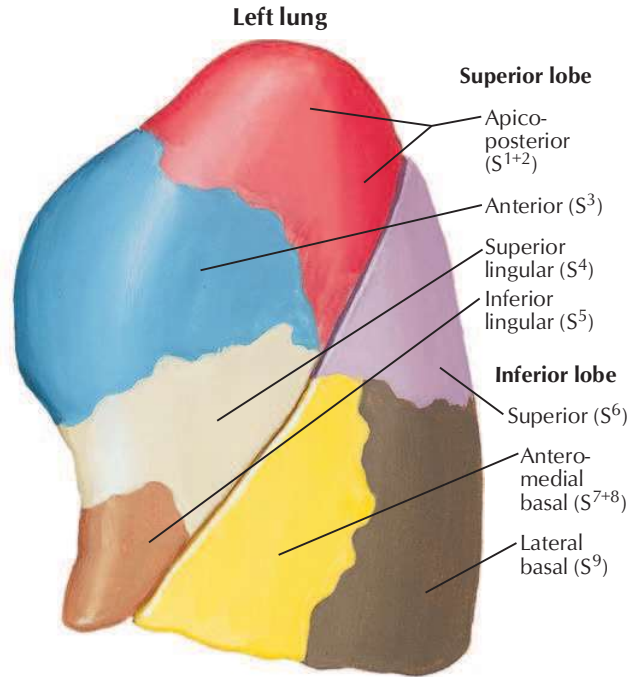
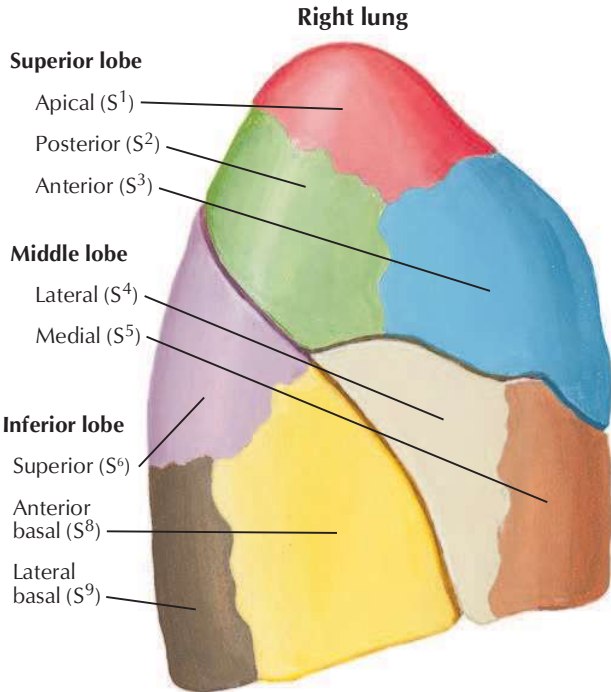






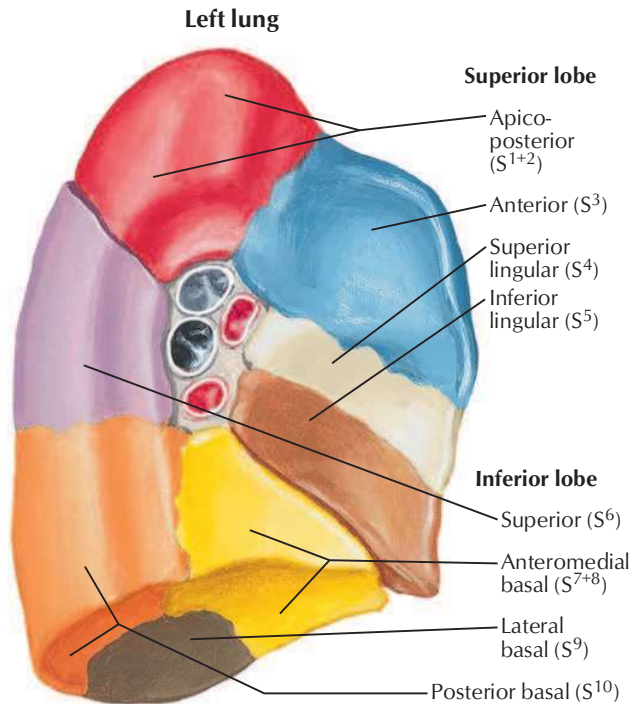
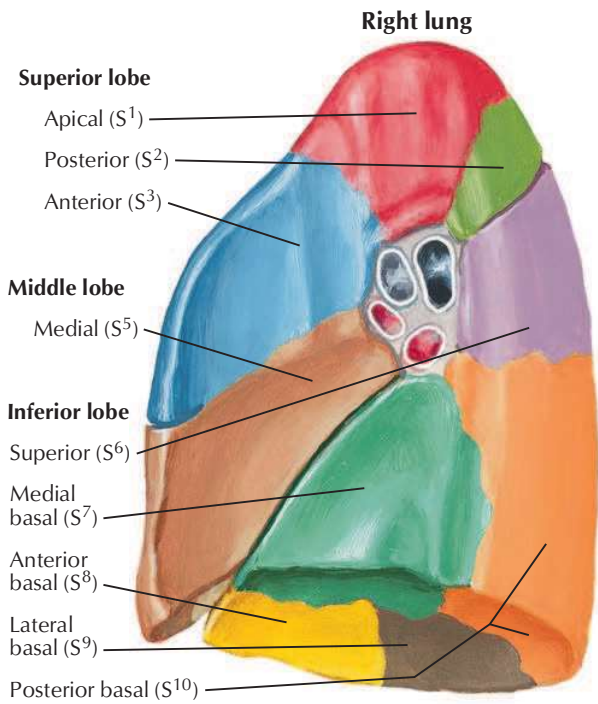


Lateral views



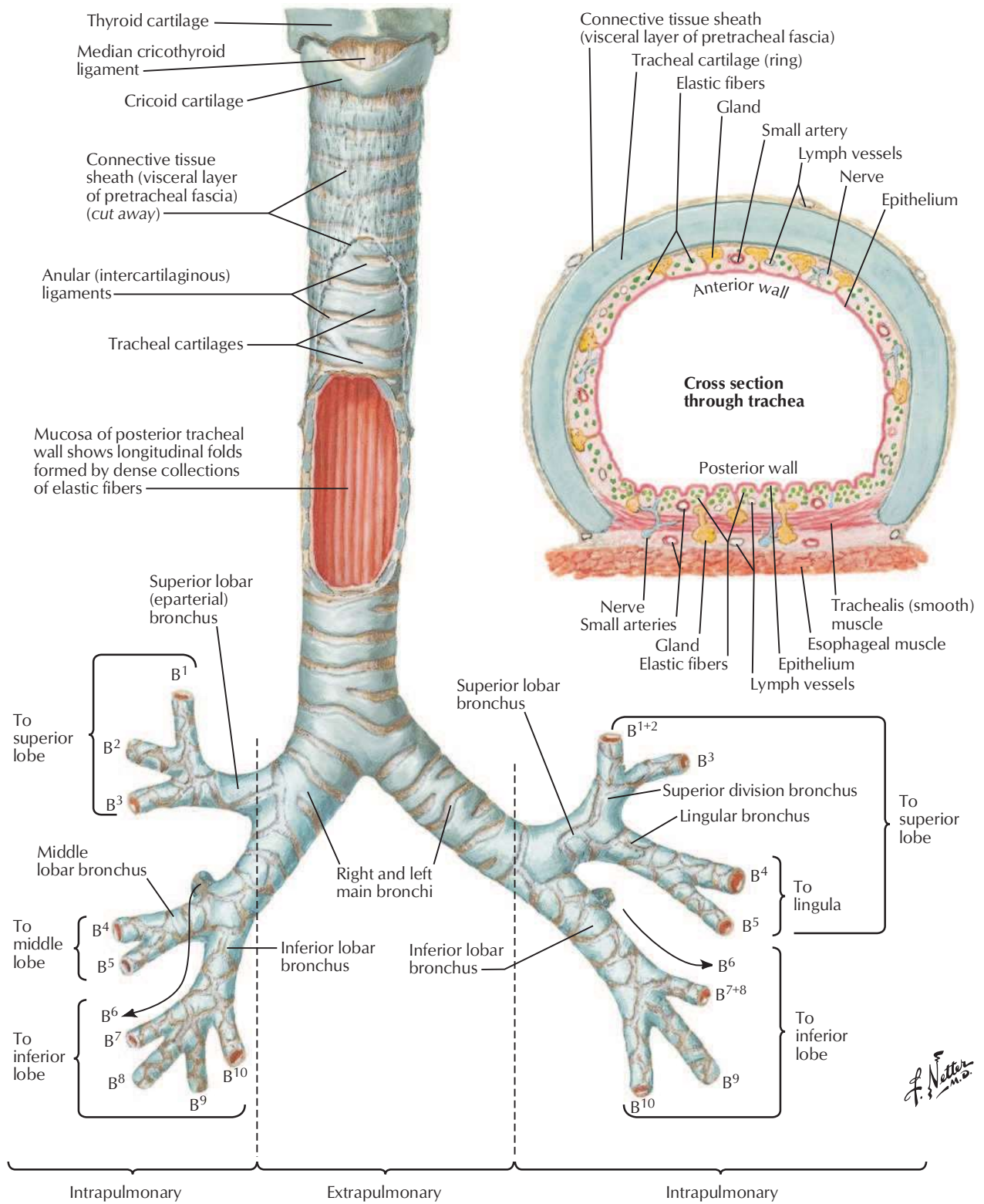
F. Netter M.D.

Medial views

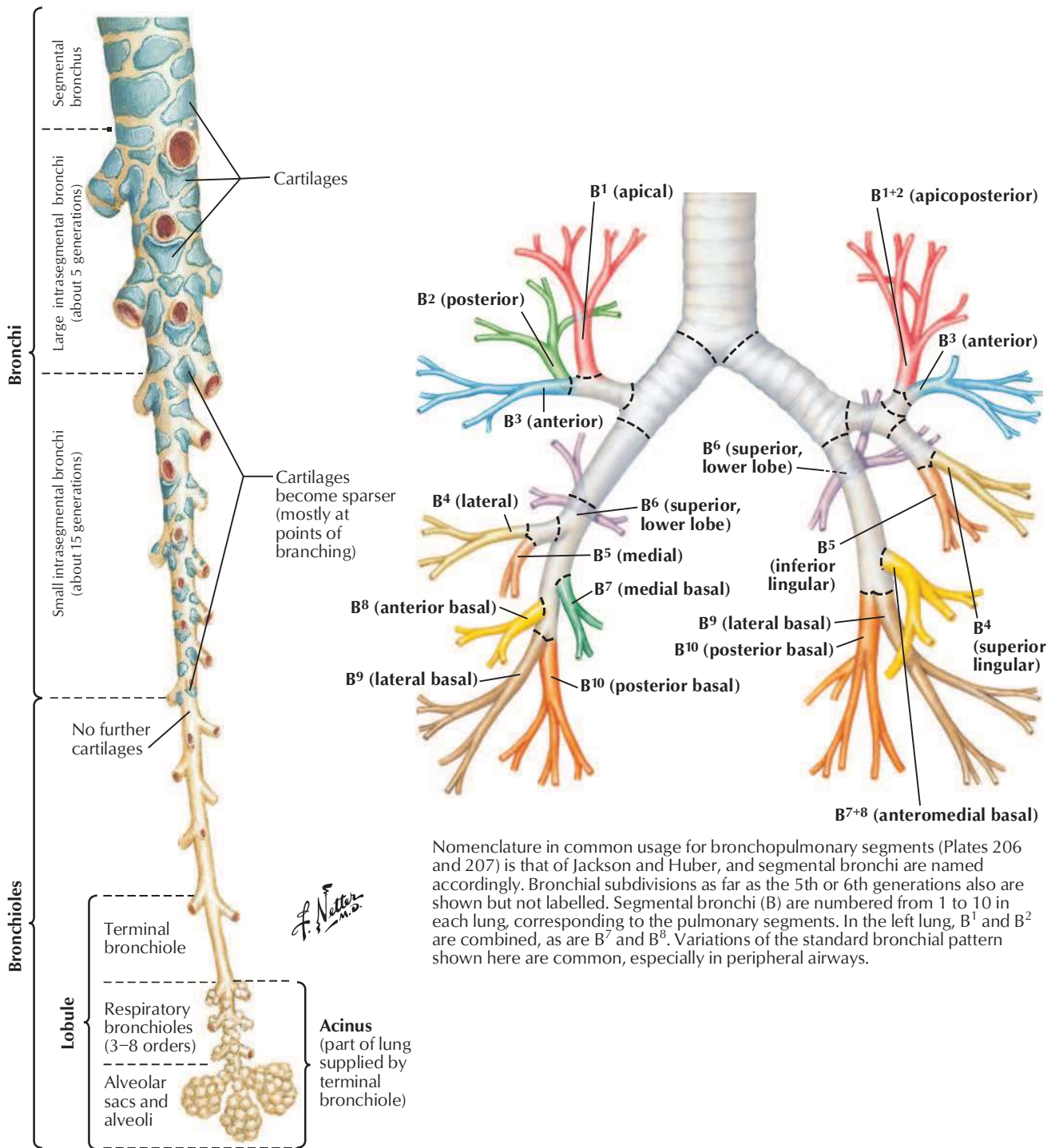


Trachea and Major Bronchi

See also **Plates 81, 211, 214**



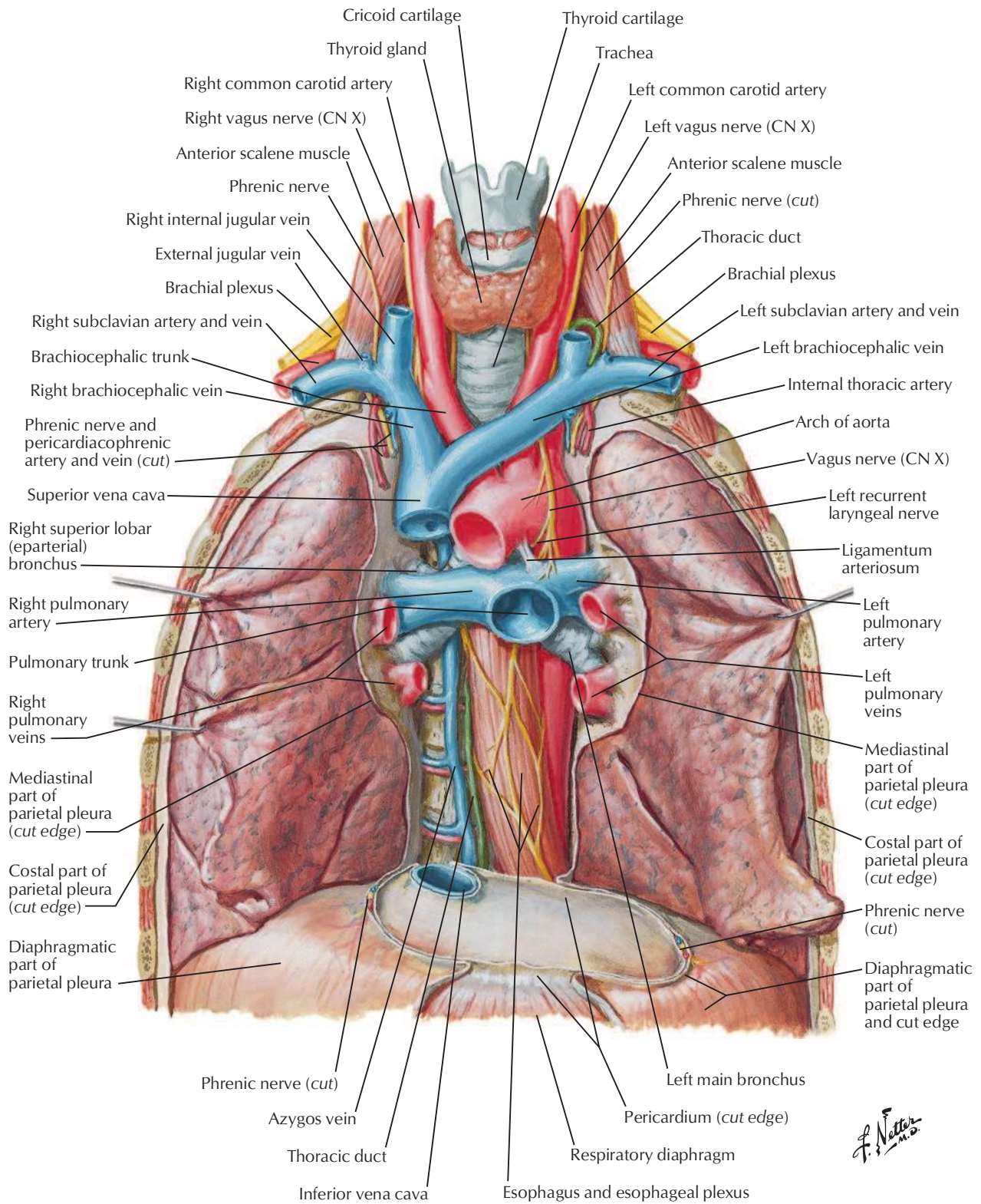
F. Netter M.D.

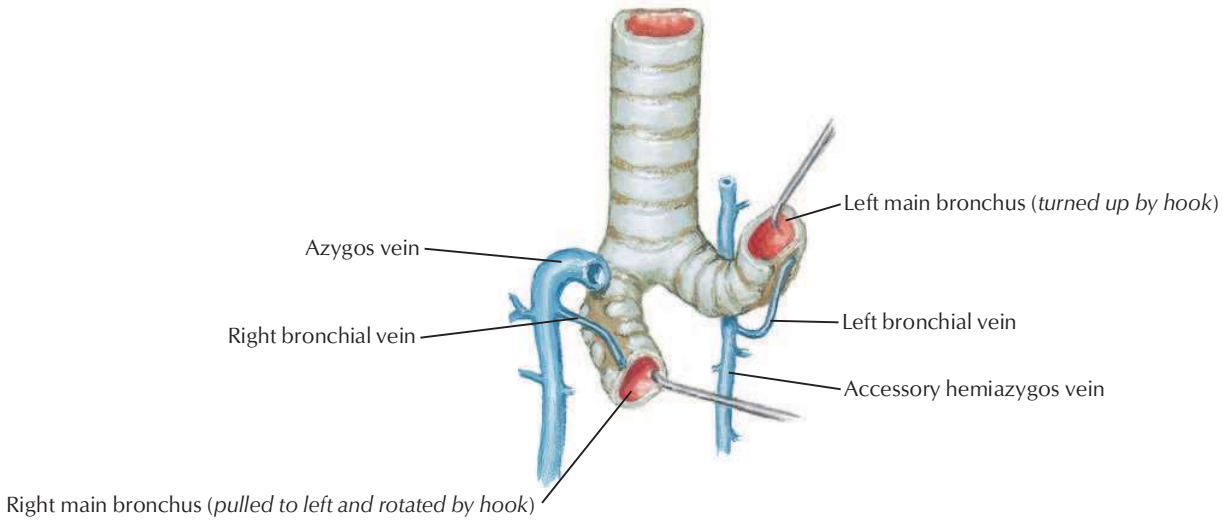
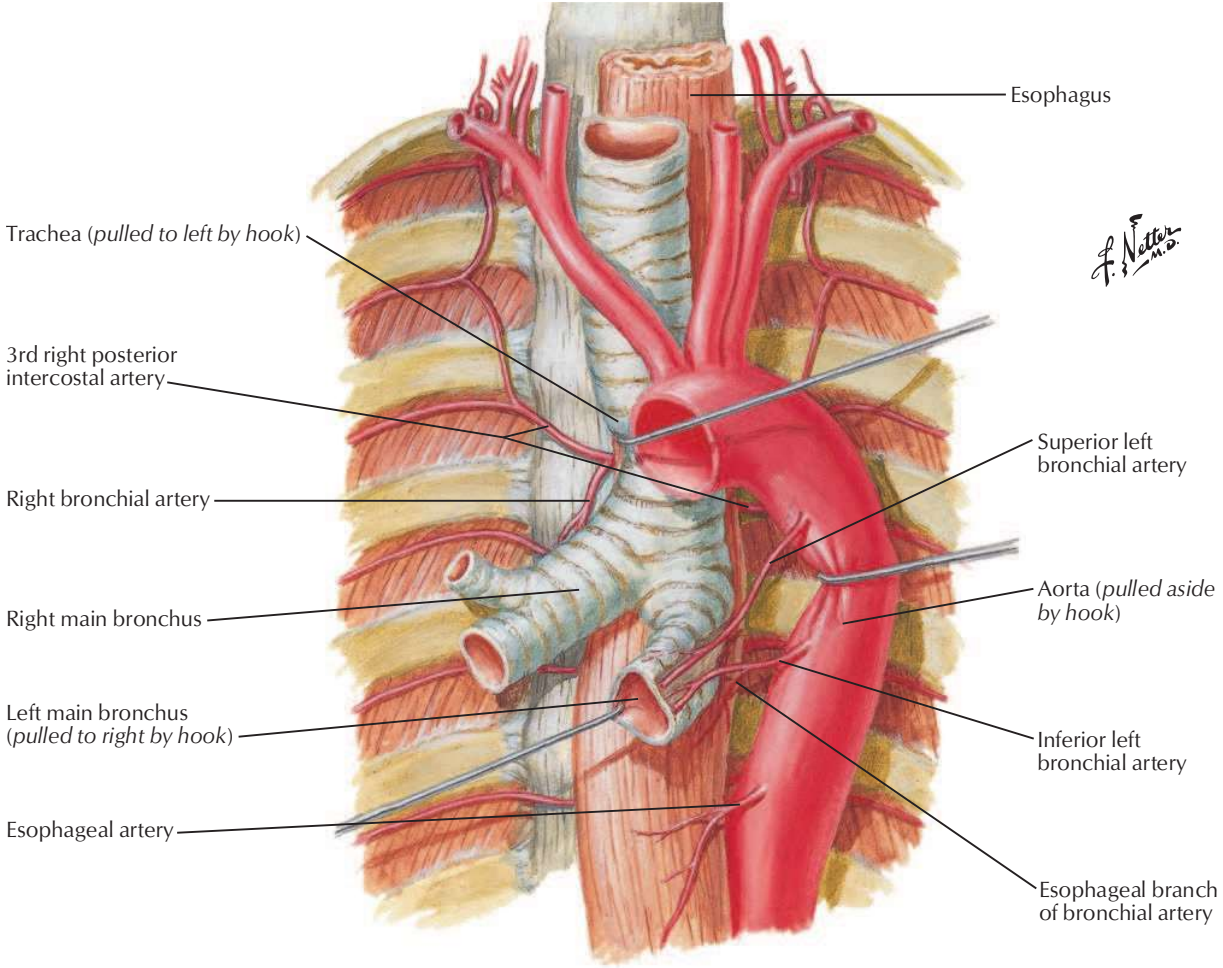


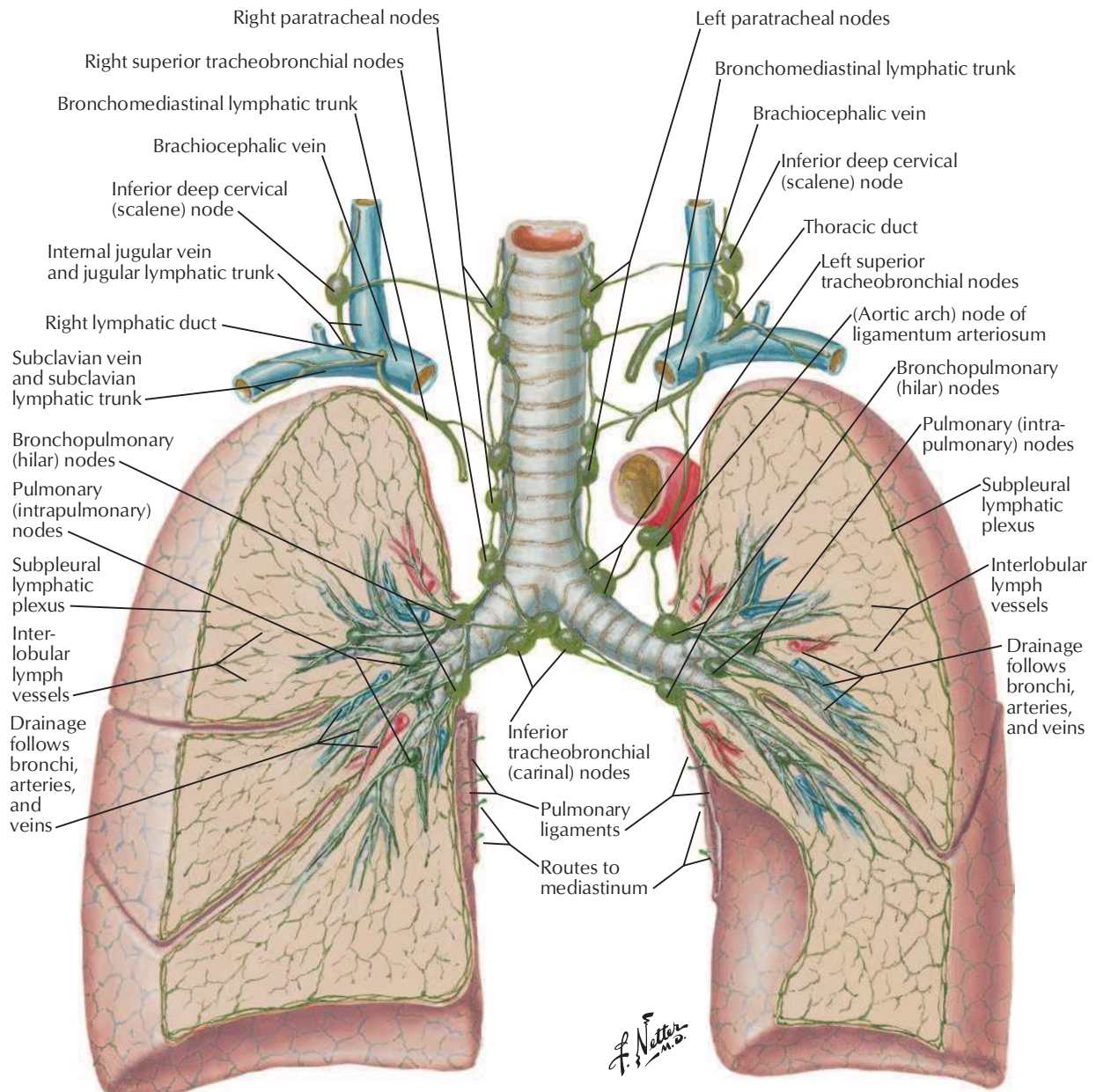
Nomenclature in common usage for bronchopulmonary segments (Plates 206 and 207) is that of Jackson and Huber, and segmental bronchi are named accordingly. Bronchial subdivisions as far as the 5th or 6th generations also are shown but not labelled. Segmental bronchi (B) are numbered from 1 to 10 in each lung, corresponding to the pulmonary segments. In the left lung, B¹ and B² are combined, as are B⁷ and B⁸. Variations of the standard bronchial pattern shown here are common, especially in peripheral airways.

Subdivisions of intrapulmonary airways

Great Vessels of Superior Mediastinum



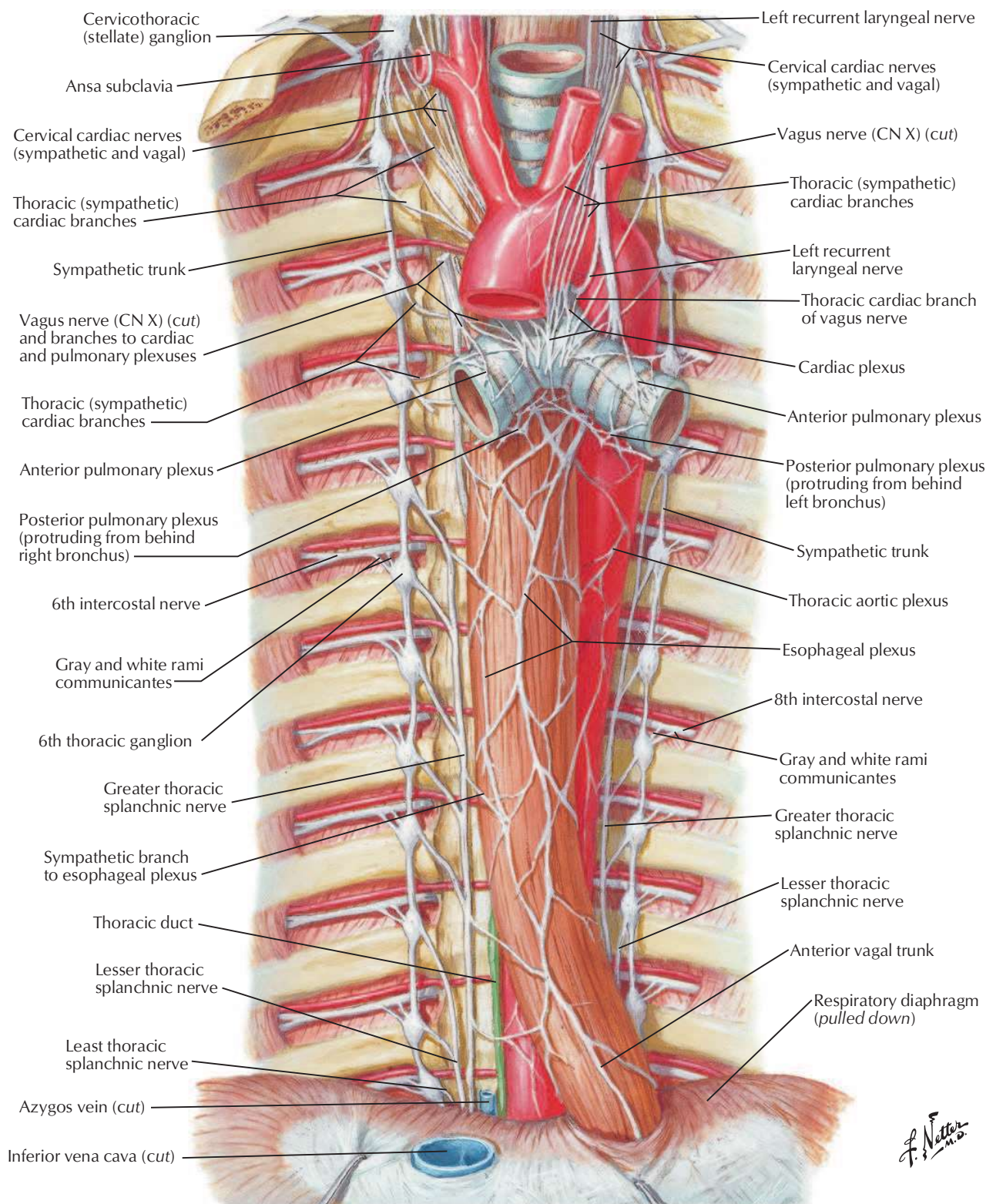




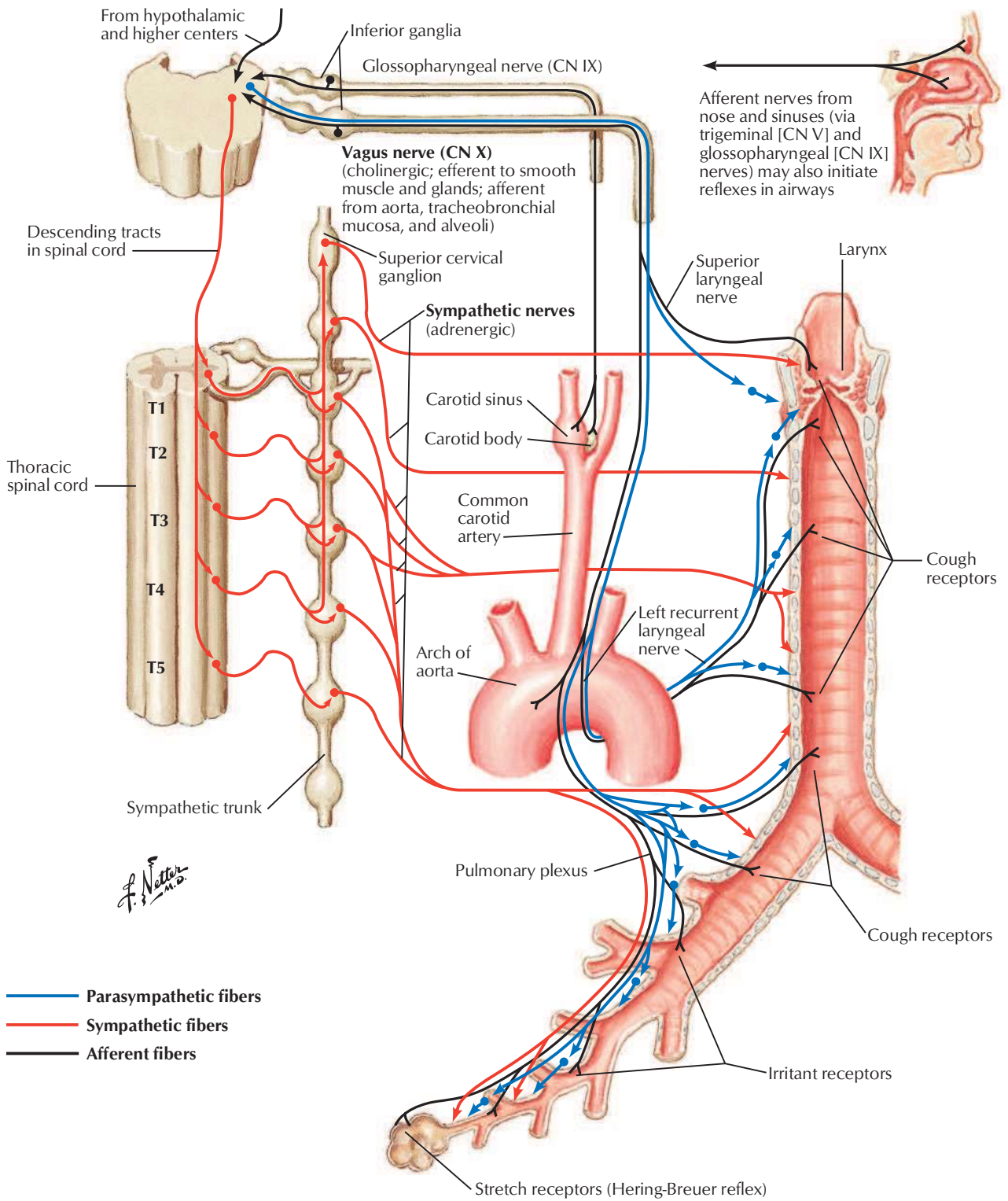
Lymphatic drainage routes

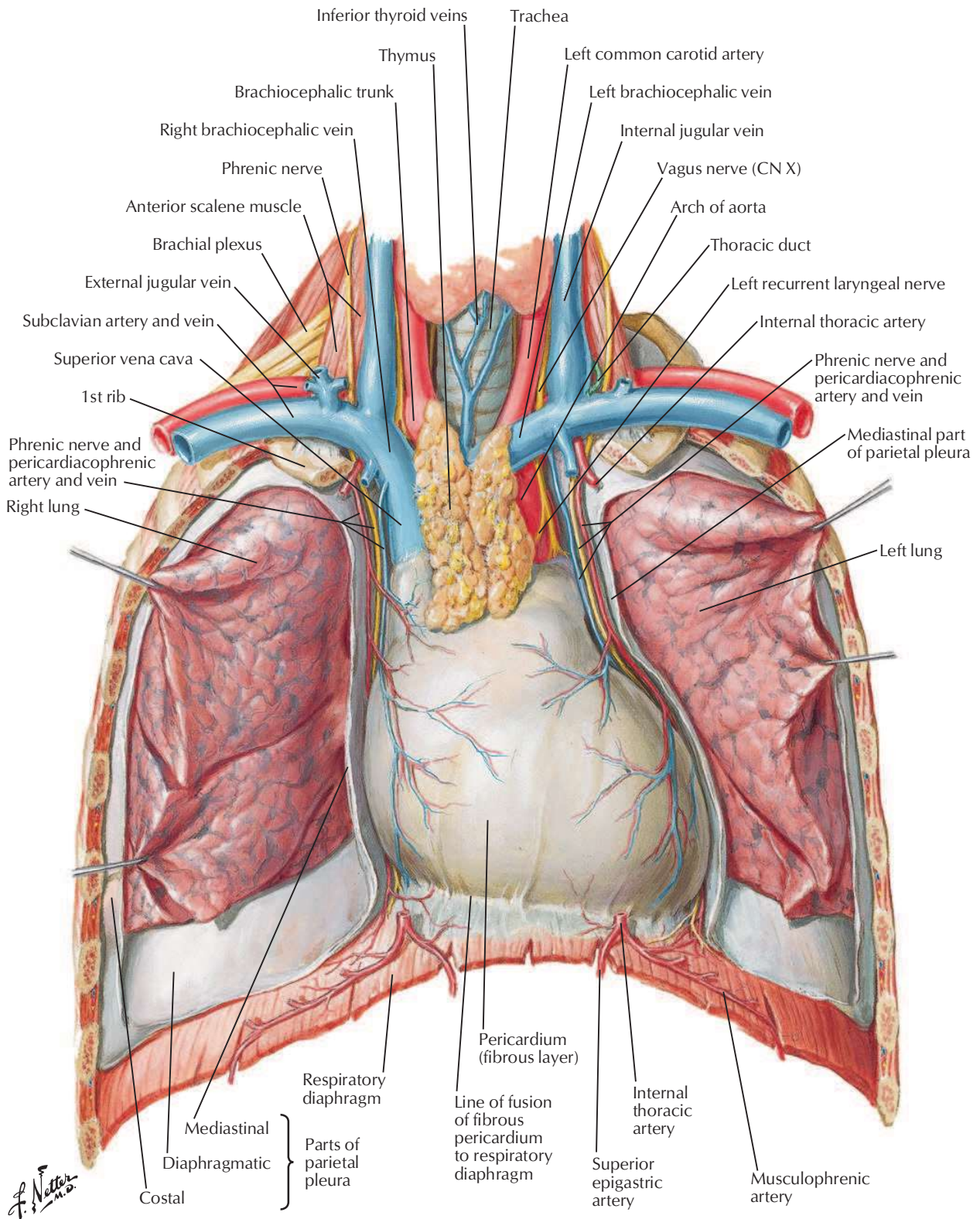
Right lung: All lobes drain to pulmonary and bronchopulmonary (hilar) nodes, then to inferior tracheobronchial (carinal) nodes, right superior tracheobronchial nodes, and right paratracheal nodes on the way to the brachiocephalic vein via the bronchomediastinal lymphatic trunk and/or inferior deep cervical (scalene) node.

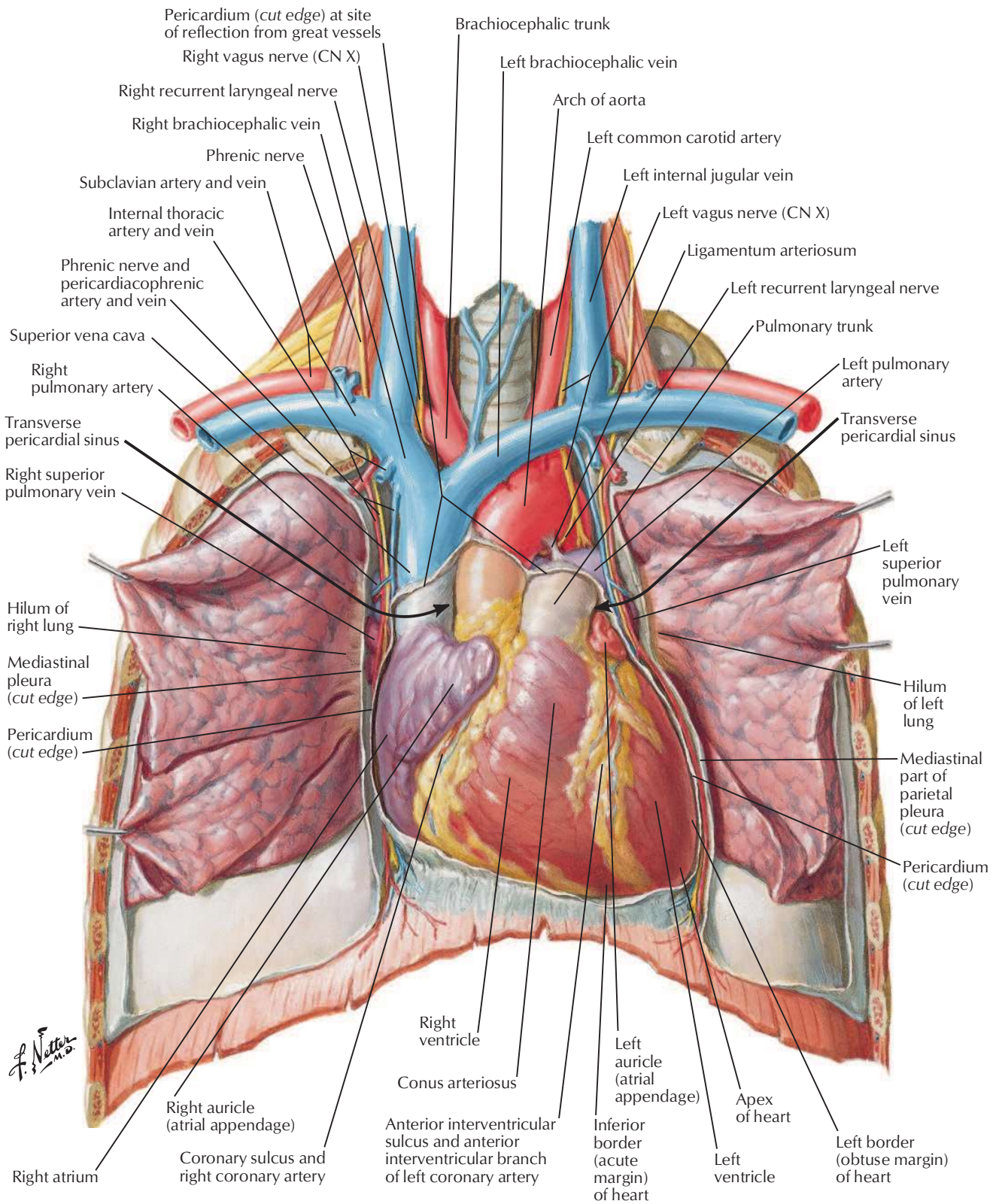
Left lung: The superior lobe drains to pulmonary and bronchopulmonary (hilar) nodes, inferior tracheobronchial (carinal) nodes, left superior tracheobronchial nodes, left paratracheal nodes and/or (aortic arch) node of ligamentum arteriosum, then to the brachiocephalic vein via the left bronchomediastinal trunk and thoracic duct. The left inferior lobe also drains to the pulmonary and bronchopulmonary (hilar) nodes and to inferior tracheobronchial (carinal) nodes, but then mostly to right superior tracheobronchial nodes, where it follows the same route as lymph from the right lung.



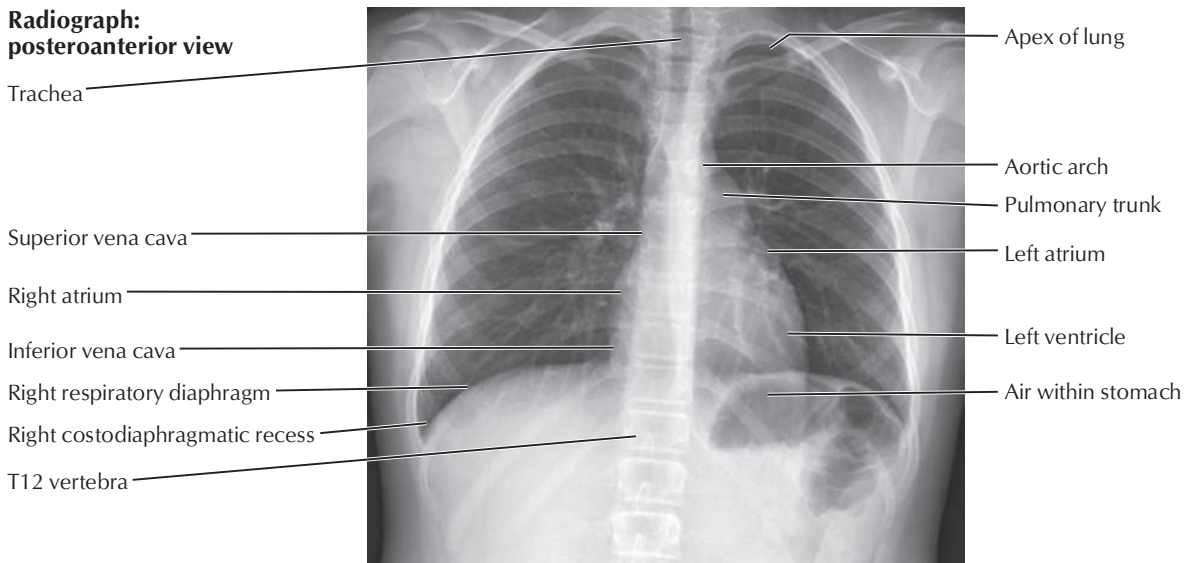
Innervation of Tracheobronchial Tree: Schema



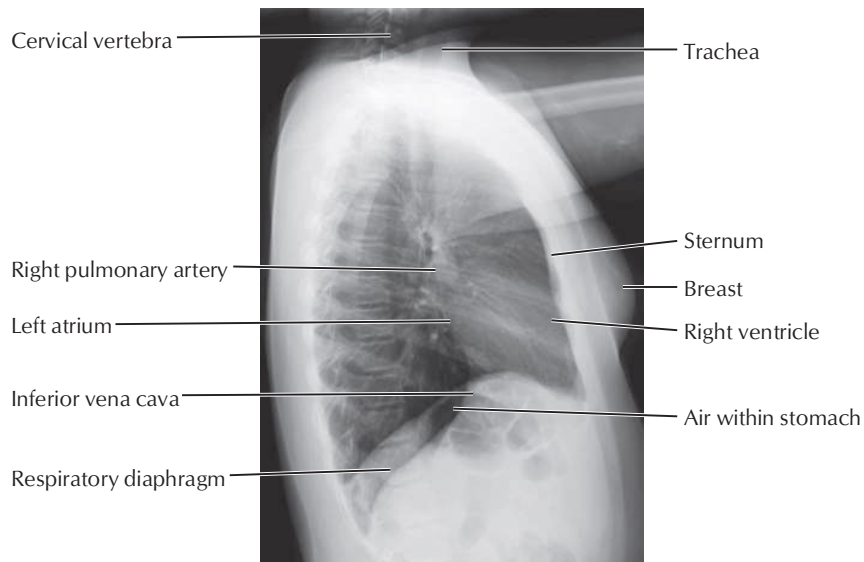




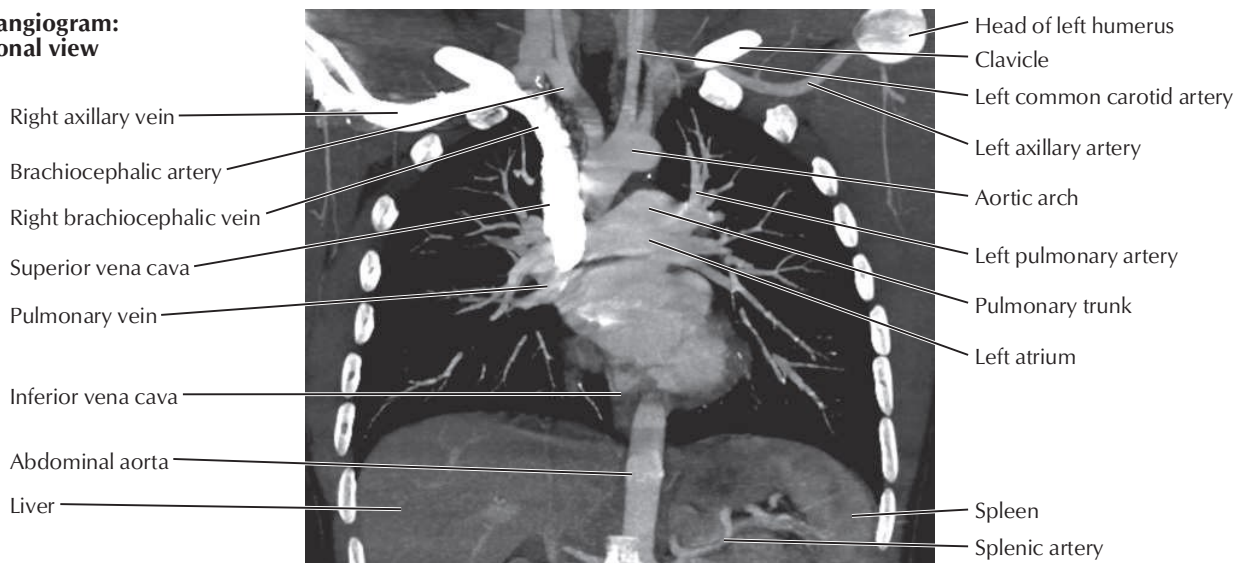
**Radiograph:
posteroanterior view**

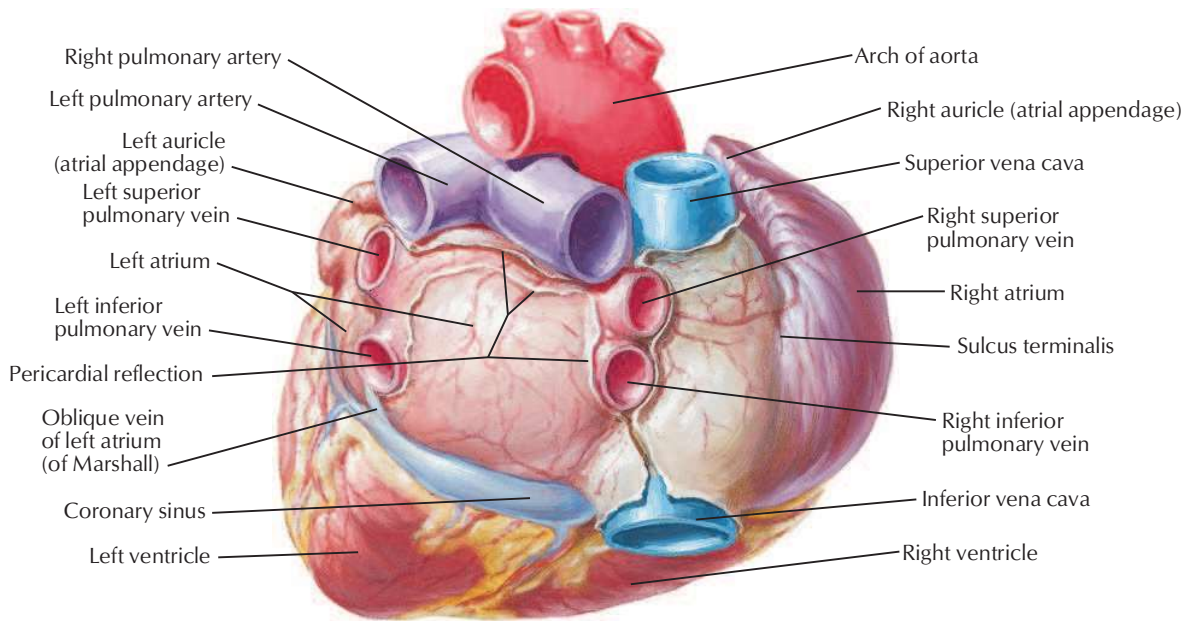


**Radiograph:
lateral view**

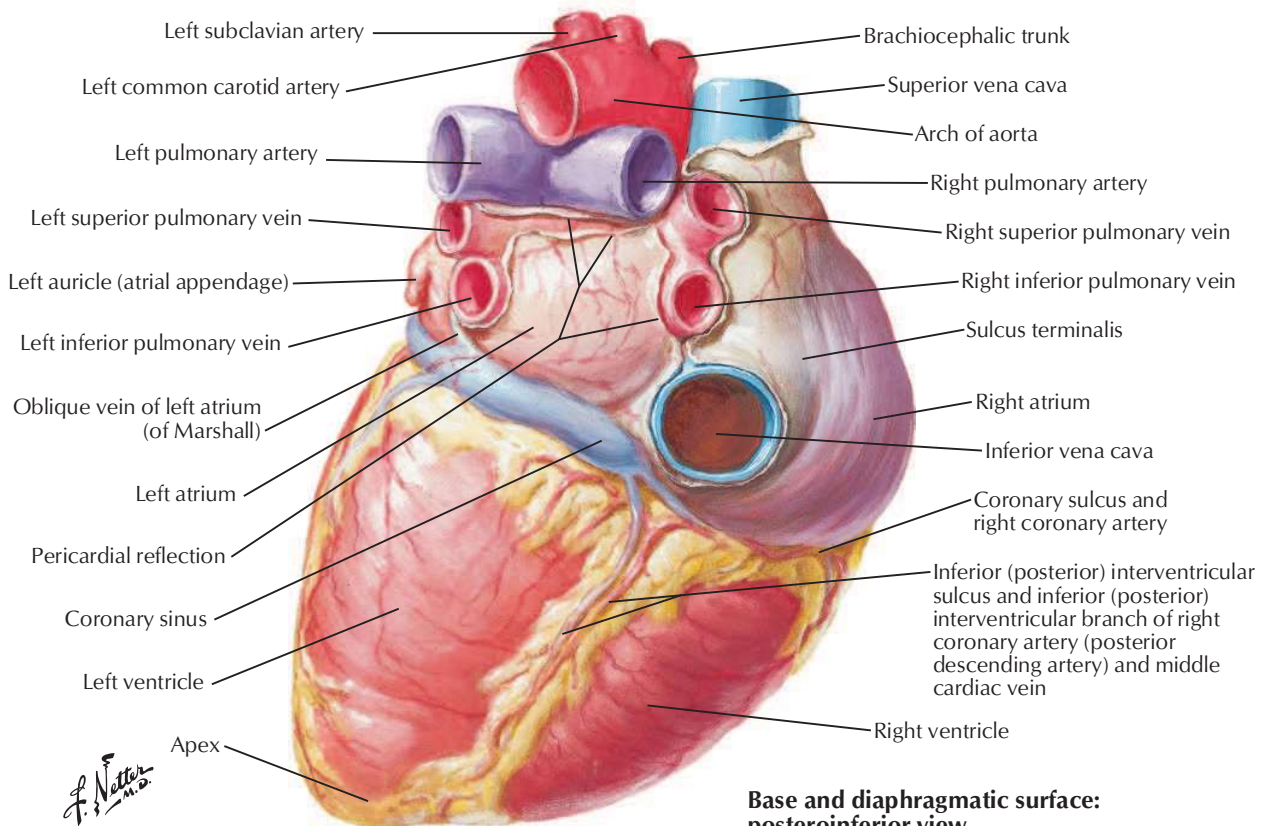


**CT angiogram:
coronal view**

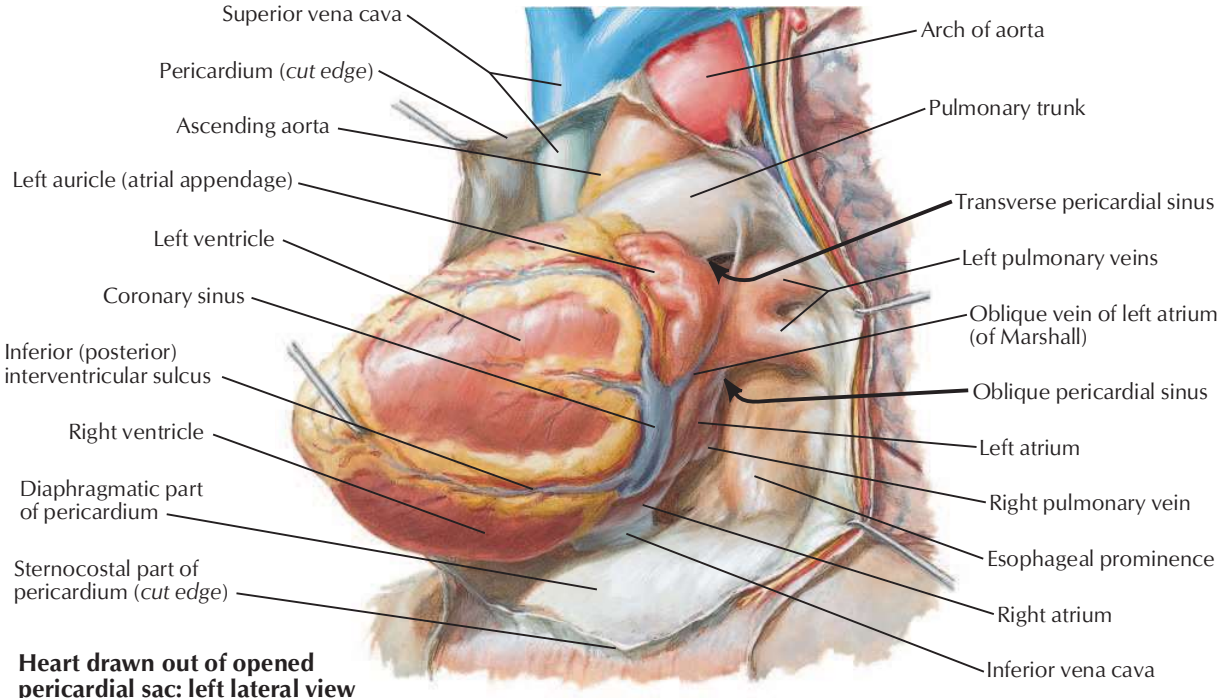




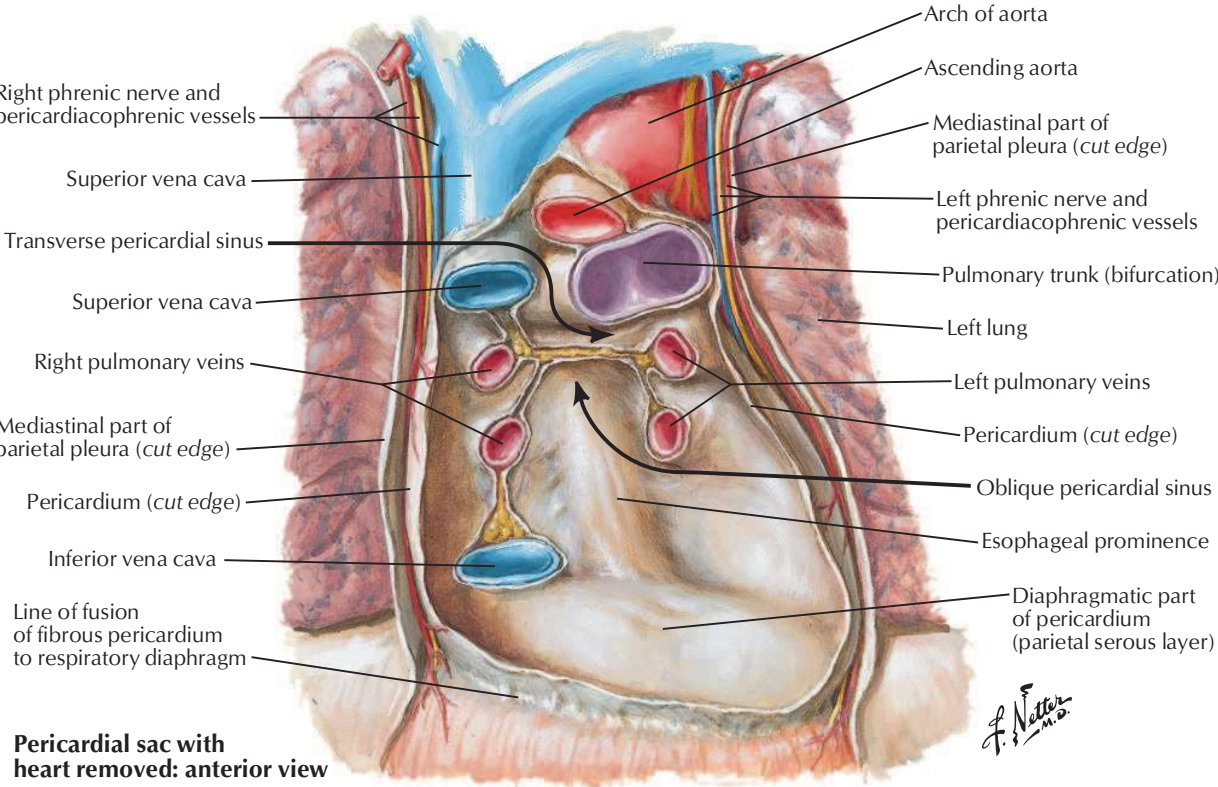
Base of heart: posterior view



Base and diaphragmatic surface: posteroinferior view



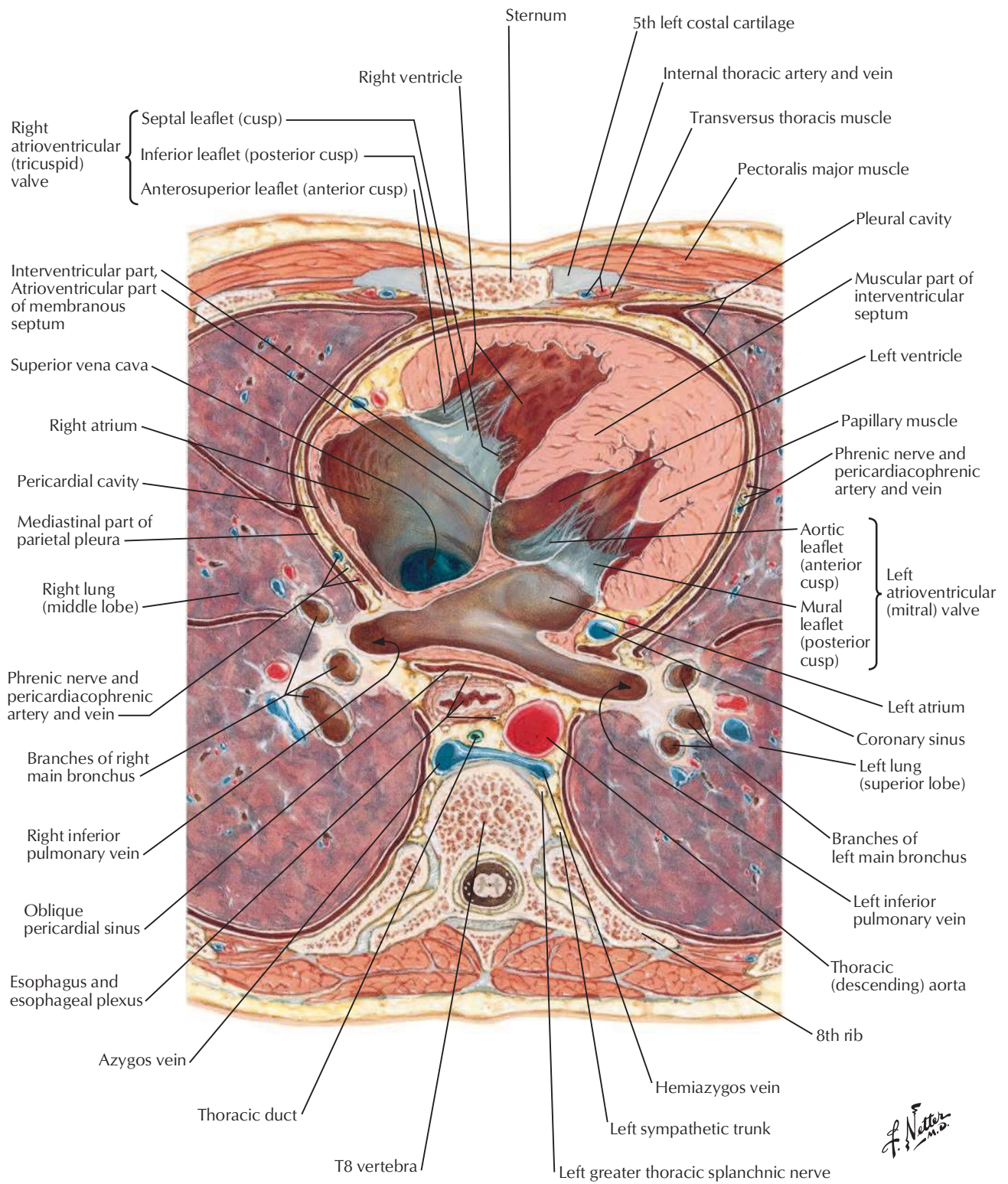
Heart drawn out of opened pericardial sac: left lateral view

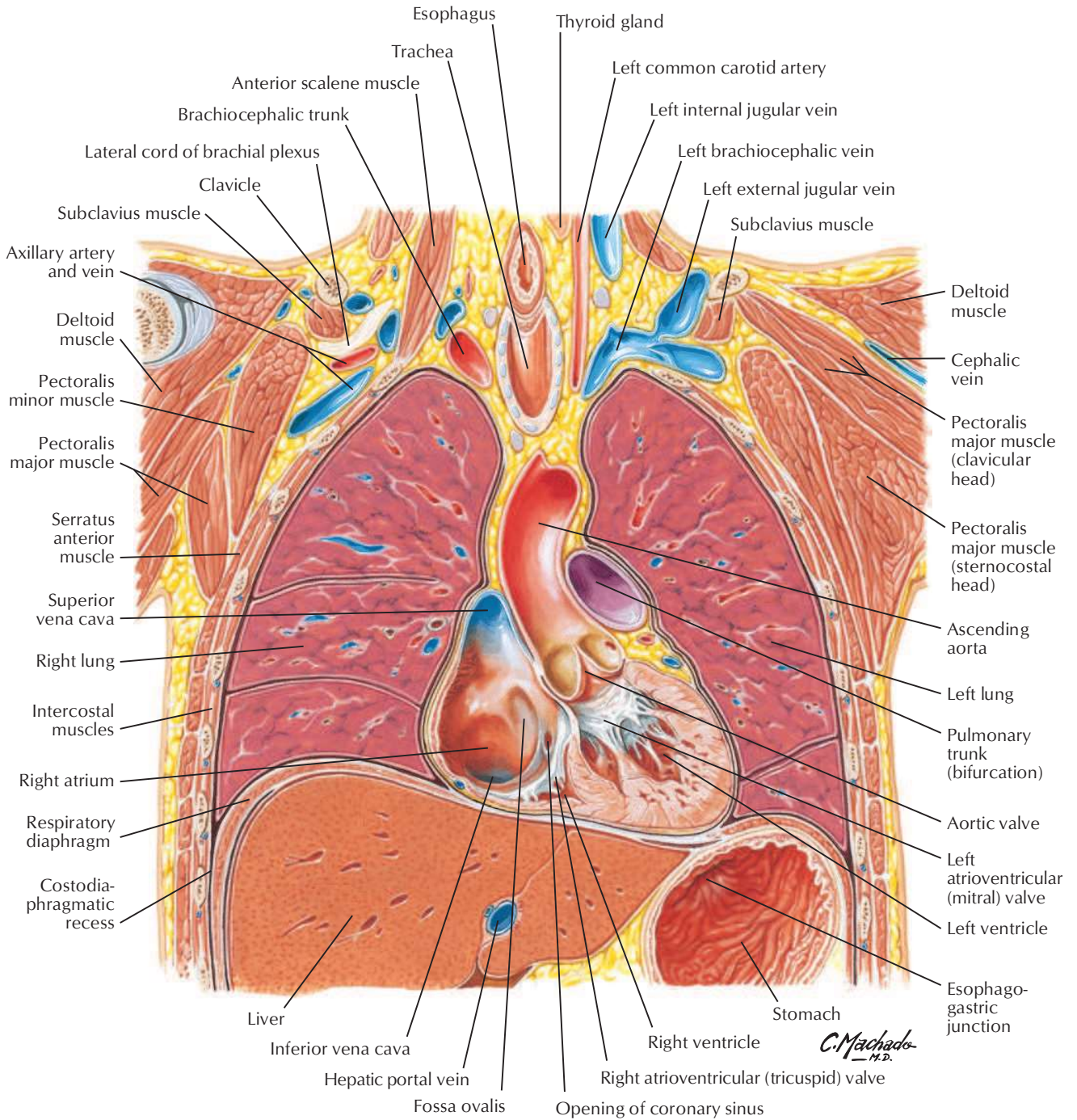


Pericardial sac with heart removed: anterior view

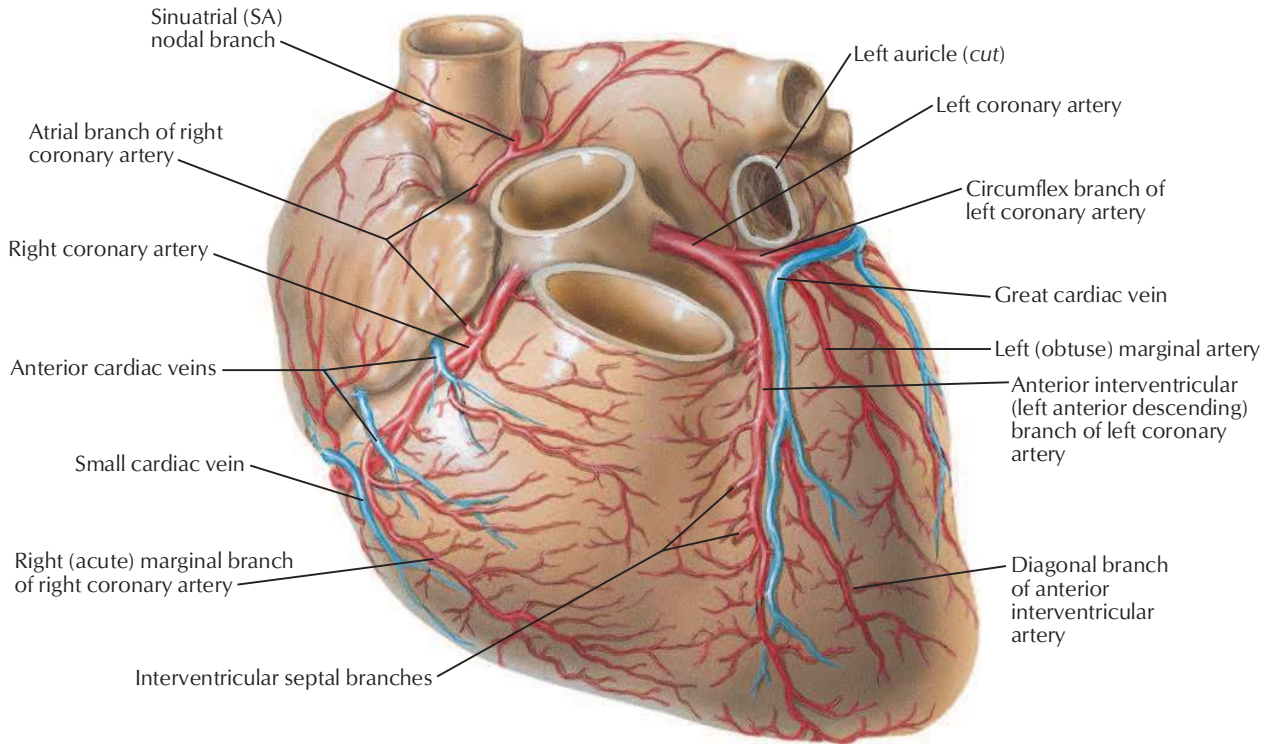
F. Netter M.D.

Mediastinum: Cross Section

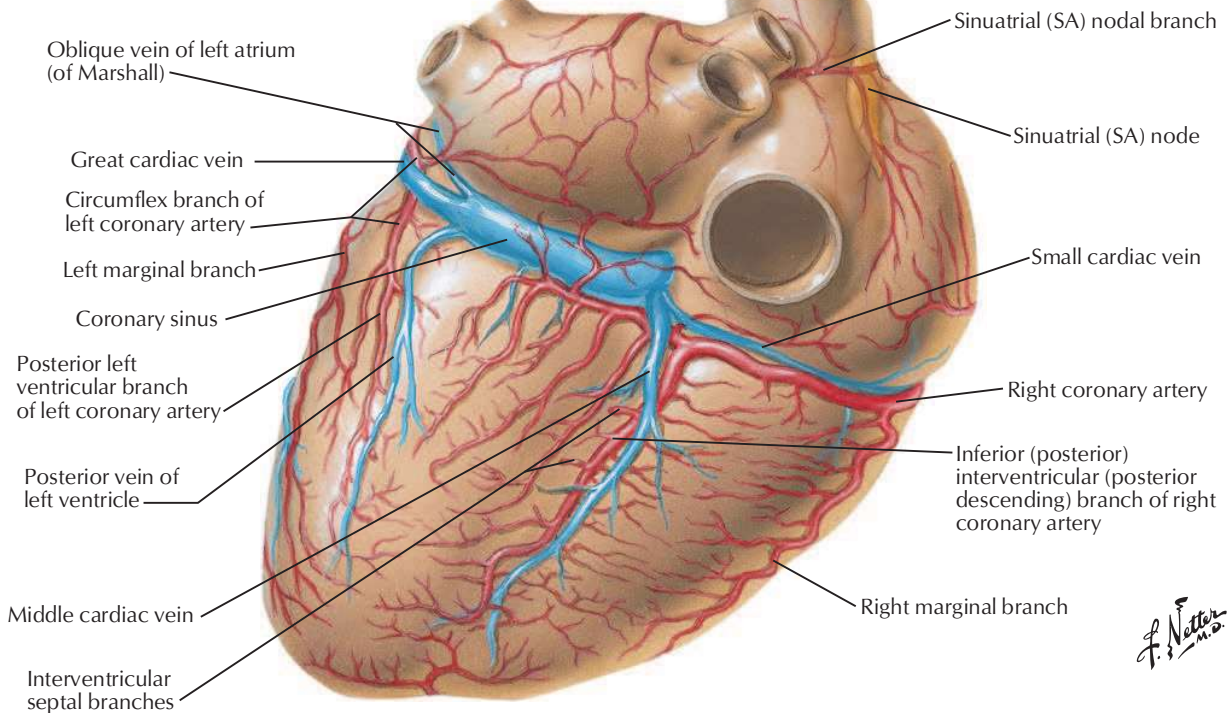


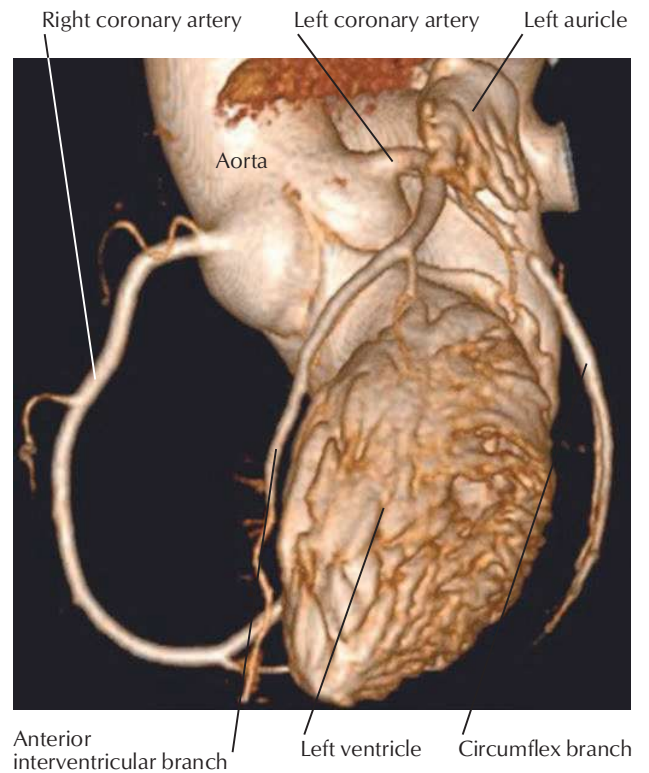
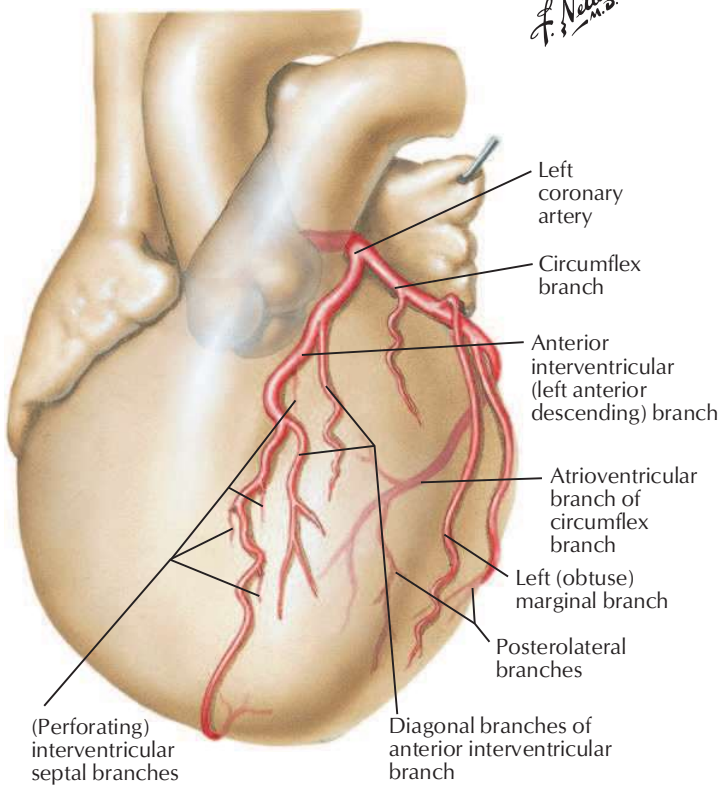
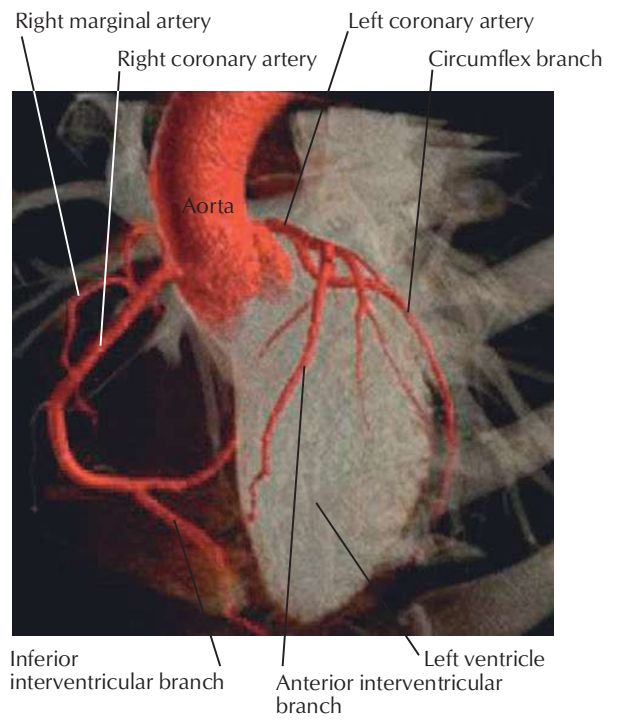
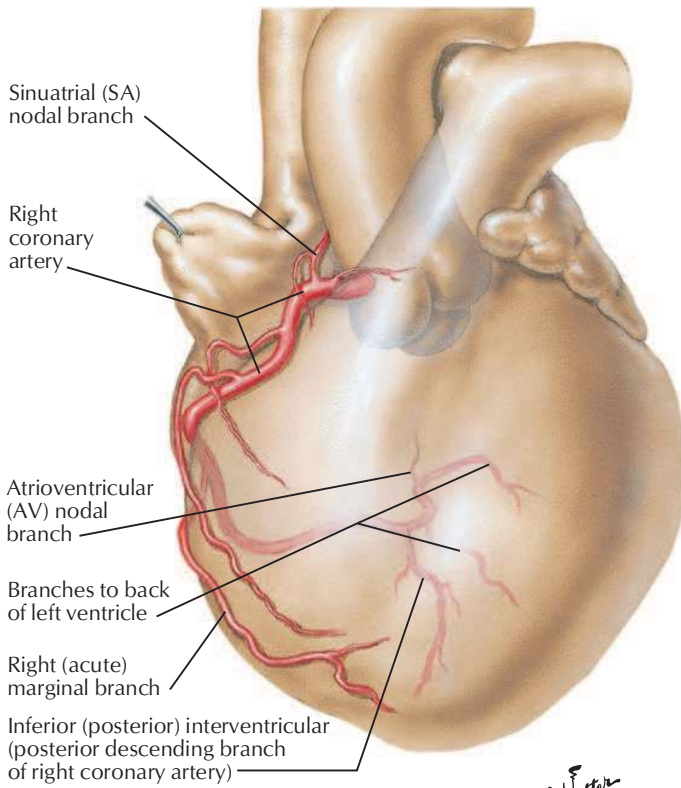


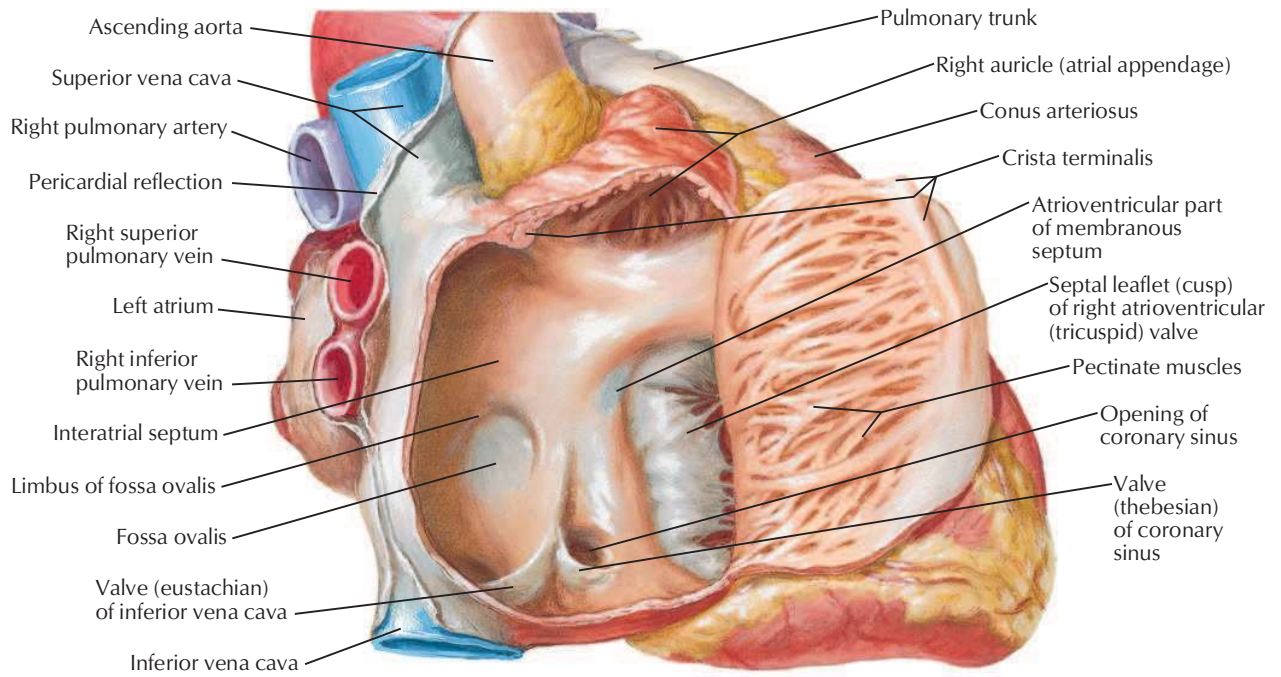
Sternocostal surface



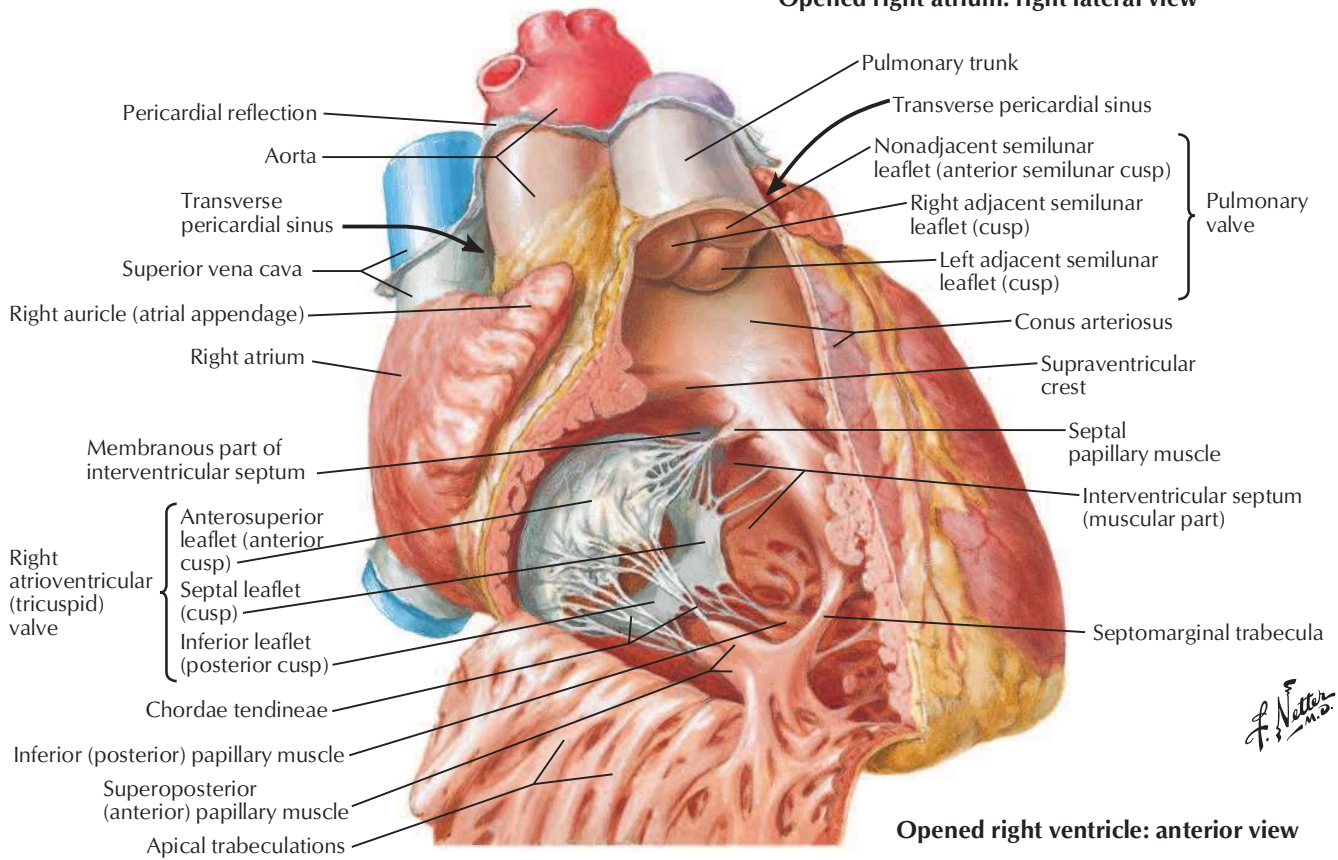
Diaphragmatic surface



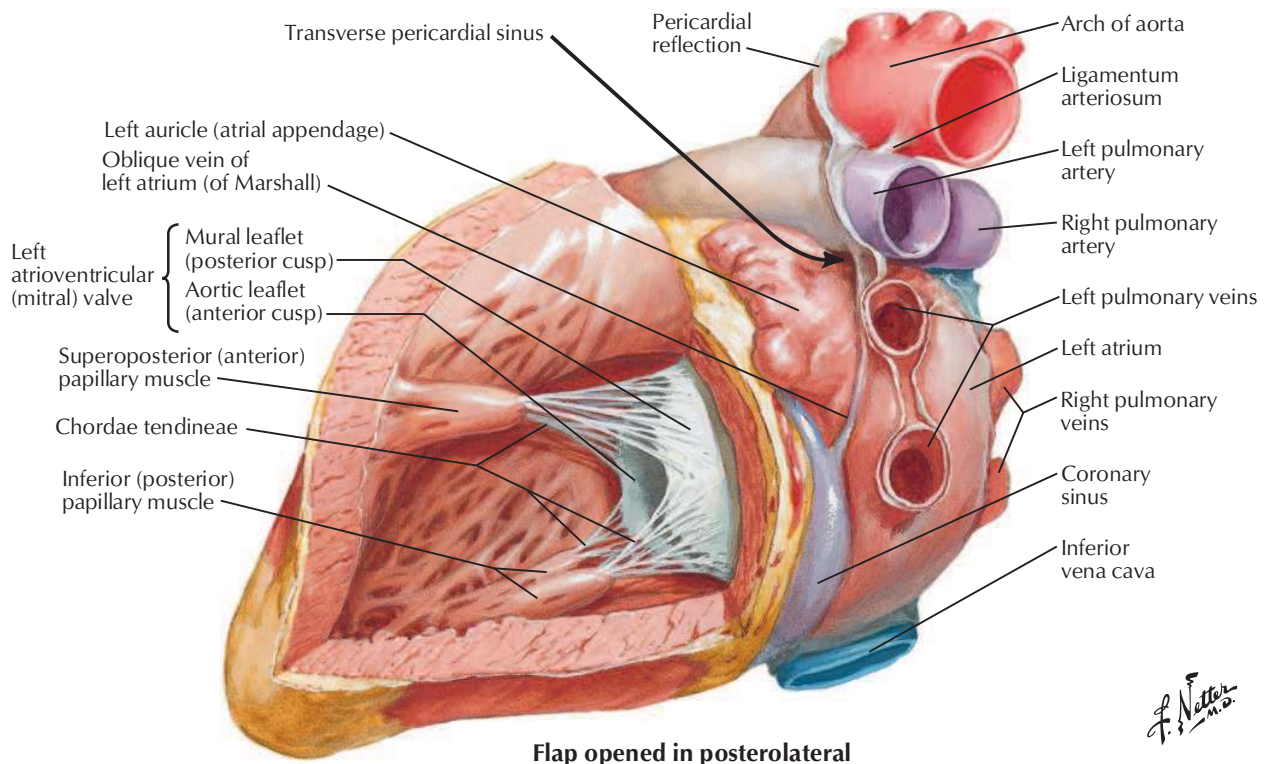




Opened right atrium: right lateral view

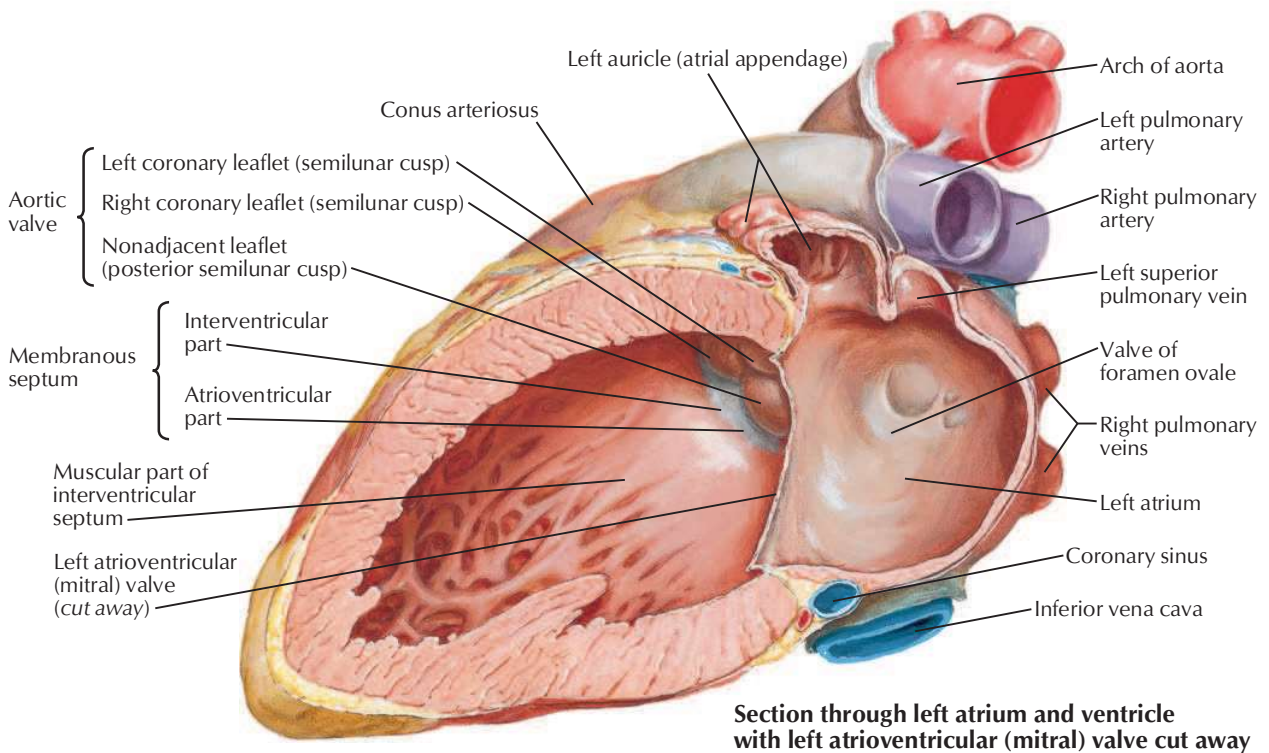


Opened right ventricle: anterior view

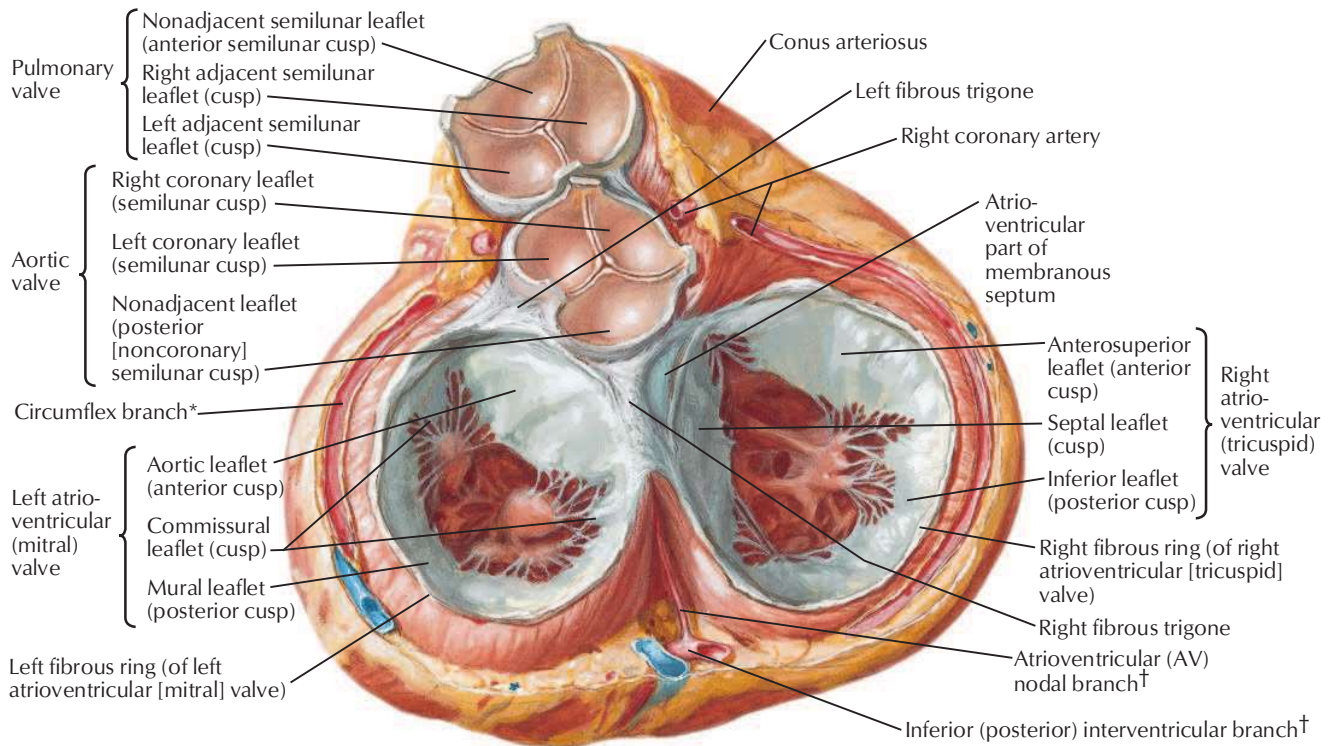


Flap opened in posterolateral wall of left ventricle

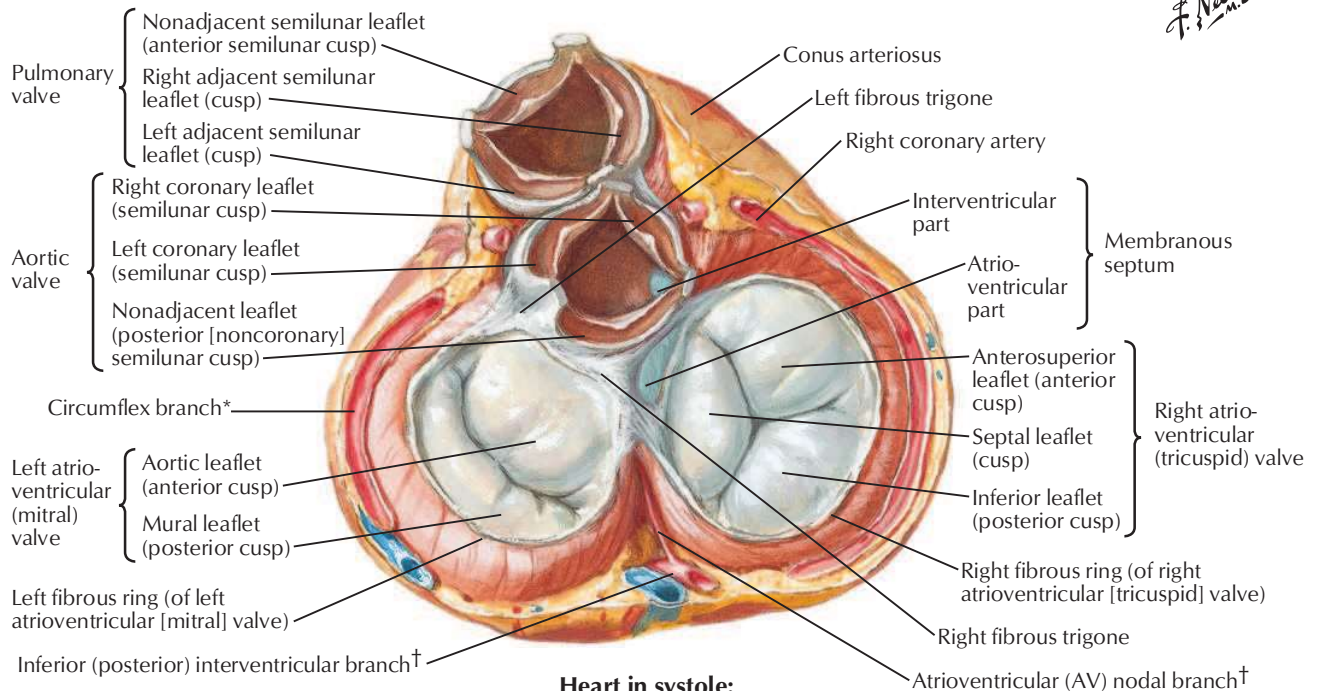
F. Netter M.D.



Section through left atrium and ventricle with left atrioventricular (mitral) valve cut away

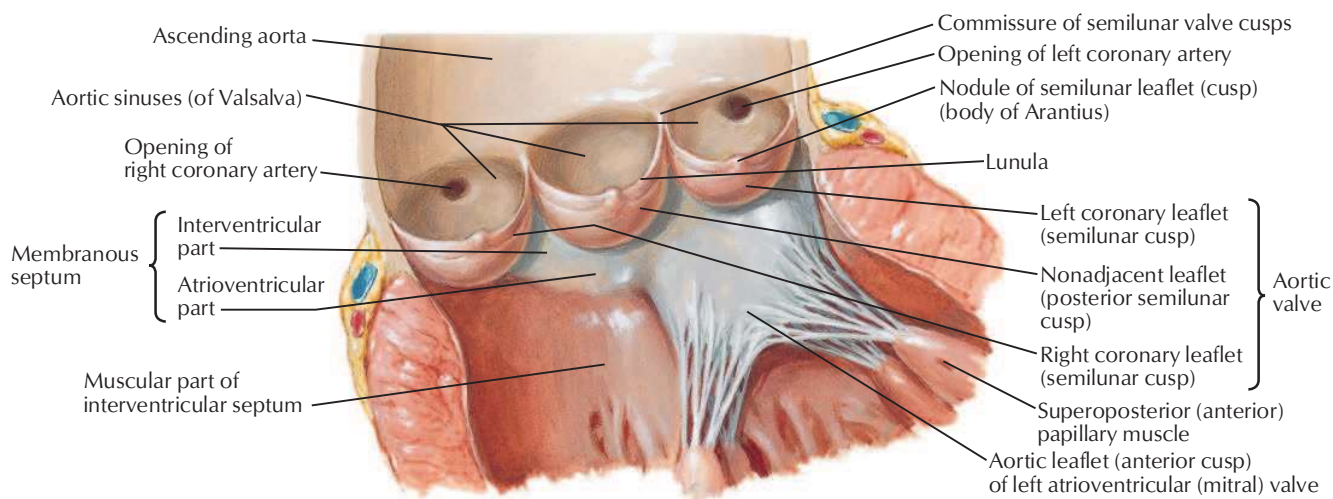


**Heart in diastole:
viewed from base with atria removed**

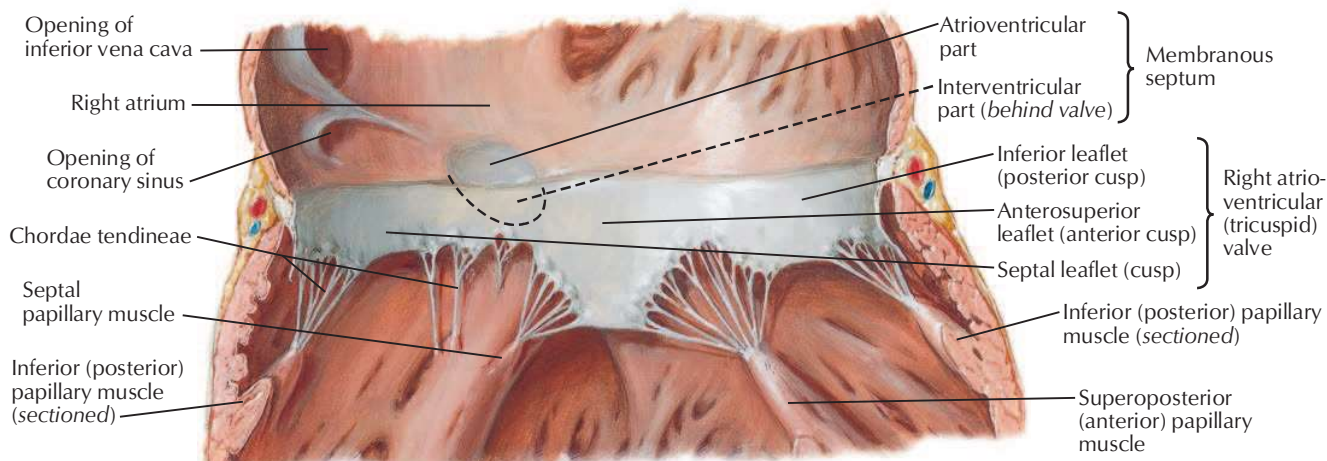


**Heart in systole:
viewed from base with atria removed**


*Of left coronary artery
†Of right coronary artery



Aortic valve



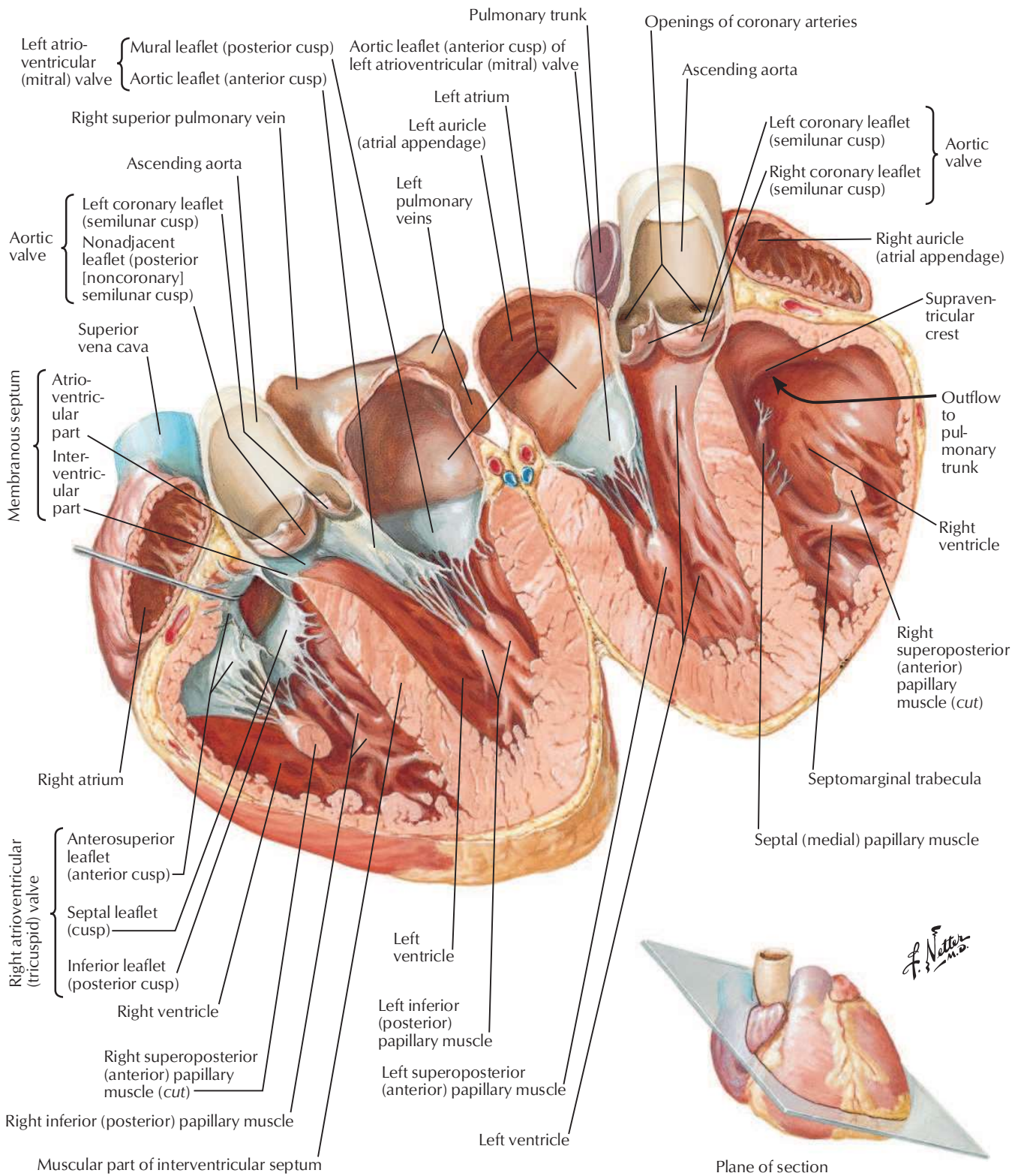
Right atrioventricular (tricuspid) valve



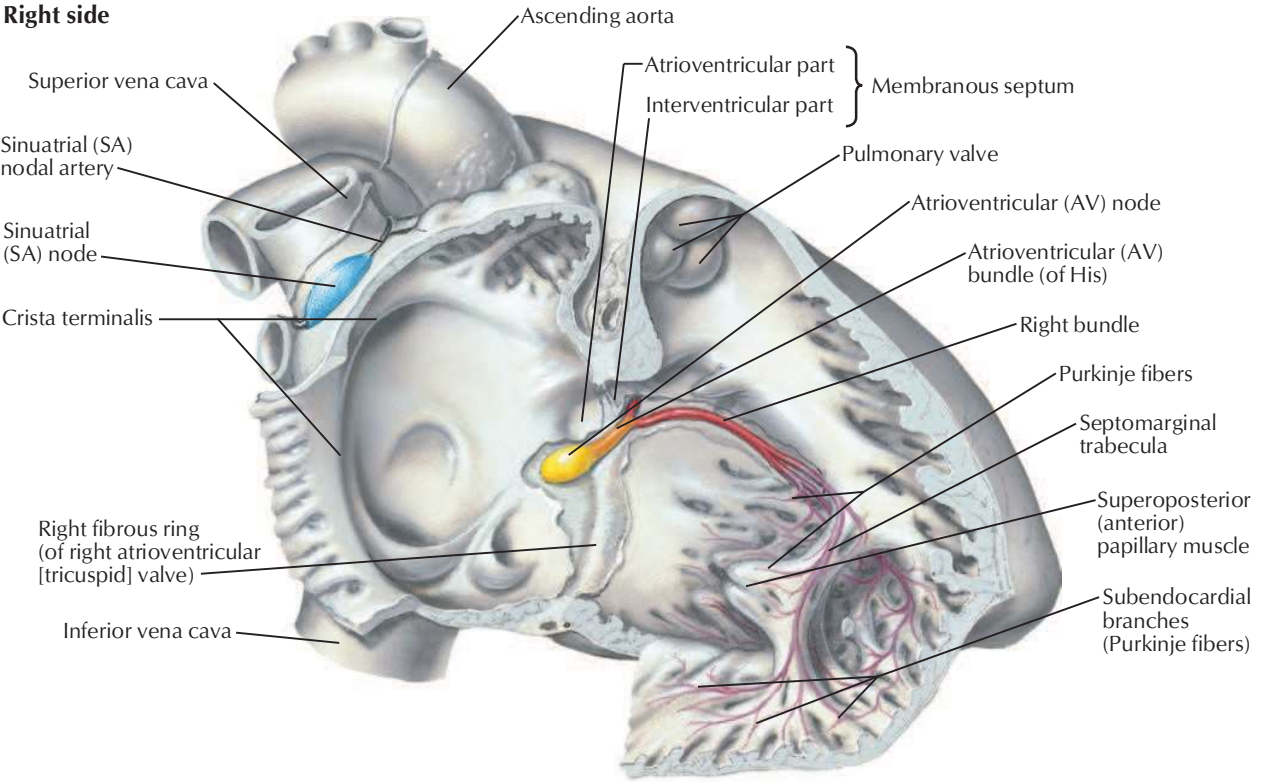
Left atrioventricular (mitral) valve

F. Netter M.D.

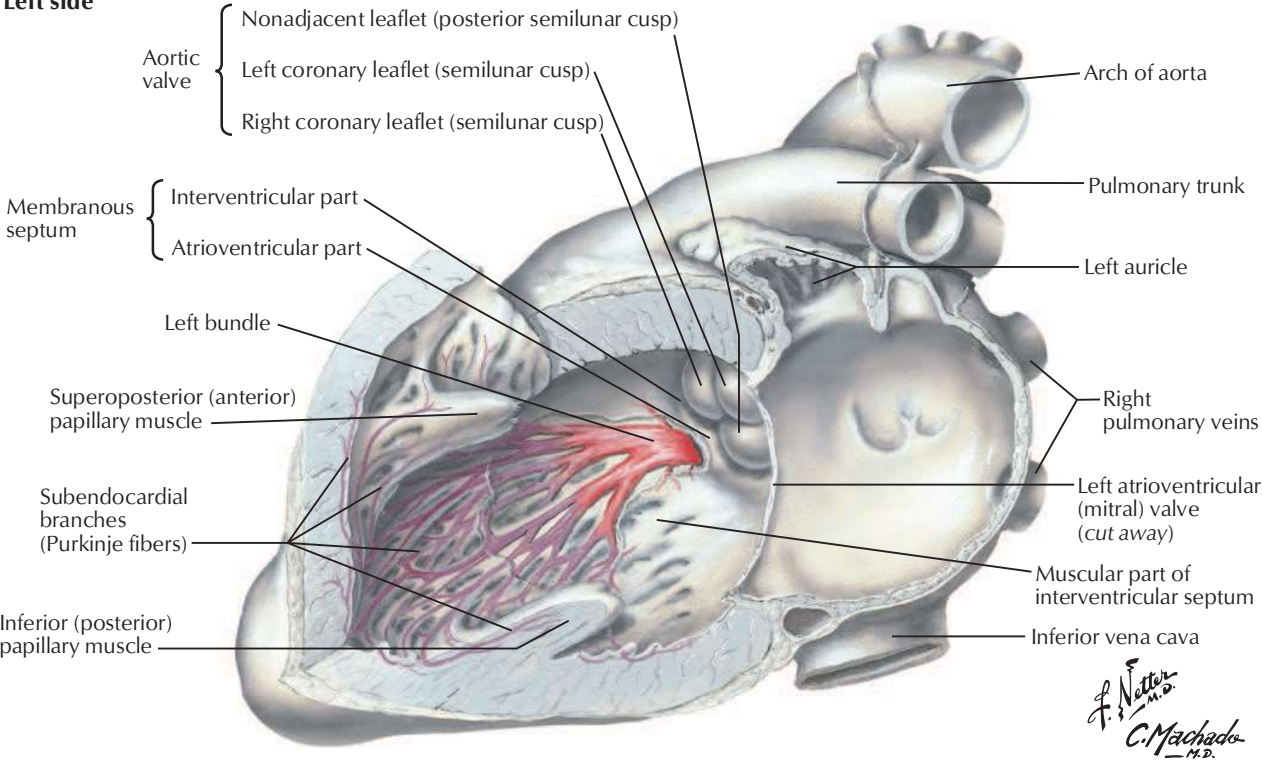
Atria, Ventricles, and Interventricular Septum



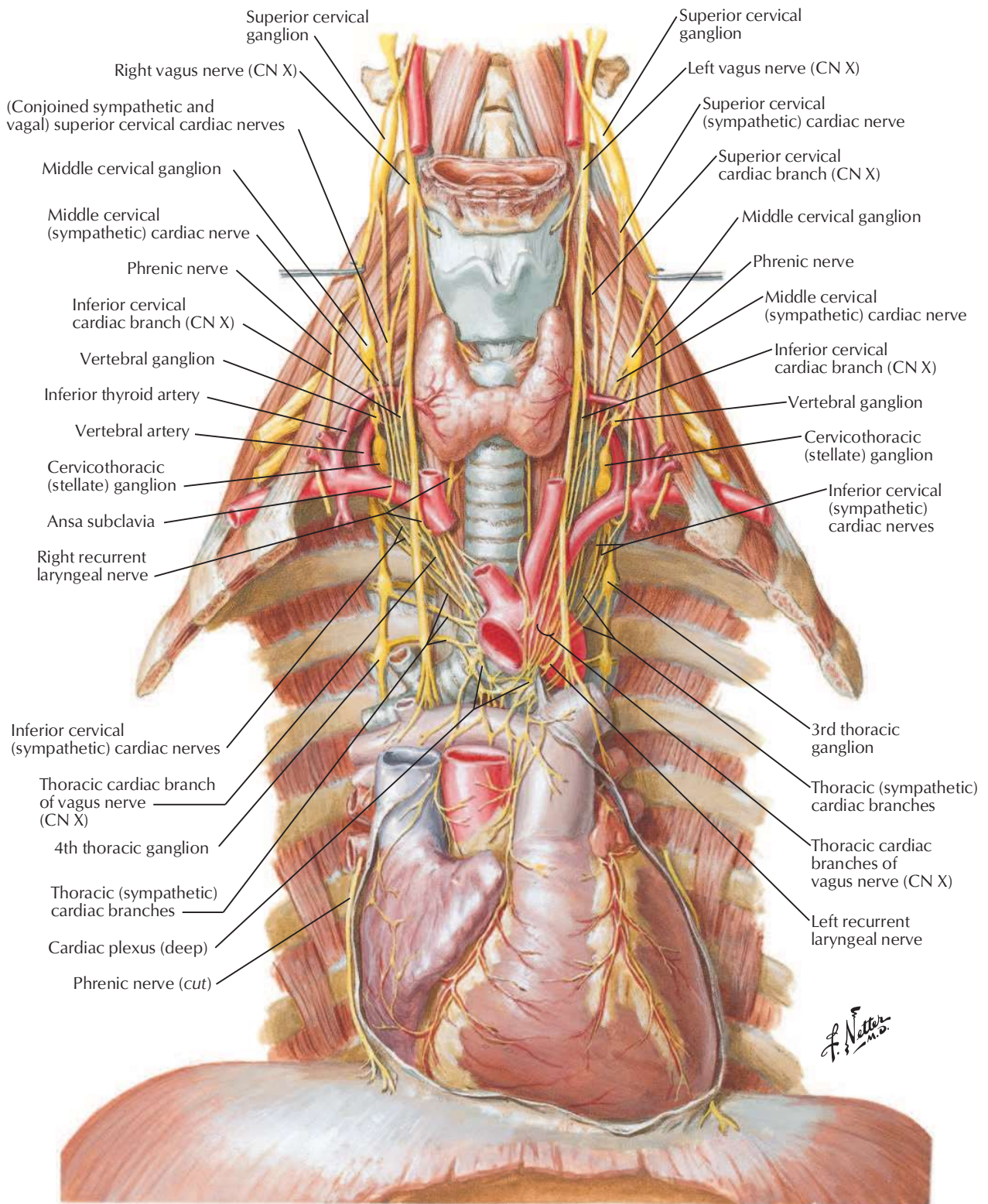
Right side

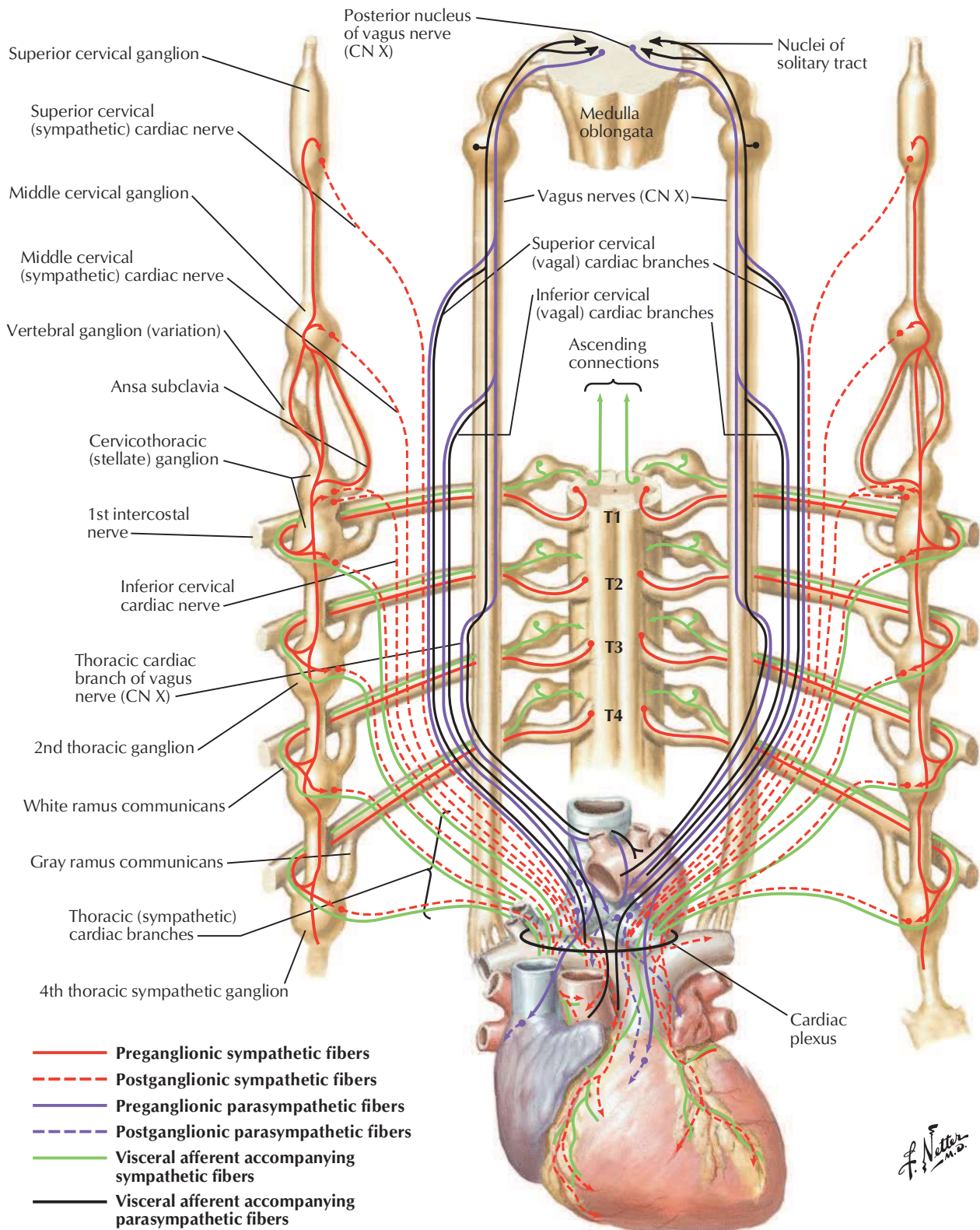


Left side

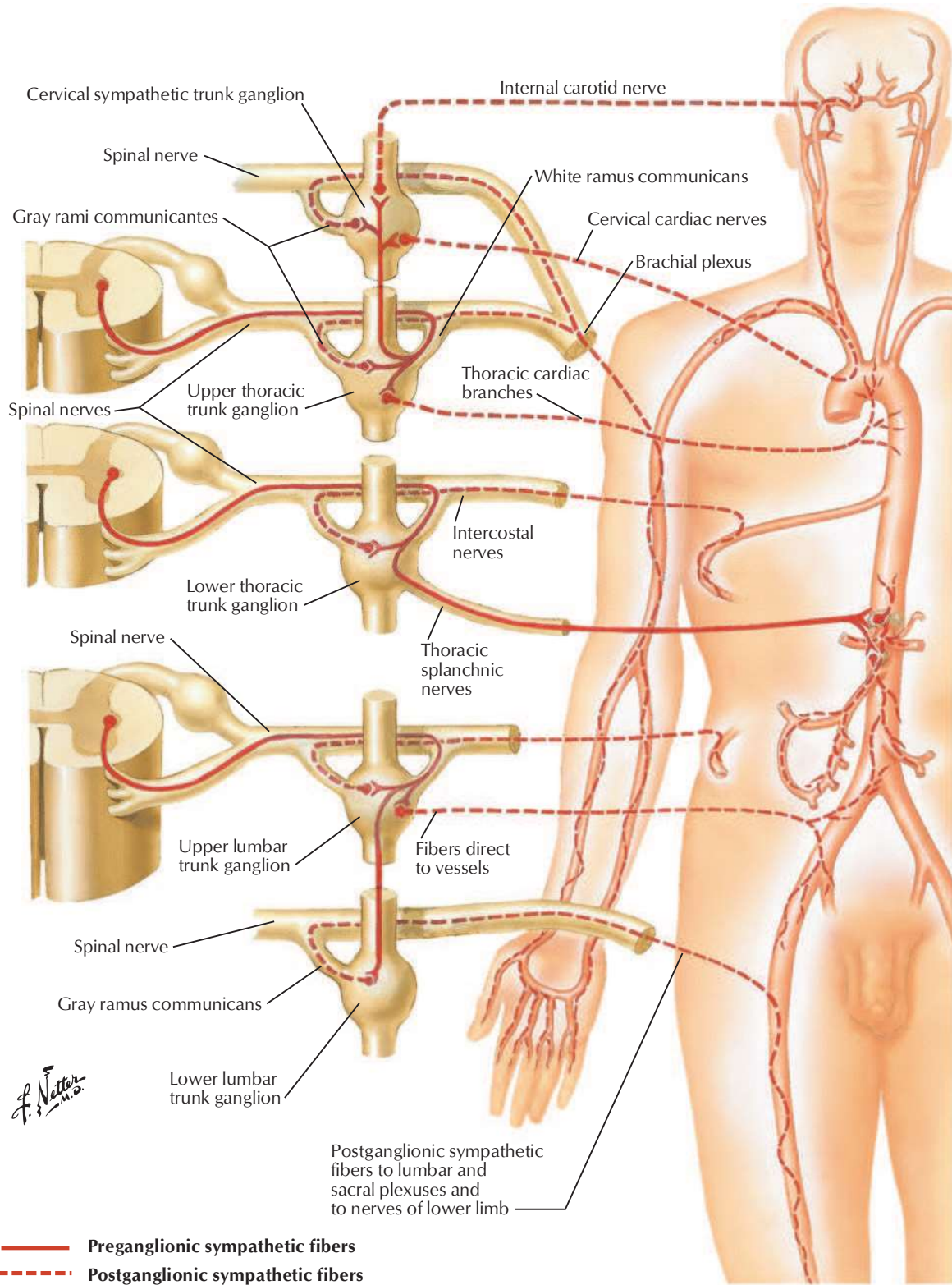


C. Machado M.D.

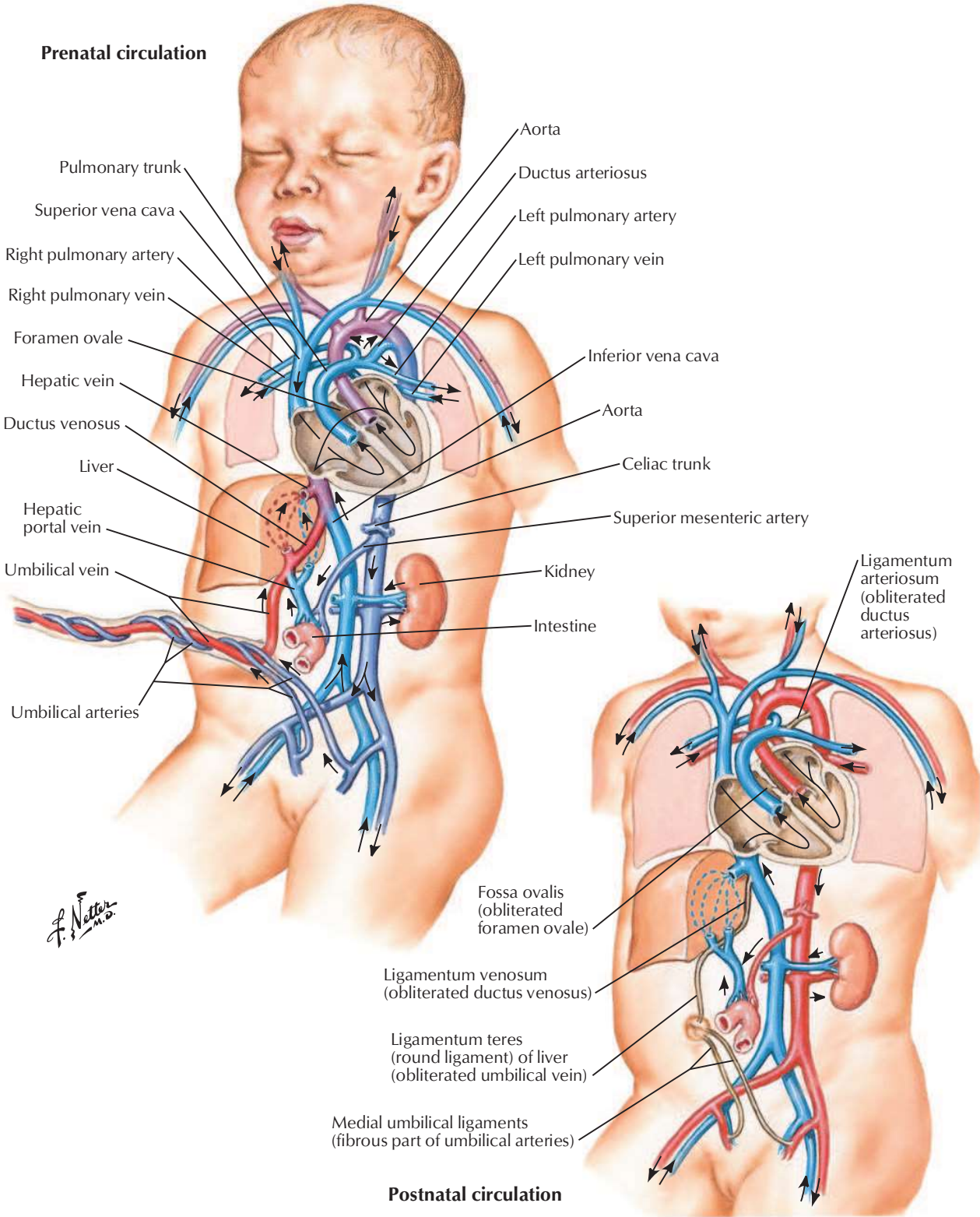




F. Netter M.D.

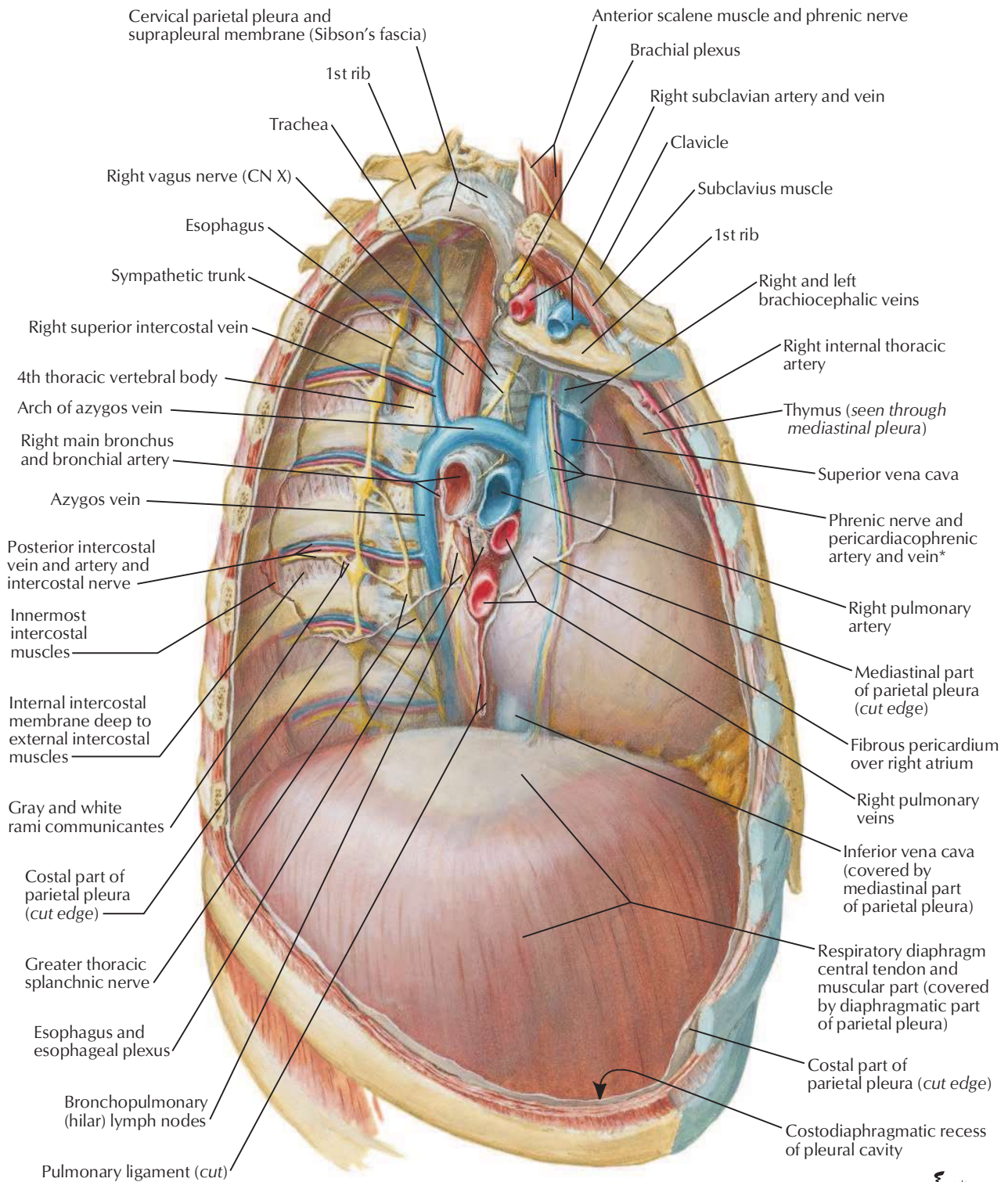


Prenatal circulation

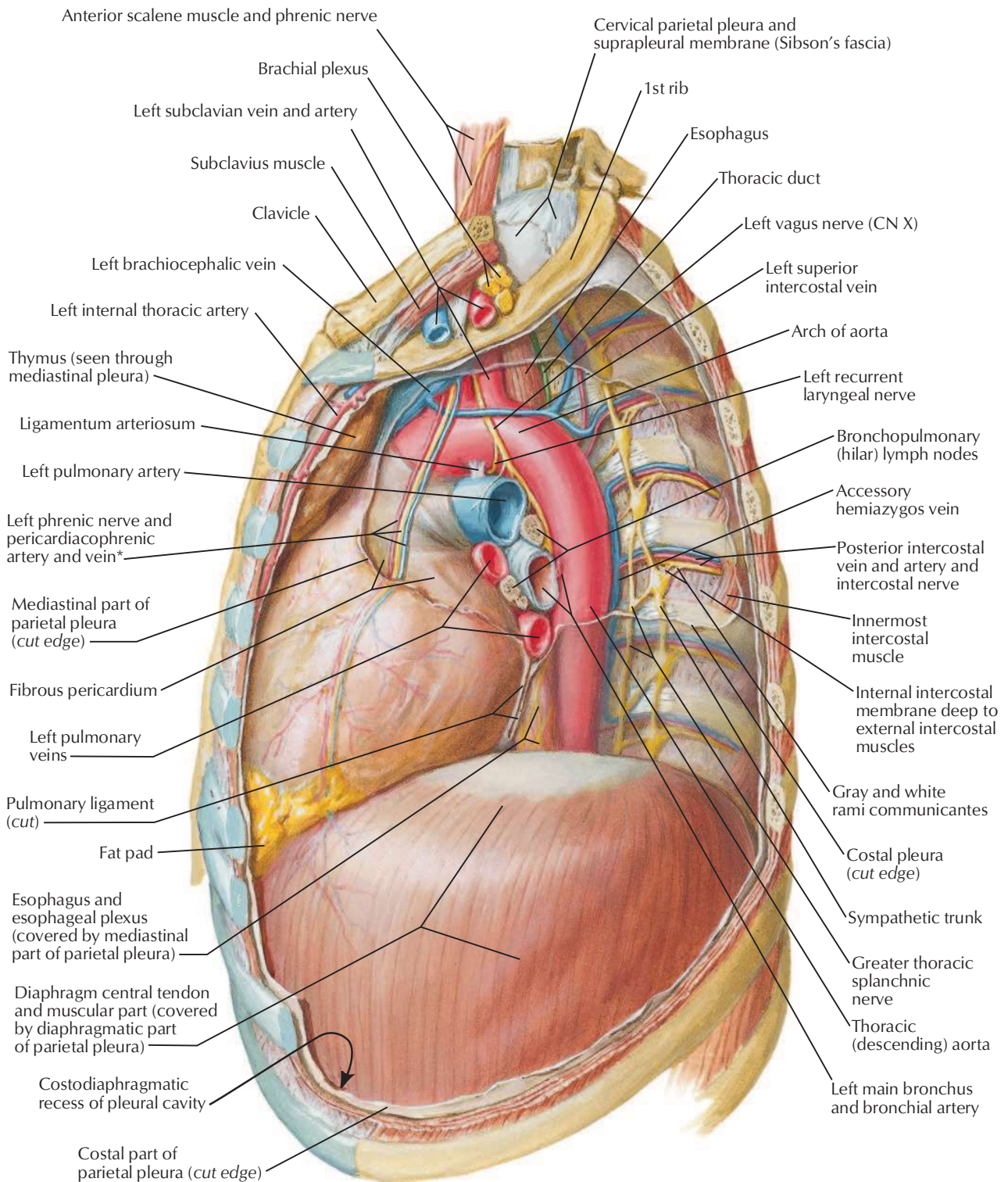


F. Netter M.D.

Postnatal circulation

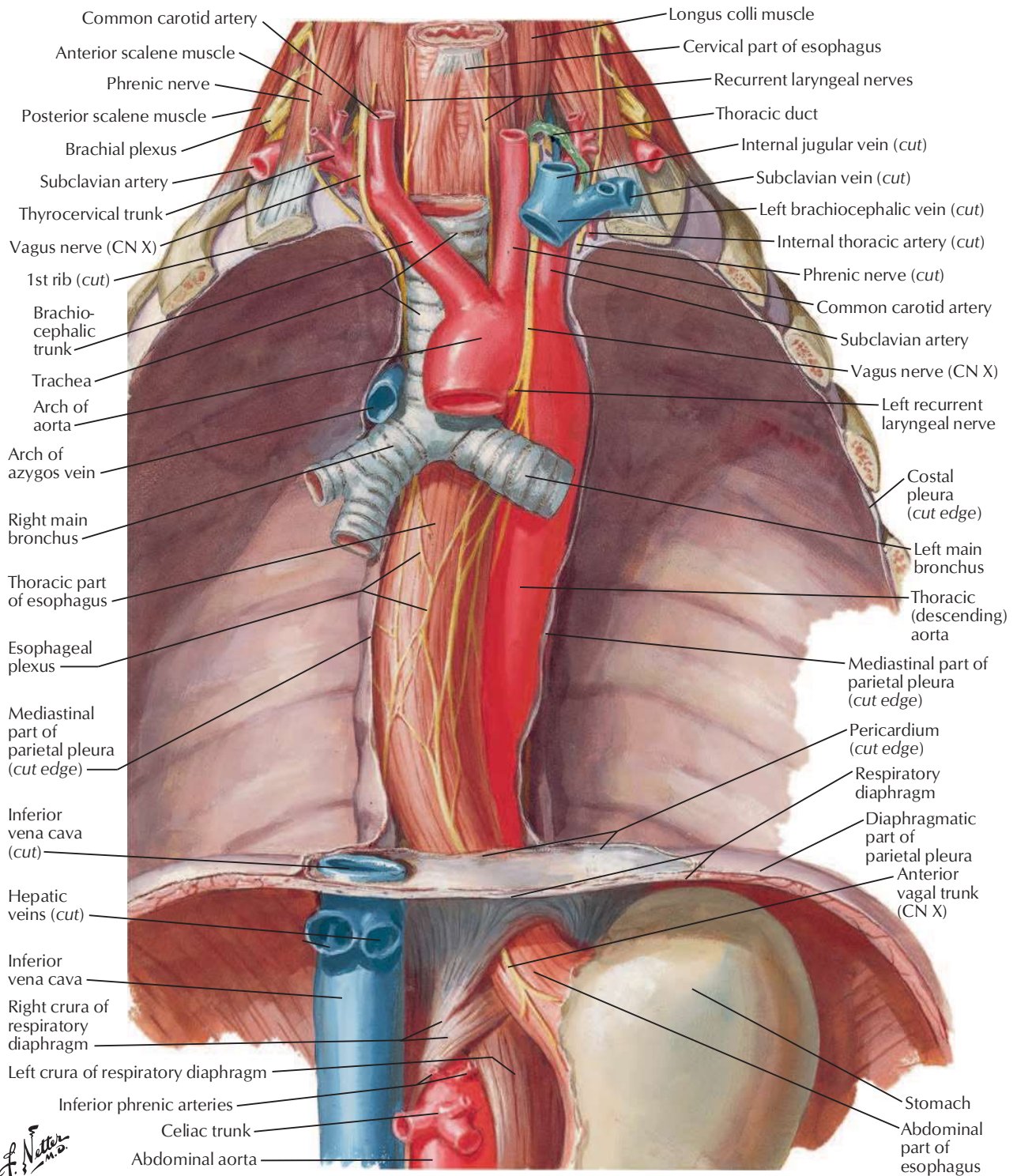


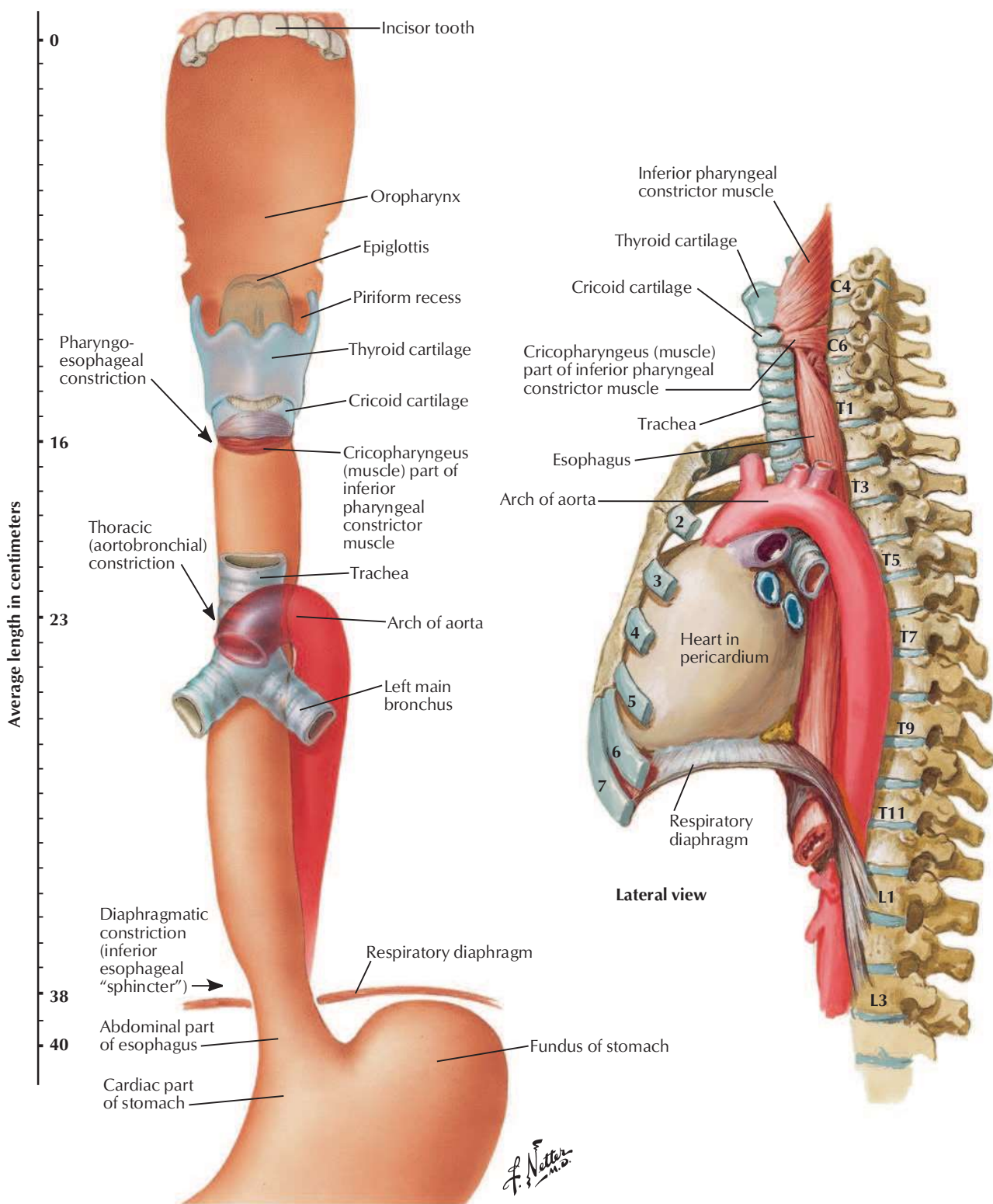
*Nerve and vessels commonly run independently.



*Nerve and vessels commonly run independently.

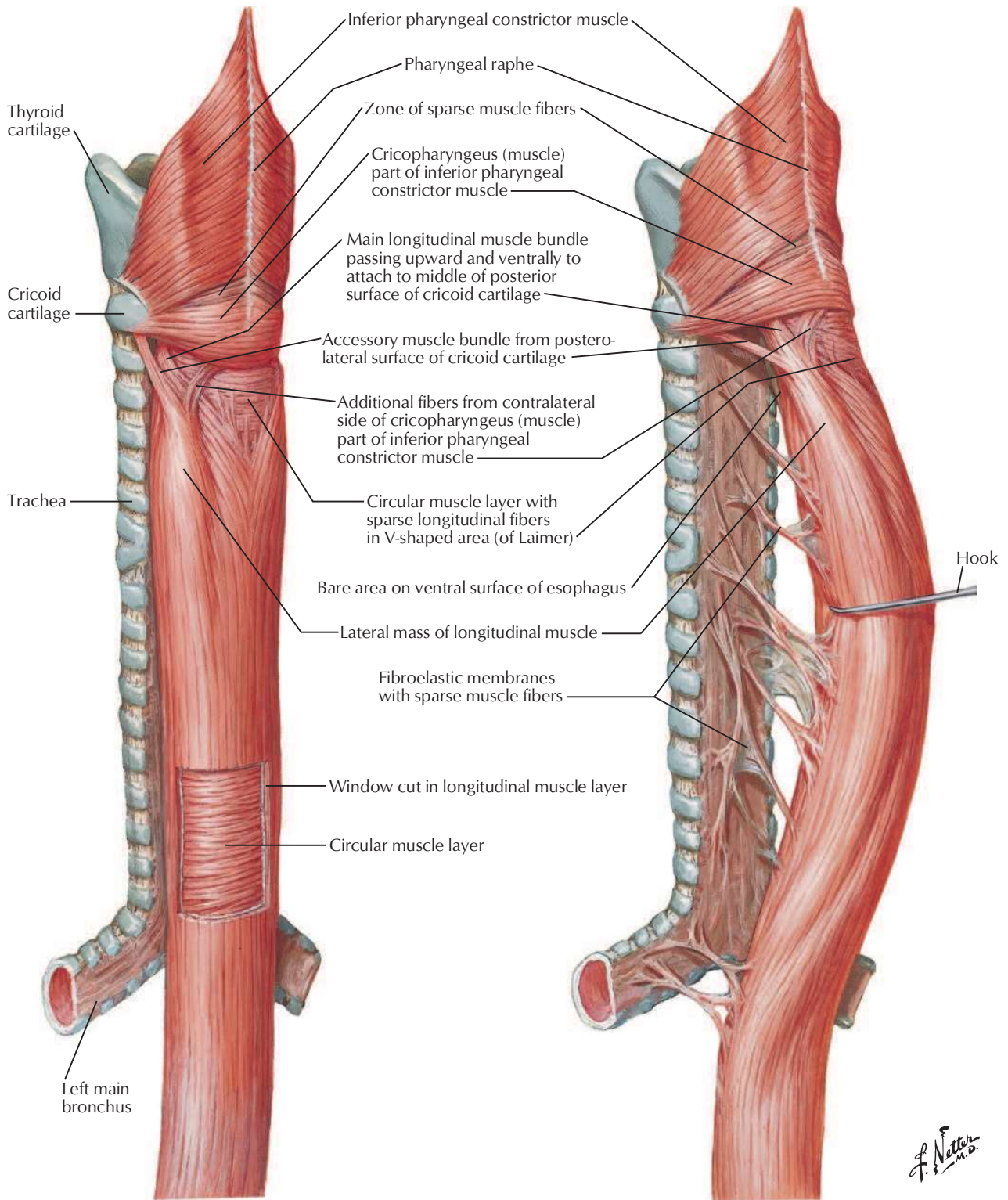
F. Netter M.D.



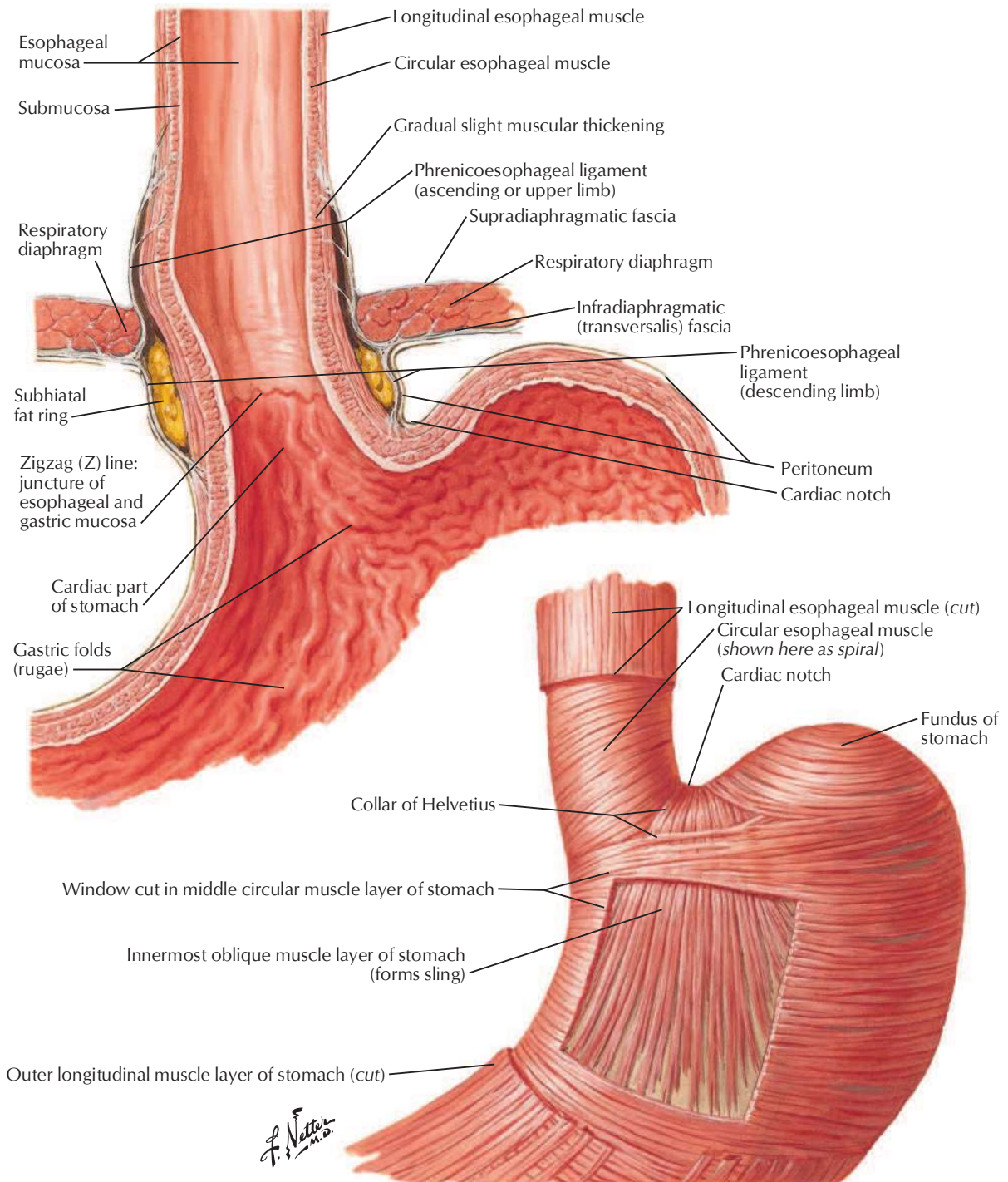


Musculature of Esophagus

See also Plates 75, 81

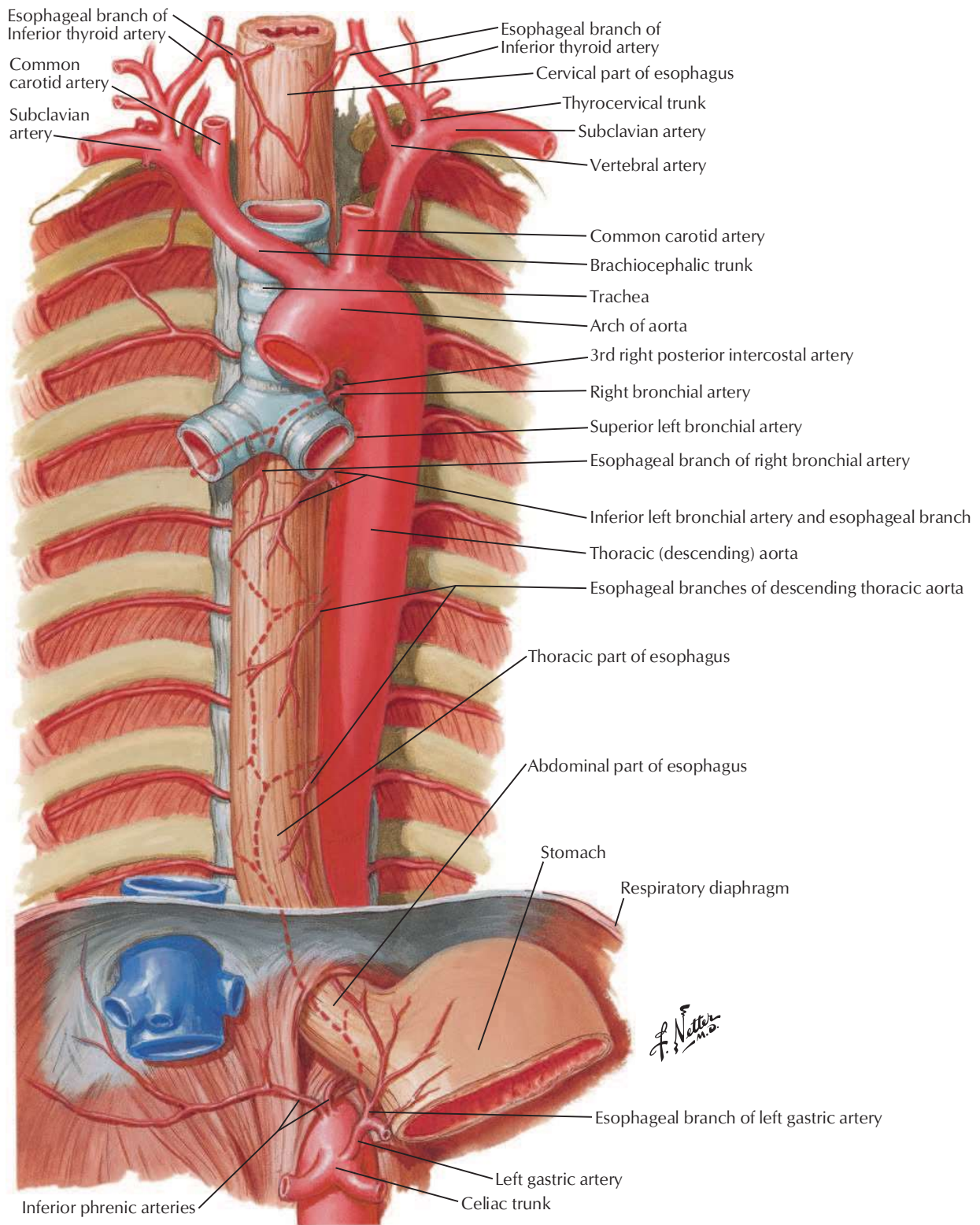


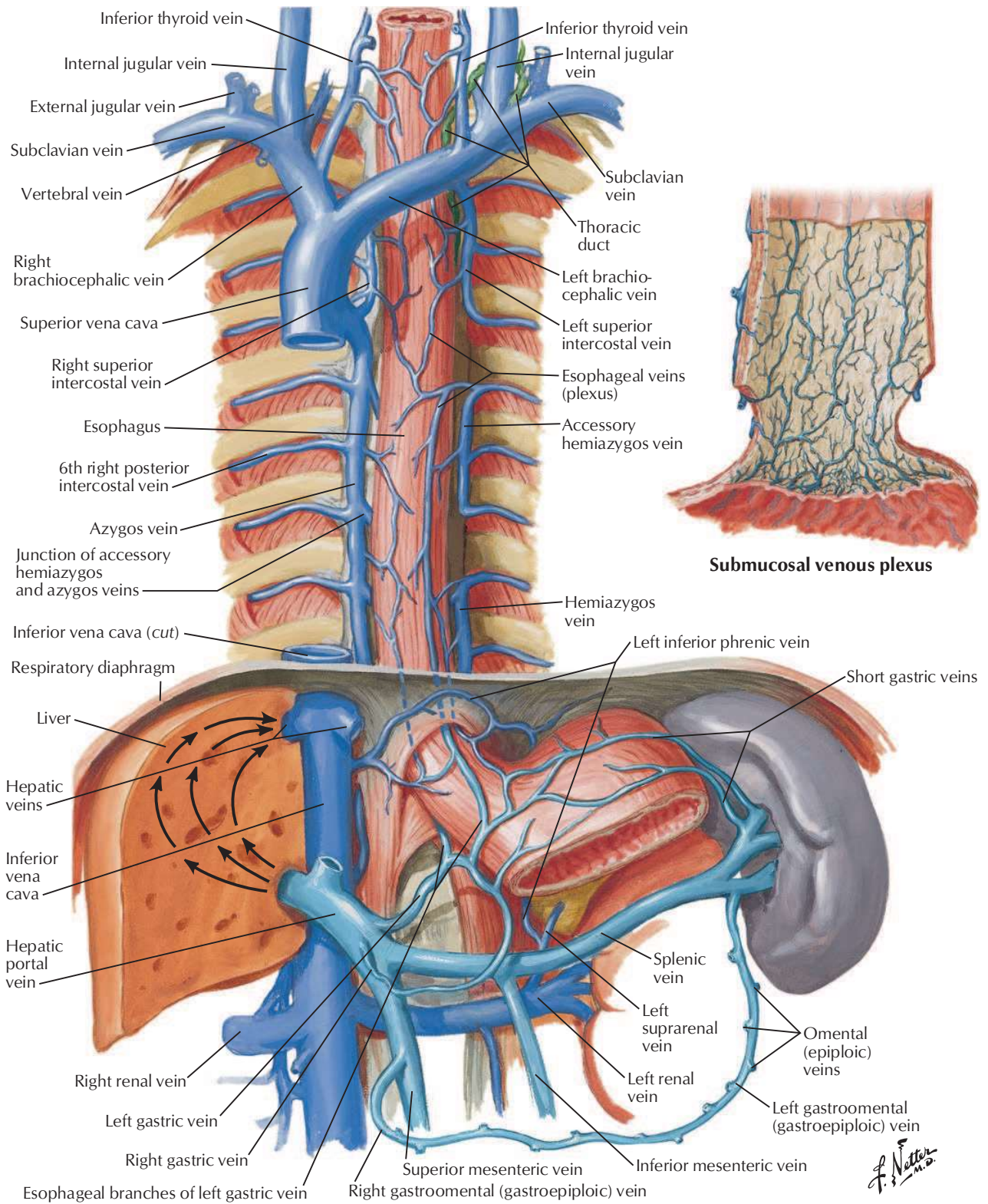
Posterolateral view



Arteries of Esophagus

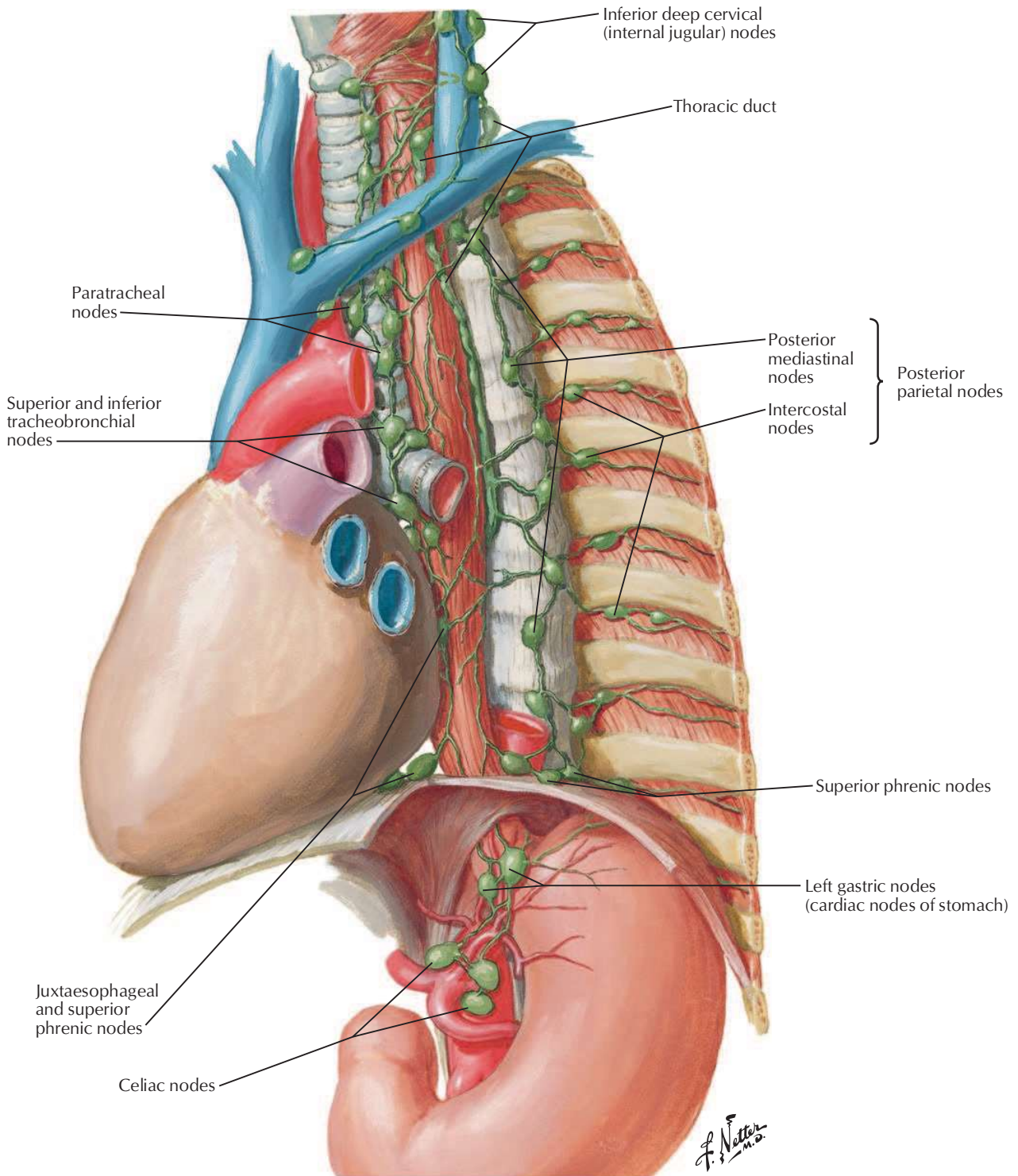
See also [Plates 211, 291](#)



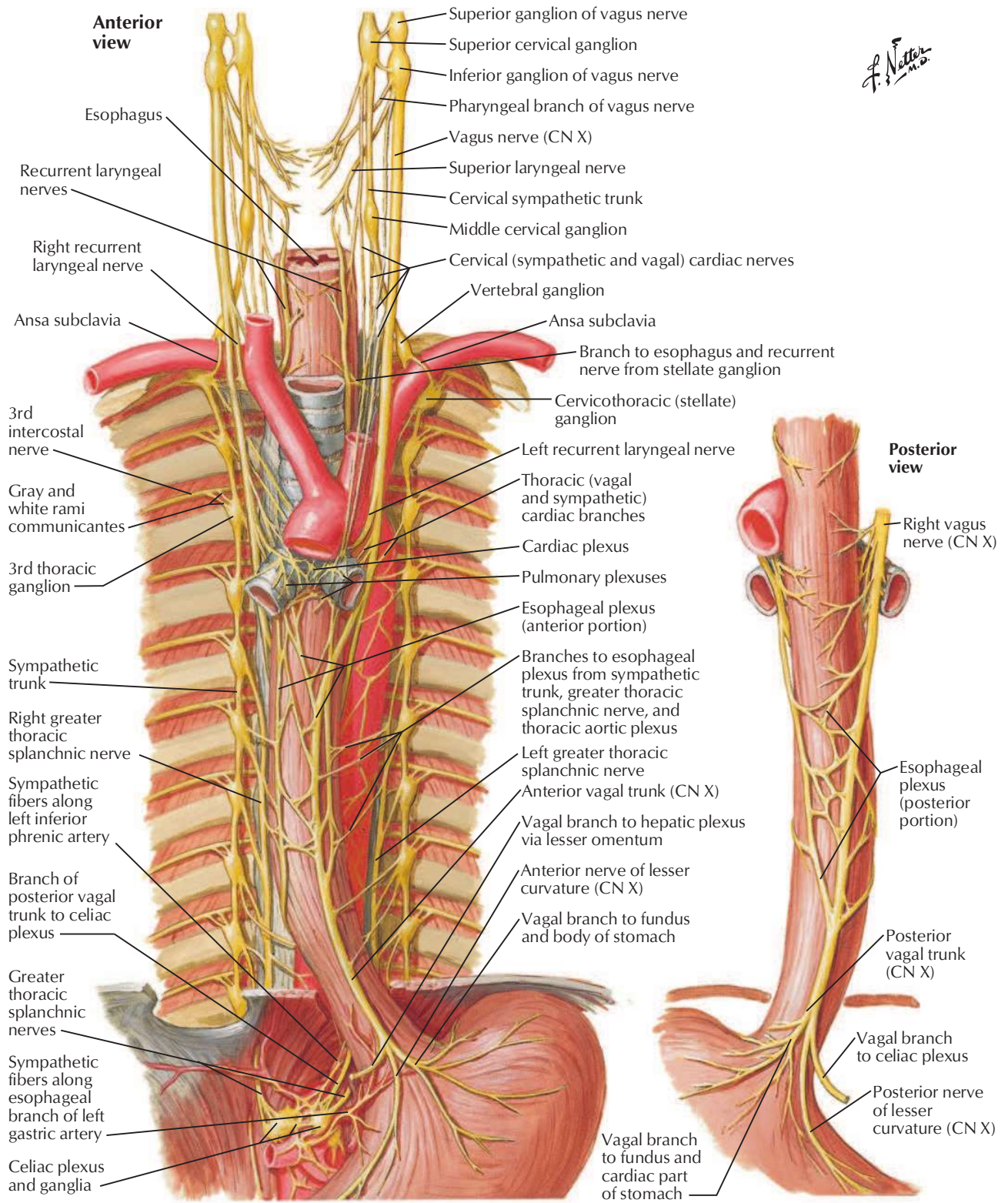


Lymph Vessels and Nodes of Esophagus

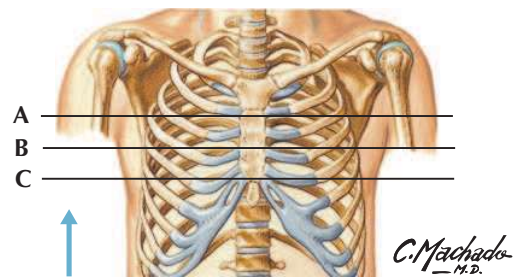
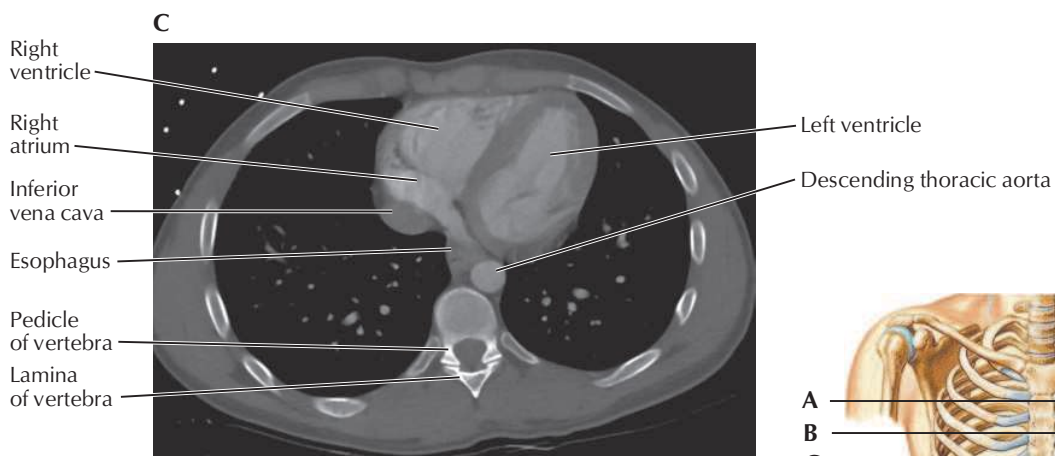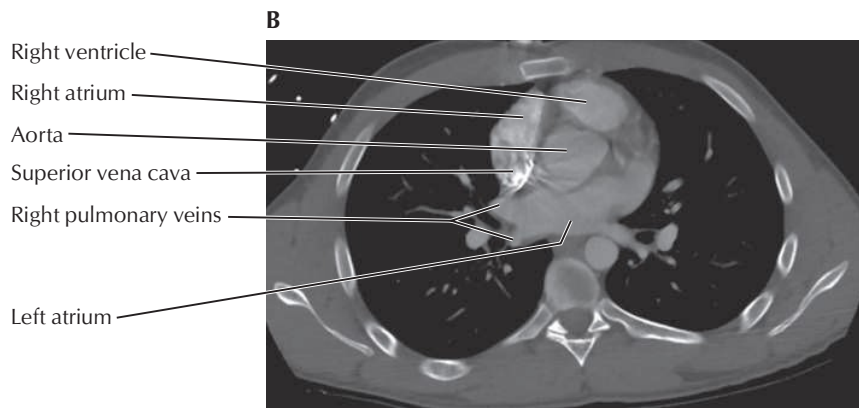
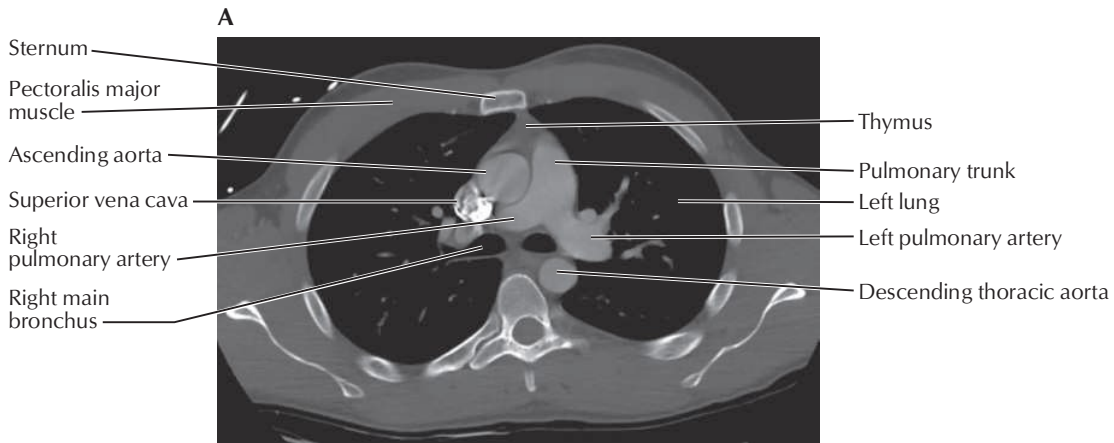
See also [Plate 212](#)

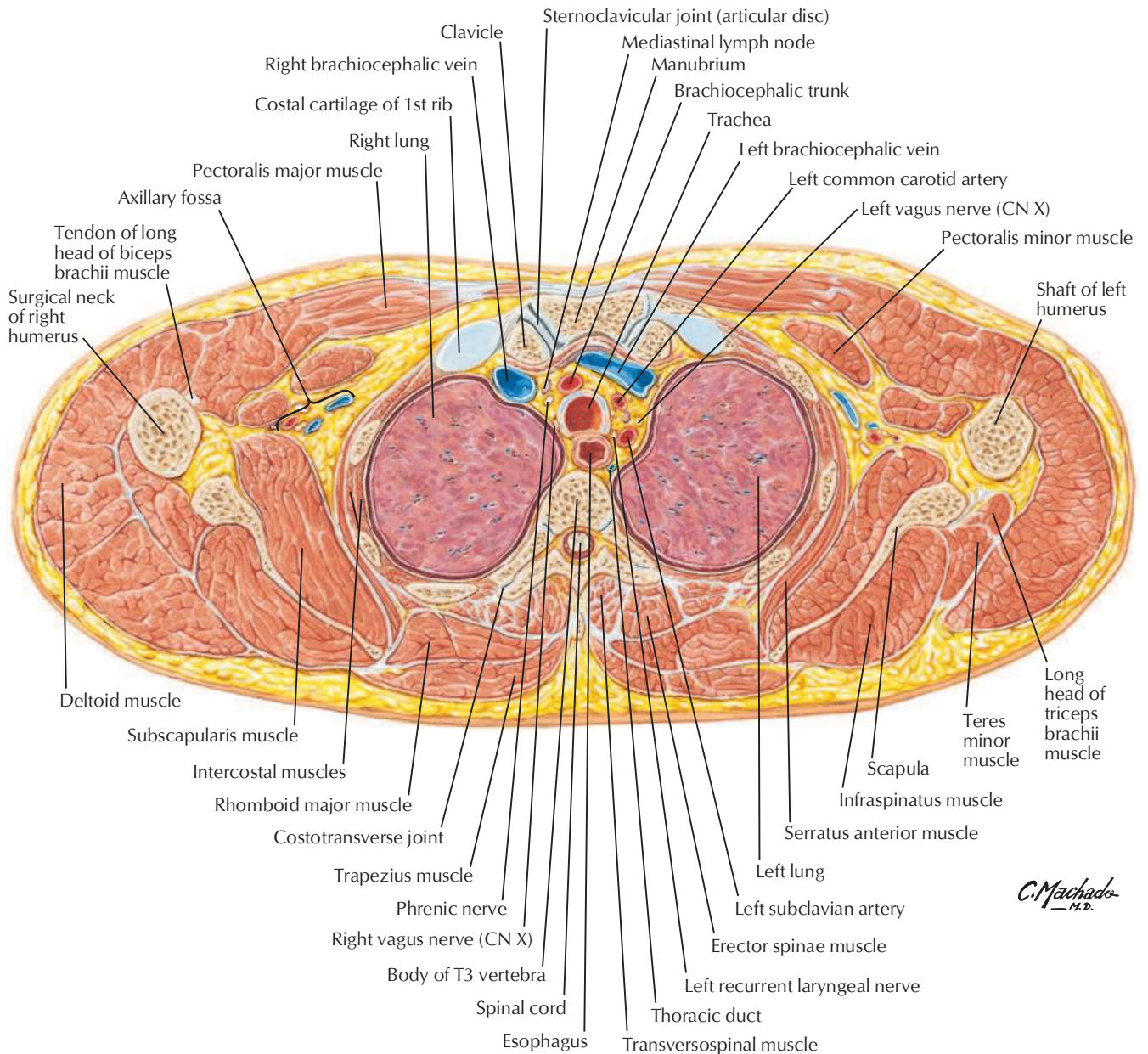
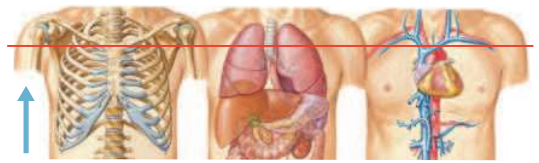

F. Netter M.D.



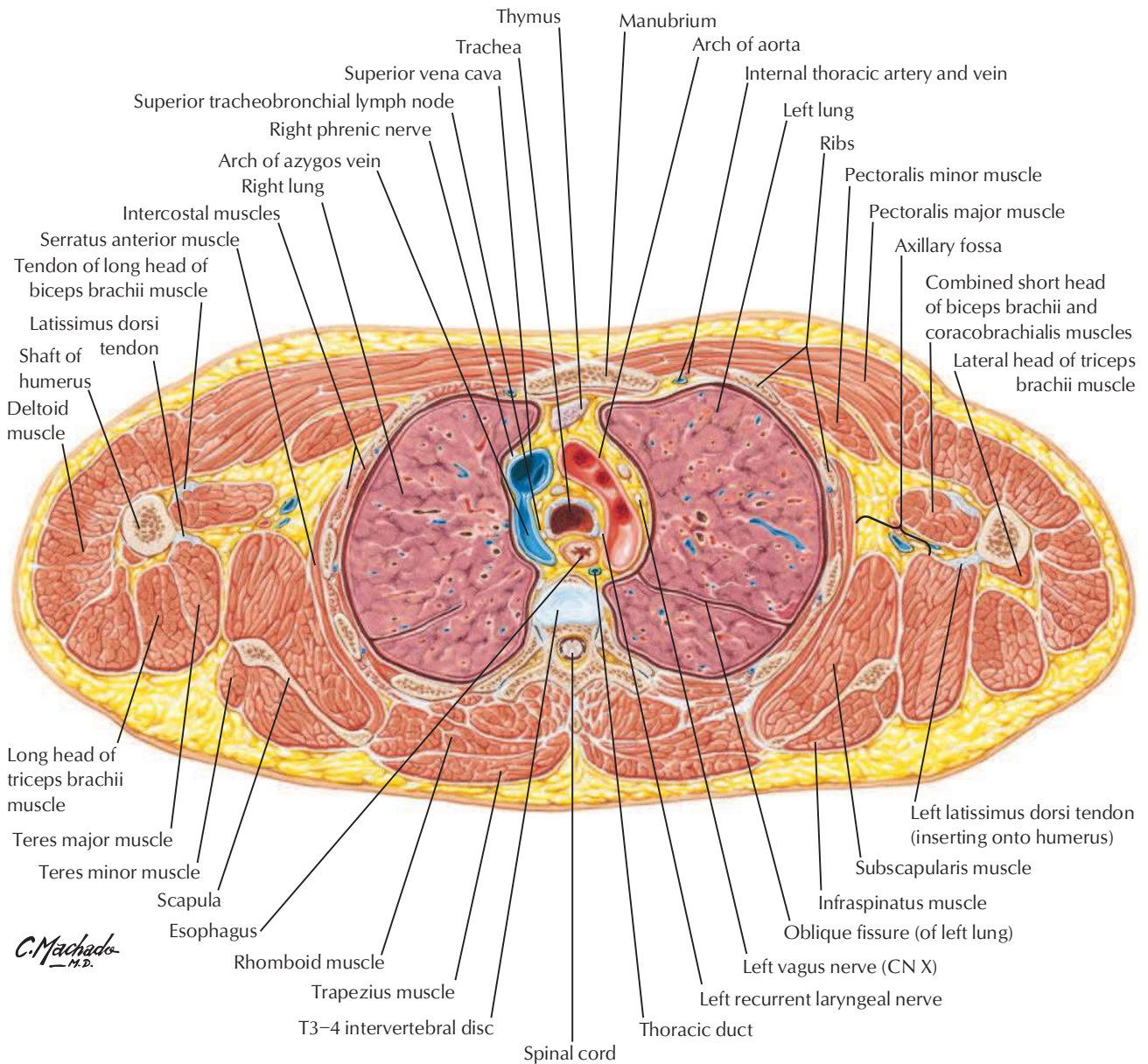
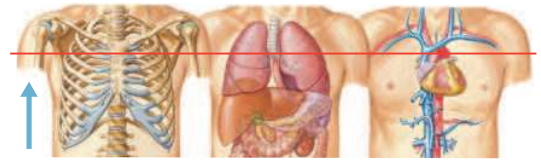Axial CT images of the thorax from superior (A) to inferior (C)



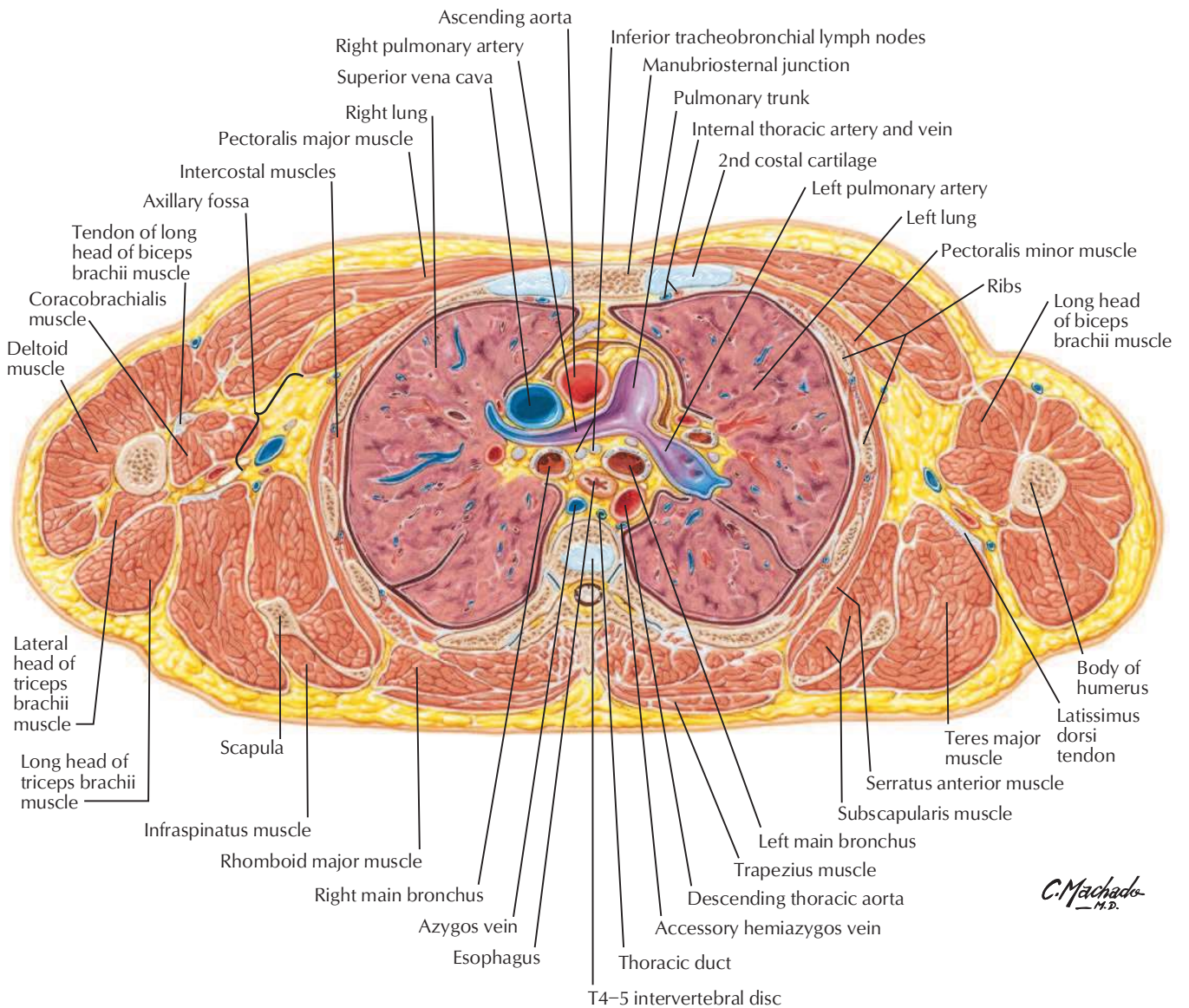
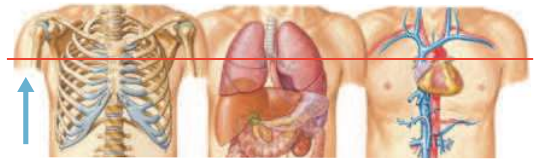


C. Machado
—M.D.

Cross Section of Thorax at T3-4 Disc Level

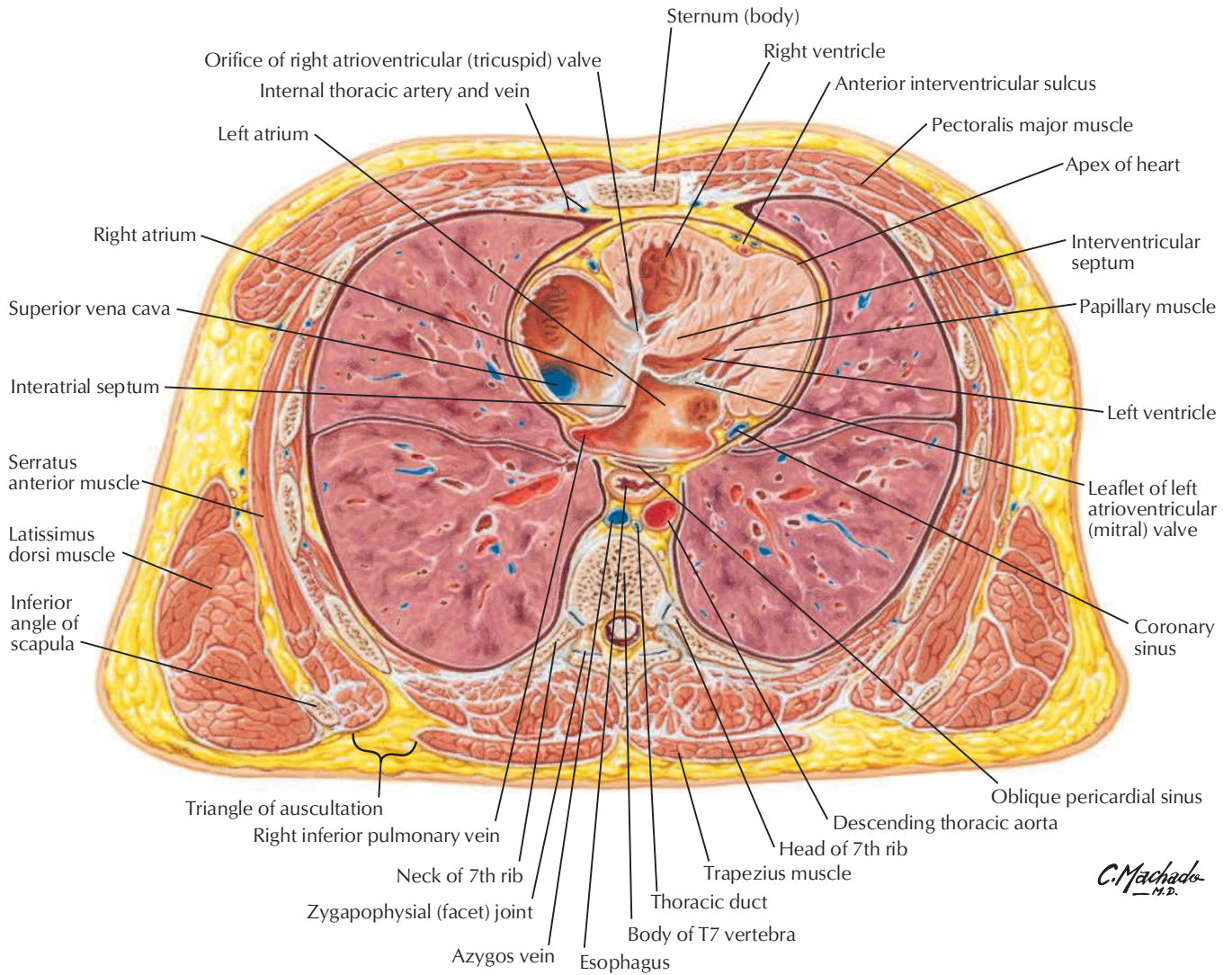
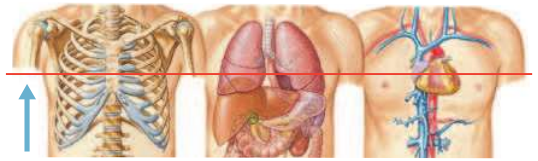


C. Machado
M.D.







C. Machado
M.D.

Cross Section of Thorax at T7 Level



C. Machado
— M.D.

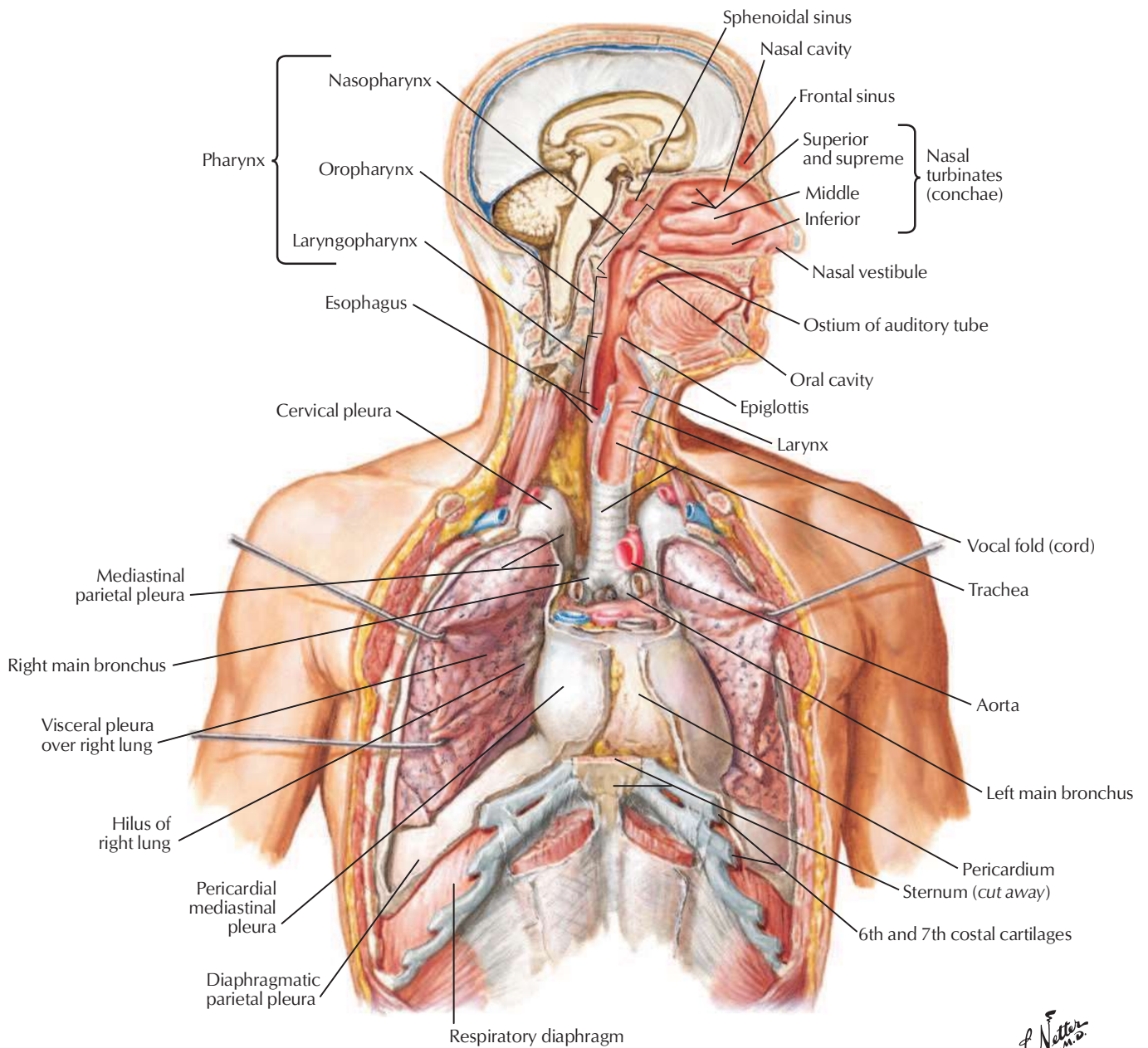
ANATOMICAL STRUCTURES	CLINICAL IMPORTANCE	PLATE NUMBERS
 INTEGUMENTARY SYSTEM		
Mammary gland	Breast cancer is most common malignancy in women; movement of breast with pectoral muscles indicates invasion of retromammary space	188
 SKELETAL SYSTEM		
Ribs	Rib fractures may breach pleural space and cause pneumothorax; flail chest occurs when multiple rib fractures lead to thoracic cage instability	192
Sternal angle (of Louis)	Surface landmark for counting ribs (2nd pair of ribs articulate here) and intercostal spaces; divides superior from inferior mediastinum	192
Chest wall (ribs and intercostal spaces)	Knowledge of relationships between chest wall and underlying organs is necessary for thoracotomy	194, 202, 204
Left ribs (ribs 9, 10, 11)	If fractured, may cause injury to underlying spleen	202
Superior thoracic aperture	Compression of neurovascular structures traversing superior thoracic aperture may produce thoracic outlet syndrome	198
 MUSCULAR SYSTEM		
Intercostal spaces	Important relationship of intercostal neurovascular bundle to ribs when placing chest drainage tube to relieve pneumothorax or hemothorax	195, 221
Respiratory diaphragm	Widening of esophageal hiatus or congenital defect allows for protrusion of stomach into thorax (hiatal hernia)	201, 239
 RESPIRATORY SYSTEM		
Lines of pleural reflection	Knowledge of location of lung and pleura with respect to chest wall is necessary for chest tube thoracostomy	202, 203
Pleura of lungs	Air or gas (spontaneous or traumatic) can leak into pleural space between visceral and parietal pleura and compress lung	202, 204
Cervical pleura	Extends into neck superior to 1st rib; it may therefore be punctured during neck procedures, producing pneumothorax	202
Tracheal bifurcation	Right main bronchus is shorter, more vertical, and wider; aspirated objects are therefore often in right lung	208
Apex of lung	Pancoast syndrome (bronchiogenic carcinoma) of apex invades sympathetic trunk, resulting in Horner's syndrome (ipsilateral miosis, ptosis, anhidrosis, facial flushing)	202, 234
 NERVOUS SYSTEM		
Long thoracic nerve	May be damaged during chest tube placement or mastectomy, resulting in winged scapula (denervation of serratus anterior muscle)	189, 194
Intercostal nerve	Site of local anesthetic nerve block for procedures such as thoracostomy or to alleviate pain caused by shingles	196, 197
Posterior root (spinal) ganglion	Can house dormant varicella zoster virus, which, when activated, can result in herpes zoster (shingles)	197
Phrenic nerve and respiratory diaphragm	Ipsilateral injury to phrenic nerve may cause ipsilateral paralysis of hemidiaphragm Diaphragmatic irritation may manifest as shoulder pain because of referral to C3-5 spinal levels	199, 201 199, 216
Recurrent laryngeal branch of vagus nerve (CN X)	Pathologic findings in aorticopulmonary window may compress this nerve and produce hoarseness of voice	235, 236

ANATOMICAL STRUCTURES	CLINICAL IMPORTANCE	PLATE NUMBERS
 NERVOUS SYSTEM—Continued		
Visceral pain afferents from heart	Pain of myocardial ischemia referred to upper thoracic dermatomes; may be perceived as somatic pain in chest and medial upper limb	231
 CARDIOVASCULAR SYSTEM		
Internal thoracic artery	Commonly used for coronary artery bypass grafts	196, 197
Pulmonary arteries	Thromboemboli may obstruct pulmonary vasculature, leading to infarction	205, 210
Pericardium	Pericardial effusion (accumulation of fluid or blood) may compromise heart function (cardiac tamponade)	215, 219
Coronary arteries	Atherosclerotic blockage may cause myocardial ischemia and/or infarct; anterior interventricular (left anterior descending) artery most commonly diseased	222
Interventricular septum of heart	Ventricular septal defect is most common congenital cardiac defect; most often involves membranous part of septum	225, 228
Heart valves	Congenital variations of valve anatomy or valvular disease (e.g., rheumatic heart disease) can cause valvular stenosis	226
Sinatrial node	Aging, previous heart surgery, and some medications can cause cardiac arrhythmias	229
Ligamentum arteriosum	Abnormal closure of ductus arteriosus can produce aortic coarctation; lack of closure produces patent ductus arteriosus; if not closed, may cause exertional dyspnea, pulmonary vascular disease, or heart failure	233
Thoracic aorta	Congenital coarctation of aorta can compromise systemic blood flow; collateral vascular connections can alleviate this condition	240
Azygos venous system	Drains posterior thorax and provides important collateral channel between inferior vena cava and superior vena cava	241
 LYMPHATIC SYSTEM		
Mammary gland lymphatics	Metastatic spread of cancer cells to axilla and chest via lymphatics draining breast	191
Axillary lymph nodes	Primary nodes that receive lymphatic drainage from upper limb, thoracic wall, and breast; commonly enlarged in patients with breast cancer	190, 191

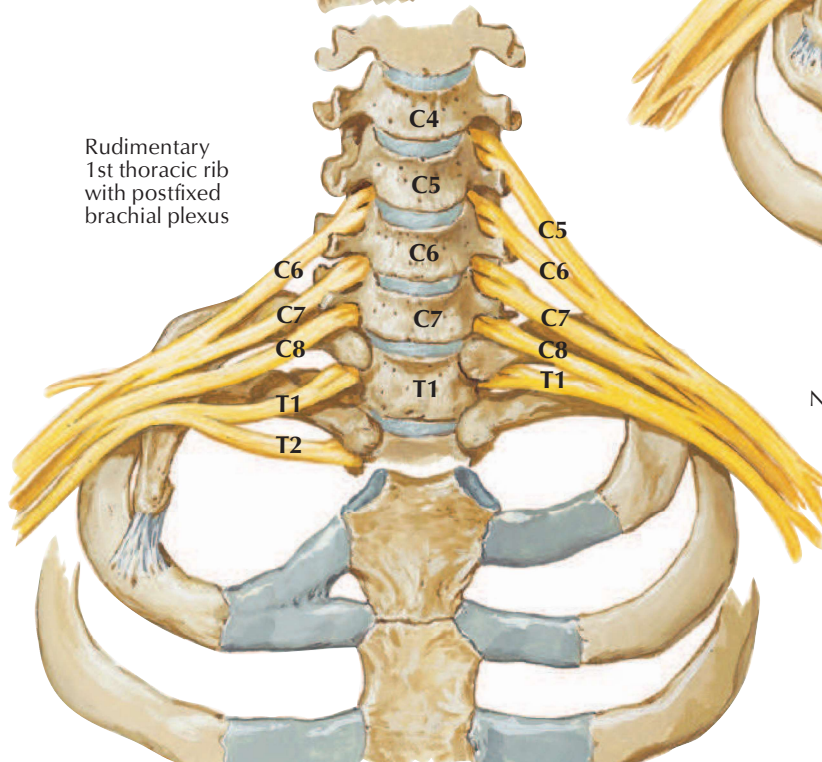
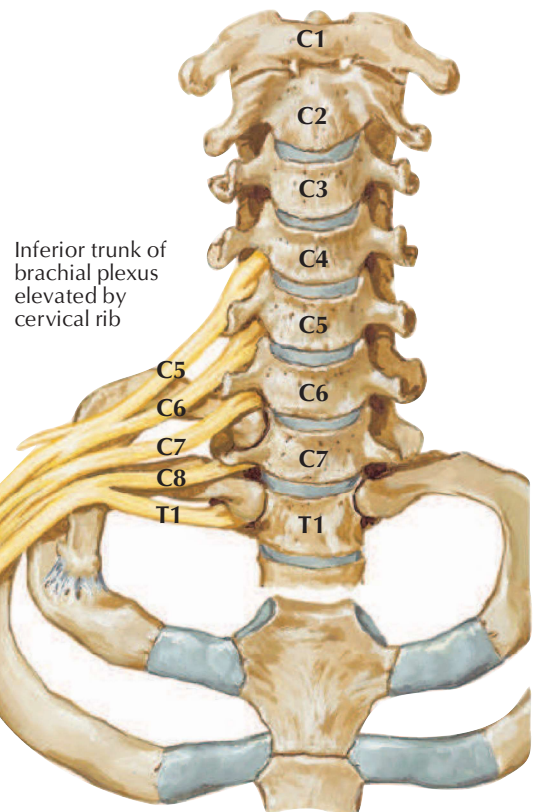
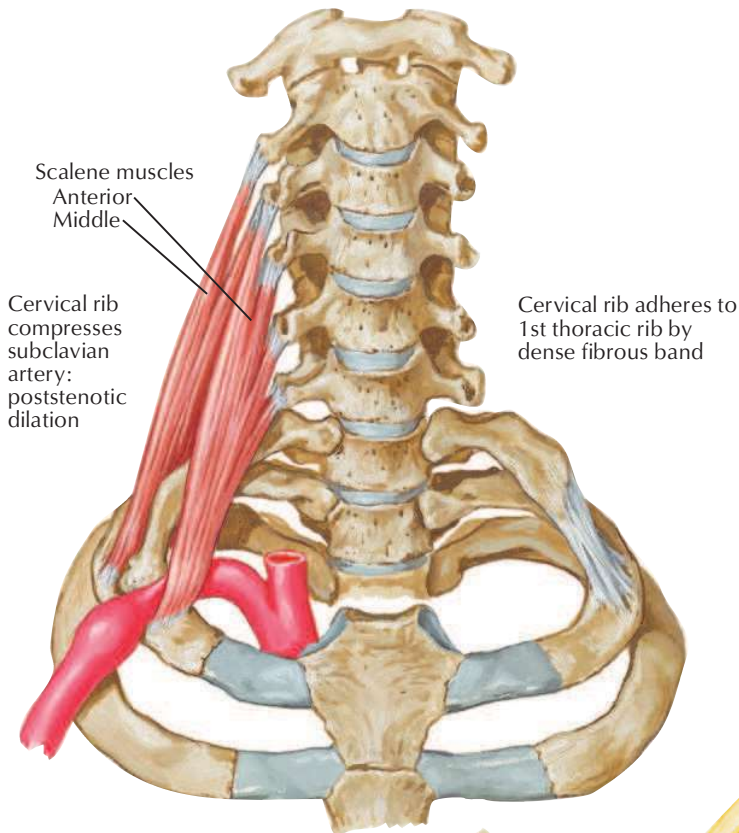
*Selections were based largely on clinical data as well as commonly covered clinical correlations in gross anatomy courses.

MUSCLE	MUSCLE GROUP	PROXIMAL ATTACHMENT (ORIGIN)	DISTAL ATTACHMENT (INSERTION)	INNERVATION	BLOOD SUPPLY	MAIN ACTIONS
Respiratory diaphragm	Posterior abdominal wall	Xiphoid process, lower six costal cartilages, L1–L3 vertebrae	Converge into central tendon	Phrenic nerve	Pericardiophrenic, musculophrenic, superior and inferior phrenic arteries	Draws central tendon down and forward during inspiration
External intercostal	Thoracic wall	Lower border of ribs	Upper border of rib below rib of origin	Intercostal nerves	Posterior intercostal arteries, collateral branches of posterior intercostal arteries, costocervical trunk, anterior intercostal branches of internal thoracic artery, musculophrenic artery	Supports intercostal spaces in inspiration and expiration, elevates ribs in inspiration
Innermost intercostal	Thoracic wall	Lower border of ribs	Upper border of rib below rib of origin	Intercostal nerves	Muscular branches of anterior intercostal arteries, muscular branches of posterior intercostal arteries, intercostal branches of internal thoracic and musculophrenic arteries, costocervical trunk branches	Elevates ribs
Internal intercostal	Thoracic wall	Lower border of ribs	Costal cartilage and edge of costal groove of rib above rib of origin	Intercostal nerves	Muscular branches of anterior intercostal arteries, muscular branches of posterior intercostal arteries, intercostal branches of internal thoracic and musculophrenic arteries, costocervical trunk branches	Prevents pushing out or drawing in of intercostal spaces in inspiration and expiration, lowers ribs in forced expiration
Levator costarum	Thoracic wall	Transverse processes of C7 and T1–T11	Subjacent ribs between tubercle and angle	Posterior ramus of lower thoracic nerves	Posterior intercostal arteries	Elevates ribs
Pectoralis major	Pectoral/axillary regions	Sternal half of clavicle, sternum to 7th rib, cartilages of true ribs, aponeurosis of external abdominal oblique muscle	Lateral lip of intertubercular sulcus of humerus	Medial and lateral pectoral nerves	Pectoral branch of thoracoacromial artery, perforating branches of internal thoracic artery	Flexes, adducts, and medially rotates arm
Pectoralis minor	Pectoral/axillary regions	Outer surface of upper margin of ribs 3–5	Coracoid process of scapula	Medial pectoral nerve	Pectoral branch of thoracoacromial artery, and superior and lateral thoracic arteries	Lowers lateral angle of scapula and protracts scapula
Serratus anterior	Shoulder	Lateral surfaces of upper 8–9 ribs	Costal surface of medial border of scapula	Long thoracic nerve	Lateral thoracic artery	Protracts and rotates scapula and holds it against thoracic wall
Serratus posterior inferior	Intermediate back	Spinous processes of T11–L2	Inferior aspect of ribs 9–12	Anterior rami of lower thoracic nerves	Posterior intercostal arteries	Depresses ribs
Serratus posterior superior	Intermediate back	Nuchal ligament, spinous processes of C7–T3	Superior aspect of ribs 2–5	Anterior rami of upper thoracic nerves	Posterior intercostal arteries	Elevates ribs
Subcostal	Thoracic wall	Internal surface of lower ribs near their angles	Superior borders of 2nd or 3rd rib below	Intercostal nerves 2nd–5th	Posterior intercostal artery, musculophrenic artery	Depresses ribs
Transversus thoracis	Thoracic wall	Internal surfaces of costal cartilages 2–6	Posterior surface of lower sternum	Intercostal nerves	Anterior intercostal arteries, internal thoracic artery	Depresses ribs and costal cartilages

Variations in spinal nerve contributions to the innervation of muscles, their arterial supply, their attachments, and their actions are common themes in human anatomy. Therefore, expect differences between texts and realize that anatomical variation is normal.

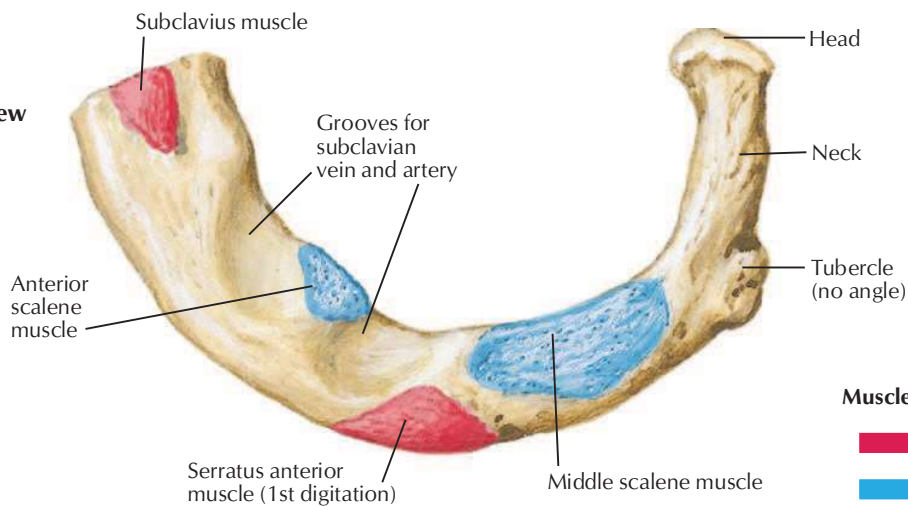


F. Netter M.D.

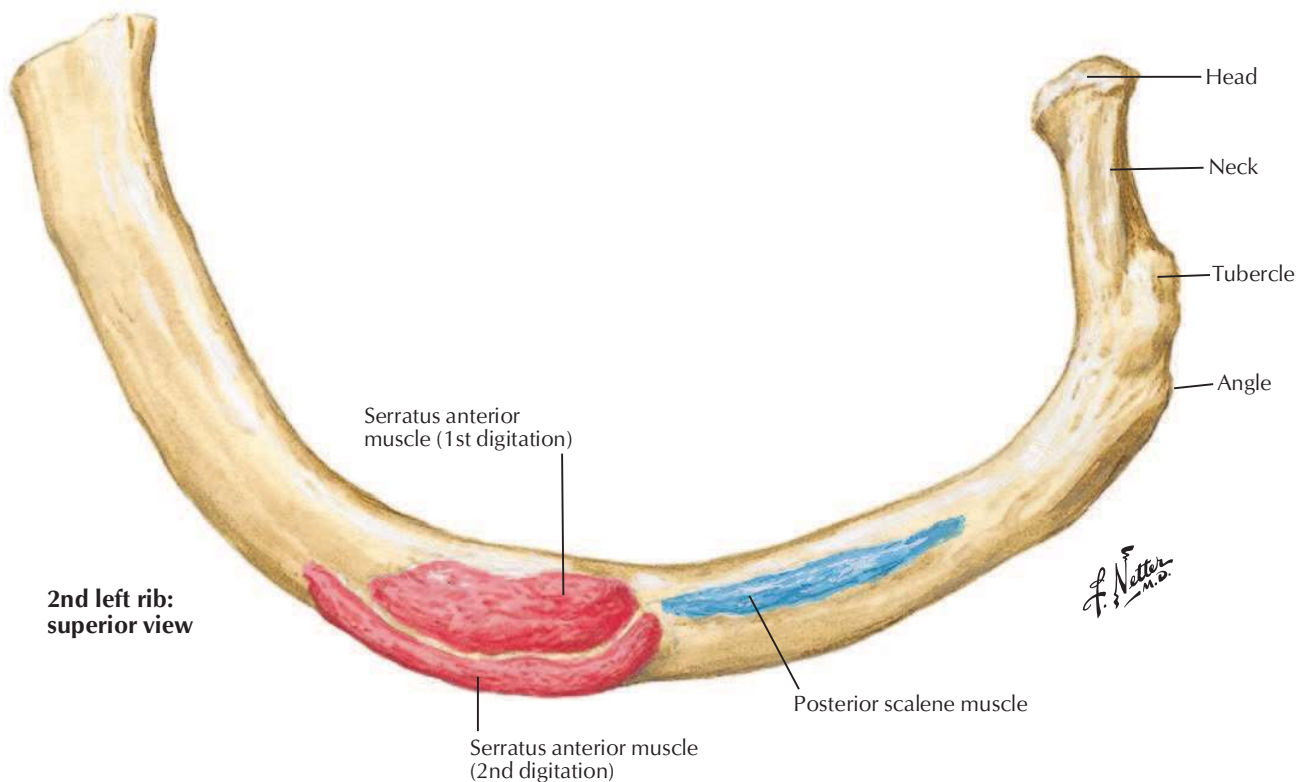


Normal morphology

1st left rib: superior view



2nd left rib: superior view



Muscles of inspiration

Accessory

Sternocleidomastoid
(elevates sternum)

Scalene muscles

Anterior

Middle

Posterior

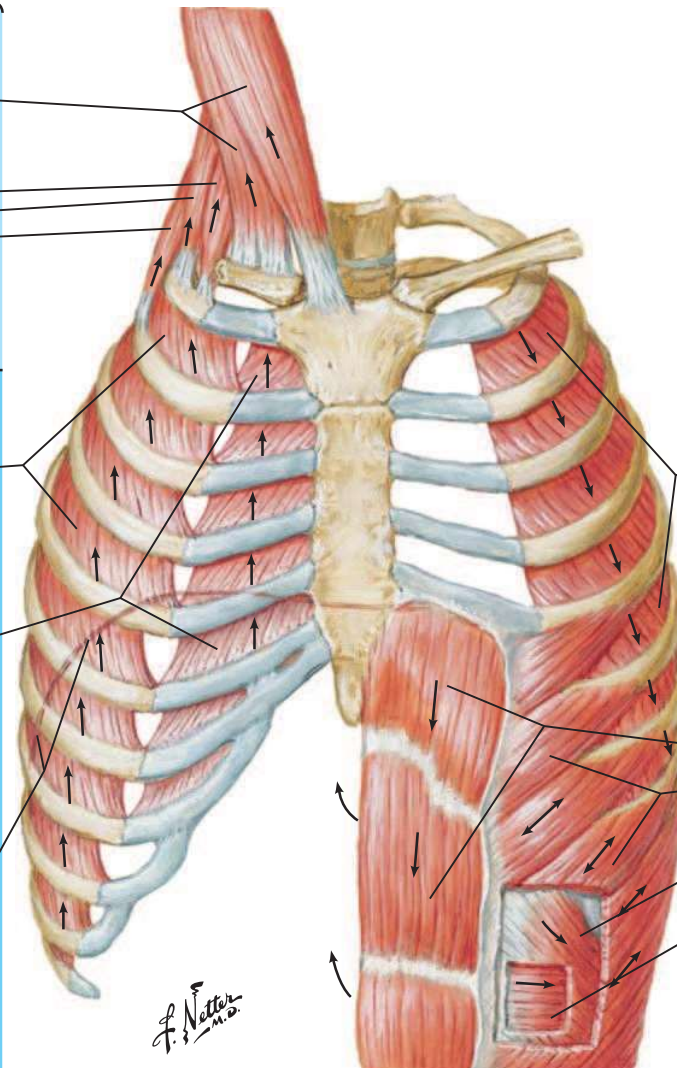
(elevate and fix upper ribs)

Principal

External intercostals, most superficial (elevate ribs, thus increasing width of thoracic cavity and aiding deep inspiration)

Interchondral parts of internal intercostals are deep to external intercostals (also elevate ribs and aid external intercostals with deep inspiration)

Respiratory diaphragm (dome descends, thus increasing vertical dimension of thoracic cavity; also elevates lower ribs)



Muscles of expiration

Quiet breathing

Expiration results from passive recoil of lungs and rib cage

Active breathing

Internal intercostal muscles, except interchondral part (aid forced expiration)

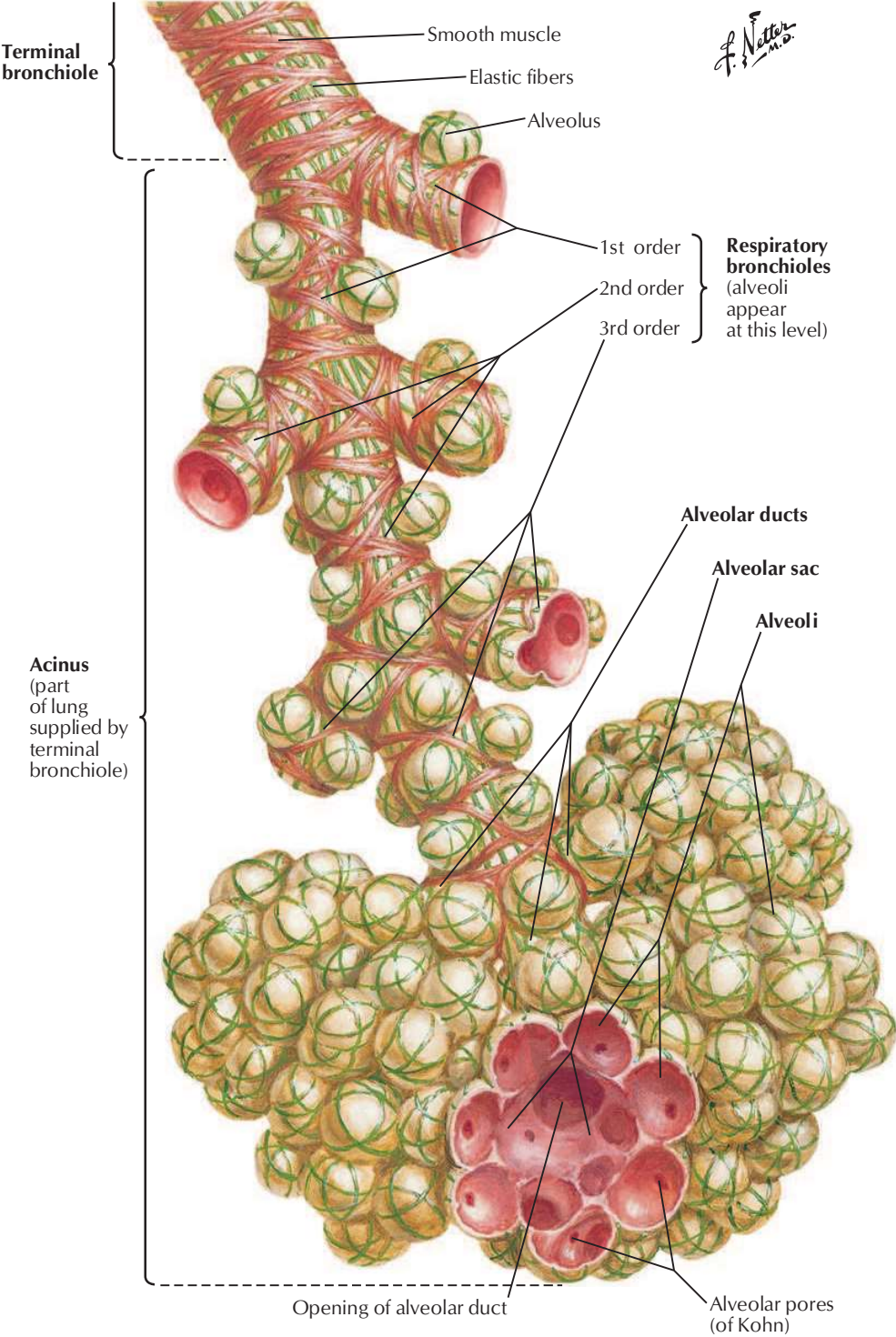
Abdominals (depress lower ribs, compress abdominal contents, thus pushing up respiratory diaphragm, aiding forced expiration)

Rectus abdominis

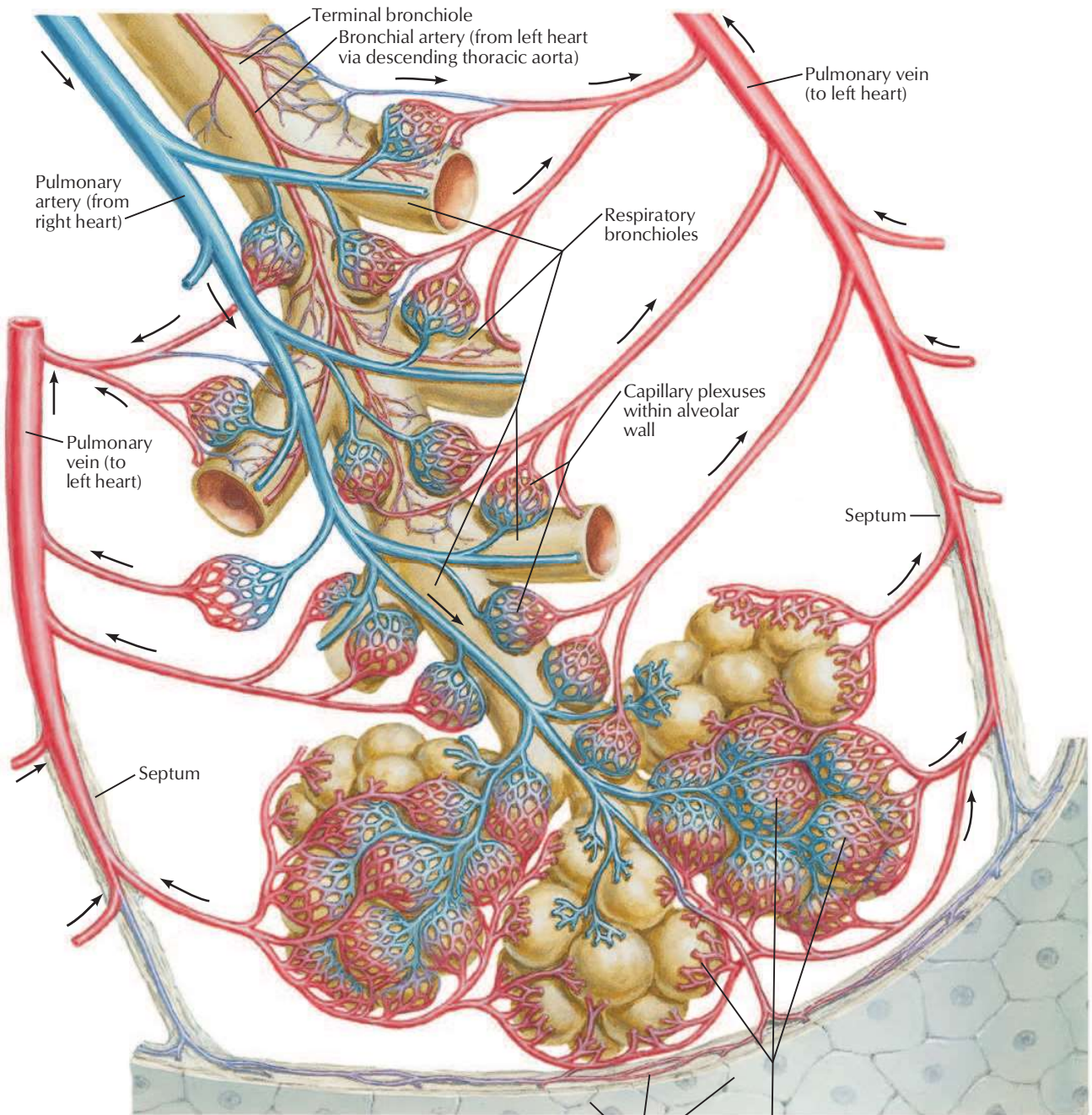
External abdominal oblique muscle

Internal abdominal oblique muscle

Transversus abdominis muscle



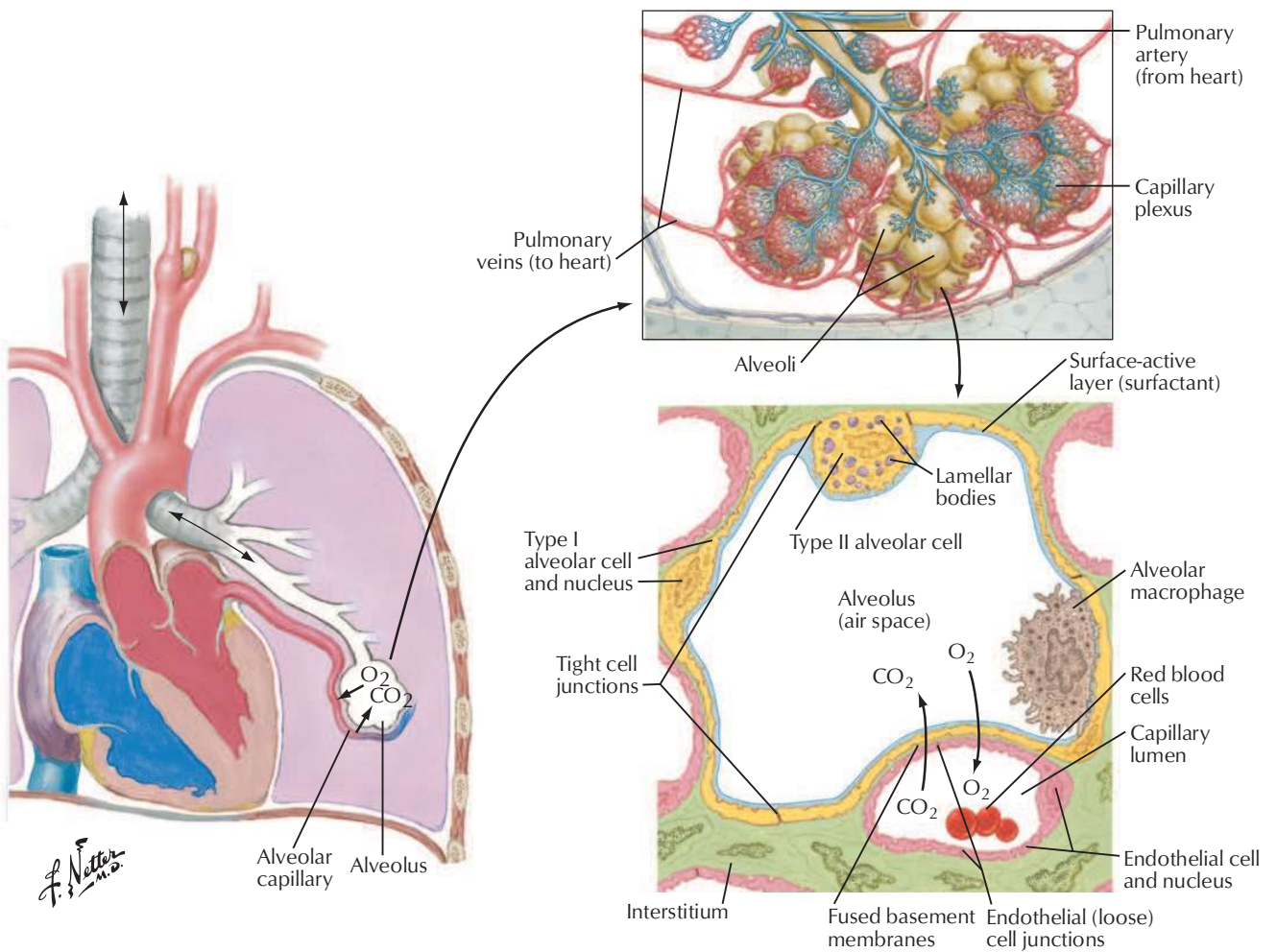
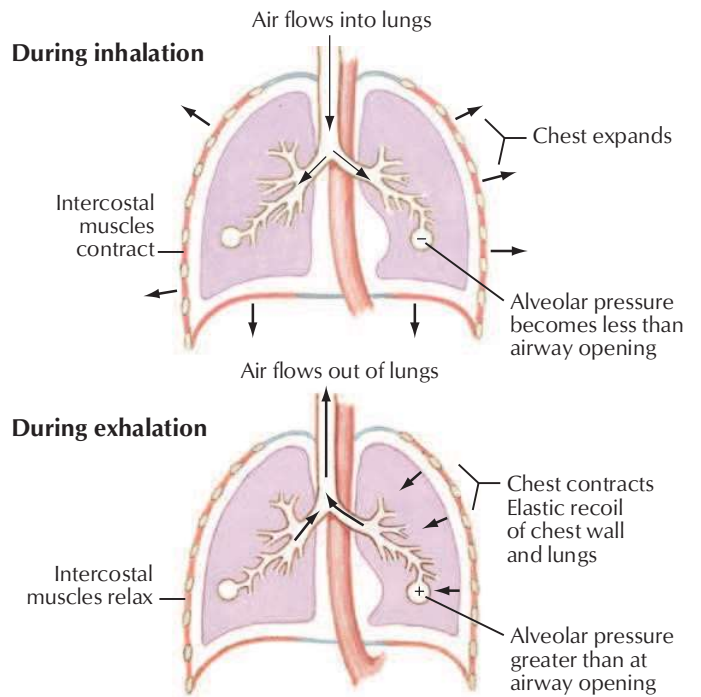
Structure of intrapulmonary airways



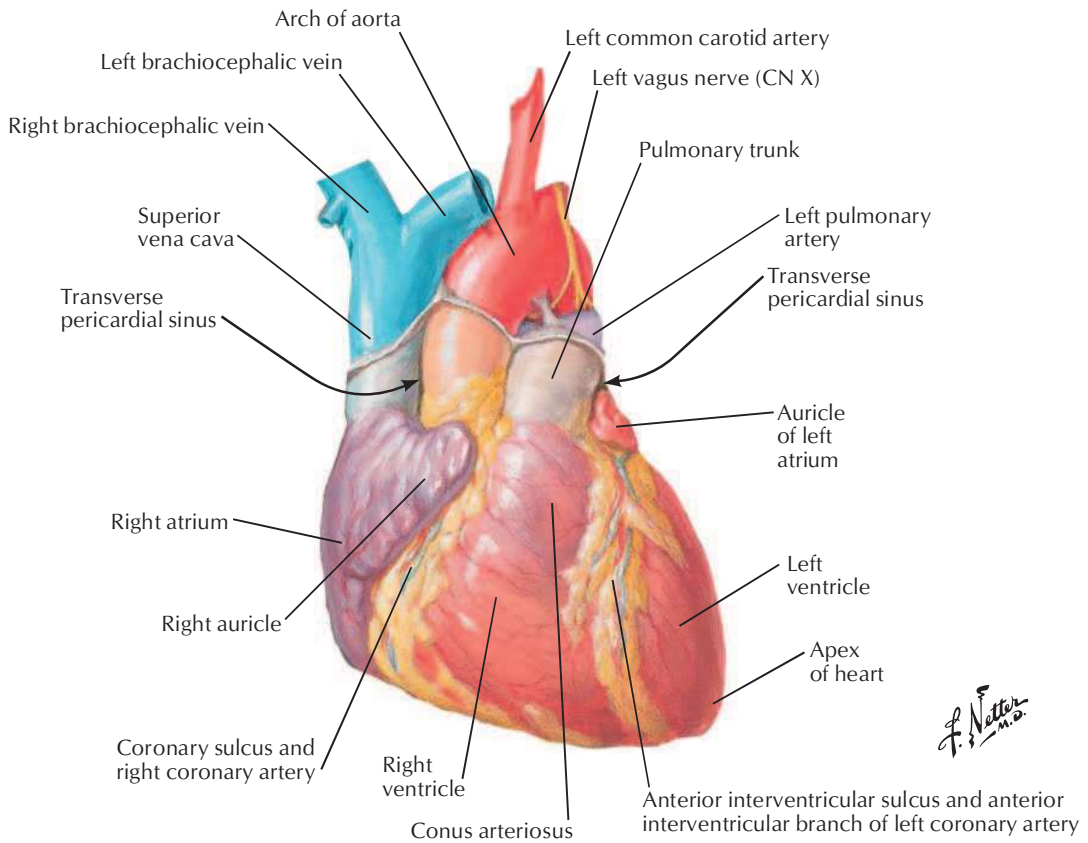
Pulmonary arteries and their branches distribute segmentally with the bronchi. Pulmonary veins and their tributaries drain intersegmentally.

Visceral pleura and subpleural capillaries

Capillary bed within alveolar wall (cut away in places)



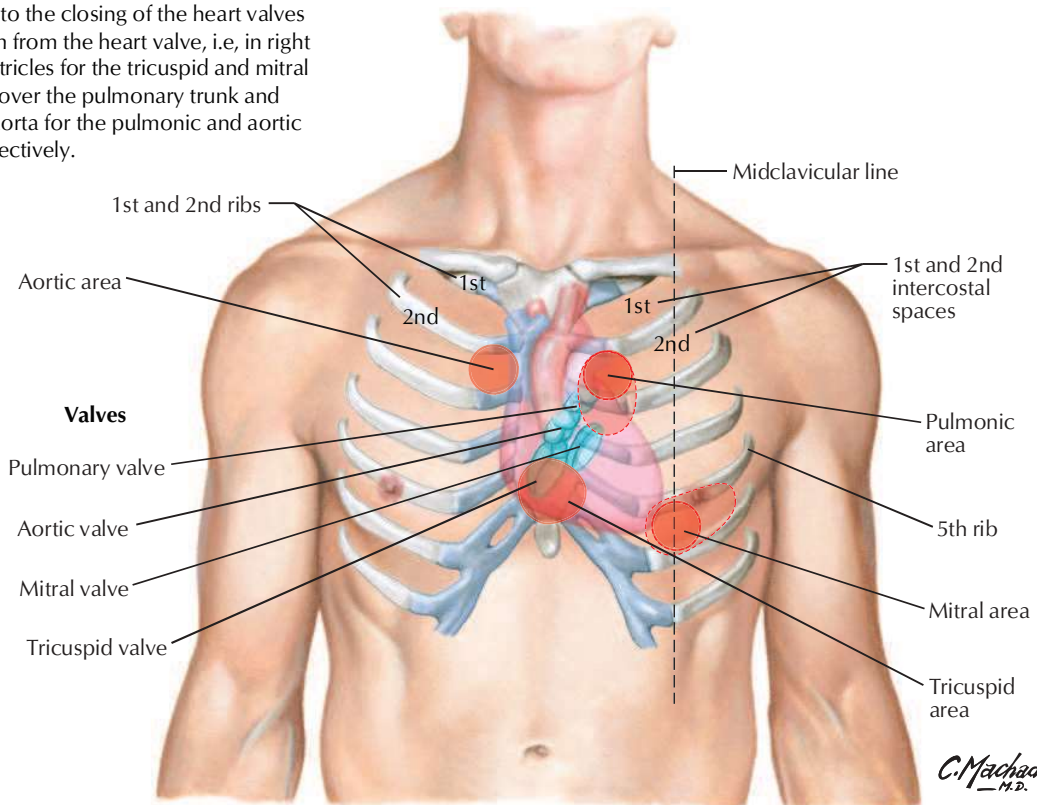
Anterior Aspect of Heart



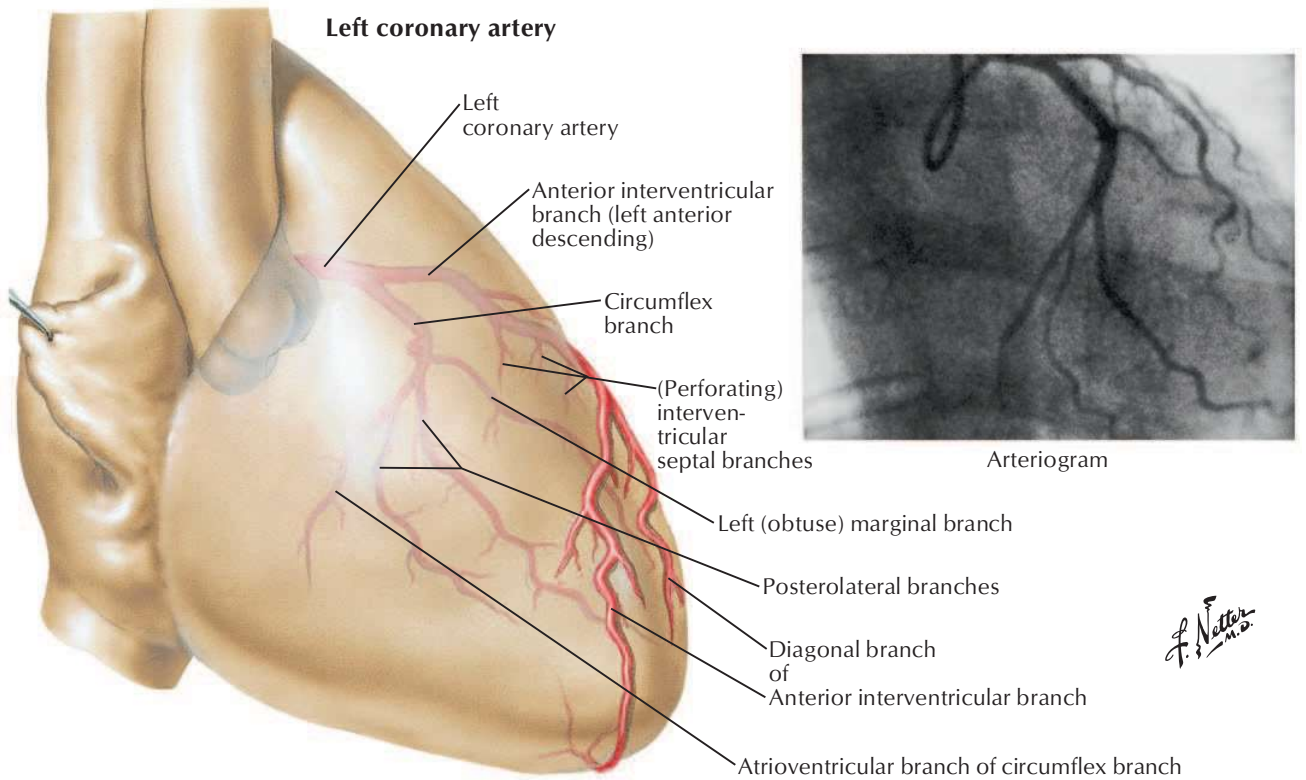
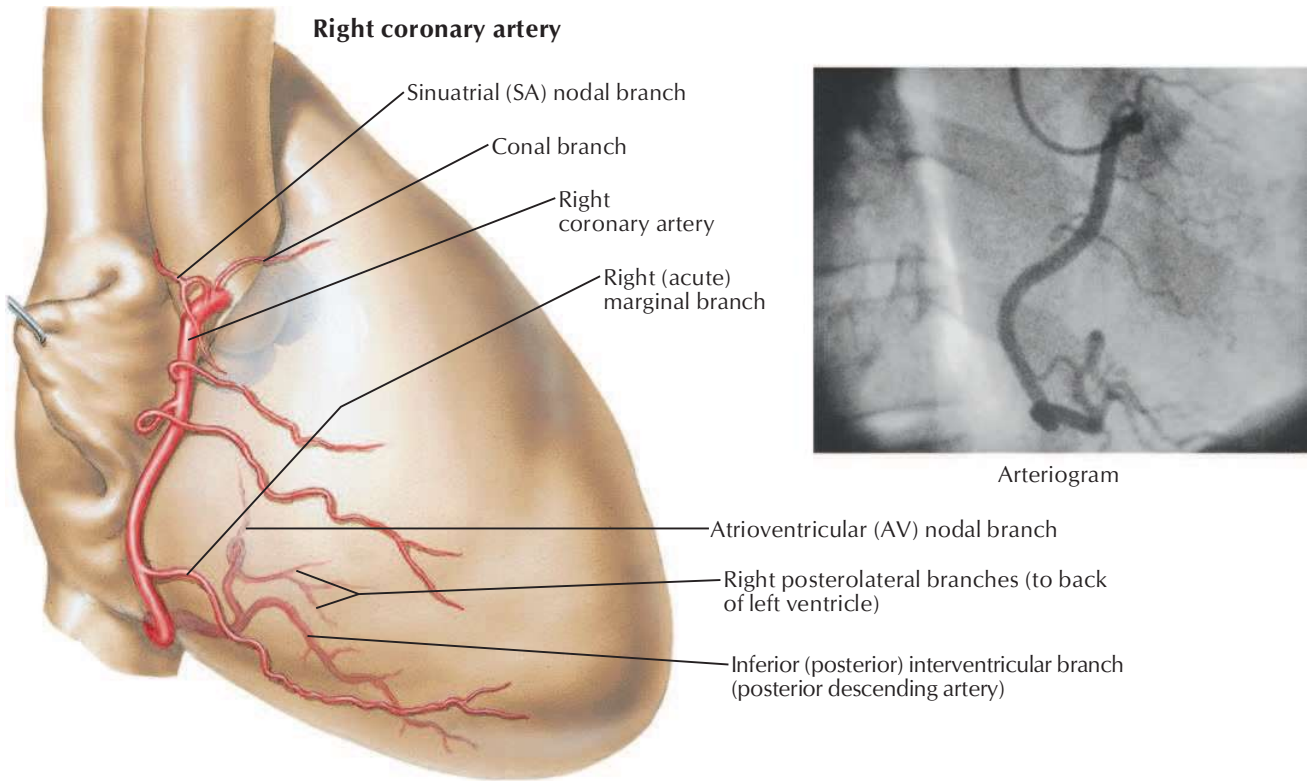
F. Netter M.D.

Precordial areas of auscultation:

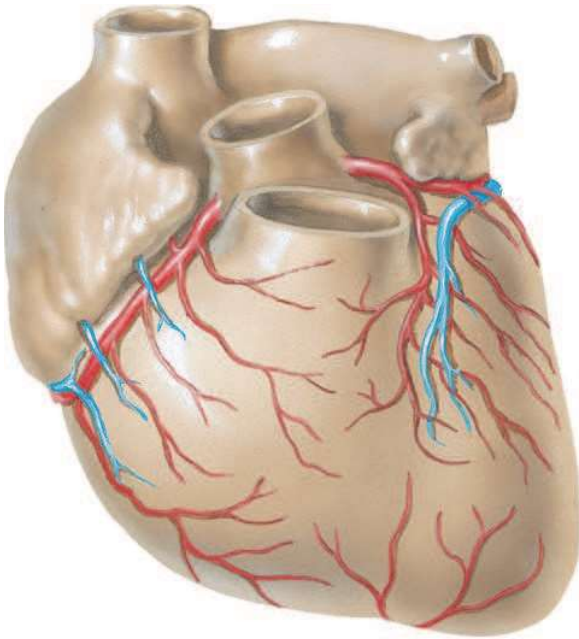
One listens to the closing of the heart valves downstream from the heart valve, i.e, in right and left ventricles for the tricuspid and mitral valves, and over the pulmonary trunk and ascending aorta for the pulmonic and aortic valves, respectively.



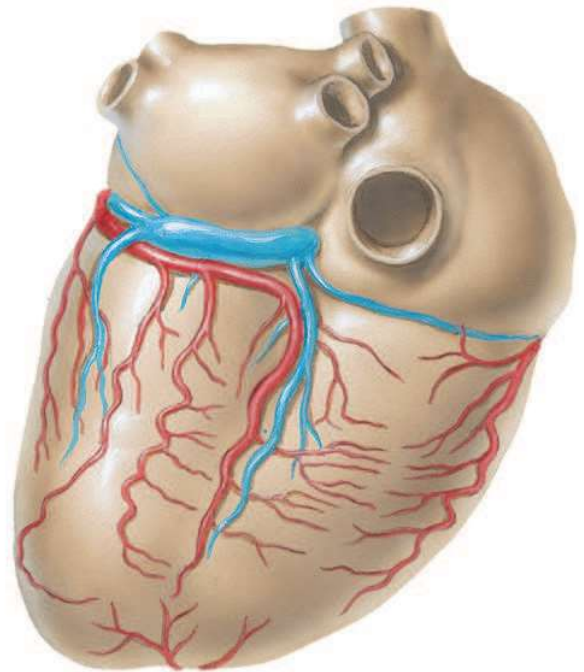
C. Machado M.D.



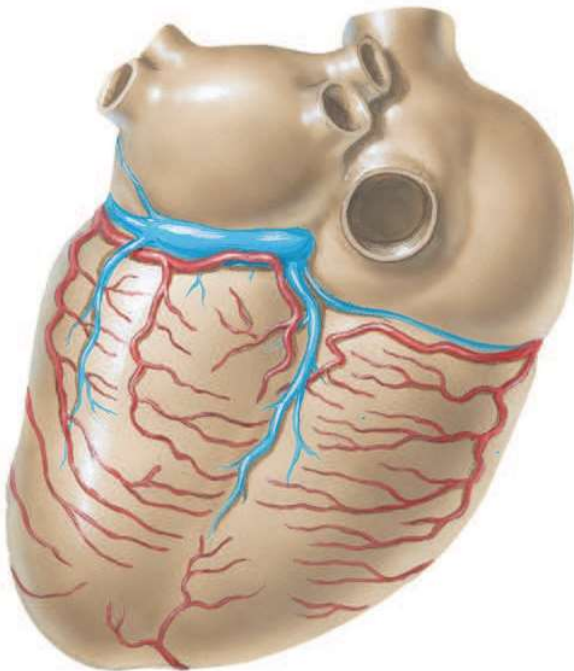
F. Netter M.D.



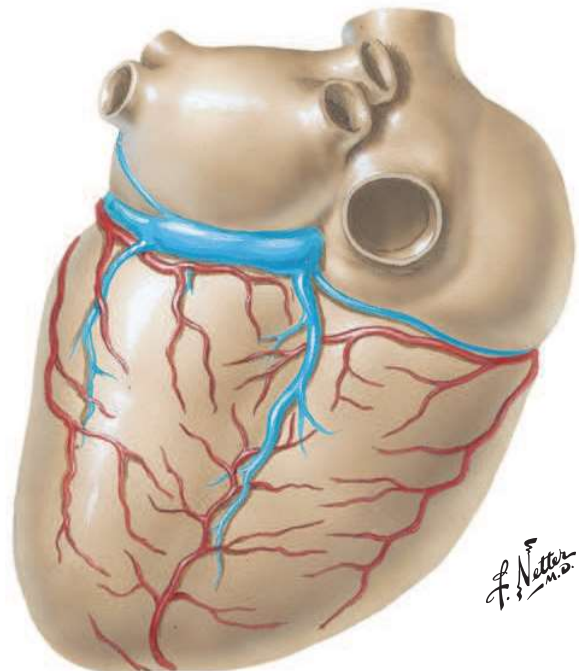
Anterior interventricular (left anterior descending) branch of left coronary artery is very short. Apical part of anterior (sternocostal) surface is supplied by branches from inferior interventricular (posterior descending) branch of right coronary artery curving around apex.



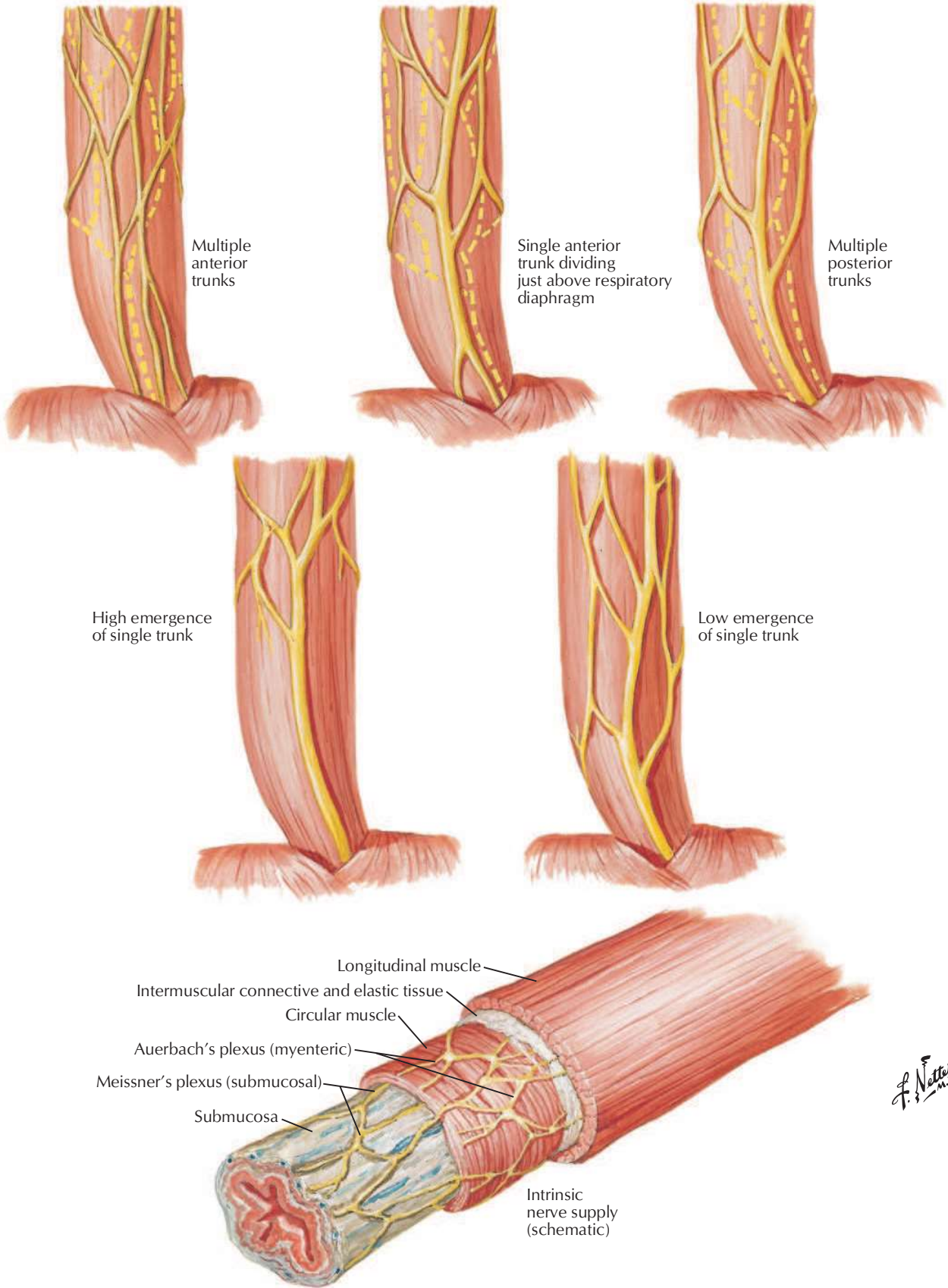
Inferior interventricular (posterior descending) branch is derived from circumflex branch of left coronary artery instead of from right coronary artery.

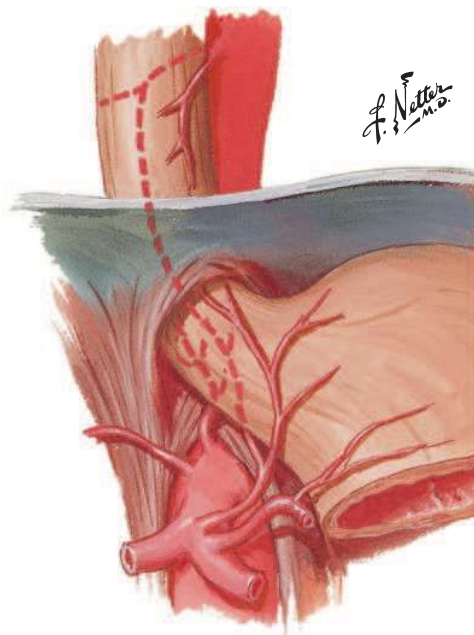


Inferior interventricular (posterior descending) branch is absent. Area is supplied chiefly by small branches from circumflex branch of left coronary artery and from right coronary artery.

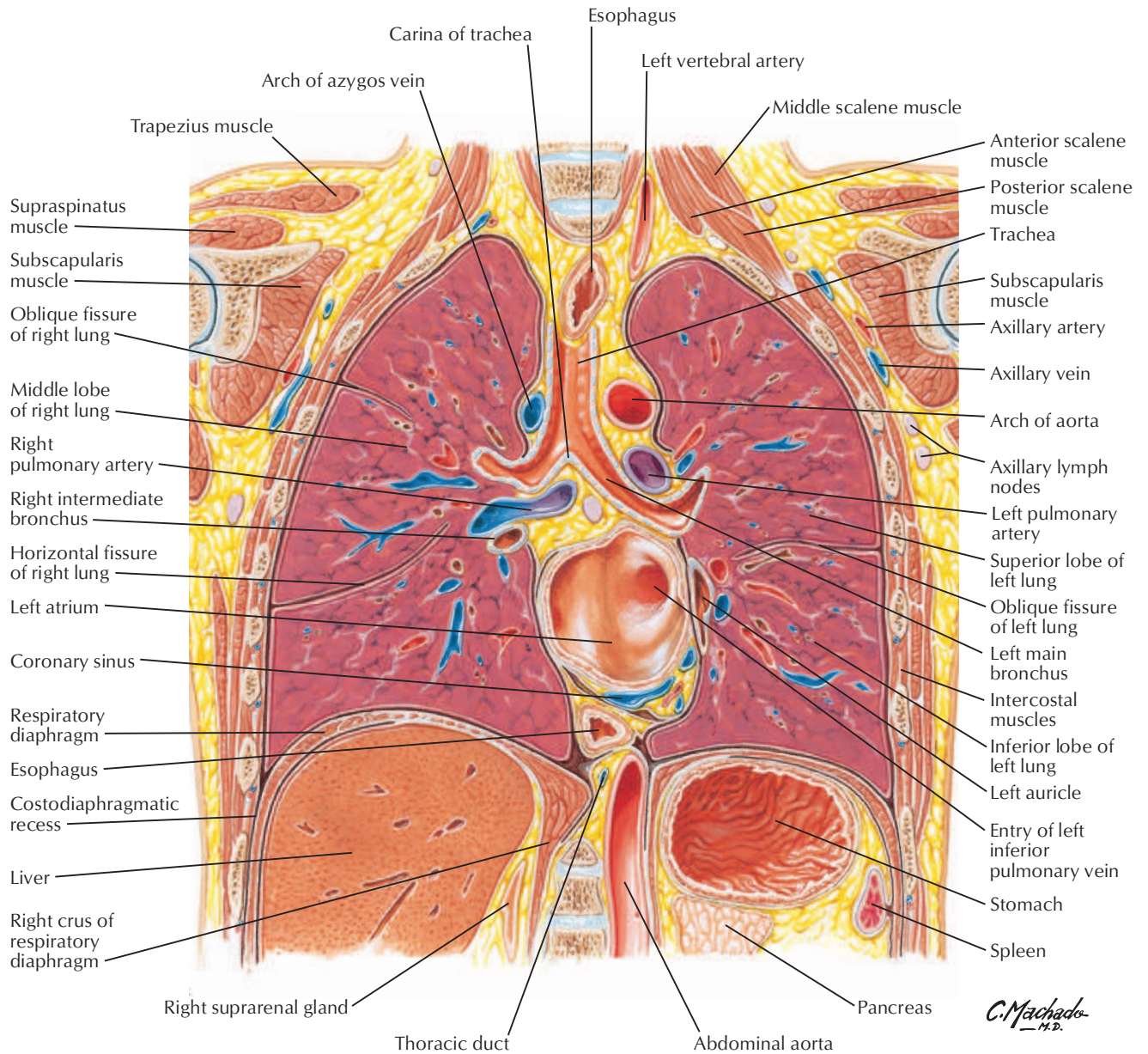


Inferior interventricular (posterior descending) branch is absent. Area is supplied chiefly by elongated anterior interventricular (left anterior descending) branch curving around apex.

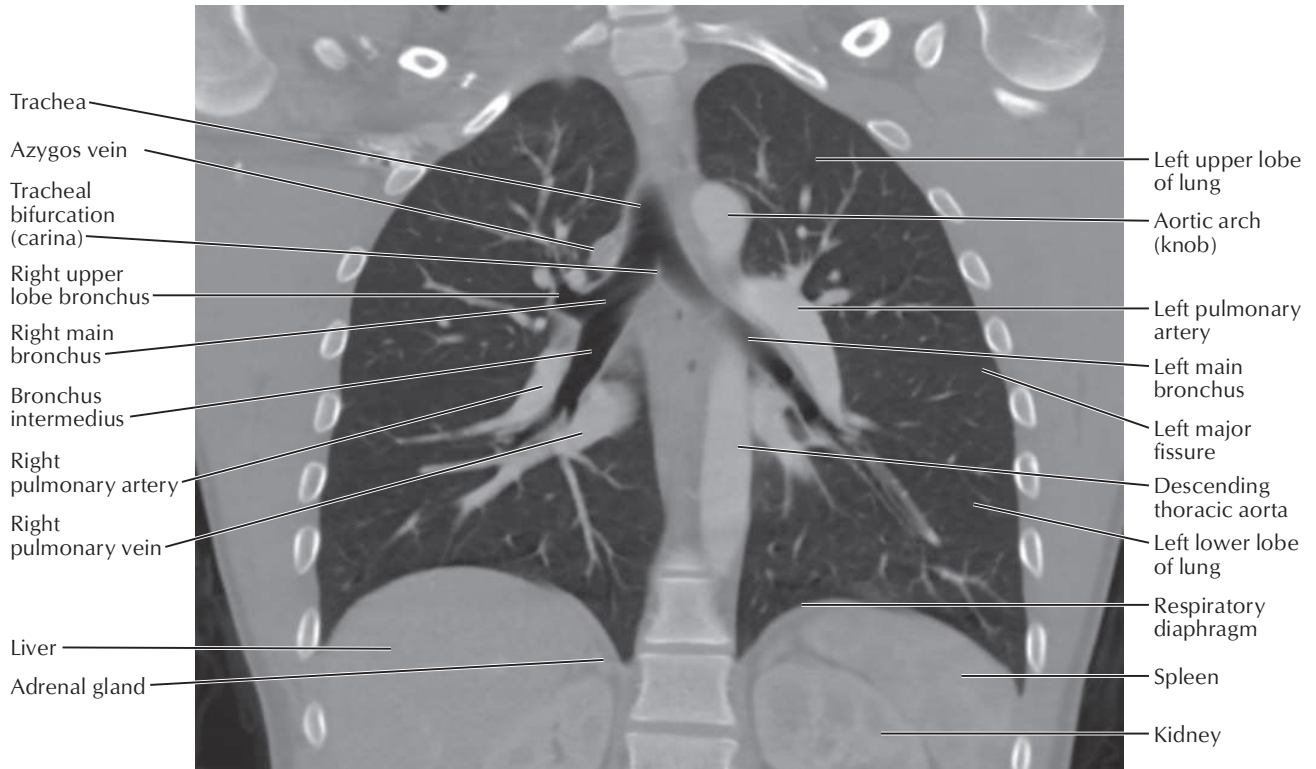




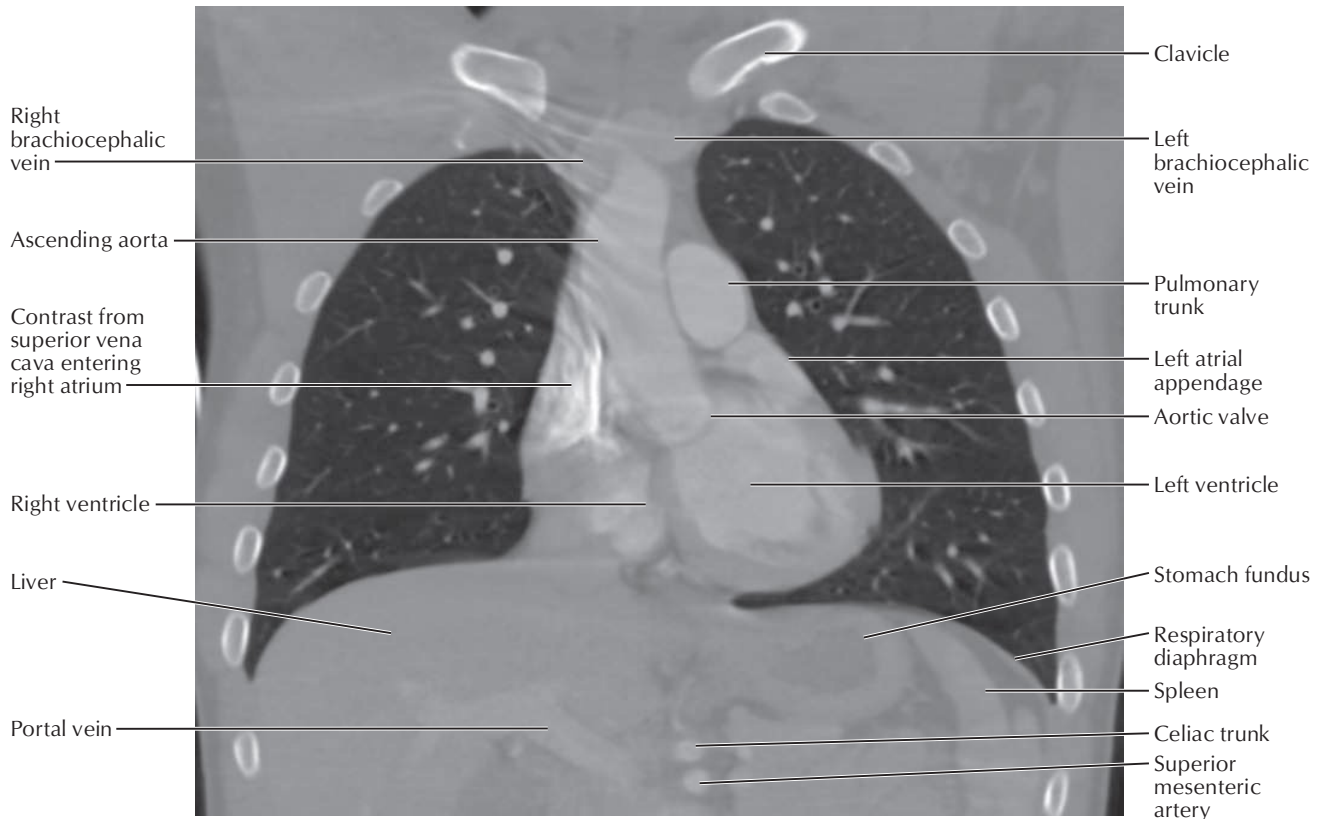Common variations: Esophageal branches may originate from left inferior phrenic artery and/or directly from celiac trunk. Branches to abdominal esophagus may also come from splenic or short gastric arteries.



Contrast windowed to accentuate lungs and bones



Contrast windowed to accentuate lungs and bones



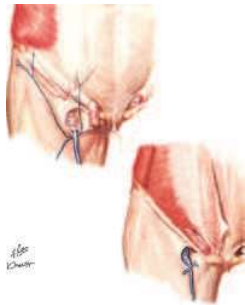This page intentionally left blank

ABDOMEN

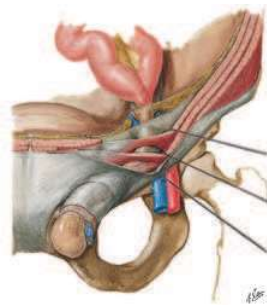
5

Surface Anatomy	249	Lymphatics	325
Body Wall	250-269	Regional Scans	326-327
Peritoneal Cavity	270-275	Cross-Sectional Anatomy	328-332
Viscera (Gut)	276-283	Structures with High Clinical Significance	Tables 5.1-5.2
Viscera (Accessory Organs)	284-289	Muscle Table	Table 5.3
Visceral Vasculature	290-299	Electronic Bonus Plates	BP58-BP87
Innervation	300-310		
Kidneys and Suprarenal Glands	311-324		

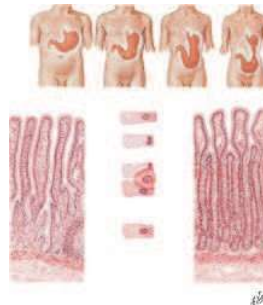
ELECTRONIC BONUS PLATES



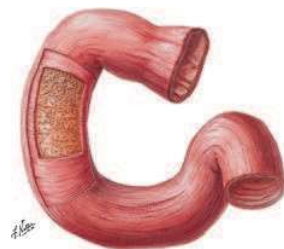
BP58 Inguinal and Femoral Regions



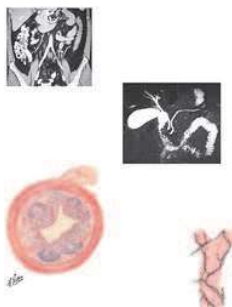
BP59 Indirect Inguinal Hernia



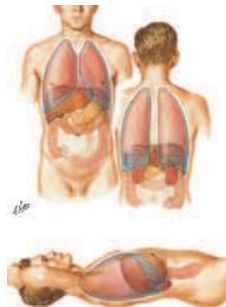BP60 Variations in Position and Contour of Stomach in Relation to Body Habitus



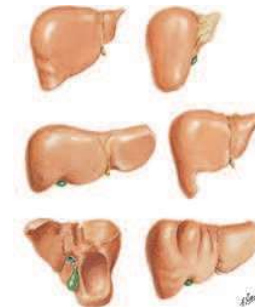
BP61 Layers of Duodenal Wall



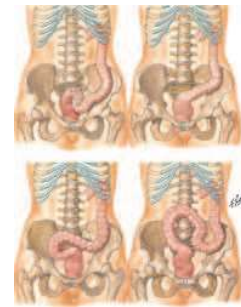BP62 CT and MRCP Showing Appendix, Gallbladder, and Ducts; Nerve Branches of Hepatic Artery



BP63 Topography of Liver

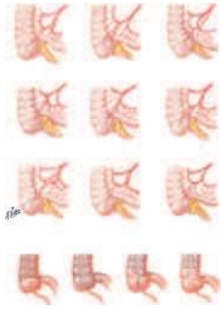


BP64 Variations in Form of Liver

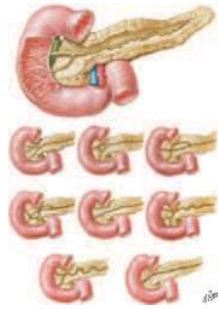


BP65 Sigmoid Colon: Variations in Position

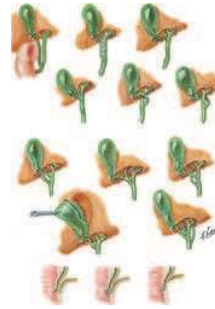ELECTRONIC BONUS PLATES—*cont'd*



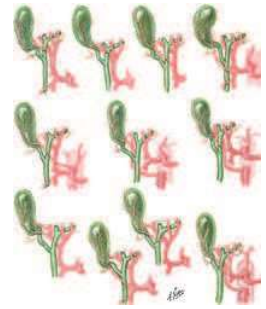
BP66 Variations in Arterial Supply to Cecum and Posterior Peritoneal Attachment of Cecum



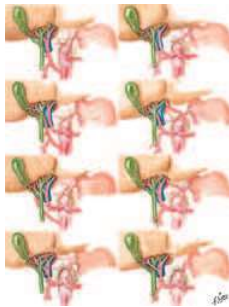BP67 Variations in Pancreatic Duct



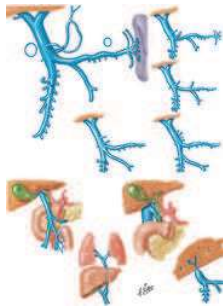
BP68 Variations in Cystic, Hepatic, and Pancreatic Ducts



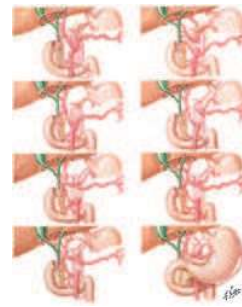BP69 Variations in Cystic Arteries



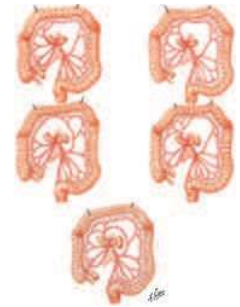
BP70 Variations in Hepatic Arteries



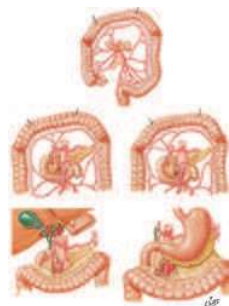
BP71 Variations and Anomalies of Hepatic Portal Vein



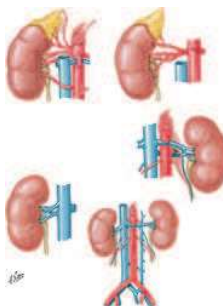
BP72 Variations in Celiac Trunk



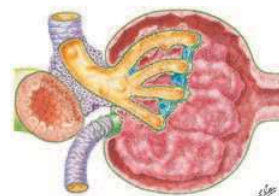
BP73 Variations in Colic Arteries



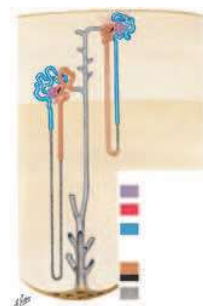
BP74 Variations in Colic Arteries (continued)



BP75 Variations in Renal Artery and Vein

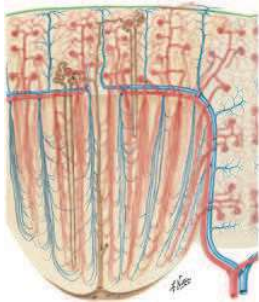


BP76 Histology of Renal Corpuscle

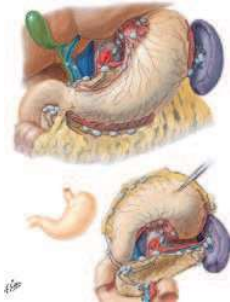


BP77 Nephron and Collecting Tubule: Schema

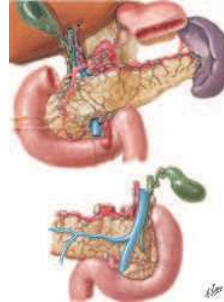
ELECTRONIC BONUS PLATES—*cont'd*



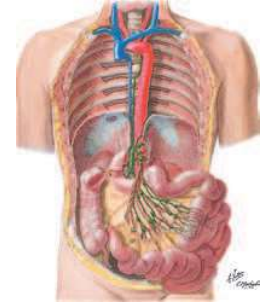
BP78 Blood Vessels in Parenchyma of Kidney: Schema



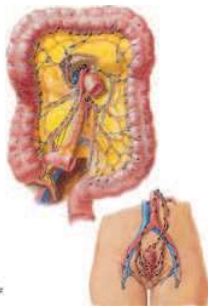
BP79 Lymph Vessels and Nodes of Stomach



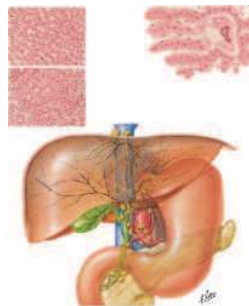
BP80 Lymph Vessels and Nodes of Pancreas



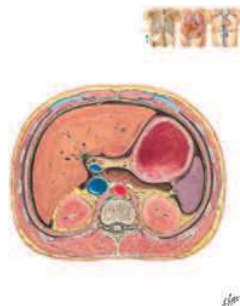BP81 Lymph Vessels and Nodes of Small Intestine



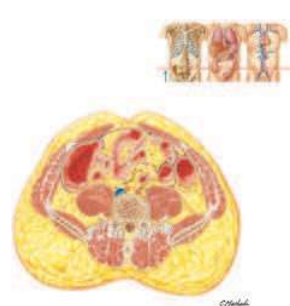BP82 Lymph Vessels and Nodes of Large Intestine



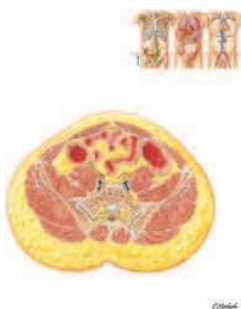BP83 Lymph Vessels and Nodes of Liver



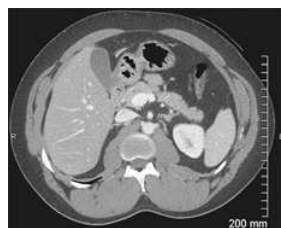BP84 Schematic Cross Section of Abdomen at Middle T12



BP85 Transverse Section of Abdomen: Level of L5, Near Transtubercular Plane



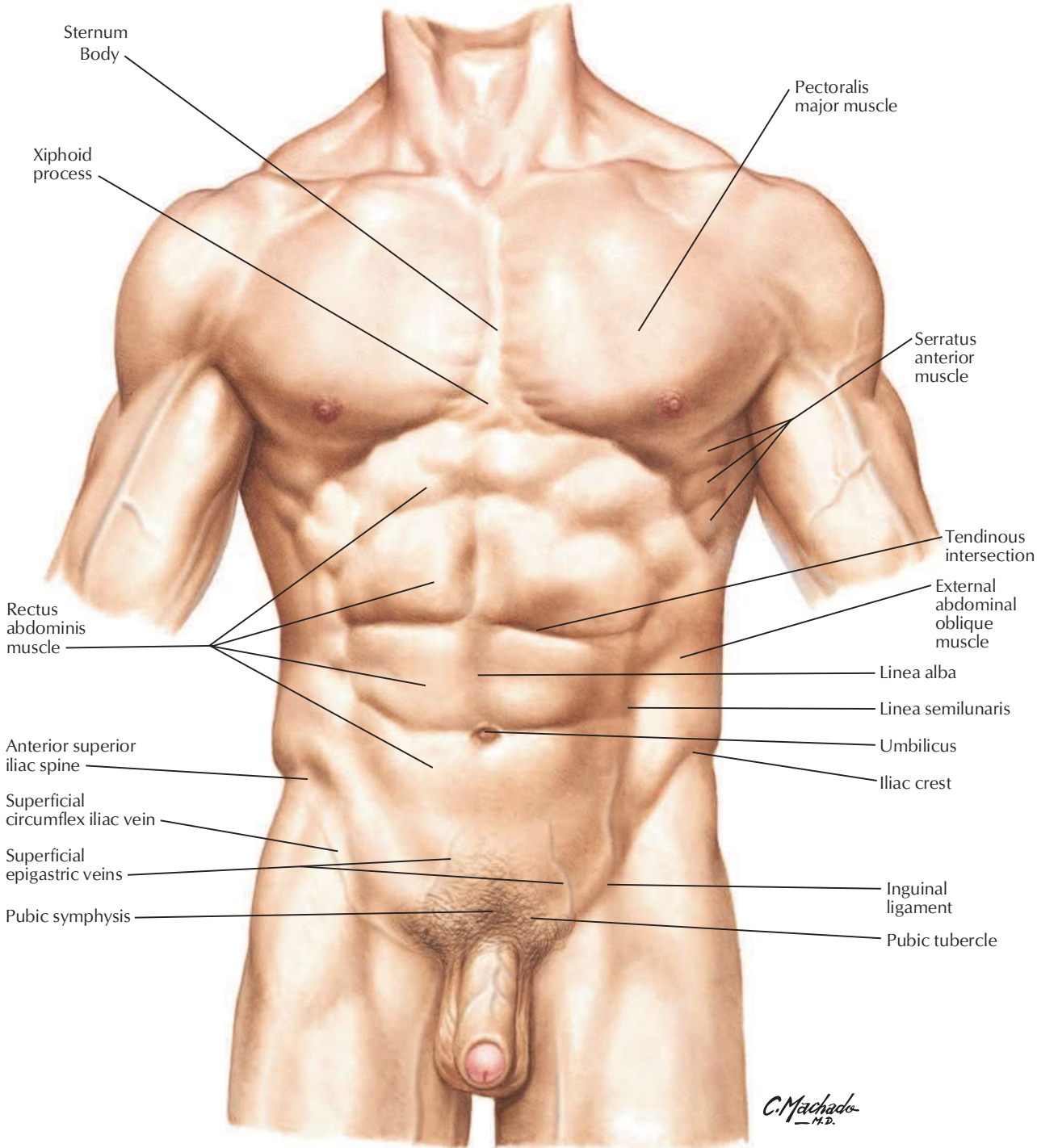
BP86 Transverse Section of Abdomen: Level of S1, Anterior Superior Iliac Spine



BP87 Axial CT Image of Upper Abdomen

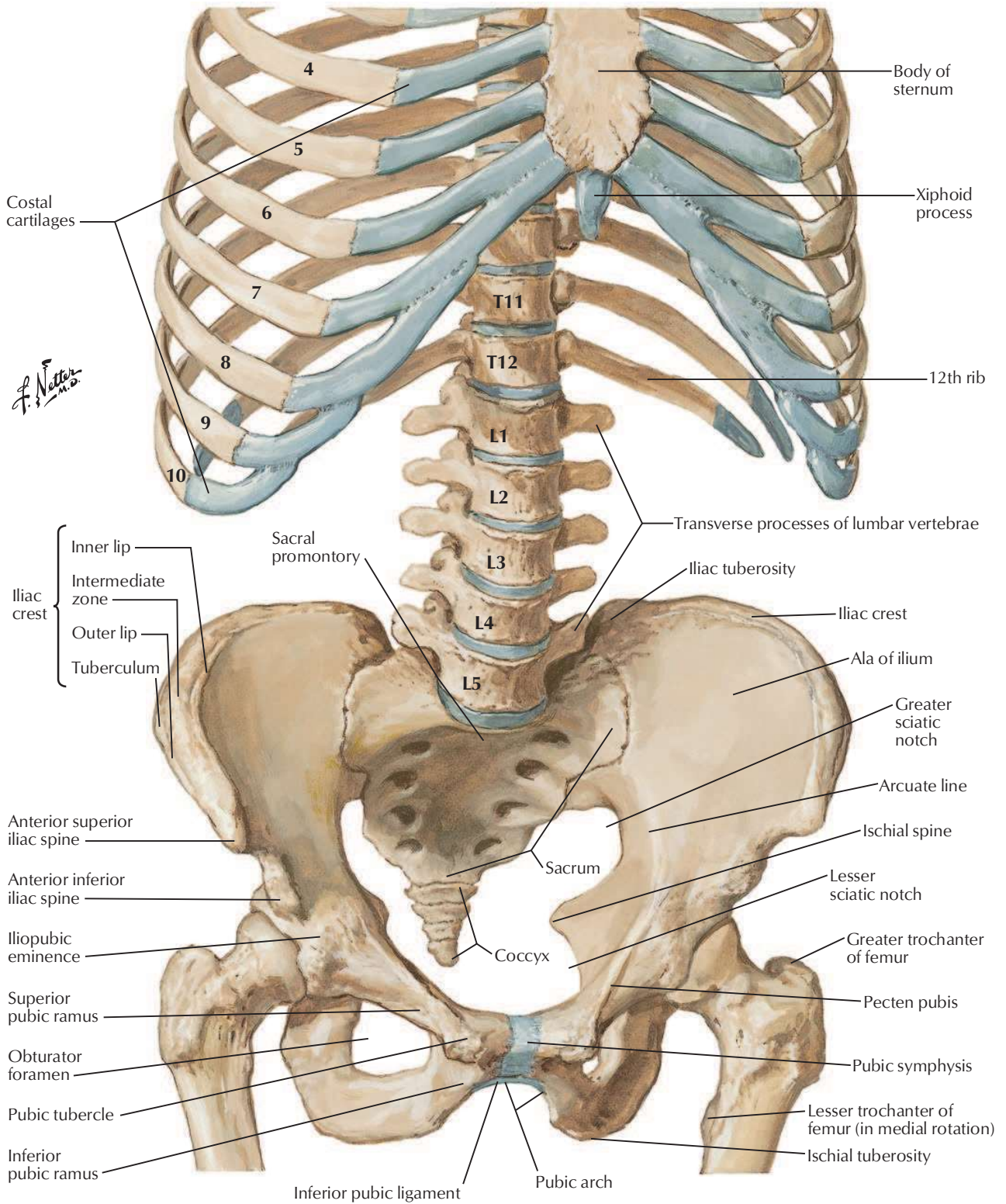
This page intentionally left blank

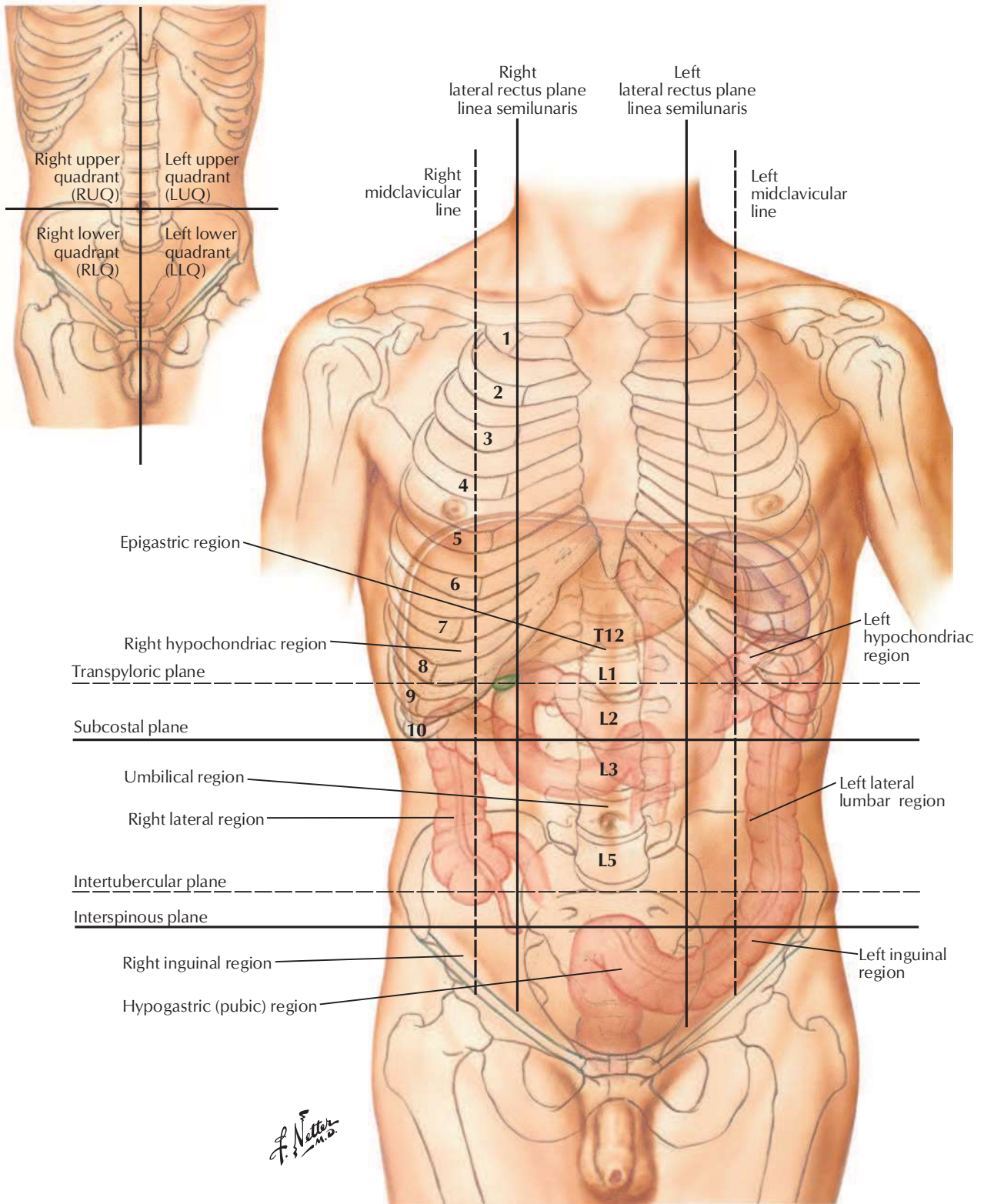
See also Plates 171, 252



Bony Framework of Abdomen

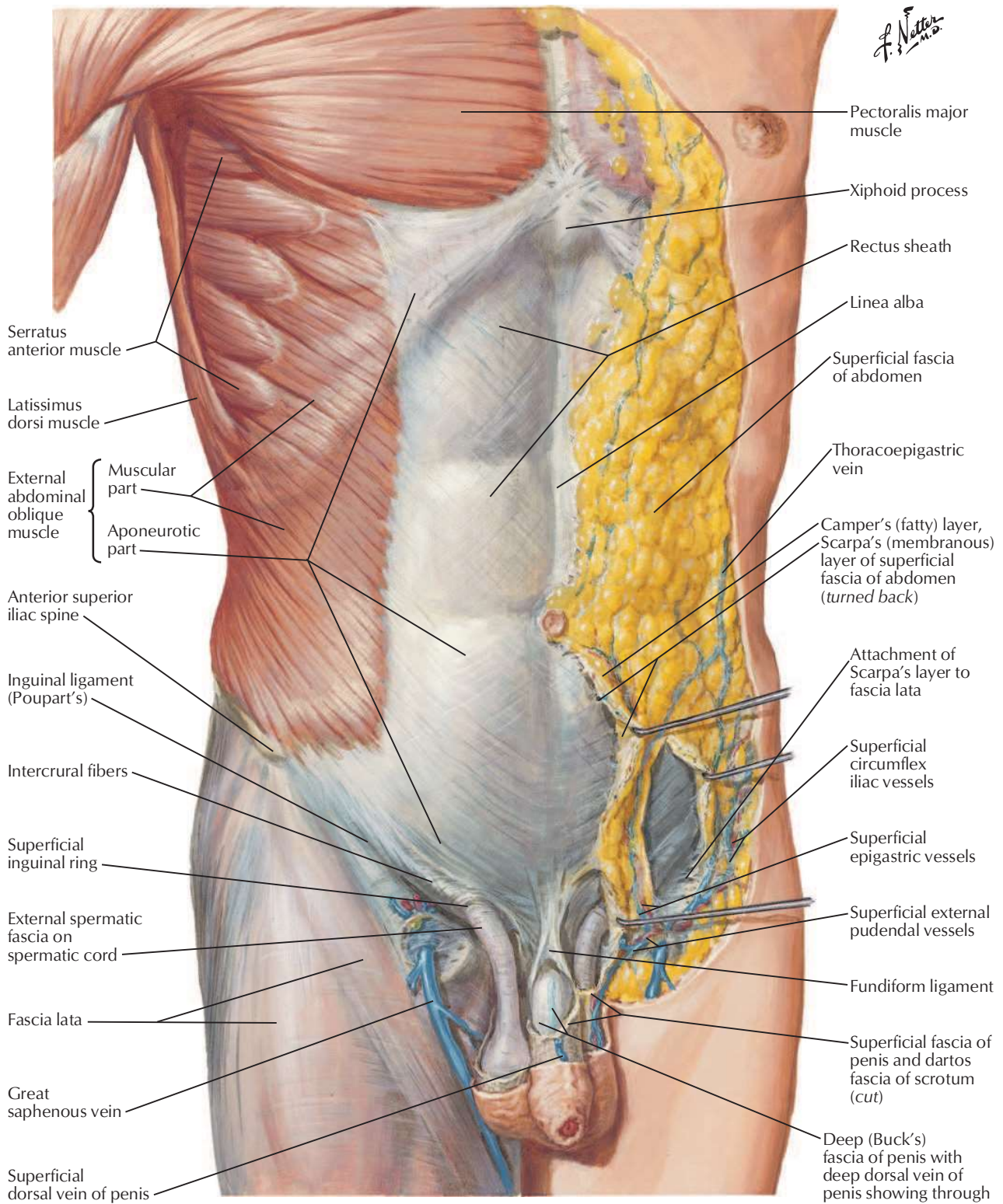
See also [Plates 192, 334](#)





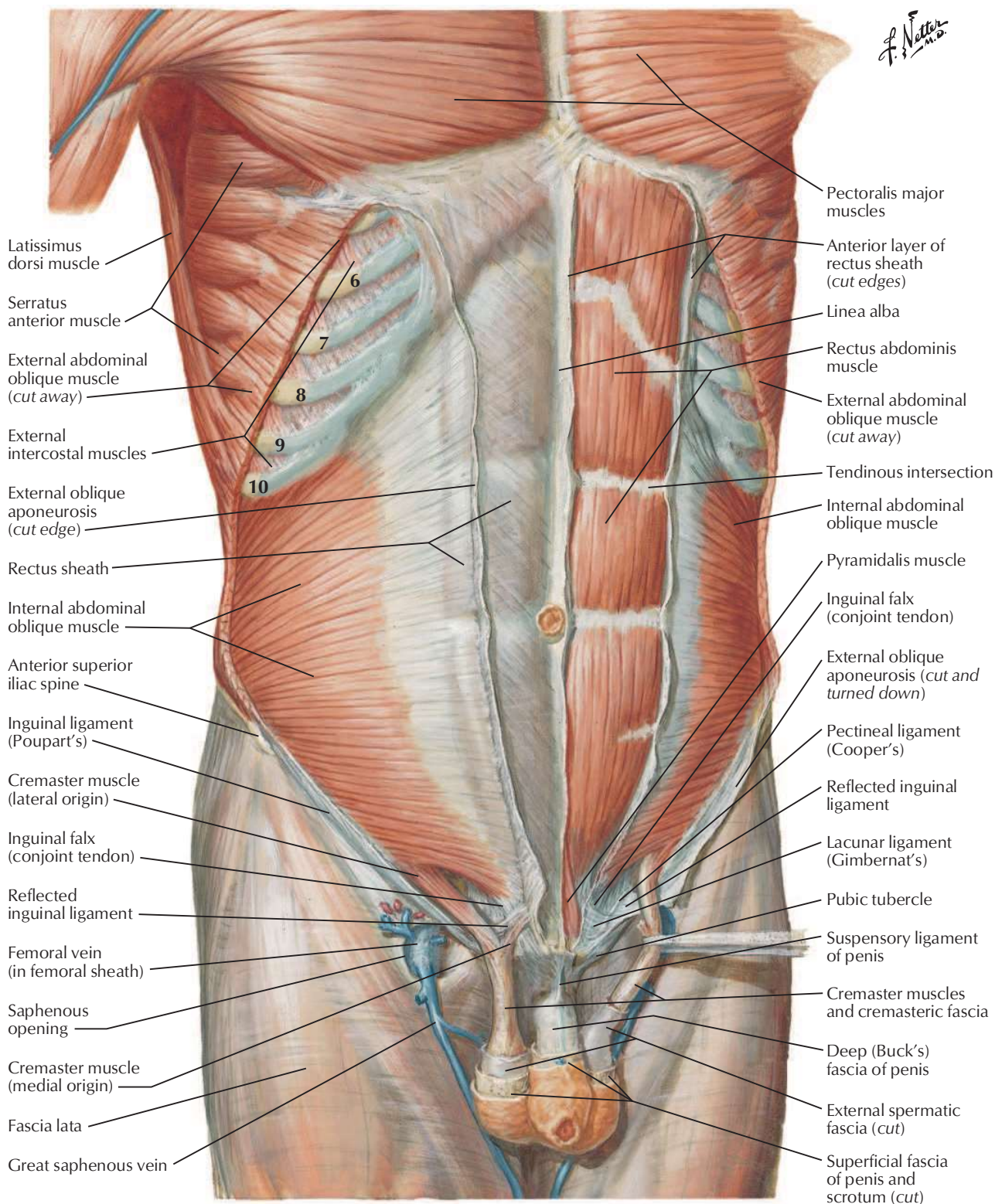
Anterior Abdominal Wall: Superficial Dissection

See also [Plates 259, 333](#)



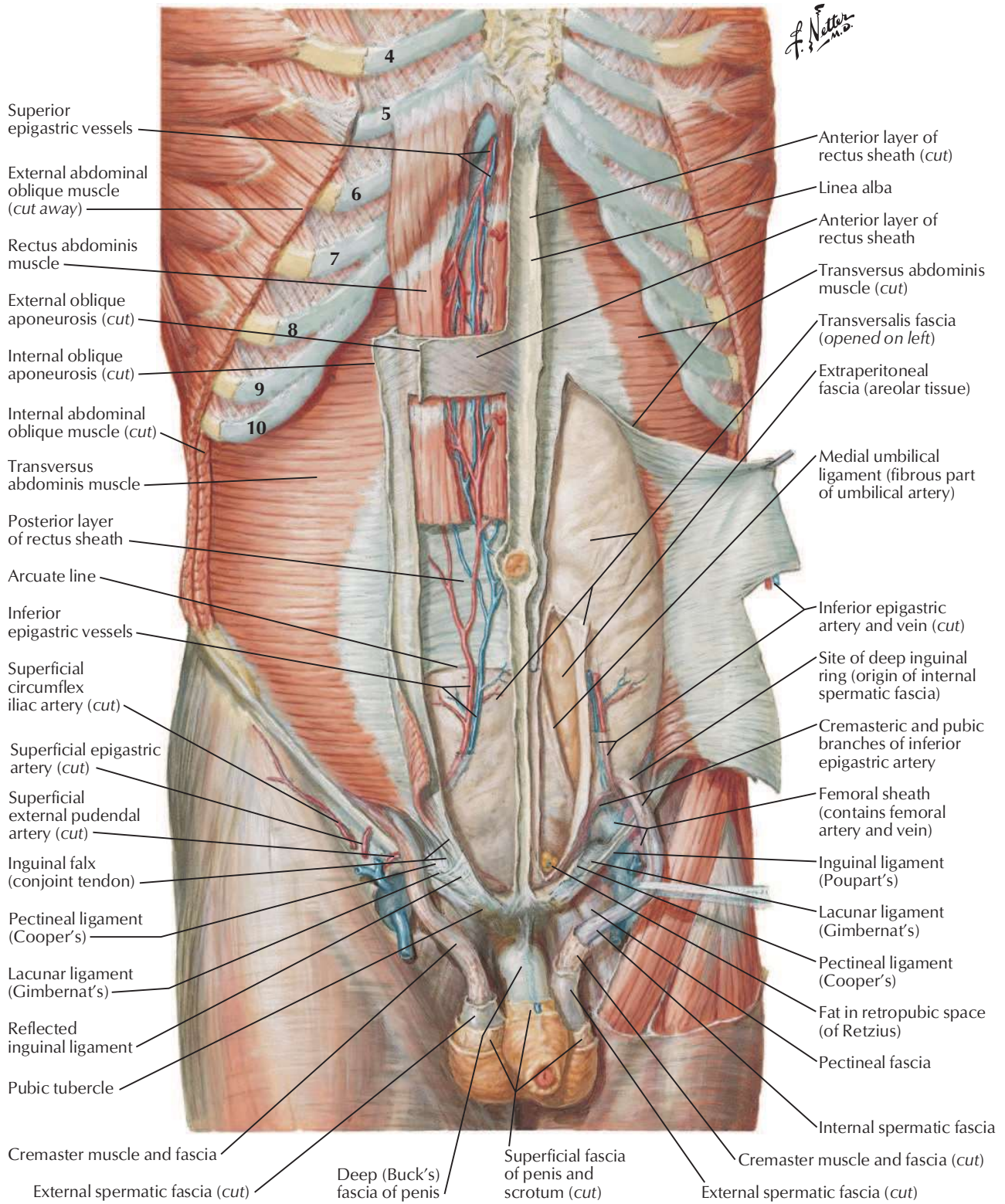
See also [Plates 194, 195](#)

F. Netter M.D.

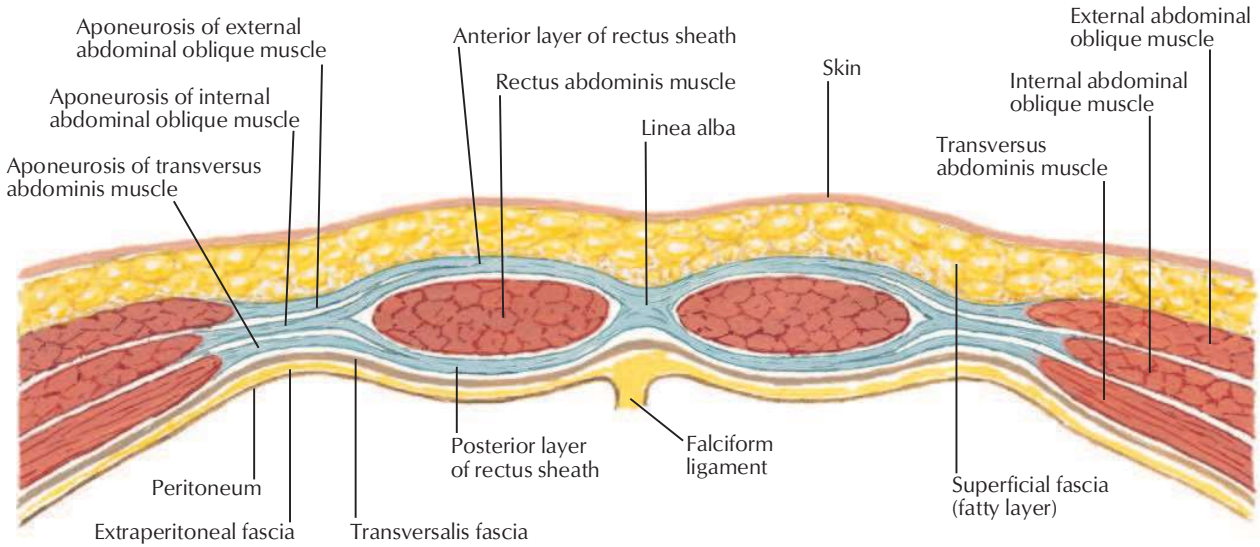


Anterior Abdominal Wall: Deep Dissection

See also [Plates 195, 258](#)

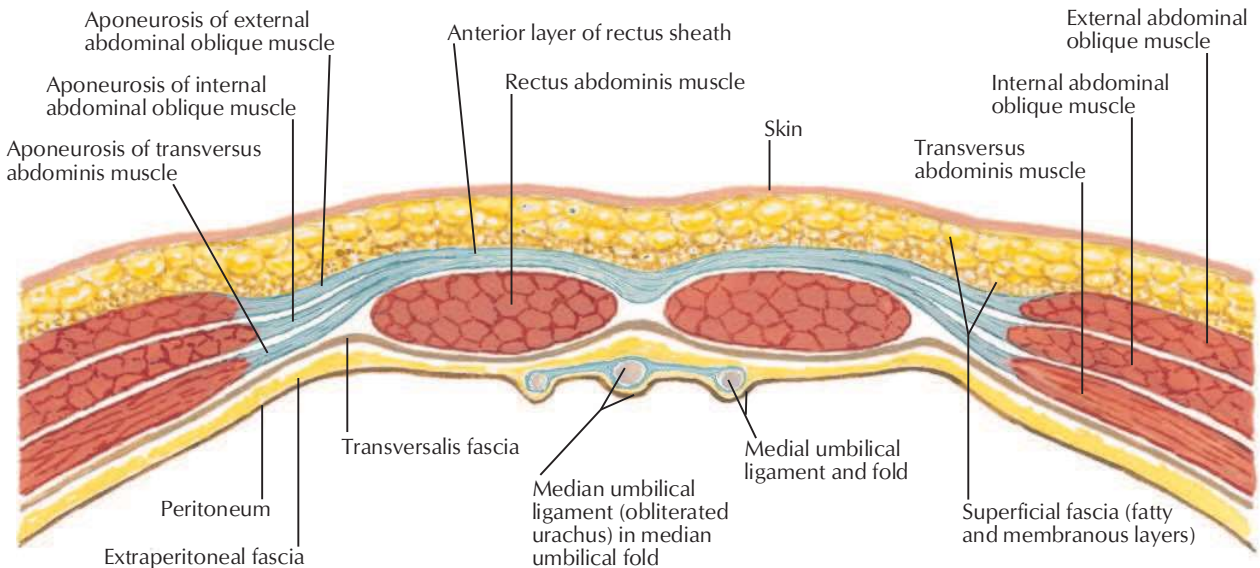


Section above arcuate line



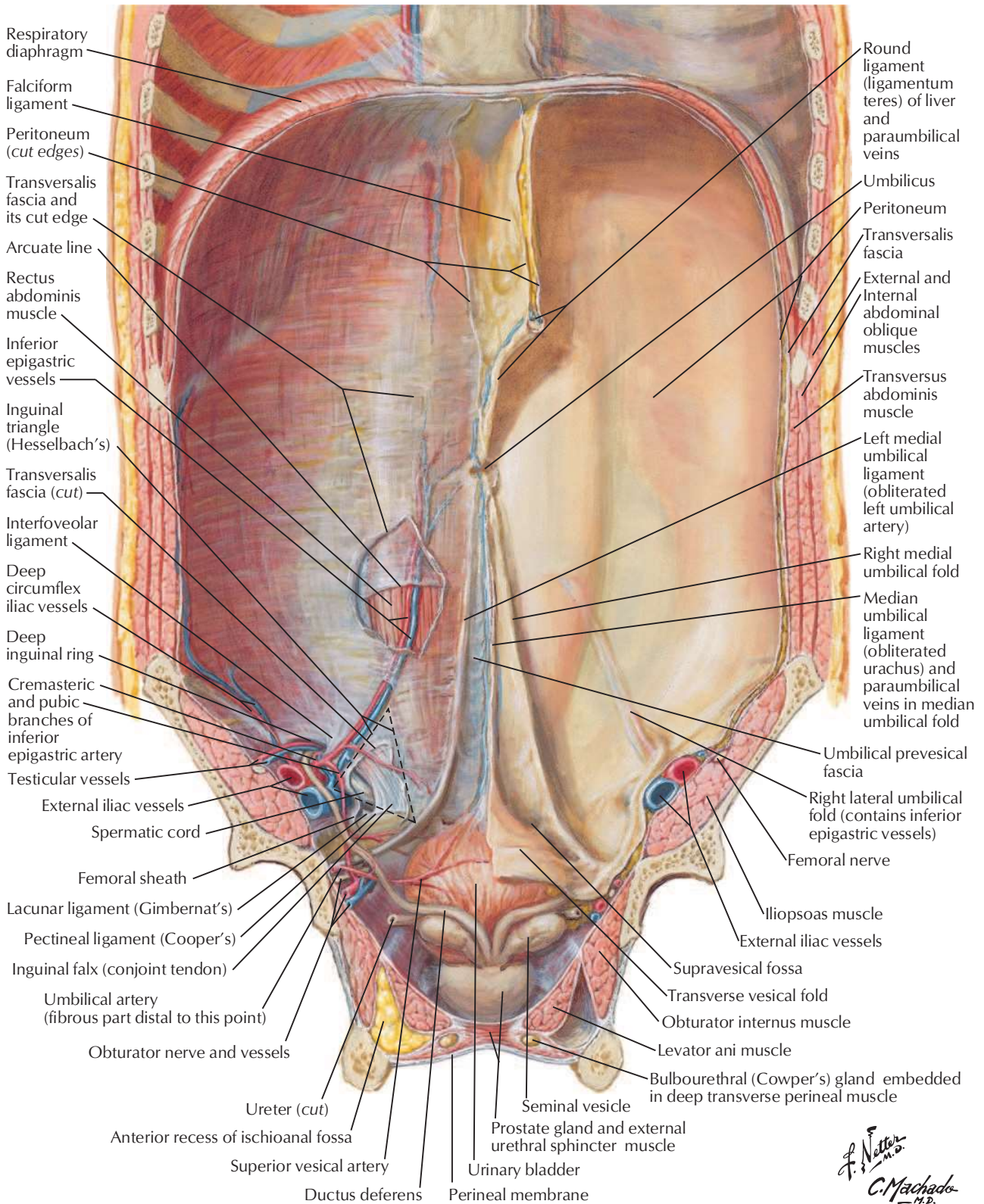
Aponeurosis of internal abdominal oblique muscle splits to form anterior and posterior layers of rectus sheath. Aponeurosis of external abdominal oblique muscle joins anterior layer of sheath; aponeurosis of transversus abdominis muscle joins posterior layer. Anterior and posterior layers of rectus sheath unite medially to form linea alba.

Section below arcuate line

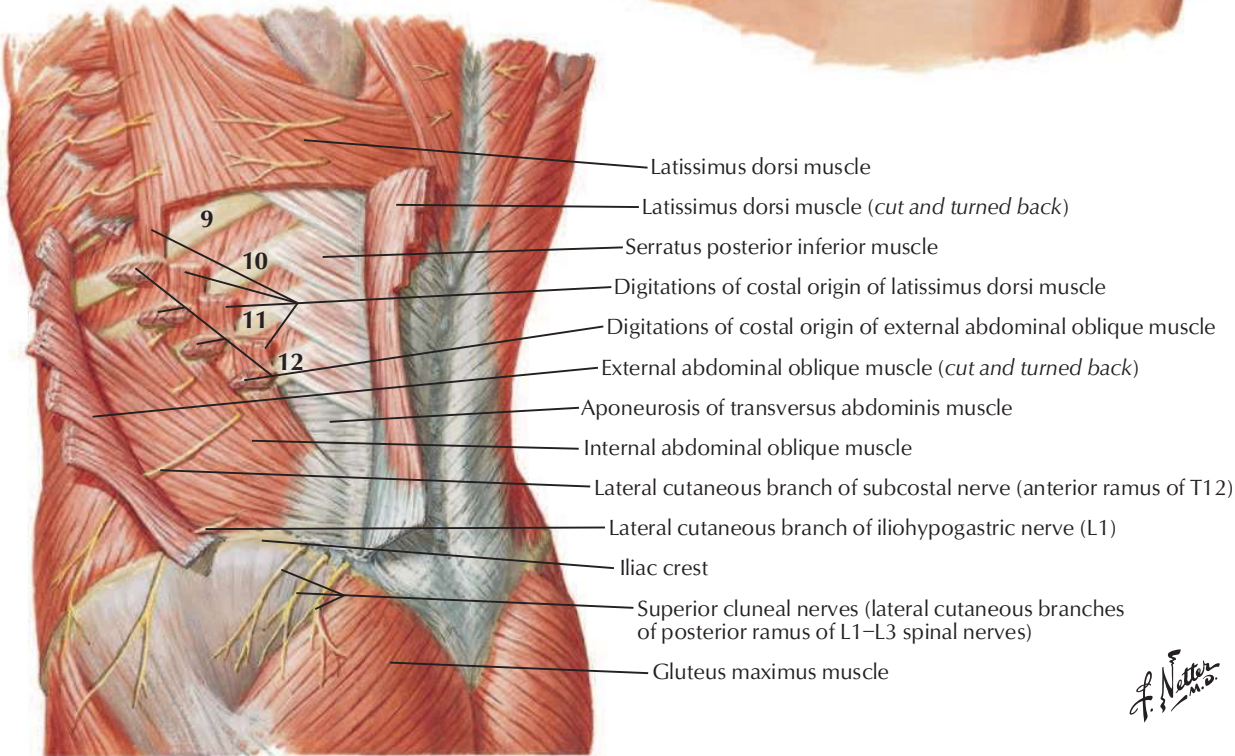
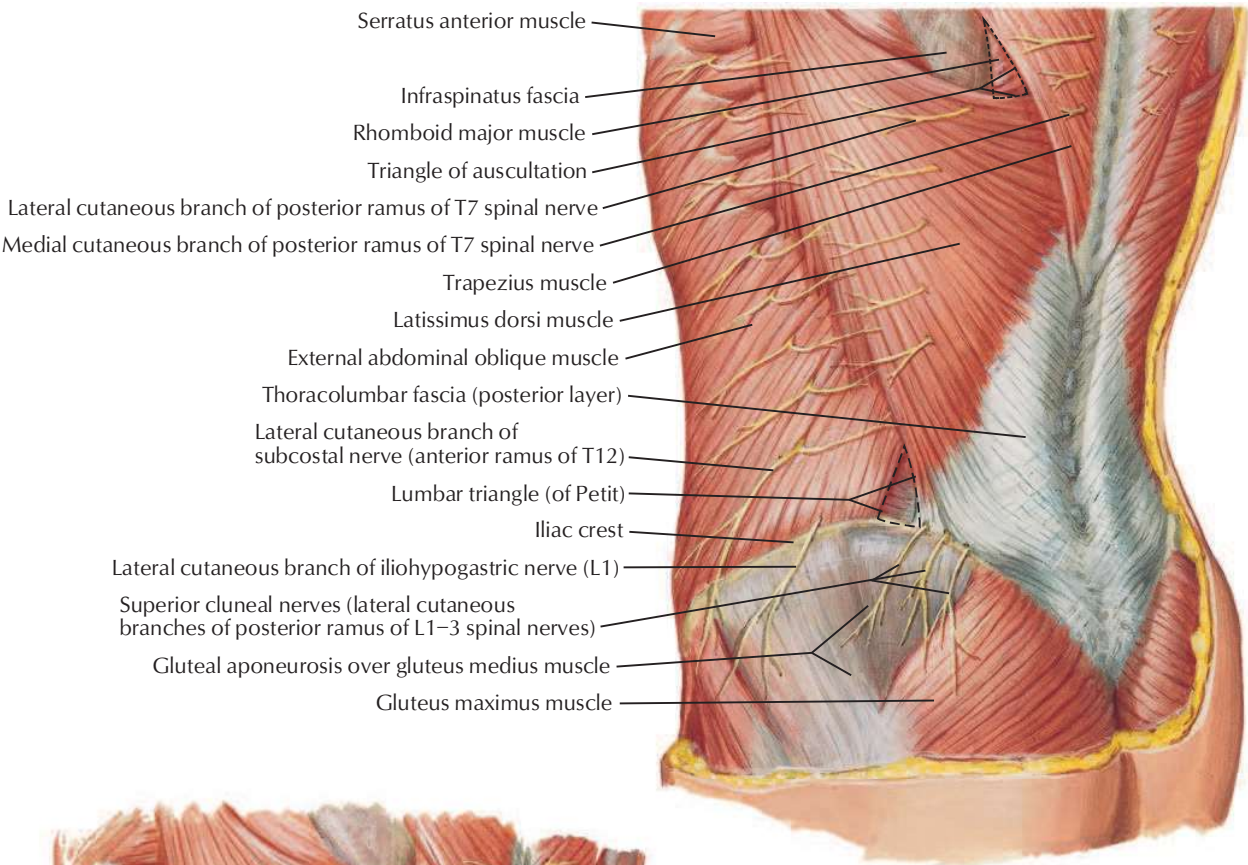


Aponeurosis of internal abdominal oblique muscle does not split at this level but passes completely anterior to rectus abdominis muscle and is fused there with both aponeurosis of external abdominal oblique muscle and that of transversus abdominis muscle. Thus, posterior wall of rectus sheath is absent below arcuate line, leaving only transversalis fascia.

F. Netter M.D.



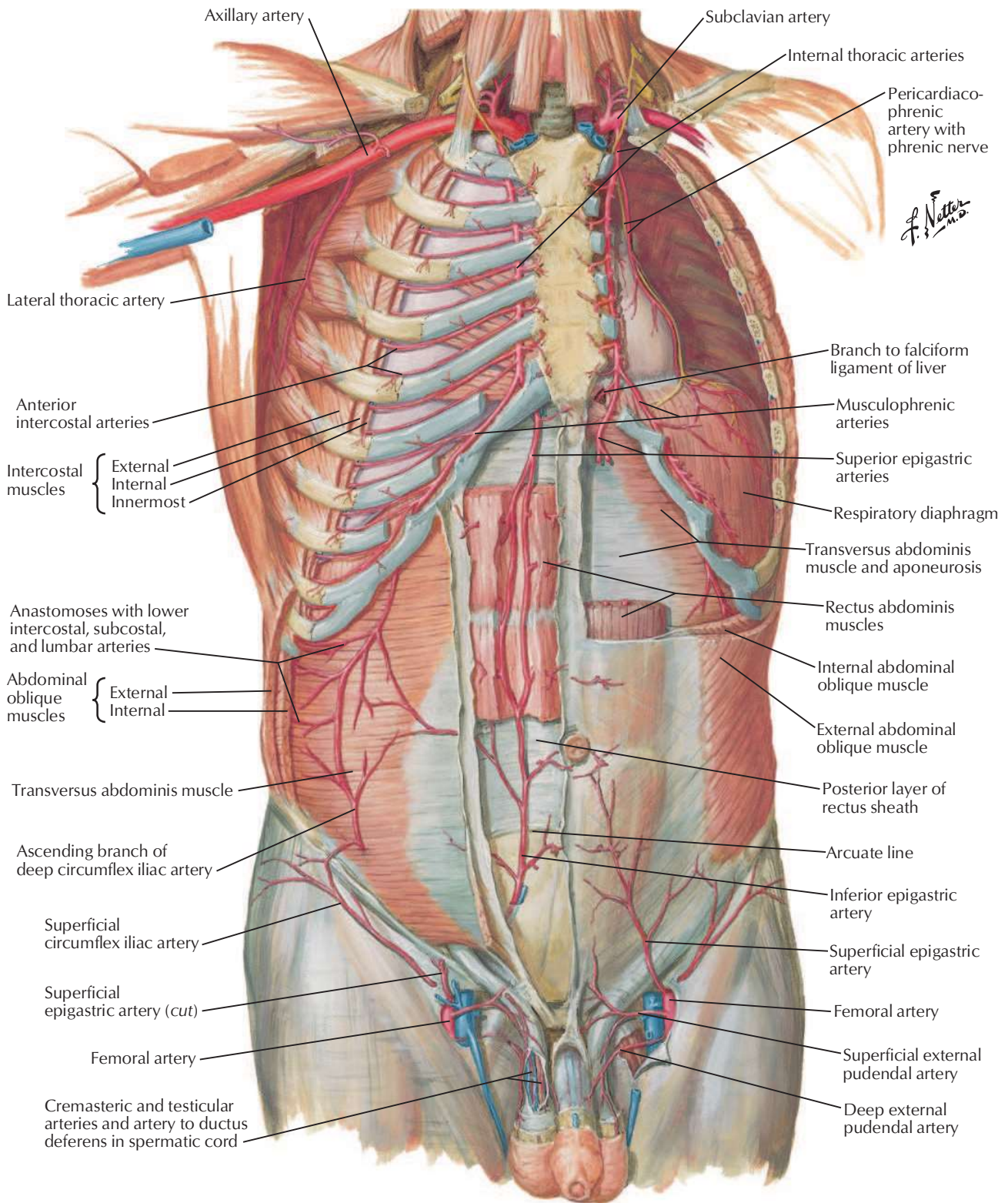
F. Netter
M.D.
C. Machado
M.D.



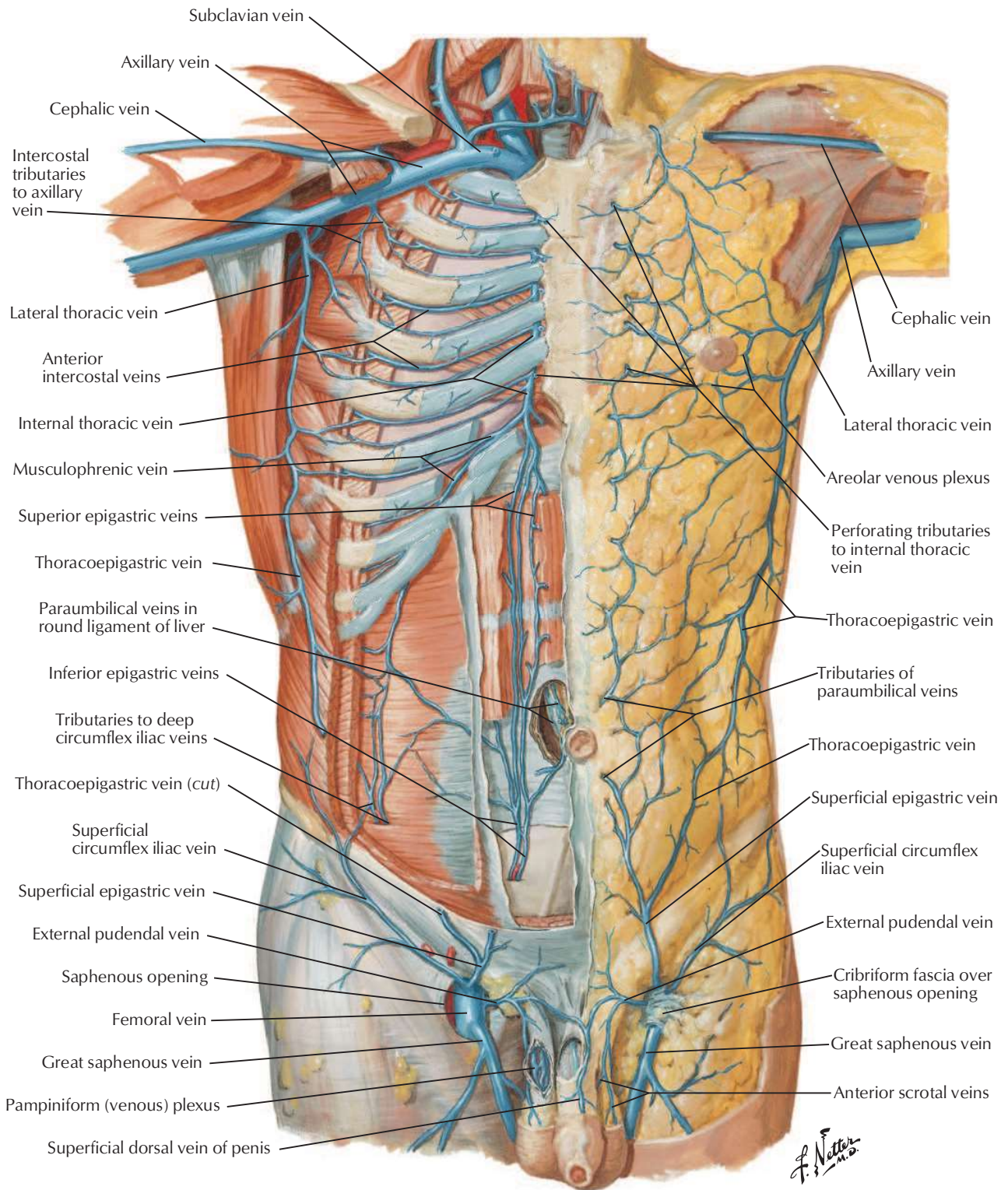
F. Netter M.D.

Arteries of Anterior Abdominal Wall

See also [Plate 254](#)

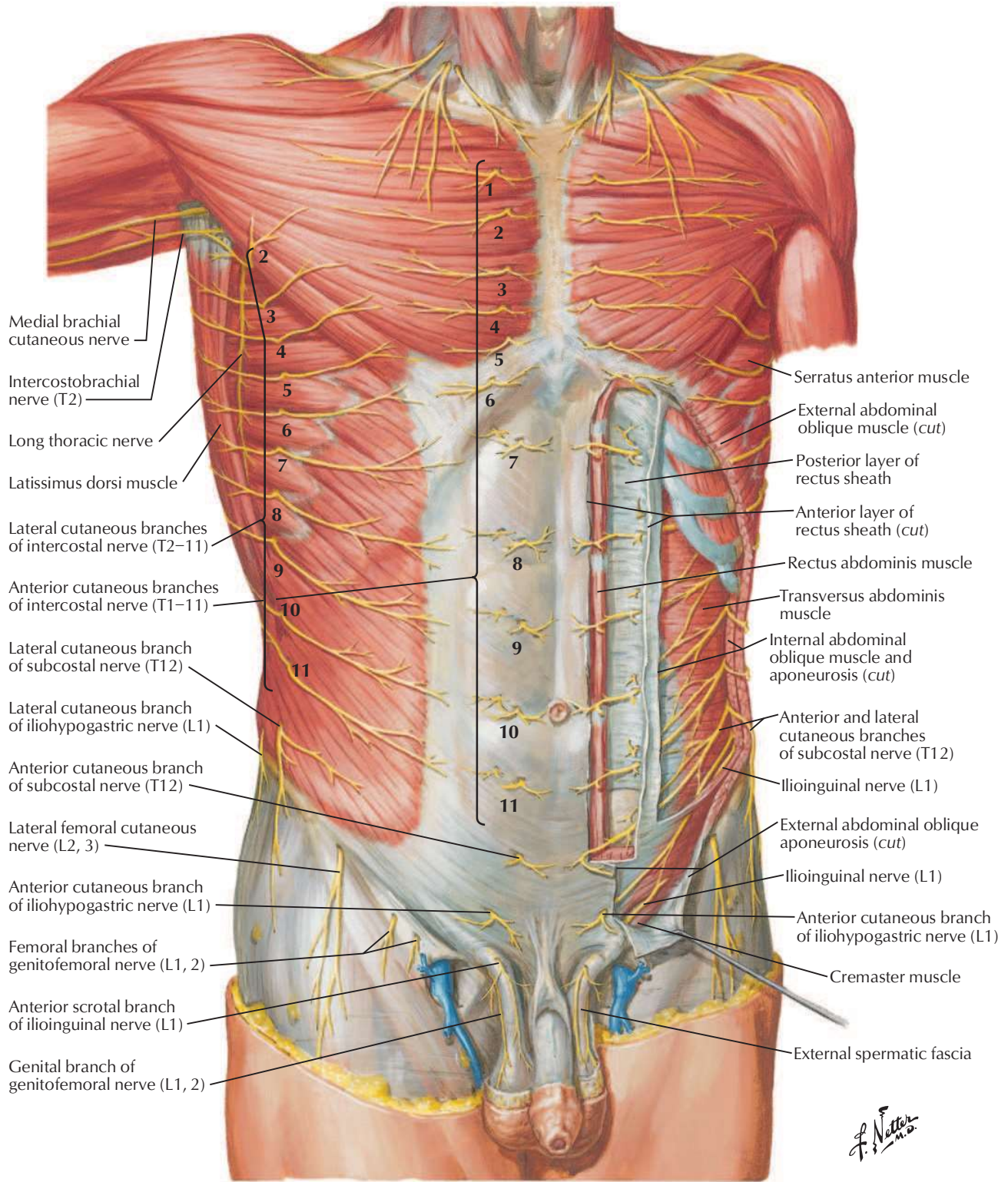


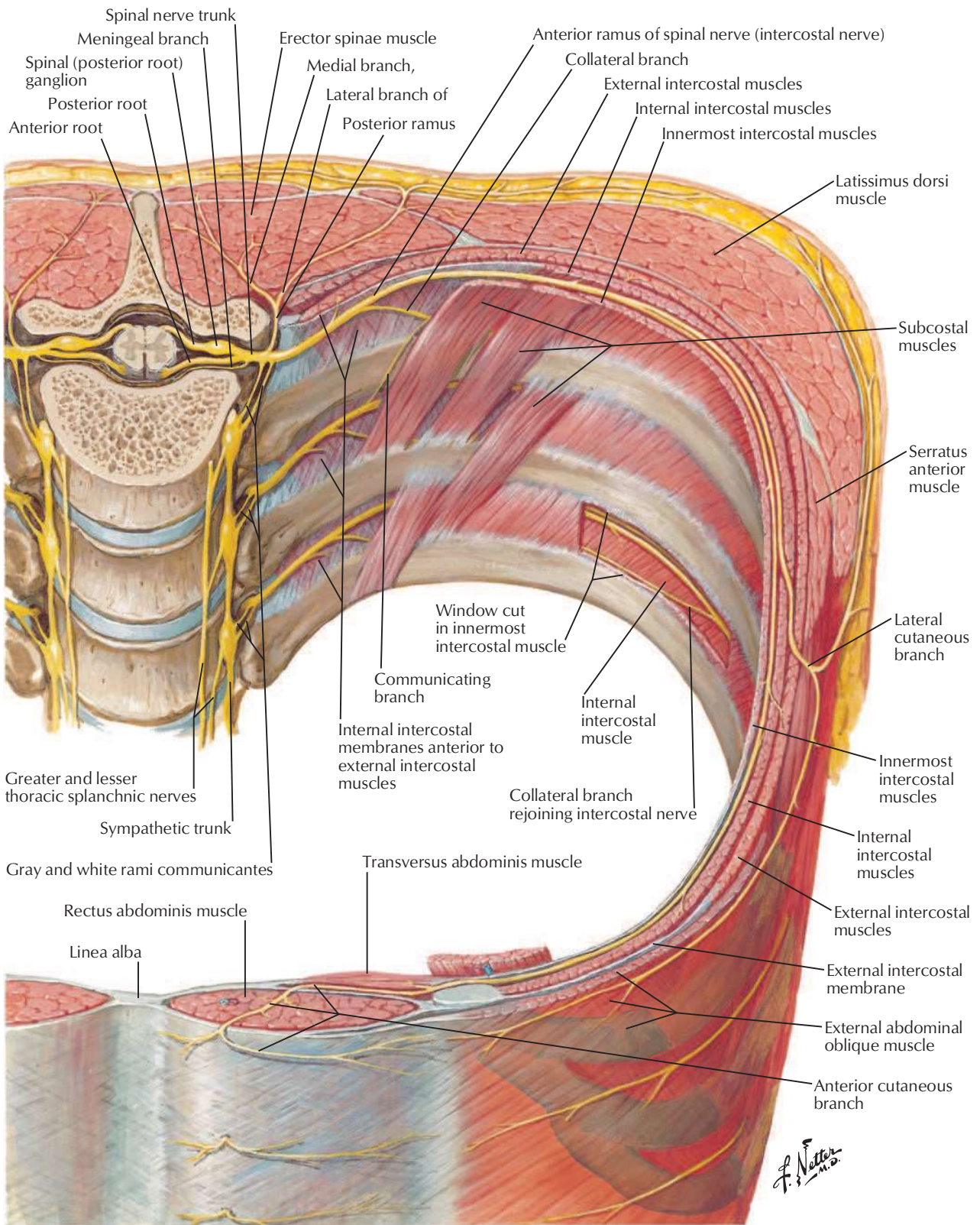
See also [Plates 252, 254](#)



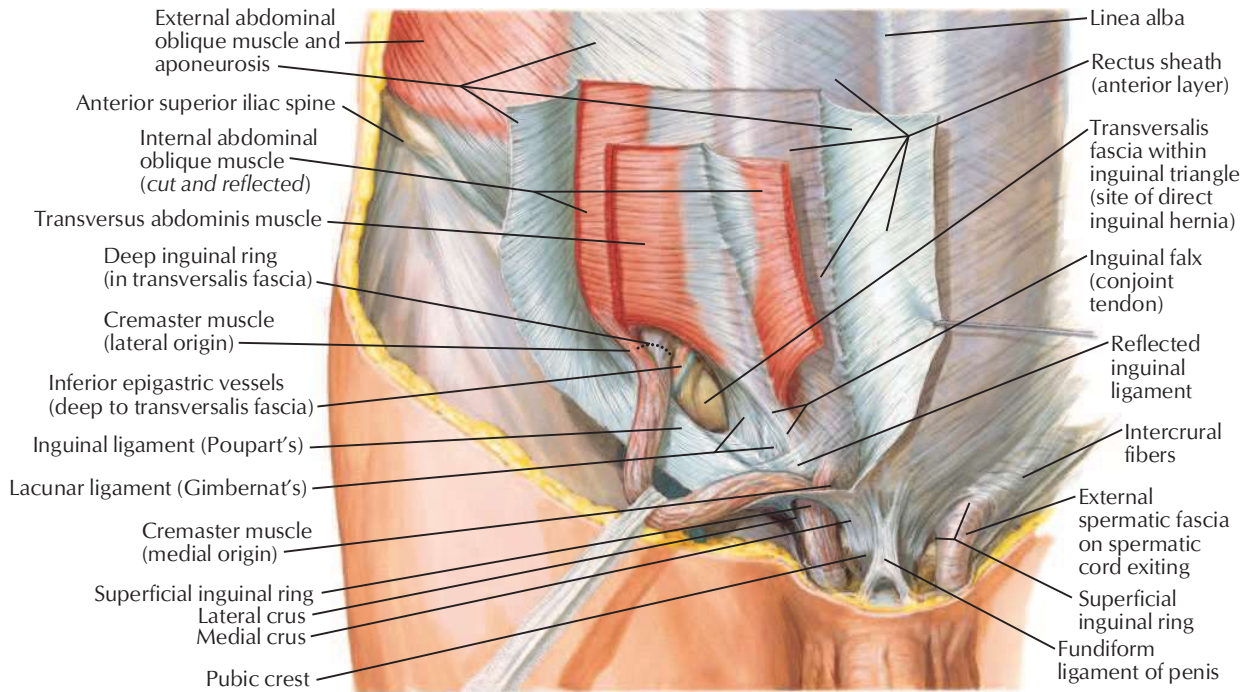
Nerves of Anterior Abdominal Wall

See also [Plates 186, 194, 261](#)



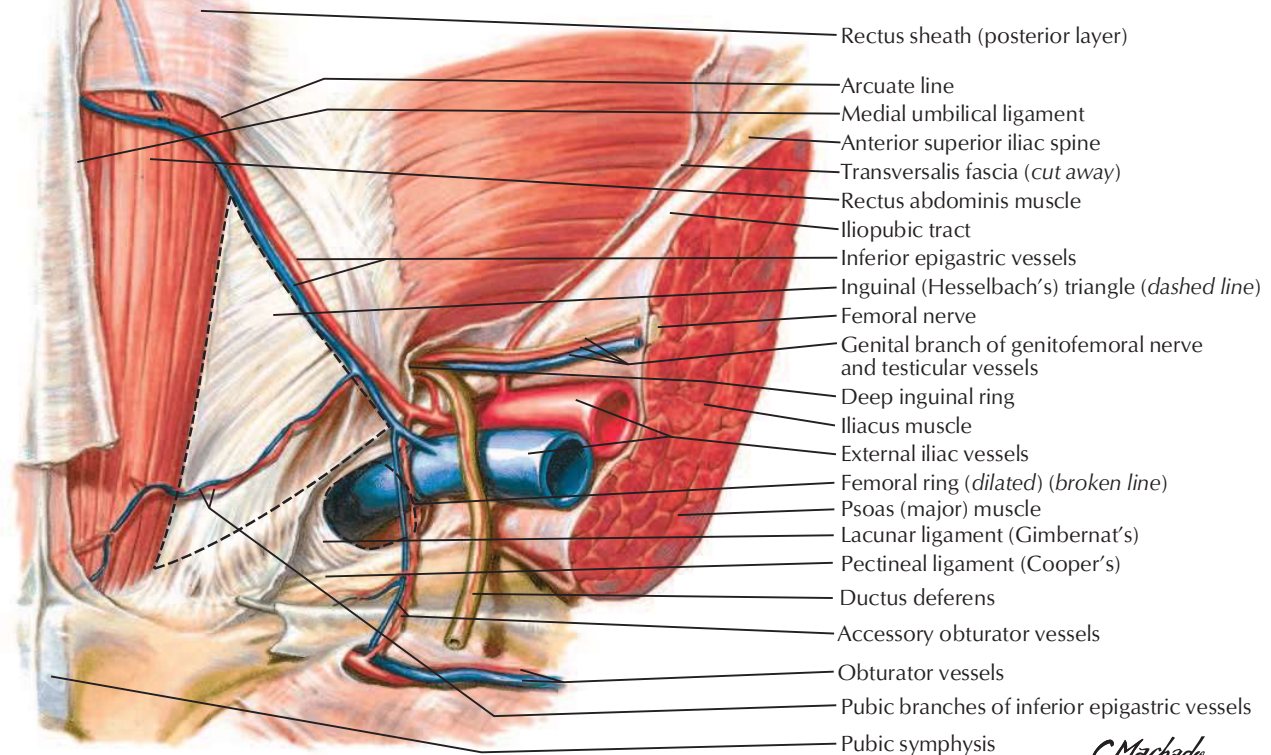


Anterior view



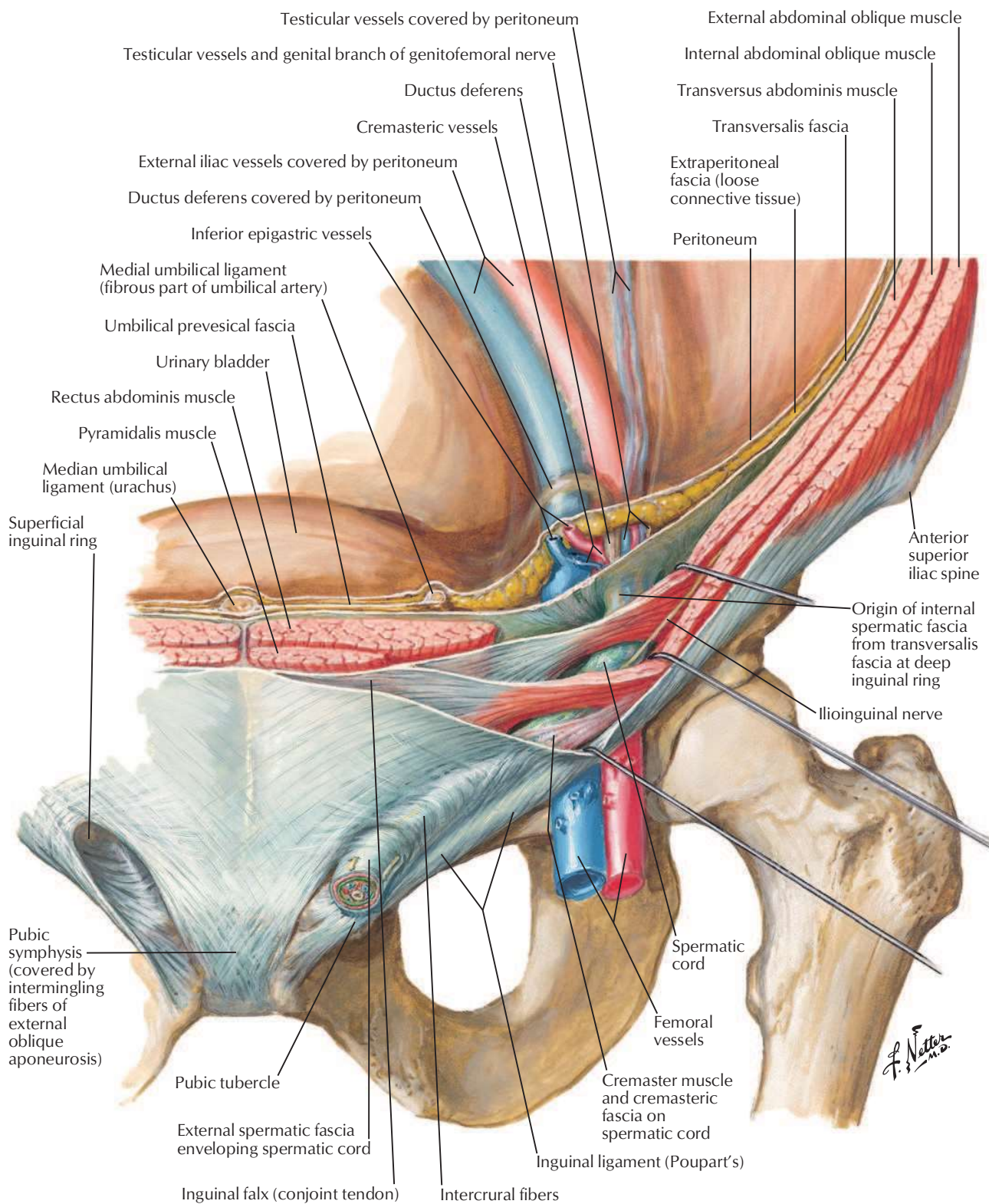
F. Netter M.D.

Posterior (internal) view



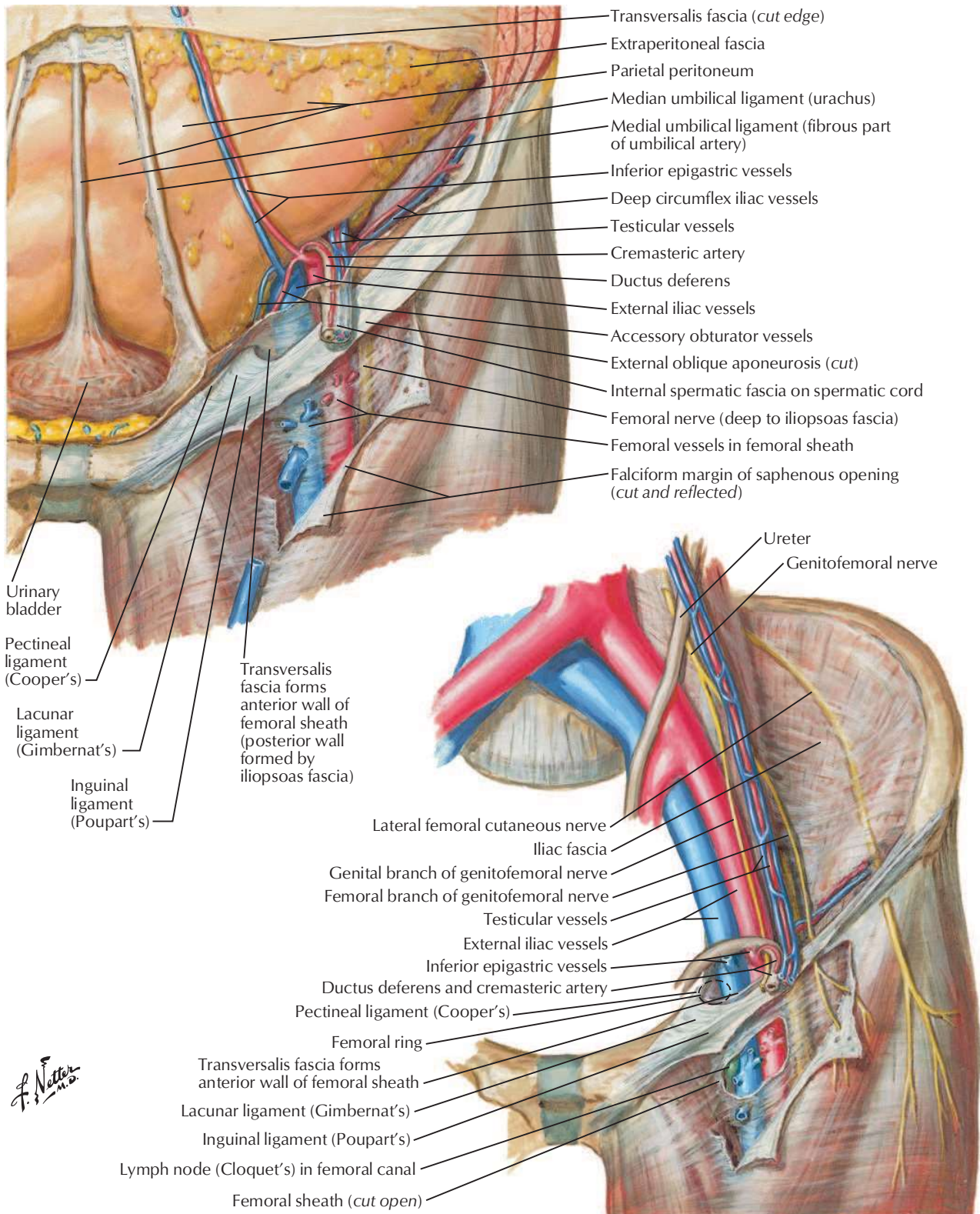
C. Machado M.D.

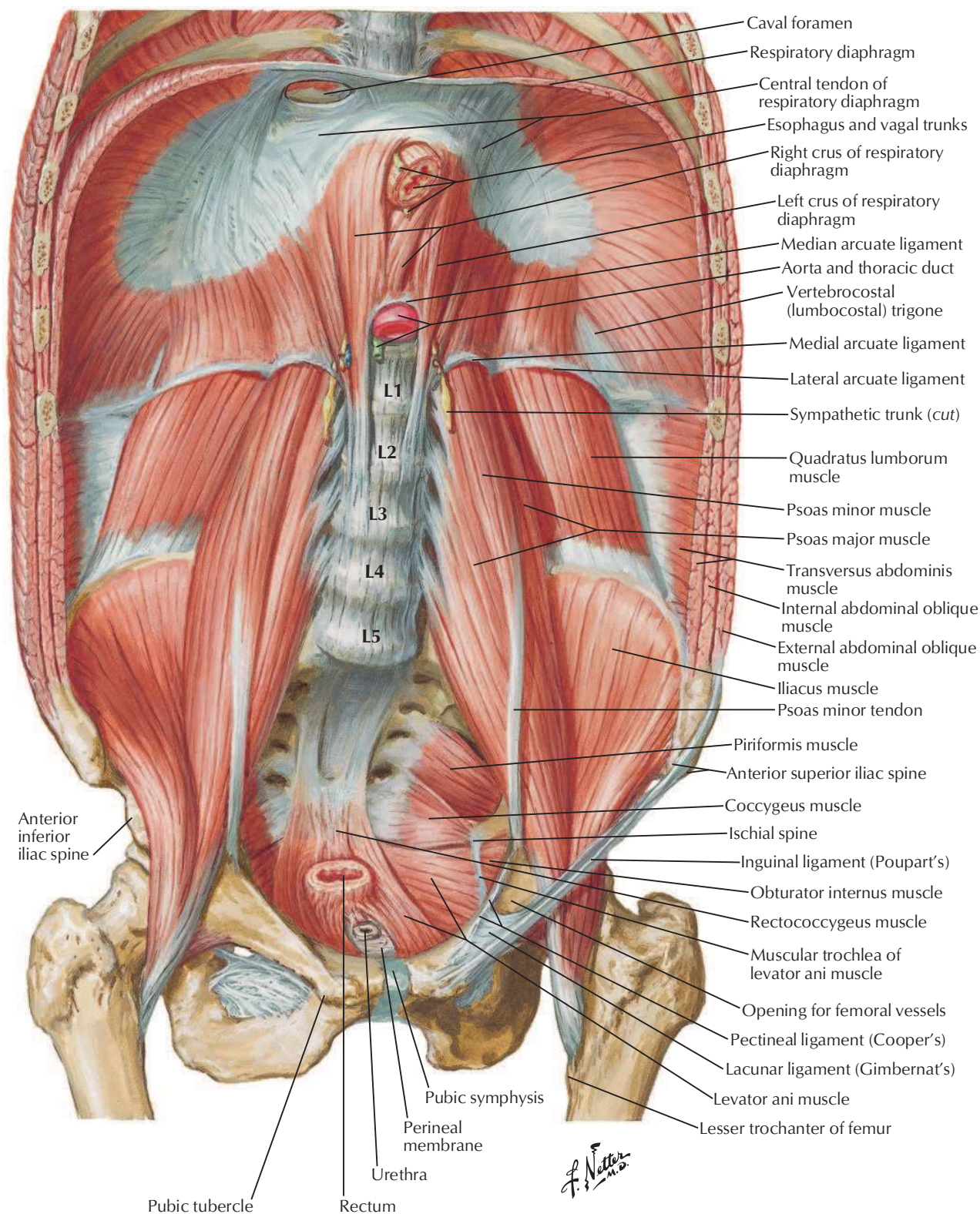
Hesselbach's triangle by Carlos Machado after Frank Netter



Femoral Sheath and Inguinal Canal

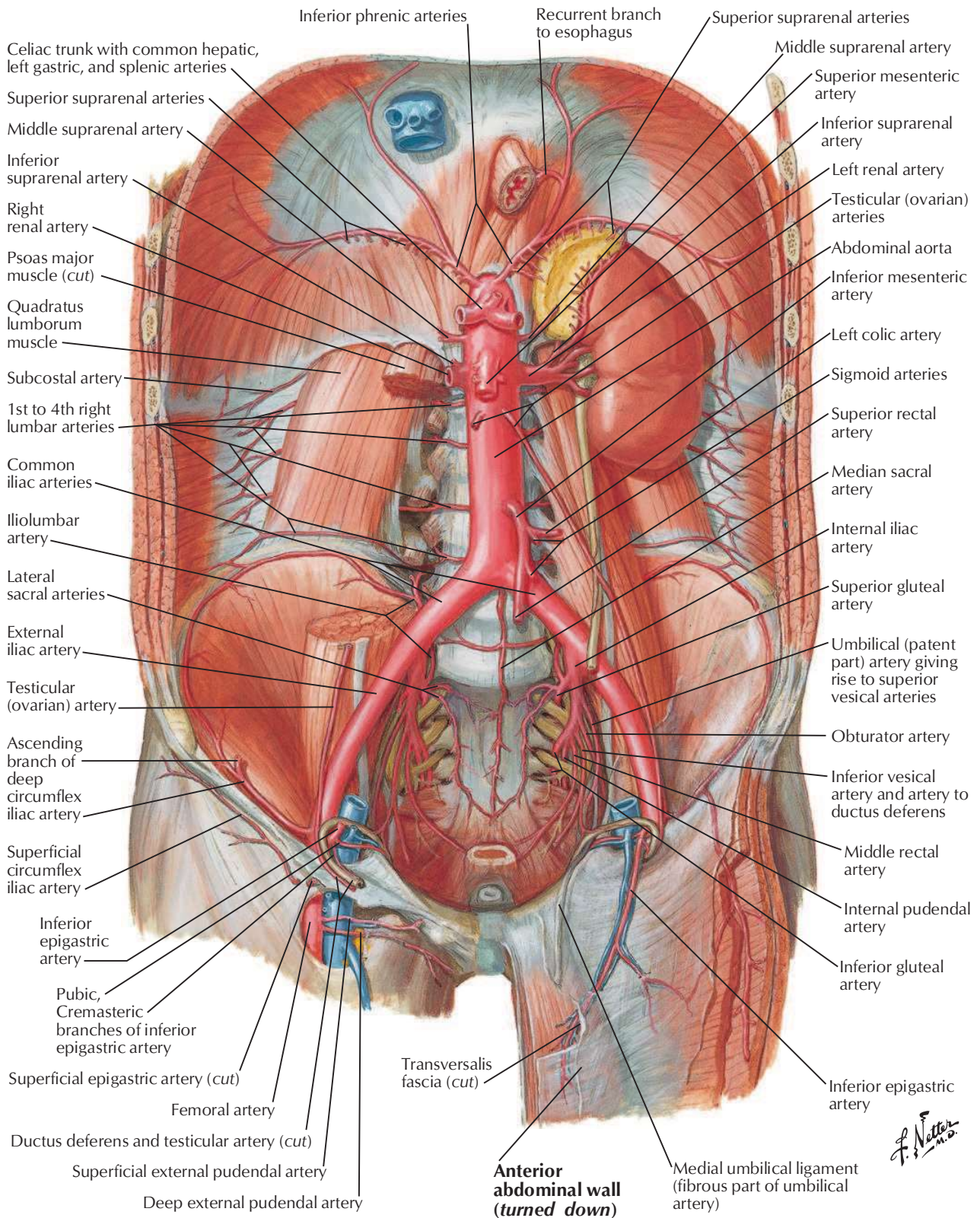
See also [Plates 253, 254, 256](#)



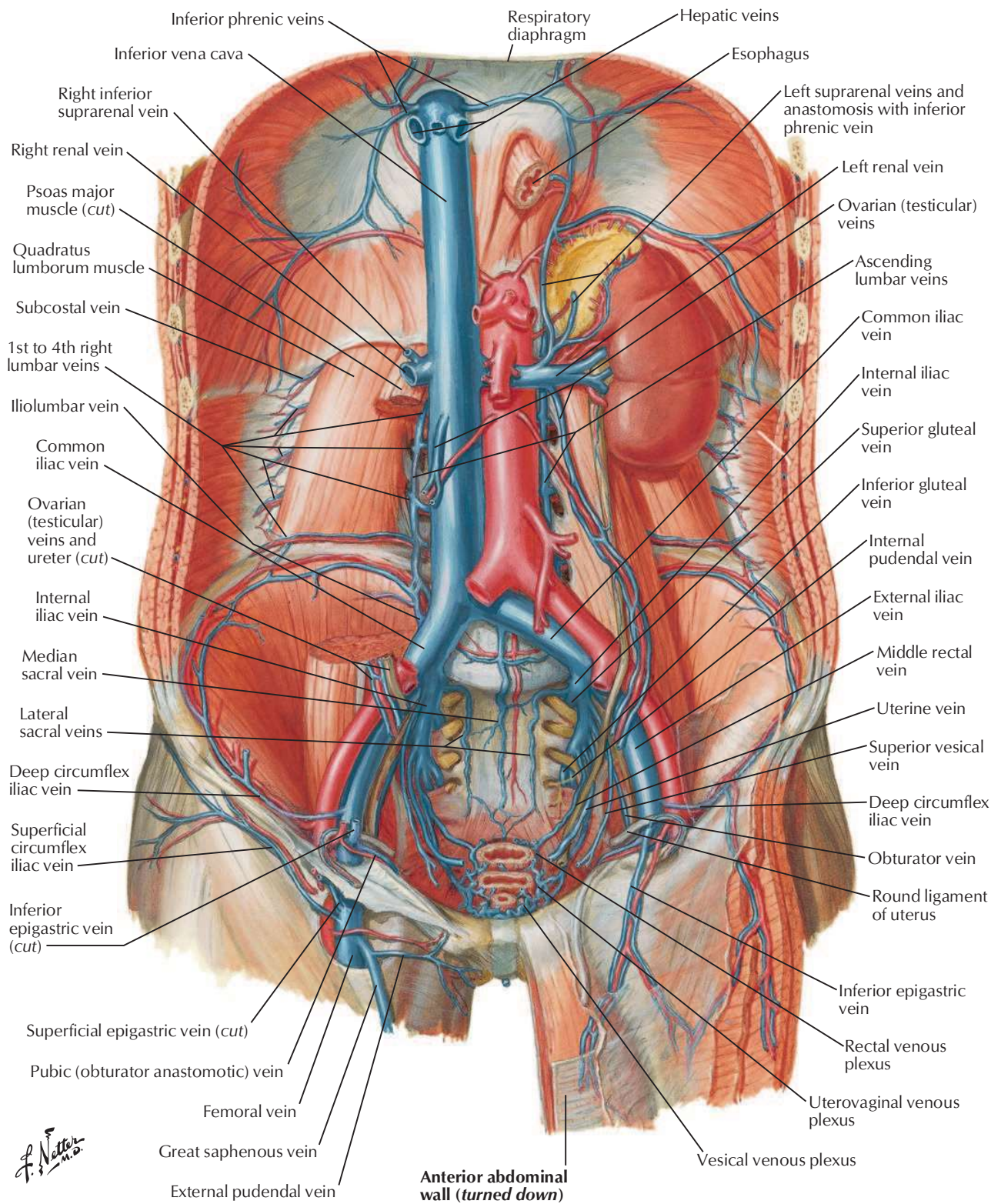


Arteries of Posterior Abdominal Wall

See also **Plates 201, 383, 384**



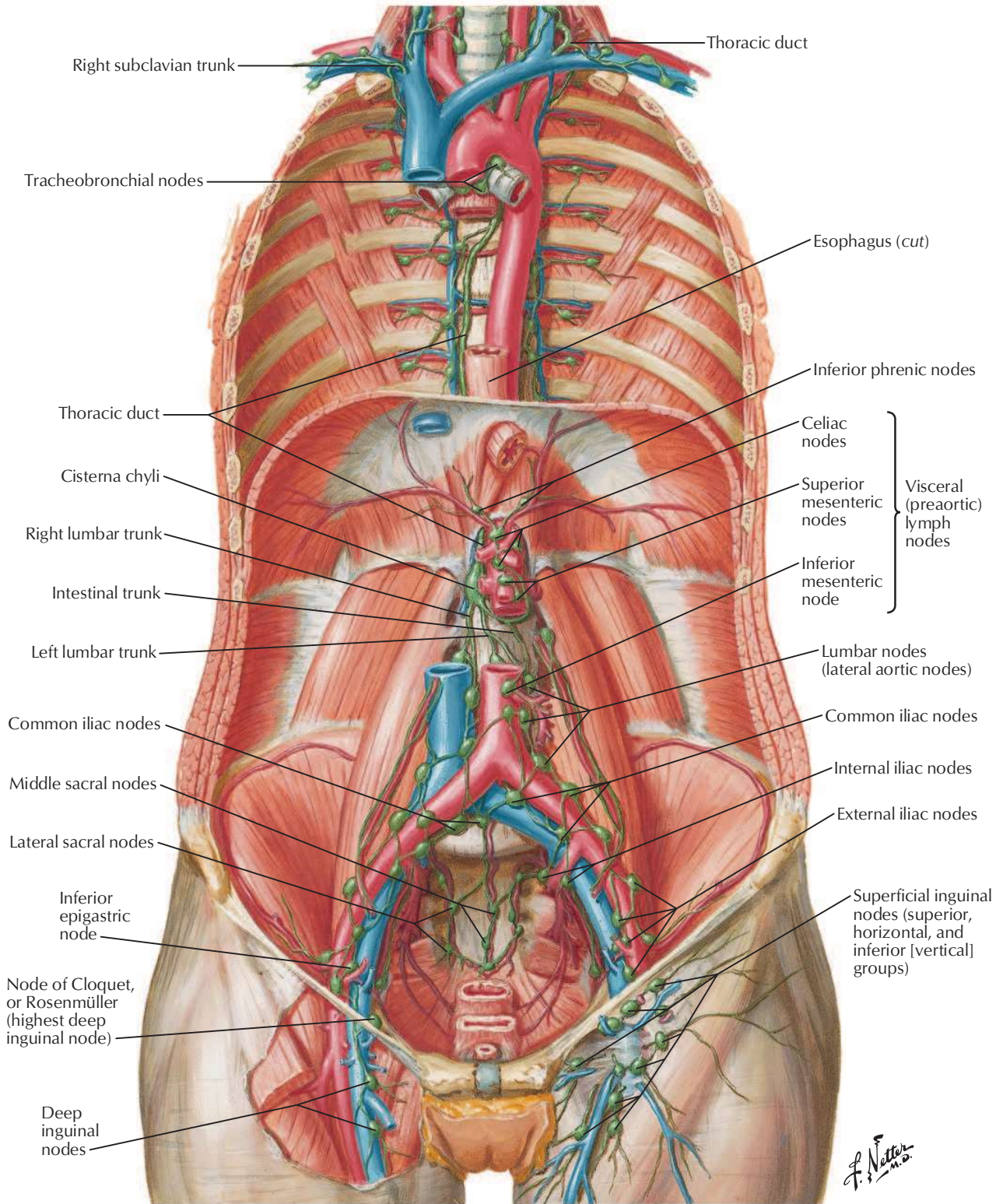
See also [Plates 382, 383](#)

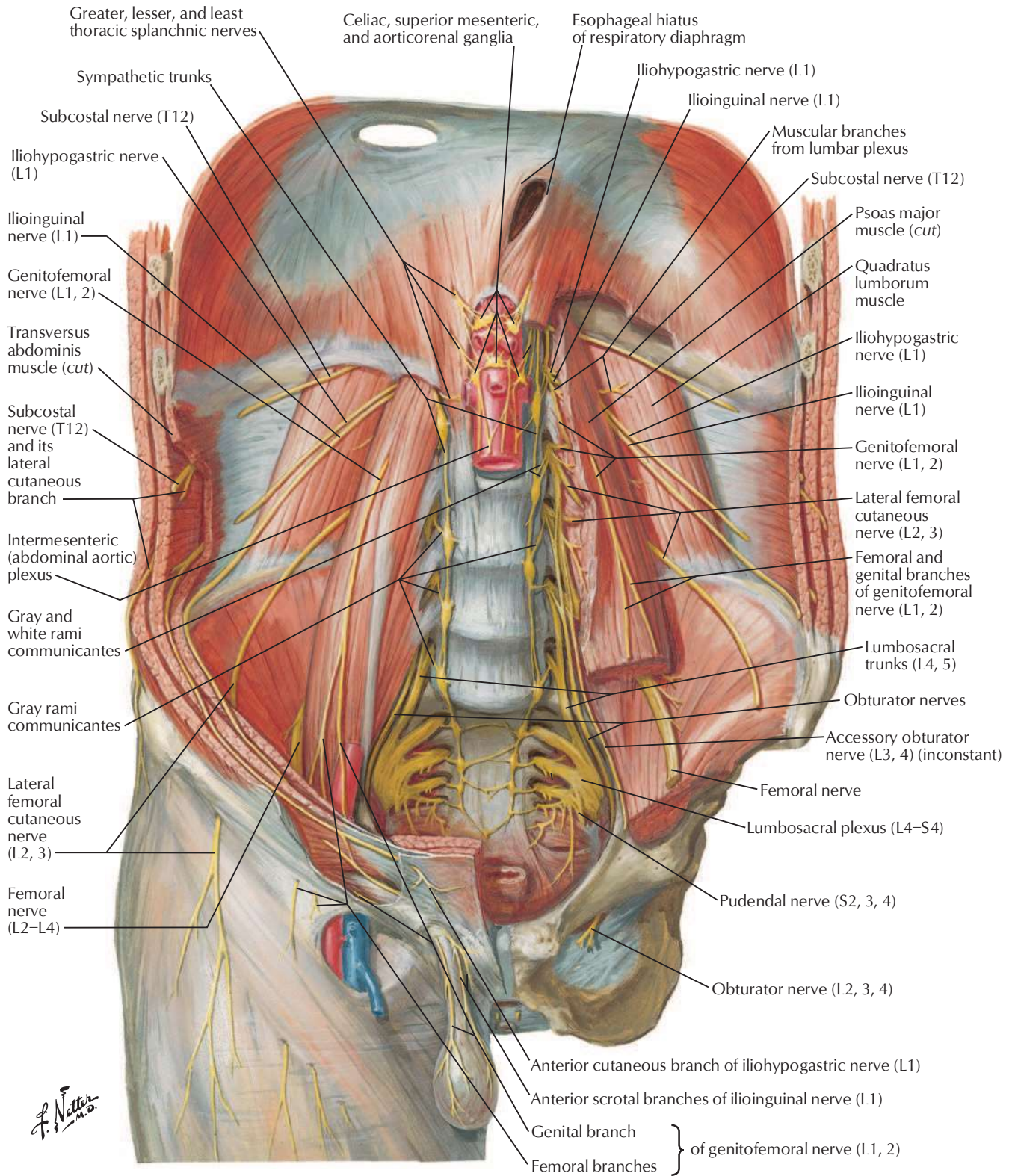


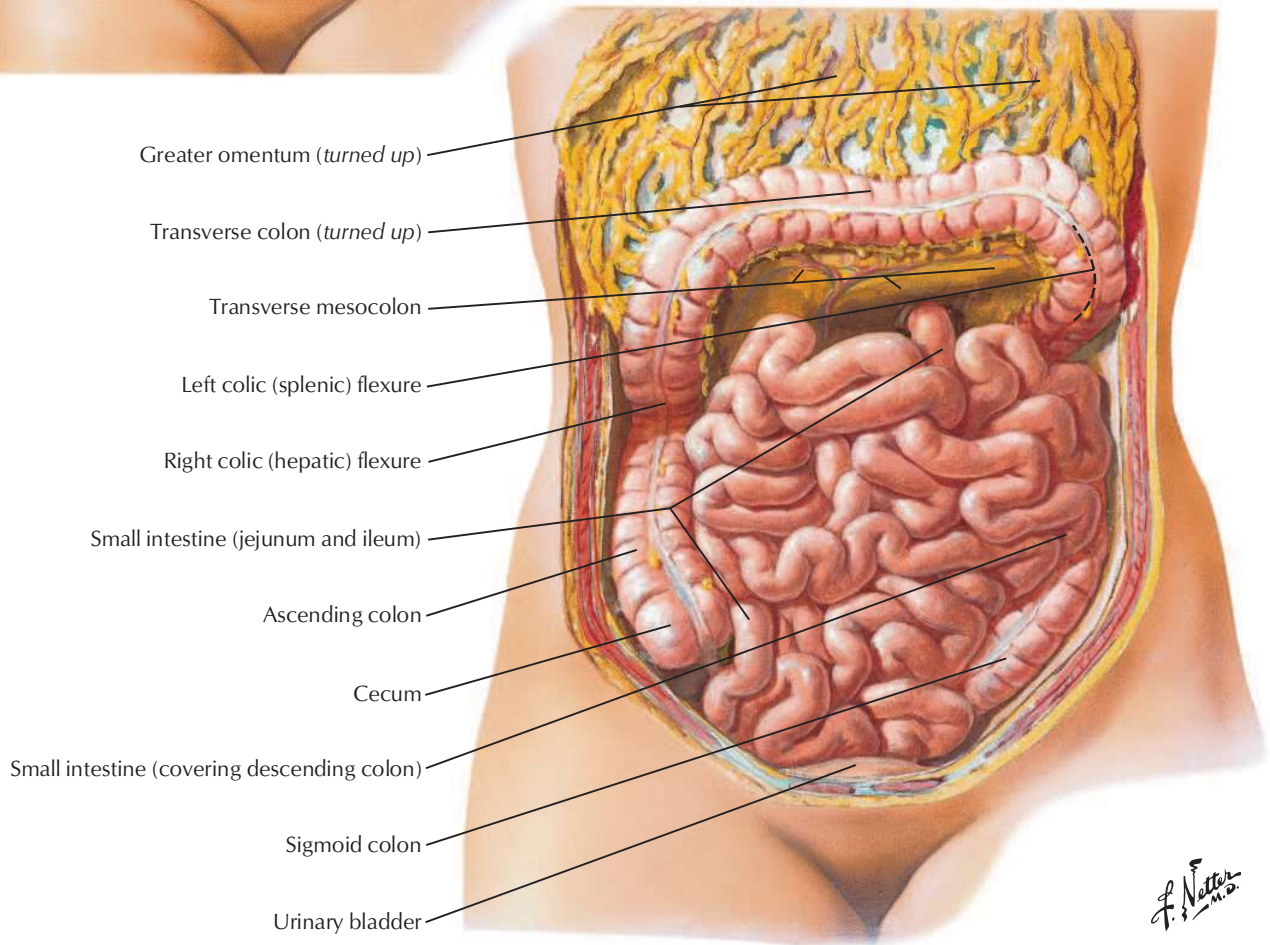
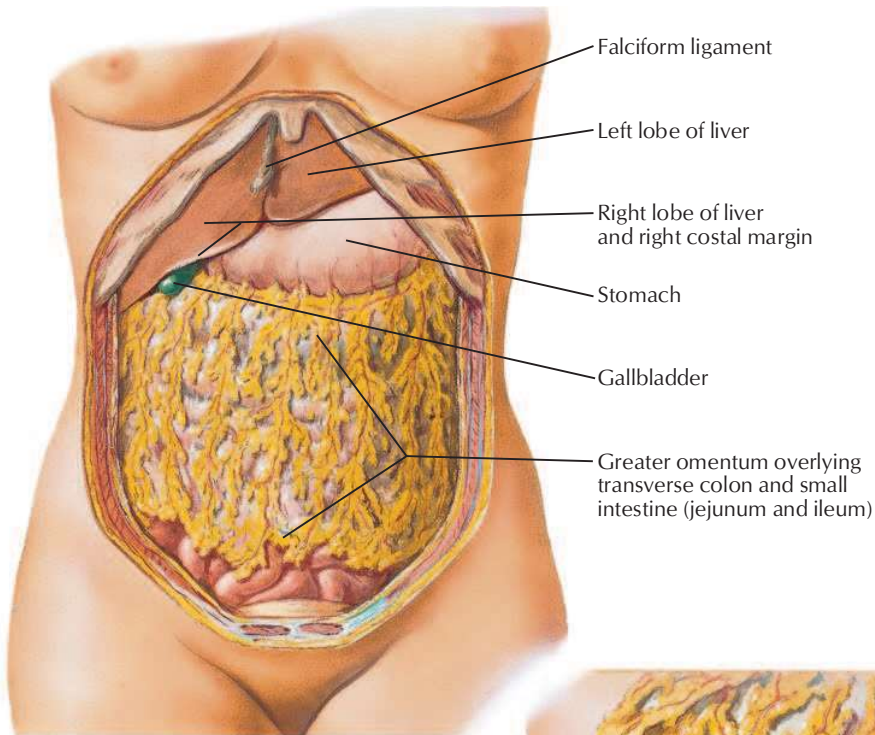
F. Netter M.D.

Lymph Vessels and Nodes of Posterior Abdominal Wall

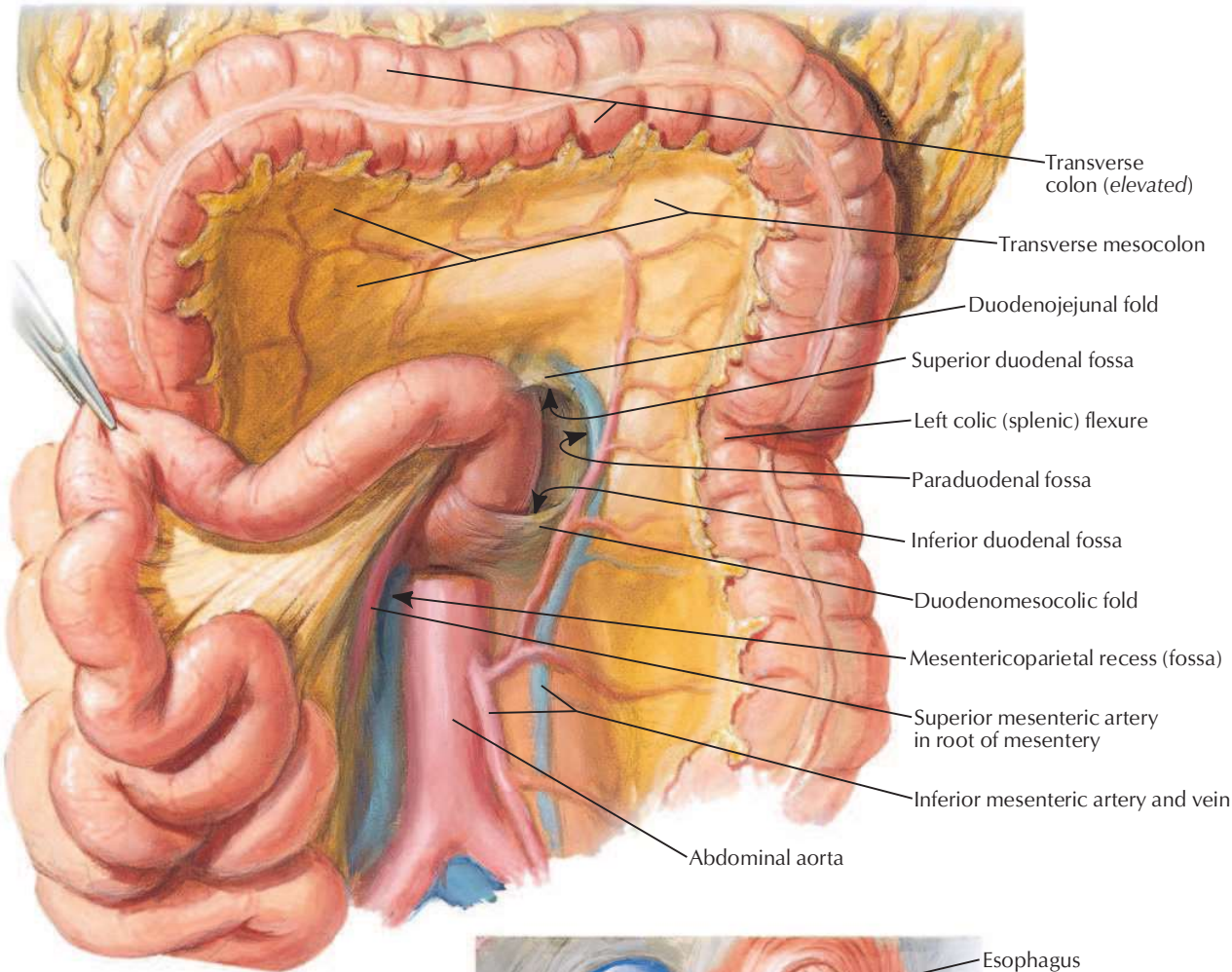
See also [Plates 319, 388](#)



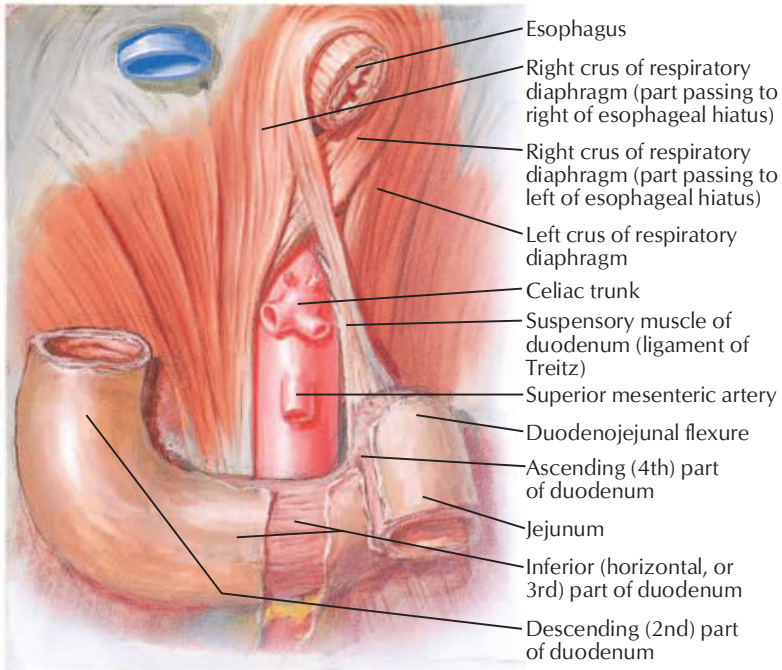




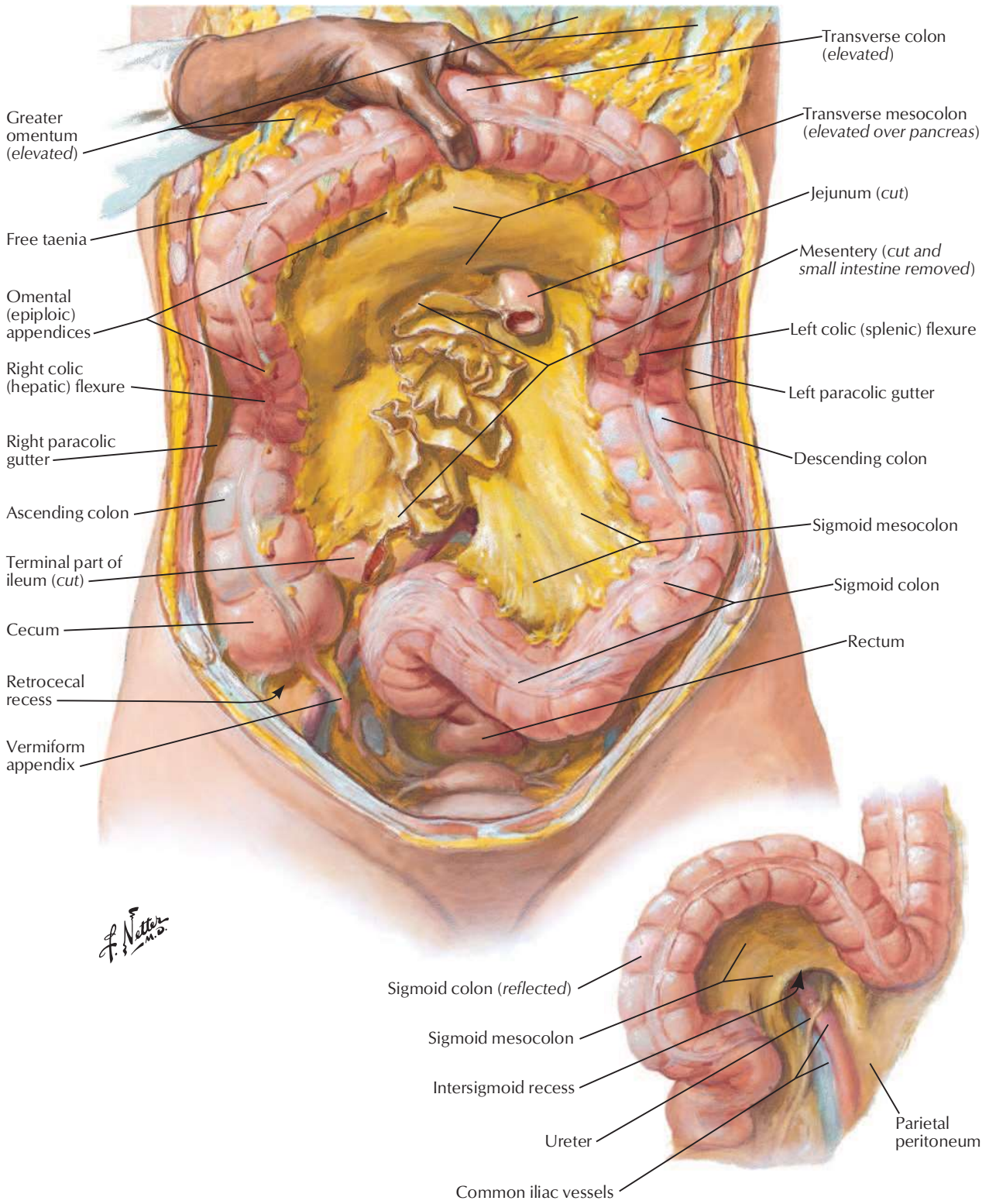
See also Plate 288

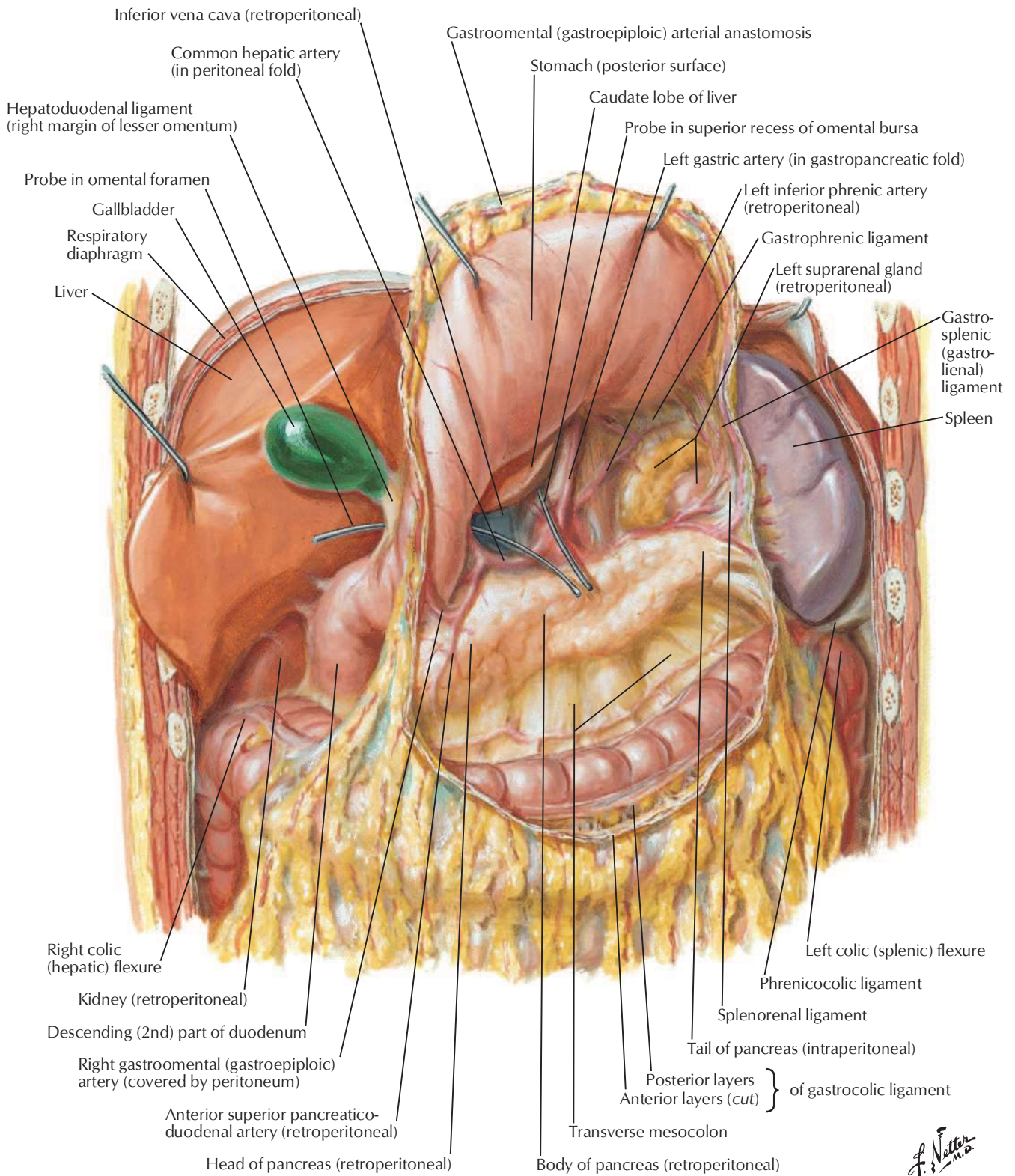


Exposure of suspensory muscle of duodenum (ligament of Treitz)



F. Netter M.D.

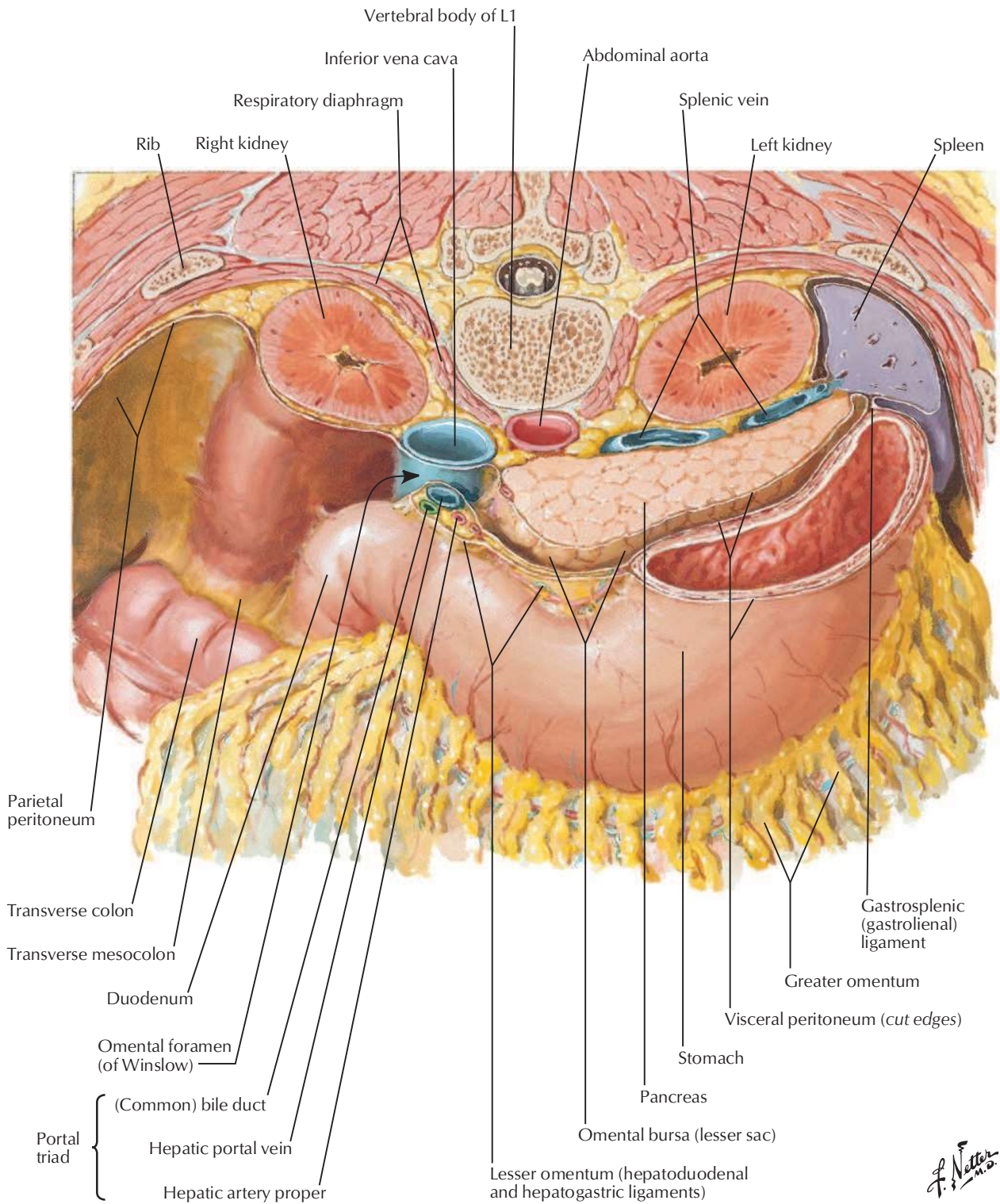


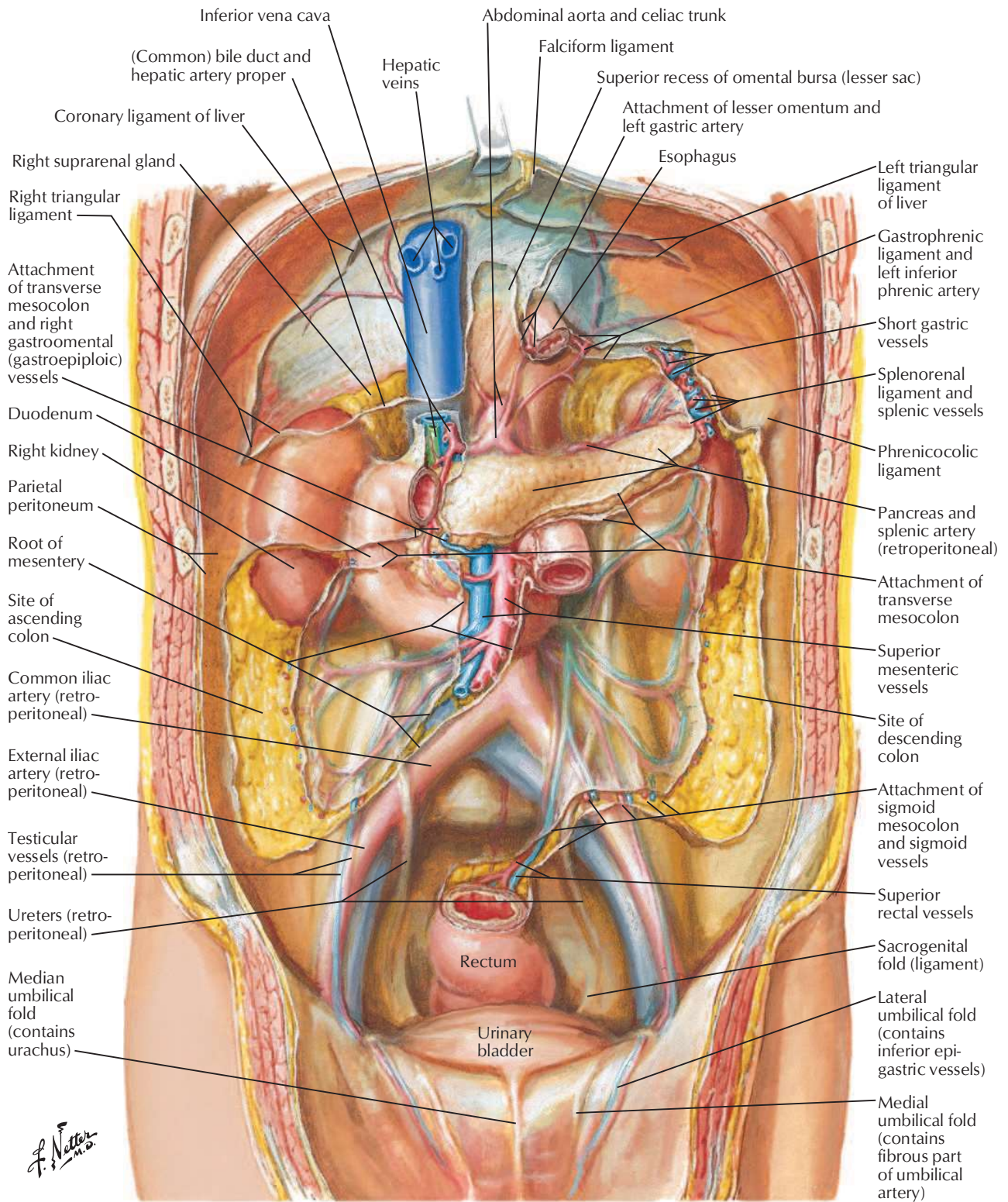


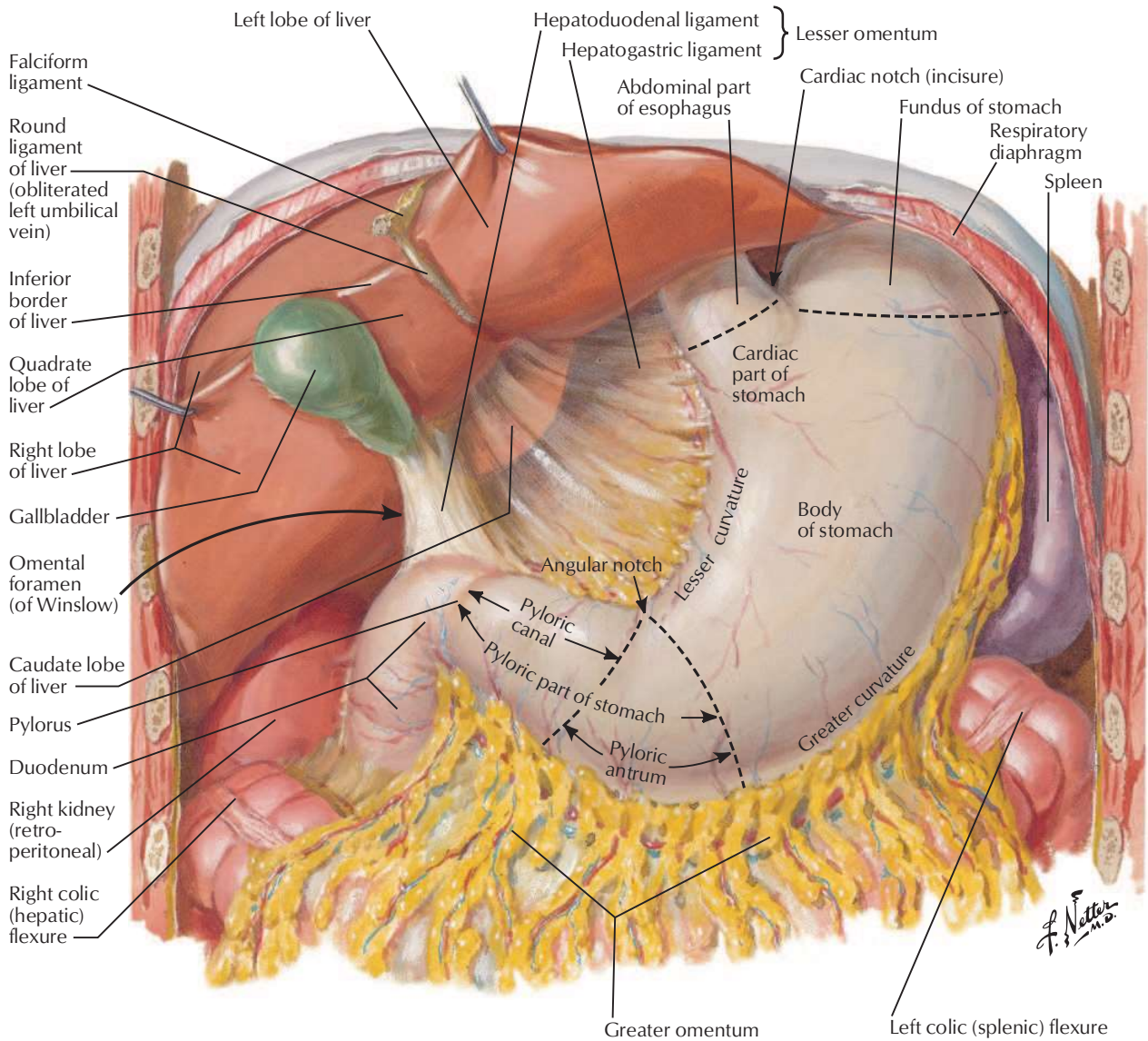
F. Netter M.D.

Omental Bursa: Cross Section

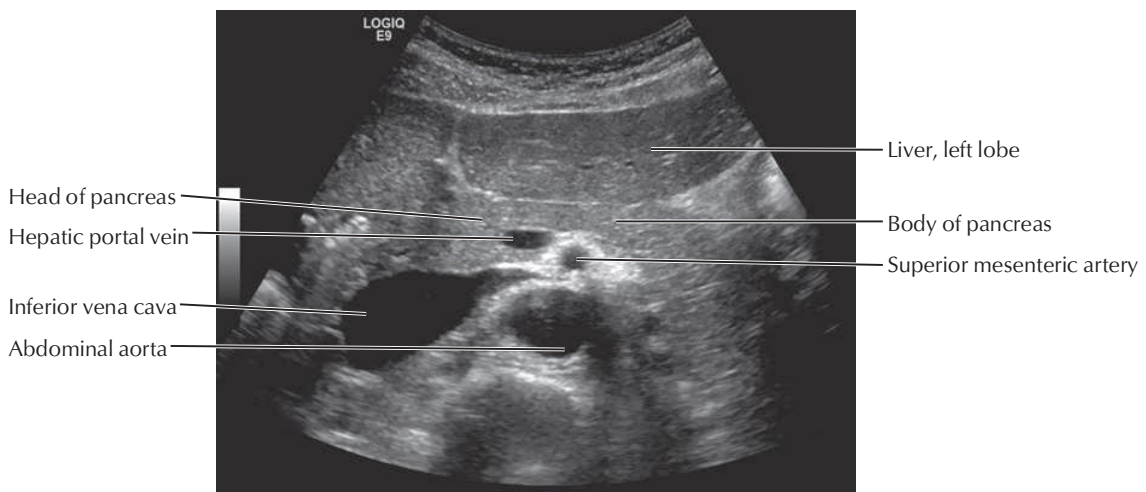
See also [Plate 276](#)

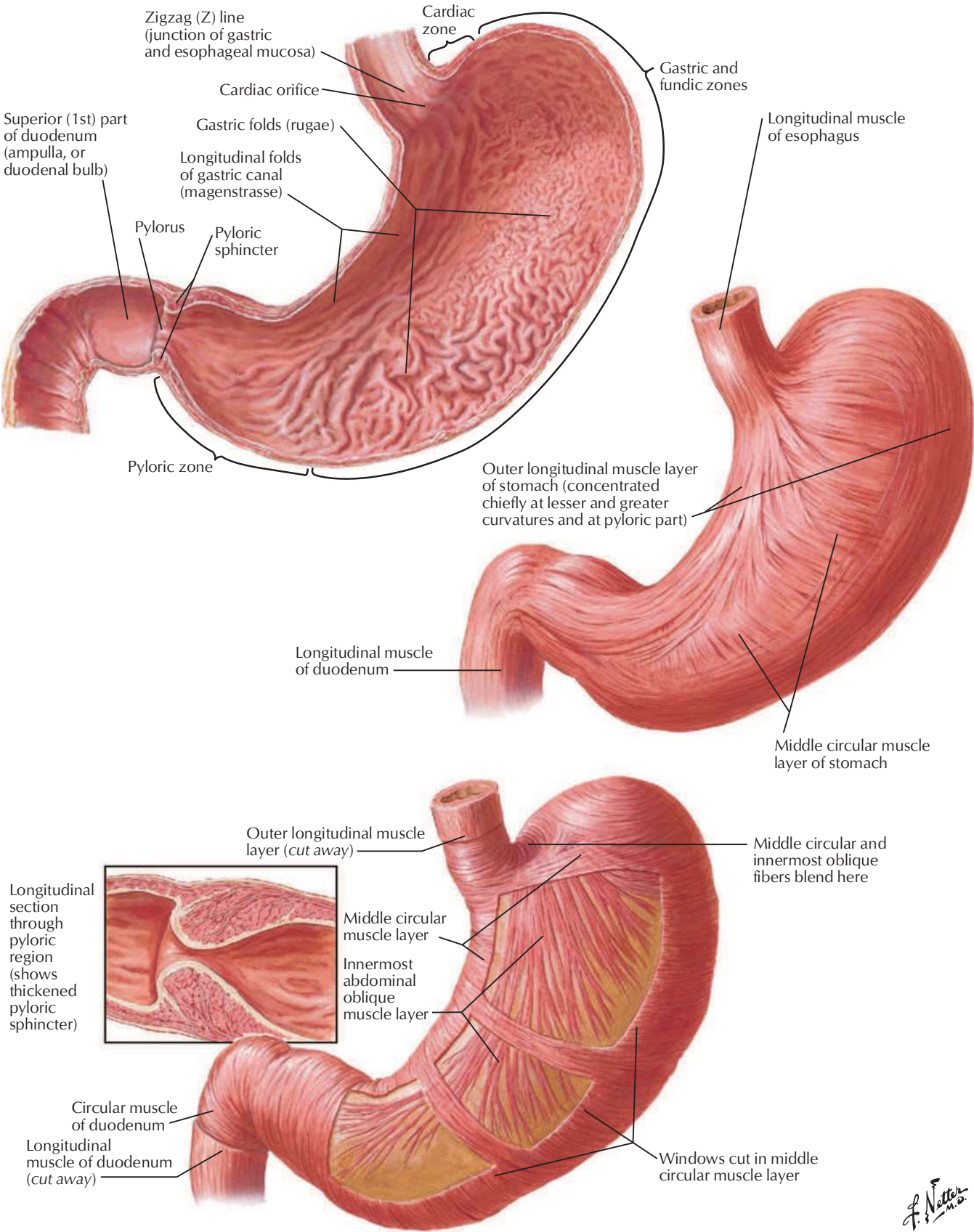






Transverse gray-scale ultrasound image of midabdomen

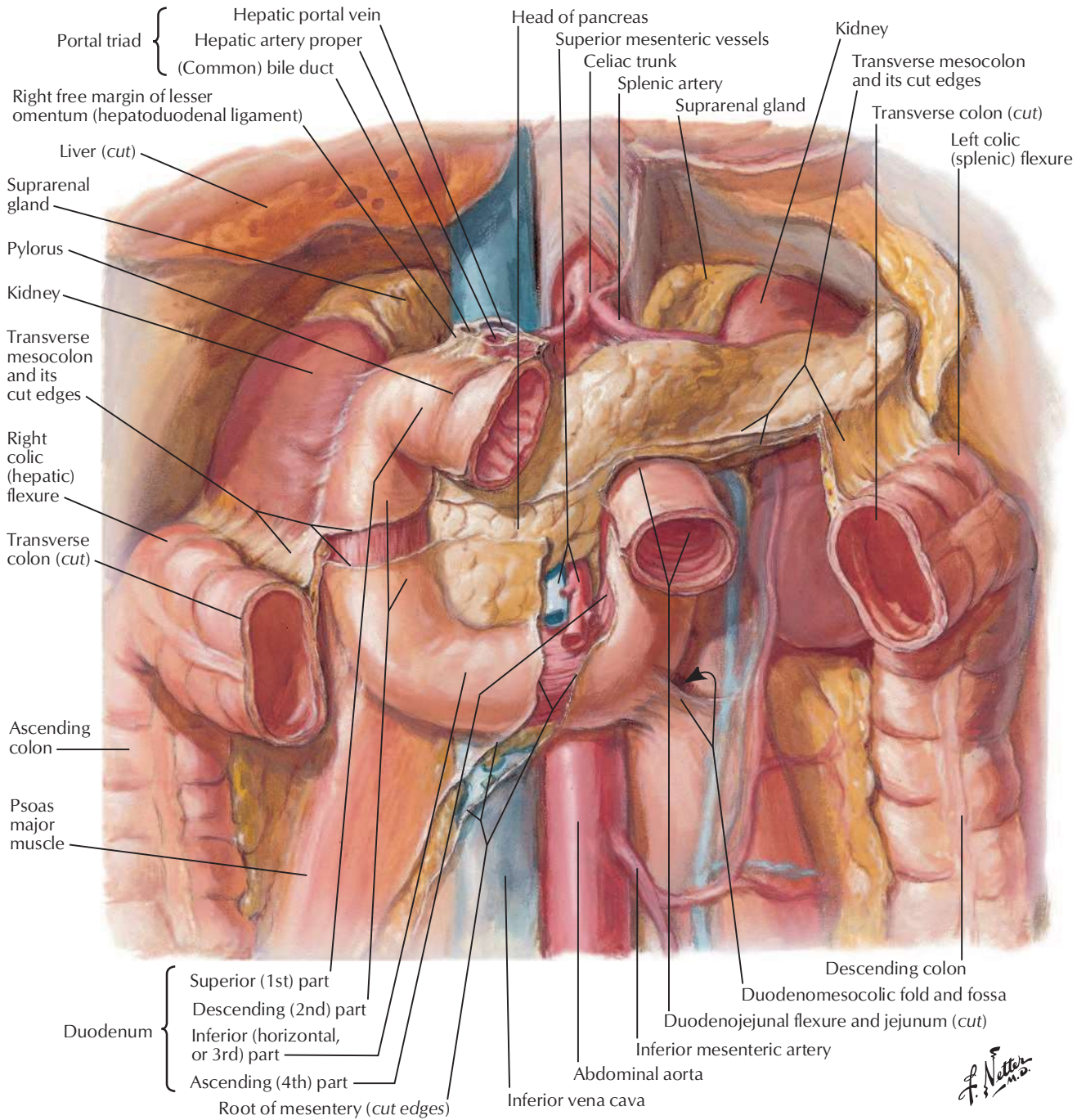




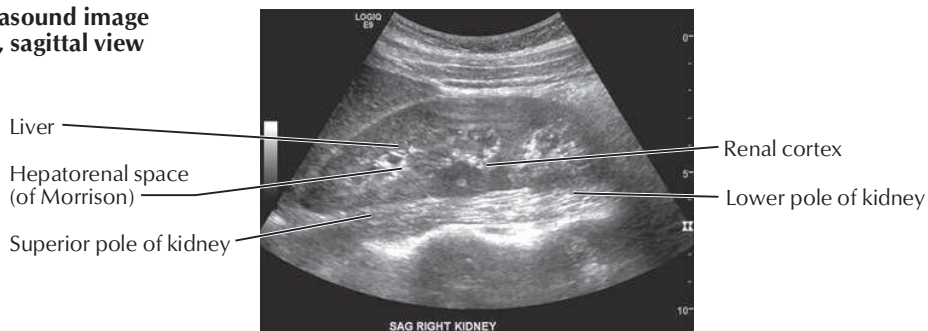
F. Netter M.D.

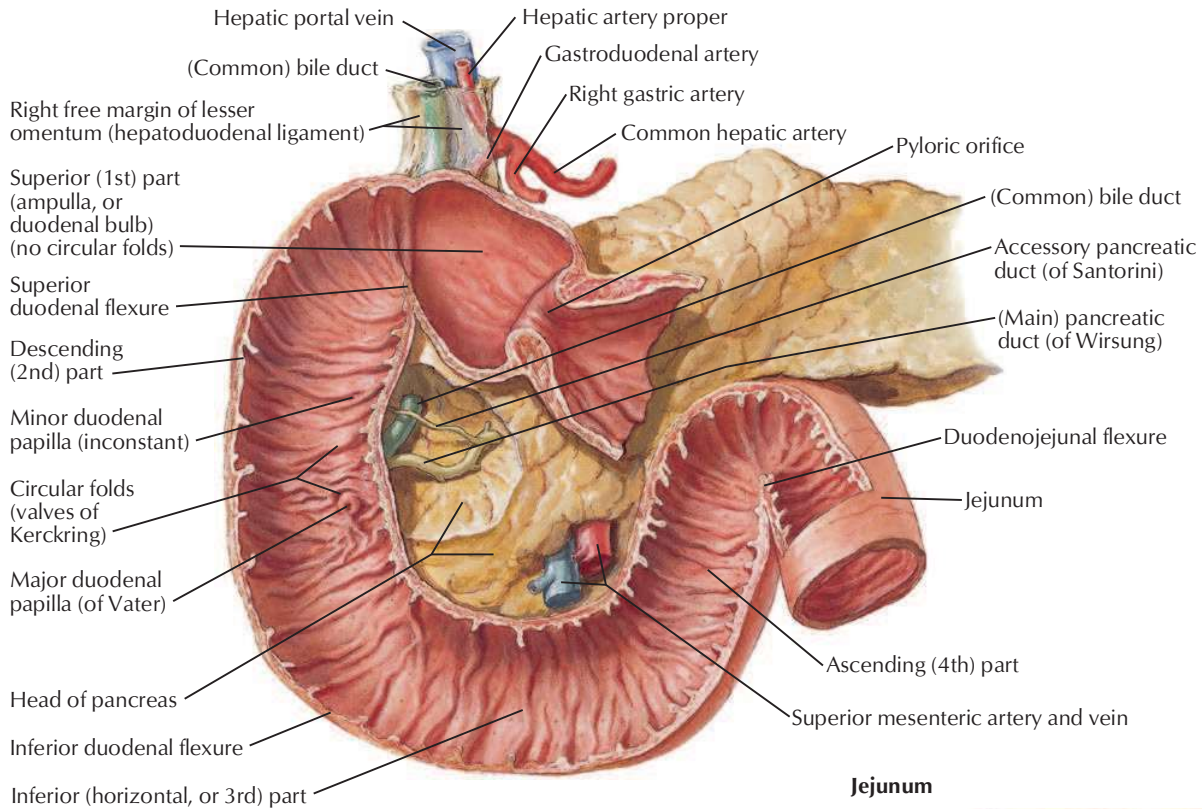
Duodenum in Situ

See also [Plate 275](#)

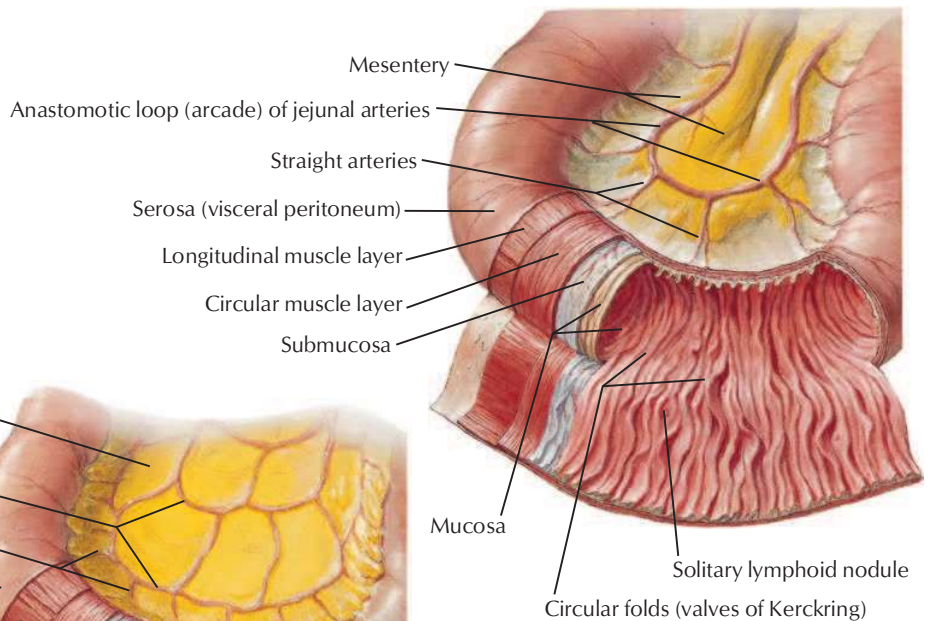


Gray-scale ultrasound image of right kidney, sagittal view

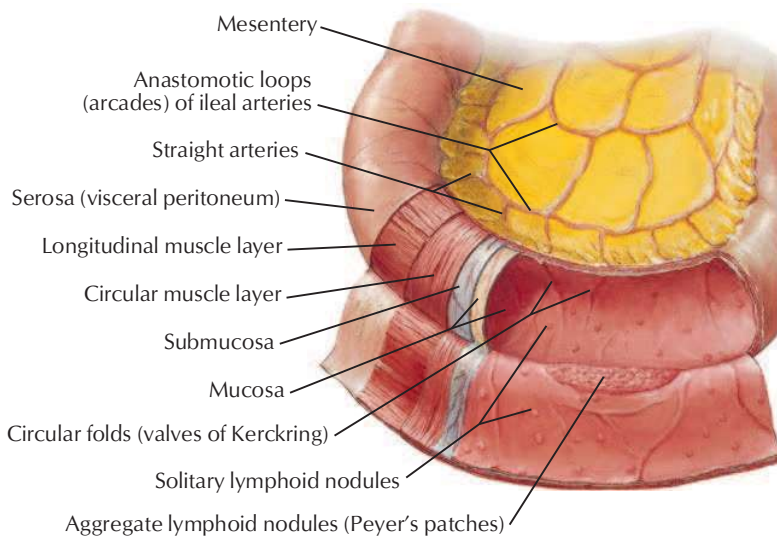




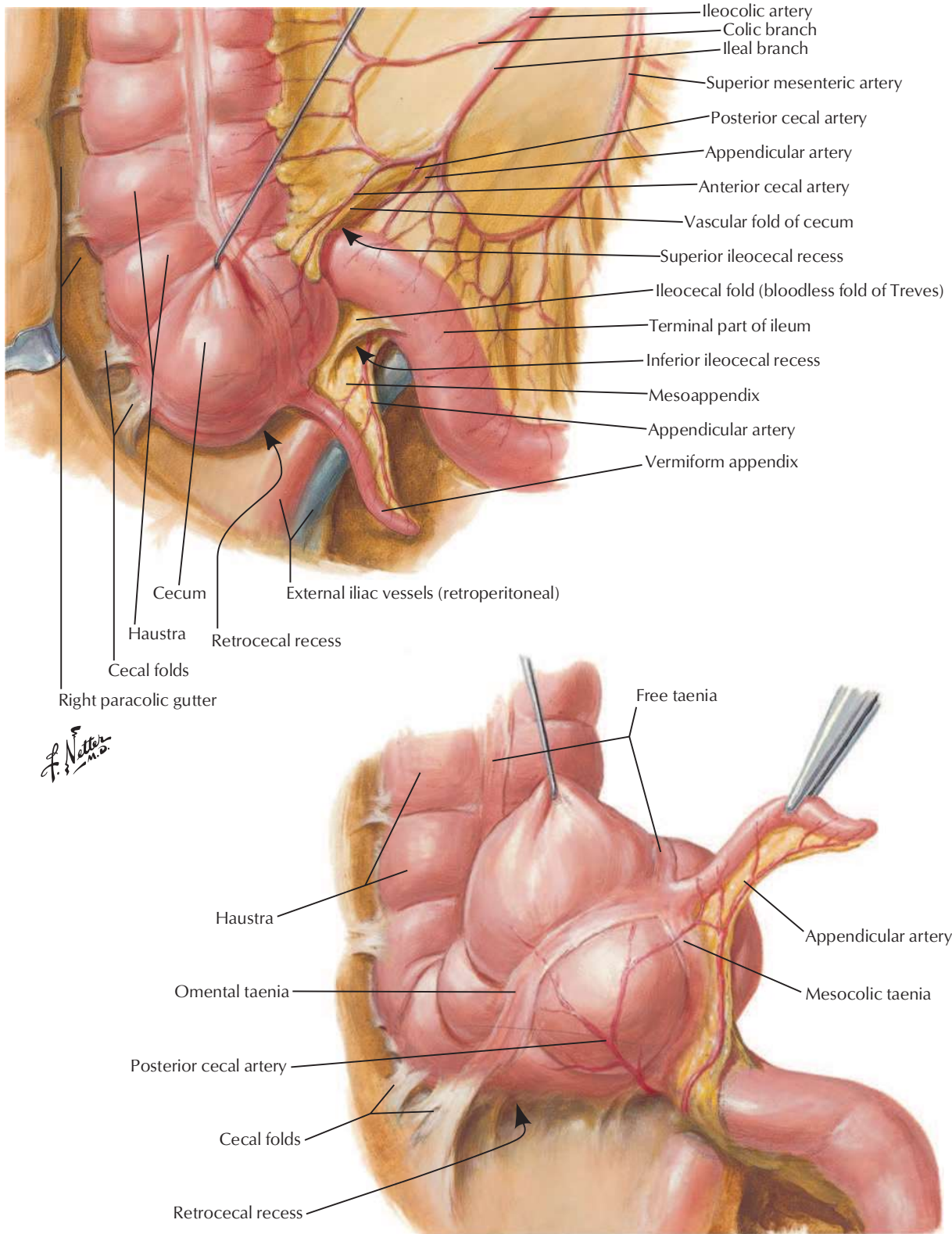
Jejunum

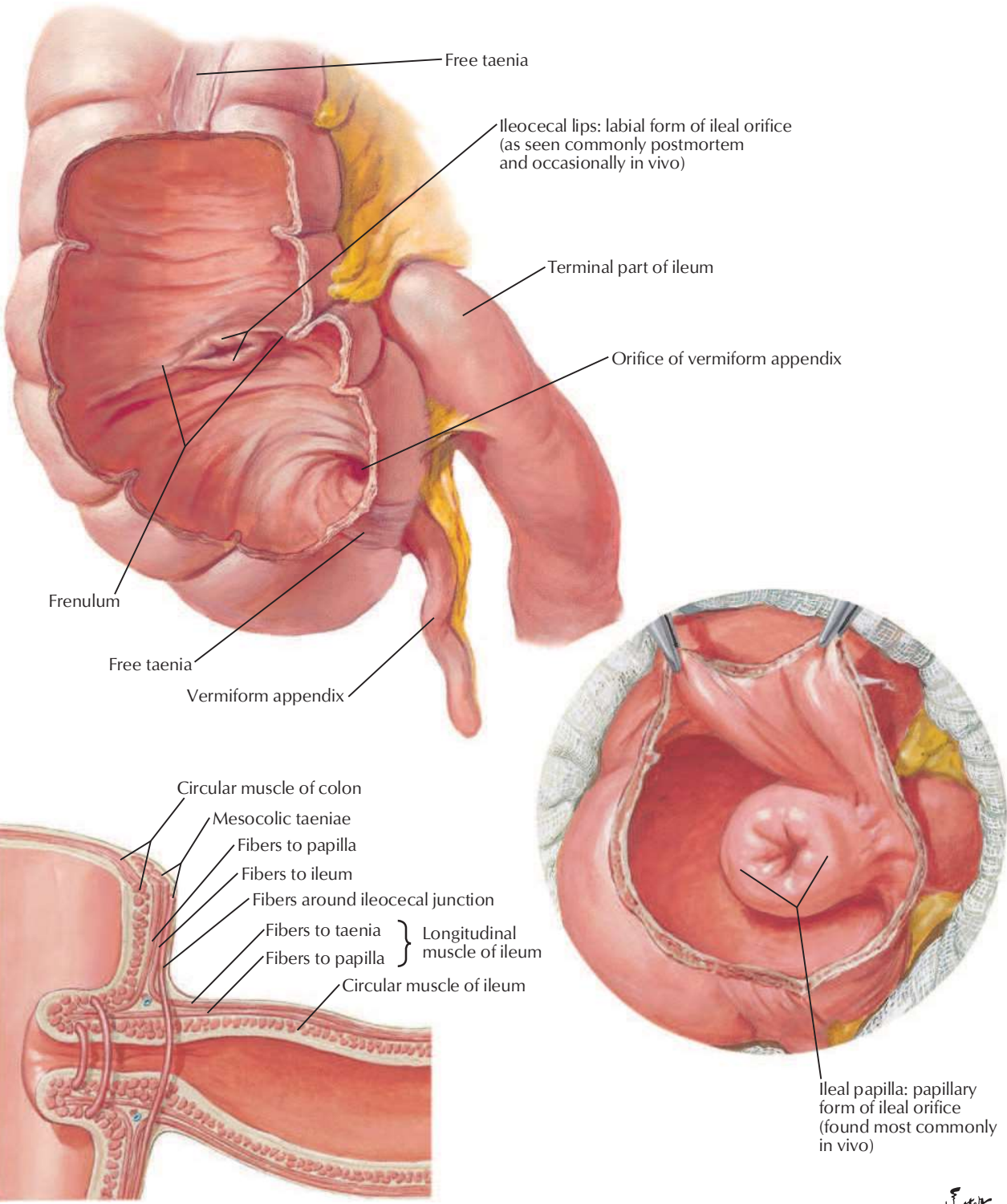


Ileum



F. Netter M.D.

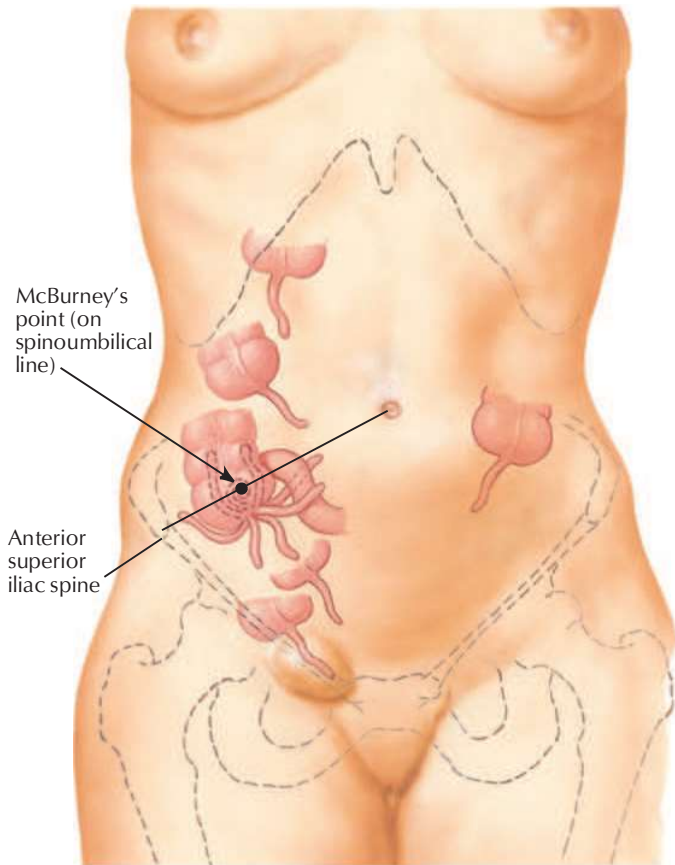




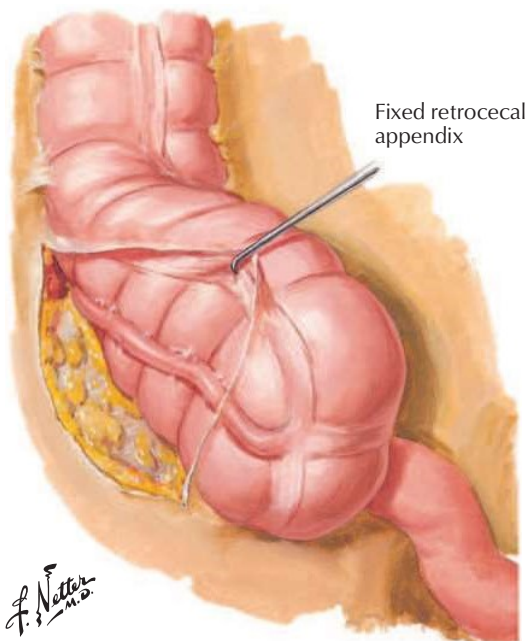
Schema of muscle fibers at ileal orifice

F. Netter M.D.

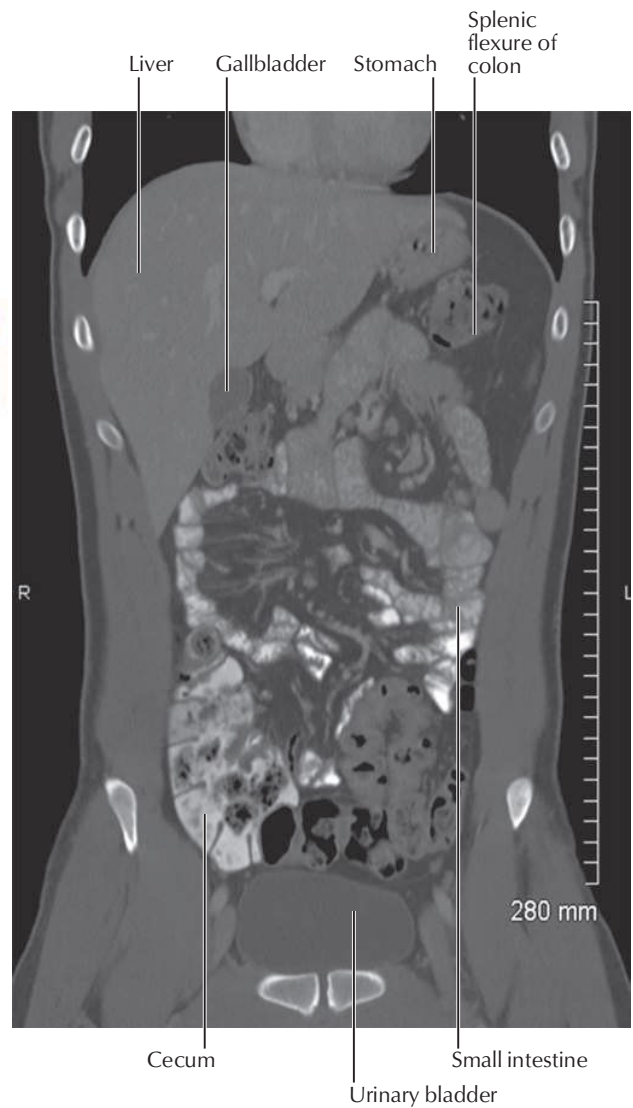
(Vermiform) Appendix

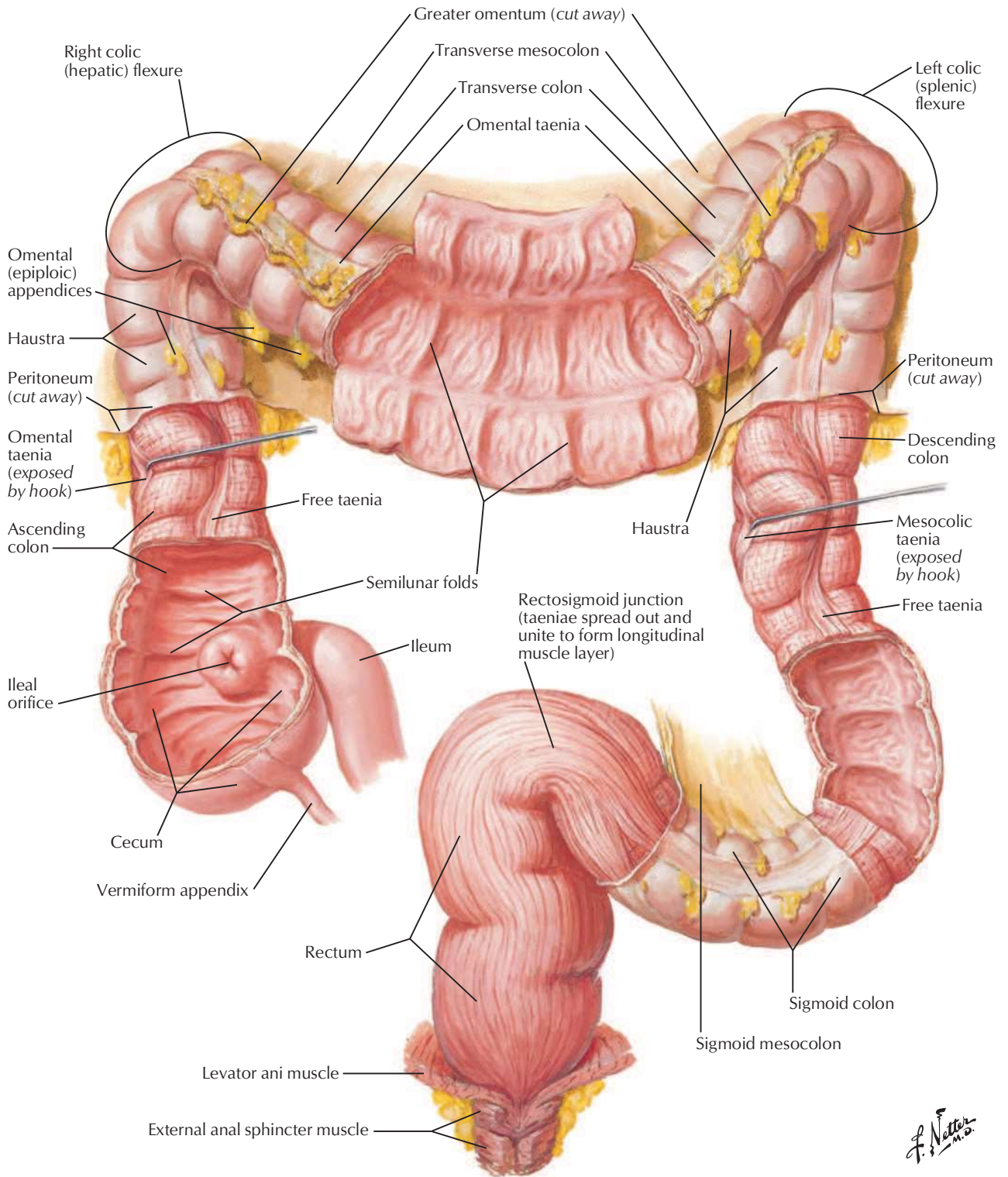


Variations in position of appendix



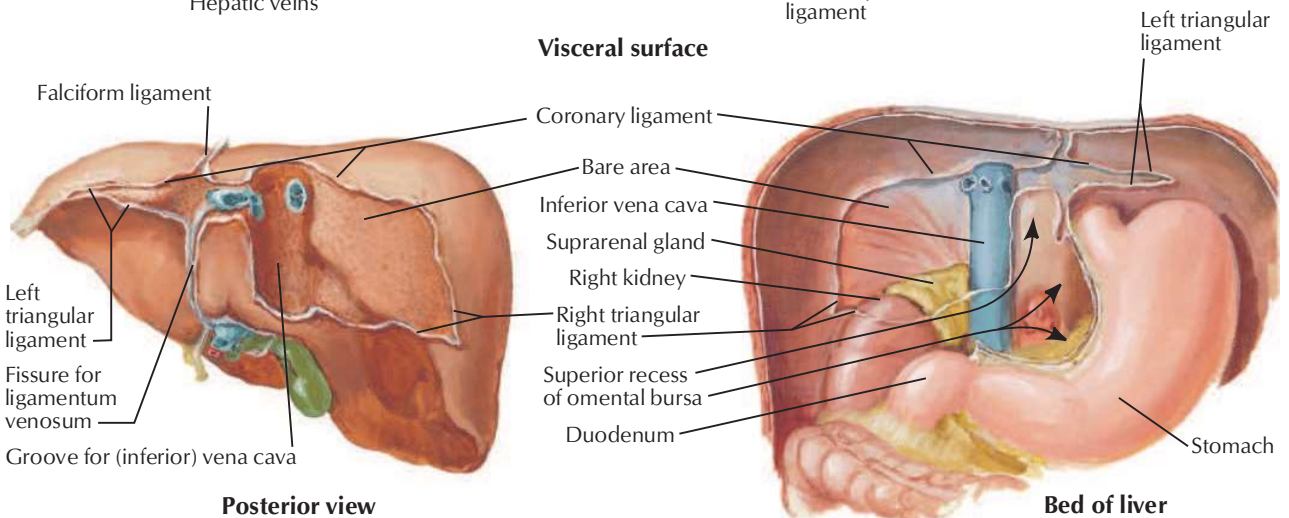
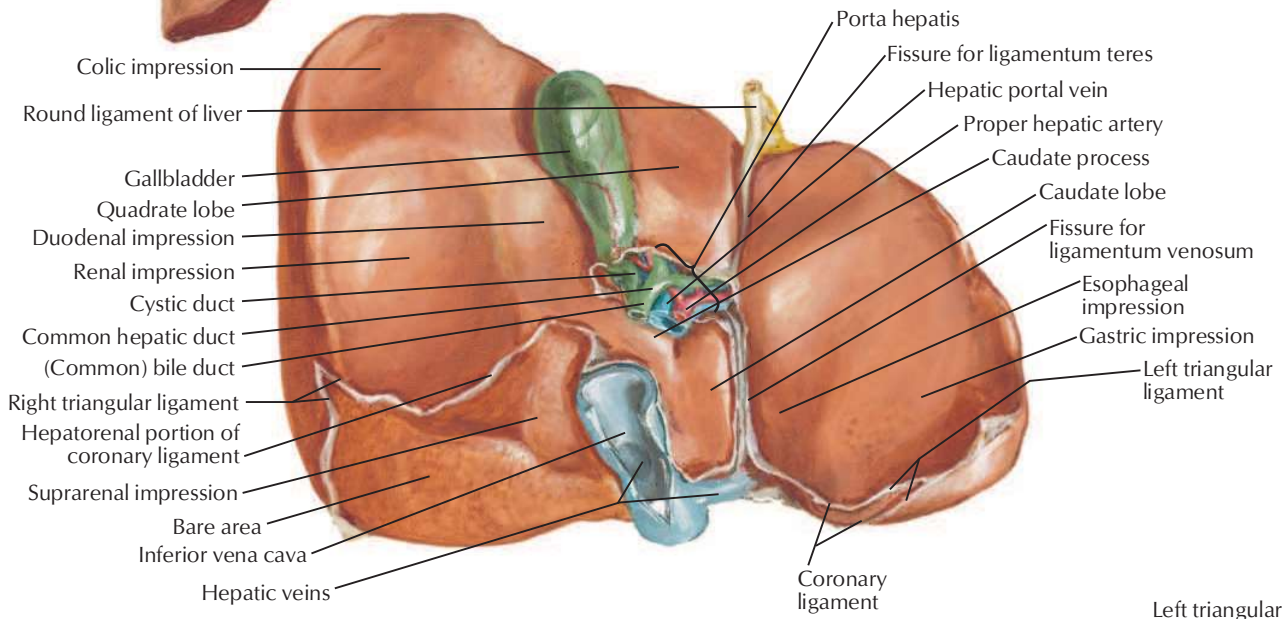
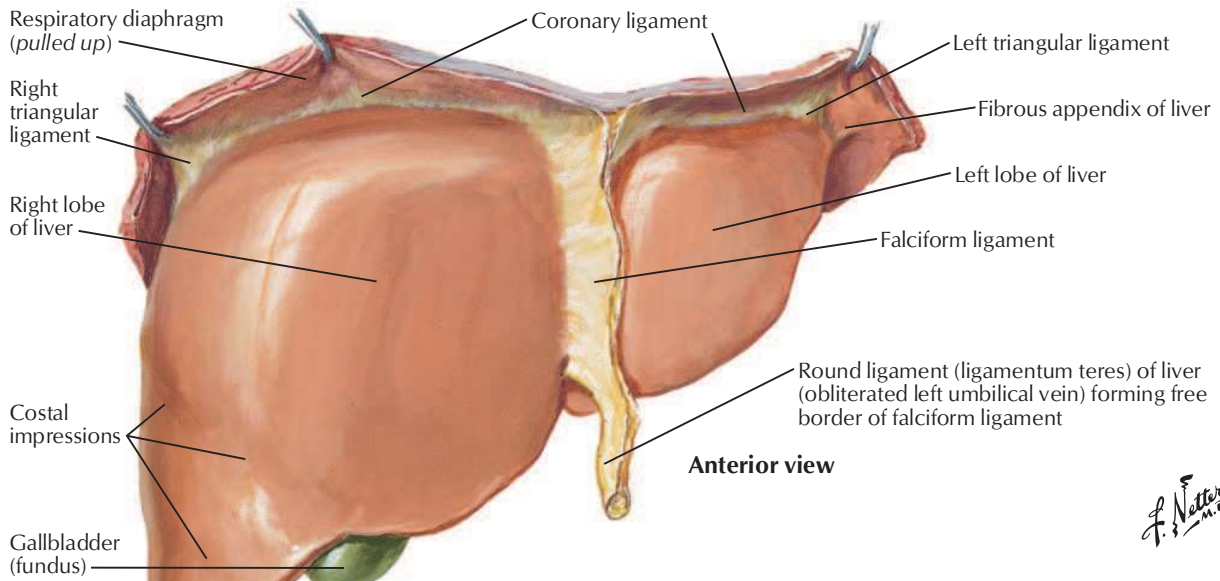
Coronal CT image with oral and intravenous contrast

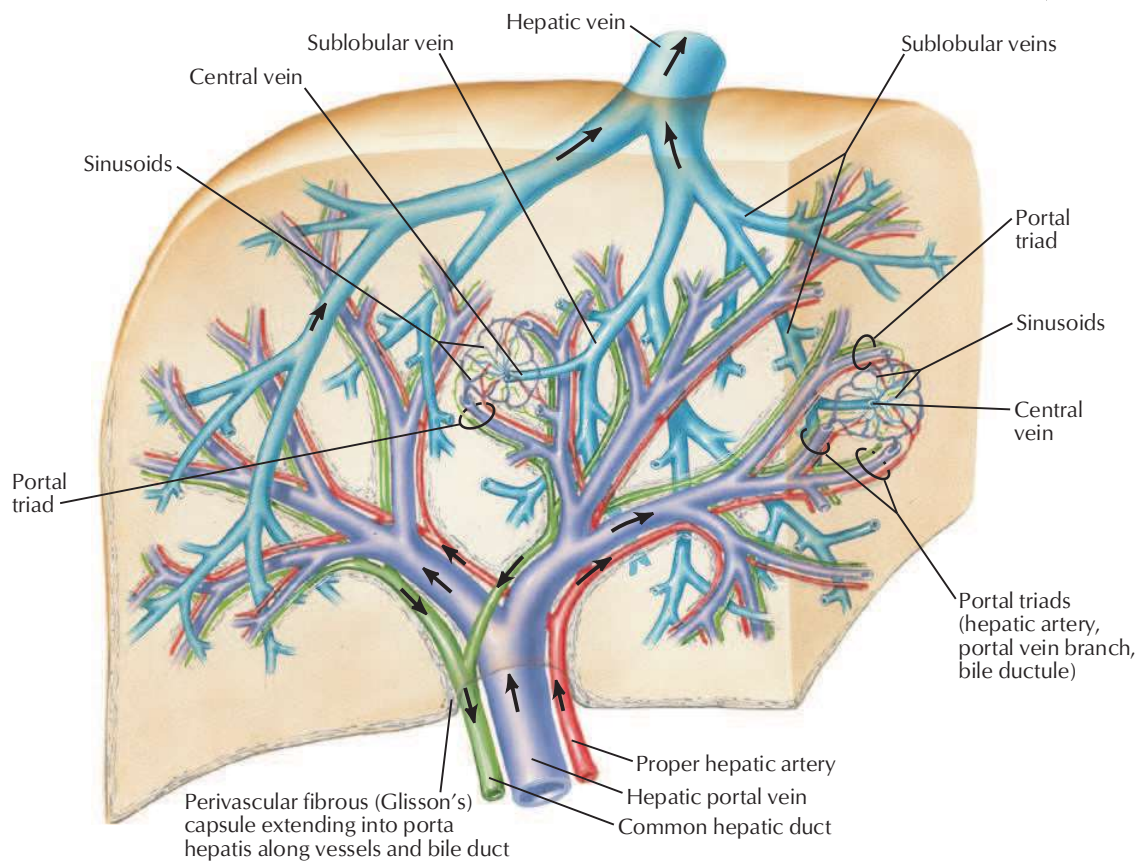
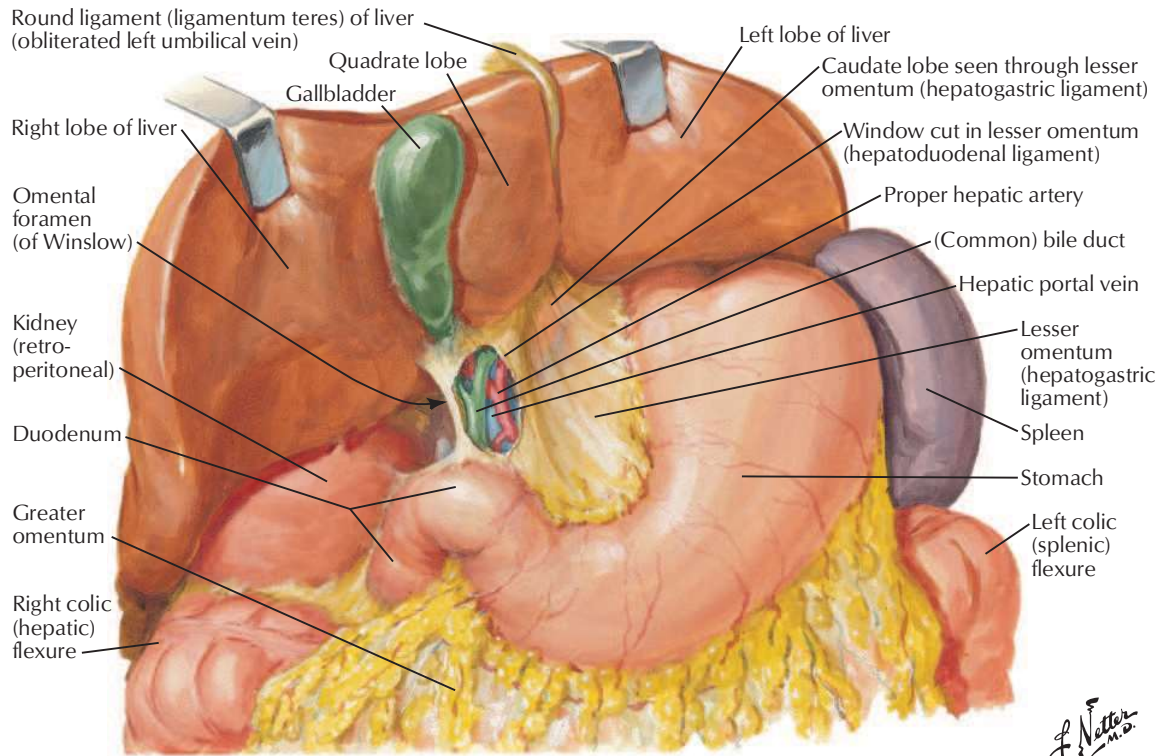


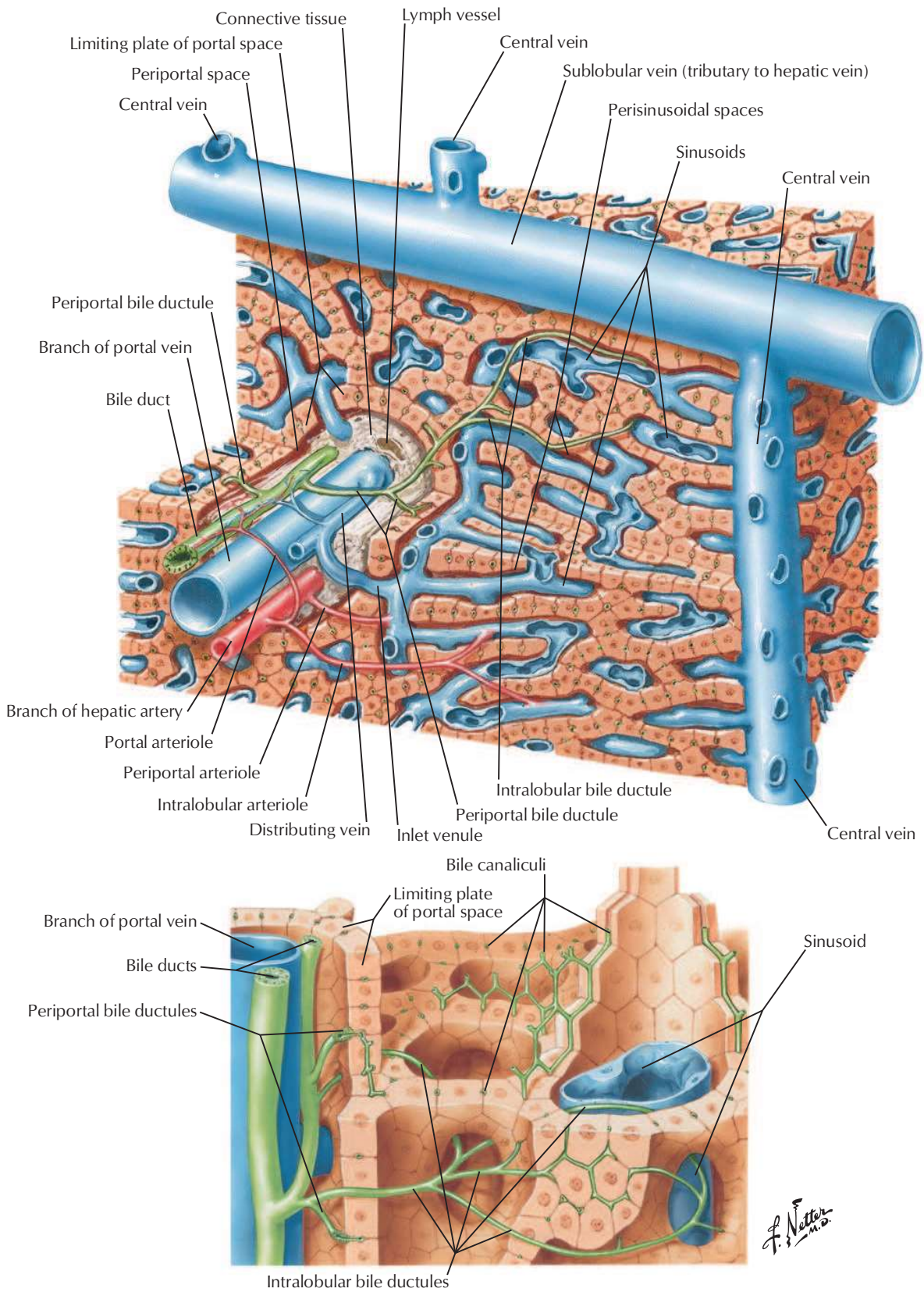


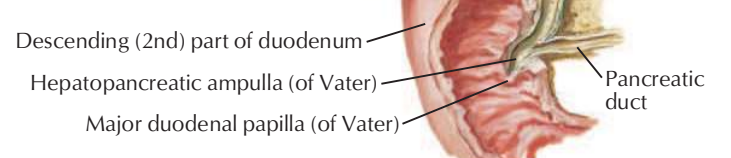
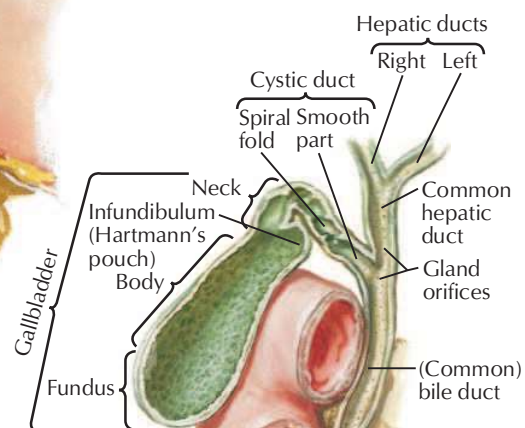
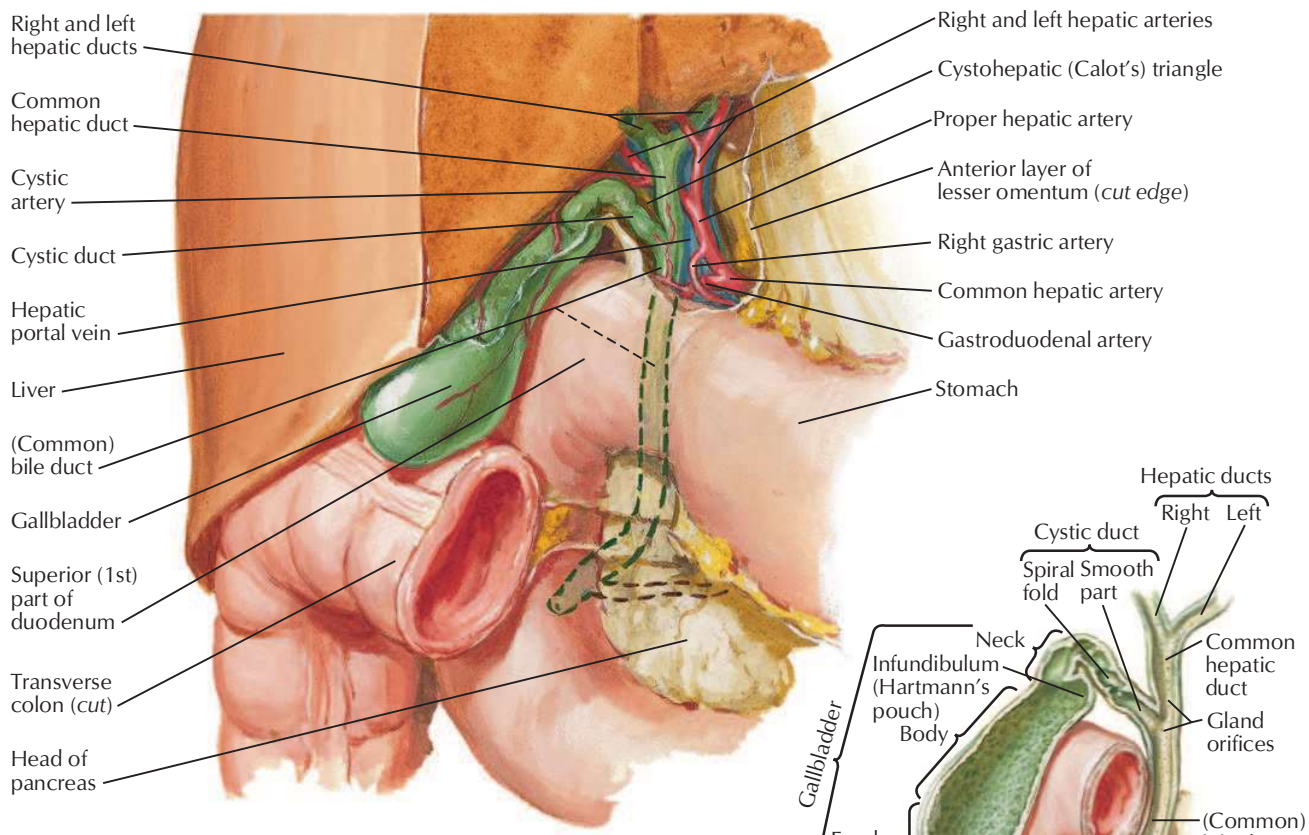
Surfaces and Bed of Liver

See also **Plate 275**

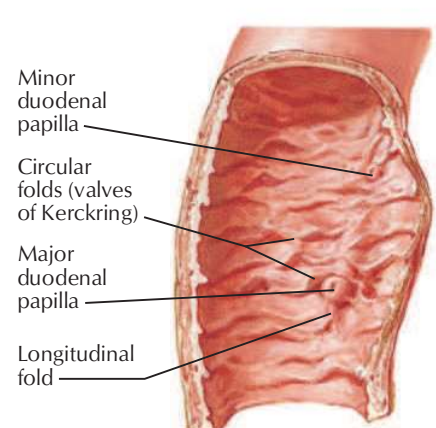




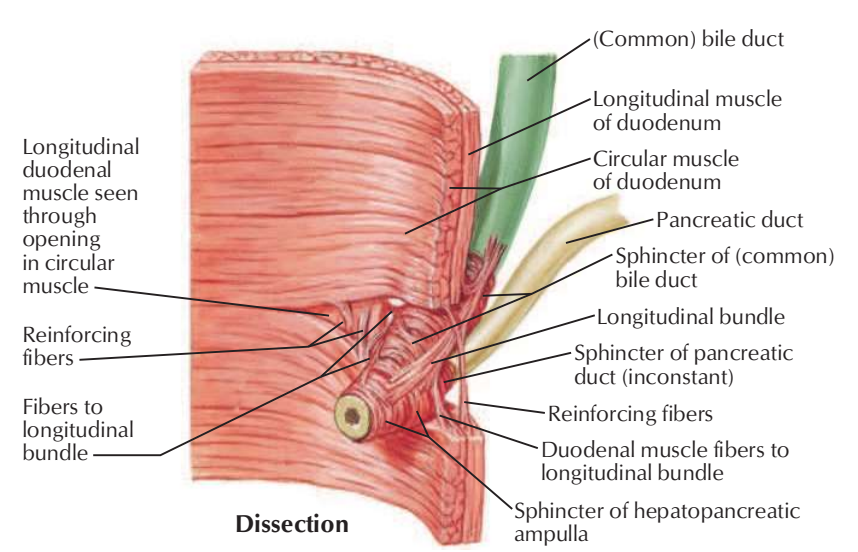




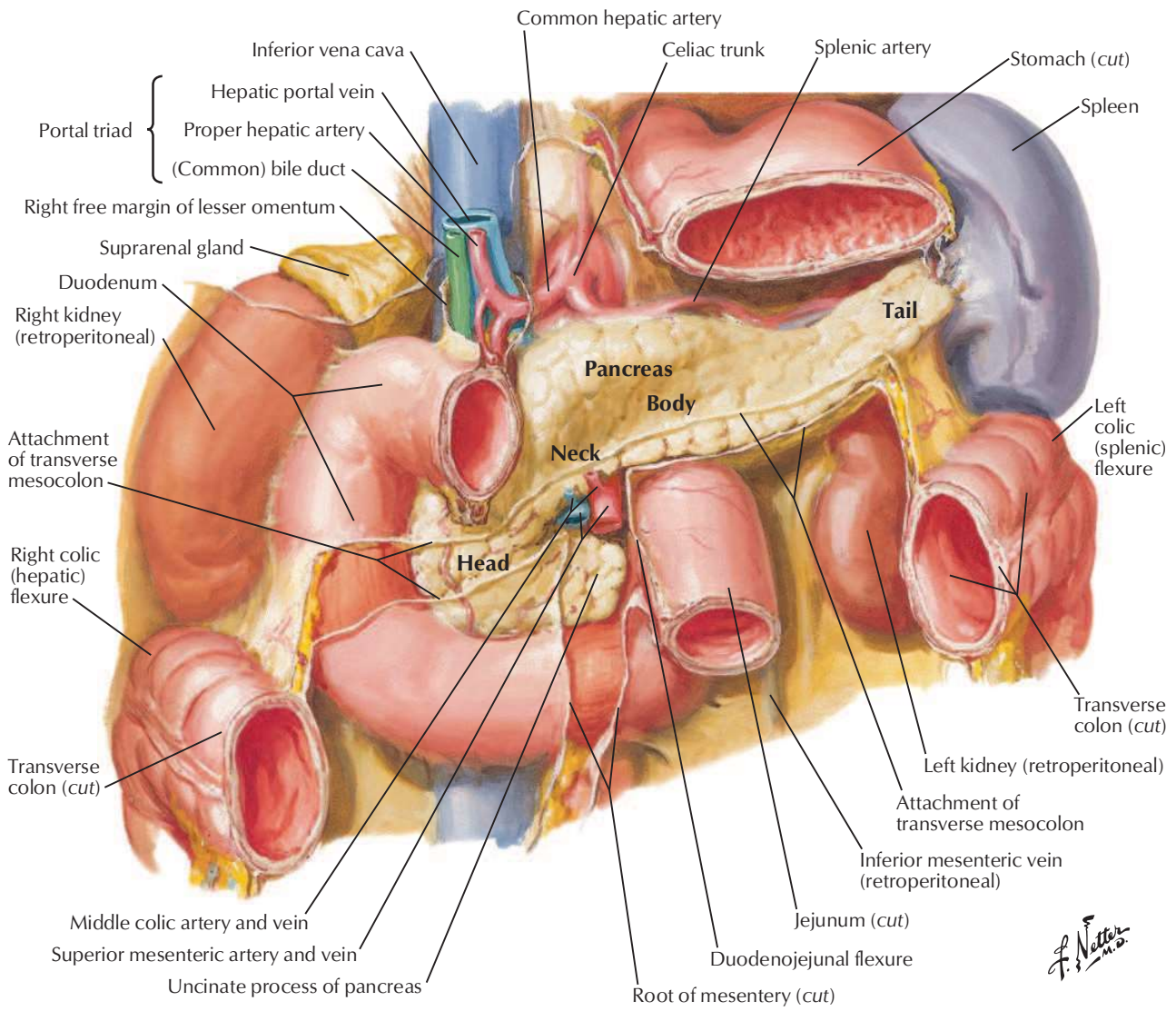
F. Netter M.D.



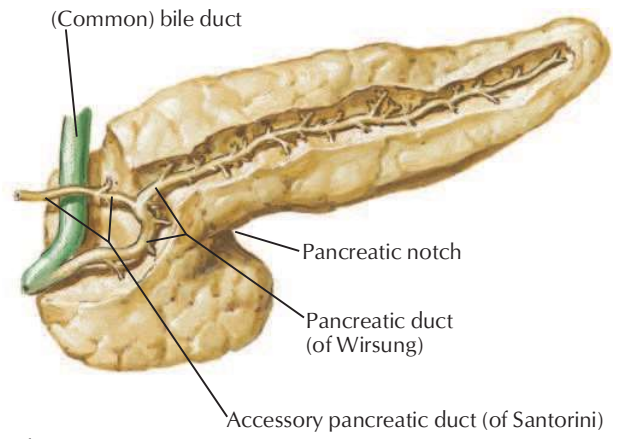
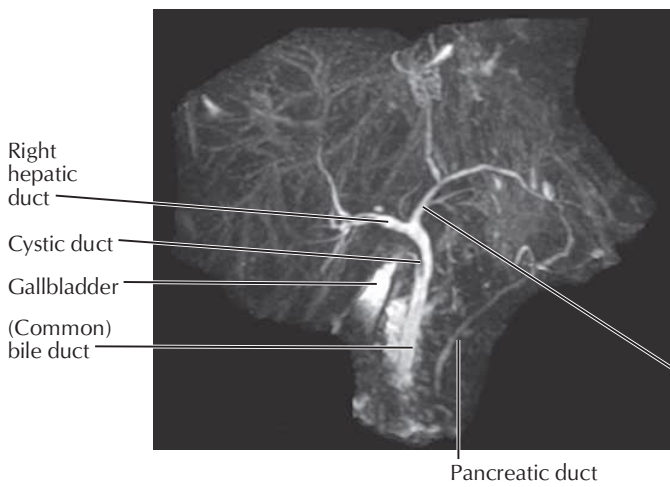
Interior of descending (2nd) part of duodenum

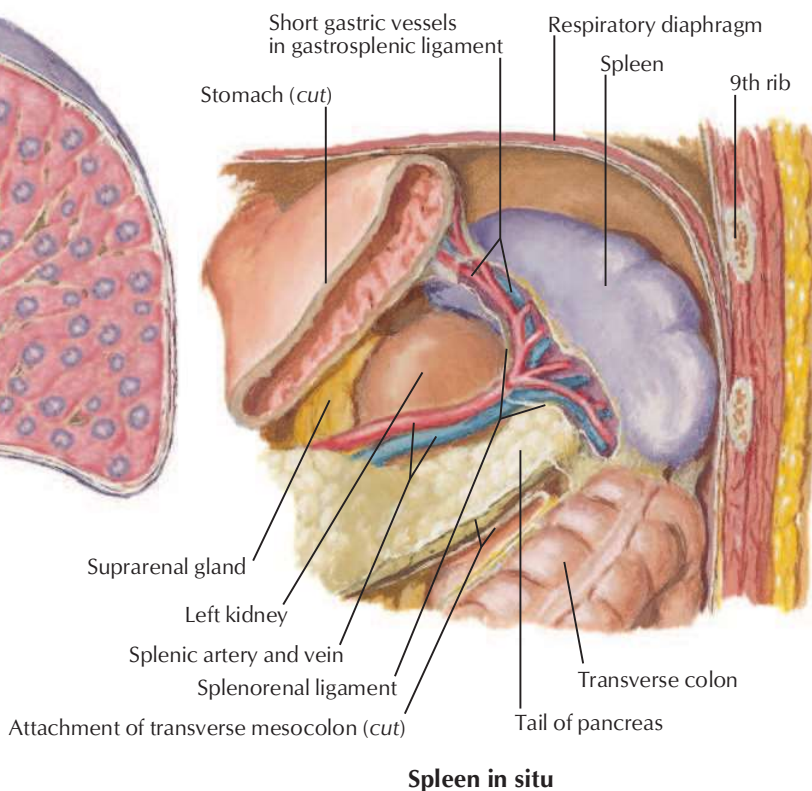
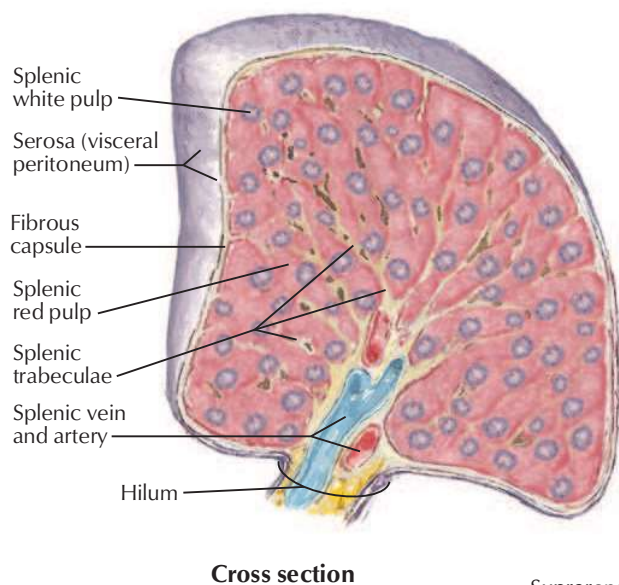
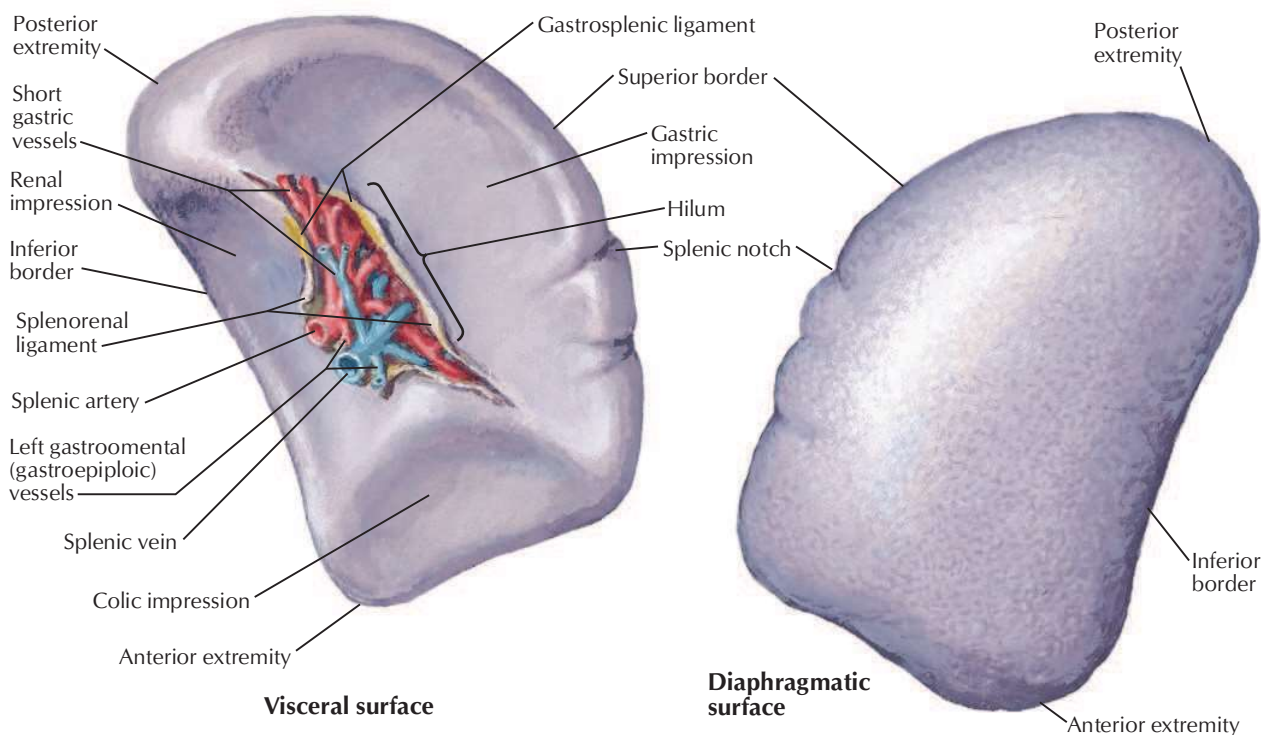


Dissection

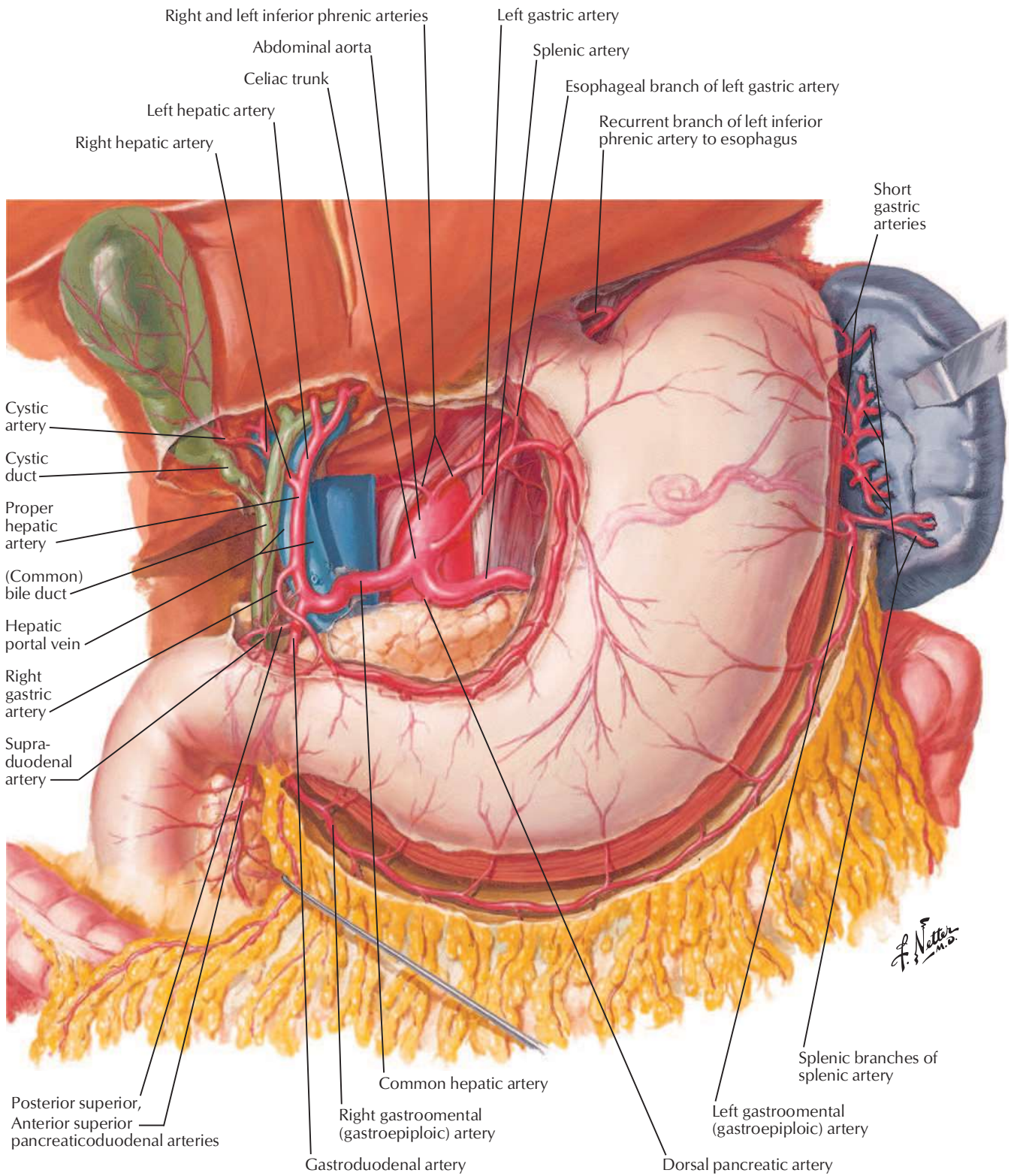


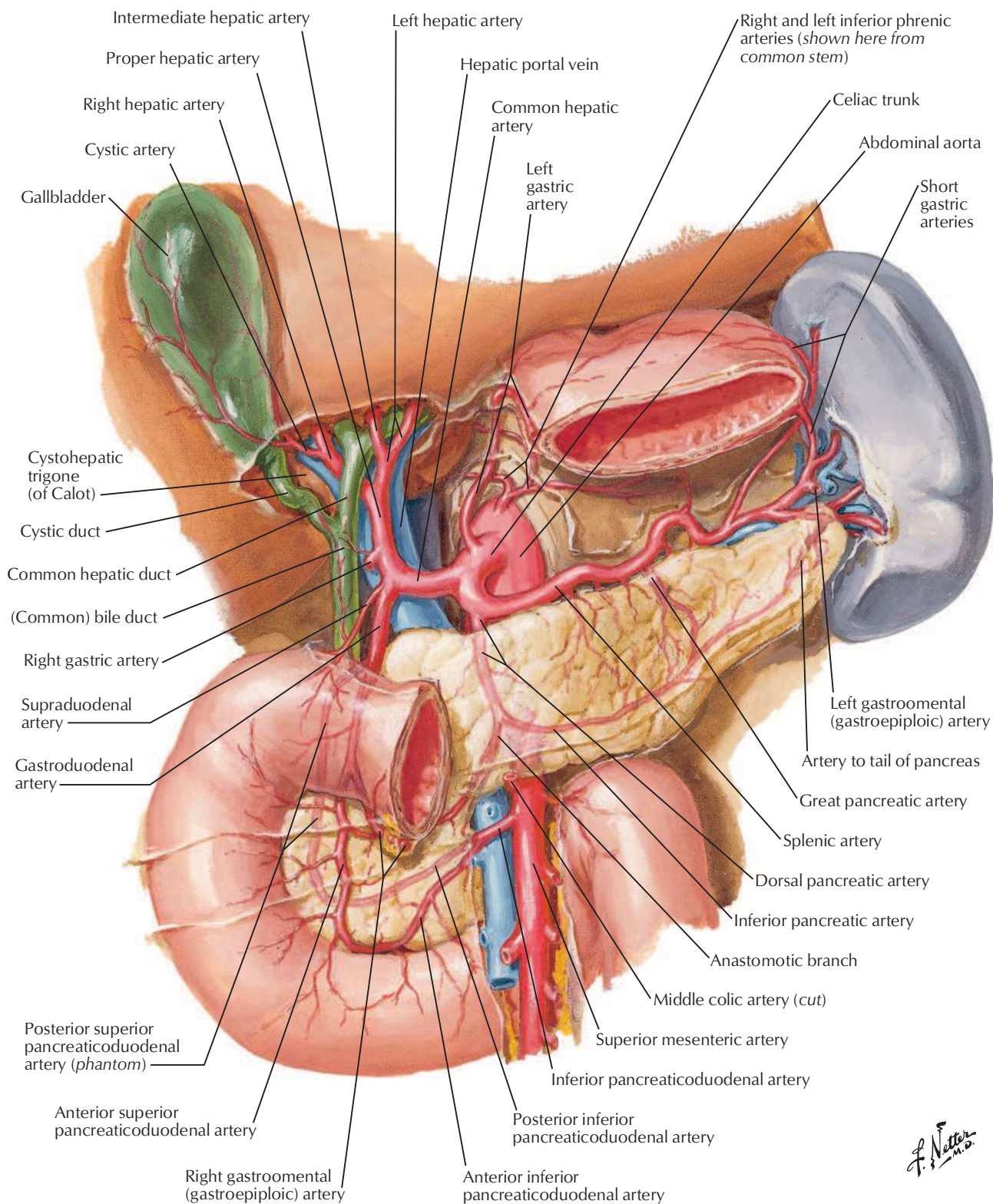
Magnetic resonance cholangiopancreatography (MRCP)





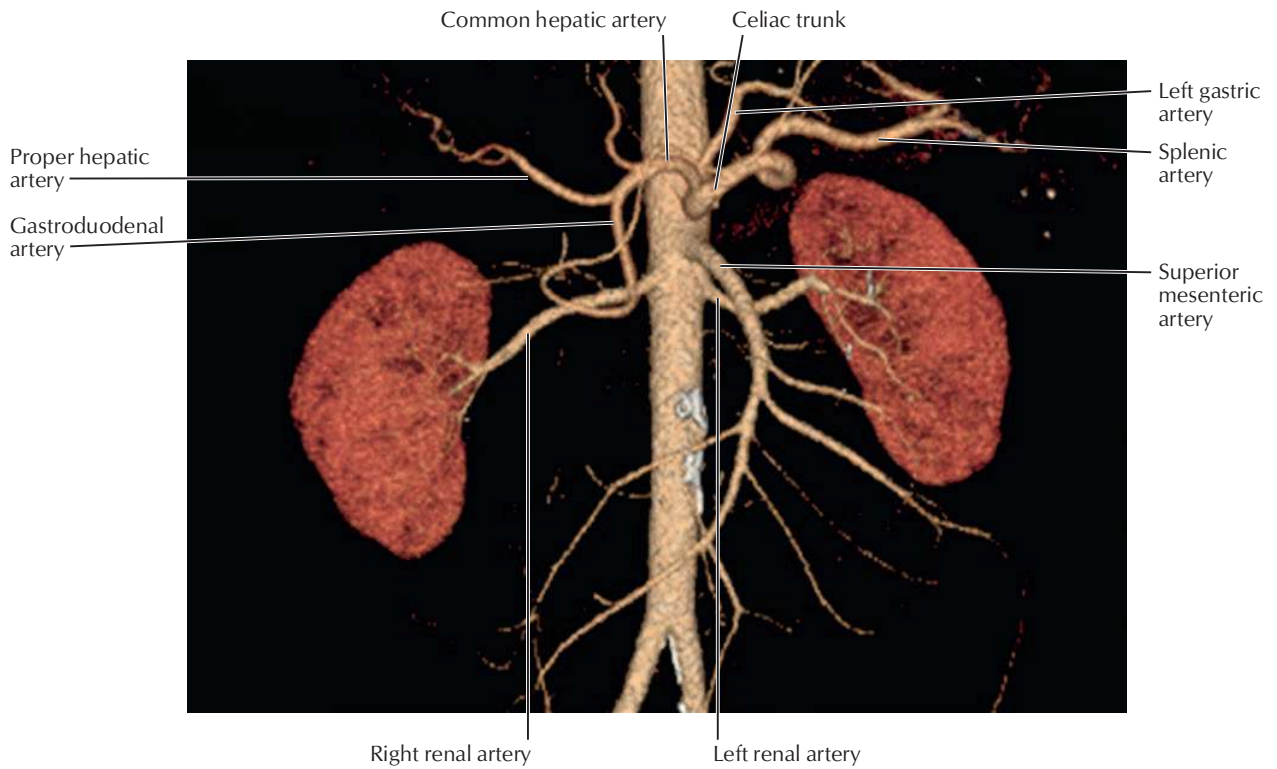
F. Netter M.D.



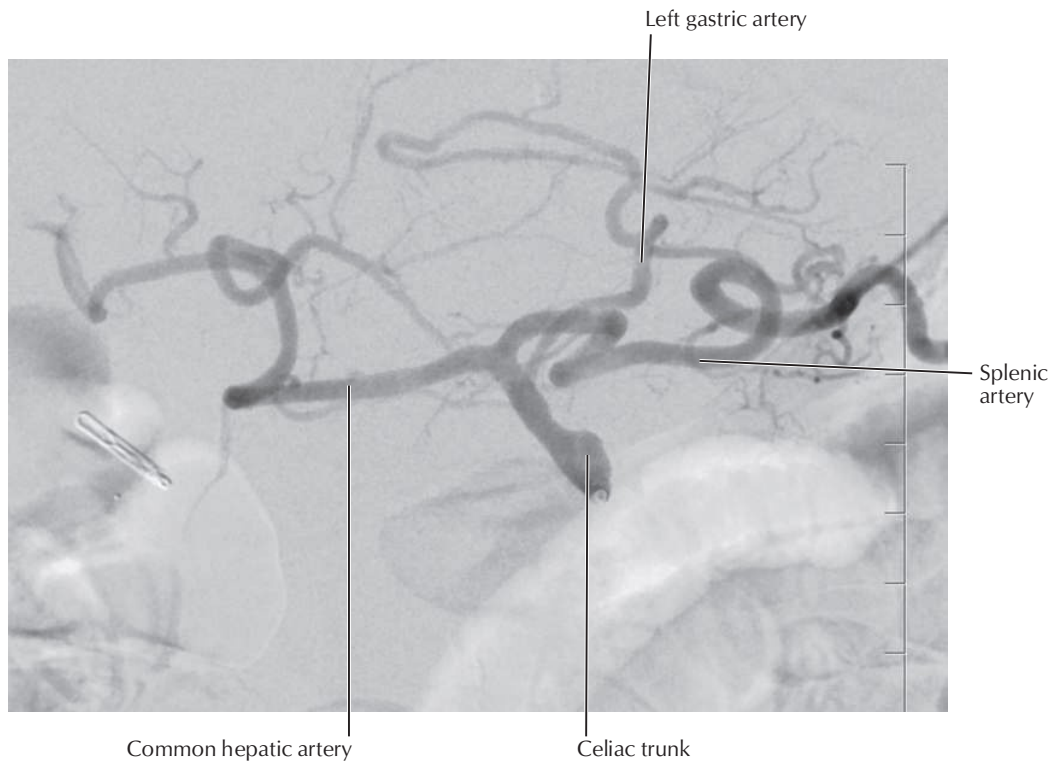

F. Netter M.D.

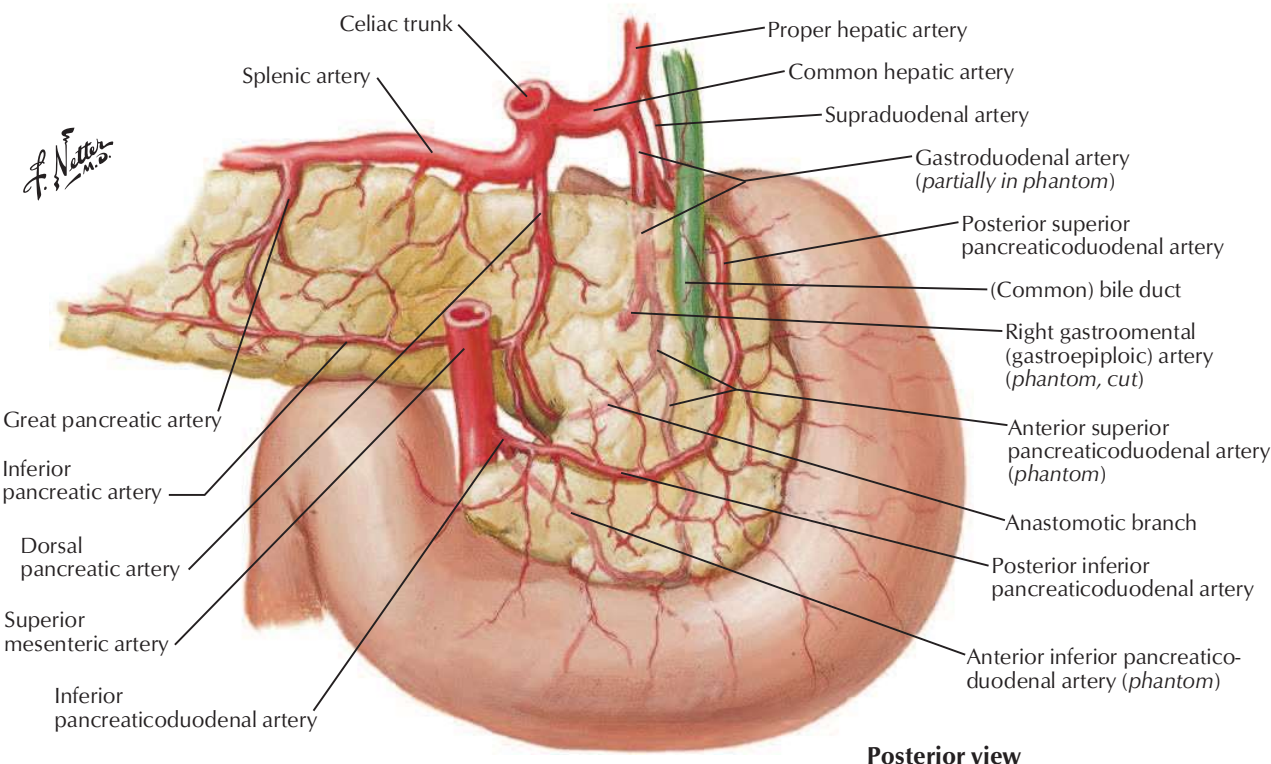
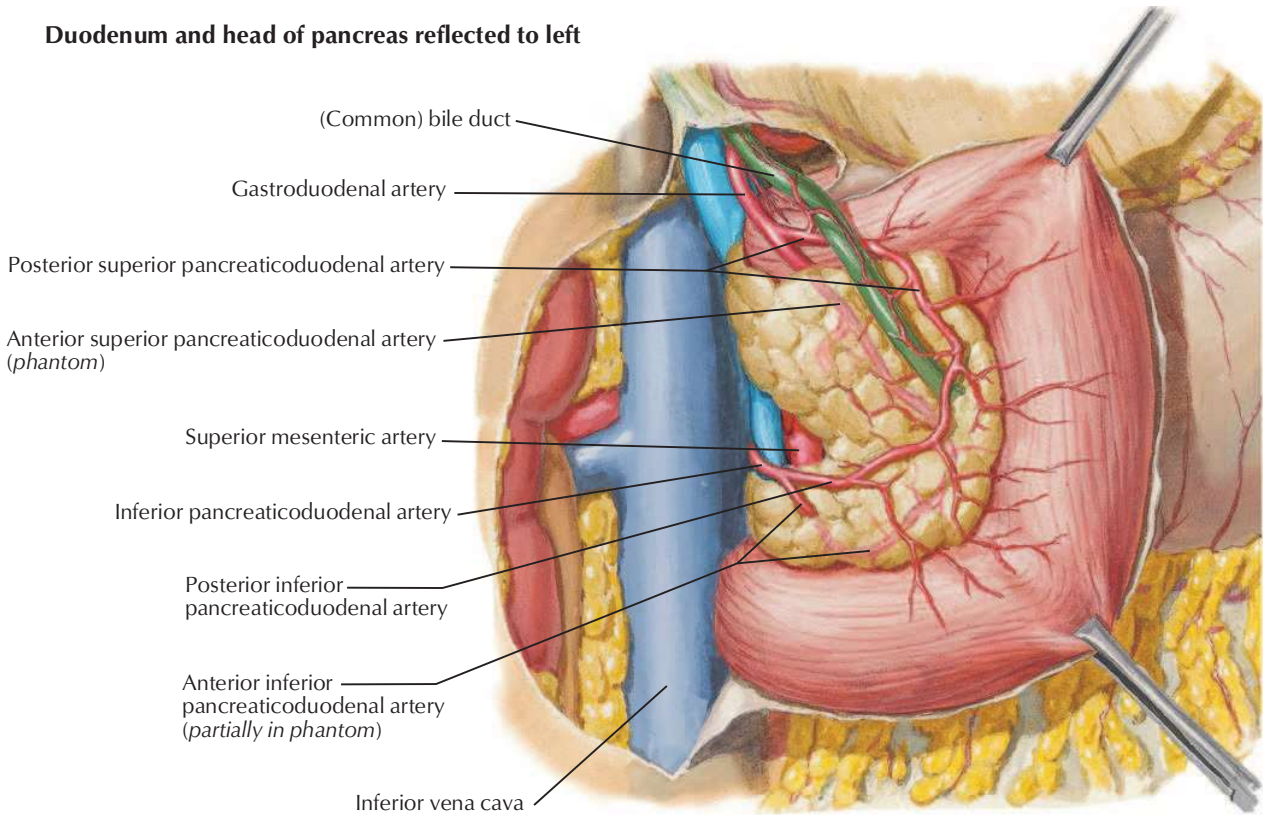
3D volume-rendered CT image with intravenous contrast enhancement



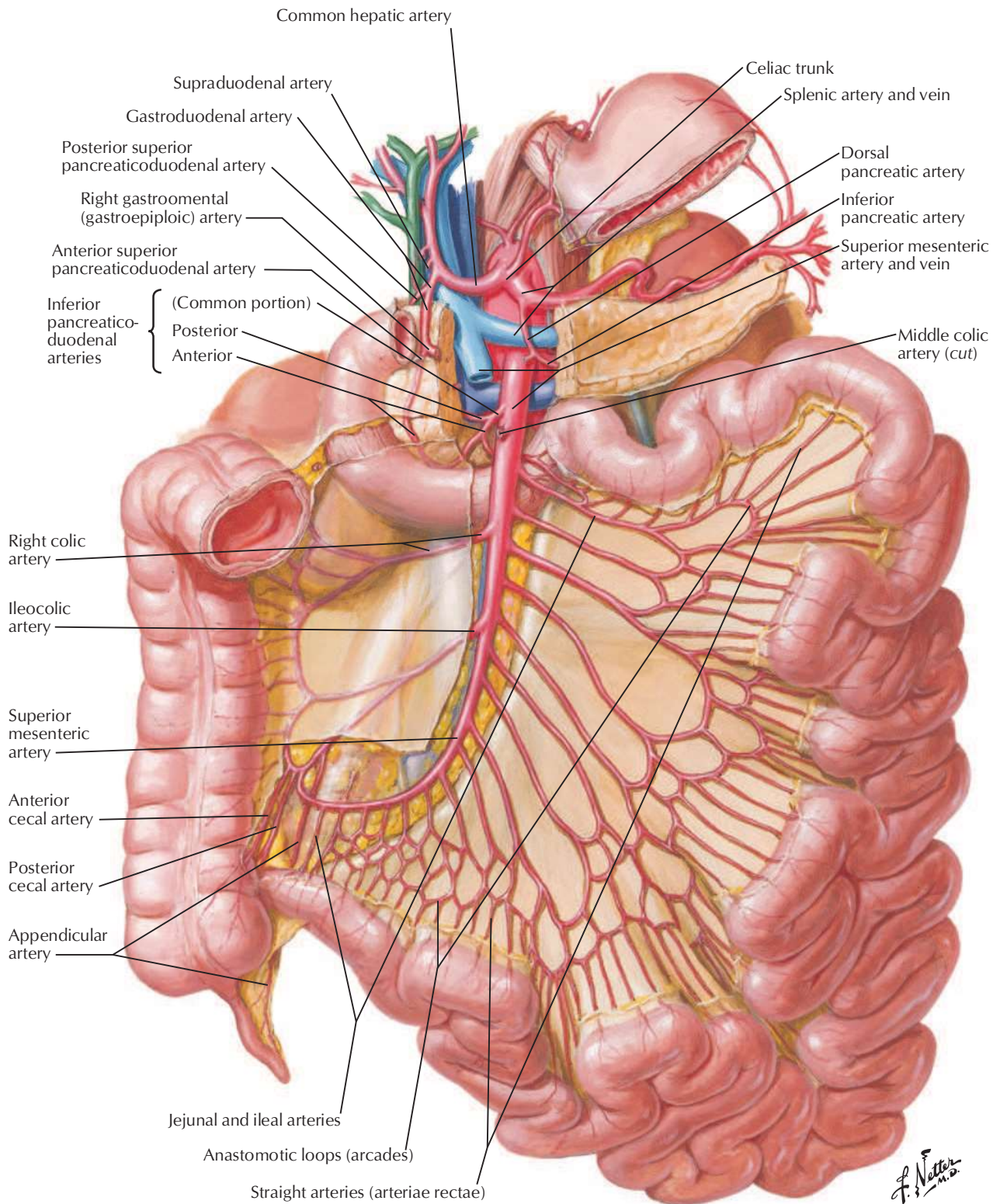
Selective digital subtraction angiogram, celiac trunk

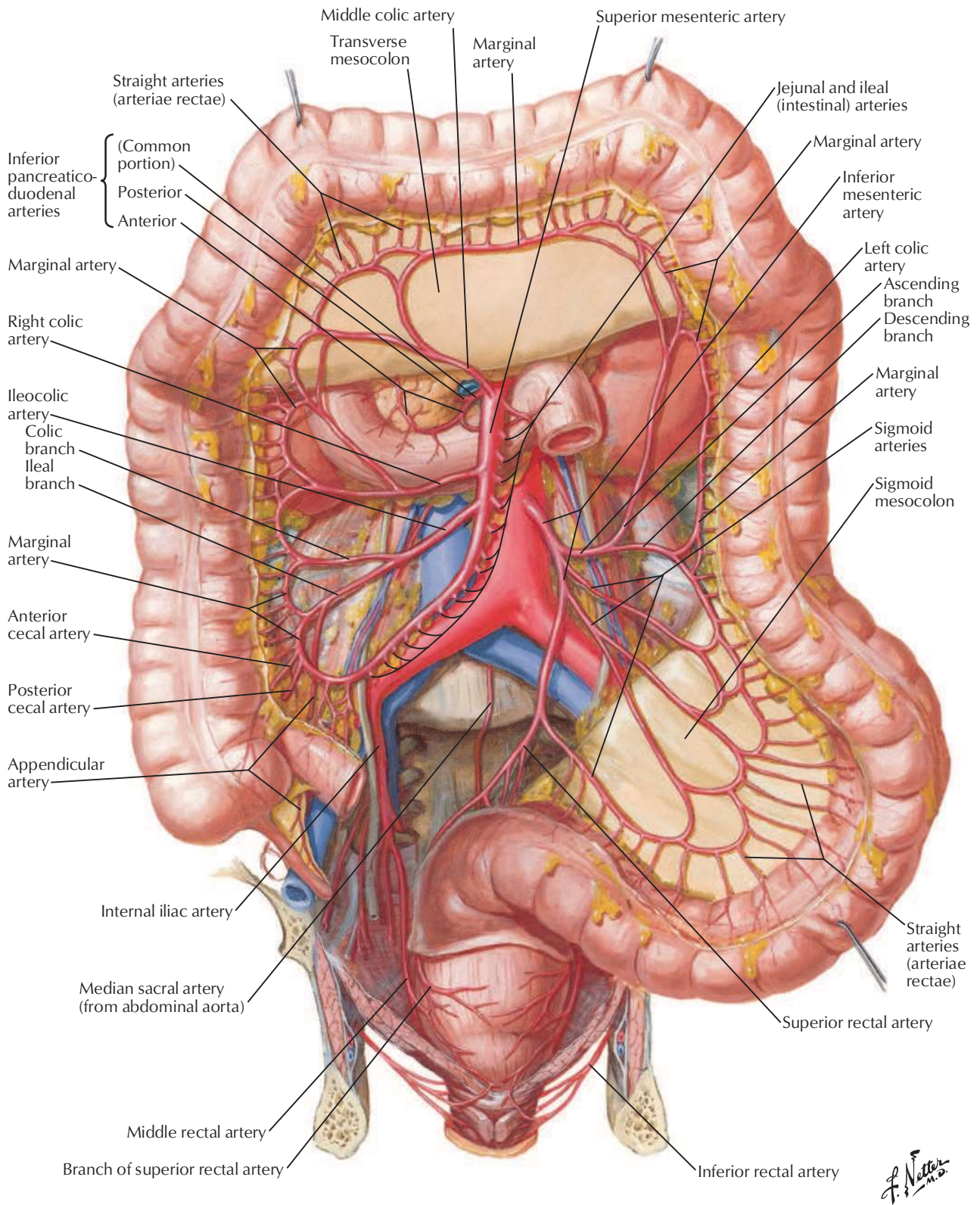


Duodenum and head of pancreas reflected to left

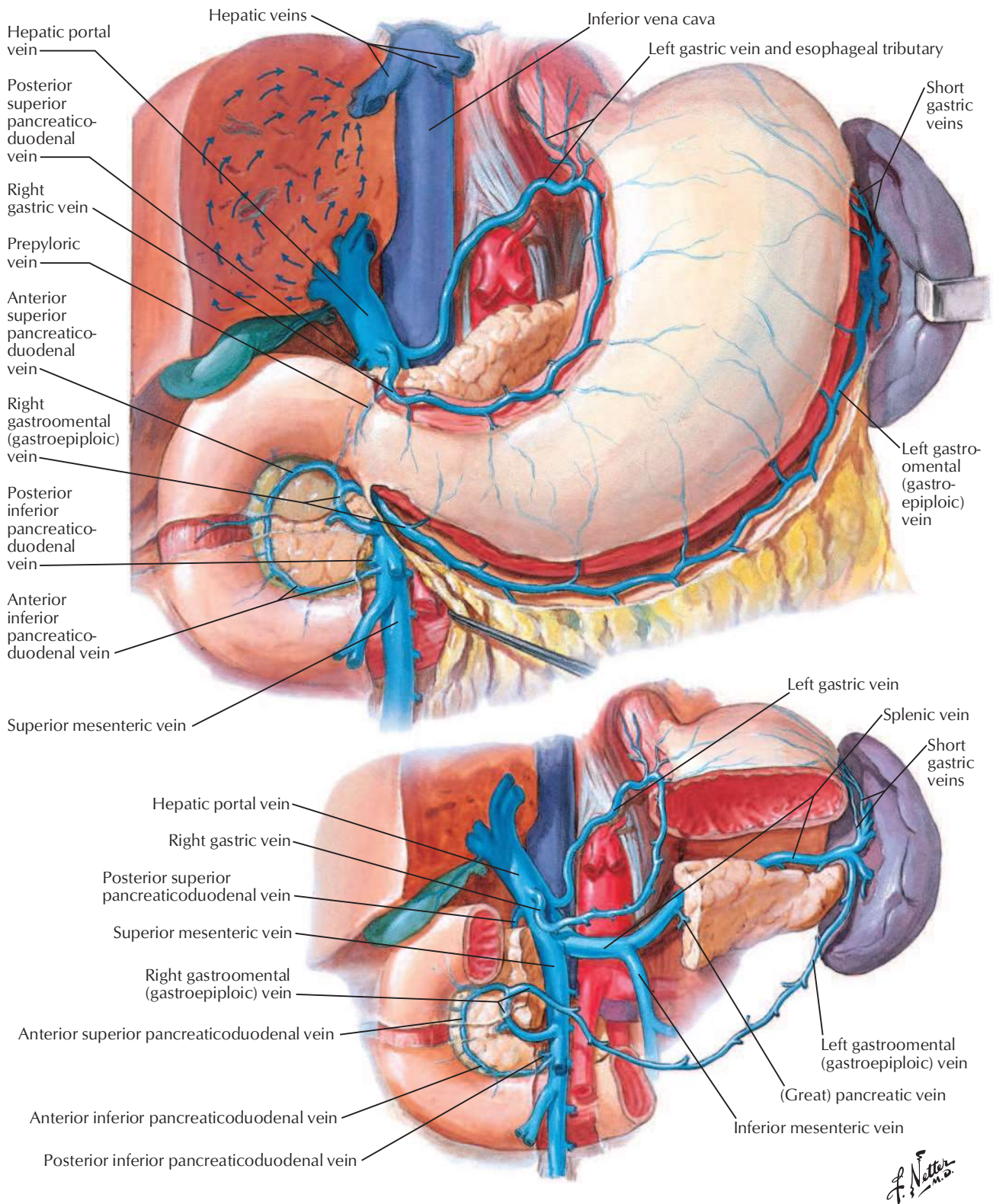


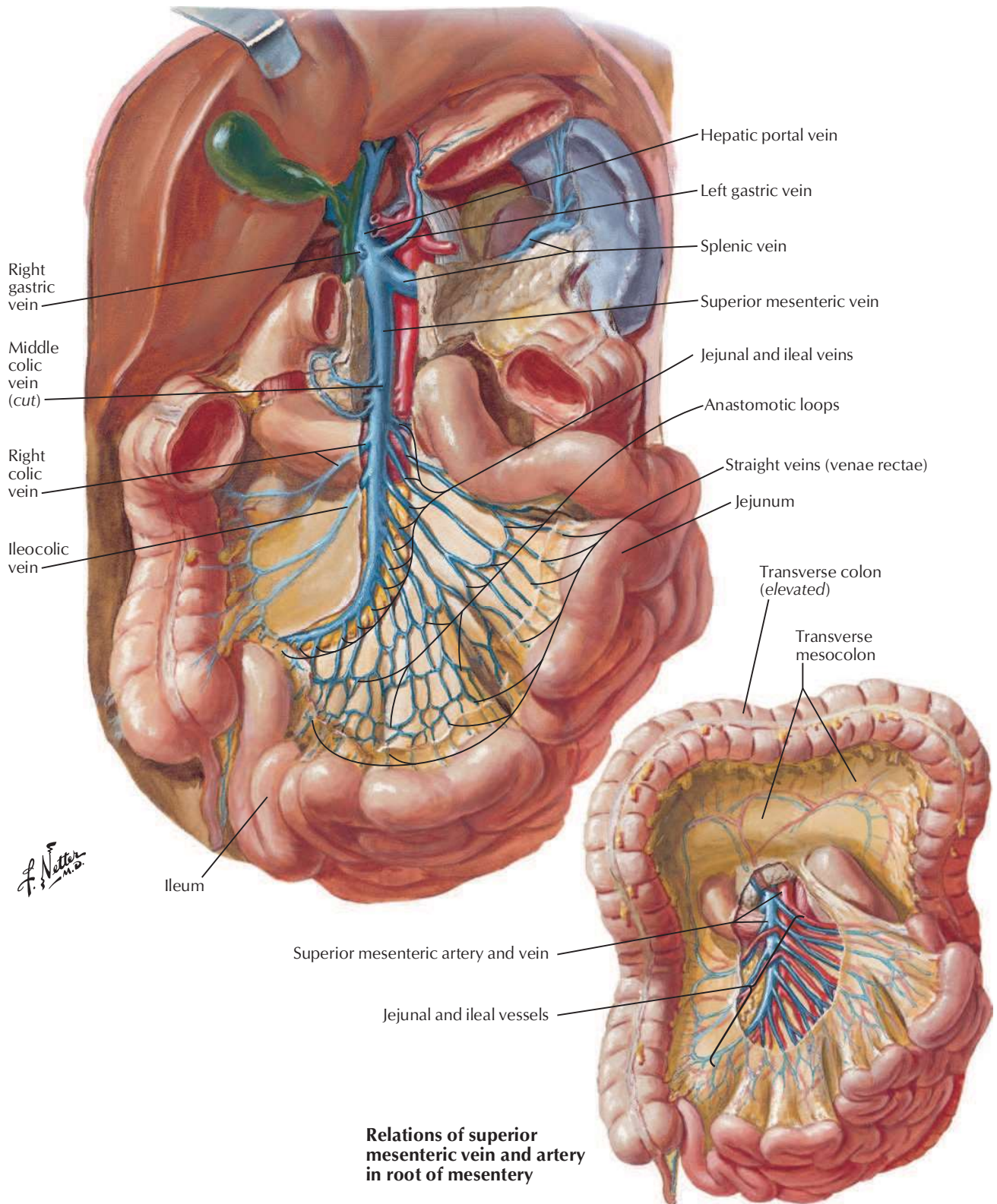
Posterior view





Veins of Stomach, Duodenum, Pancreas, and Spleen

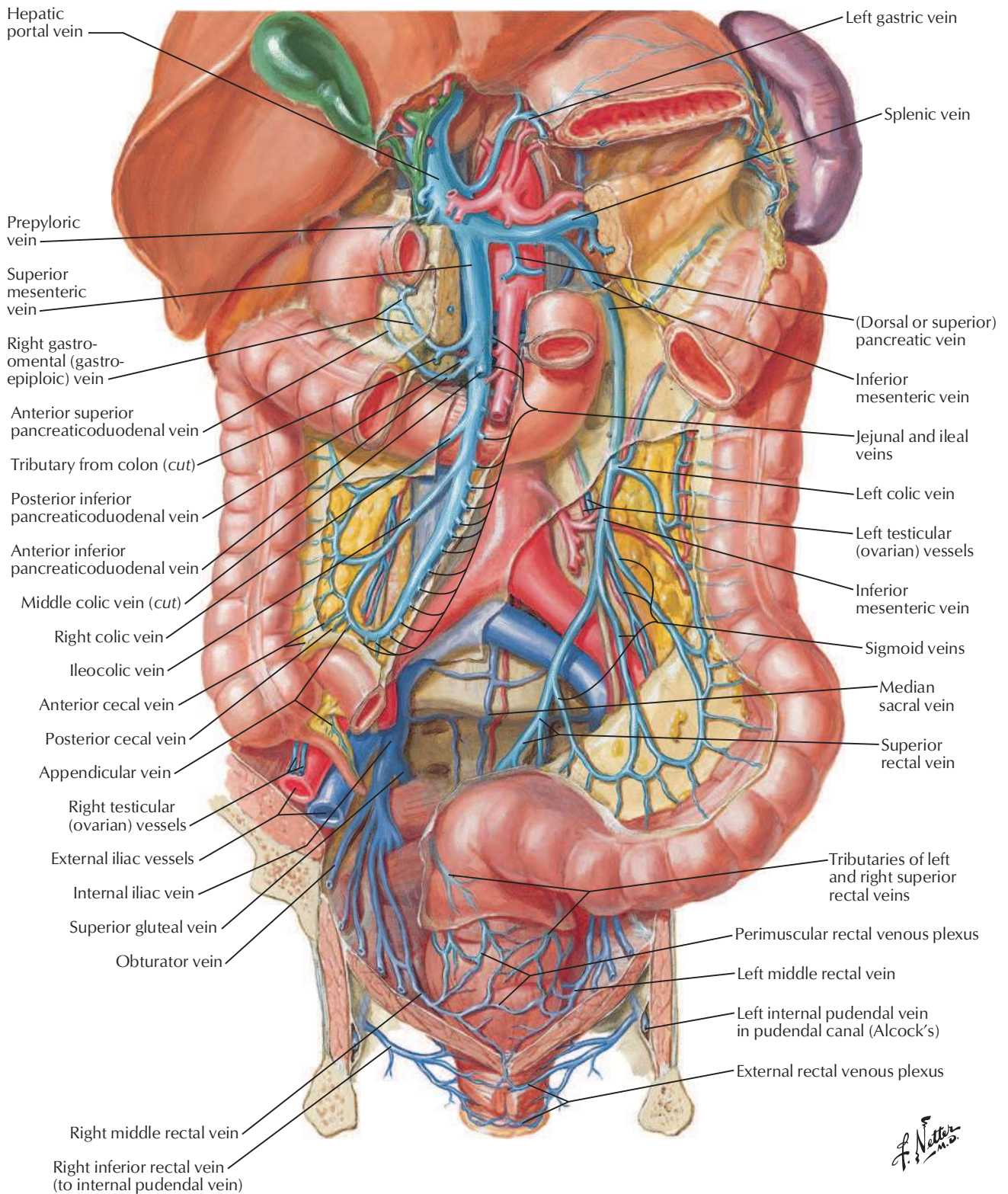


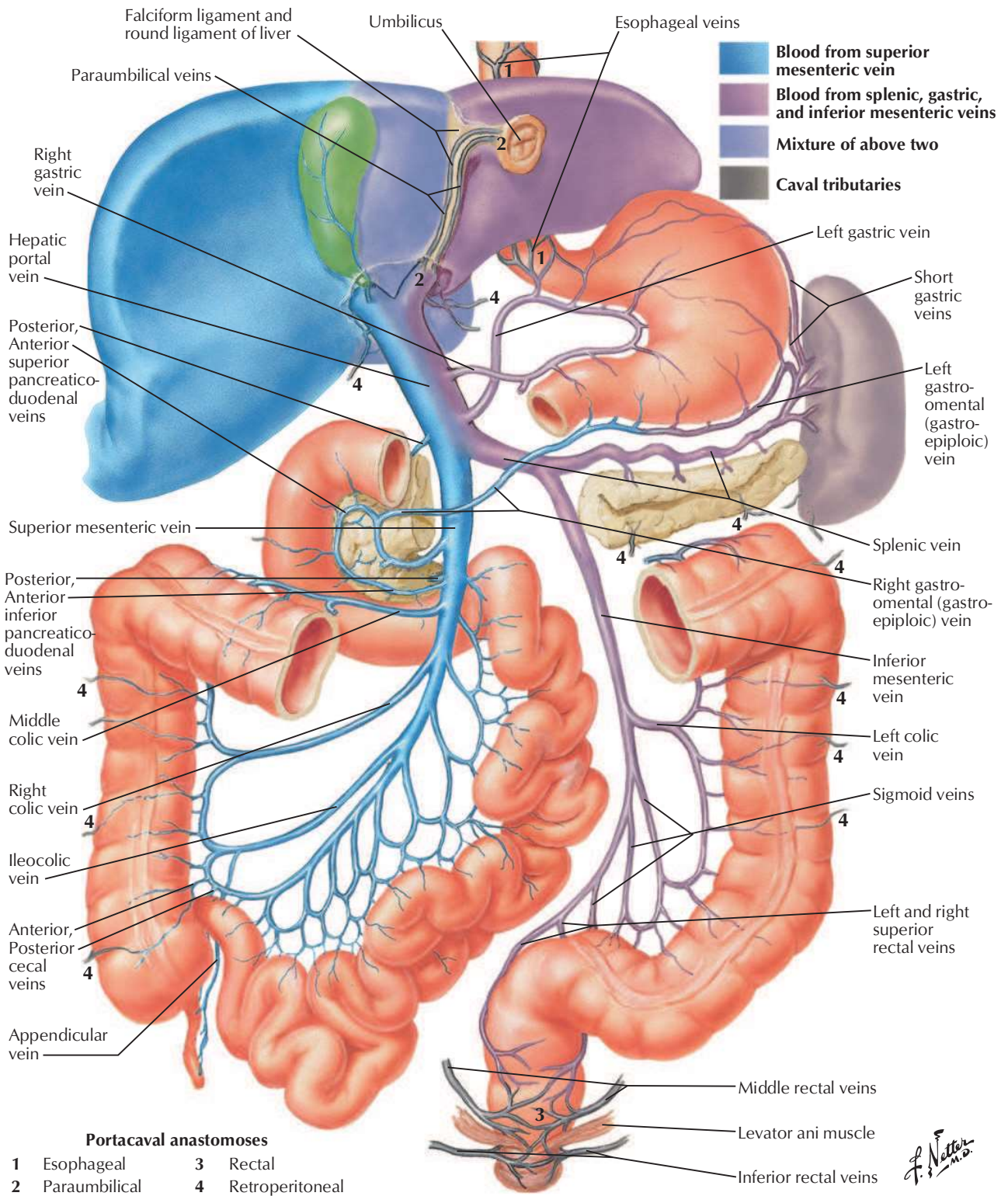


Relations of superior mesenteric vein and artery in root of mesentery

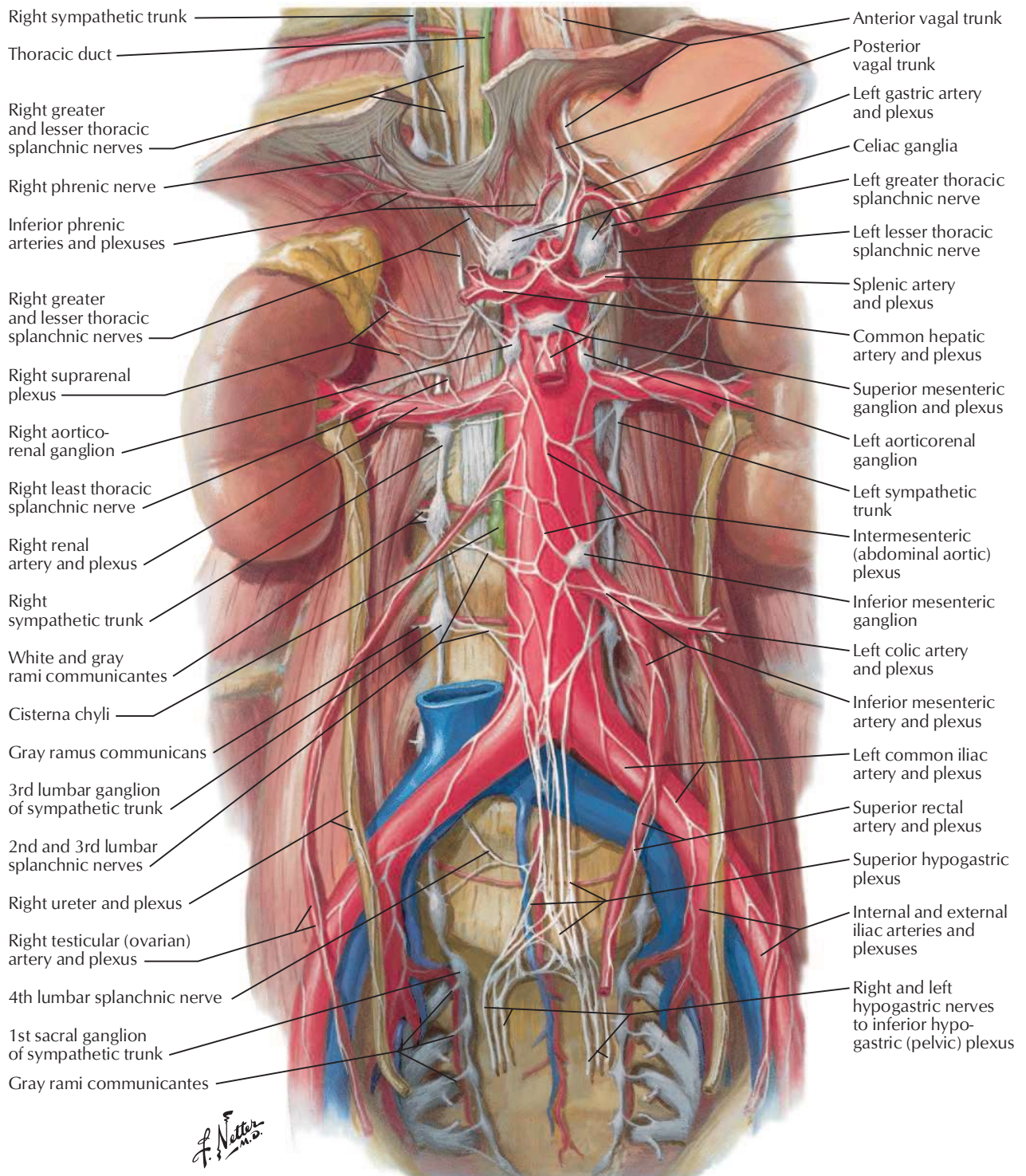
Veins of Large Intestine

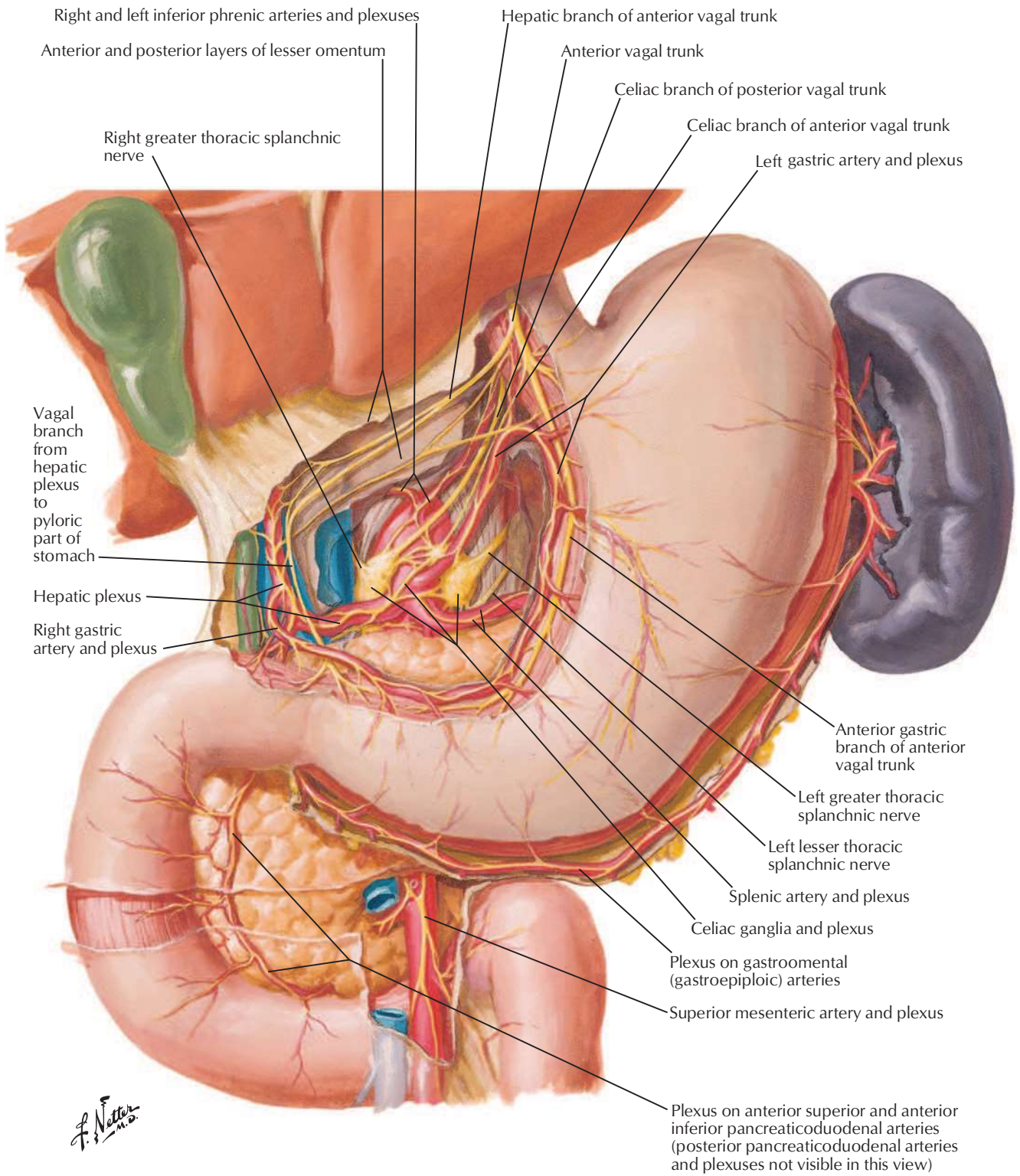
See also [Plate 381](#)



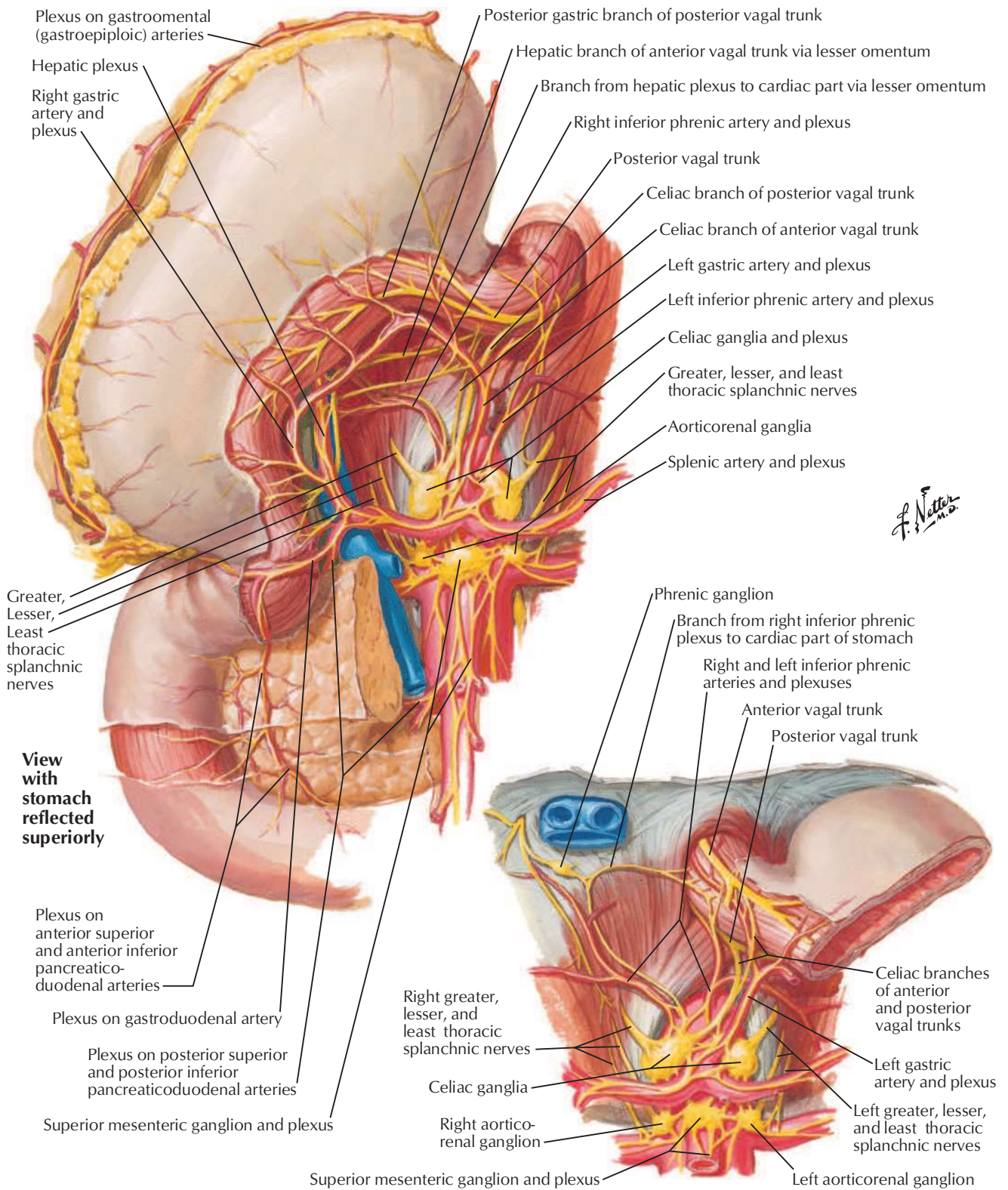


F. Netter M.D.

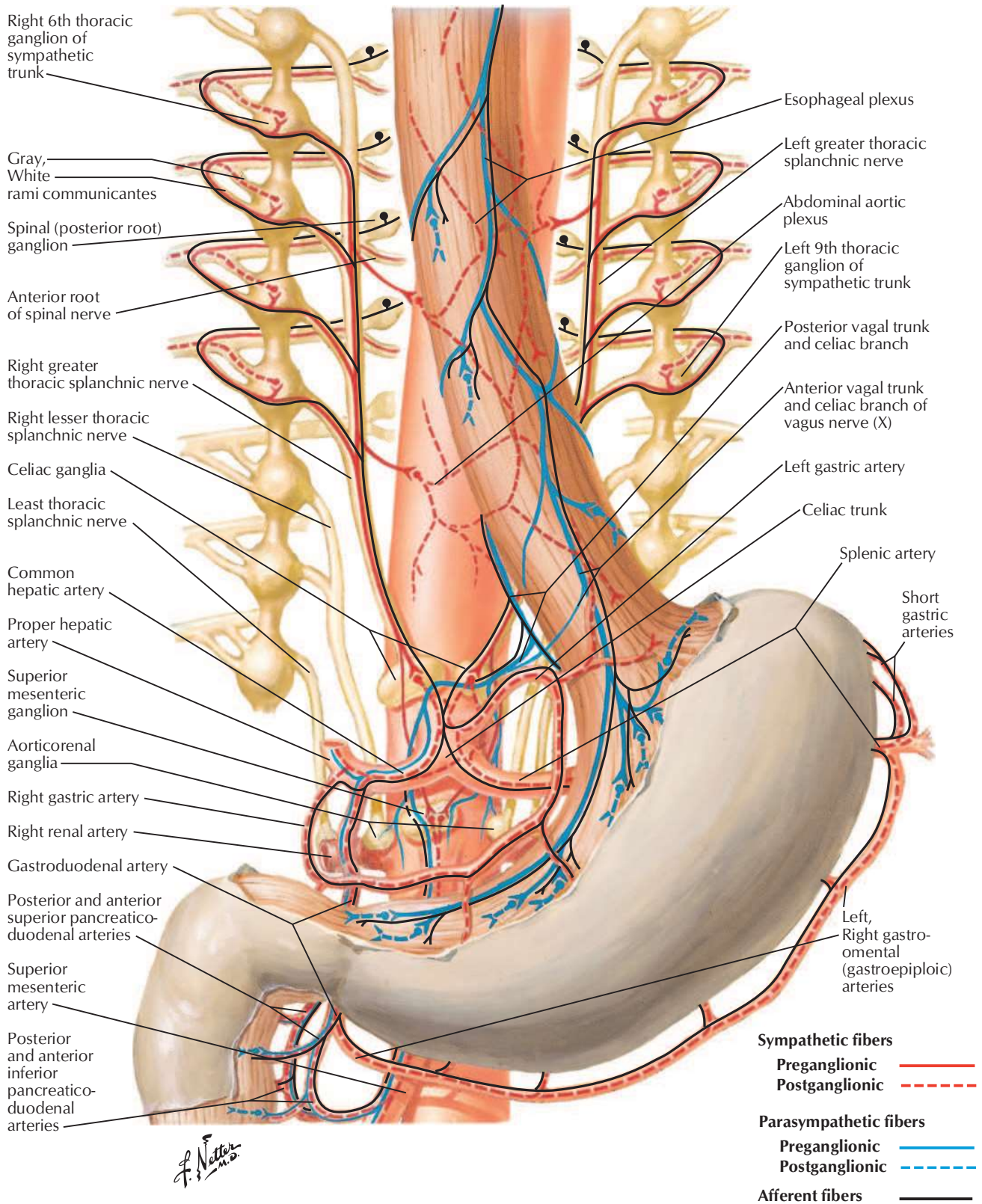


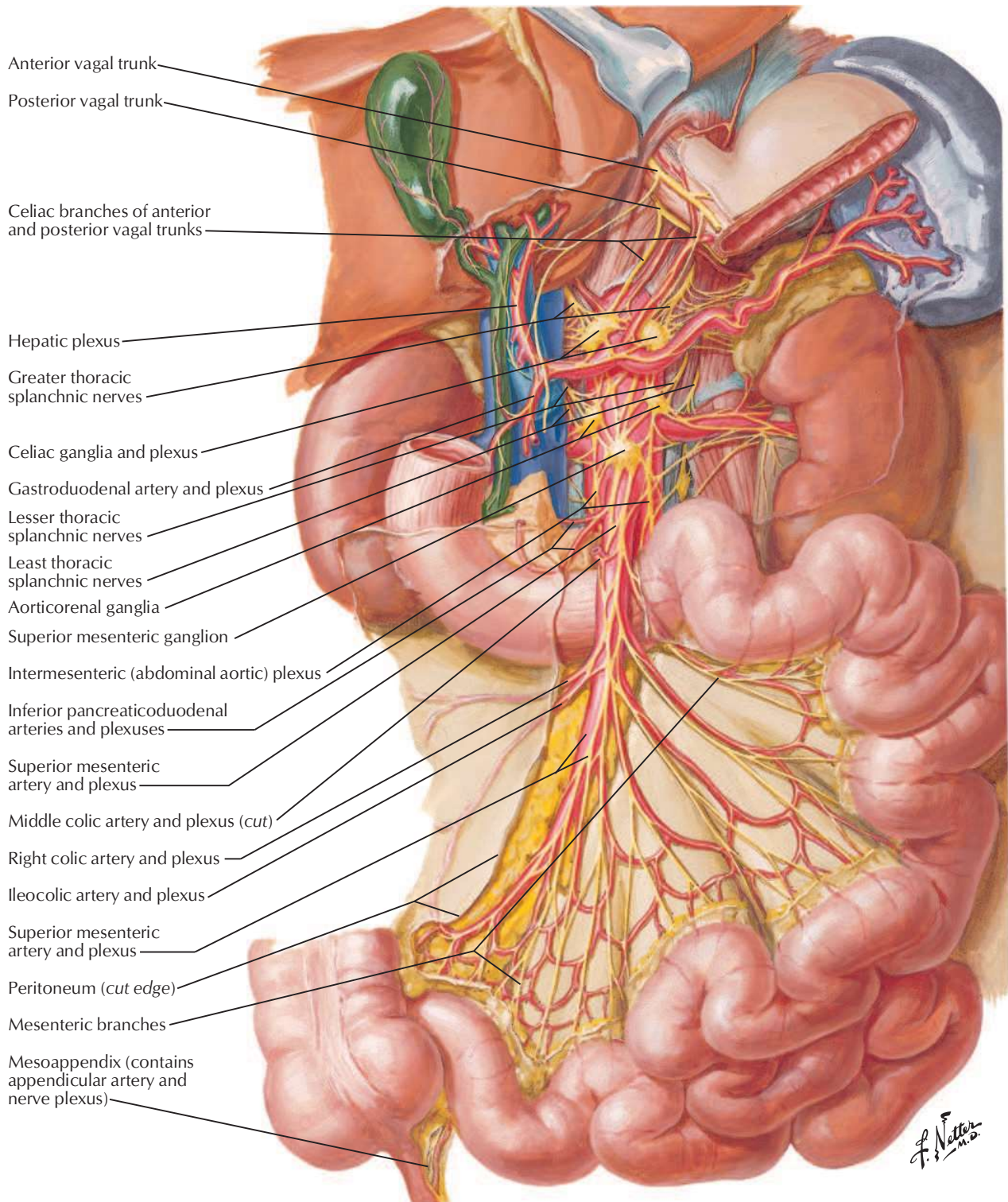


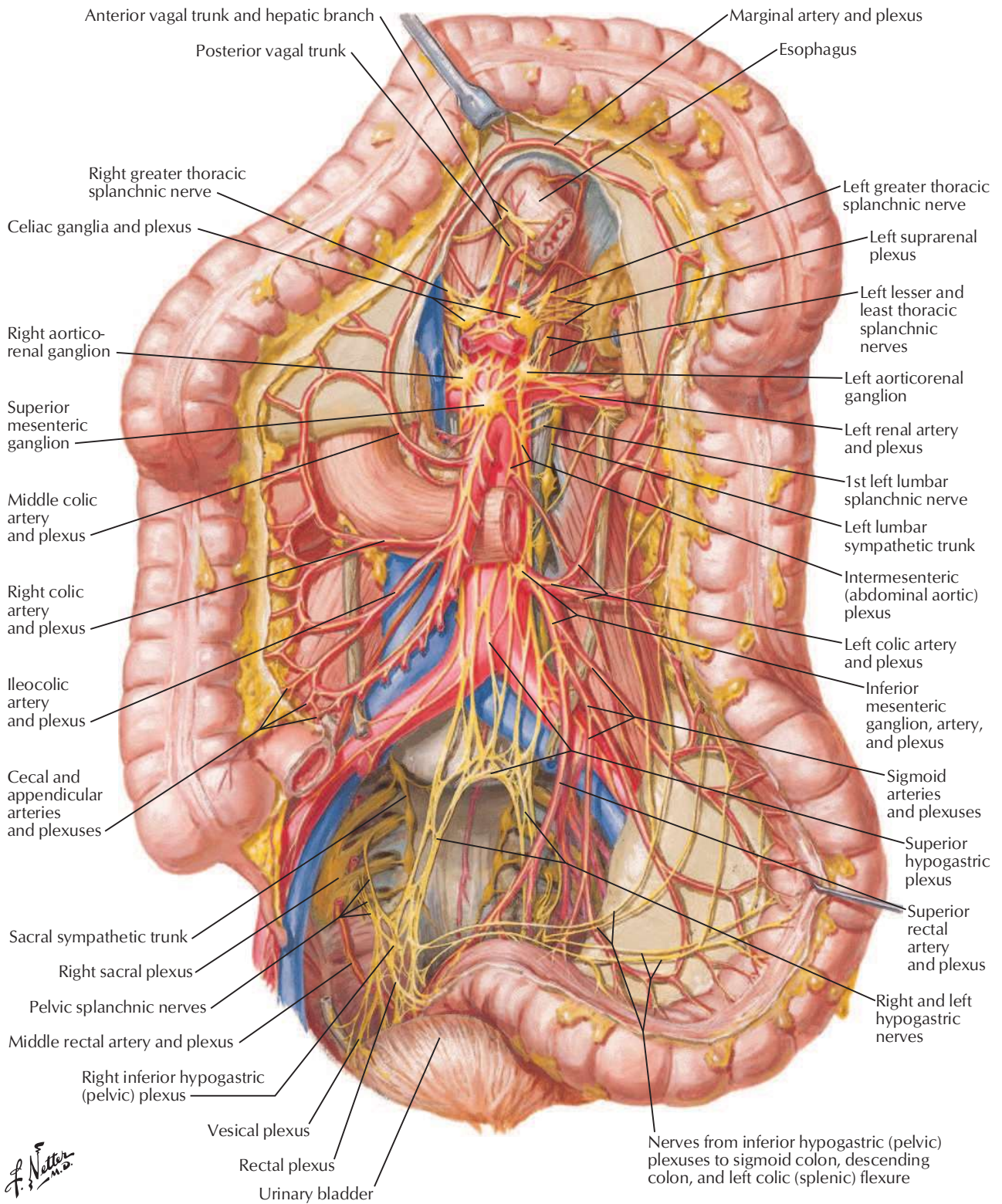
Autonomic Innervation of Stomach and Duodenum (continued)



F. Netter M.D.



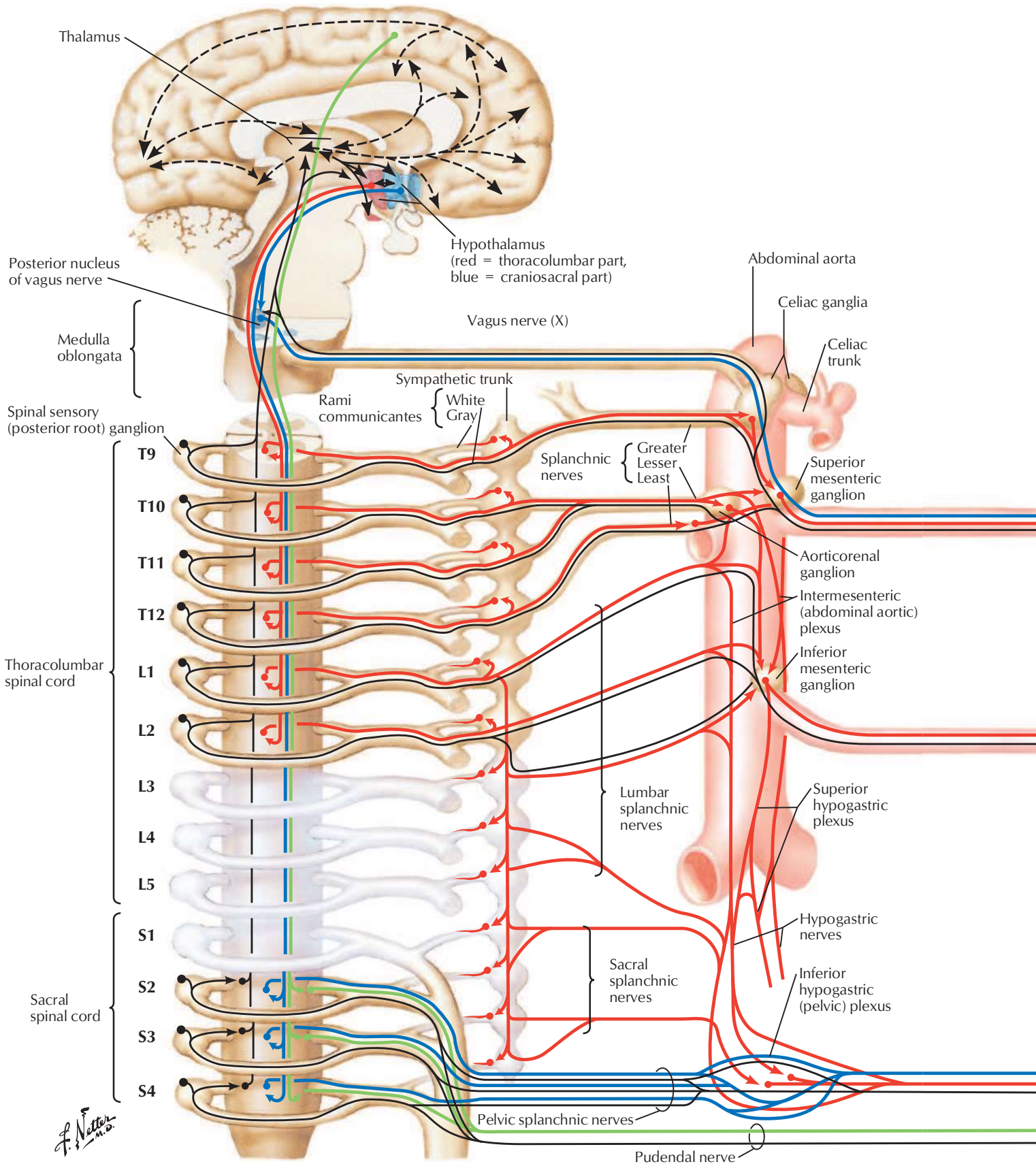




F. Netter M.D.

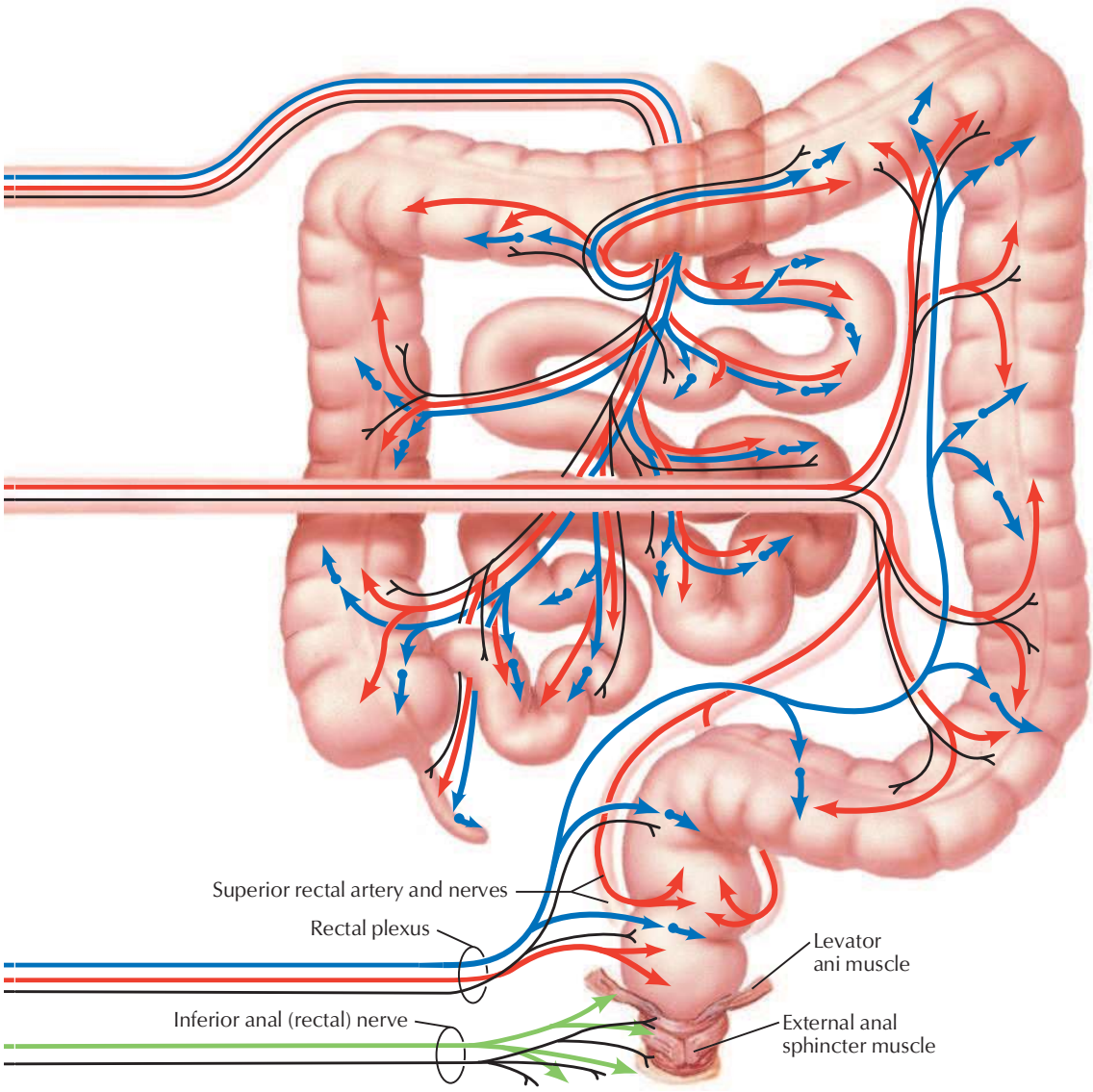
Autonomic Innervation of Intestines: Schema

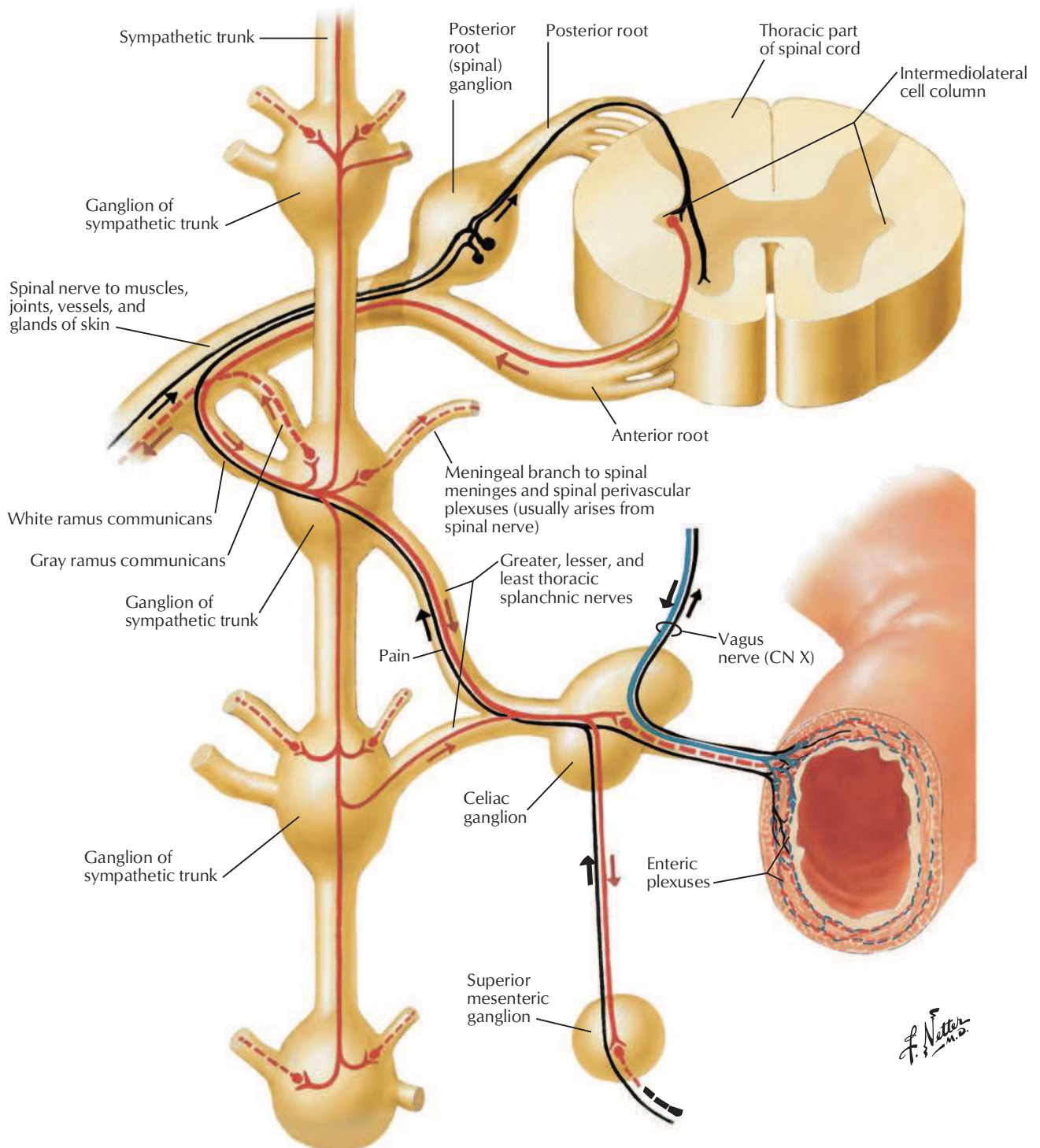
See also [Plates 172, 173](#)



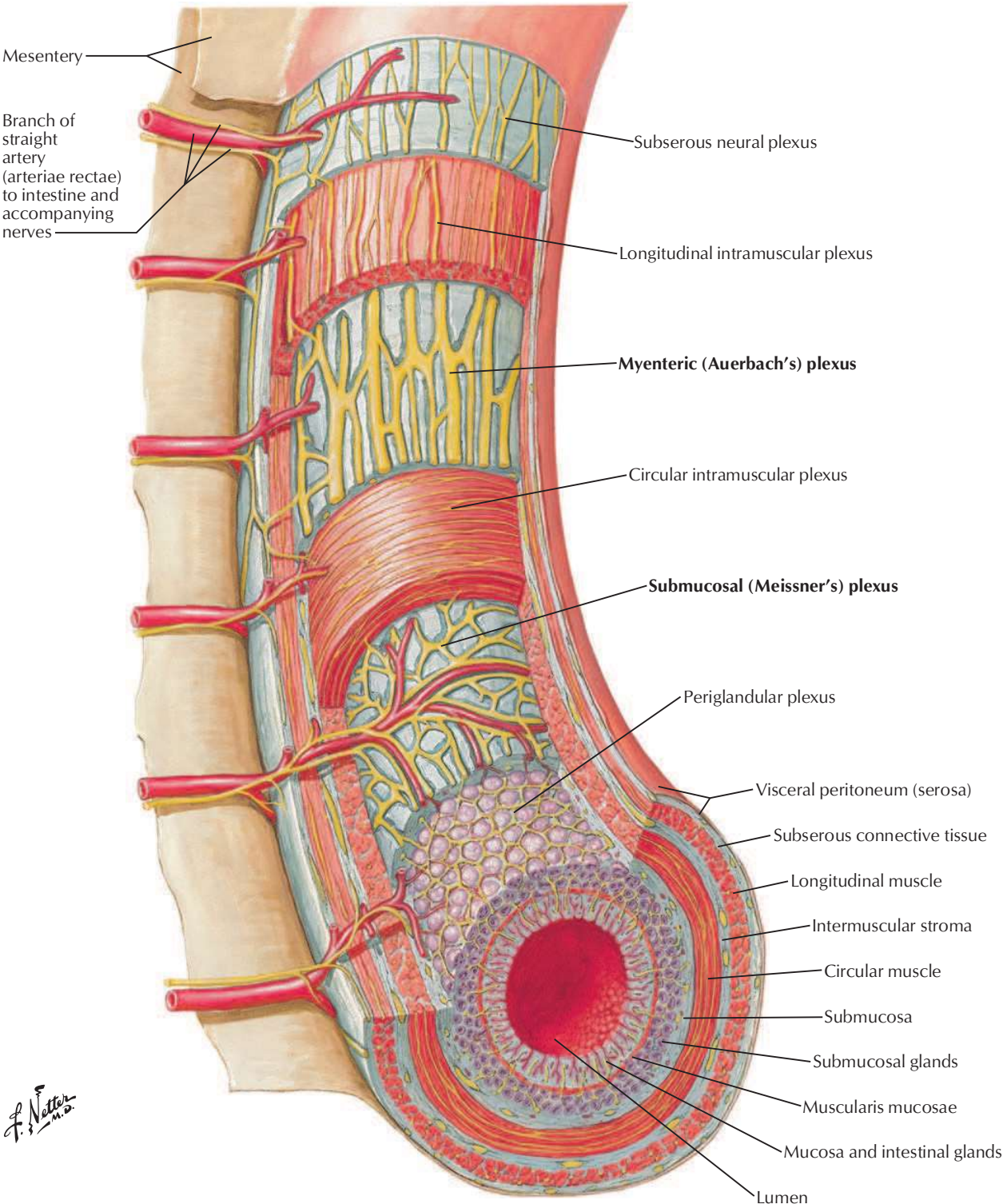
See also Plates 172, 173

- Sympathetic efferents ———
- Parasympathetic efferents ———
- Somatic efferents ———
- Afferents and CNS connections ———
- Indefinite paths - - - - -





Sympathetic fibers	{	Preganglionic	—	Parasympathetic fibers	{	Preganglionic	—	Afferent fibers	—
		Postganglionic	- - -			Postganglionic	- - -		

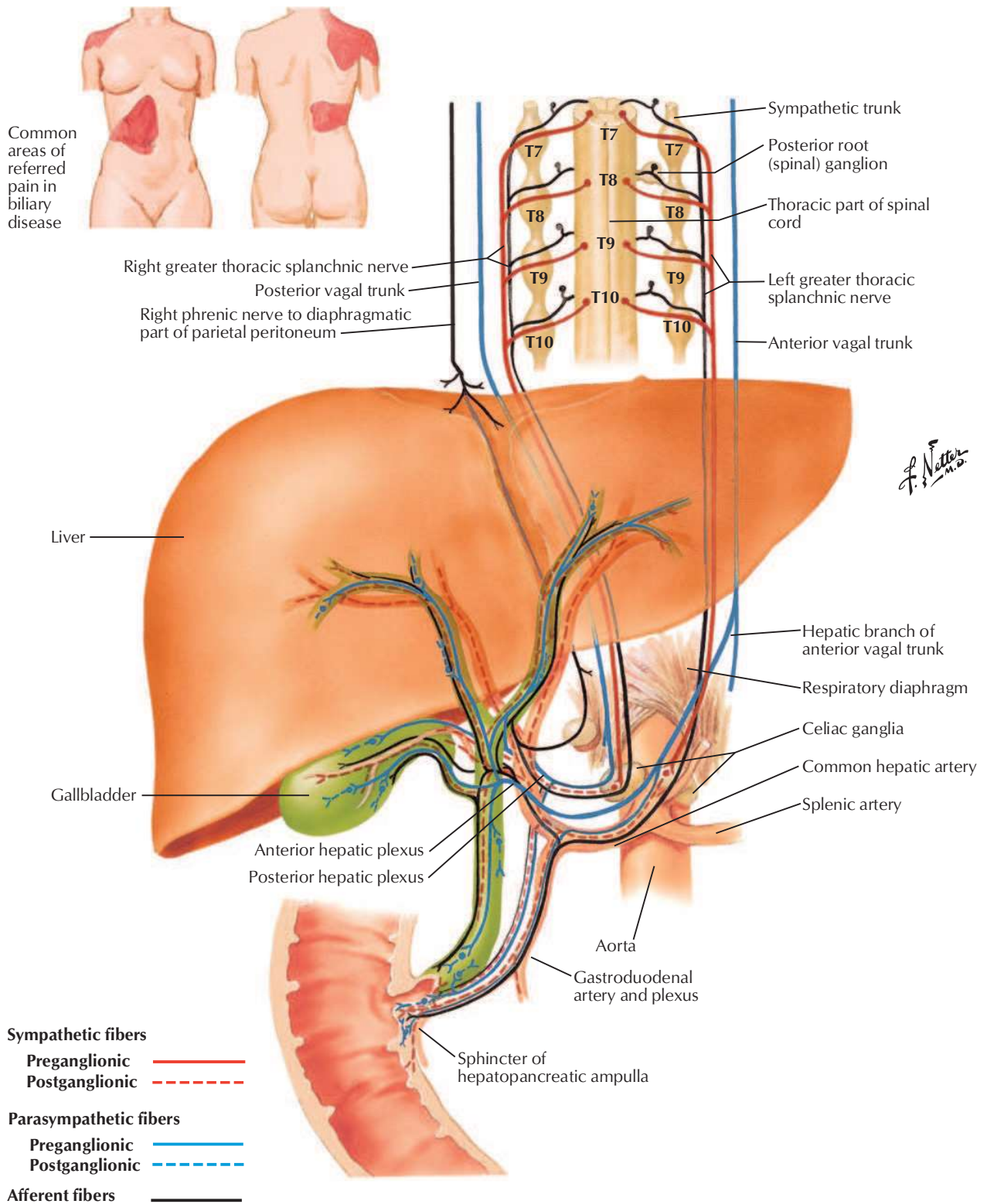


Note: Intestinal wall is shown much thicker than in actuality.

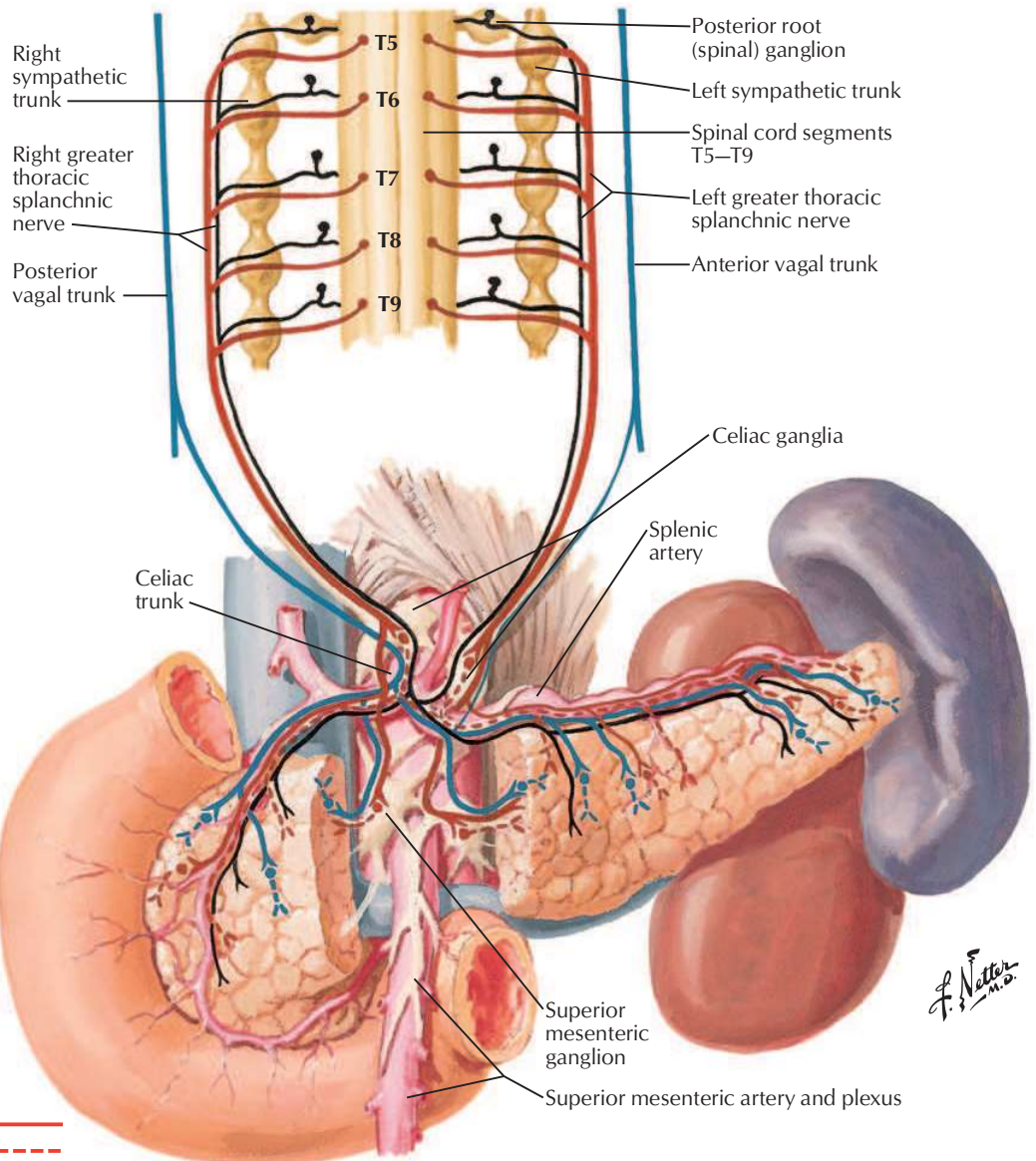
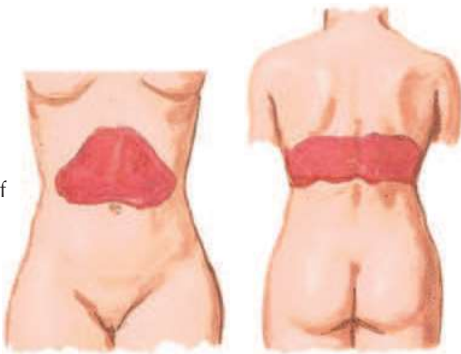
F. Netter M.D.

Autonomic Innervation of Liver: Schema

See also [Plates 172, 173](#)



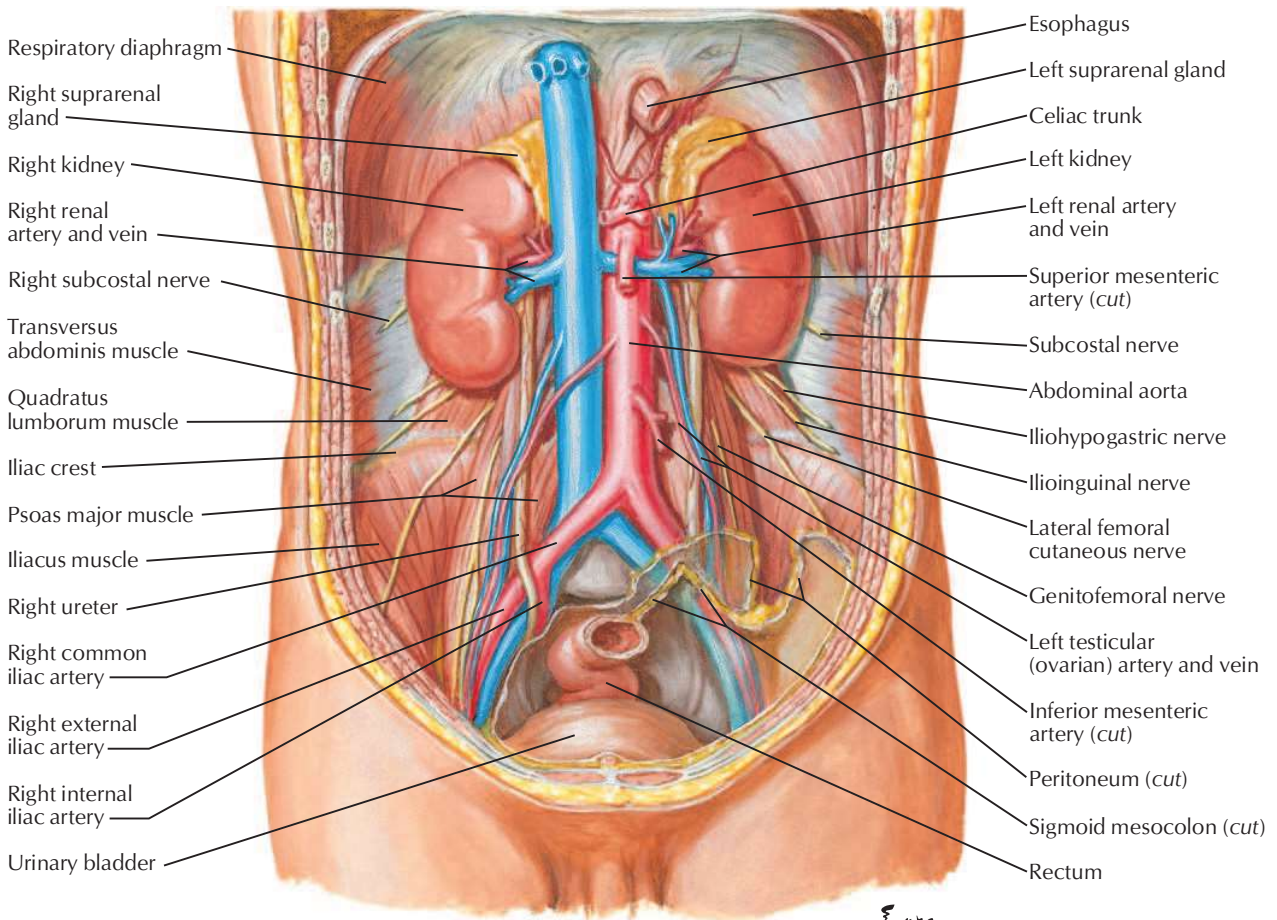
Common areas of pancreatic pain



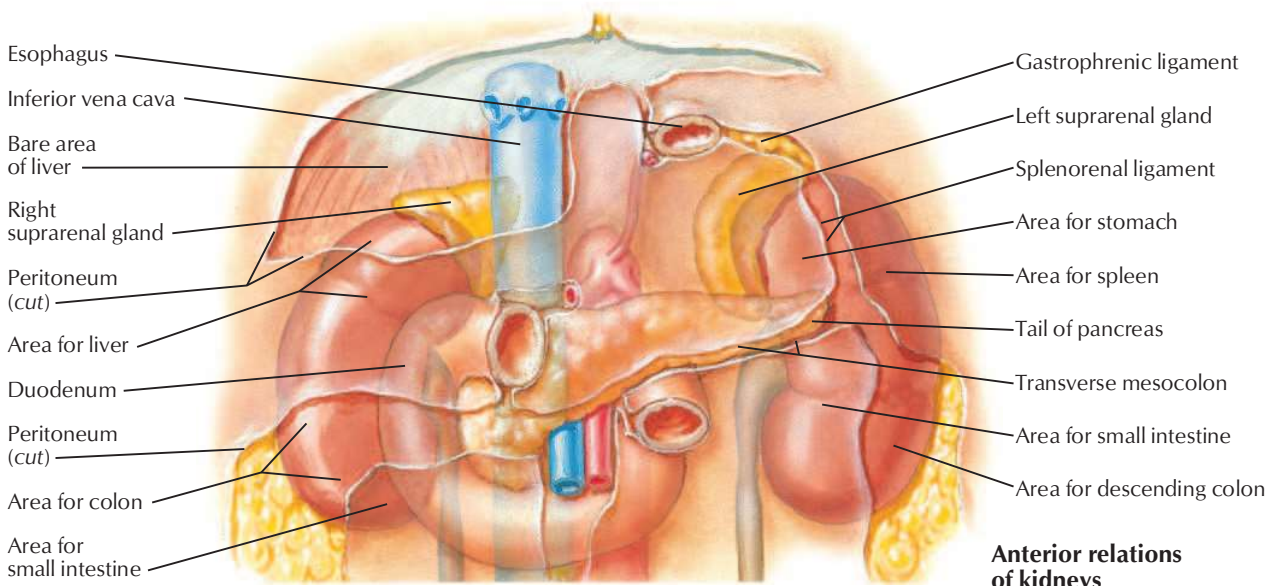
- Sympathetic fibers
 - Preganglionic ——— (solid red line)
 - Postganglionic - - - - (dashed red line)
- Parasympathetic fibers
 - Preganglionic ——— (solid blue line)
 - Postganglionic - - - - (dashed blue line)
- Afferent fibers ——— (solid black line)

F. Netter M.D.

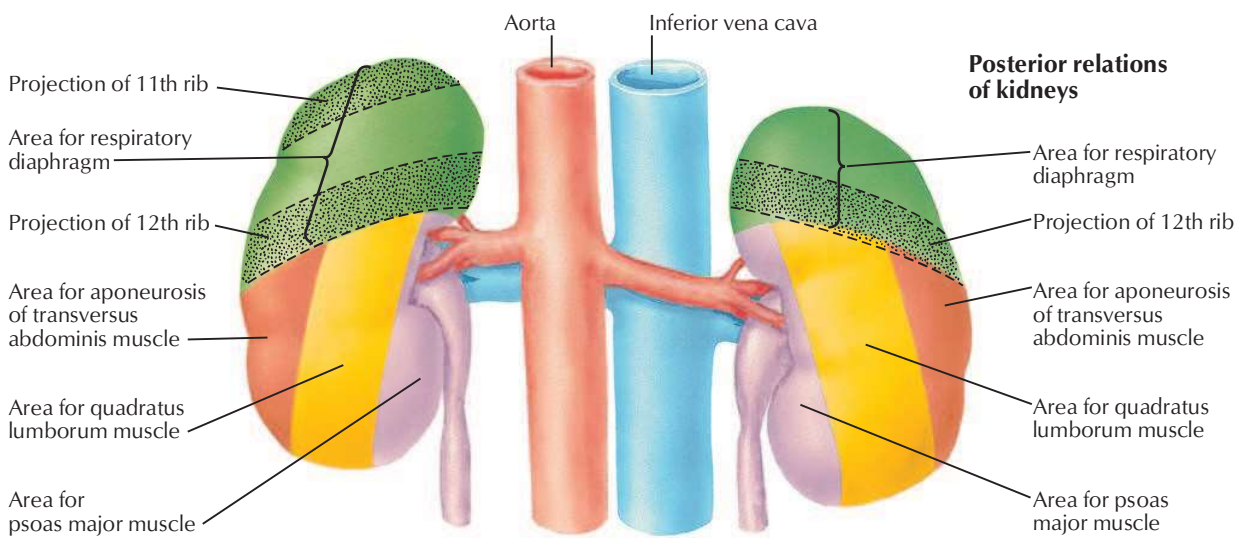
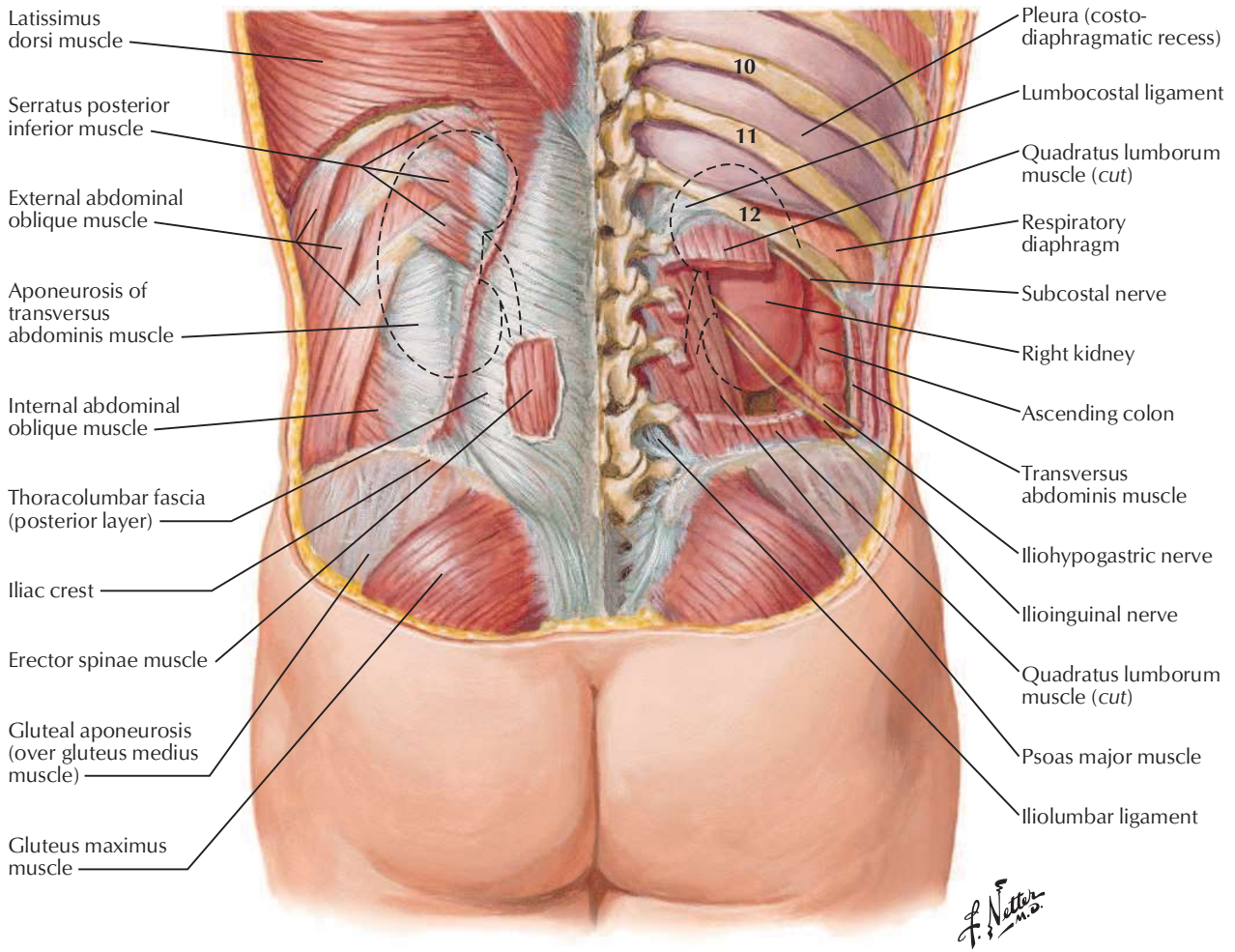
Kidneys in Situ: Anterior Views



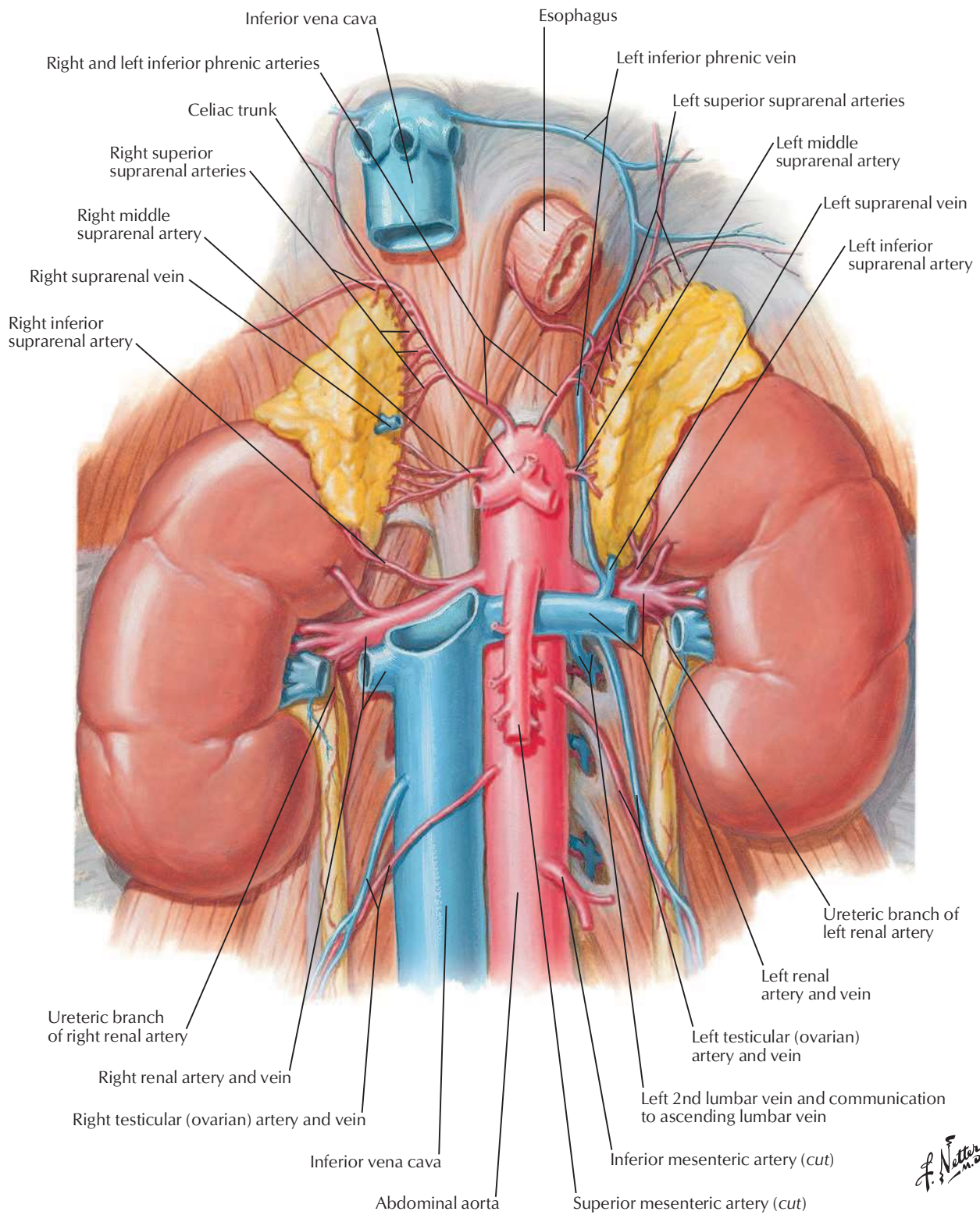
F. Netter M.D.

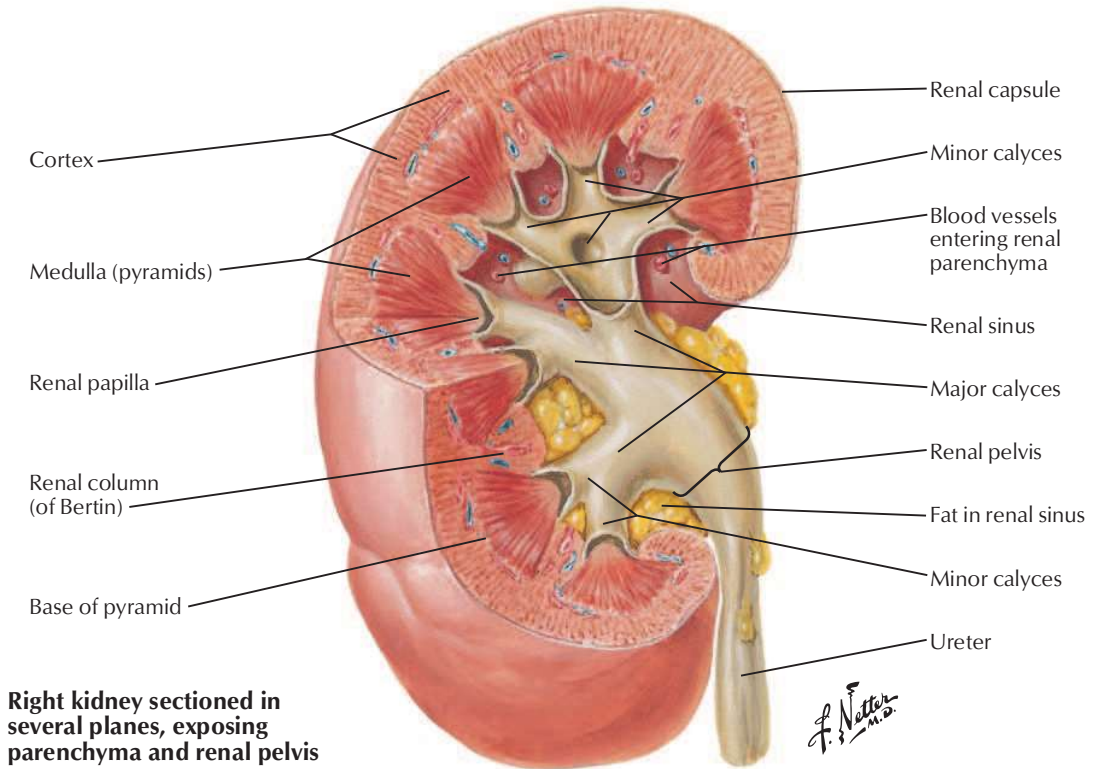
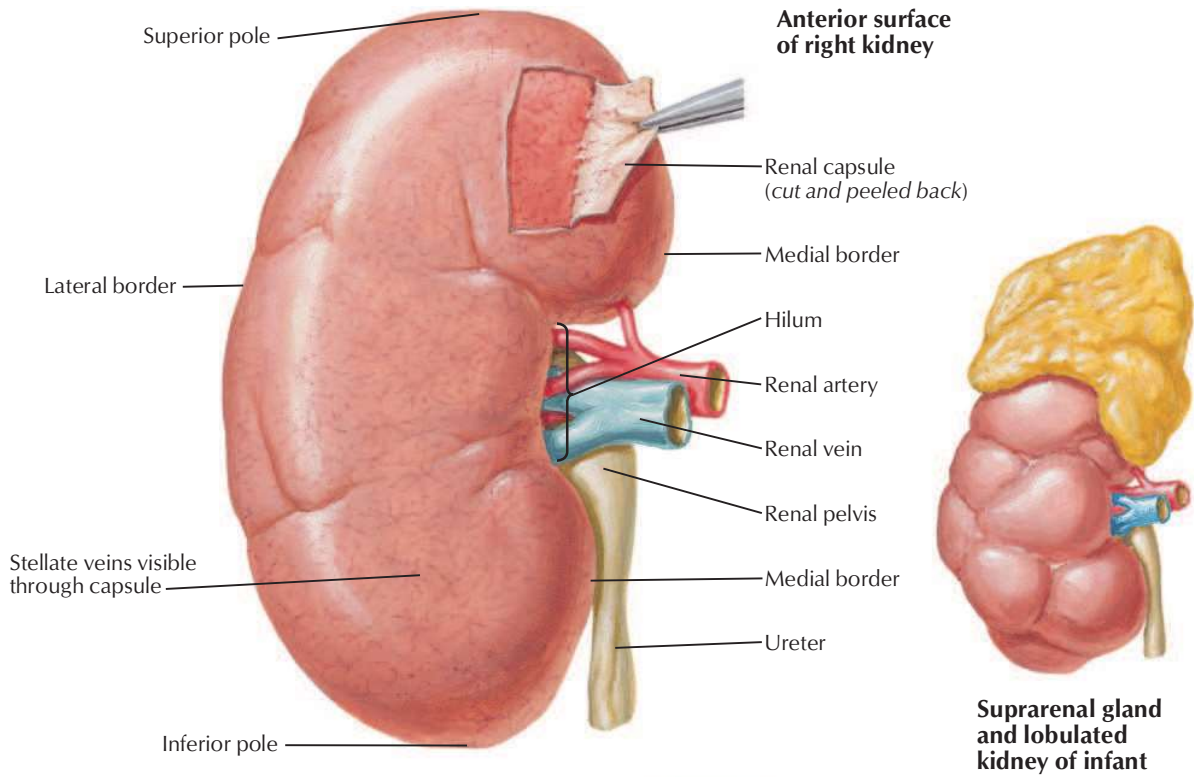


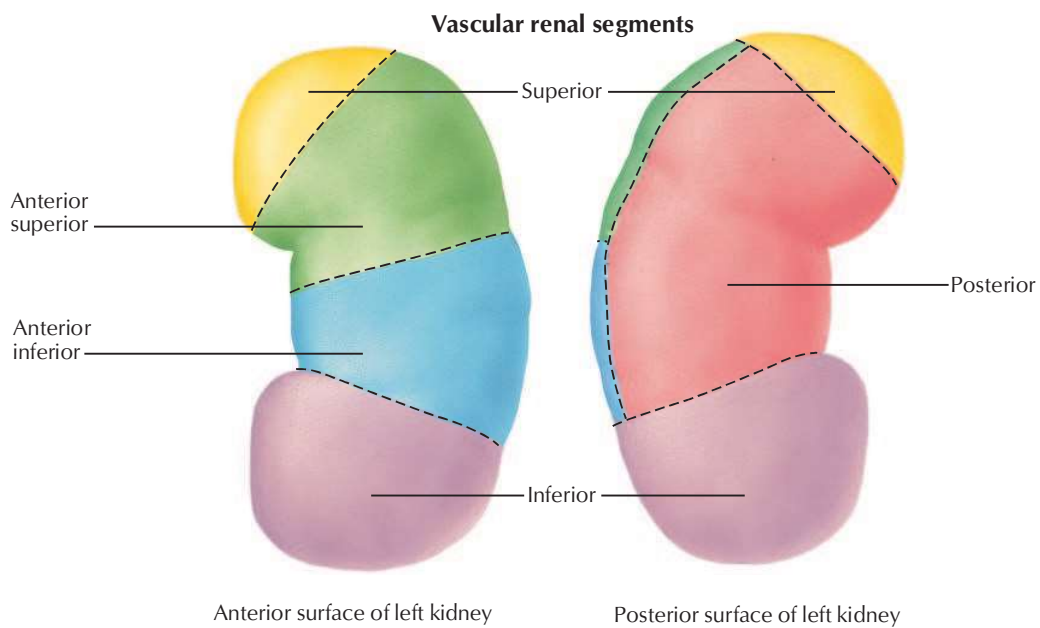
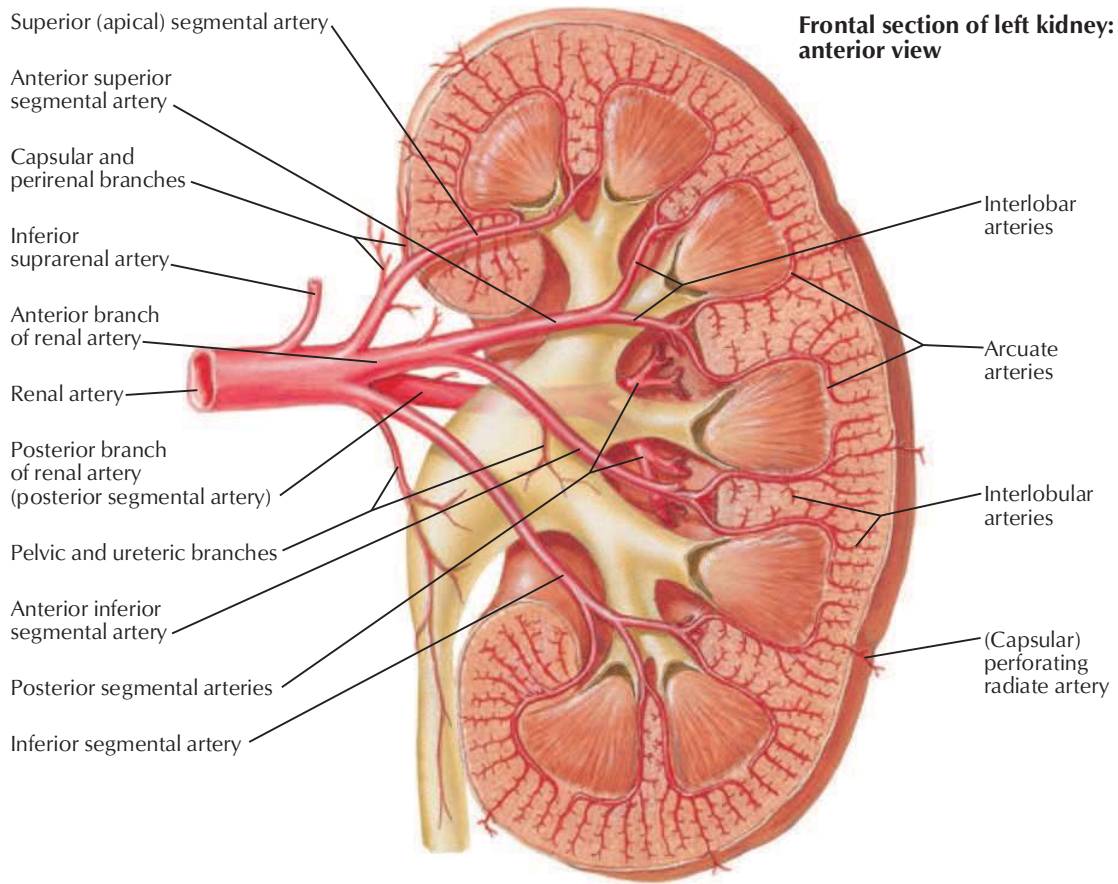
Anterior relations of kidneys



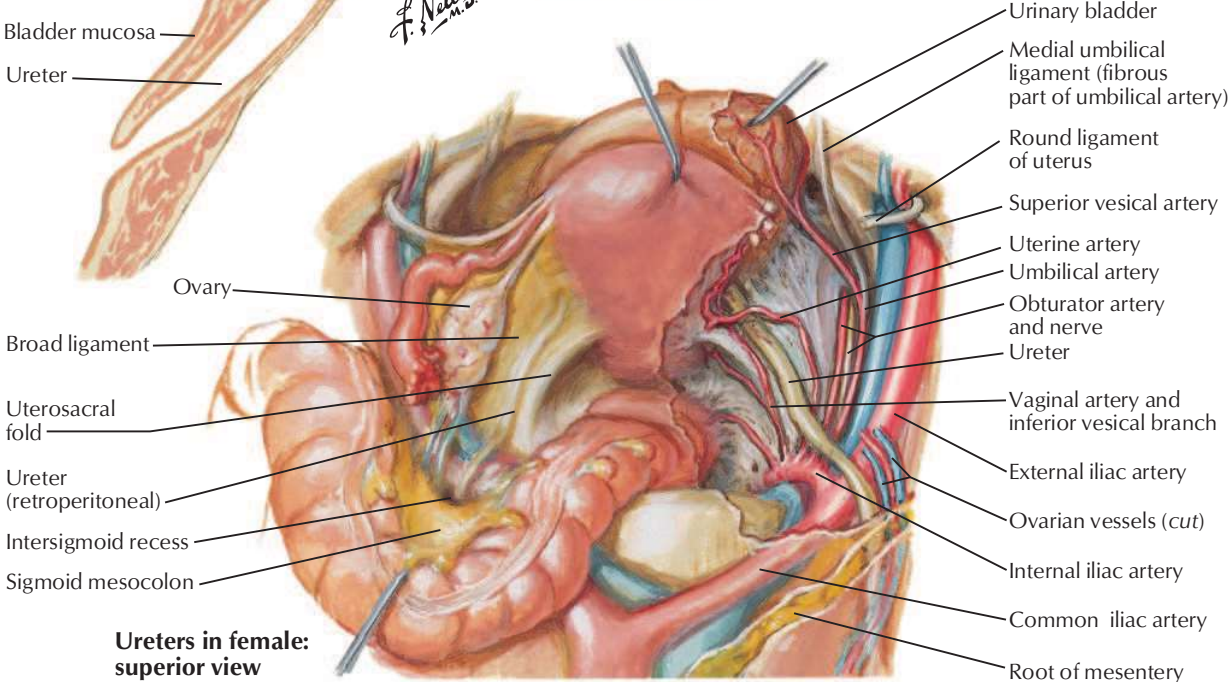
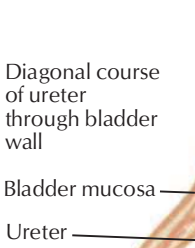
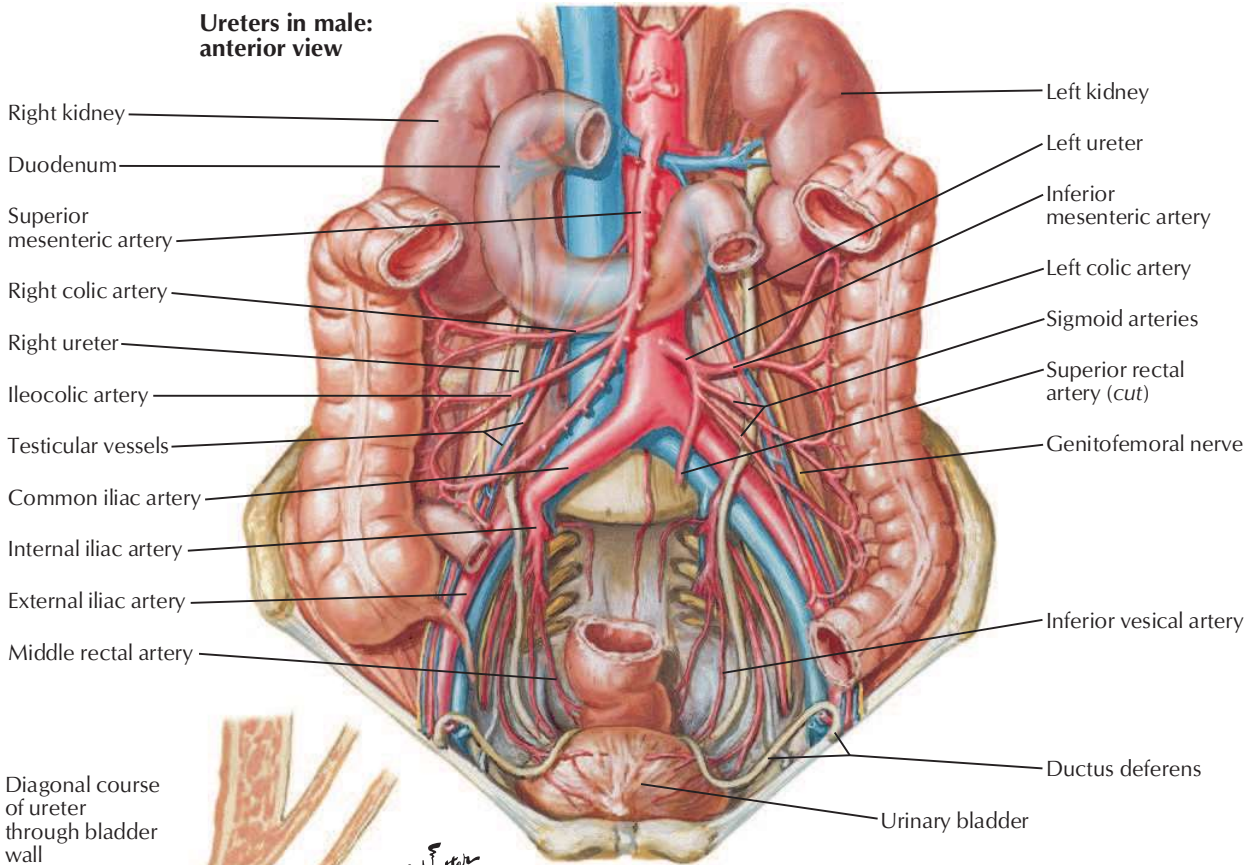
Renal Artery and Vein in Situ



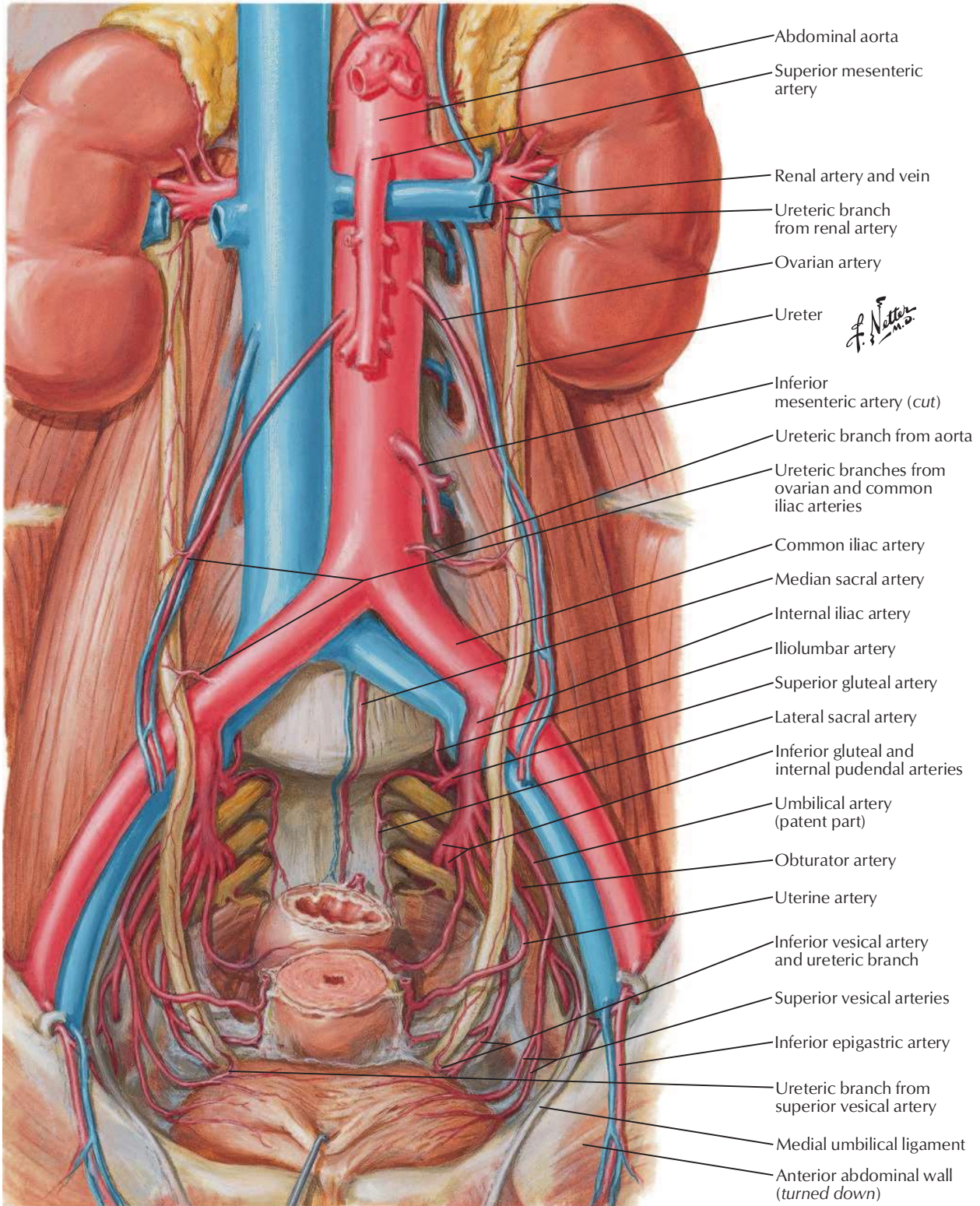


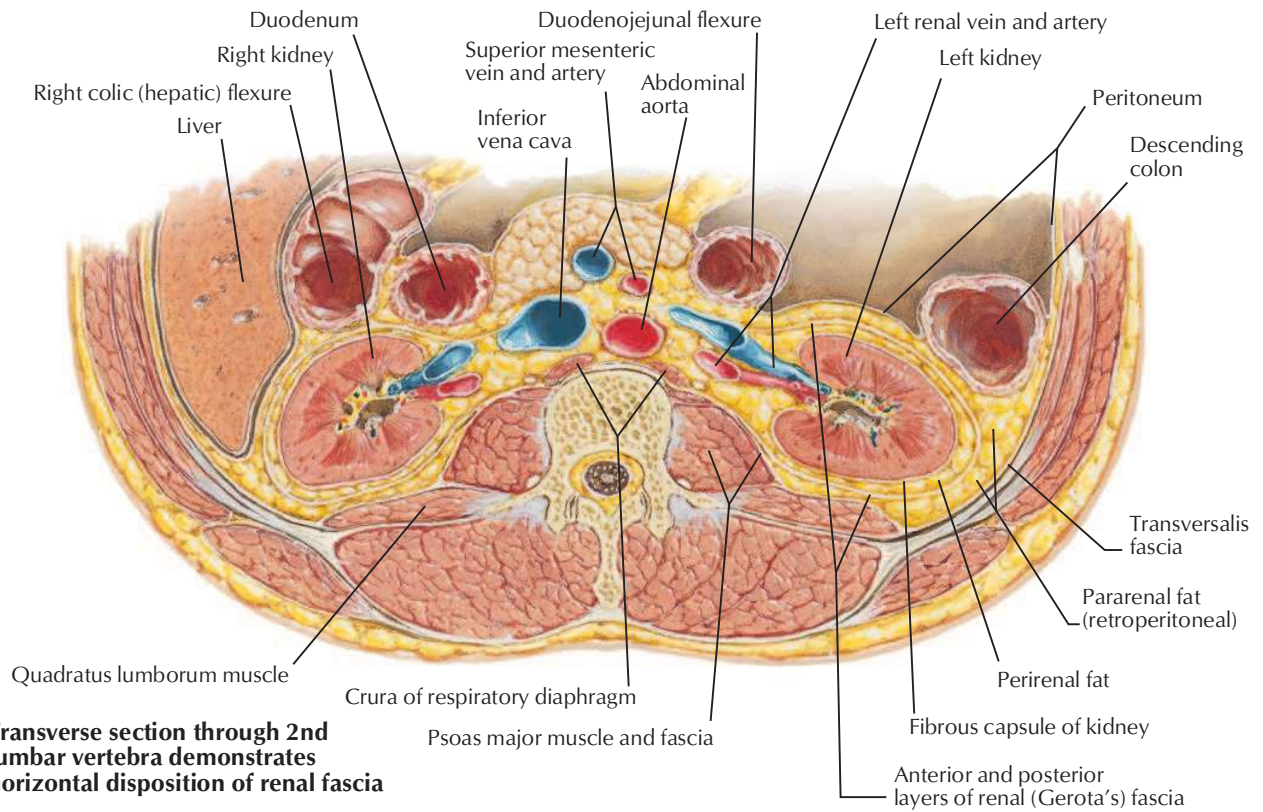


See also Plates 344, 346, 348

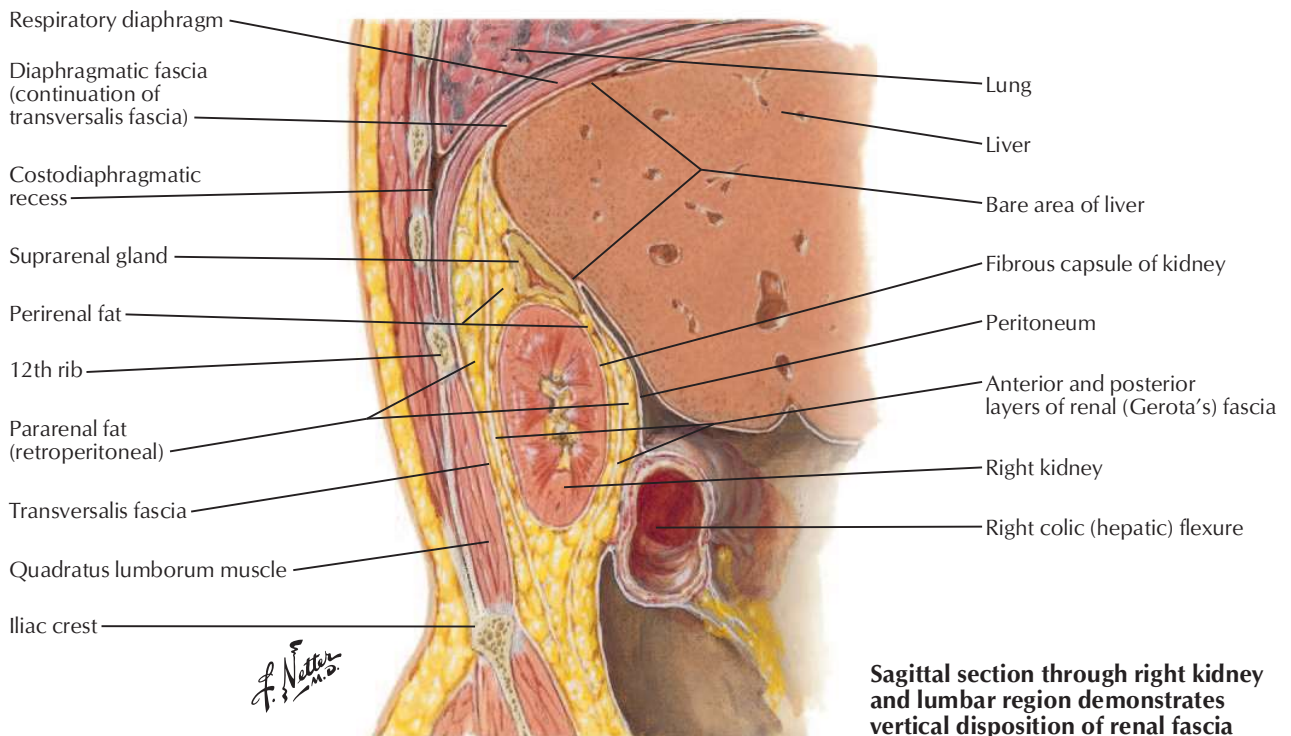


Ureters in female: superior view





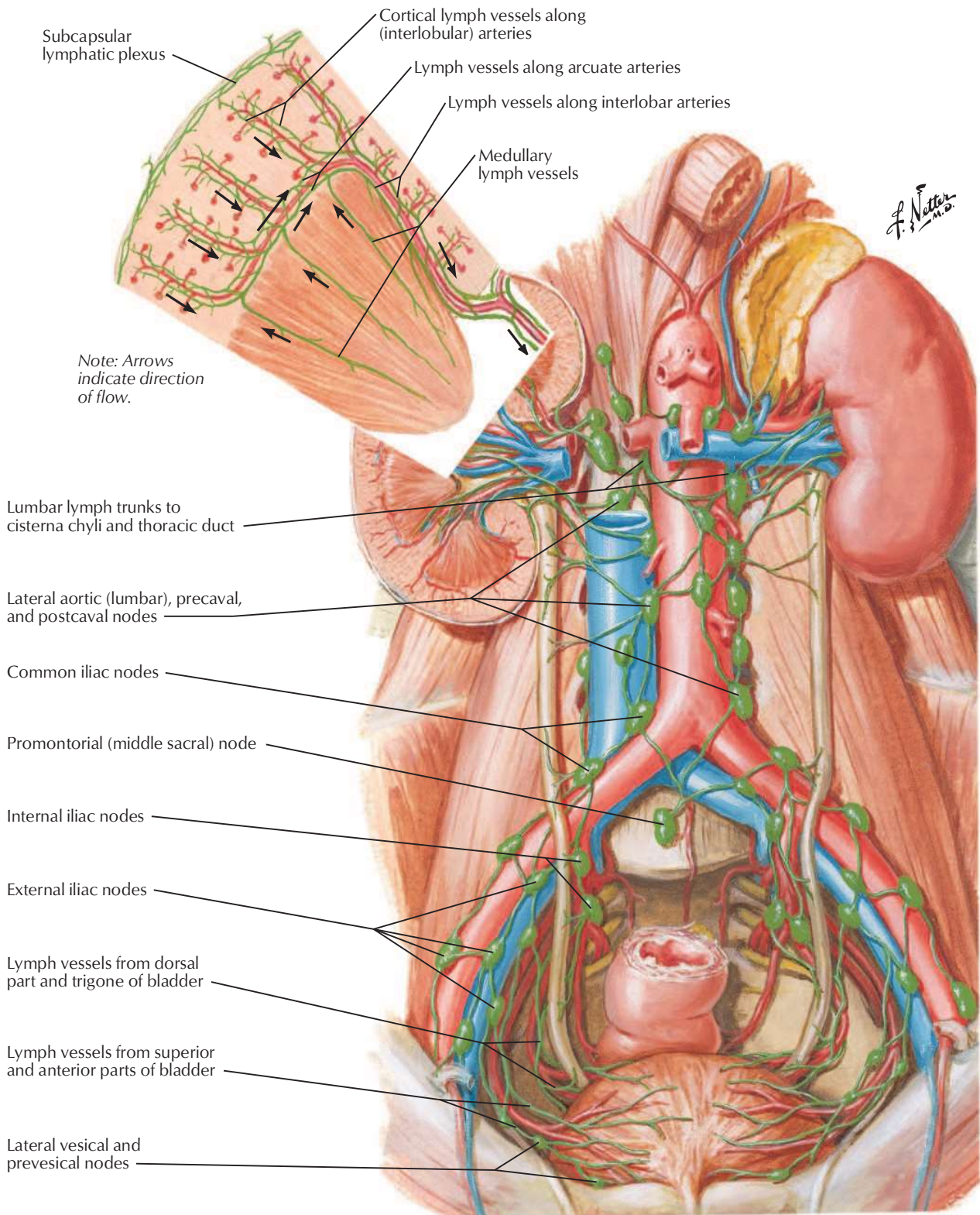
Transverse section through 2nd lumbar vertebra demonstrates horizontal disposition of renal fascia

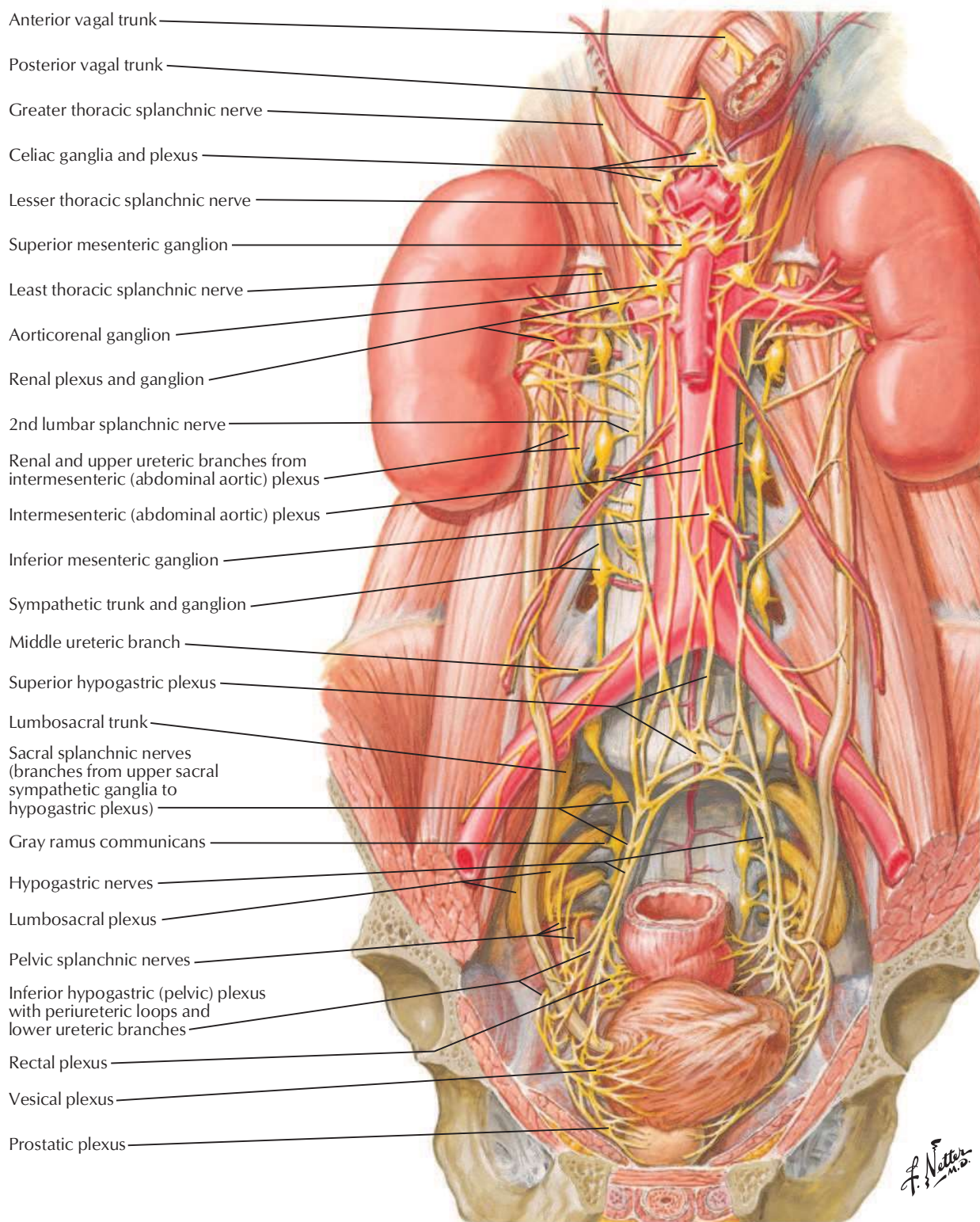


Sagittal section through right kidney and lumbar region demonstrates vertical disposition of renal fascia

Lymph Vessels and Nodes of Kidneys and Urinary Bladder

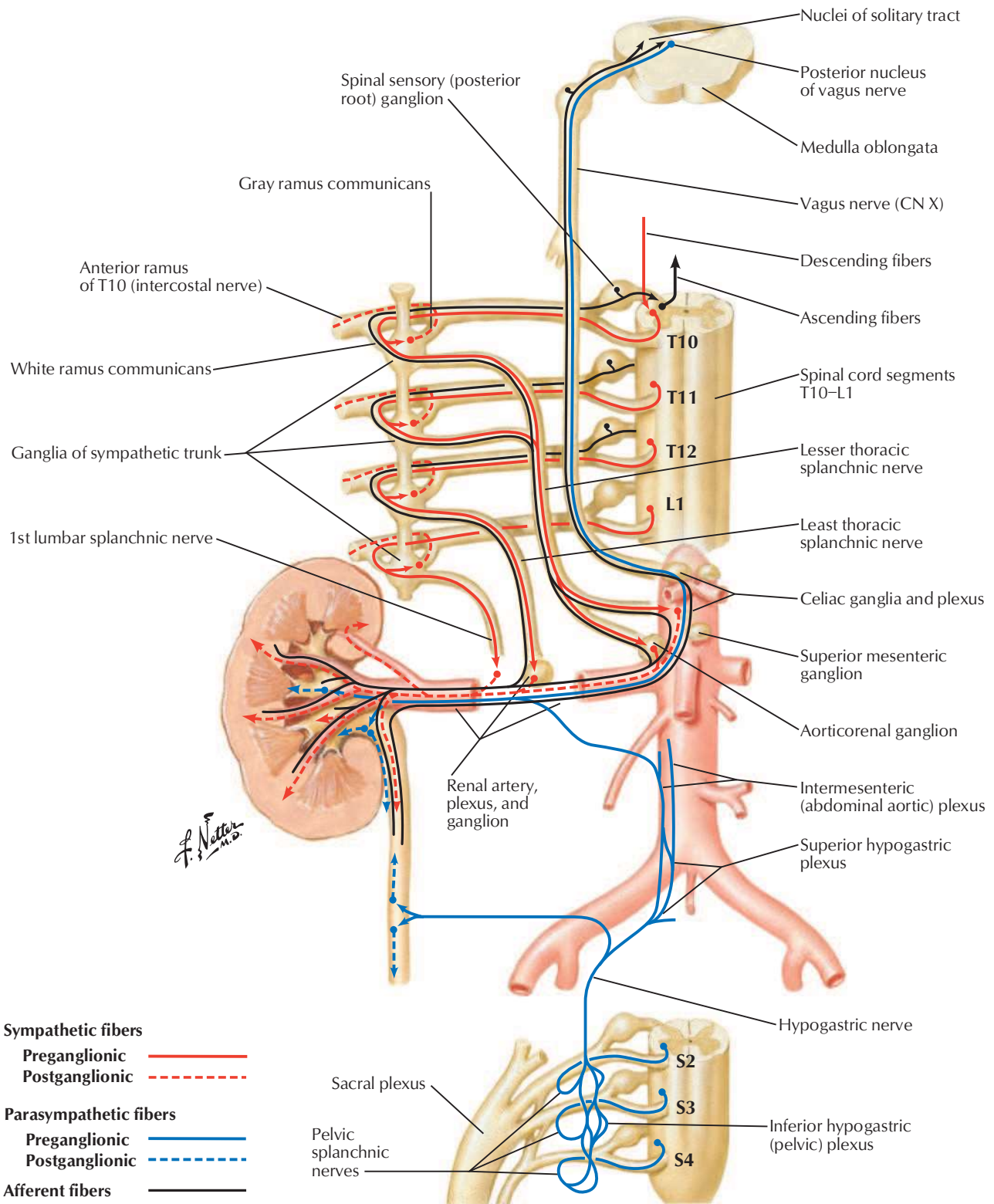
See also [Plates 388, 390](#)

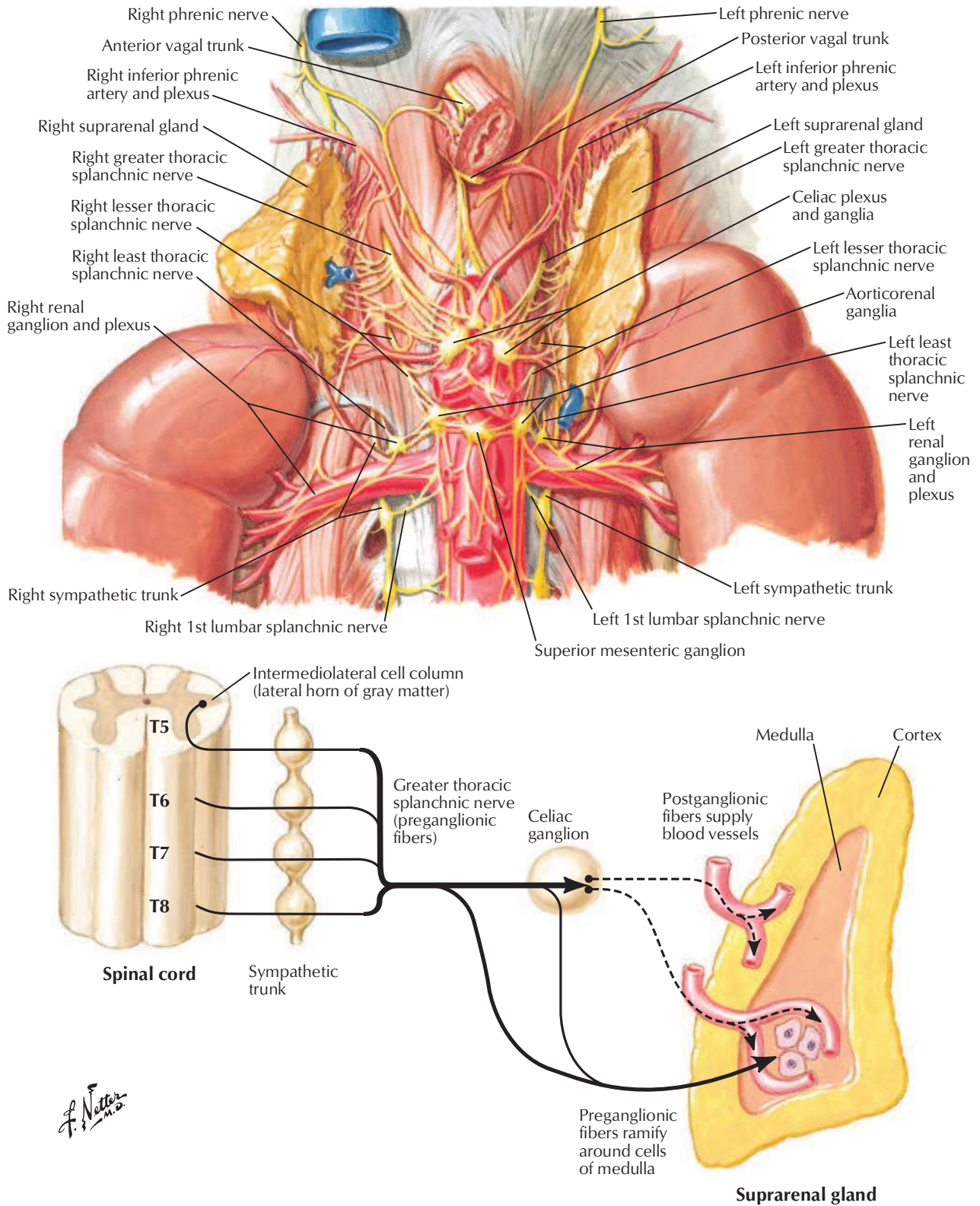




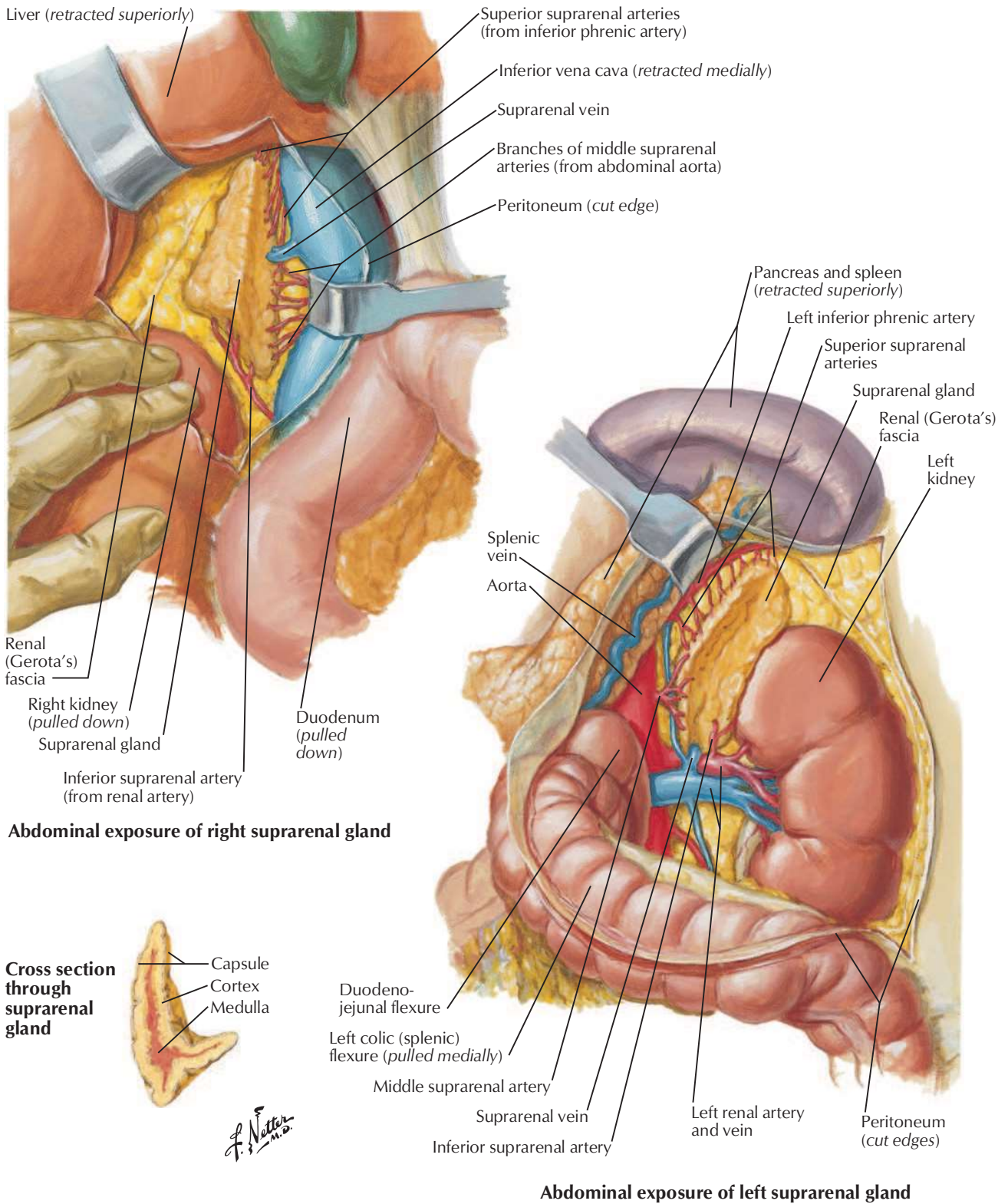
Autonomic Innervation of Kidneys and Upper Ureters: Schema

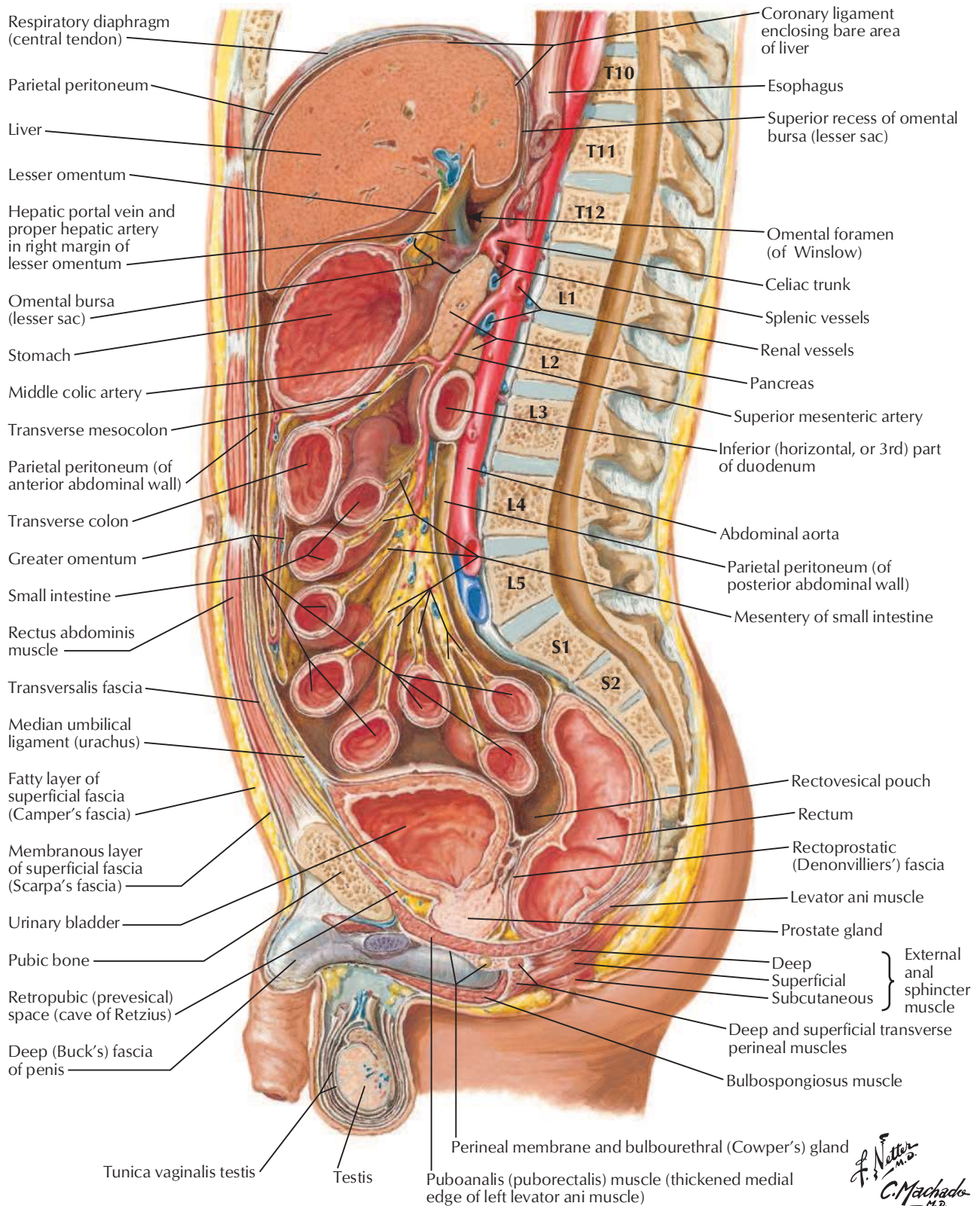
See also [Plates 172, 173, 399](#)



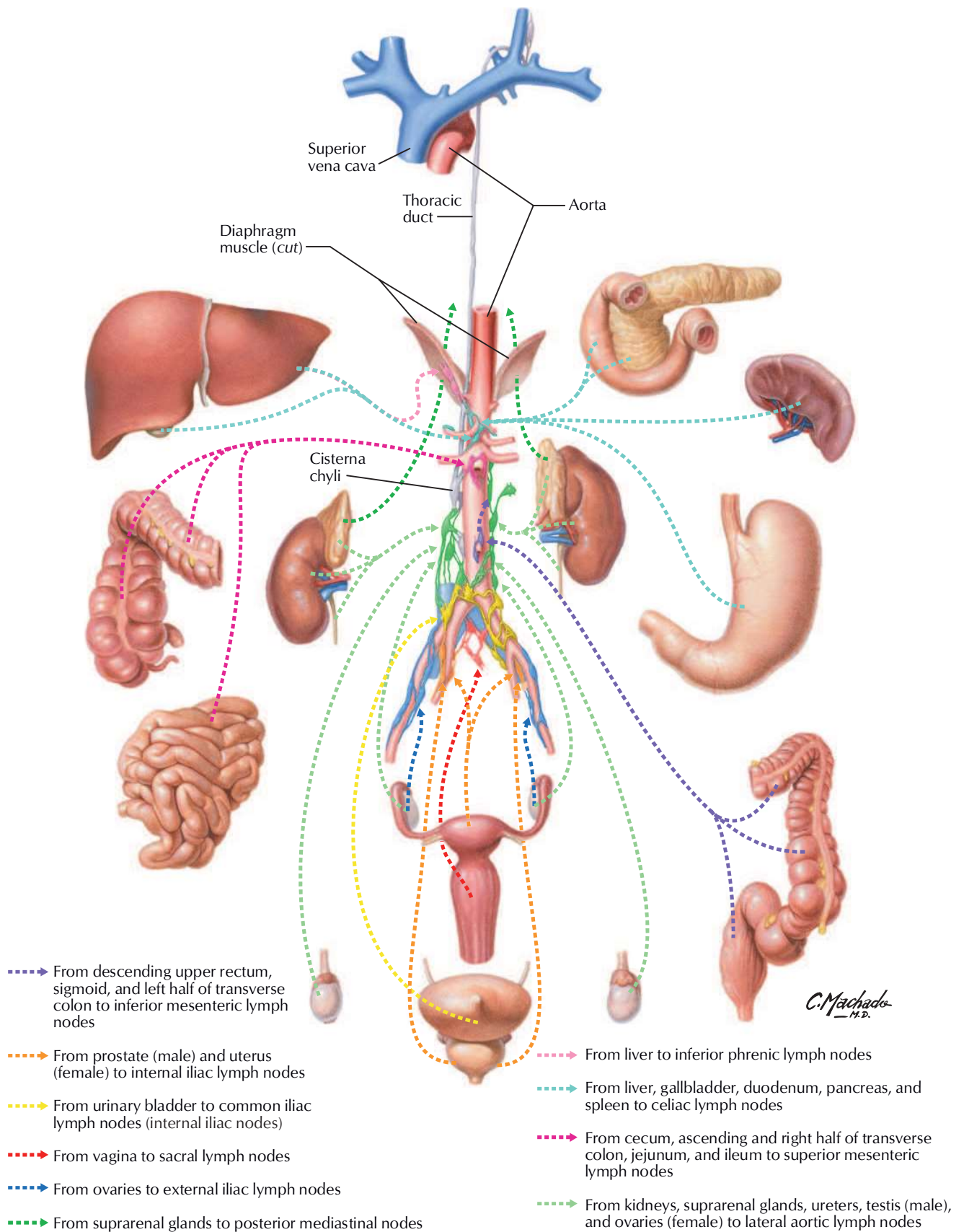


Arteries and Veins of Suprarenal Glands in Situ





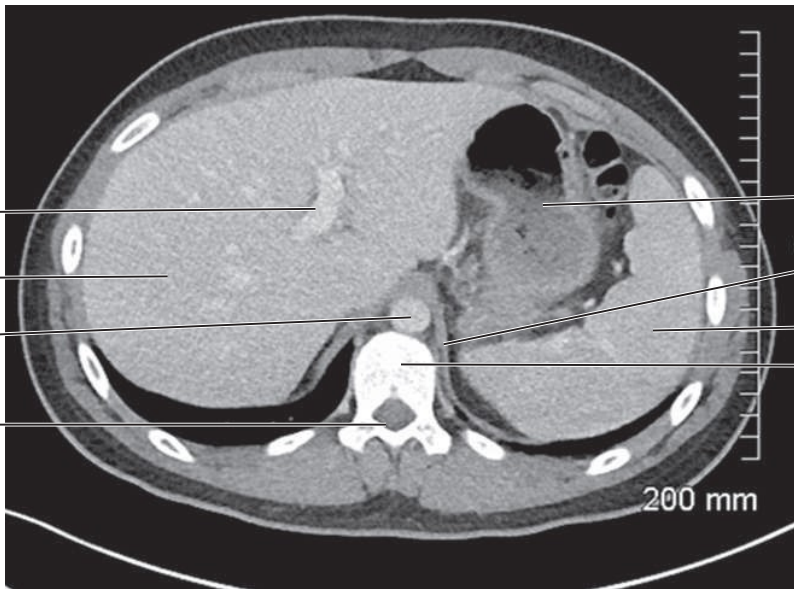
Abdominal and Pelvic Lymphatics: Schema



C. Machado M.D.

Axial CT image of abdomen with intravenous contrast enhancement

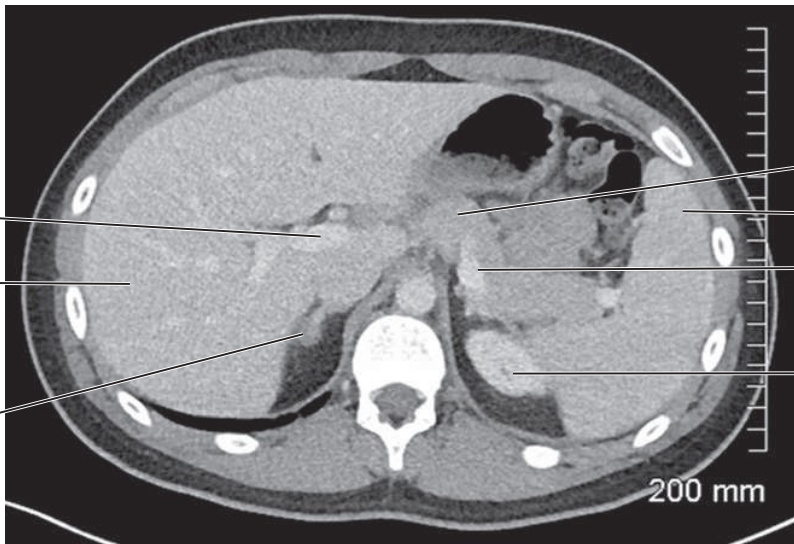
- Hepatic portal vein
- Liver
- Aorta
- Spinal canal



- Stomach
- Left diaphragm crus
- Spleen
- Vertebral body

Axial CT image of upper abdomen with intravenous contrast enhancement

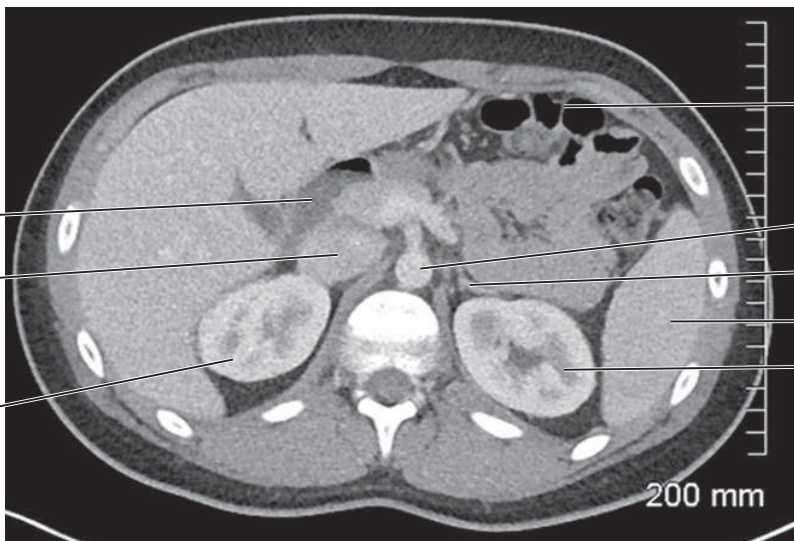
- Hepatic portal vein
- Liver
- Right adrenal gland



- Body of pancreas
- Spleen
- Splenic vein
- Left suprarenal gland

Axial CT image of midabdomen with intravenous contrast enhancement

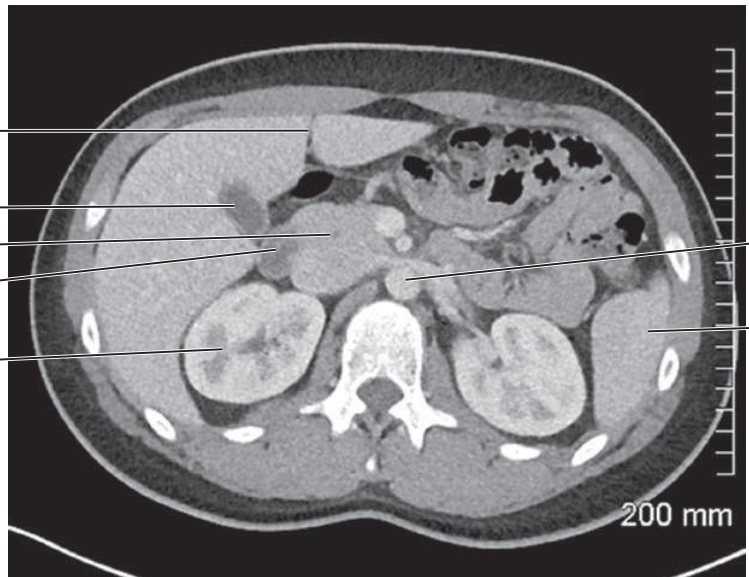
- Duodenum
- Inferior vena cava
- Right kidney



- Colon, splenic flexure
- Aorta
- Left adrenal
- Spleen
- Left kidney

Axial CT image of midabdomen with intravenous contrast enhancement

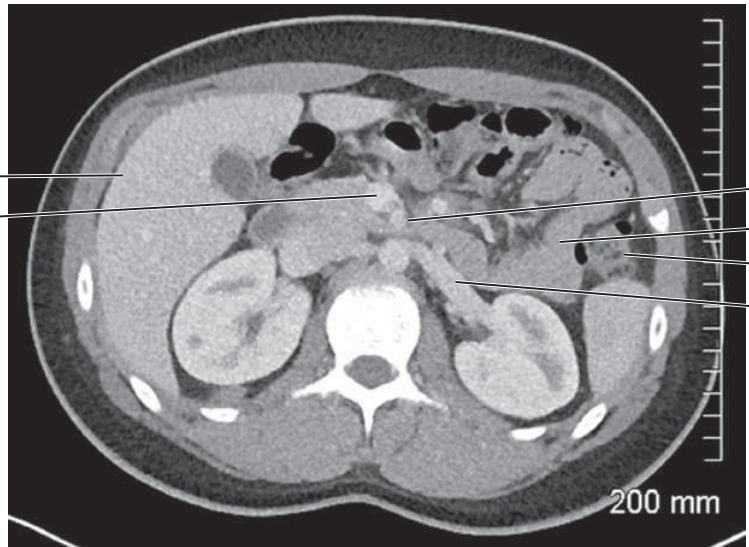
- Falciform ligament
- Gallbladder
- Head of pancreas
- Duodenum
- Right kidney



- Aorta
- Spleen

Axial CT image of abdomen with intravenous contrast enhancement

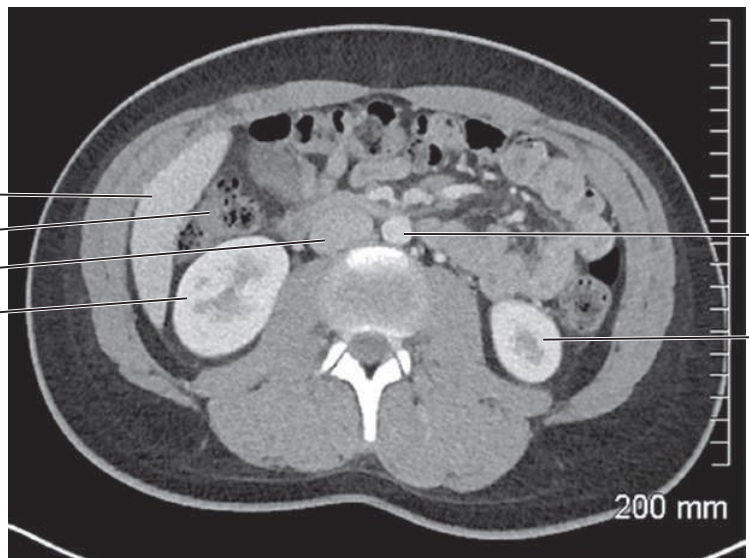
- Liver
- Superior mesenteric vein



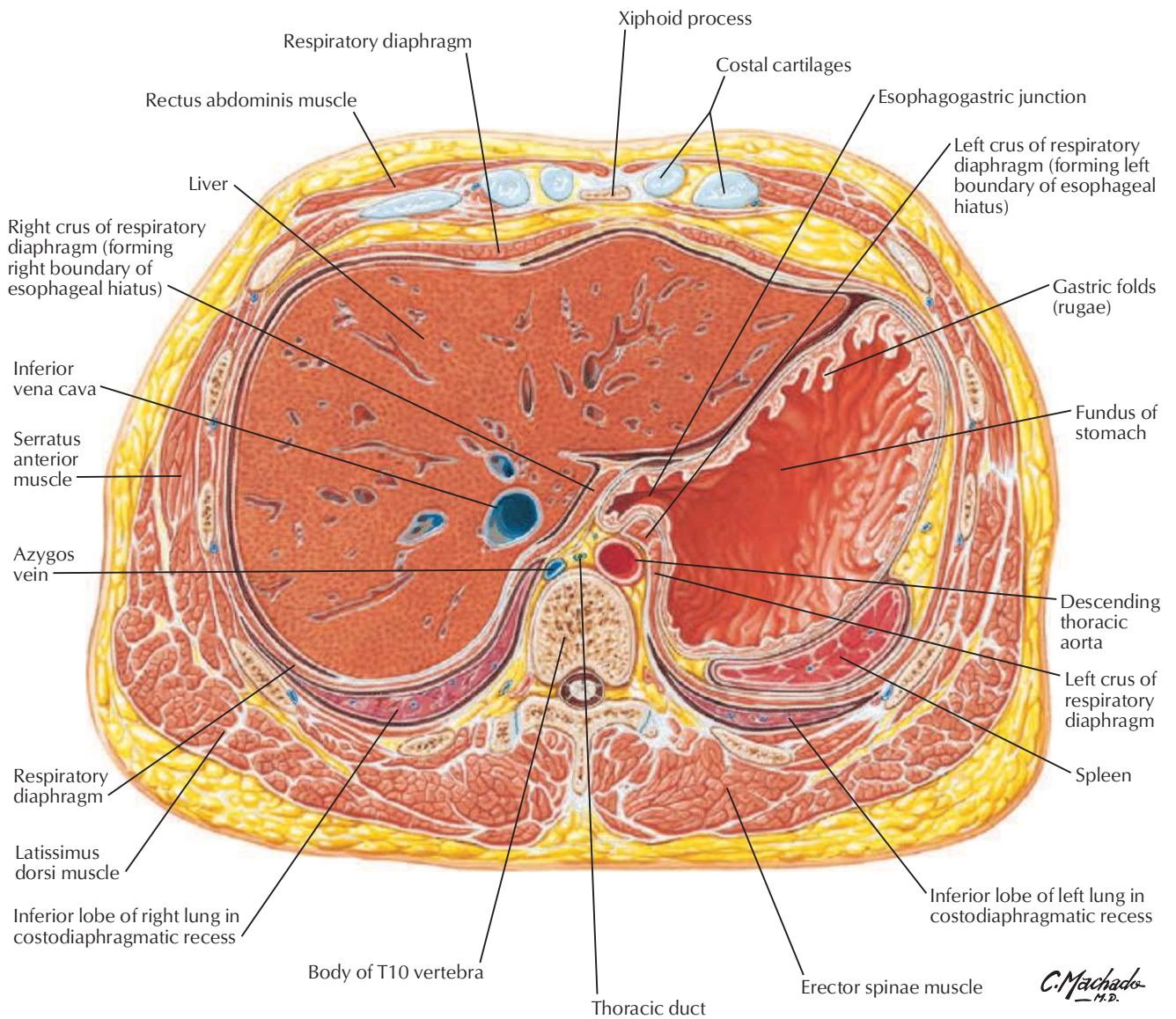
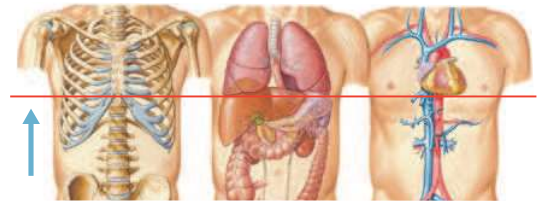- Superior mesenteric artery
- Jejunum
- Descending colon
- Left renal vein

Axial CT image of abdomen with intravenous contrast enhancement

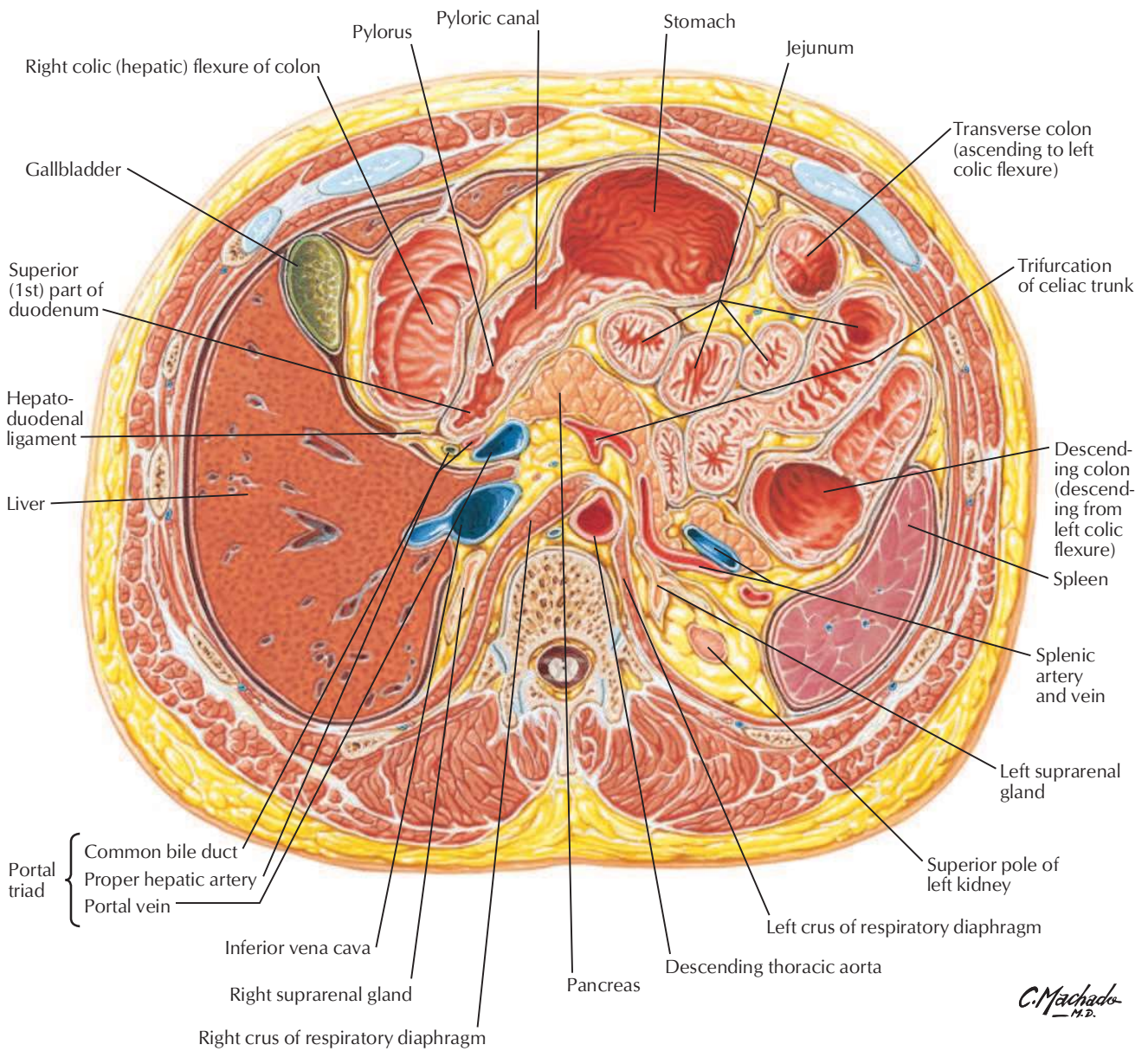
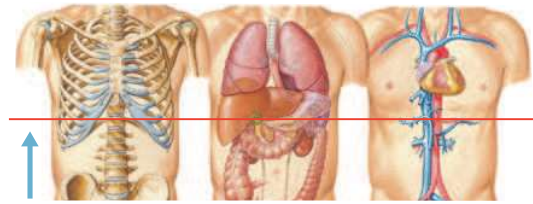
- Right lobe of liver
- Hepatic flexure, colon
- Inferior vena cava
- Right kidney



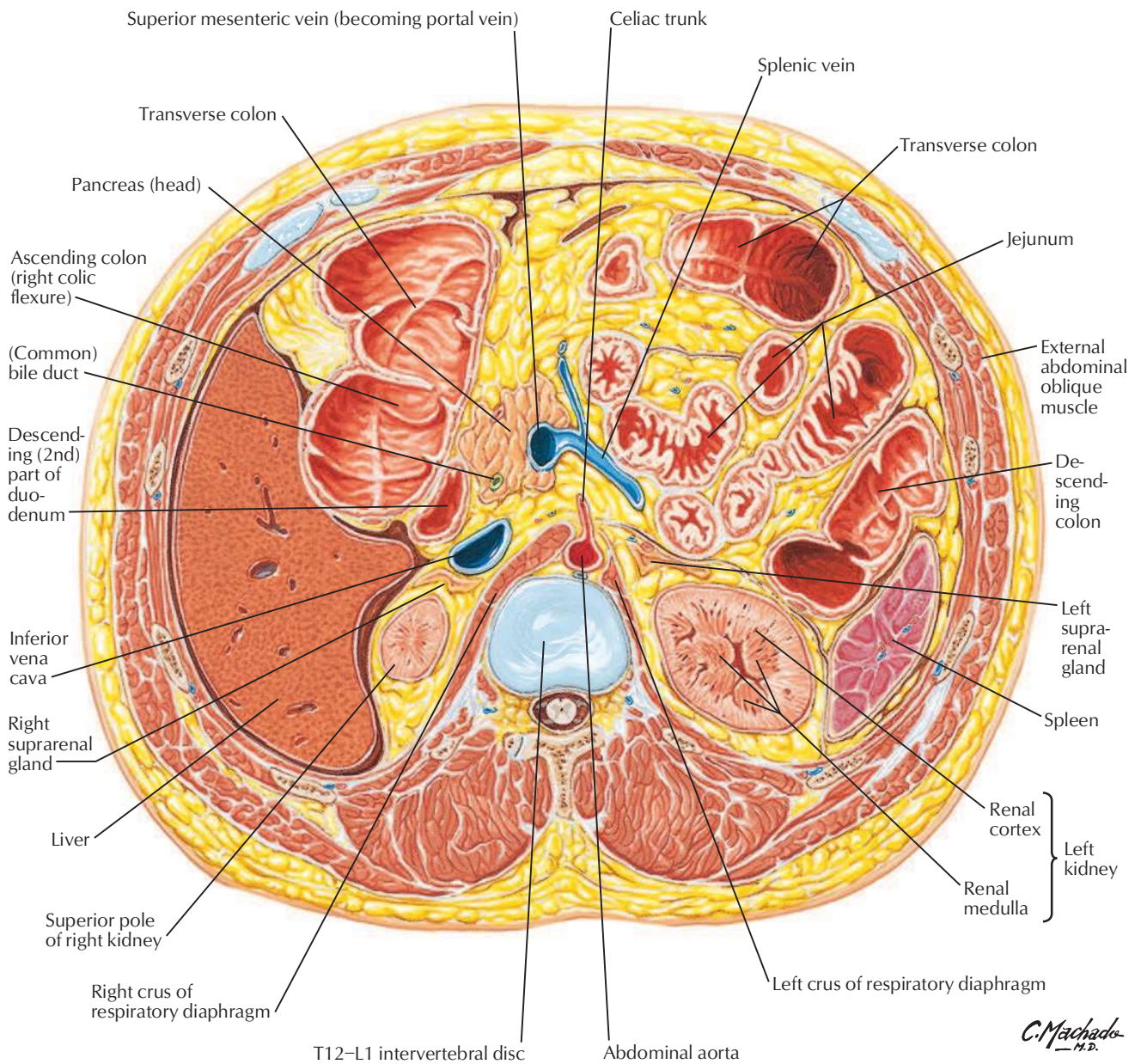
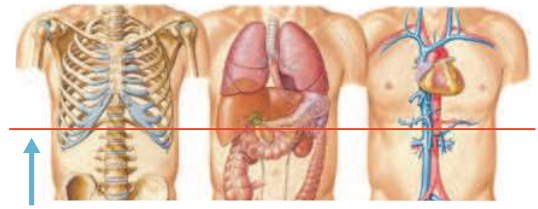
- Aorta
- Left kidney

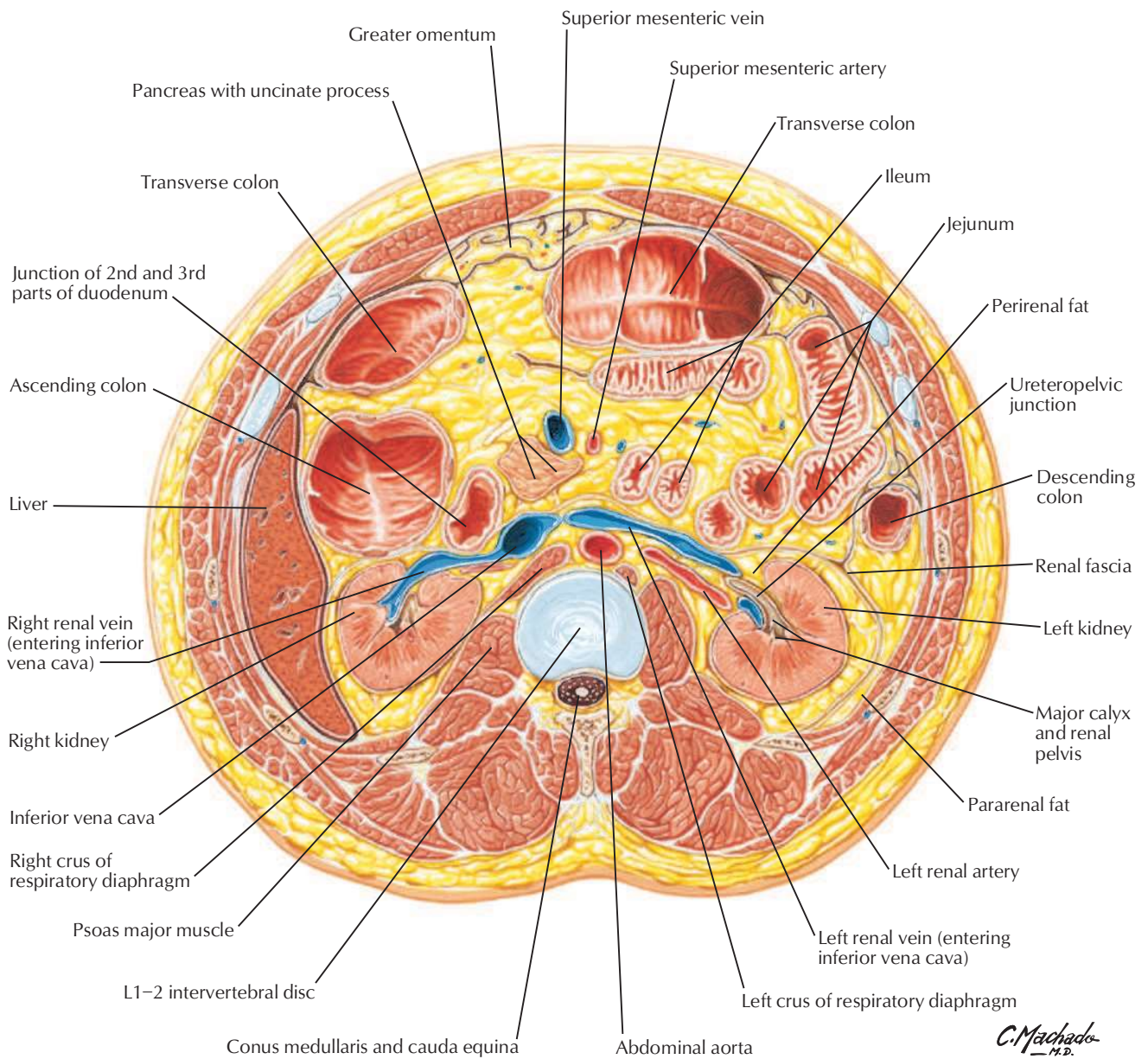
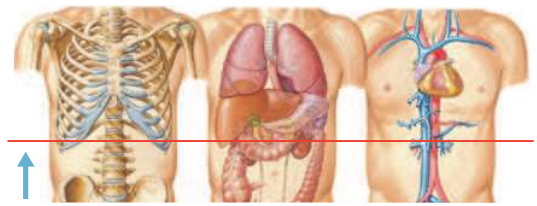


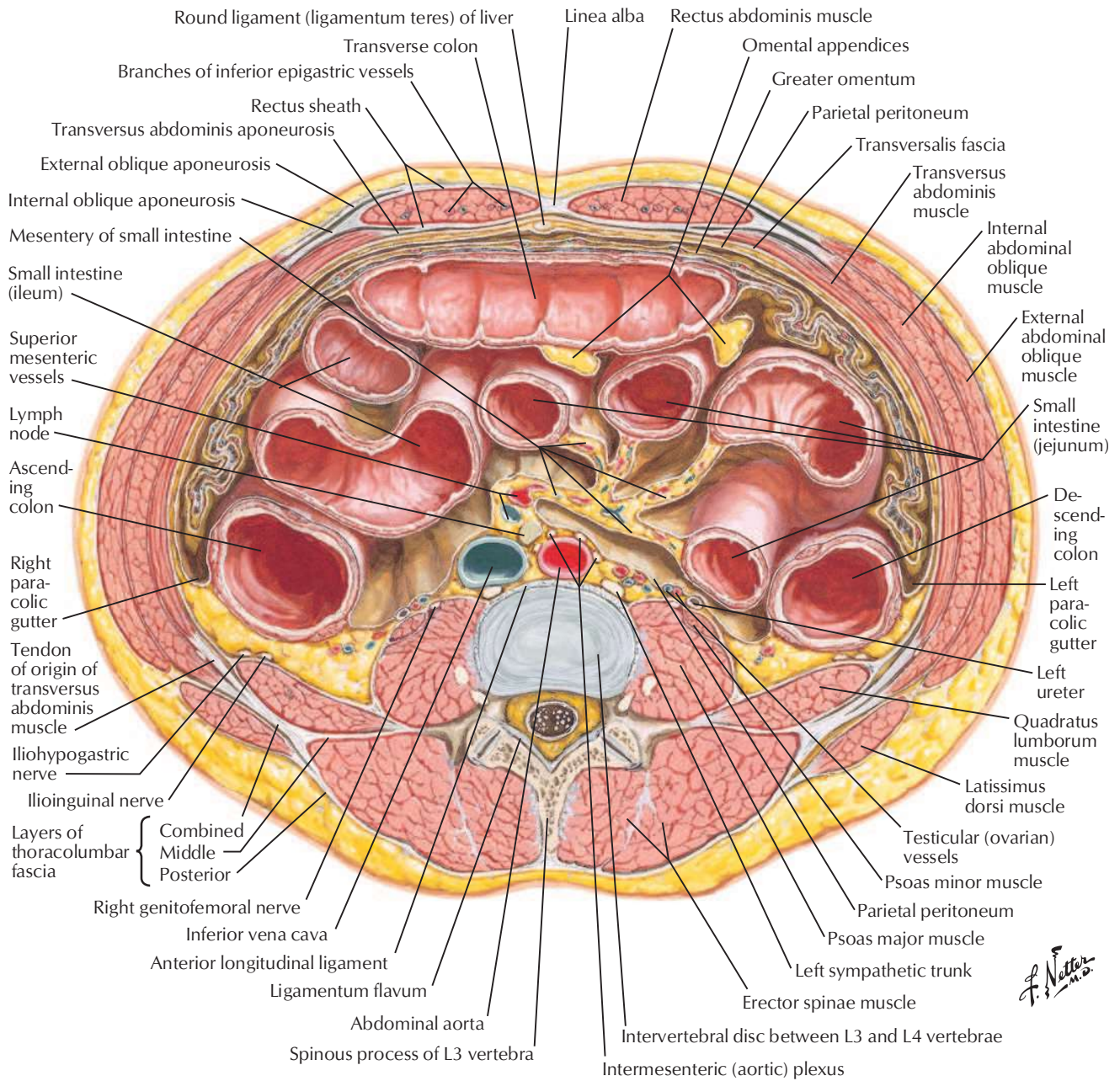
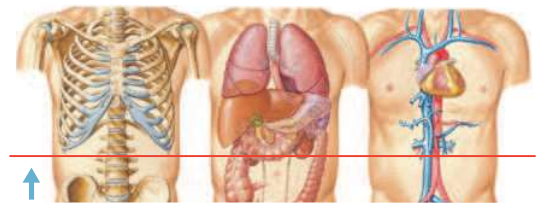
Cross Section at T12, Inferior to Xiphoid



C. Machado M.D.







F. Netter M.D.


















ANATOMICAL STRUCTURES	CLINICAL IMPORTANCE	PLATE NUMBERS
INTEGUMENTARY SYSTEM		
 Umbilicus	Landmark for locating transumbilical plane, which is used to divide abdomen into quadrants; marks position of T10 dermatome; used to locate McBurney's point; common site for hernias in abdominal wall	249, 251
SKELETAL SYSTEM		
 Xiphoid process, pubic symphysis	Palpable landmarks used to locate median plane, which is used to divide abdomen into quadrants	249
 Anterior superior iliac spine (ASIS)	Palpable landmark used to locate McBurney's point; tenderness over McBurney's point is indication of appendicitis	250, 282
MUSCULAR SYSTEM		
 Linea alba	Site used for abdominal wall incisions because there is lack of significant neurovascular branches in this region	249, 254
 Inguinal ligament	Surface landmark that marks division between abdominal wall and thigh	249, 253
 Inguinal (Hesselbach's) triangle	Weak area on anterior abdominal wall where abdominal contents may herniate, producing direct inguinal hernia	256, 262
 Deep (internal) inguinal ring	Opening on anterior abdominal wall where abdominal contents may herniate, producing indirect inguinal hernia	262, 263
 Femoral ring	Opening medial to external iliac vessels where abdominal contents may herniate, producing femoral hernia	264
 Esophageal hiatus of diaphragm	Widening of this opening allows stomach to protrude into mediastinum, causing gastroesophageal reflux	269, 271
DIGESTIVE SYSTEM		
 Liver	Palpable inferior to right costal margin	270, 276
 Gastroesophageal junction	Transient relaxations or decreased tone of lower esophageal sphincter can cause gastric esophageal reflux disease (GERD)	277, 328
 Stomach, duodenum	Site of peptic ulcer formation	276, 277
 Appendix	Prone to inflammation and rupture	280, 282
 Colon	Common site of diverticula; colonoscopy is performed to screen for colon cancer	283
 Gallbladder	Palpable at junction of right costal margin and midclavicular line; may become inflamed (cholecystitis) and cause pain; gallstones can block biliary ducts	284, 309
URINARY SYSTEM		
 Kidney	Maintain fluid and electrolyte balance; may develop renal calculi (kidney stones)	314
ENDOCRINE SYSTEM		
 Pancreas	Due to its retroperitoneal position, pain from pancreas is typically referred to the back; cancer of head of pancreas can compress common bile duct	288, 310

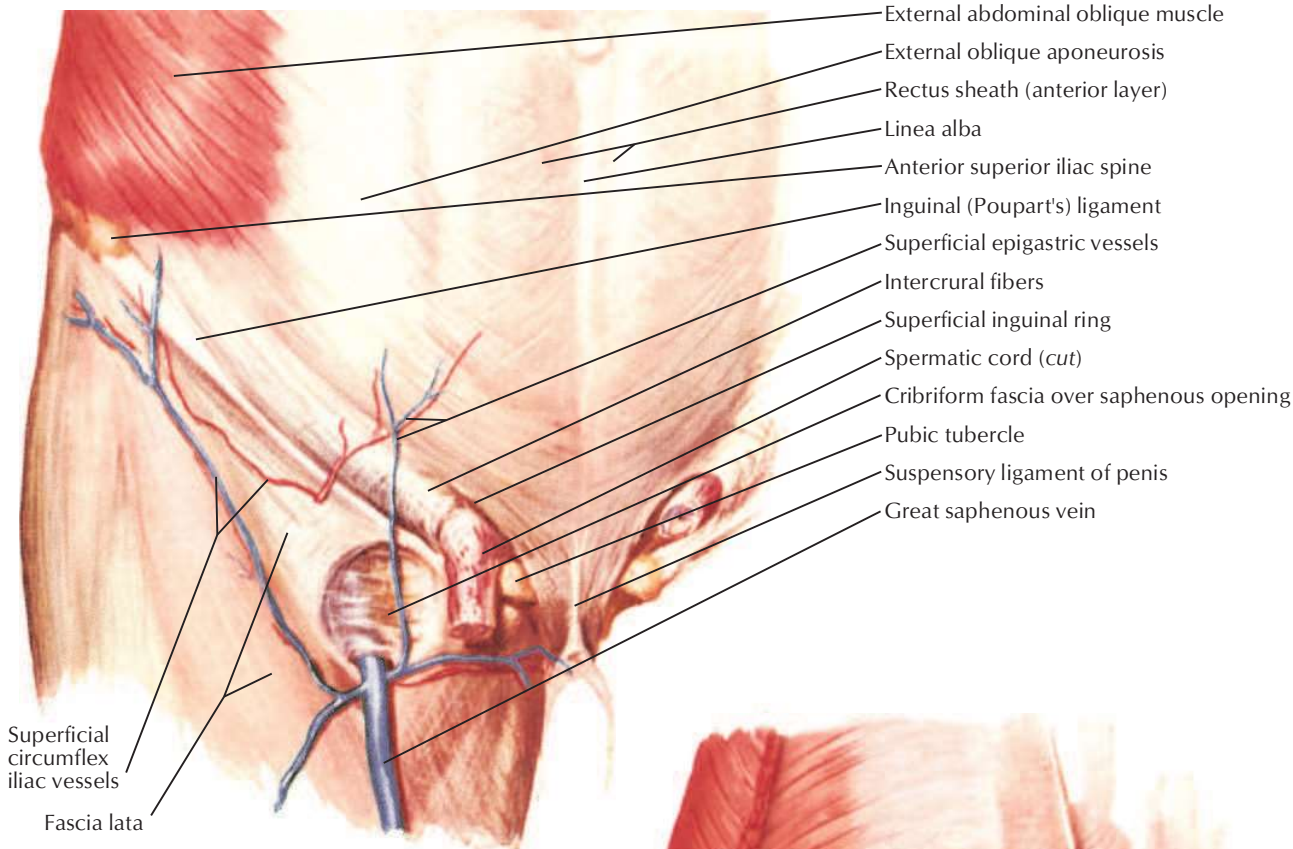
Table 5.1

ANATOMICAL STRUCTURES	CLINICAL IMPORTANCE	PLATE NUMBERS
 NERVOUS SYSTEM		
Ilioinguinal and genitofemoral nerves	Mediate cremasteric reflex, which tests integrity of L1 spinal nerve	269
Intercostal, subcostal, and iliohypogastric nerves	Convey well-localized pain sensations from abdominal wall and parietal peritoneum; pain in dermatomal distribution indicates problem with spinal nerves (e.g., herpes zoster infection)	260
Renal artery sympathetic fibers	Medically resistant hypertension can be treated in some patients by denervating sympathetic fibers traveling along renal arteries	300, 321
Celiac ganglion	Some patients with medically intractable pain from chronic pancreatitis undergo celiac ganglion block	301, 310
Sympathetic splanchnic nerves	Convey pain sensations from abdominal viscera that are often referred to other sites; quadrant in which pain is located and site of radiation provide clues to source of pain	303, 306
Iliohypogastric nerve	Nephrectomy through quadratus lumborum can damage iliohypogastric nerve, with resultant anesthesia above pubis	312
 CARDIOVASCULAR SYSTEM		
Arterial anastomoses of anterior abdominal wall	Anastomosis between epigastric arteries and internal thoracic arteries and between circumflex arteries and intercostal and lateral thoracic arteries	258
Venous anastomoses of anterior abdominal wall	Anastomosis between epigastric veins and internal thoracic veins and between circumflex and thoracoepigastric veins and lateral thoracic veins	259
Paraumbilical veins	May become dilated in patients with portal hypertension, producing caput medusa	259, 299
Cystic artery	Ligated during cholecystectomy	291
Superior mesenteric artery	May compress 3rd part of duodenum in thin patient or patient who has recently lost a lot of weight	291, 294
Intestinal arteries	Areas without significant collateral circulation between major vessels (watershed areas) are at risk for ischemia	294, 295
Marginal artery anastomosis	Marginal artery connects right, middle, and left colic arteries, providing important anastomosis for collateral circulation	295
Esophageal veins	May become dilated with portal hypertension, resulting in esophageal varices	296, 299
Hepatic portal vein	Reduced blood flow through liver (e.g., due to cirrhosis) may produce portal hypertension and dilation of tributaries of portal vein; blood may return to heart at sites of portosystemic anastomosis	298, 299
Superior rectal vein	Has anastomoses with systemic rectal veins that may become dilated with portal hypertension	298, 299
Abdominal aorta	Common site for aneurysm in abdomen, especially inferior to renal arteries	317
 LYMPHATIC SYSTEM		
Spleen	May be ruptured by fracture of ribs 9 to 11; splenic enlargement is assessed by palpation	273, 289

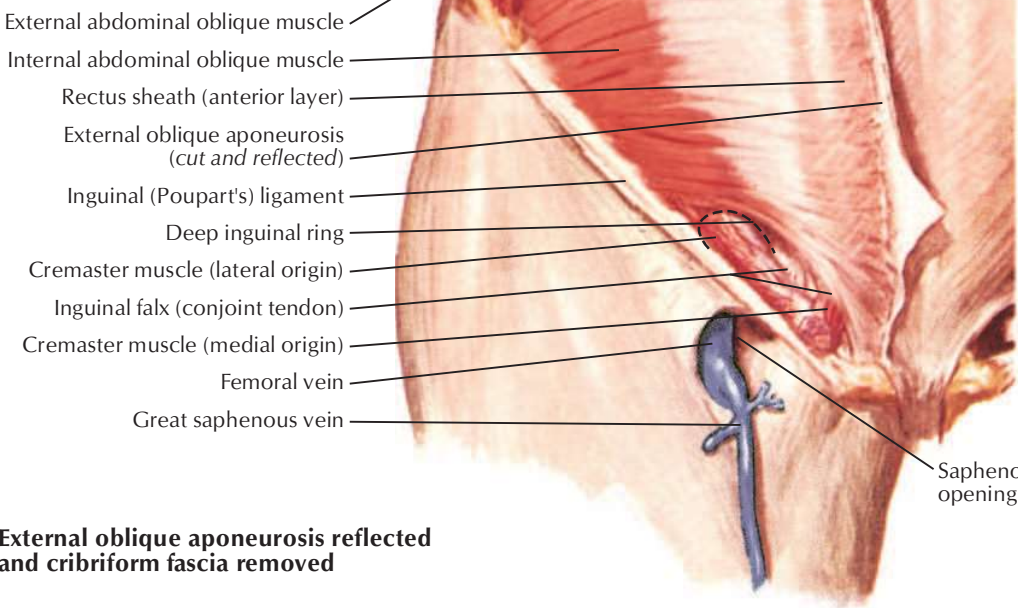
*Selections were based largely on clinical data as well as commonly covered clinical correlations in gross anatomy courses.

MUSCLE	MUSCLE GROUP	PROXIMAL ATTACHMENT (ORIGIN)	DISTAL ATTACHMENT (INSERTION)	INNERVATION	BLOOD SUPPLY	MAIN ACTIONS
Respiratory diaphragm	Posterior abdominal wall	Xiphoid process, lower six costal cartilages, L1–L3 vertebrae	Converges into central tendon	Phrenic nerve	Pericardiophrenic, musculophrenic, superior and inferior phrenic arteries	Draws central tendon down and forward during inspiration
External abdominal oblique	Anterior abdominal wall	External surfaces of ribs 5–12	Linea alba, pubic tubercle, anterior half of iliac crest	Anterior rami of six inferior thoracic nerves	Superior and inferior epigastric arteries	Compresses and supports abdominal viscera, flexes and rotates trunk
Internal abdominal oblique	Anterior abdominal wall	Thoracolumbar fascia, anterior 2/3 of iliac crest, lateral half of inguinal ligament	Inferior borders of ribs 10–12, linea alba, pubis via conjoint tendon	Anterior rami of six inferior thoracic and first lumbar nerves	Superior and inferior epigastric and deep circumflex iliac arteries	Compresses and supports abdominal viscera, flexes and rotates trunk
Psoas major	Posterior abdominal wall	Transverse processes of lumbar vertebrae, sides of bodies of T12–L5 vertebrae, intervening intervertebral discs	Lesser trochanter of femur	Anterior rami of first three lumbar nerves	Lumbar branches of iliolumbar artery	Acting superiorly with iliacus, flexes hip; acting inferiorly, flexes vertebral column laterally; used to balance trunk in sitting position; acting inferiorly with iliacus, flexes trunk
Psoas minor	Posterior abdominal wall	Vertebral margins of T12–L1 vertebrae, corresponding intervertebral disc	Pectineal line, iliopectineal eminence	Anterior rami of first lumbar nerve	Lumbar branch of iliolumbar artery	Flexes pelvis on vertebral column
Pyramidalis	Anterior abdominal wall	Body of pubis, anterior to rectus abdominis	Linea alba	Iliohypogastric nerve	Inferior epigastric artery	Tenses linea alba
Quadratus lumborum	Posterior abdominal wall	Medial half of inferior border of 12th rib, tips of lumbar transverse processes	Iliolumbar ligament, internal lip of iliac crest	Anterior rami of T12 and first four lumbar nerves	Iliolumbar artery	Extends and laterally flexes vertebral column, fixes 12th rib during inspiration
Rectus abdominis	Anterior abdominal wall	Pubic symphysis, pubic crest	Xiphoid process, costal cartilages 5–7	Anterior rami of six inferior thoracic nerves	Superior and inferior epigastric arteries	Flexes trunk, compresses abdominal viscera
Transversus abdominis	Anterior abdominal wall	Internal surfaces of costal cartilages 7–12, thoracolumbar fascia, iliac crest, lateral third of inguinal ligament	Linea alba with aponeurosis of internal abdominal oblique, pubic crest, and pecten pubis via conjoint tendon	Anterior rami of six inferior thoracic and first lumbar nerves	Deep circumflex iliac and inferior epigastric arteries	Compresses and supports abdominal viscera

Variations in spinal nerve contributions to the innervation of muscles, their arterial supply, their attachments, and their actions are common themes in human anatomy. Therefore, expect differences between texts and realize that anatomical variation is normal.



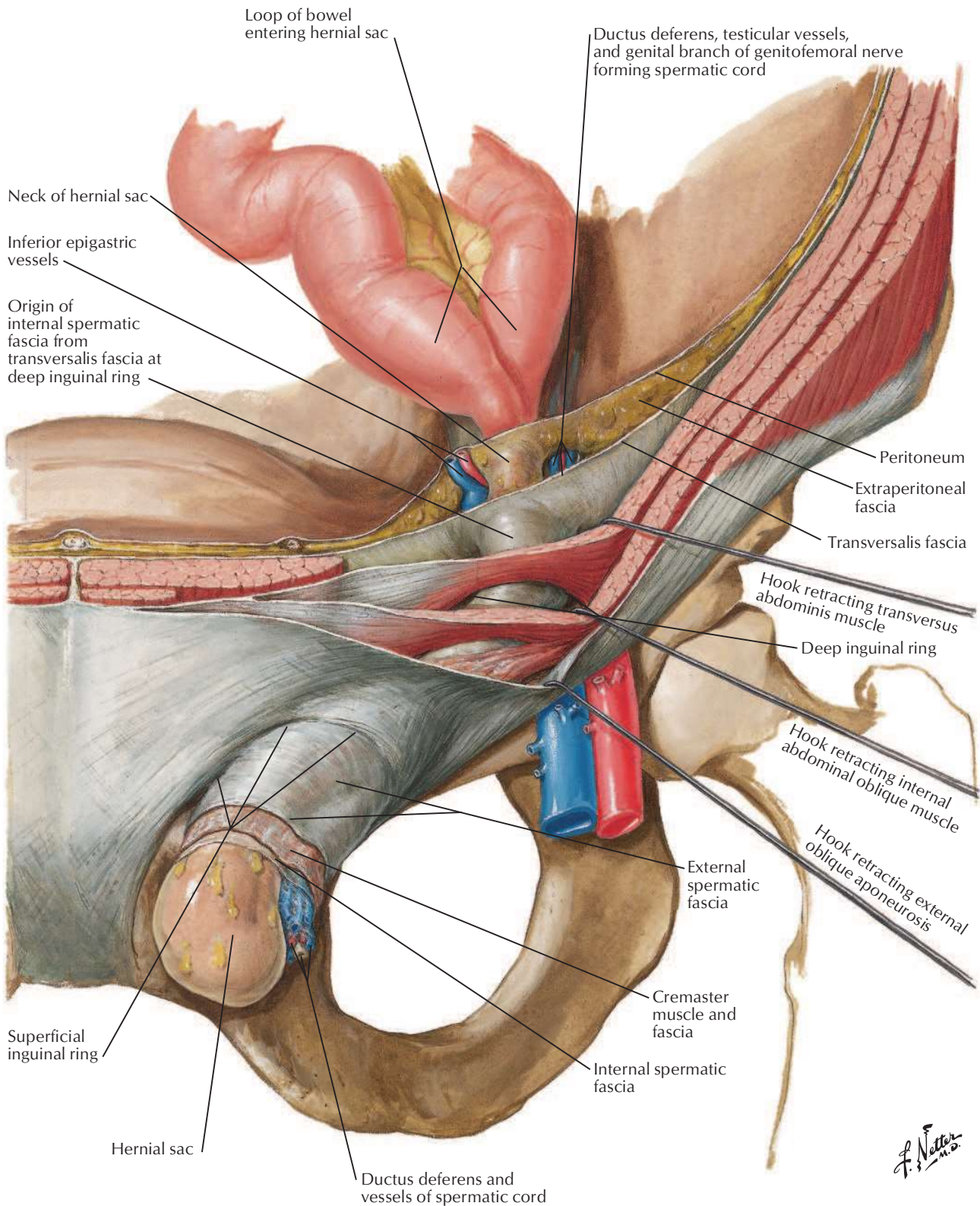
Skin and superficial fascia removed



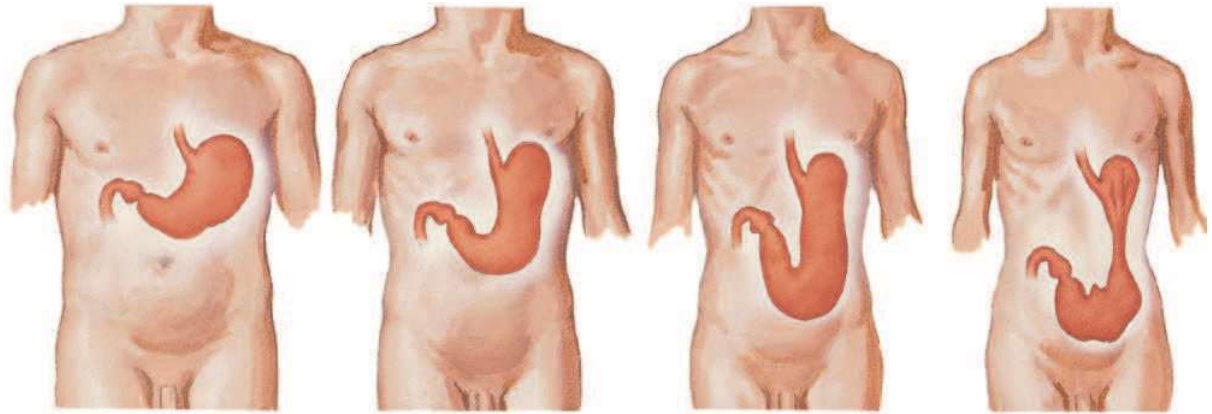
External oblique aponeurosis reflected and cribriform fascia removed

F. Netter M.D.
K. Marzigan

Indirect Inguinal Hernia



Variations in position and contour of stomach in relation to body habitus

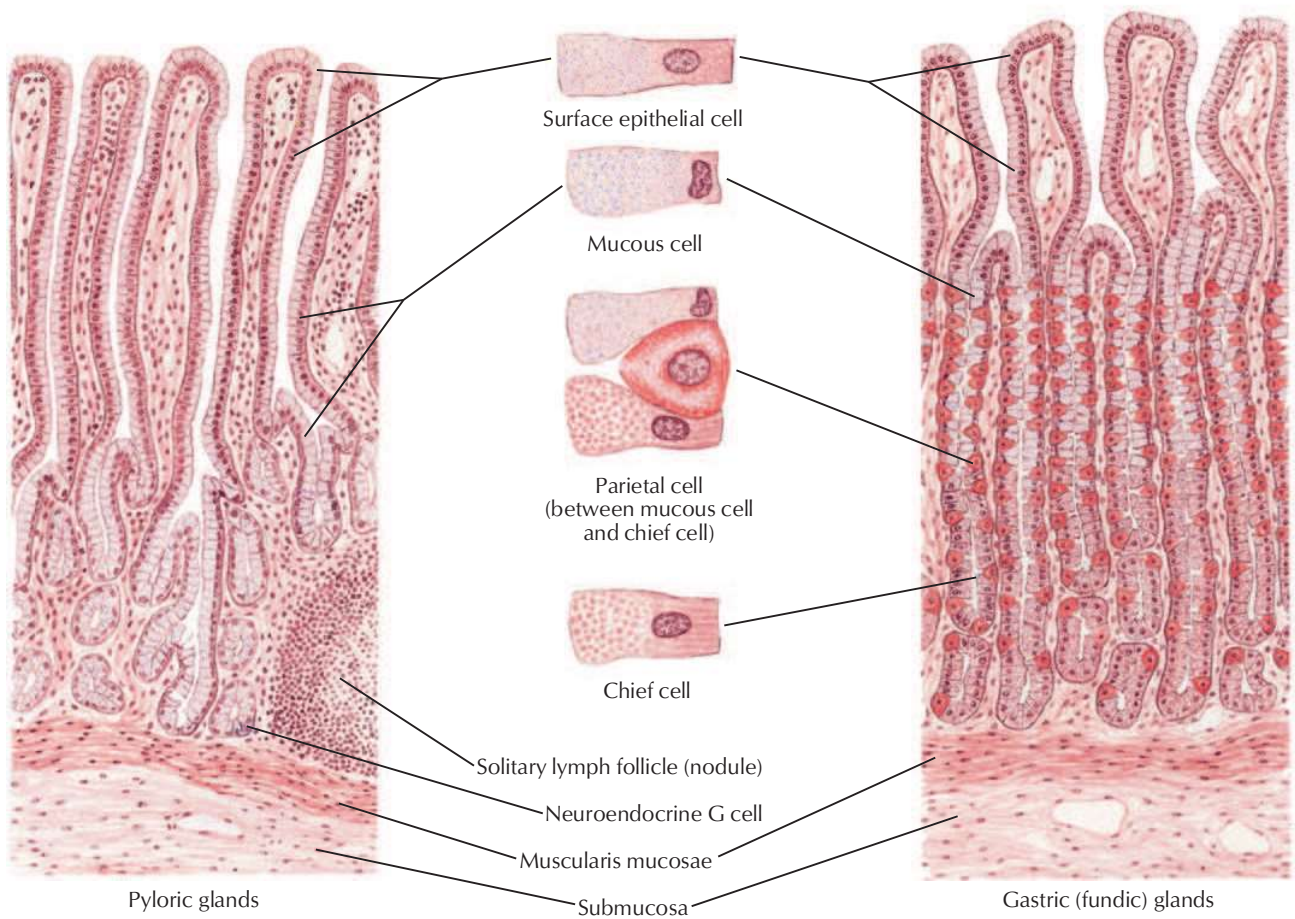


Hypertonic stomach

Orthotonic stomach

Hypotonic stomach

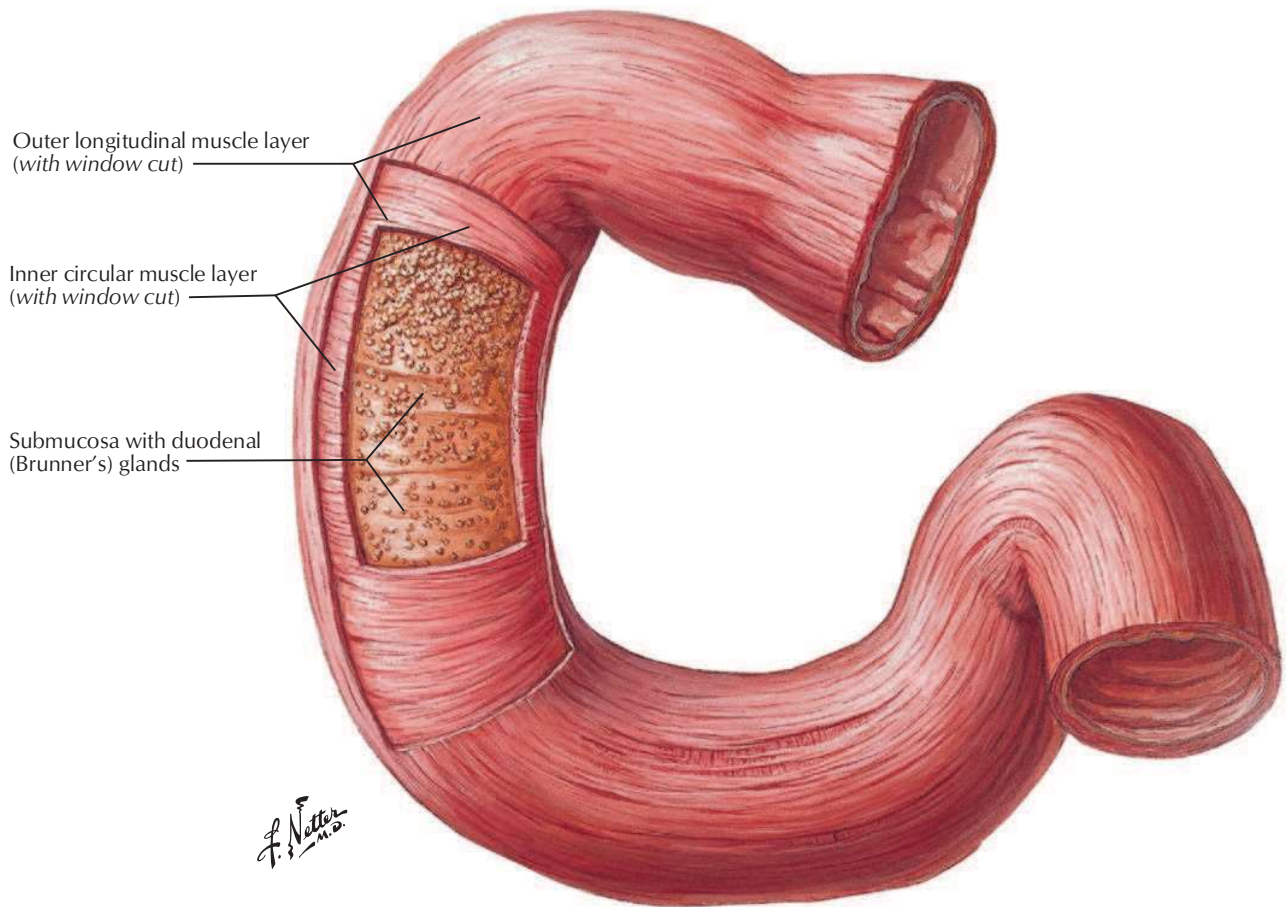
Atonic stomach



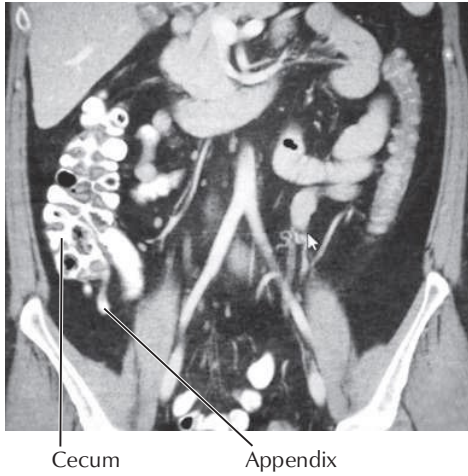
Pyloric glands

Gastric (fundic) glands

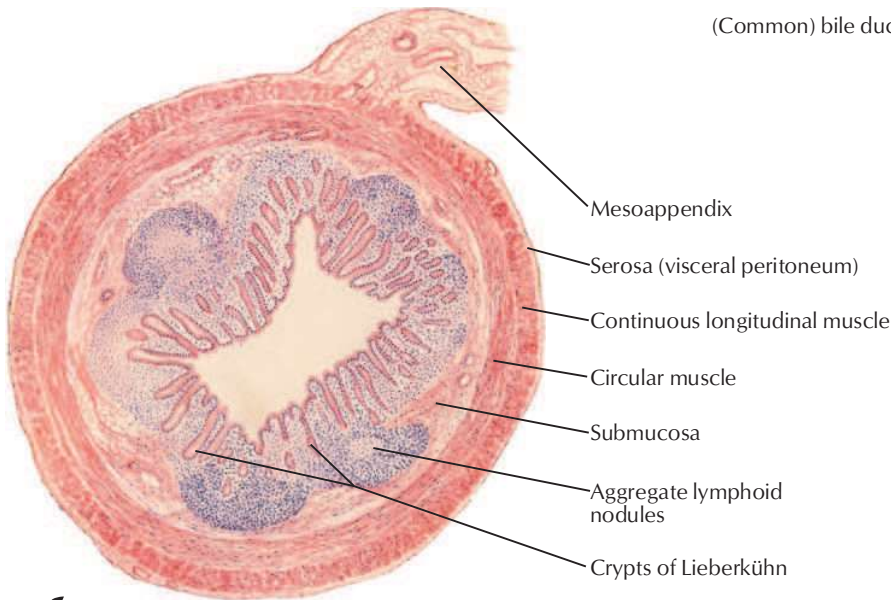
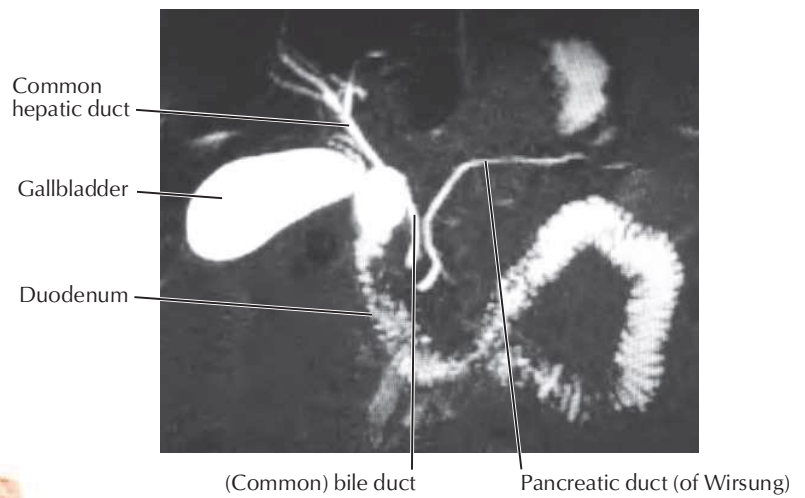
F. Netter M.D.



Coronal CT image with contrast

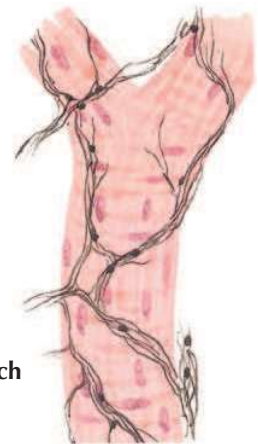


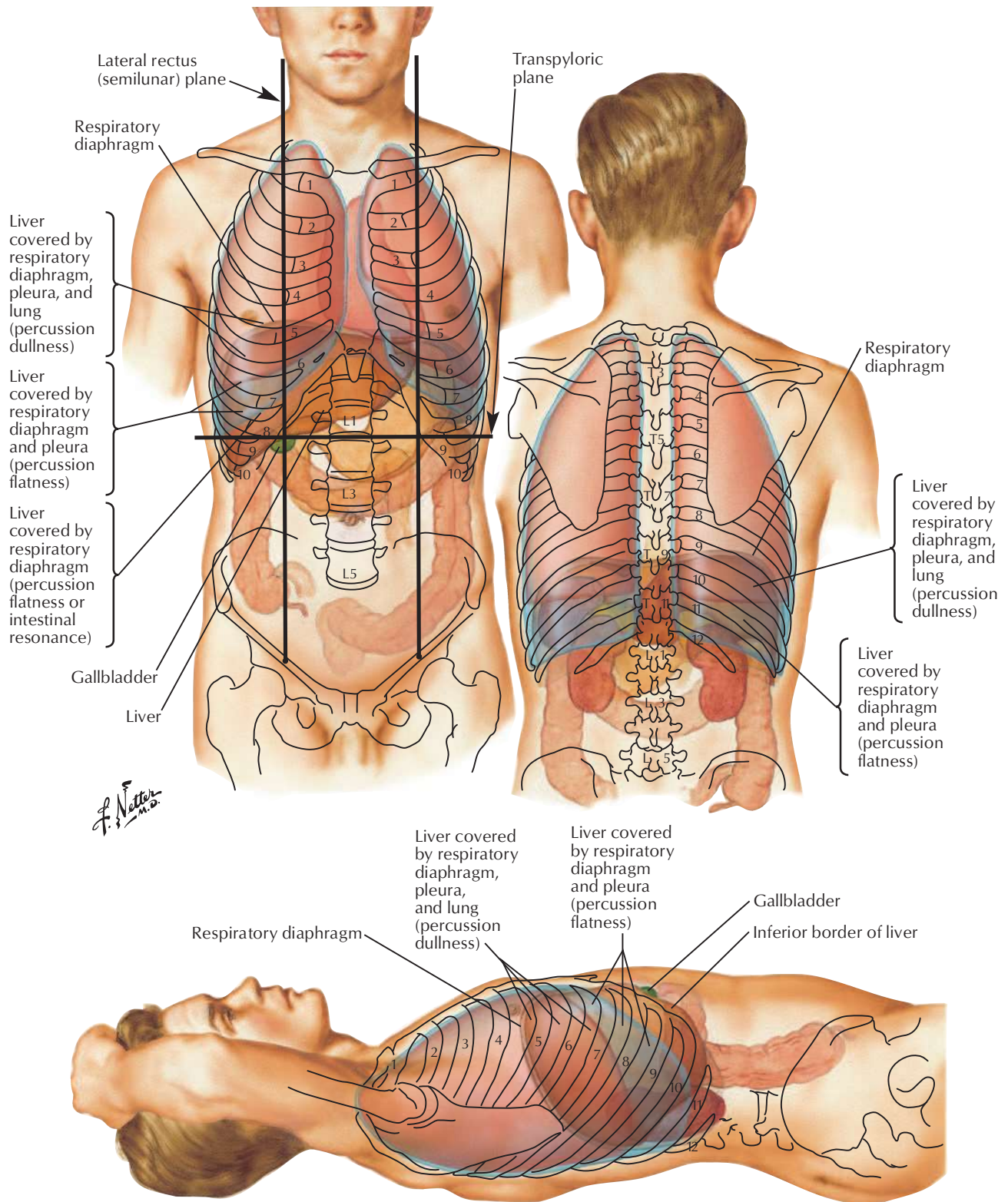
Magnetic resonance cholangiopancreatography (MRCP)

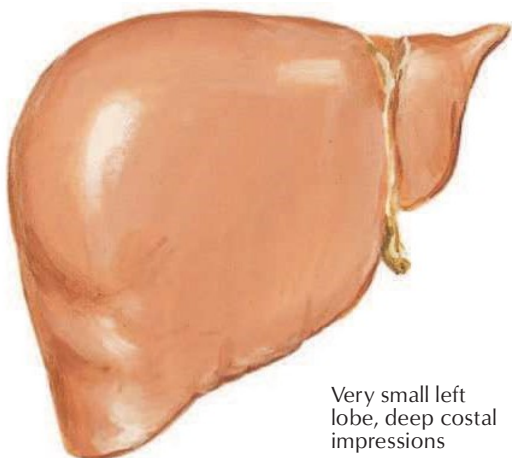


F. Netter M.D.

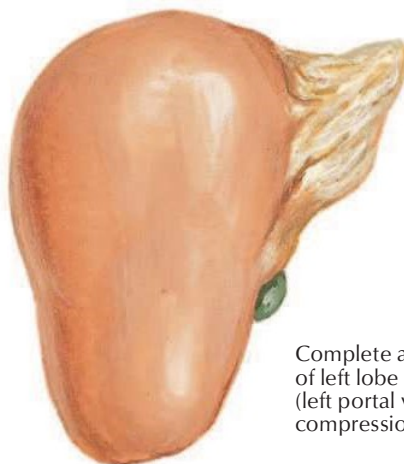
Ramification of nerve fibers around fine branch of hepatic artery



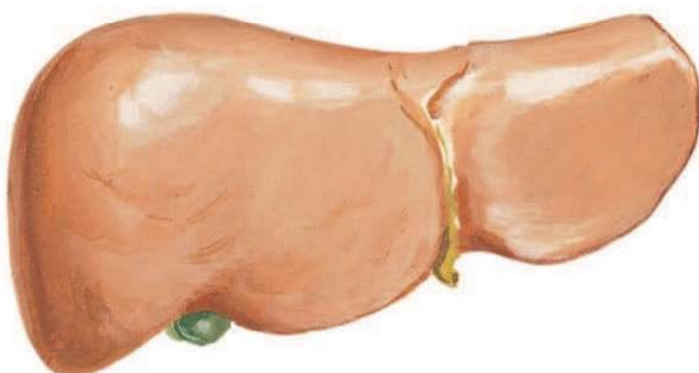




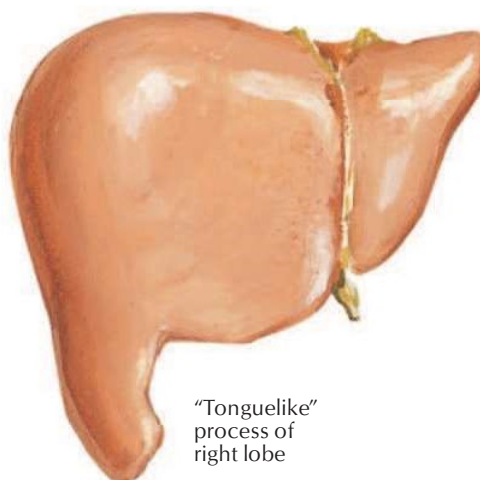
Very small left lobe, deep costal impressions



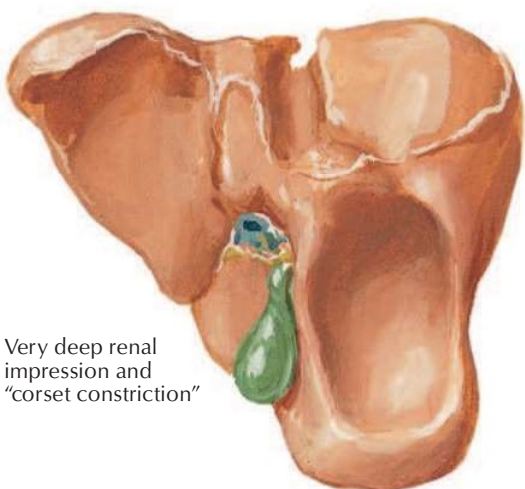
Complete atrophy of left lobe (left portal vein compression)



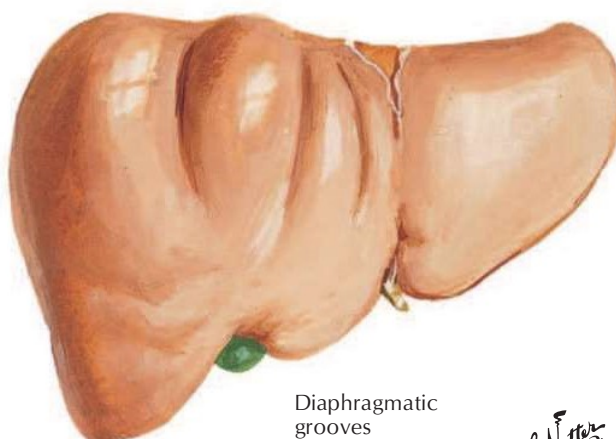
Transverse, "saddlelike" liver, relatively large left lobe



"Tonguelike" process of right lobe

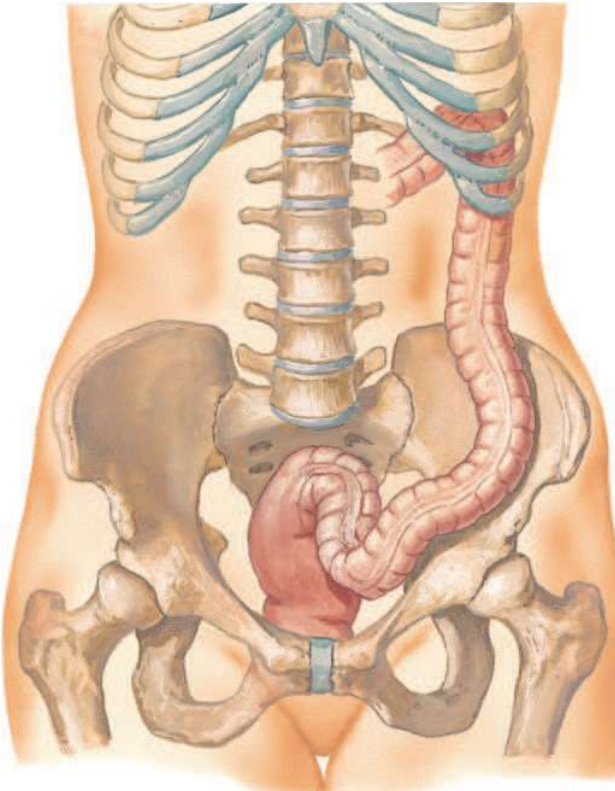


Very deep renal impression and "corset constriction"

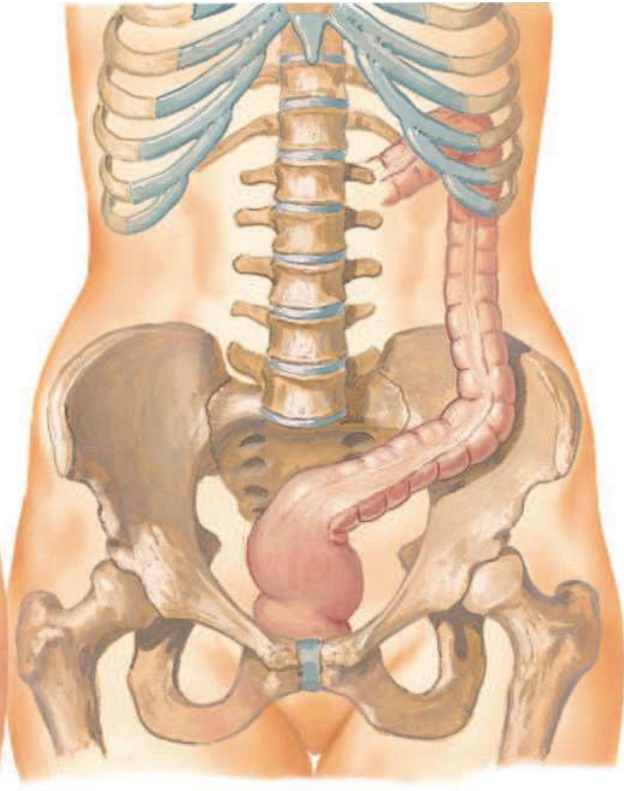


Diaphragmatic grooves

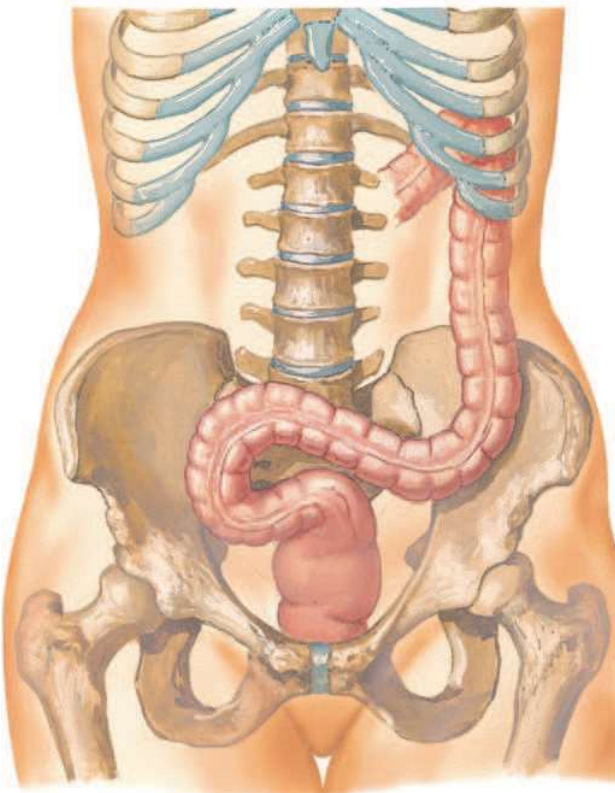
F. Netter M.D.



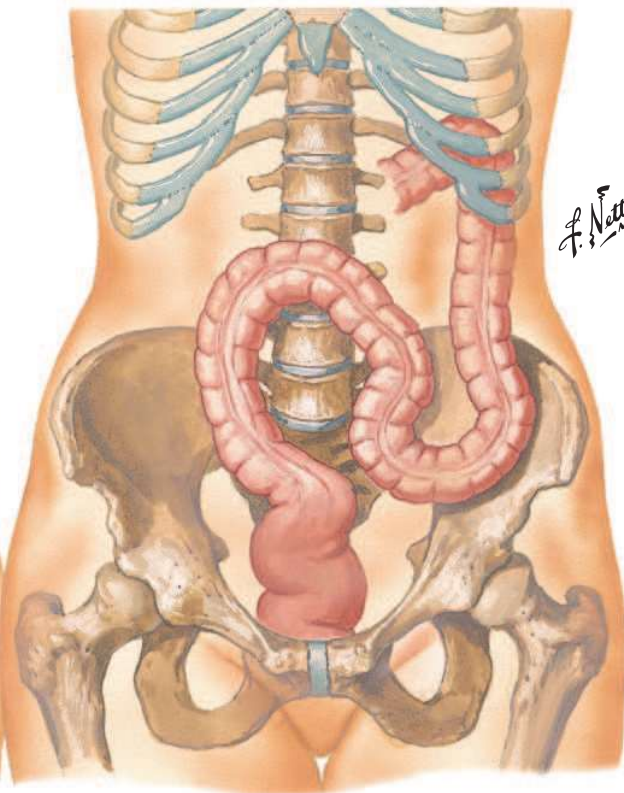
Typical



Short, straight, obliquely into pelvis

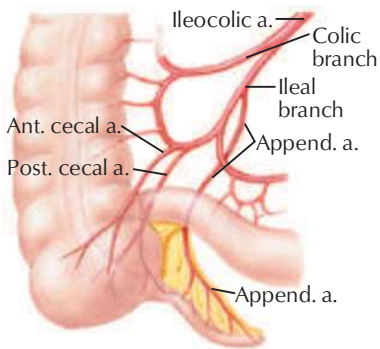


Looping to right side

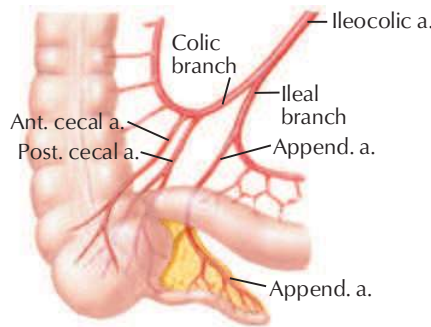


Ascending high into abdomen

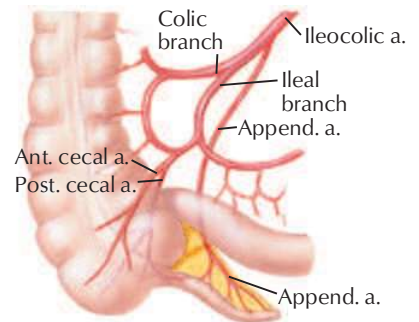
Variations in Arterial Supply to Cecum and Posterior Peritoneal Attachment of Cecum



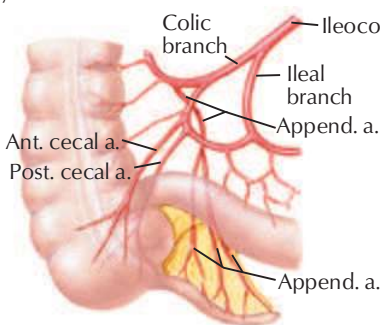
Anterior cecal and posterior cecal arteries originate from arcade between colic and ileal branches of ileocolic artery; appendicular artery from ileal branch



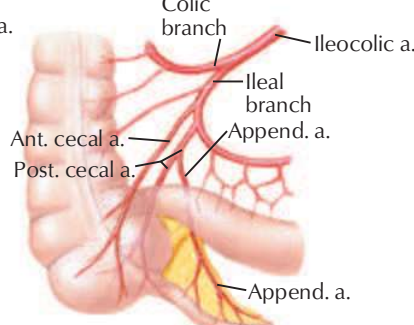
Anterior cecal and posterior cecal arteries originate from colic branch; appendicular artery from ileal branch of ileocolic artery



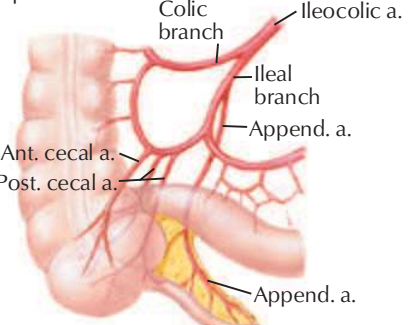
Anterior cecal and posterior cecal arteries have common origin from arcade; appendicular artery from ileocolic artery proper



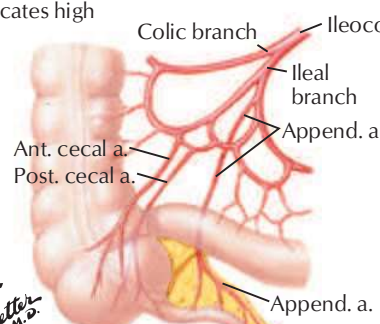
Anterior cecal and posterior cecal arteries originate from arcade between colic and ileal branches of ileocolic artery; appendicular artery from colic branch bifurcates high



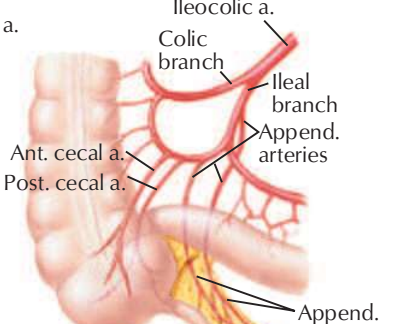
Anterior cecal and posterior cecal arteries originate from ileal branch of ileocolic artery; appendicular artery from posterior cecal



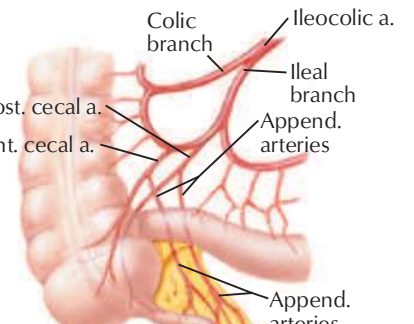
Anterior cecal and two posterior cecal arteries originate from arcade; appendicular artery from ileal branch of ileocolic artery



Multiple arcades between ileal branch and colic branch of ileocolic artery. Anterior cecal and posterior cecal arteries originate from these arcades; appendicular artery from ileal branch

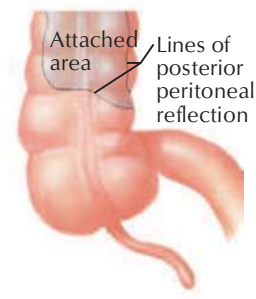
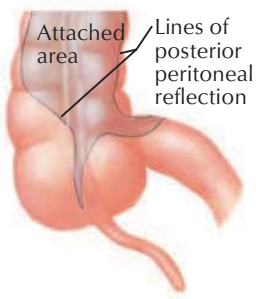
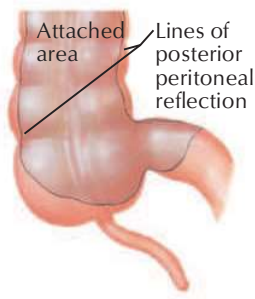
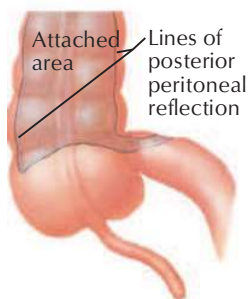


Anterior cecal and posterior cecal arteries originate from arcade between colic and ileal branches of ileocolic artery; two appendicular arteries, one deriving from arcade, the other from ileal branch, are present

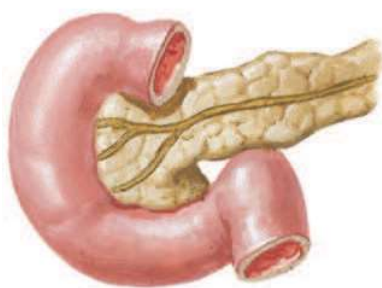
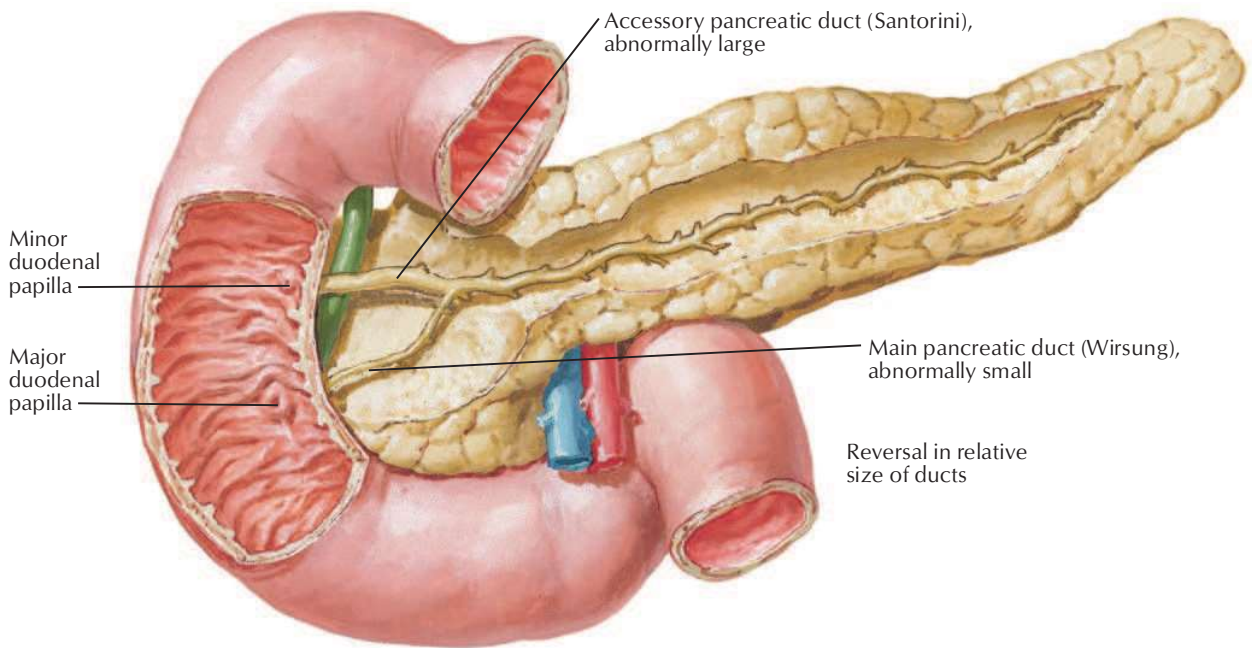


Anterior cecal and posterior cecal arteries originate from arcade; two appendicular arteries, one deriving from anterior cecal, the other from posterior cecal, are present

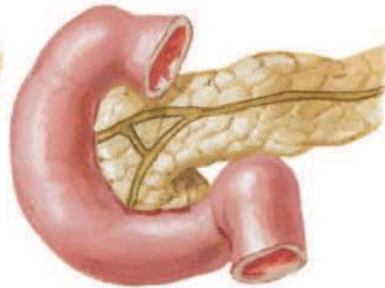
Some variations in posterior peritoneal attachment of cecum



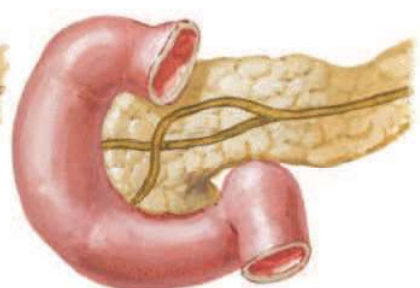
Variations in Pancreatic Duct



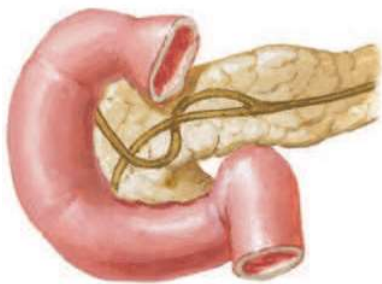
Double accessory pancreatic duct (Santorini)



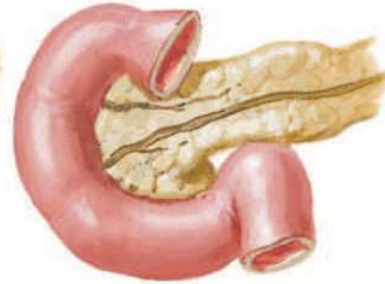
Anastomosis between ducts



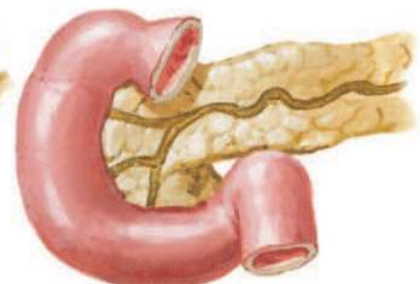
Crossing of ducts



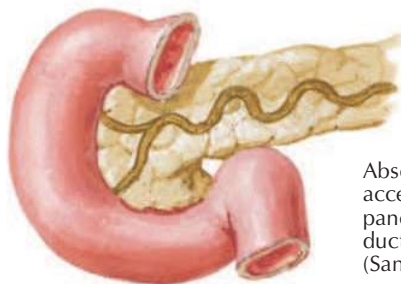Double crossing of ducts



No communication between ducts

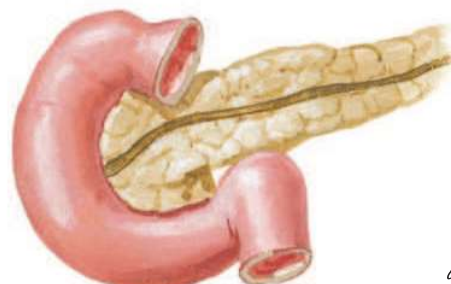

Double main pancreatic duct (Wirsung)

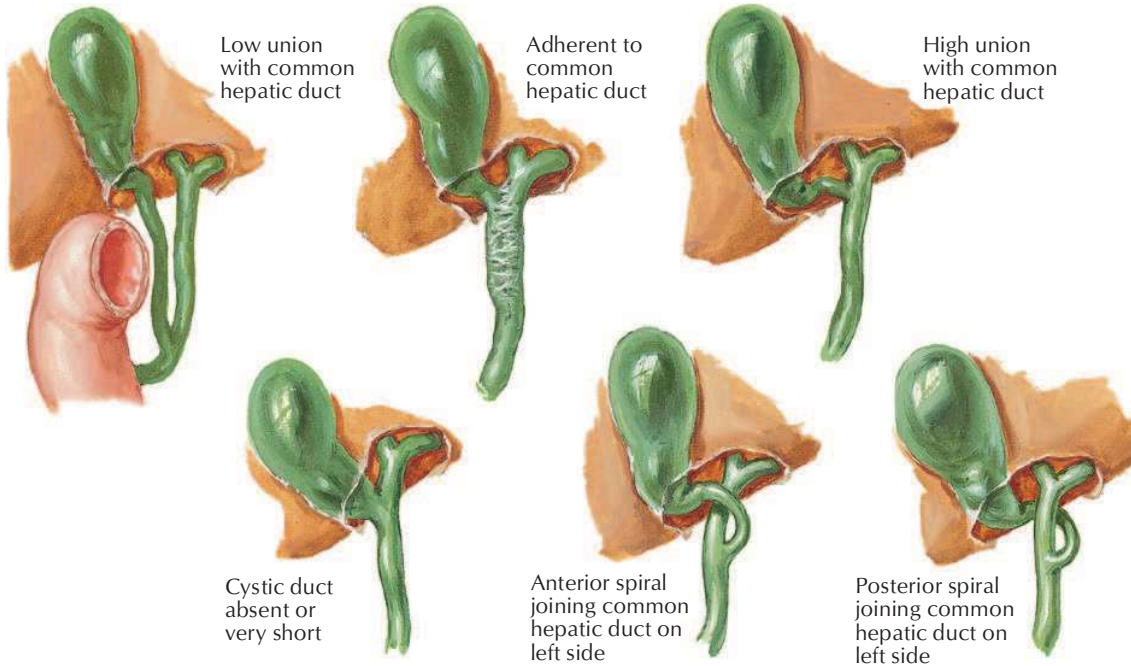


Tortuosity of ducts

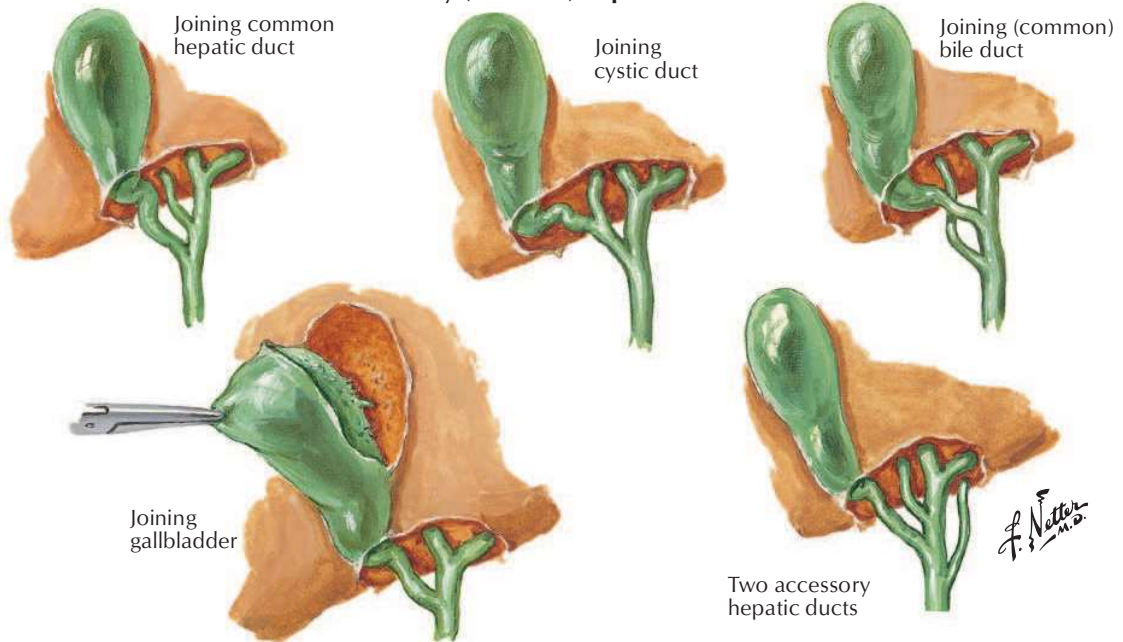
Absence of accessory pancreatic duct (Santorini)



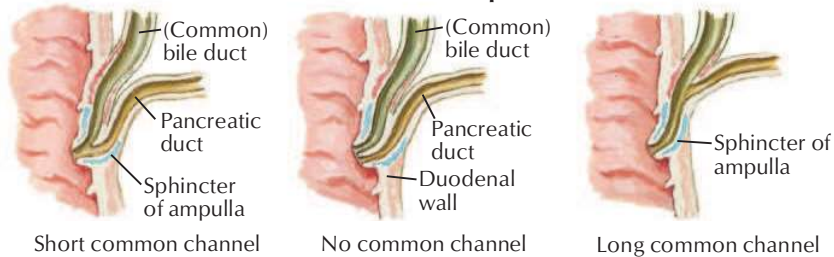
Variations in cystic duct



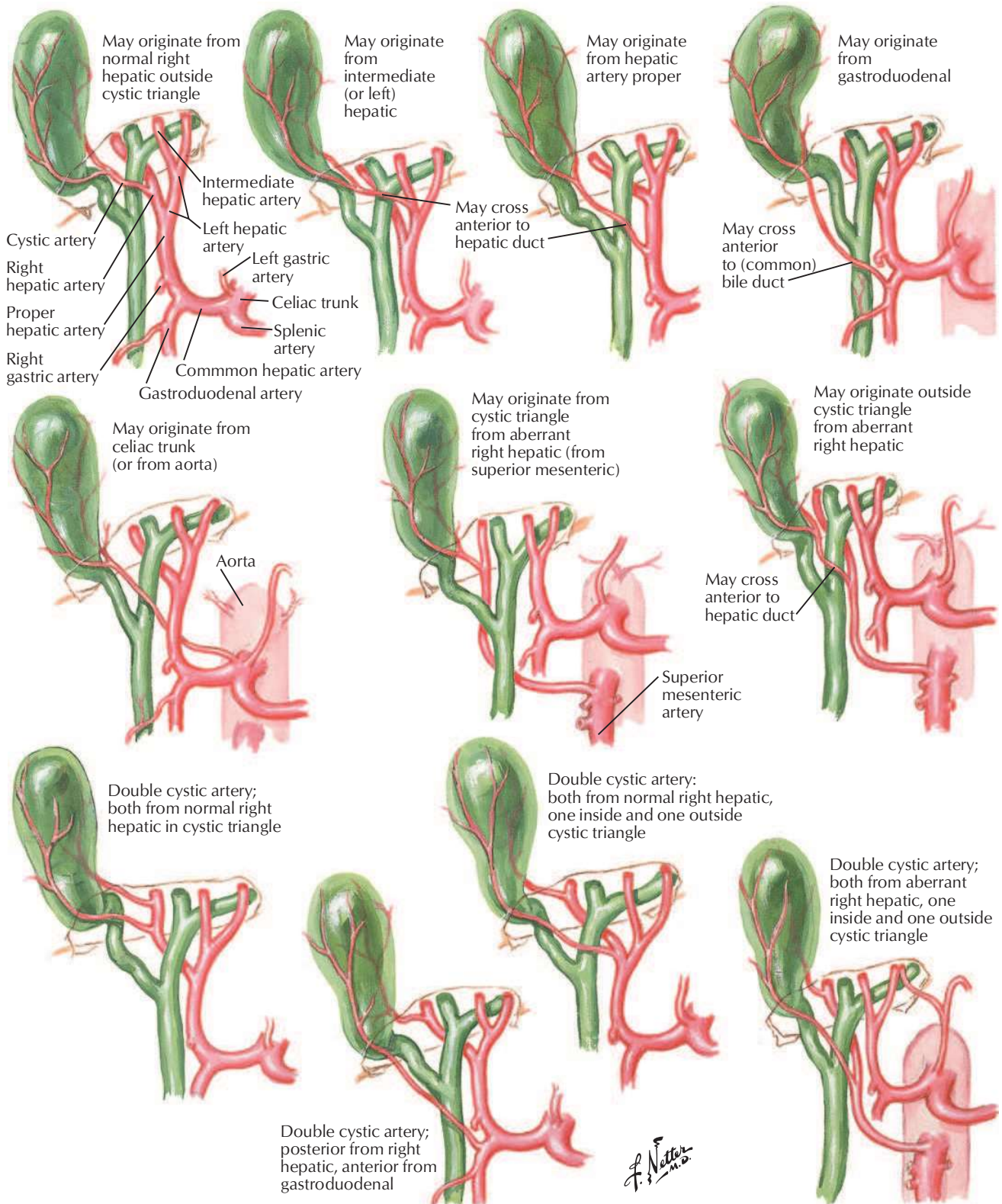
Accessory (aberrant) hepatic ducts

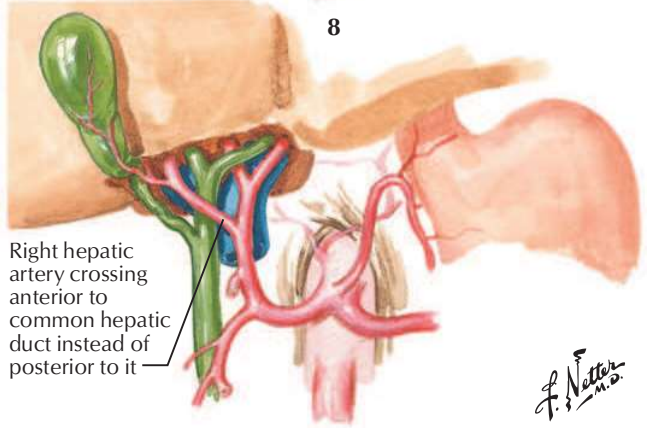
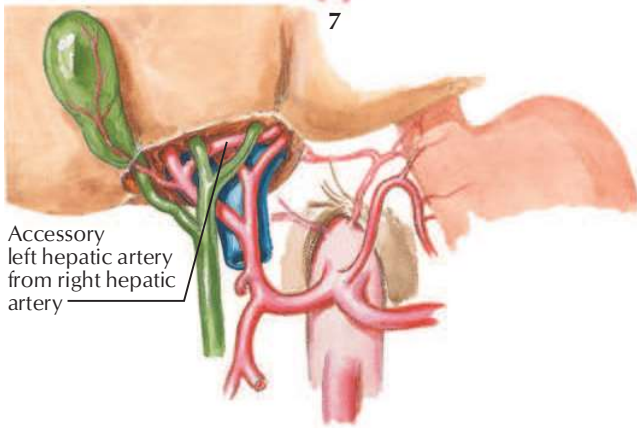
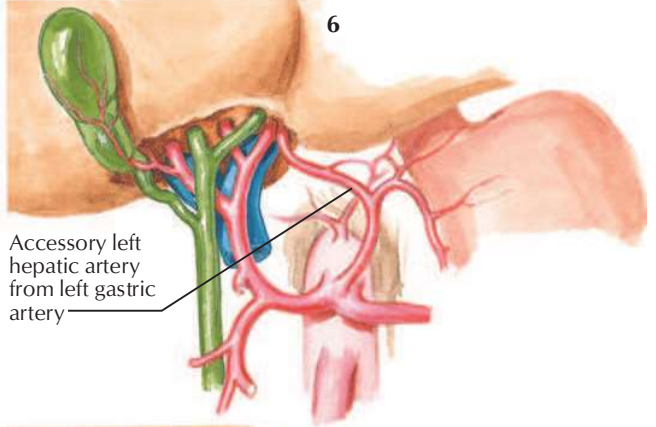
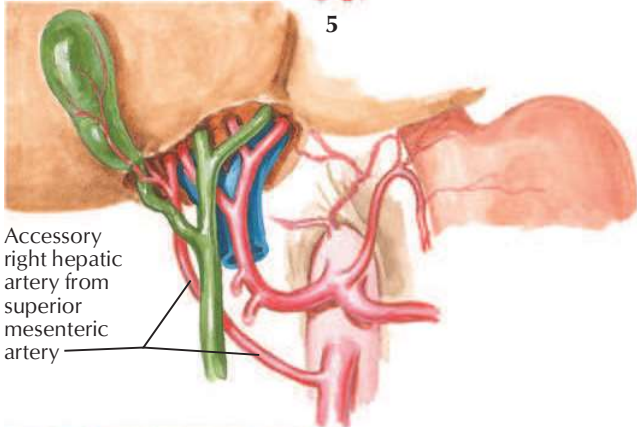
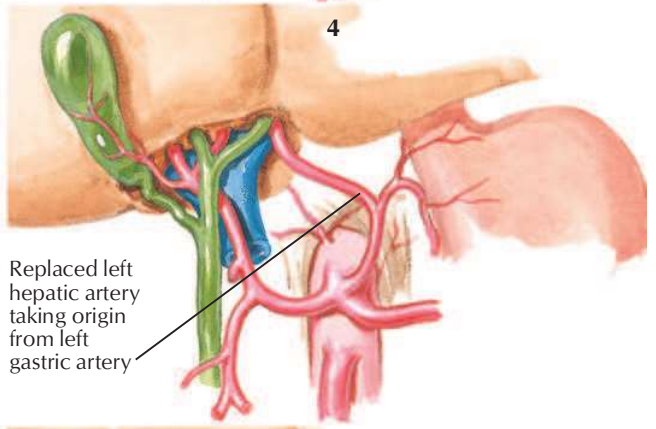
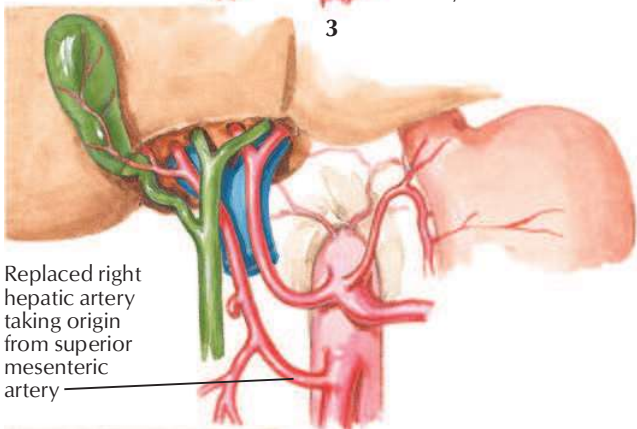
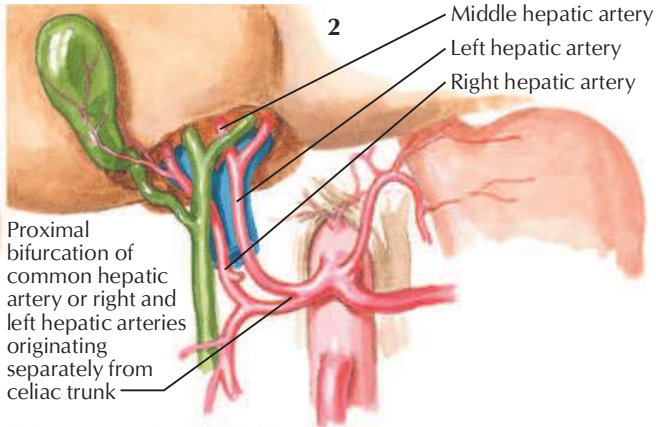
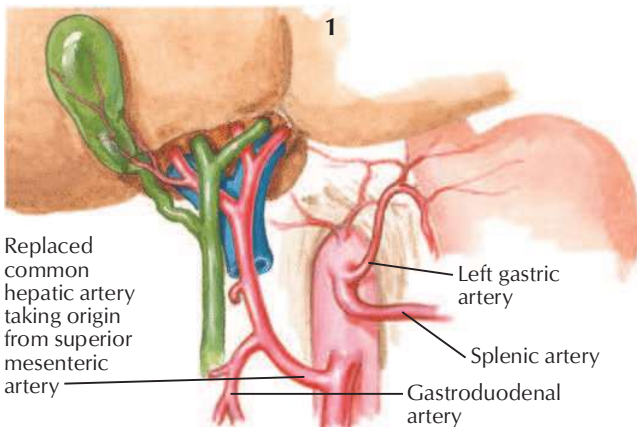


Variations in union of bile and pancreatic ducts



Variations in Cystic Arteries

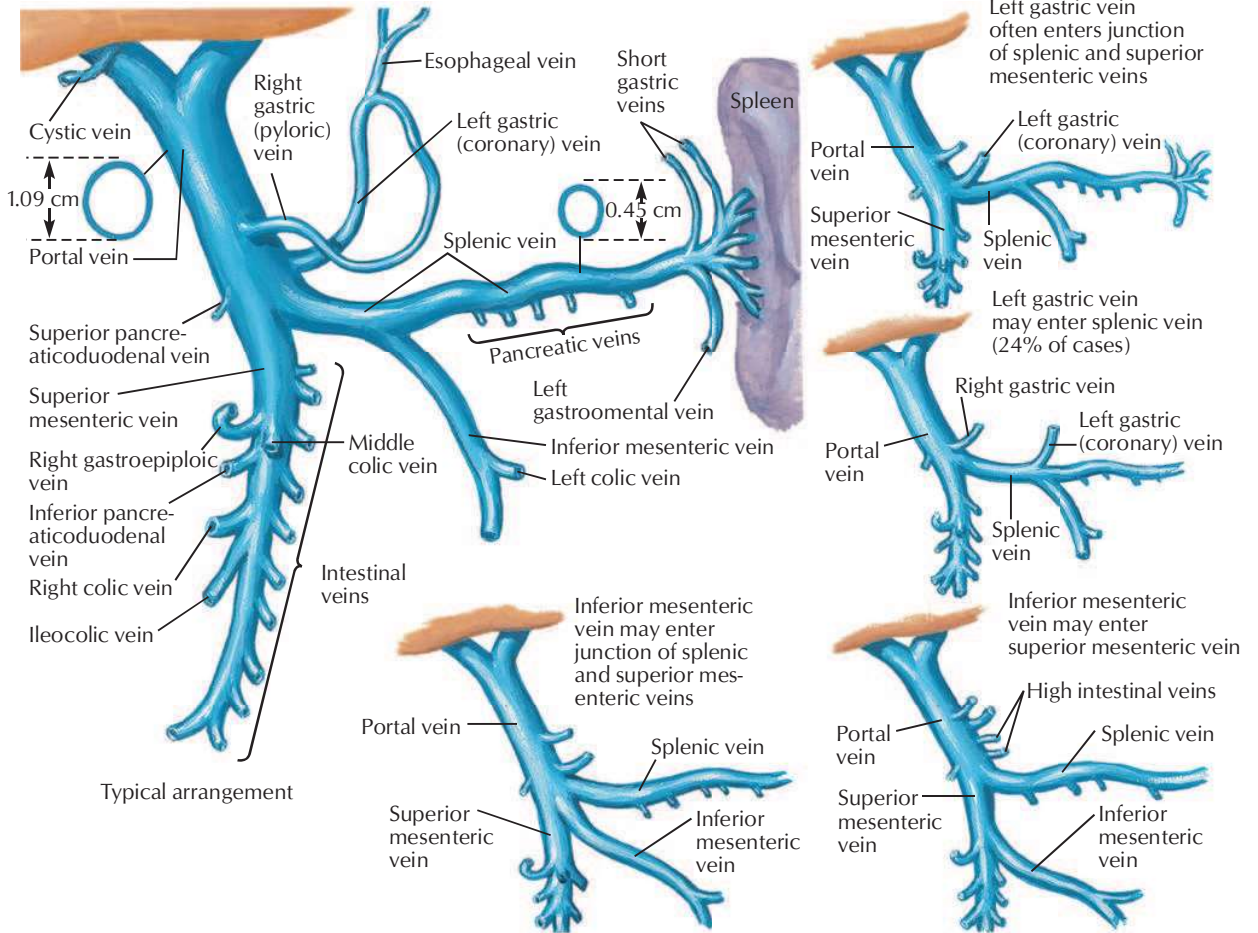




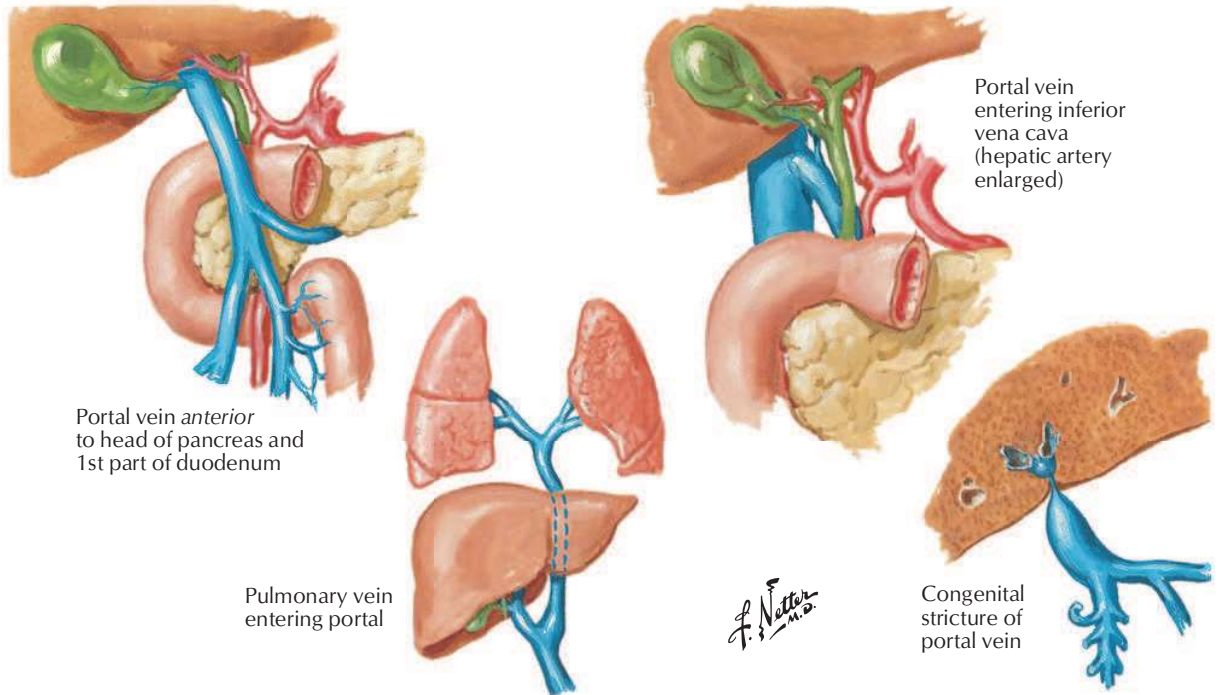
F. Netter M.D.

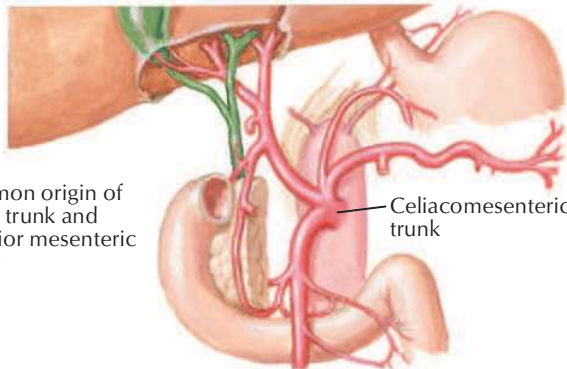
Variations and Anomalies of Hepatic Portal Vein

Variations



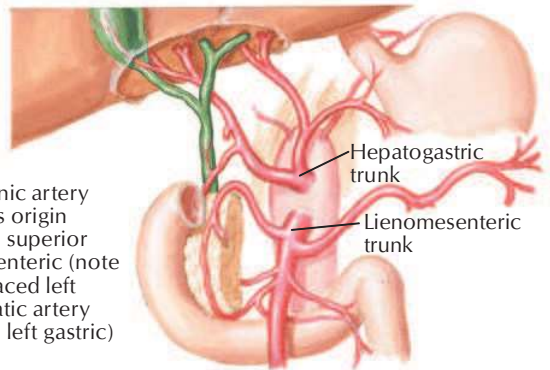
Anomalies





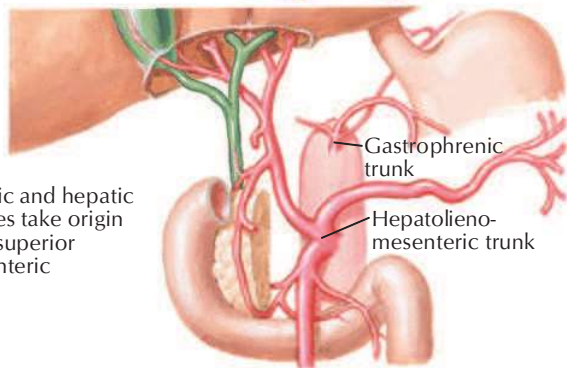
Common origin of celiac trunk and superior mesenteric artery

Celiacomesenteric trunk



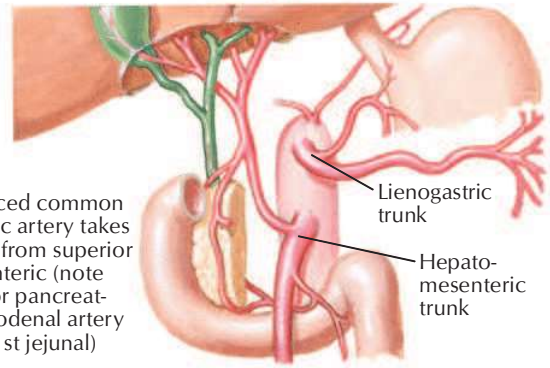
Splenic artery takes origin from superior mesenteric (note replaced left hepatic artery from left gastric)

Hepatogastric trunk
Lienomesenteric trunk



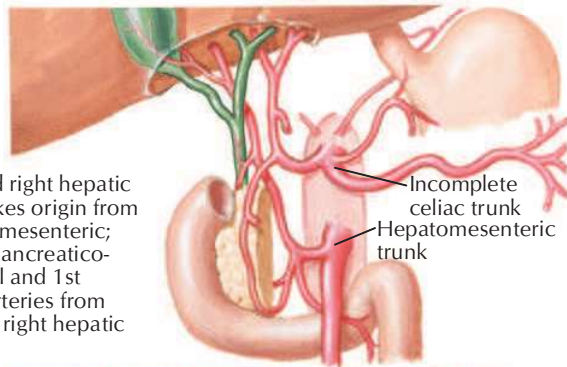
Splenic and hepatic arteries take origin from superior mesenteric

Gastrophrenic trunk
Hepatolienomesenteric trunk



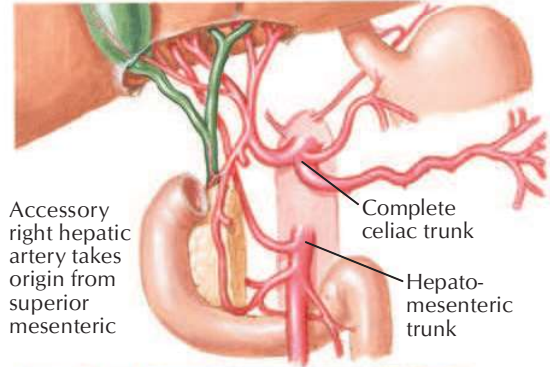
Replaced common hepatic artery takes origin from superior mesenteric (note inferior pancreaticoduodenal artery from 1st jejunal)

Lienogastric trunk
Hepatomesenteric trunk



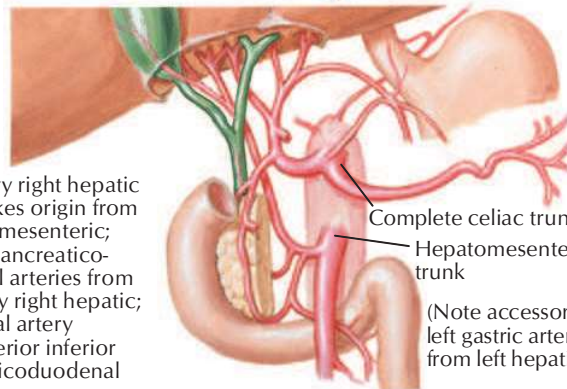
Replaced right hepatic artery takes origin from superior mesenteric; inferior pancreaticoduodenal and 1st jejunal arteries from replaced right hepatic

Incomplete celiac trunk
Hepatomesenteric trunk



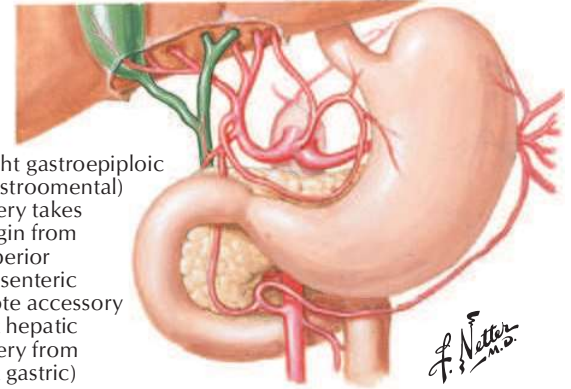
Accessory right hepatic artery takes origin from superior mesenteric

Complete celiac trunk
Hepatomesenteric trunk



Accessory right hepatic artery takes origin from superior mesenteric; inferior pancreaticoduodenal arteries from accessory right hepatic; 1st jejunal artery from anterior inferior pancreaticoduodenal

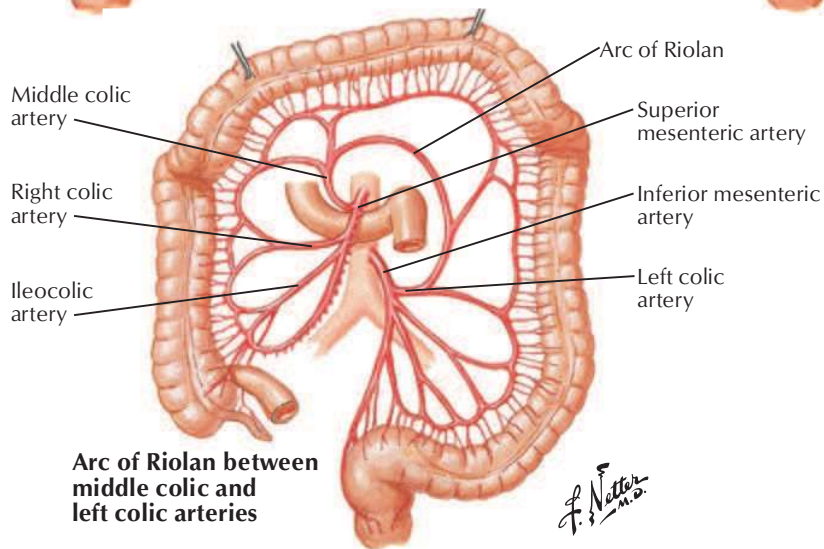
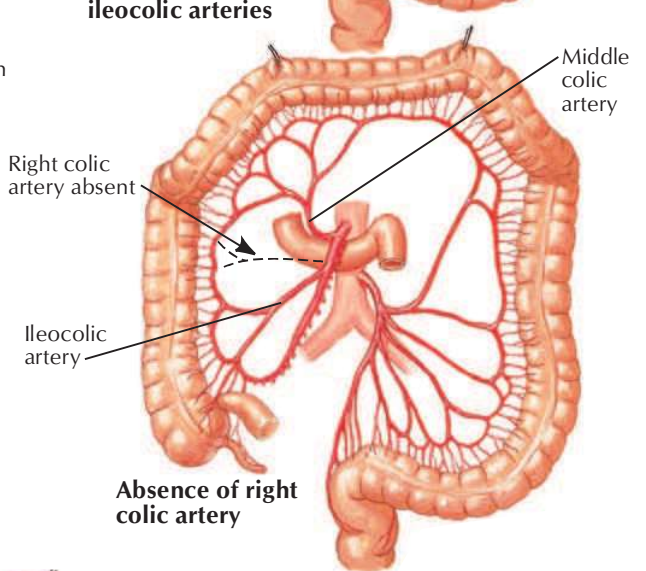
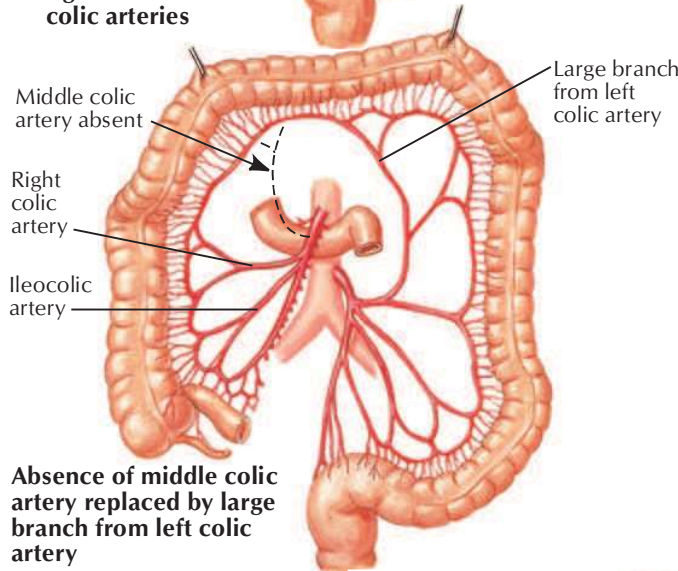
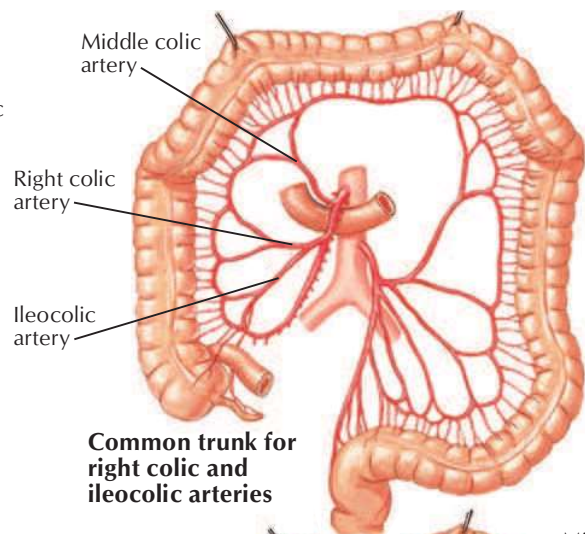
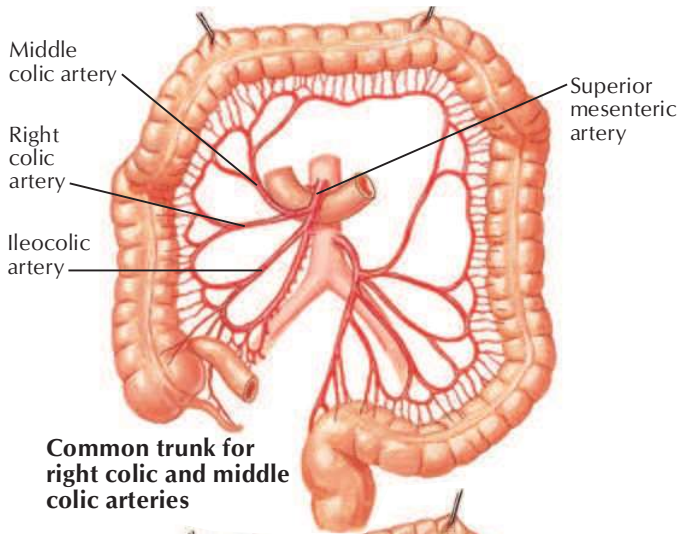
Complete celiac trunk
Hepatomesenteric trunk
(Note accessory left gastric artery from left hepatic)

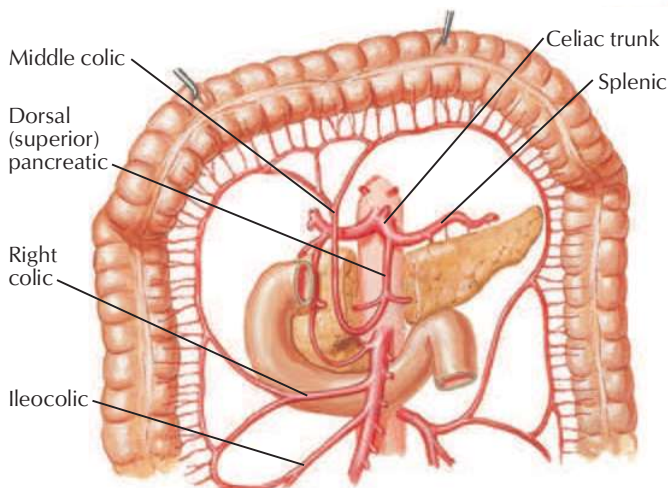
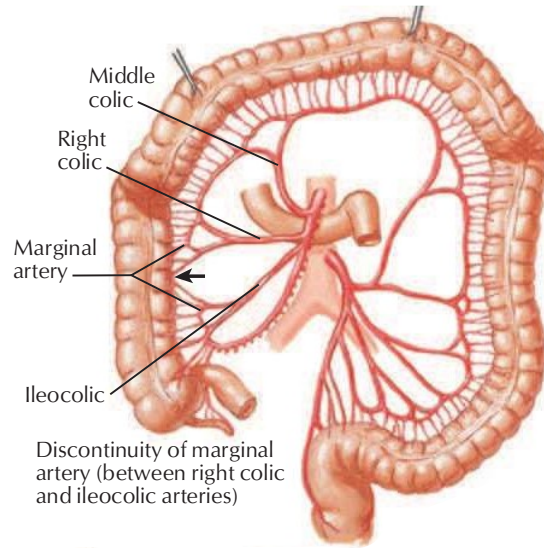


Right gastroepiploic (gastrointestinal) artery takes origin from superior mesenteric (note accessory left hepatic artery from left gastric)

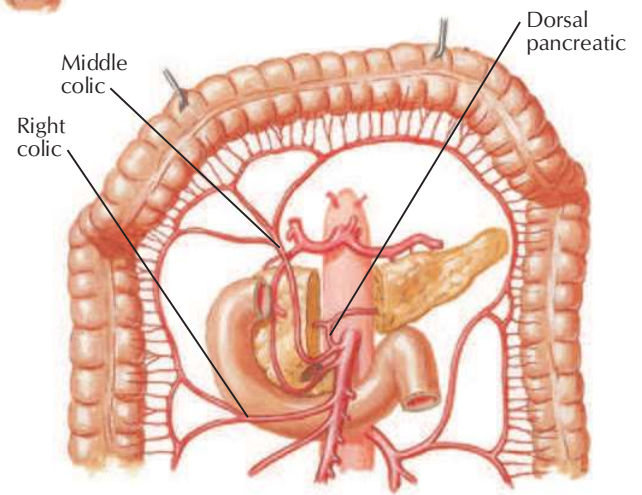
F. Netter M.D.

Variations in Colic Arteries

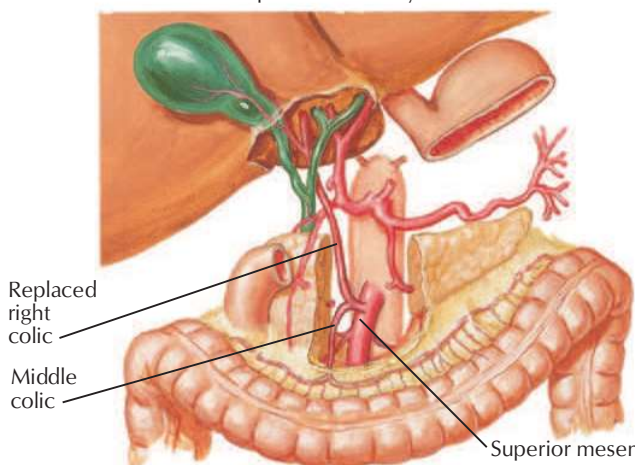




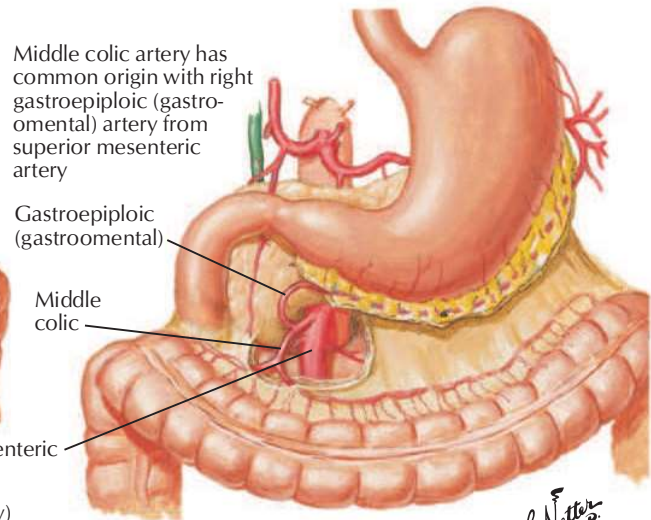
Middle colic artery originates from celiac trunk via dorsal pancreatic artery



Middle colic artery gives origin to dorsal pancreatic artery

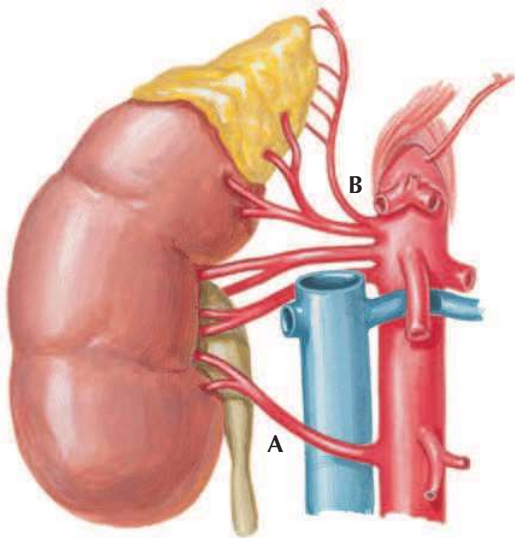


Middle colic artery originates from replaced right hepatic artery (from superior mesenteric artery)



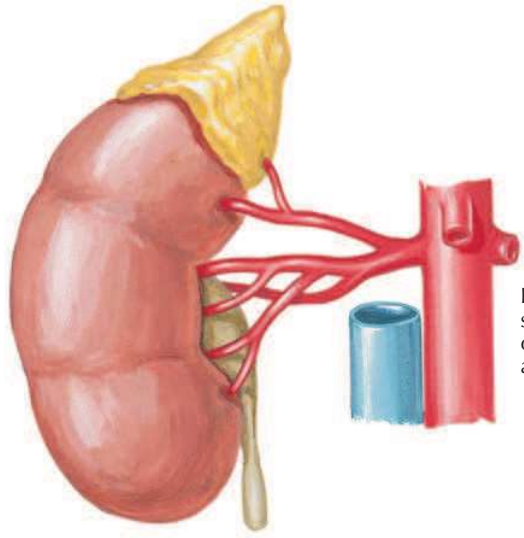
Middle colic artery has common origin with right gastroepiploic (gastro-omental) artery from superior mesenteric artery

F. Netter M.D.

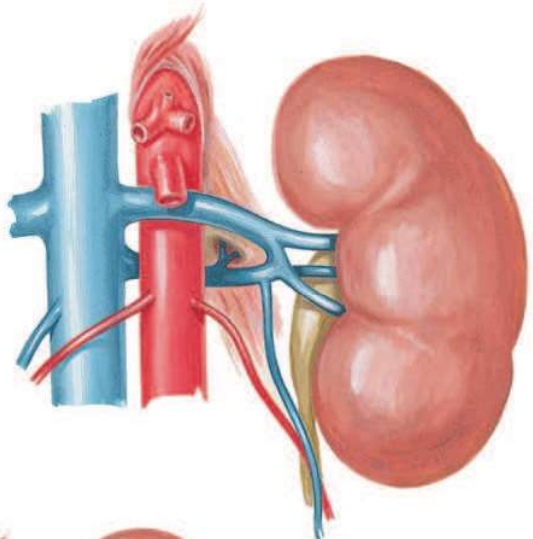


A Low accessory right renal artery may pass anterior to inferior vena cava instead of posterior to it

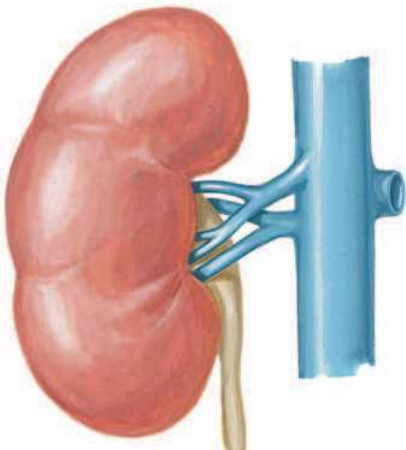
B Inferior phrenic artery with superior suprarenal arteries may arise from renal artery (middle suprarenal artery absent)



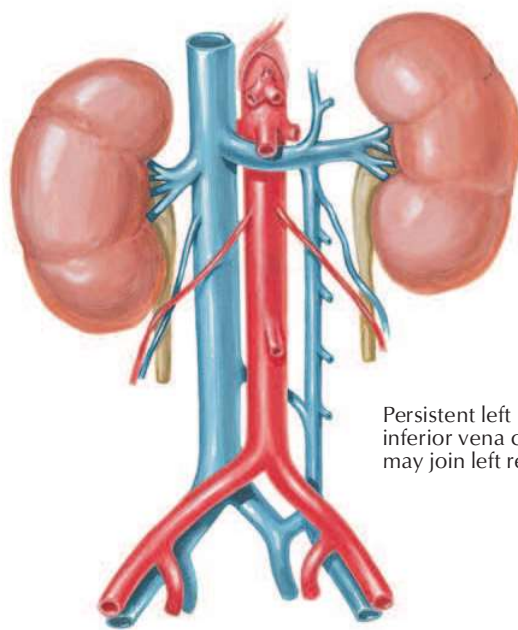
Proximal subdivision of renal artery



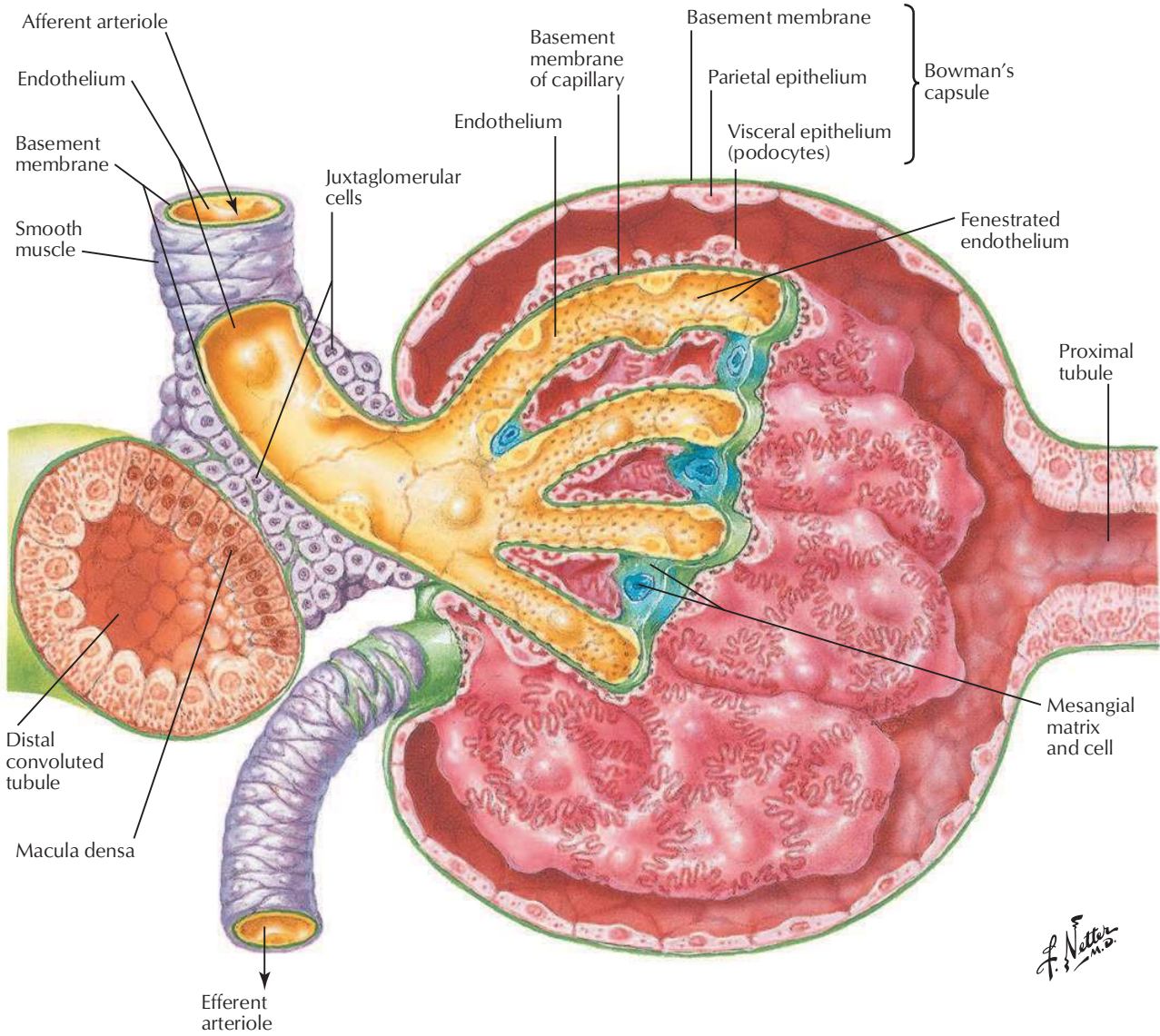
Double left renal vein may form ring around abdominal aorta



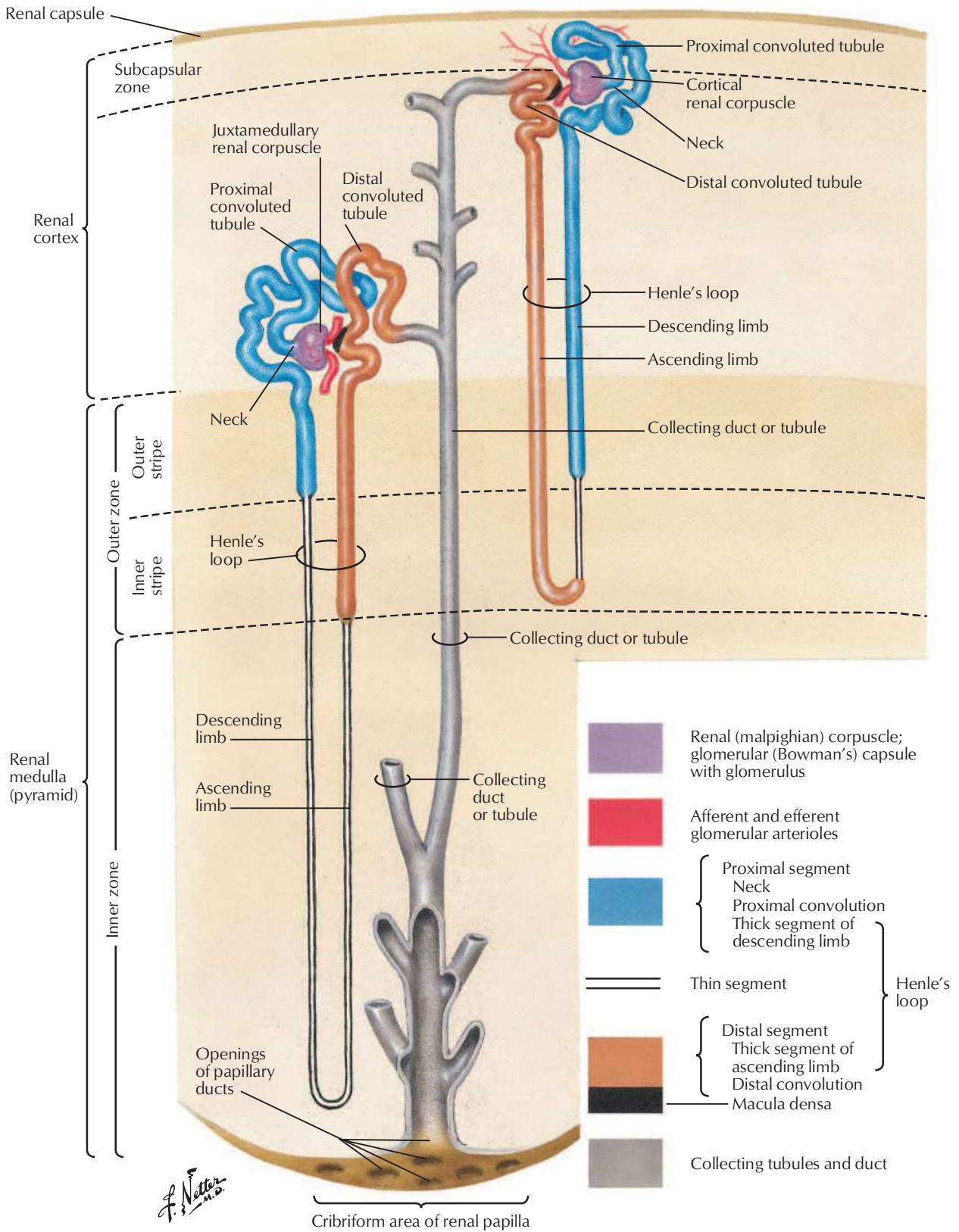
Multiple renal veins

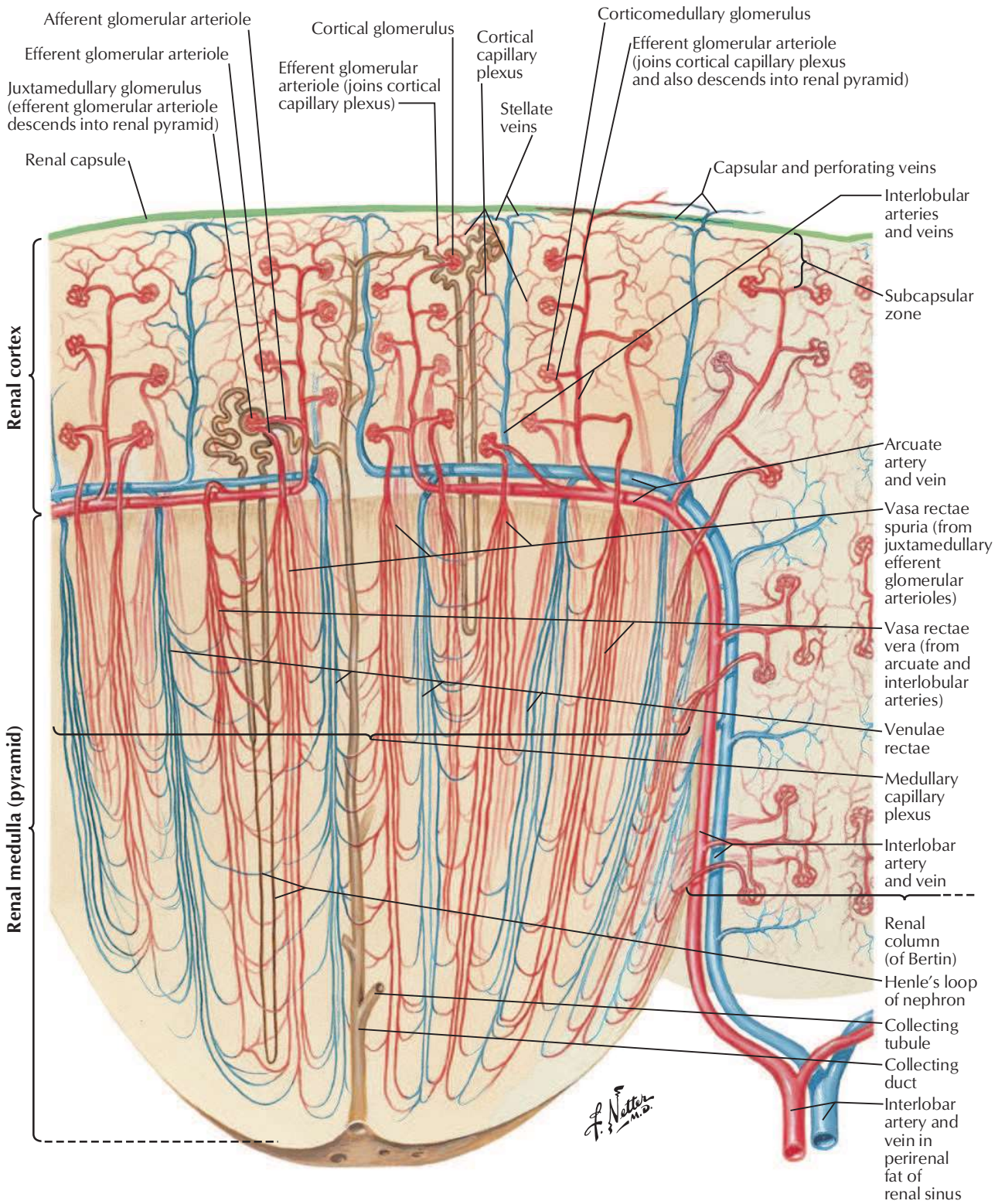


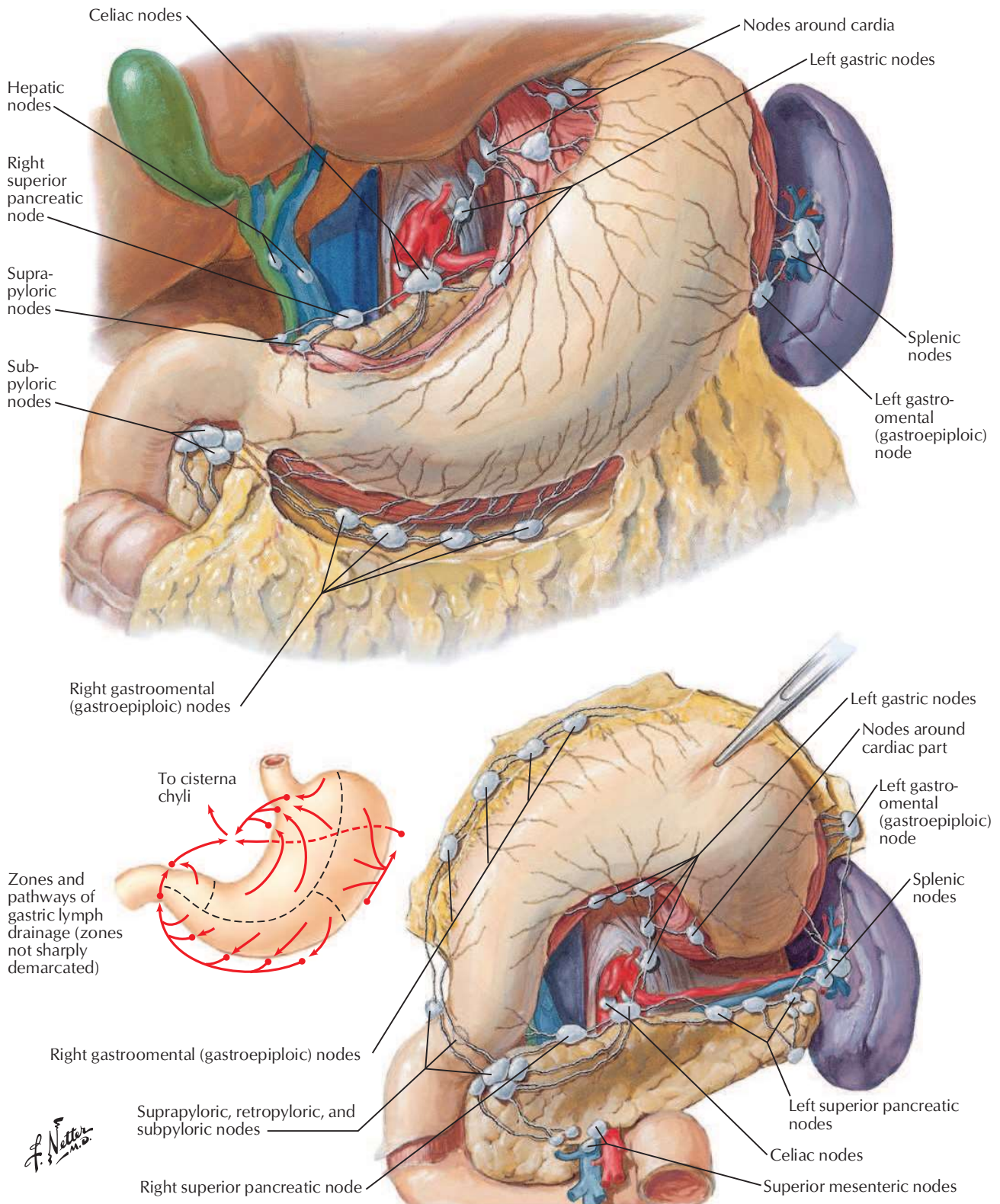
Persistent left inferior vena cava may join left renal vein

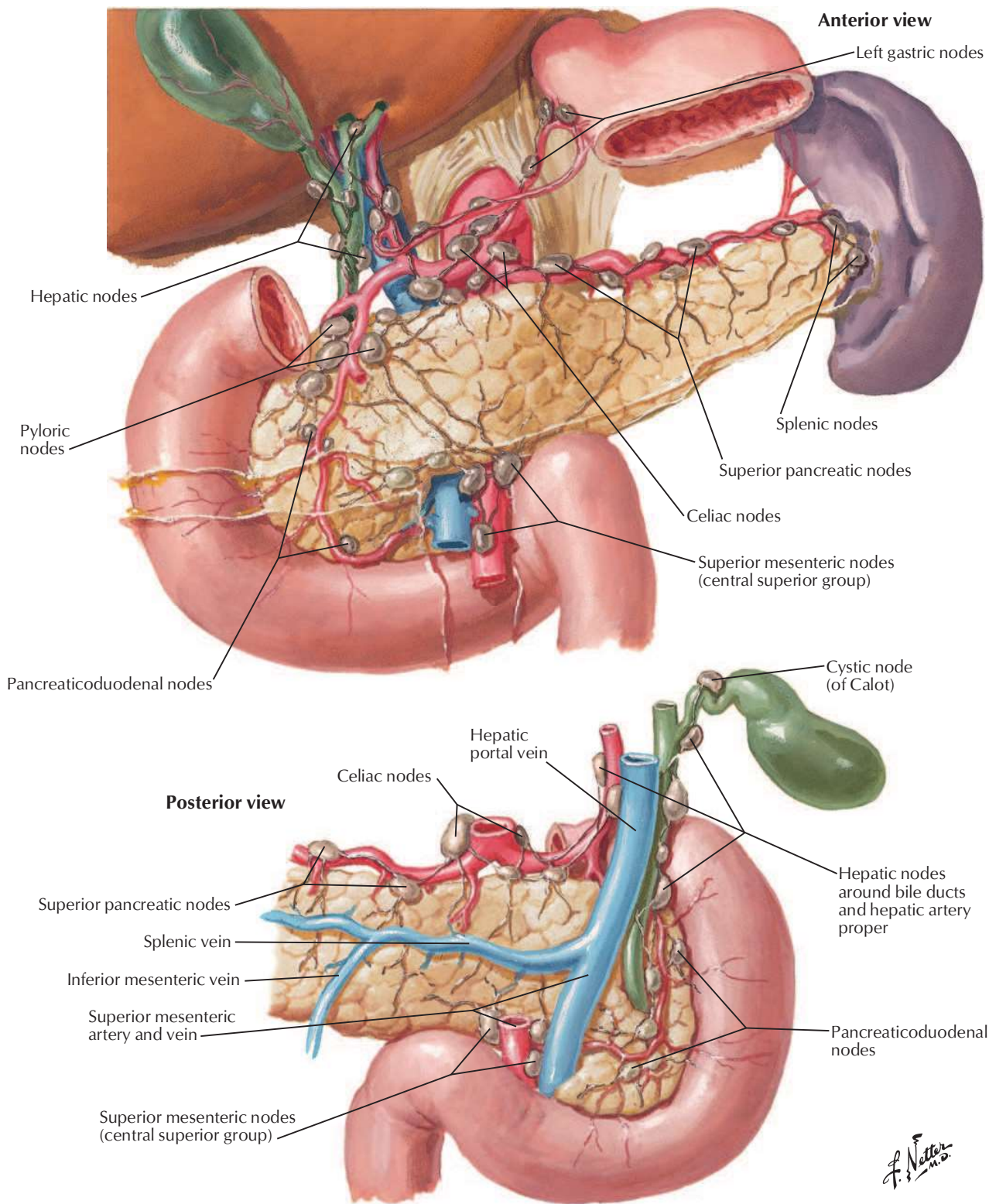


Nephron and Collecting Tubule: Schema

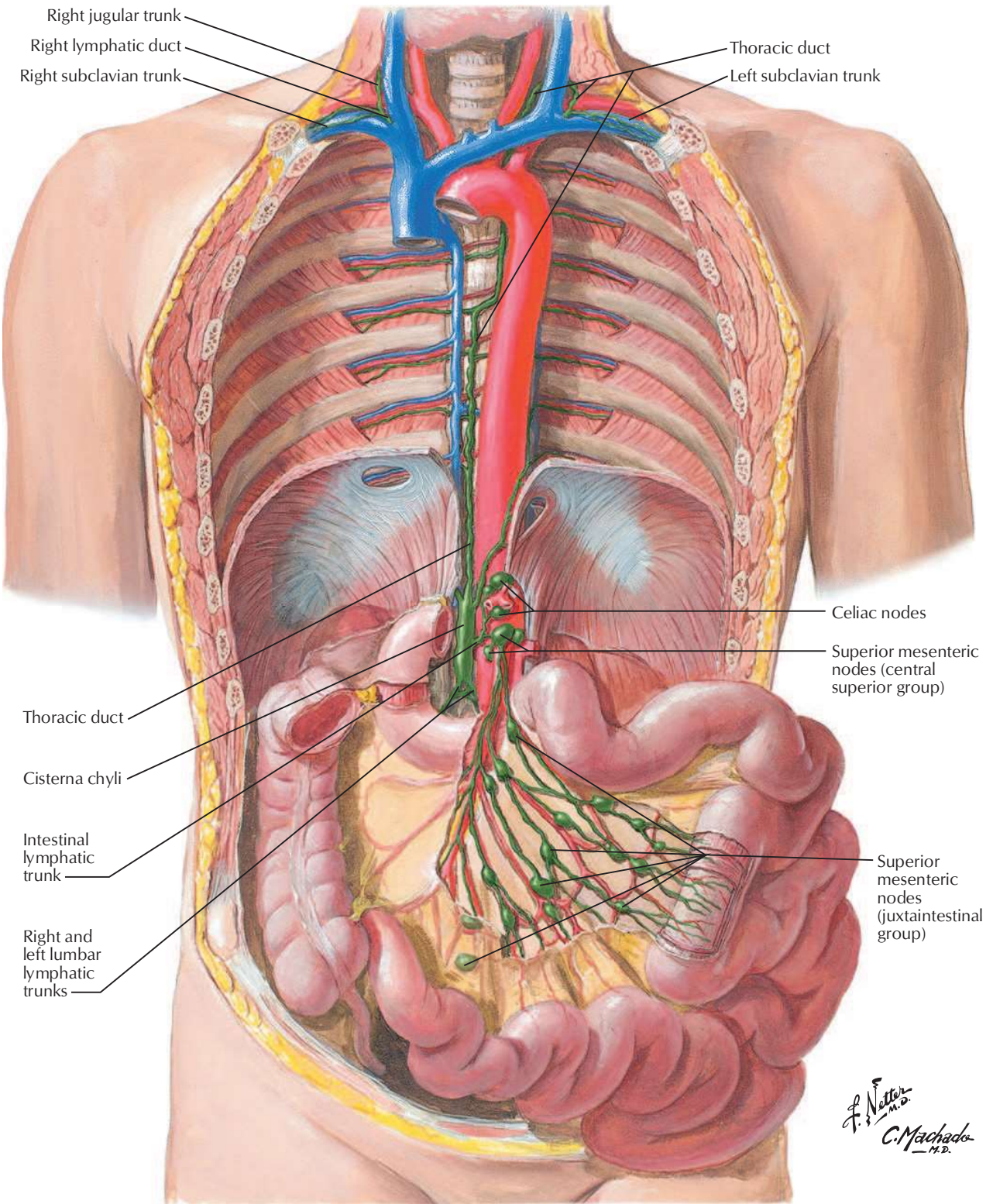


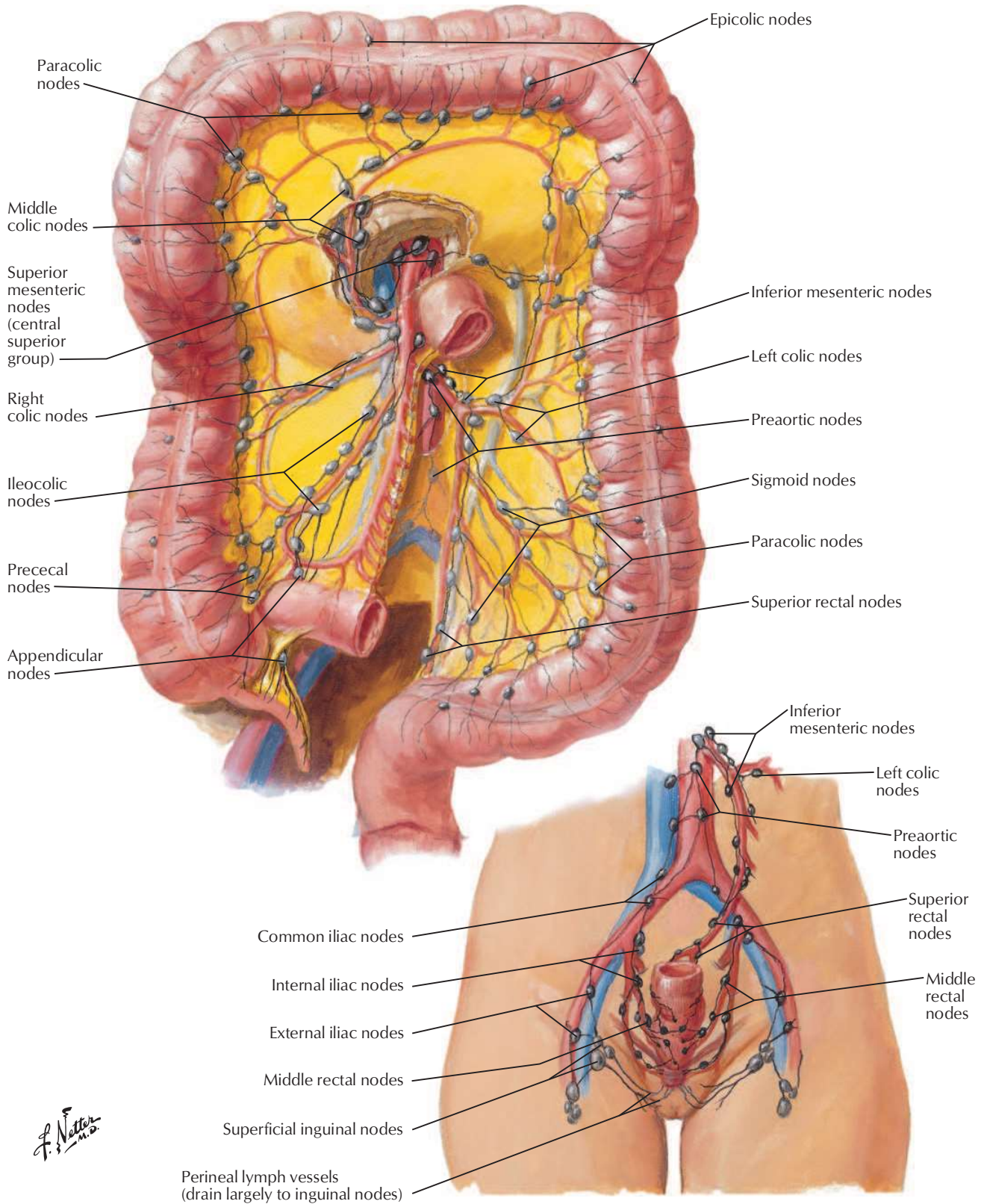




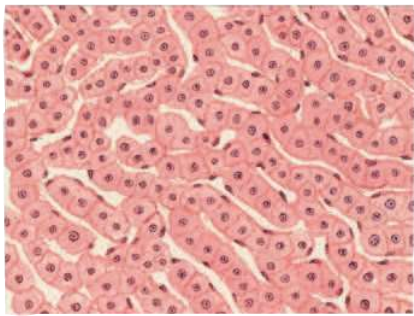


Lymph Vessels and Nodes of Small Intestine



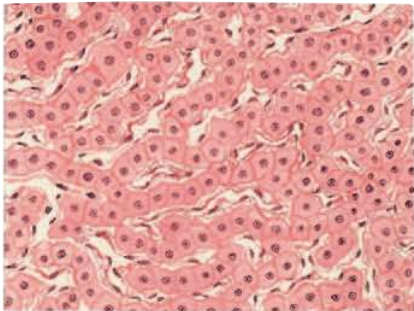


F. Netter M.D.

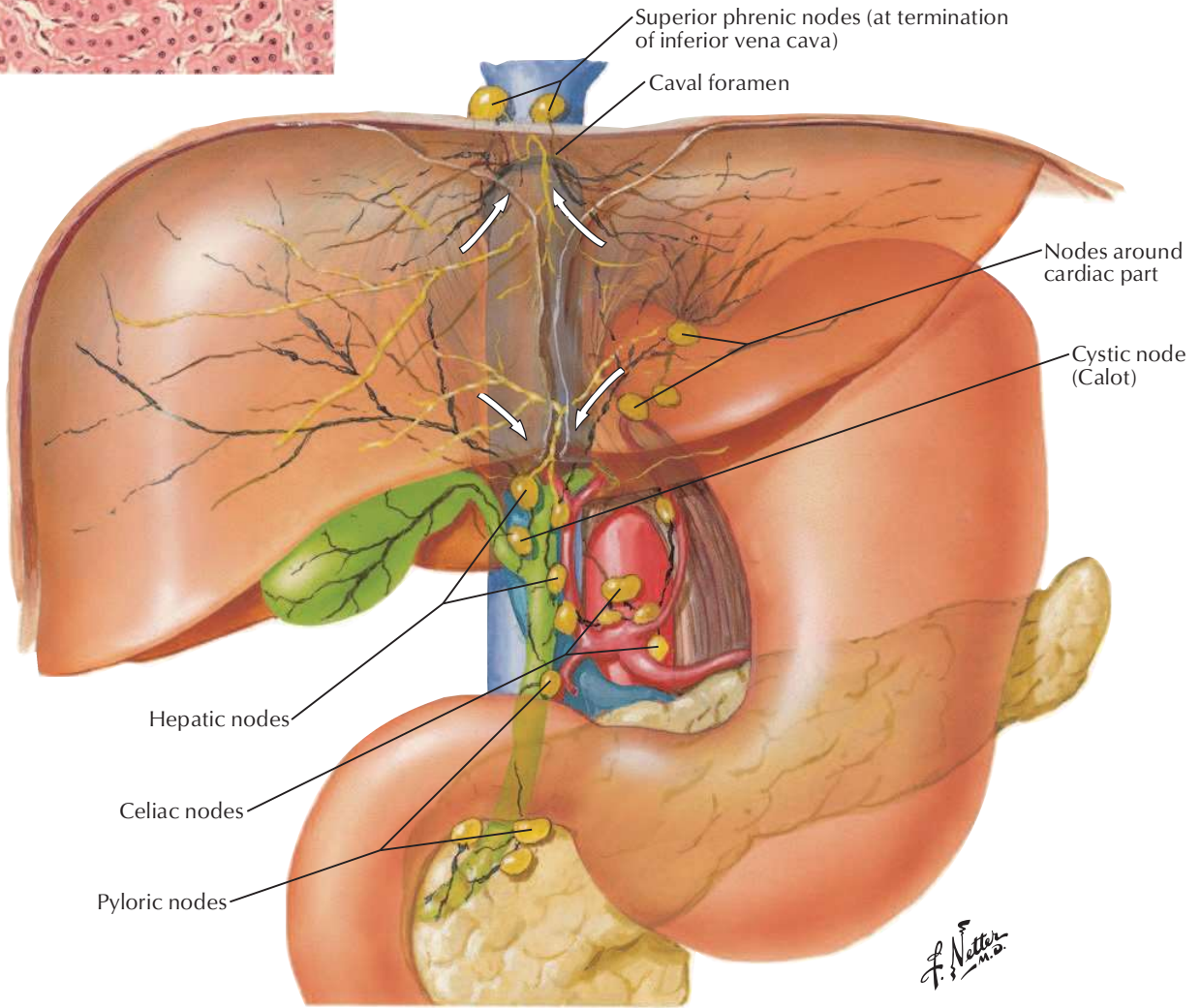
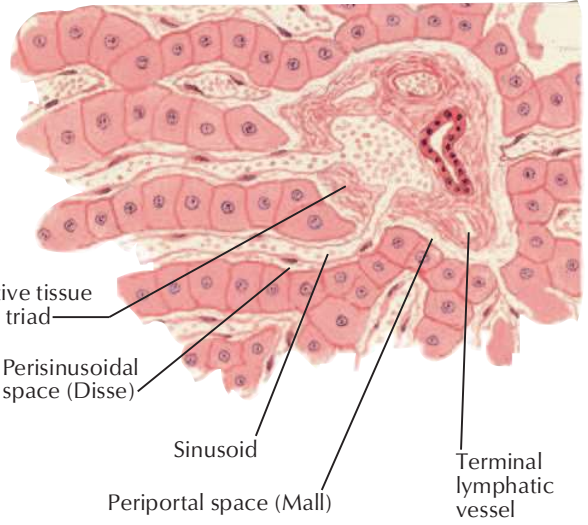


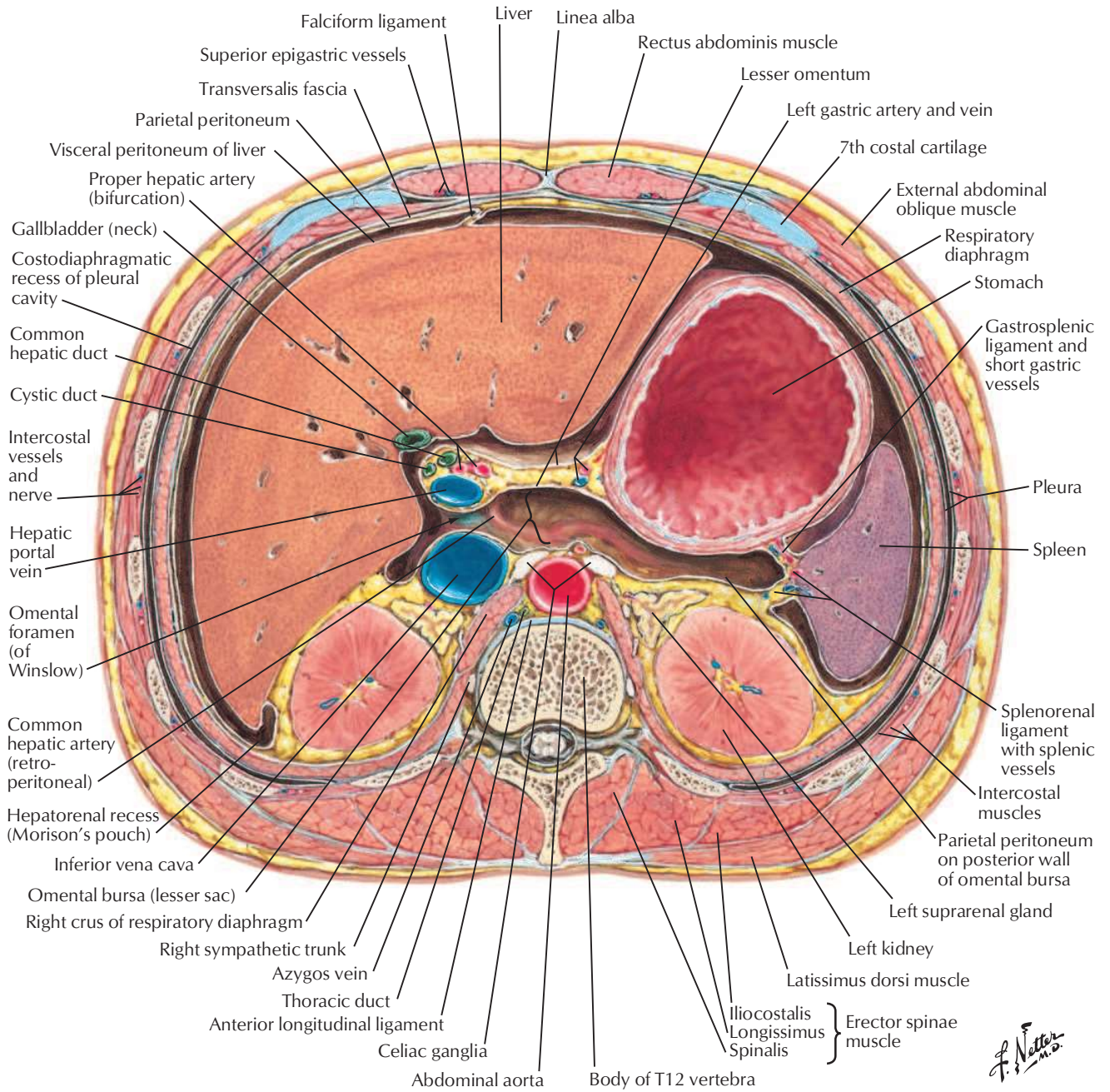
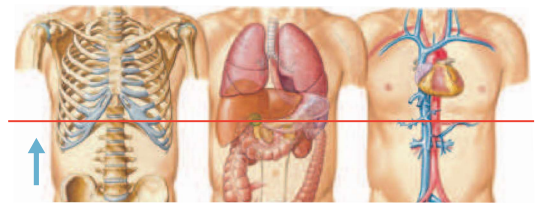
Low-power sections of liver

Perisinusoidal spaces (Disse) very narrow or obliterated

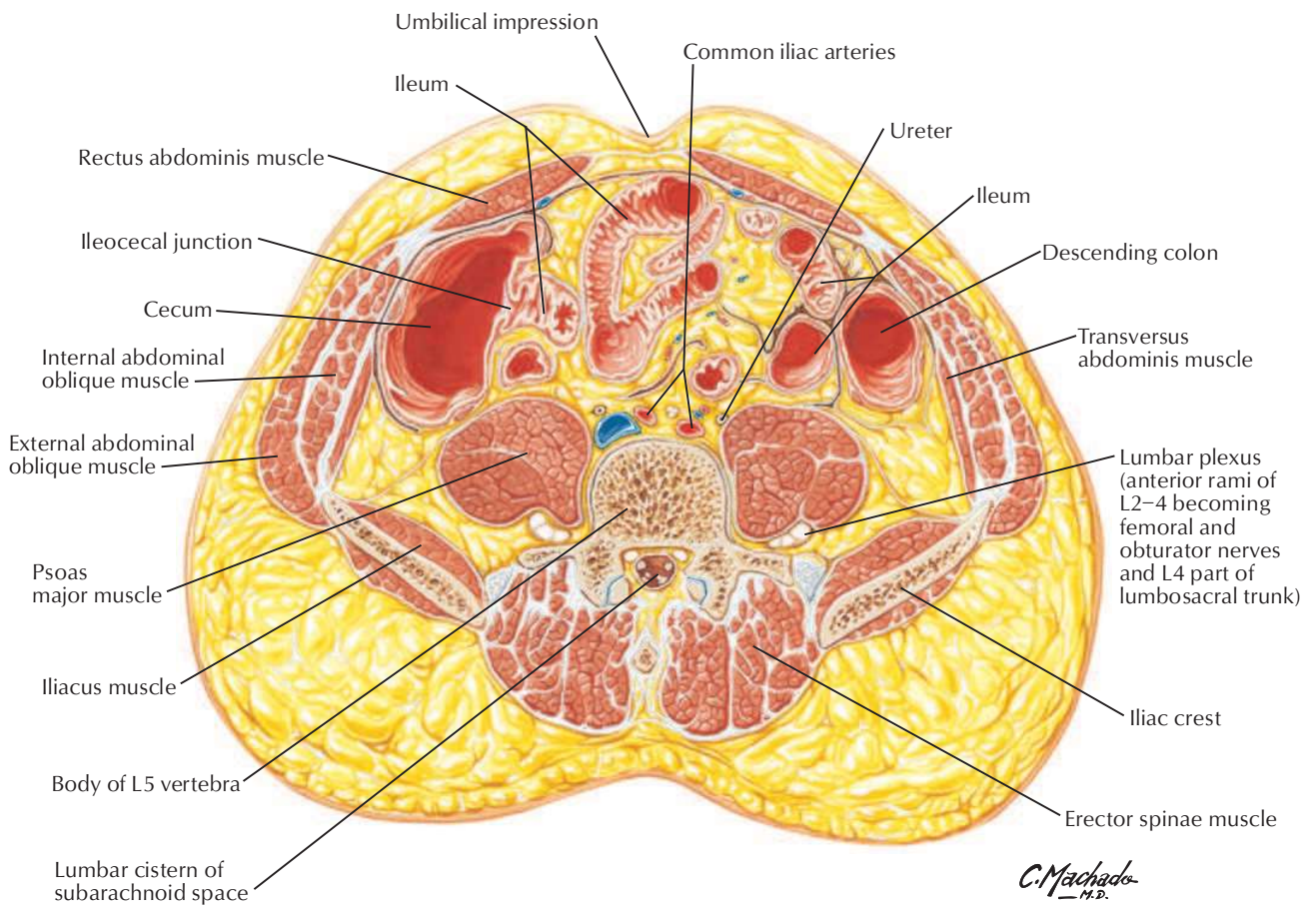
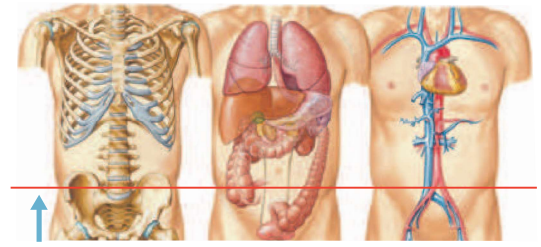


Perisinusoidal spaces (Disse) markedly widened

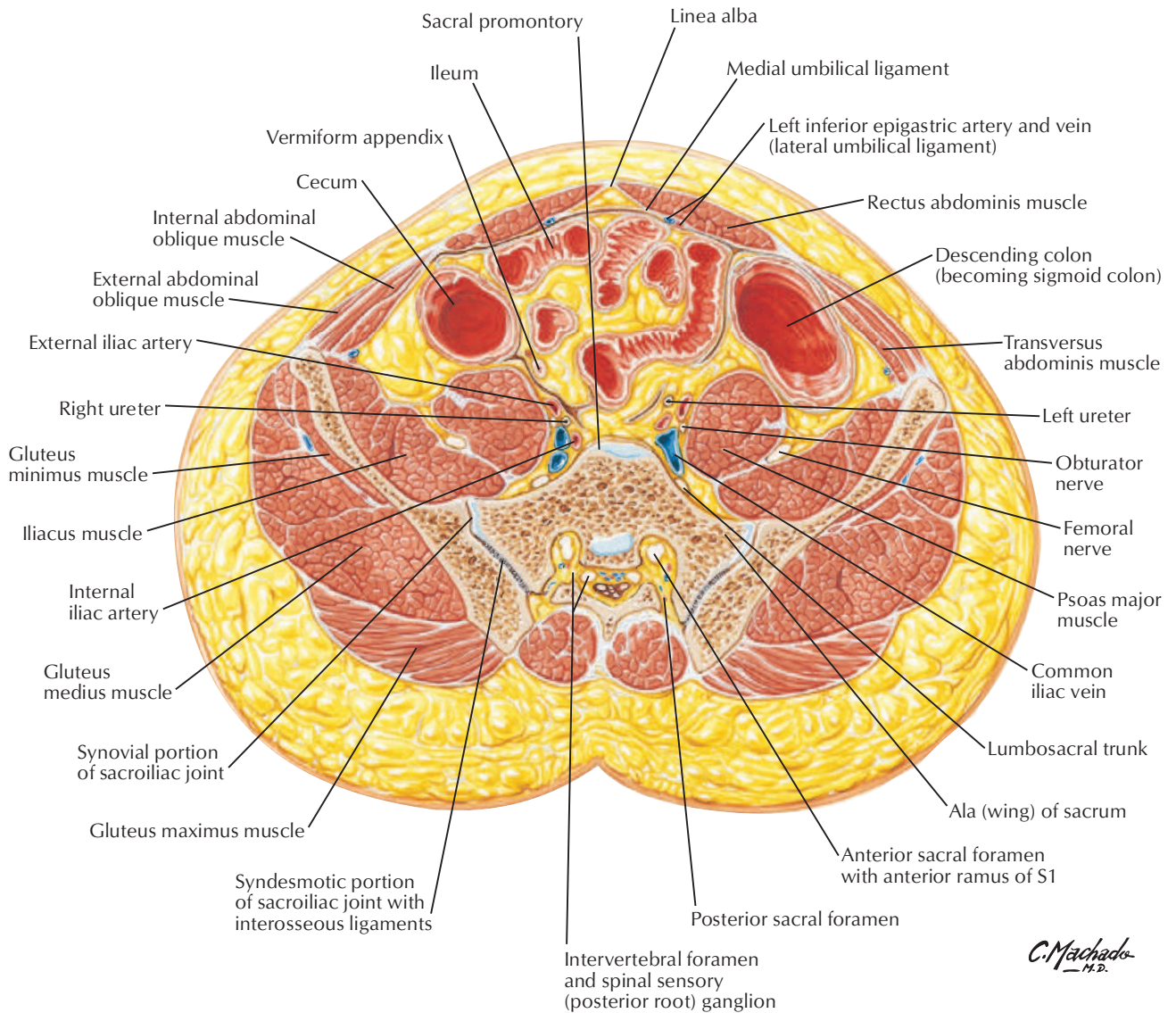
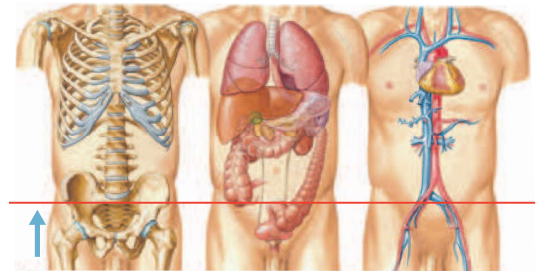




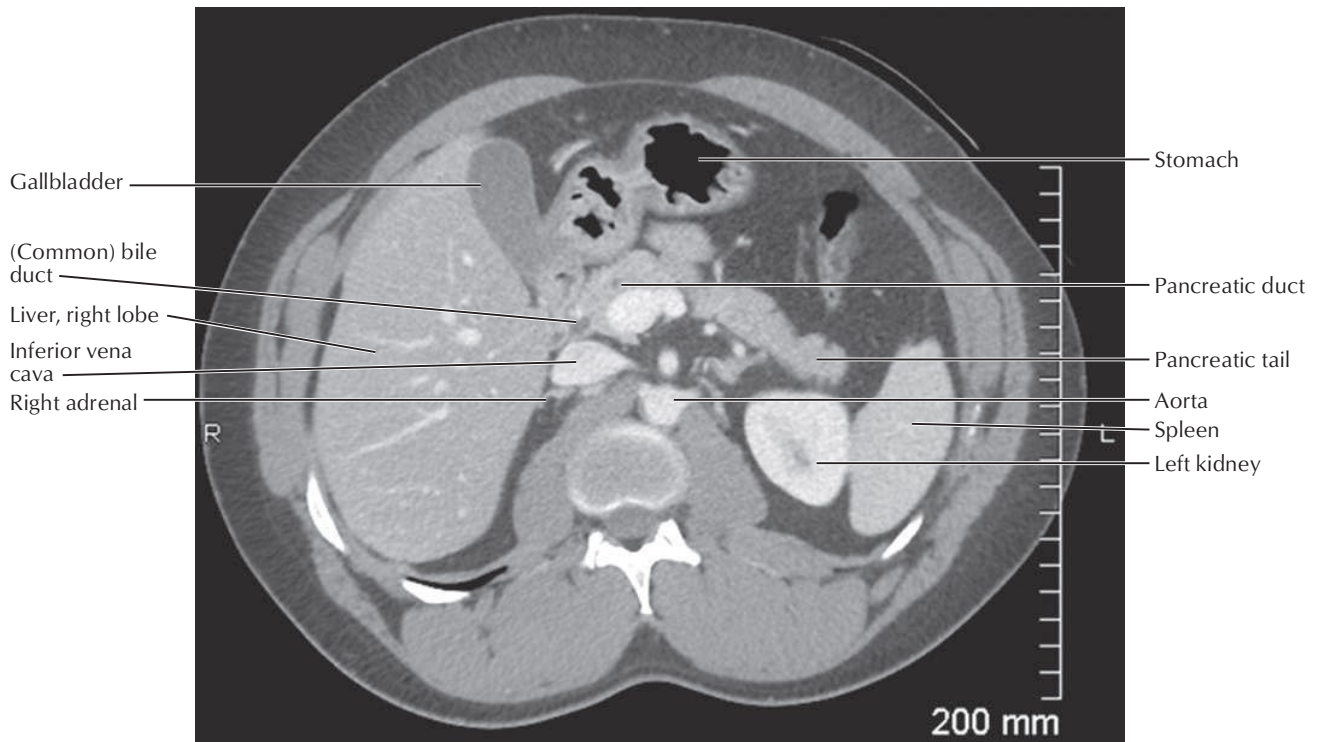
Transverse Section of Abdomen: Level of L5, Near Transtubercular Plane



C. Machado
—M.D.



Axial CT image enhanced with intravenous contrast

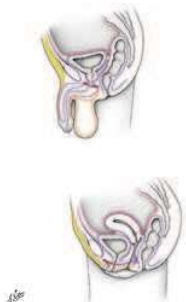

PELVIS AND PERINEUM

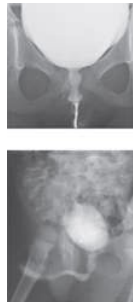
6

Surface Anatomy	333	Testis, Epididymis, and Ductus Deferens	372
Bones and Ligaments	334-338	Rectum	373-378
Pelvic Floor and Contents	339-349	Regional Scan	379
Urinary Bladder	350-352	Vasculature	380-390
Uterus, Vagina, and Supporting Structures	353-357	Innervation	391-399
Perineum and External Genitalia: Female	358-361	Cross-Sectional Anatomy Structures With High Clinical Significance	400-401
Perineum and External Genitalia: Male	362-369	Muscle Tables	Tables 6.1-6.2
Homologues of Genitalia	370-371	Electronic Bonus Plates	Tables 6.3-6.4 BP88-BP98

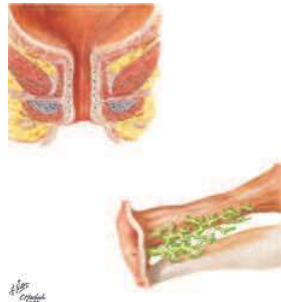
ELECTRONIC BONUS PLATES



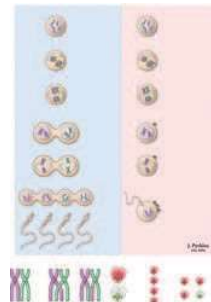
BP88 Fasciae of Male and Female Pelvis and Perineum



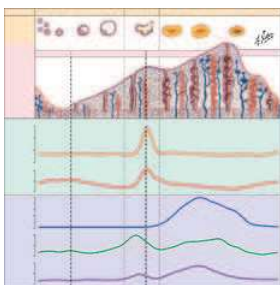
BP89 Male and Female Cystourethrograms



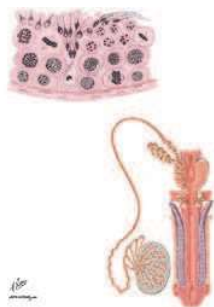BP90 Female Urethra



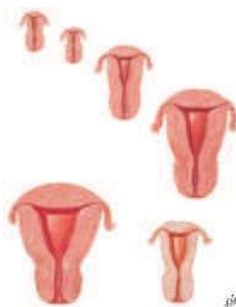BP91 Genetics of Reproduction



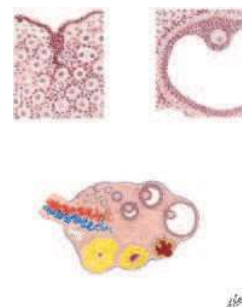
BP92 Menstrual Cycle



BP93 Testes

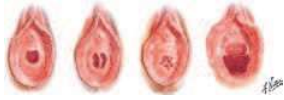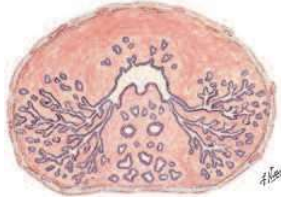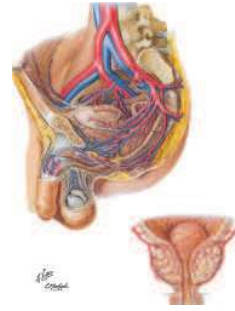


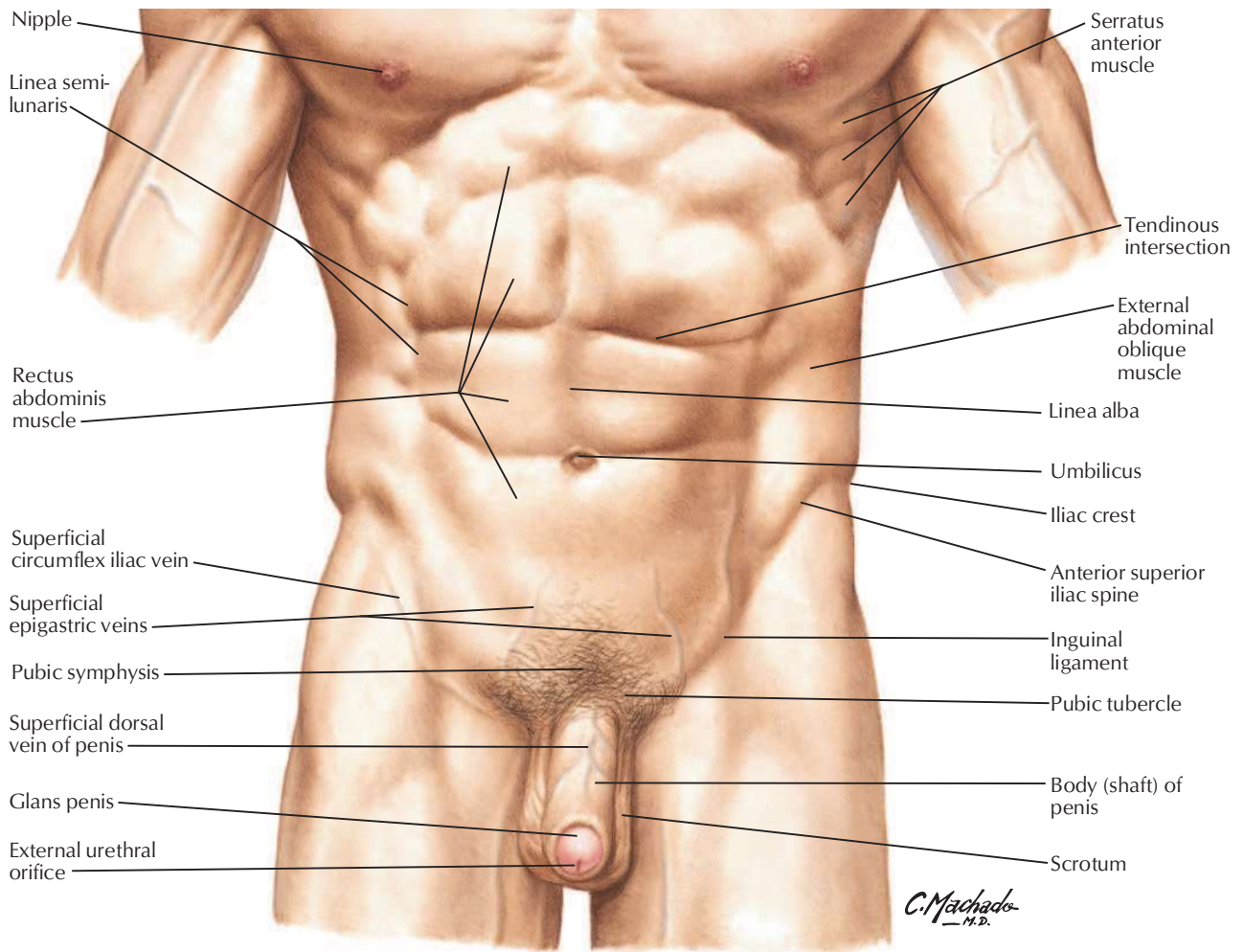
BP94 Uterine Development

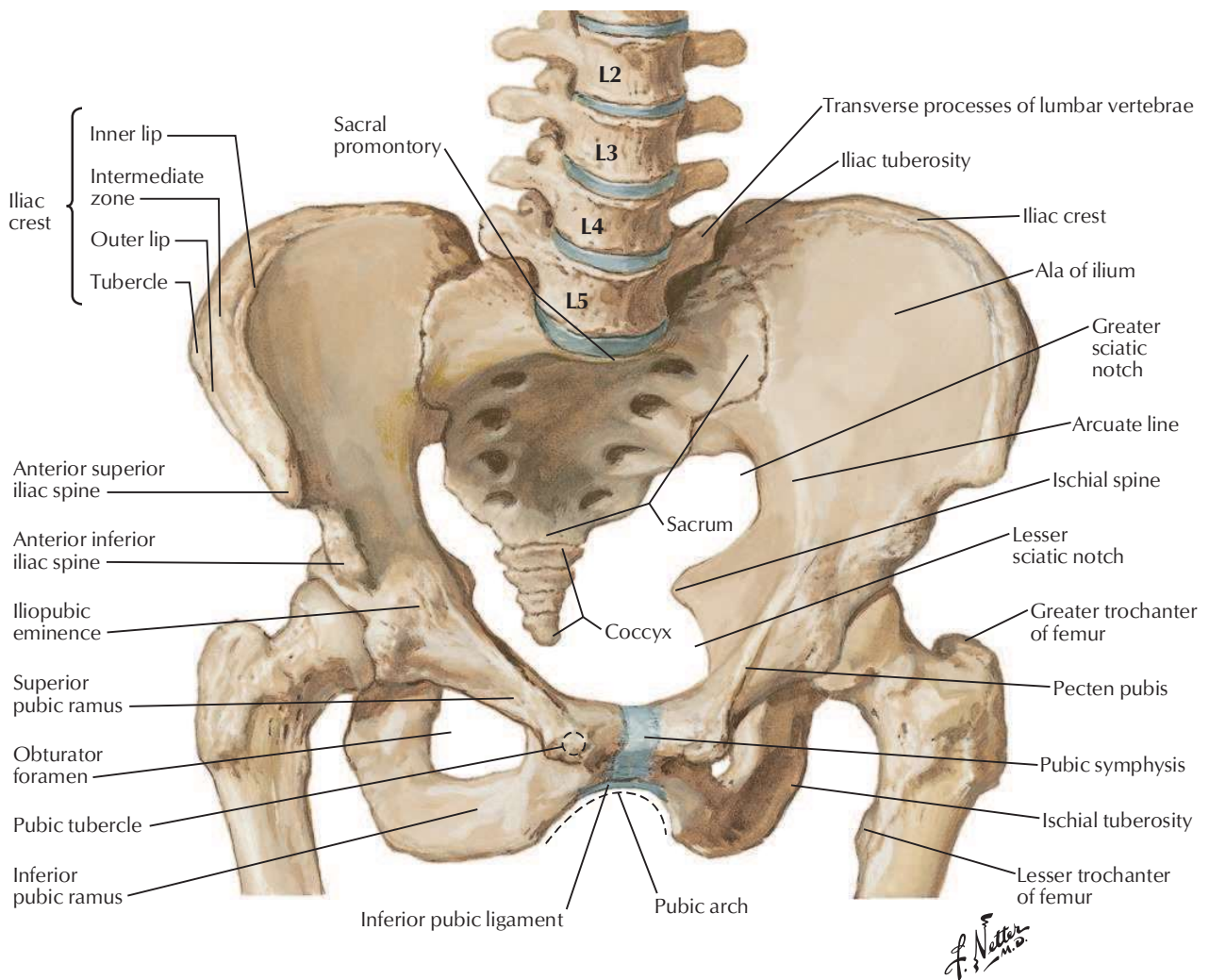


BP95 Ovary, Ova, and Follicles

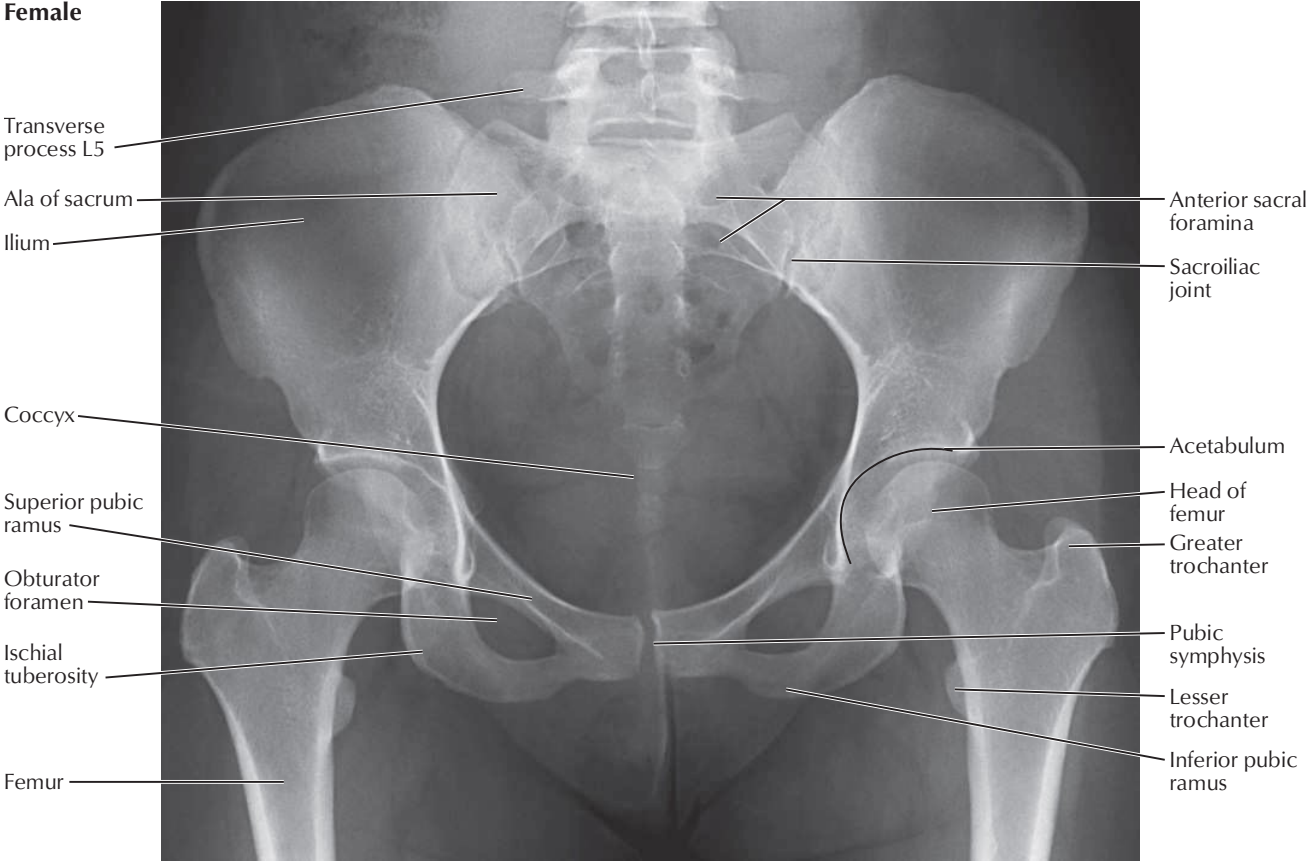
ELECTRONIC BONUS PLATES—*cont'd*

**BP96** Variations in Hymen**BP97** Cross Section Through Prostate**BP98** Arteries and Veins of Pelvis: Male

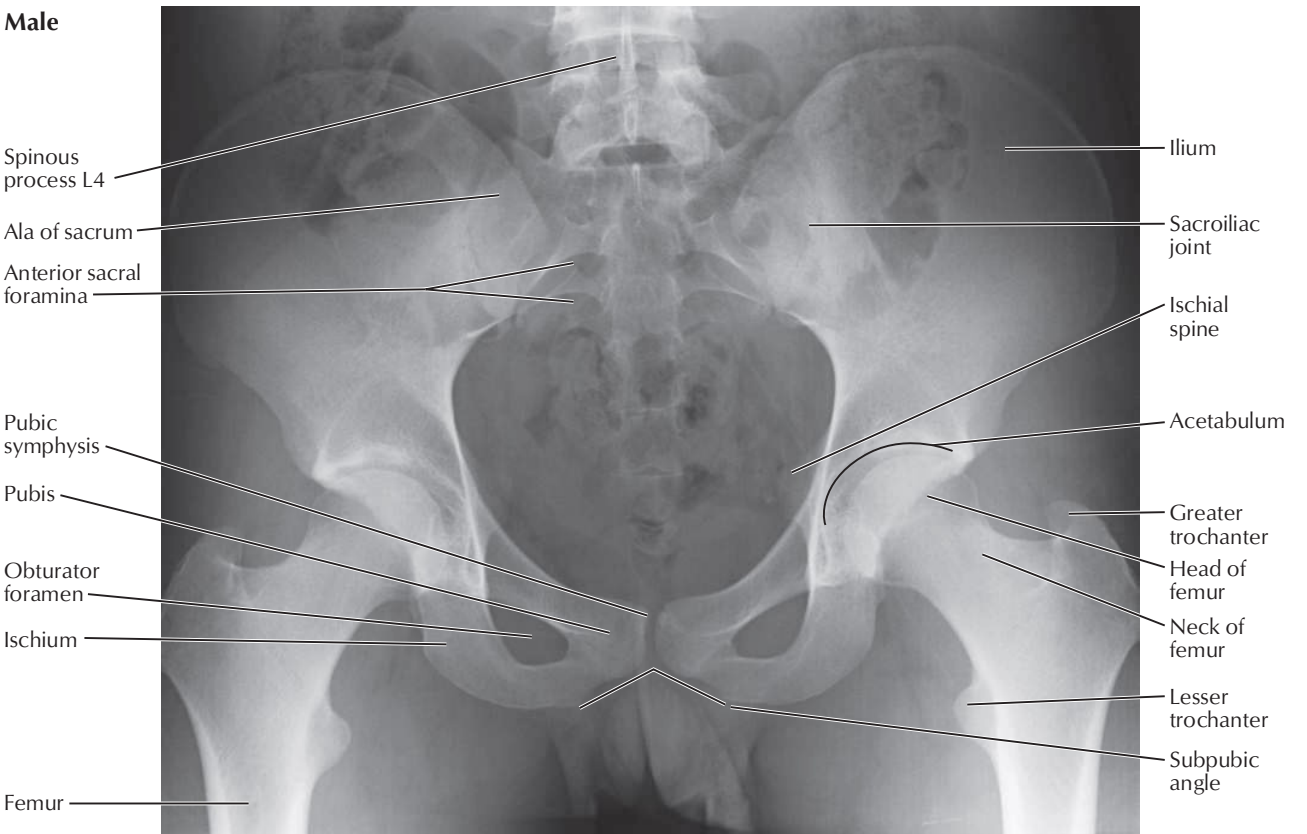


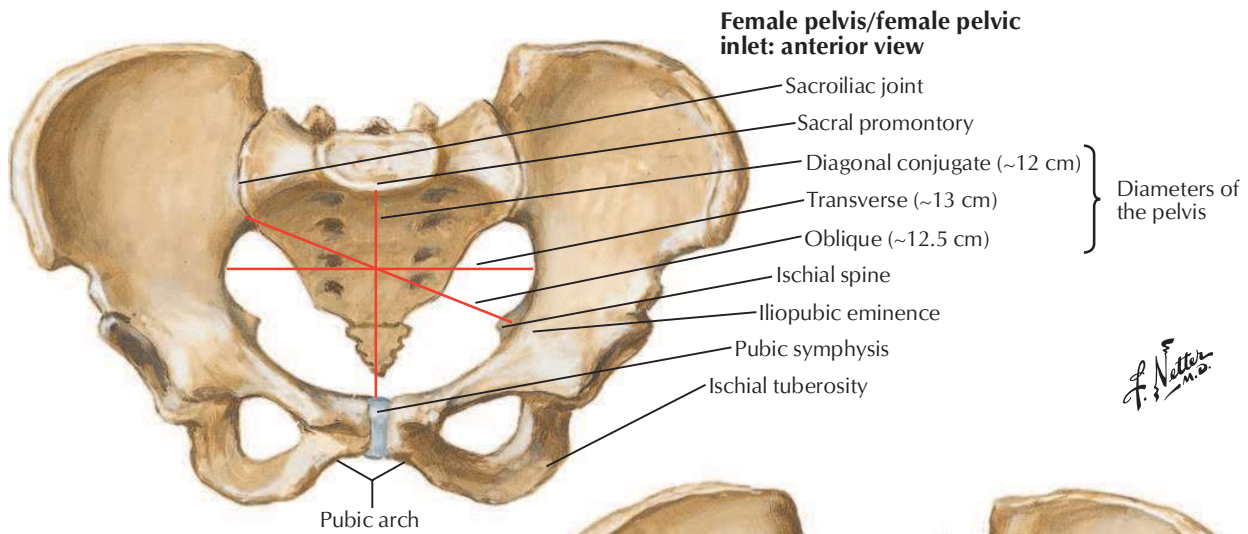


Female



Male

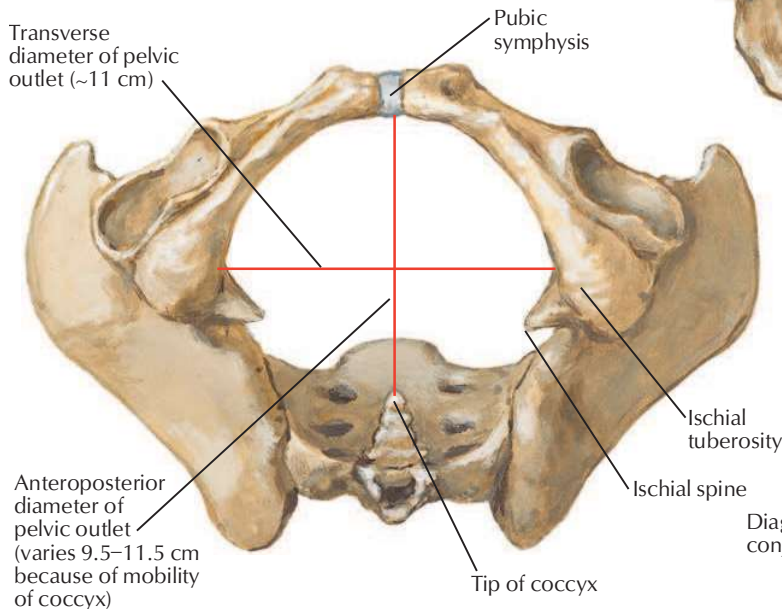
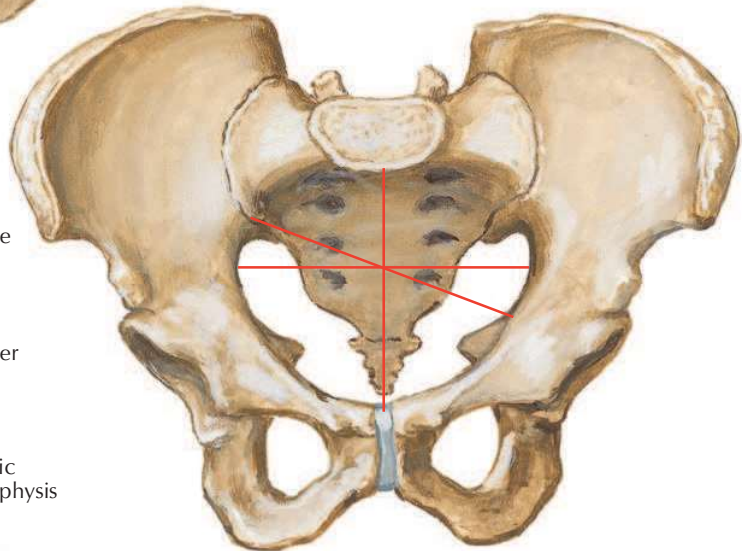




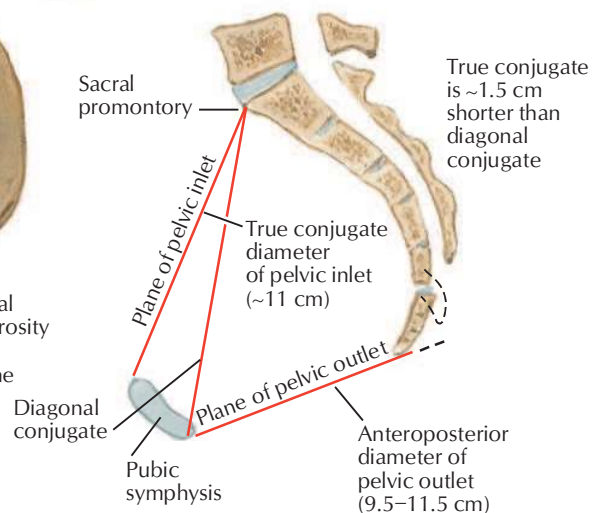
Male pelvis/male pelvic inlet: anterior view

Diagonal conjugate is only diameter of pelvic inlet that can be measured clinically

All measurements slightly shorter in relation to body size than in female
 Pelvic inlet oriented more anteroposteriorly than in female, where it tends to be transversely oval
 Pubic symphysis deeper (taller)
 Ischial tuberosities less far apart
 Iliac wings less flared

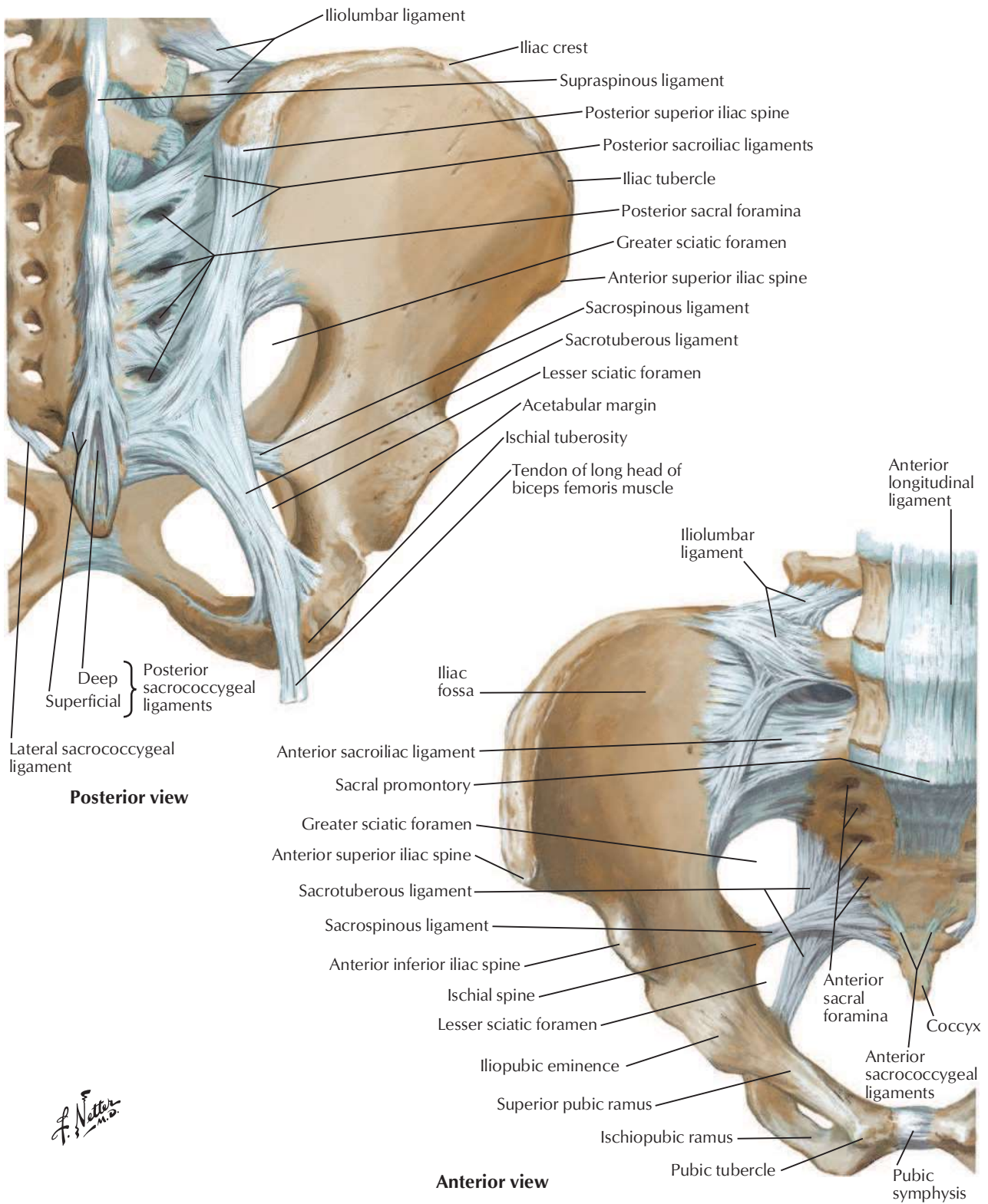


Female pelvis/female pelvic outlet: inferior view



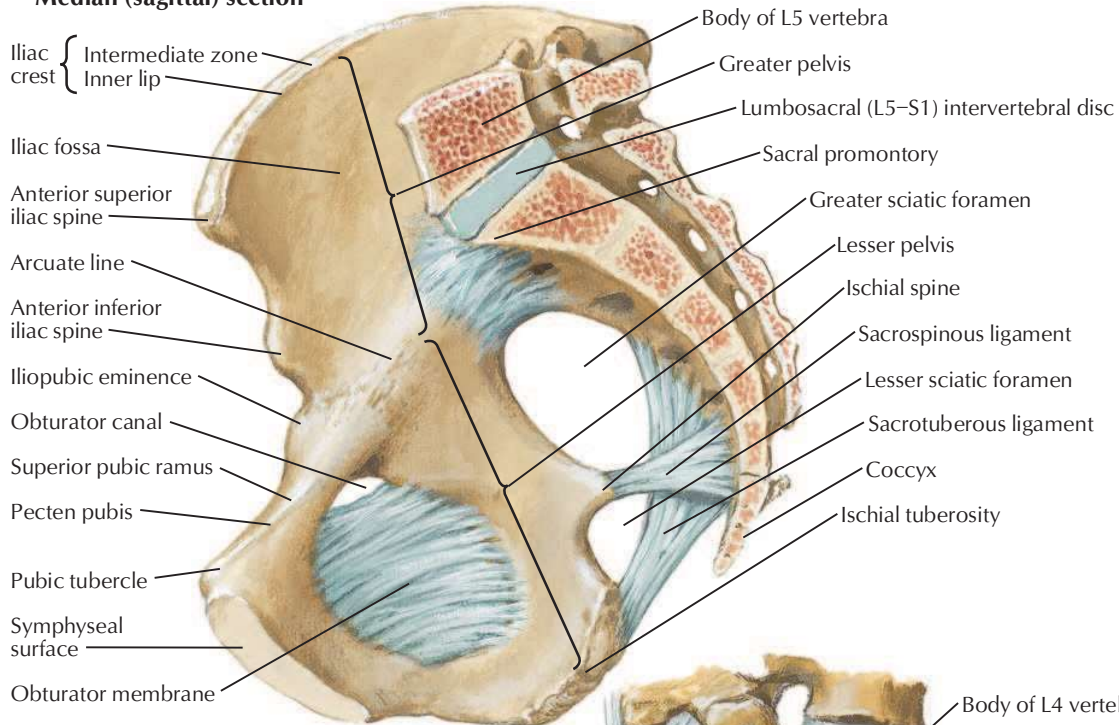
Transverse diameter is the widest distance of pelvic inlet

Female: sagittal section

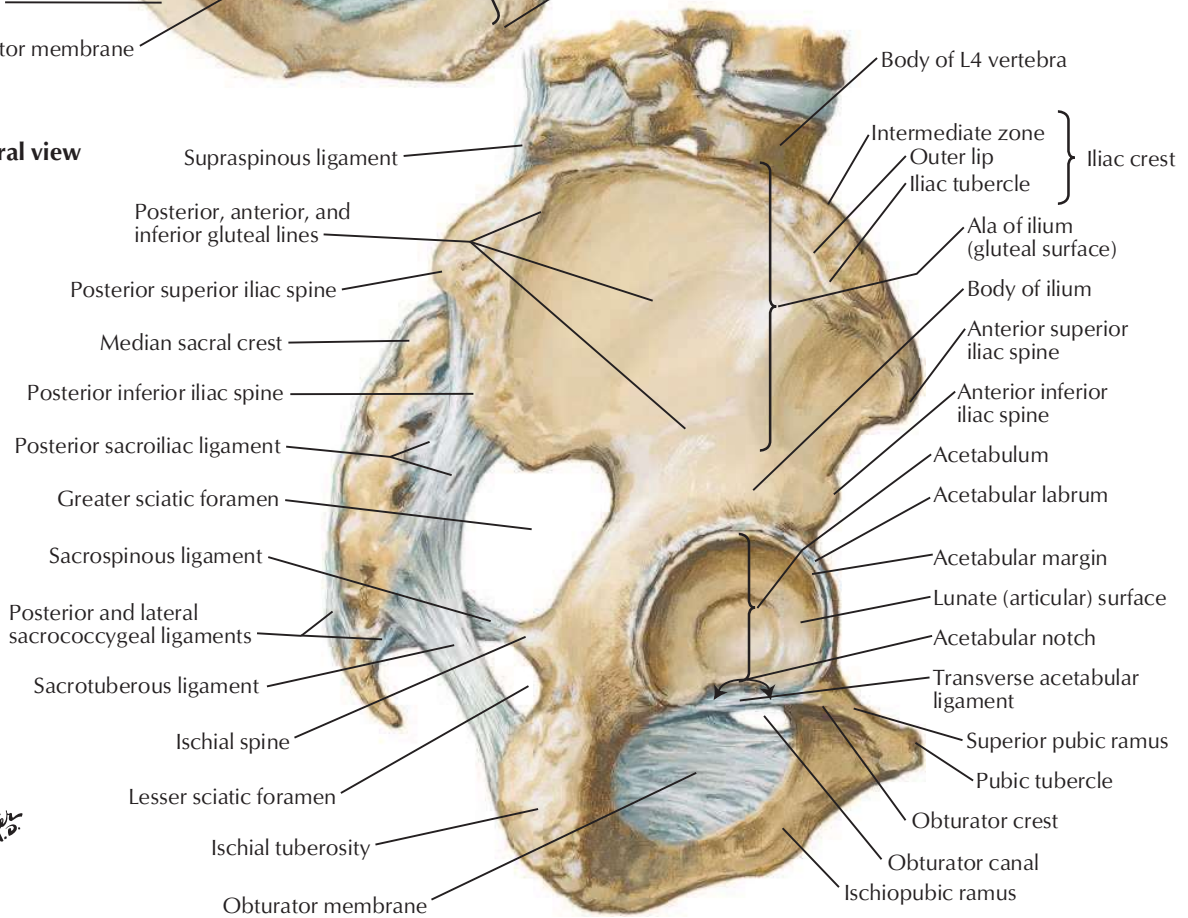


See also [Plate 167](#)

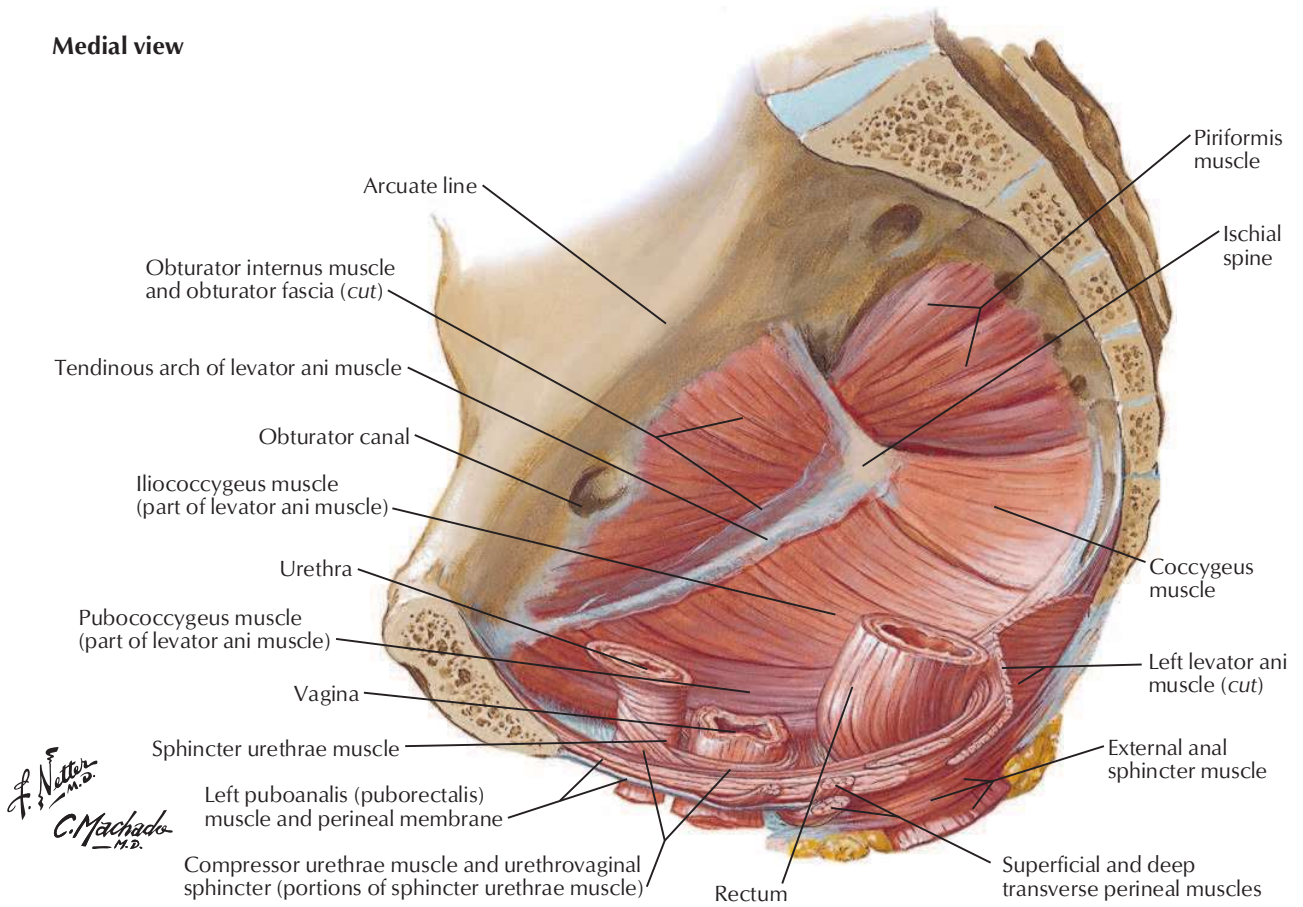
Median (sagittal) section



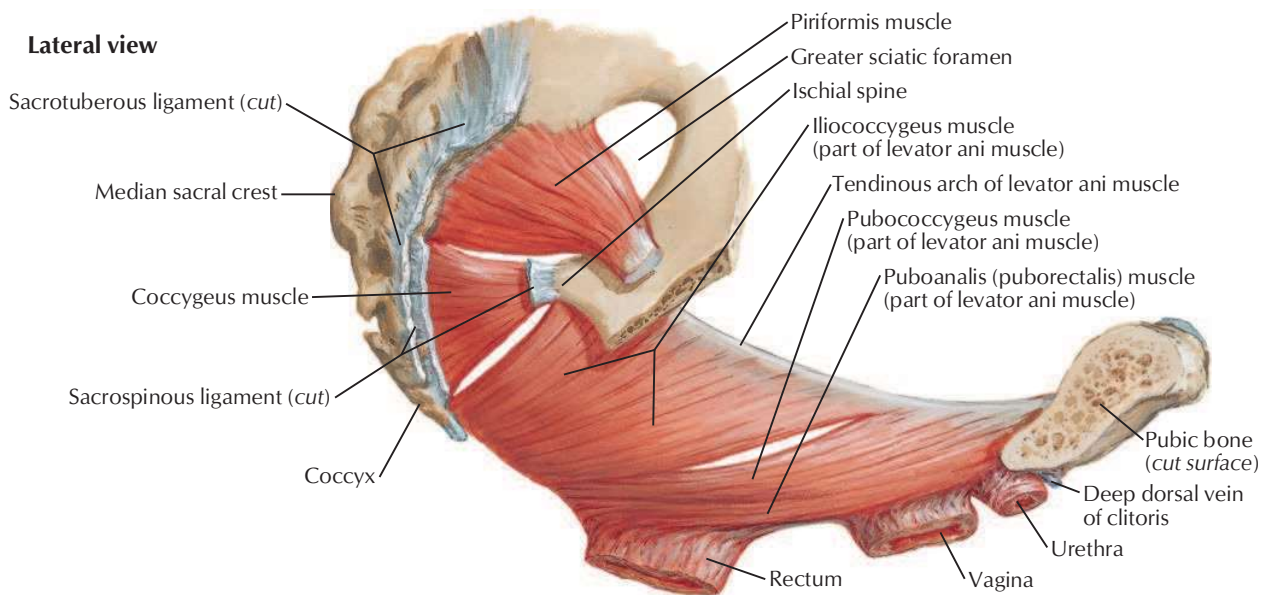
Lateral view



Medial view

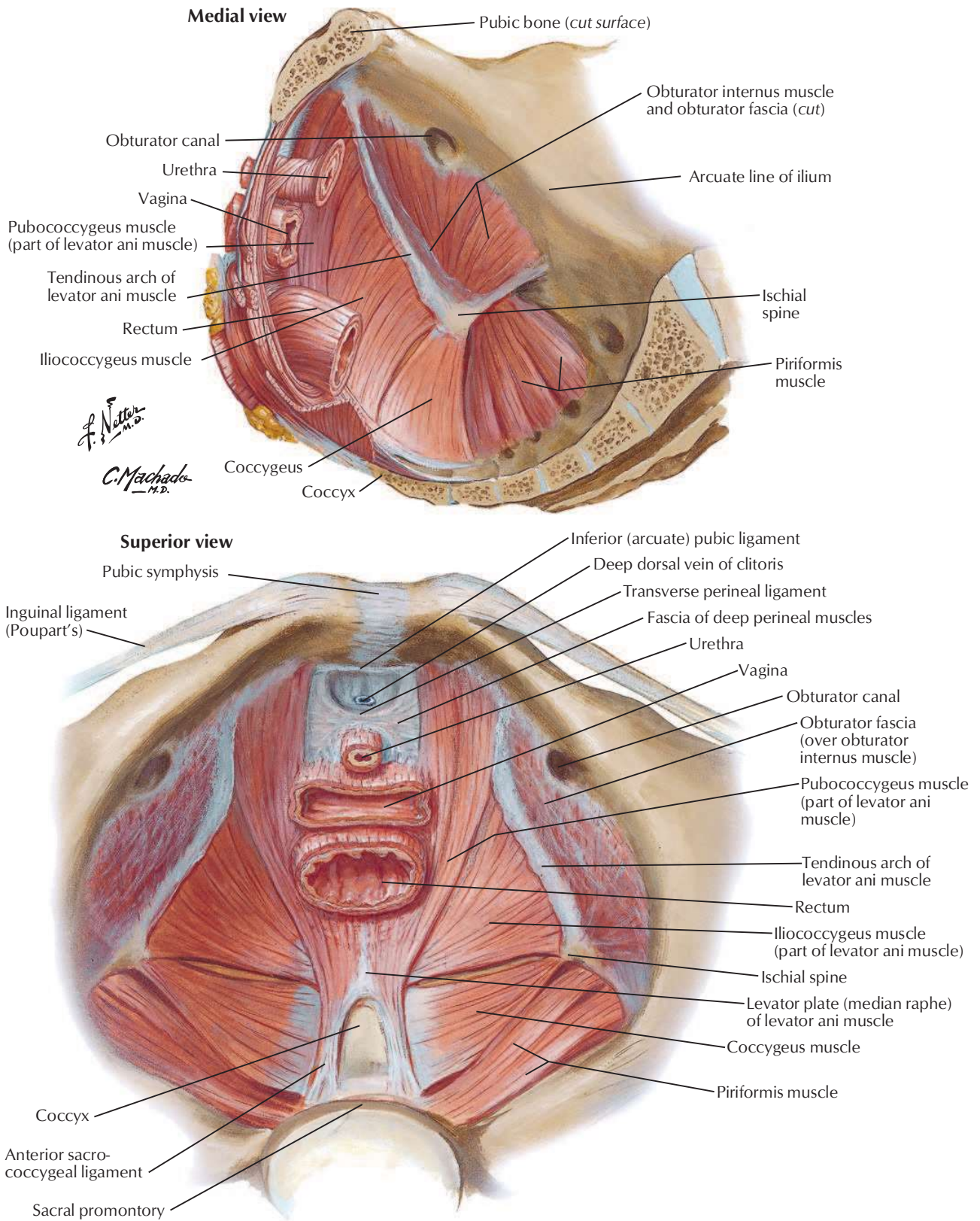


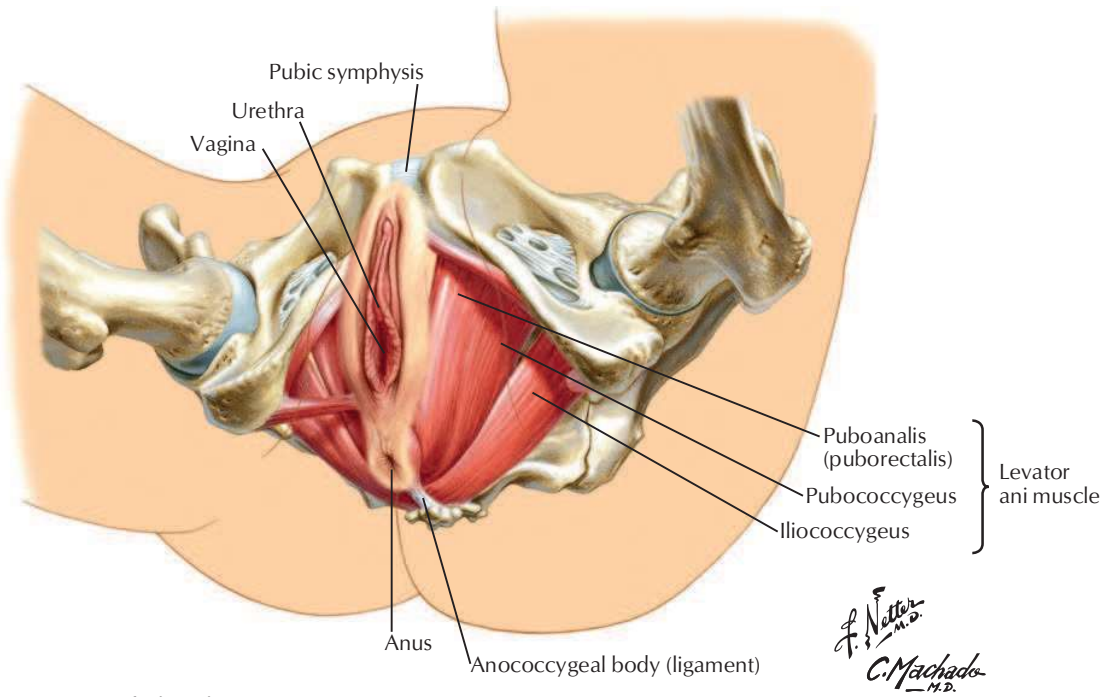
Lateral view



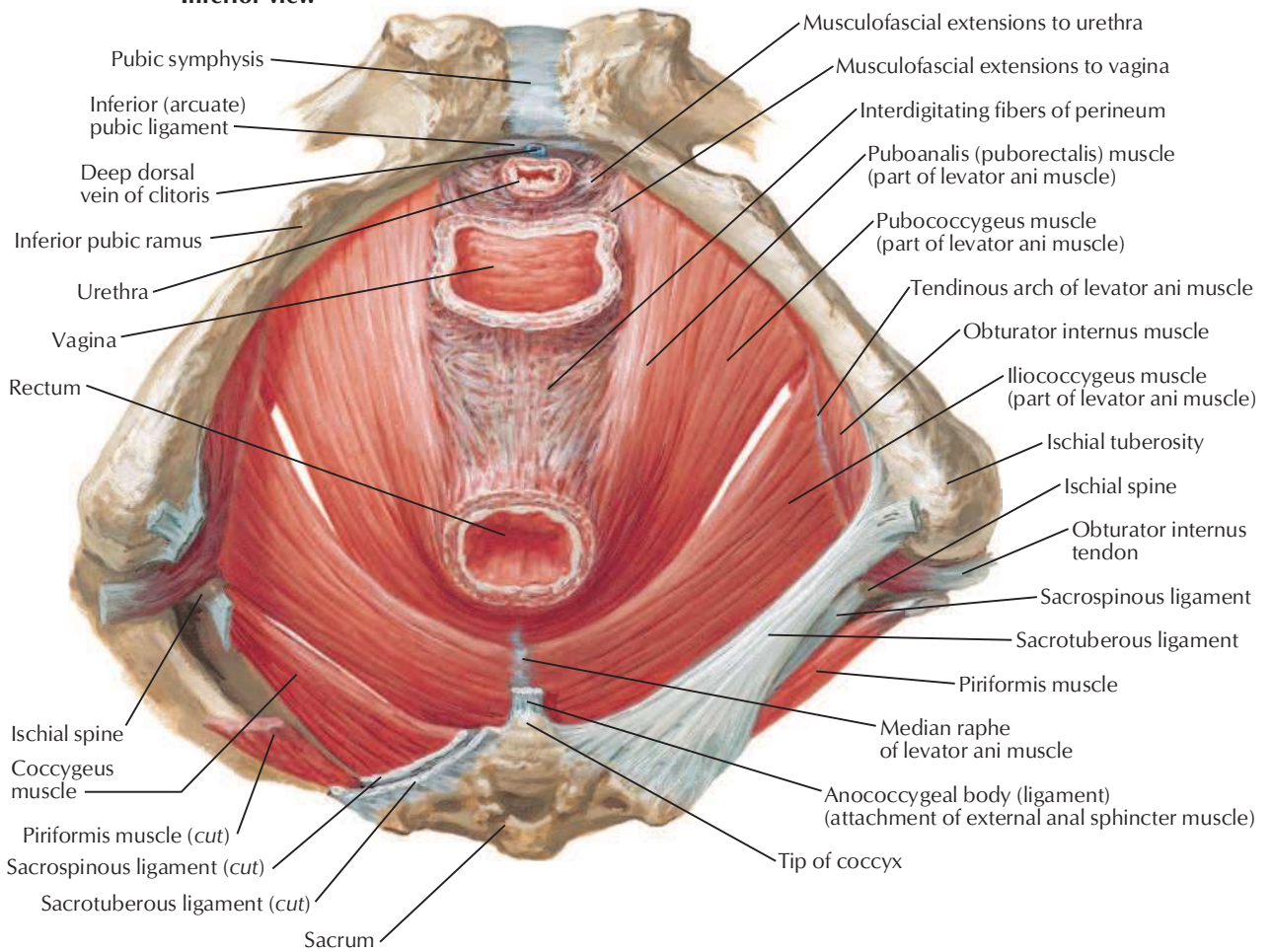
Pelvic Diaphragm: Female (continued)

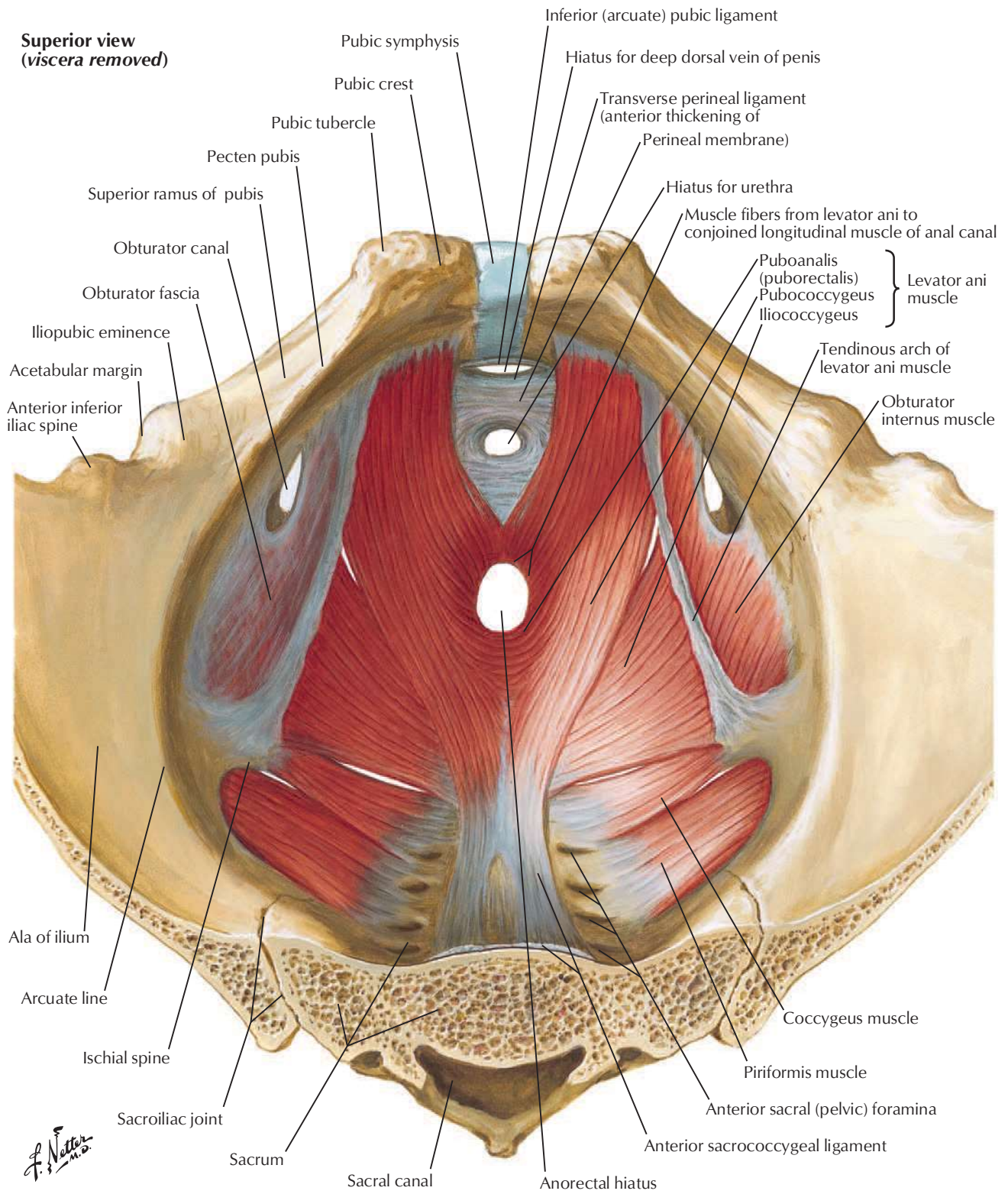
For urogenital diaphragm see [Plate 360](#)





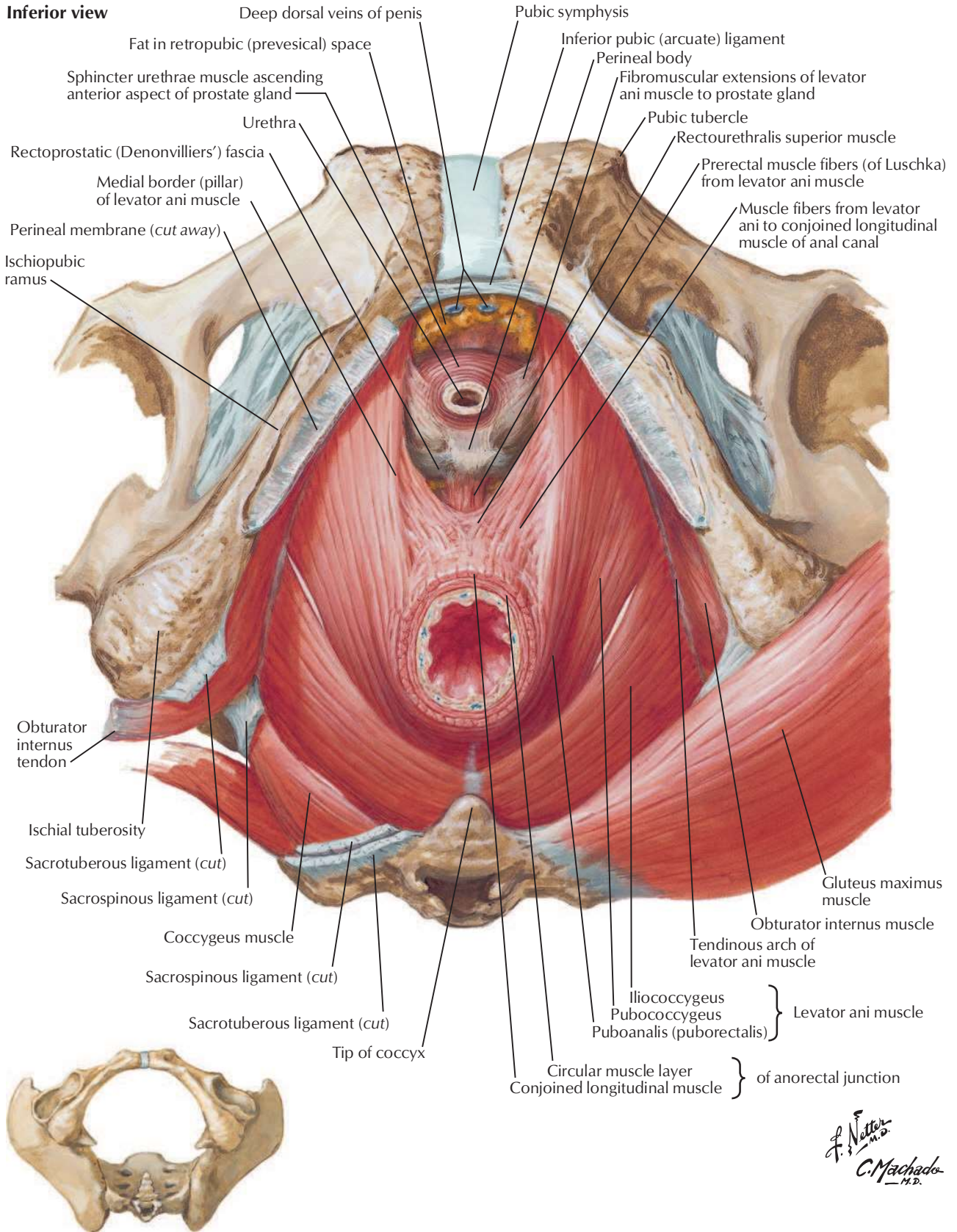
Inferior view





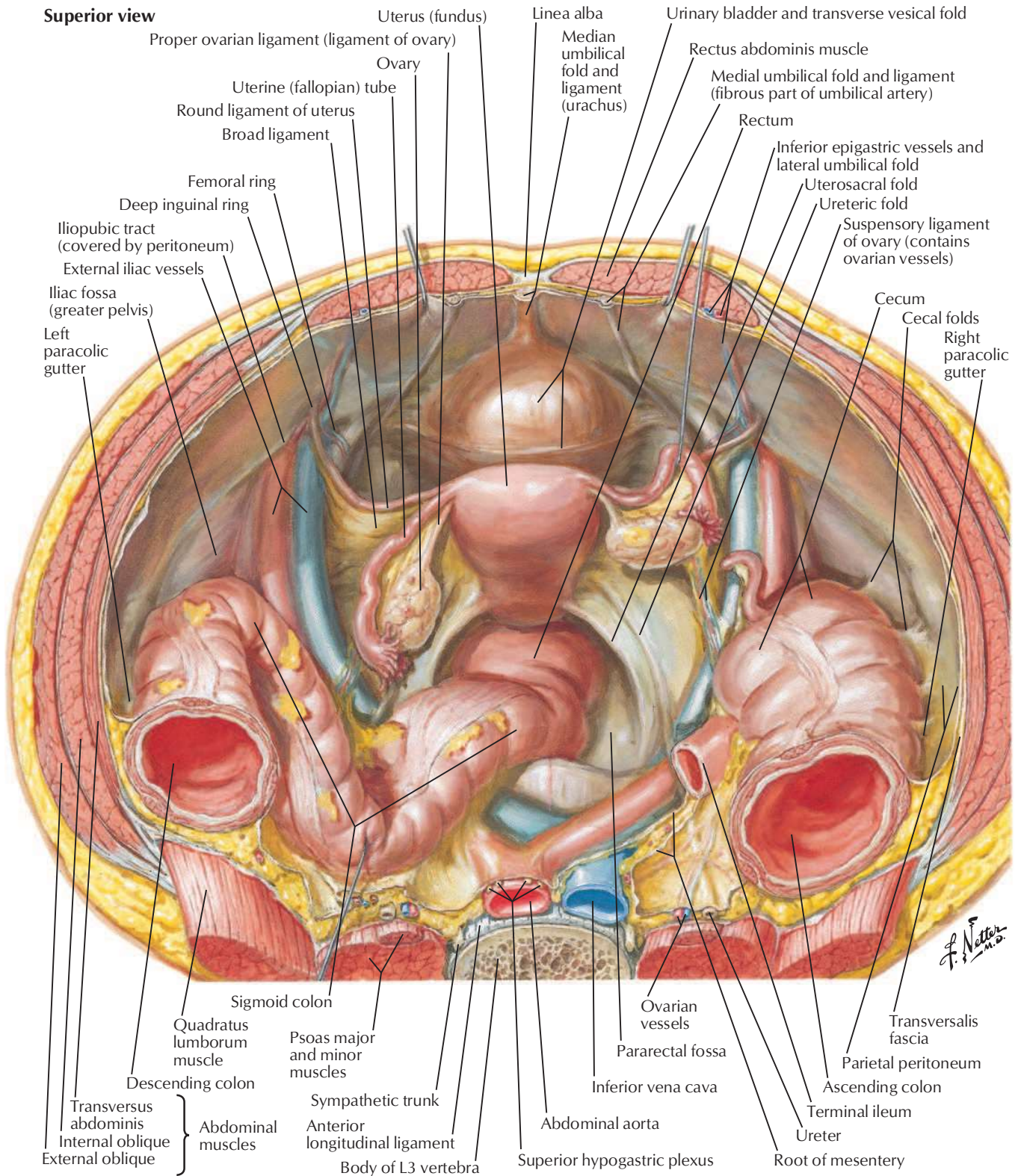
For urogenital diaphragm see [Plate 365](#)

Inferior view



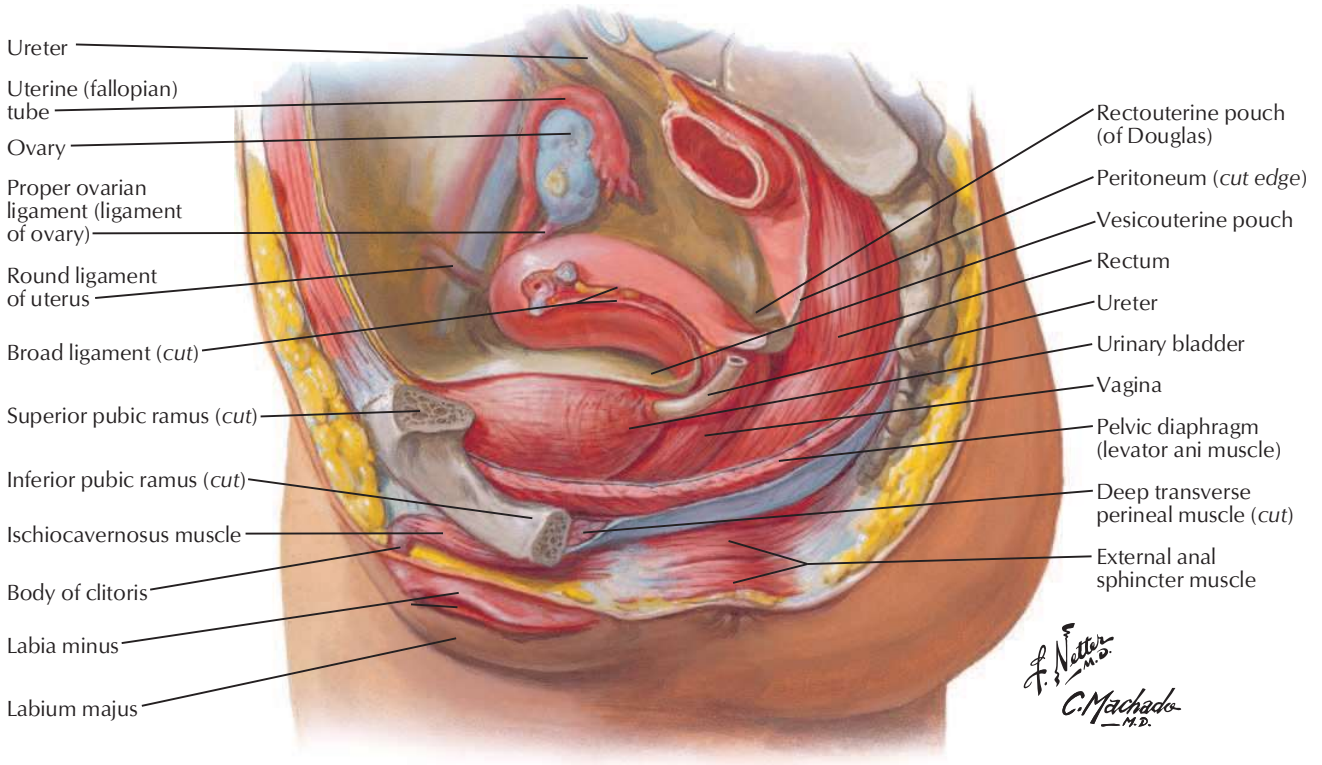
F. Netter M.D.
C. Machado M.D.

Superior view

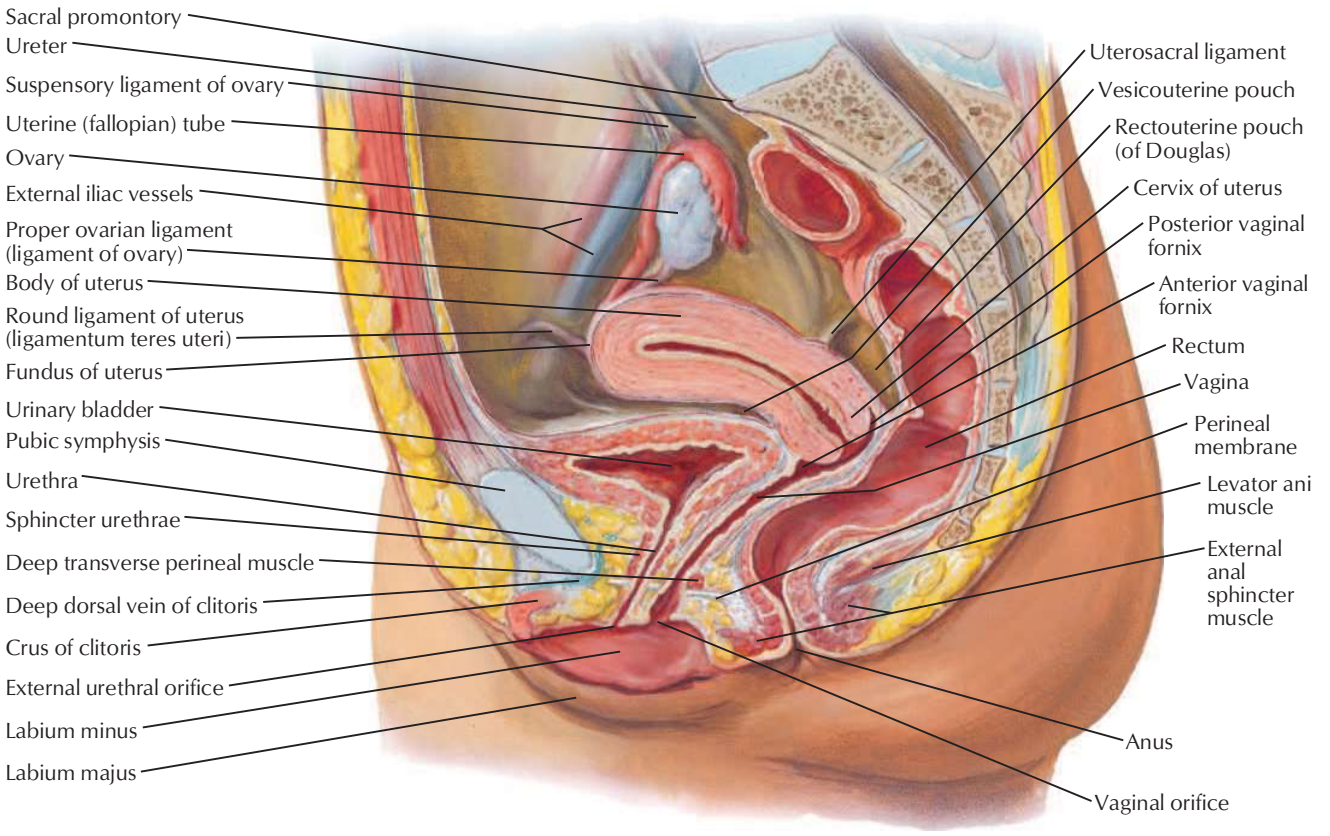


F. Netter M.D.

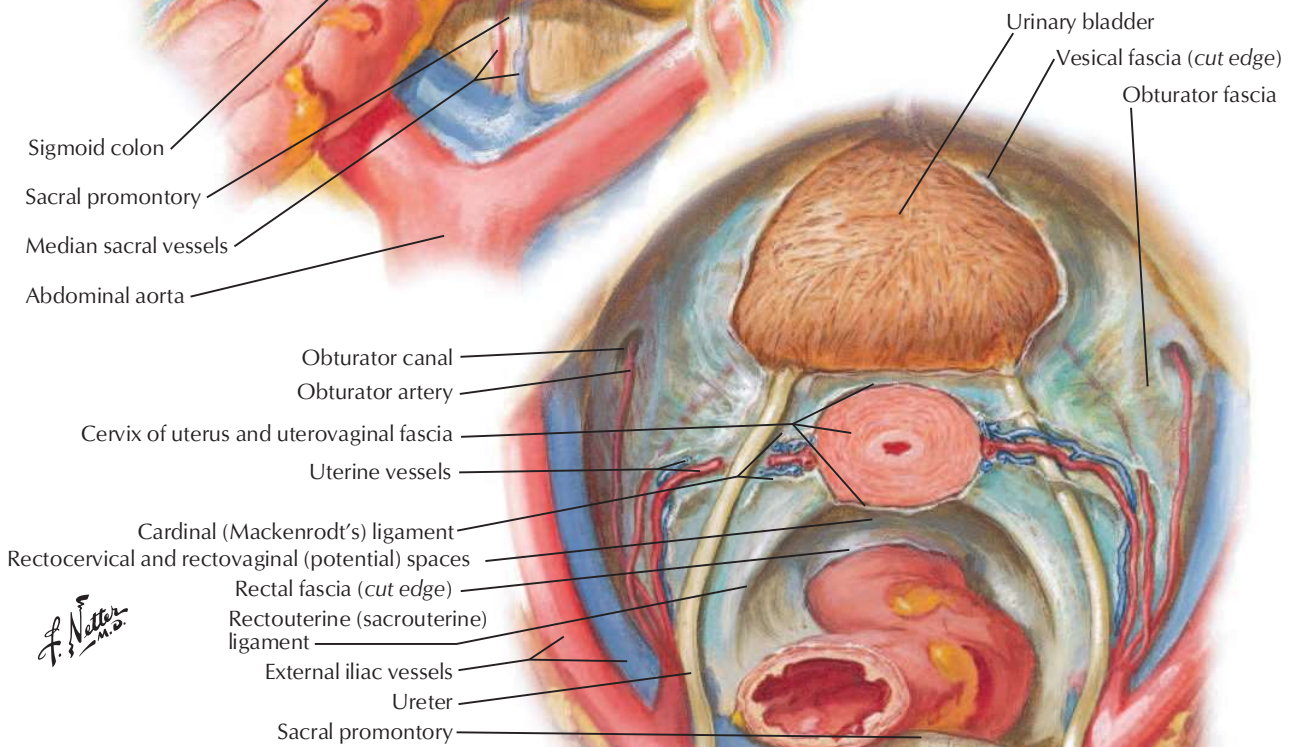
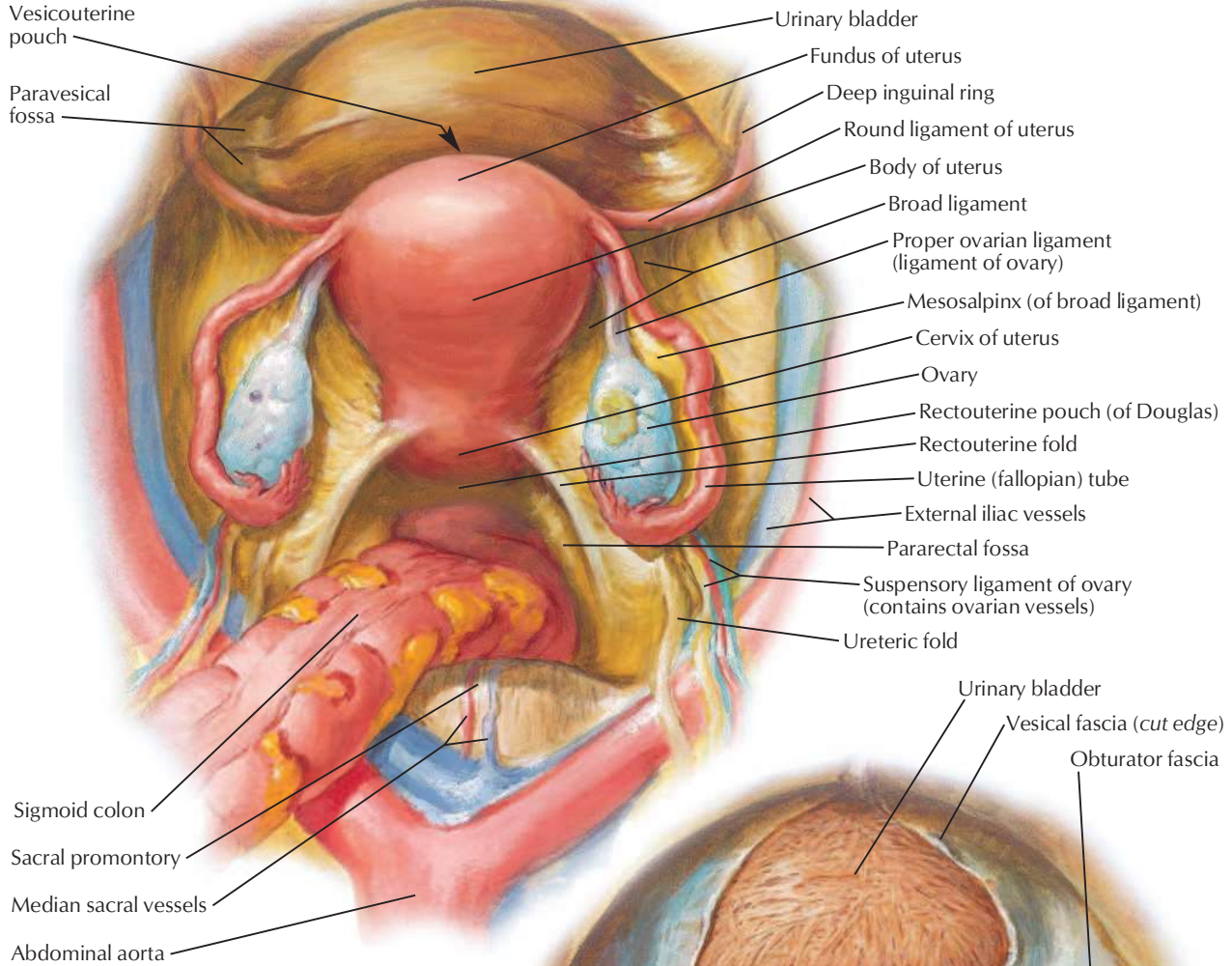
Paramedian (sagittal) dissection



Median (sagittal) section

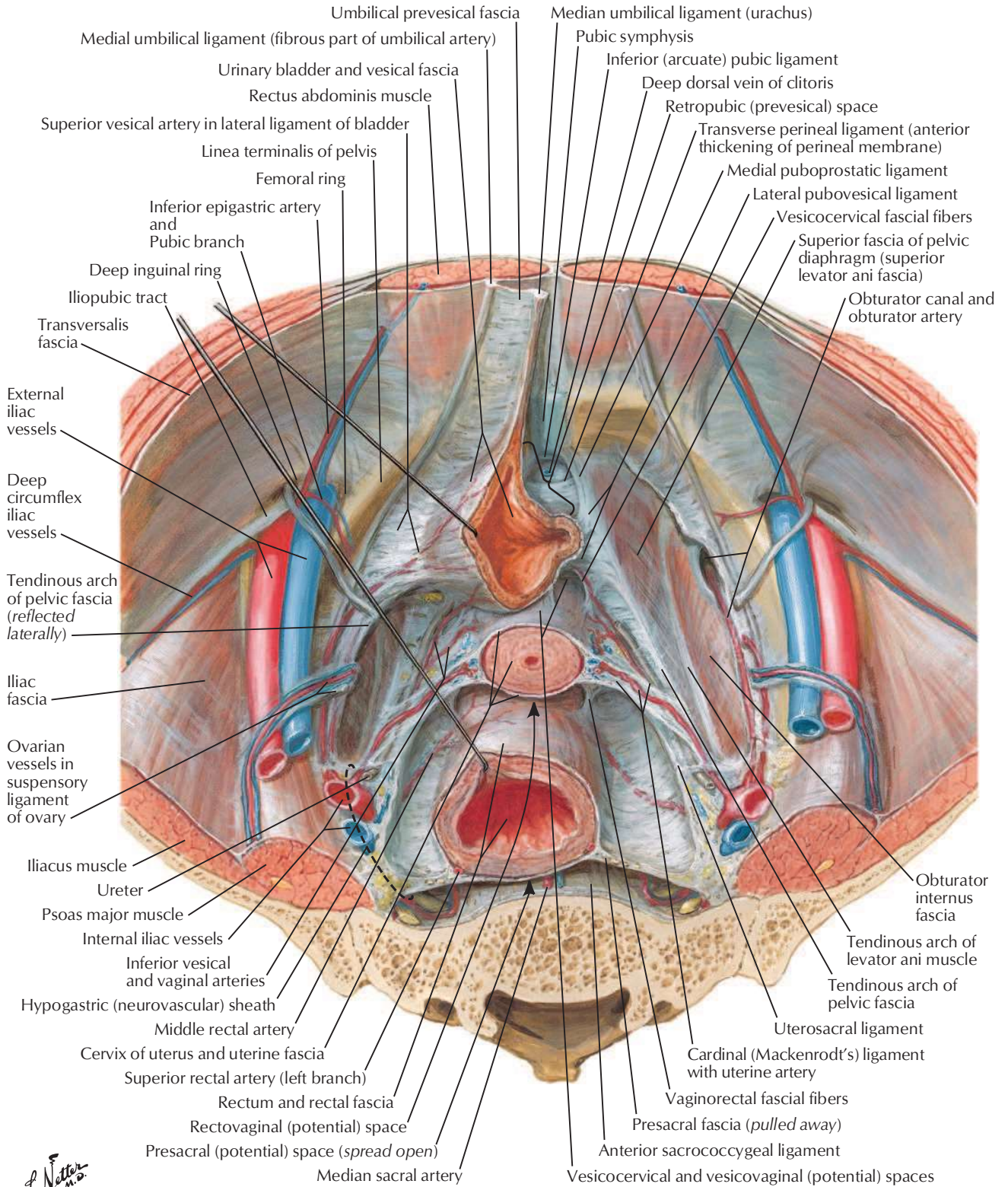


Superior view with peritoneum intact

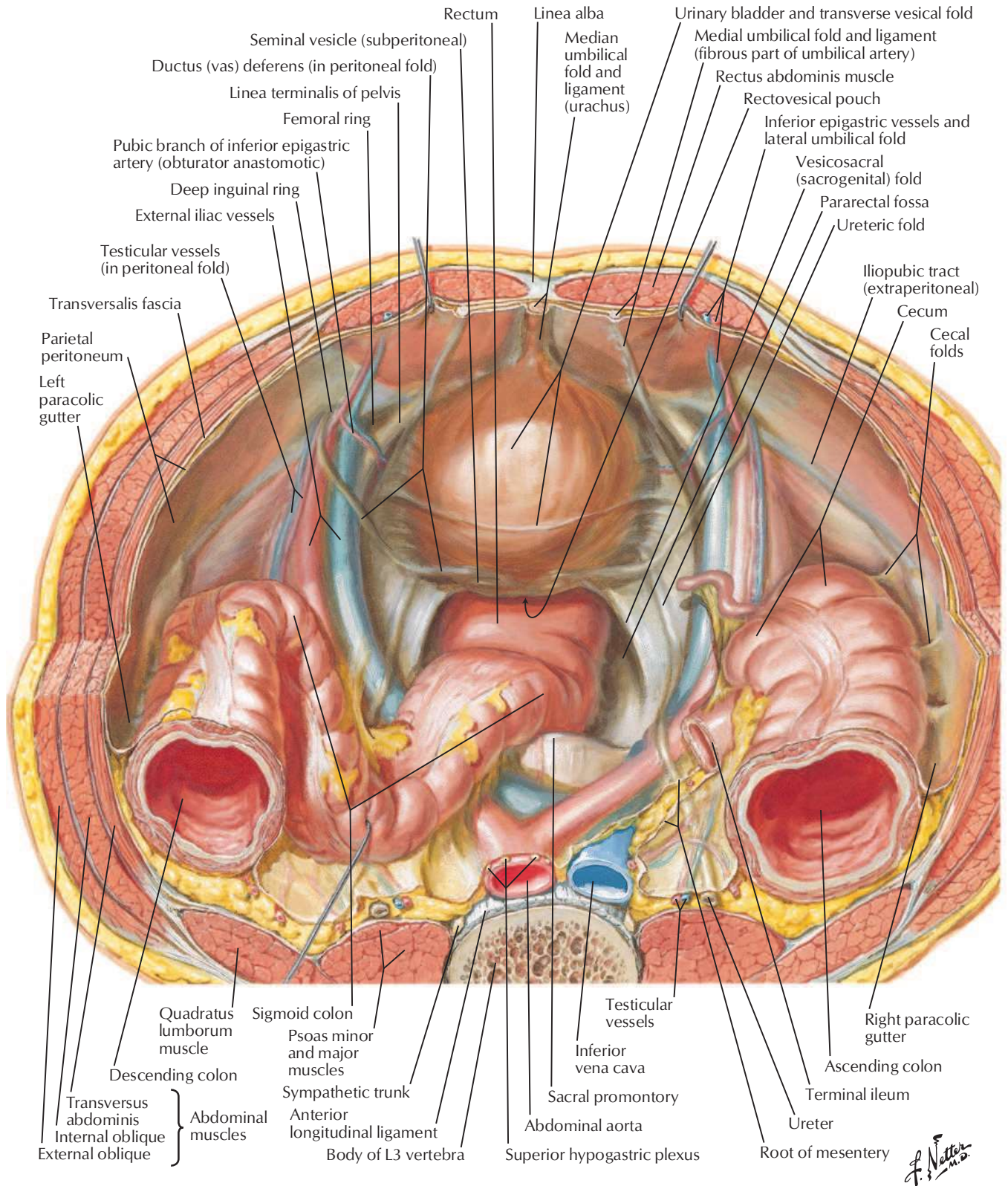


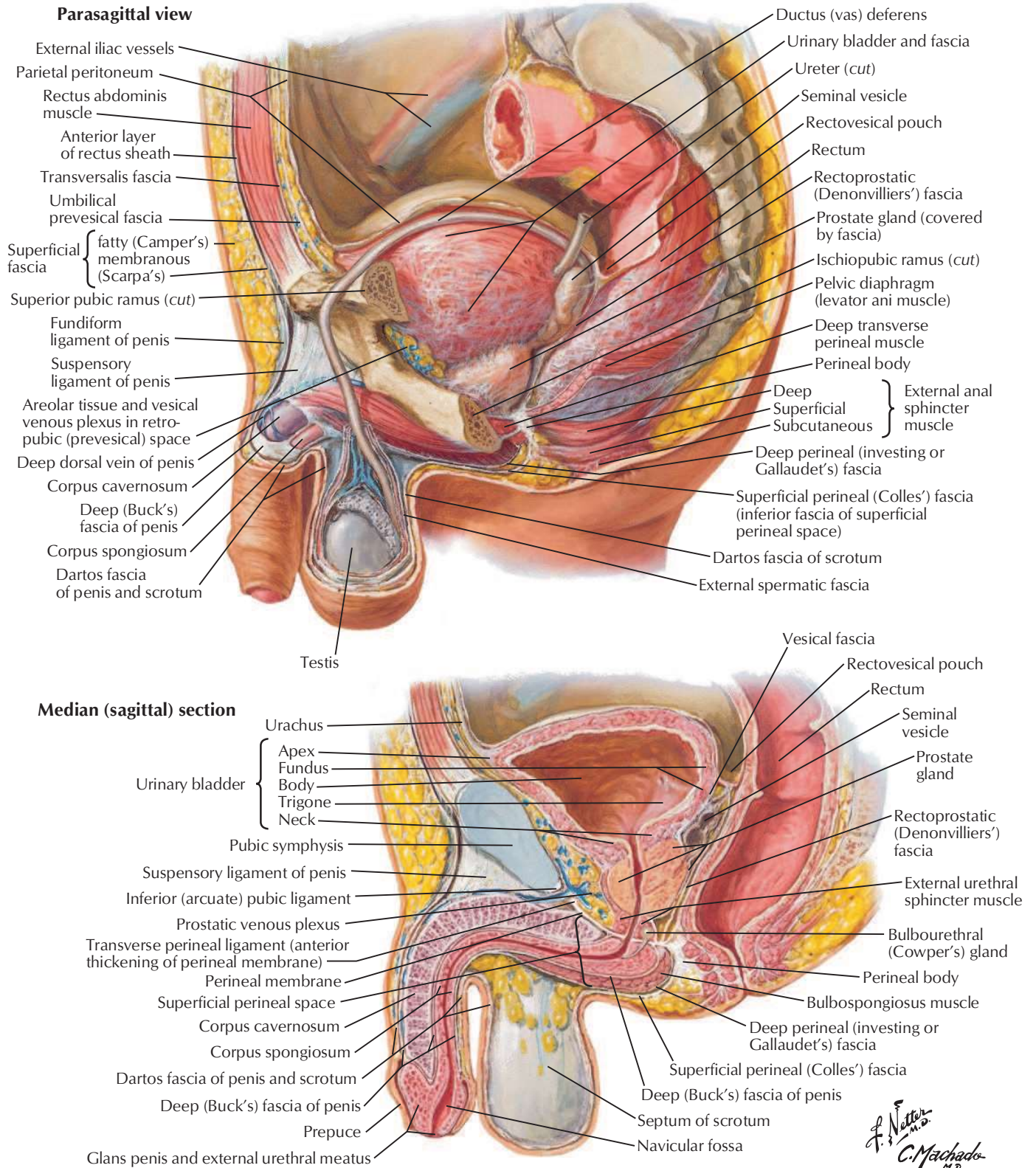
Superior view with peritoneum and uterus removed

Female: superior view (peritoneum and loose areolar tissue removed)

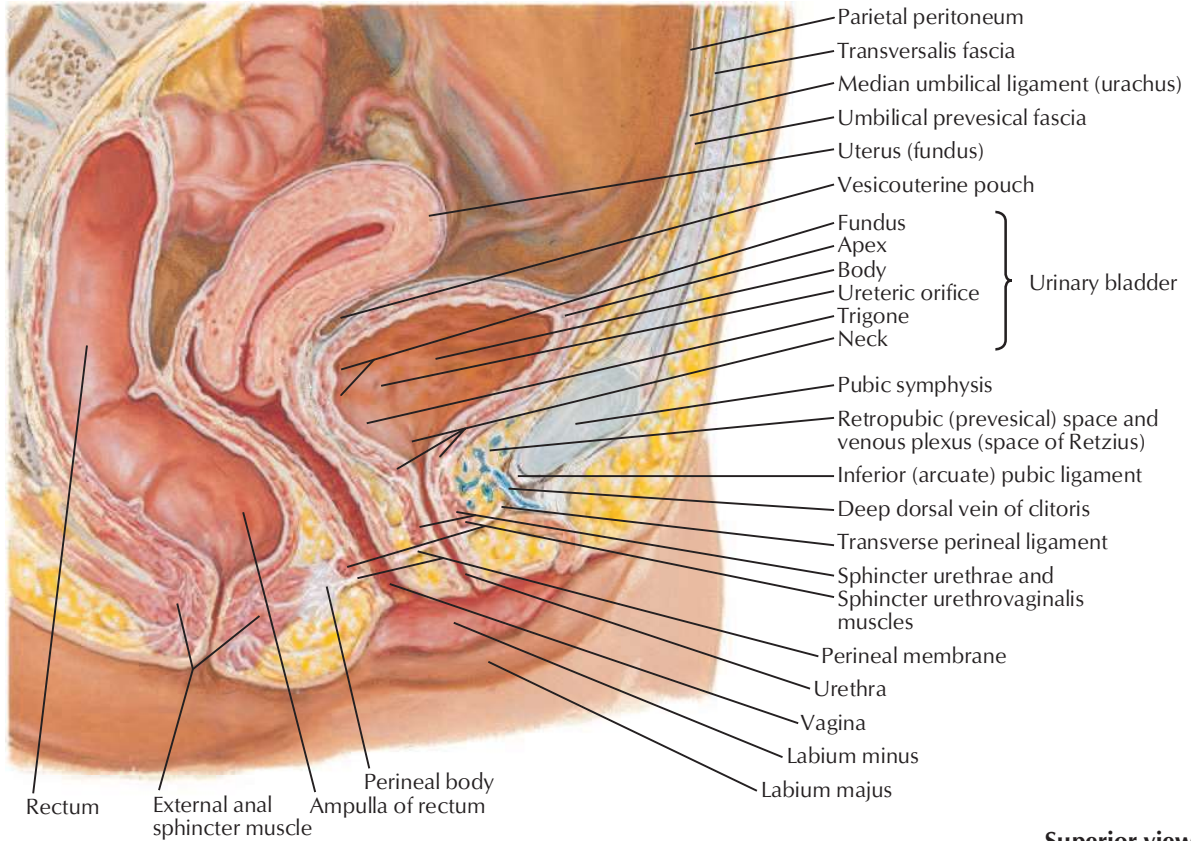


Superior view

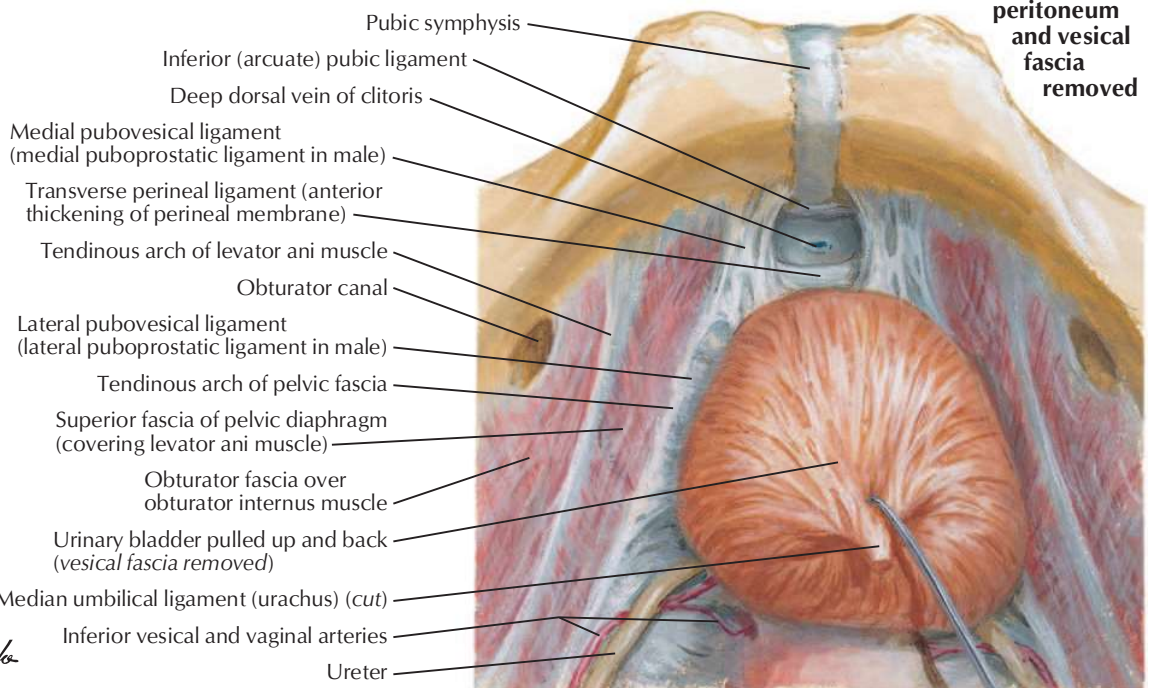




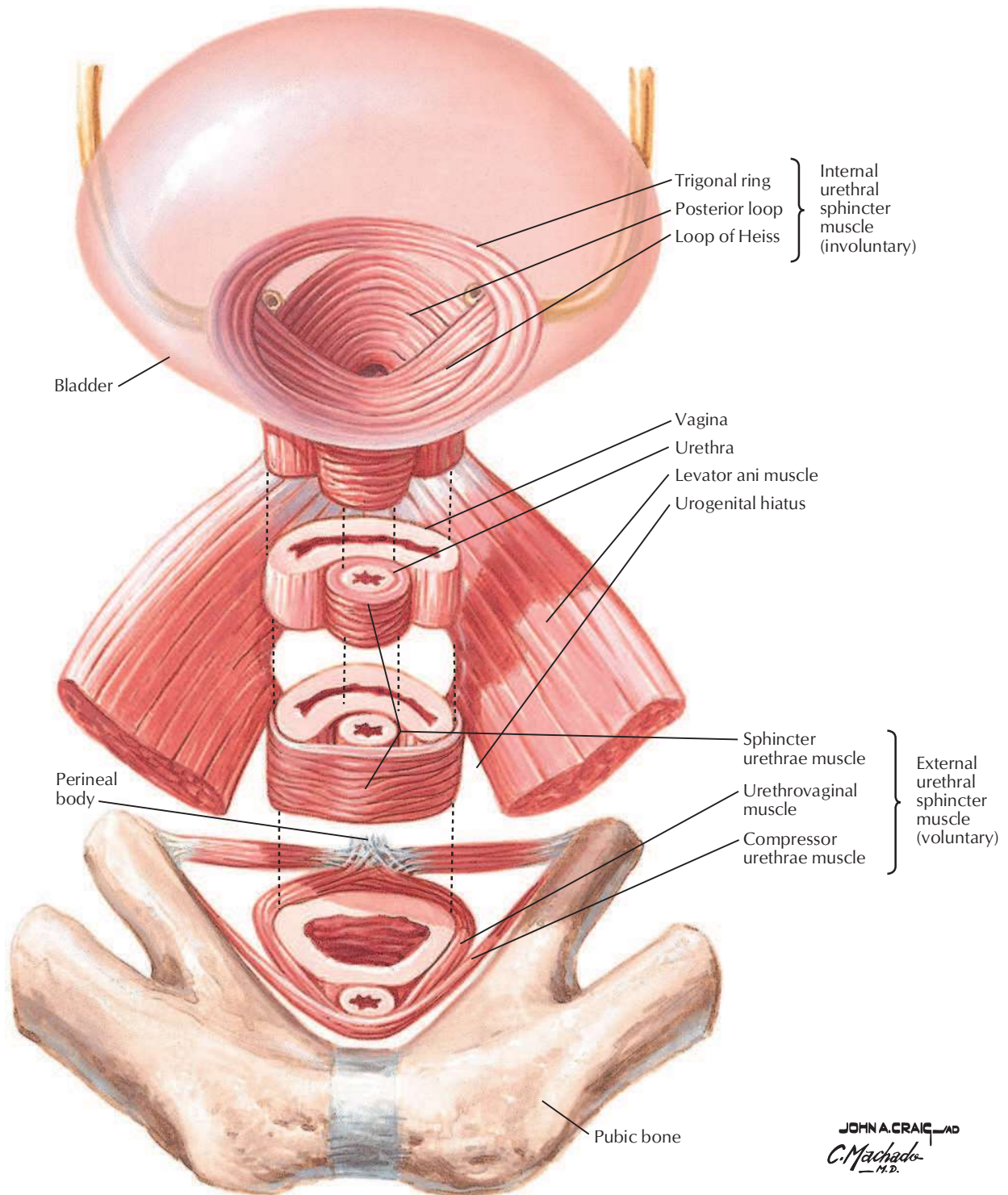
Female: midsagittal section

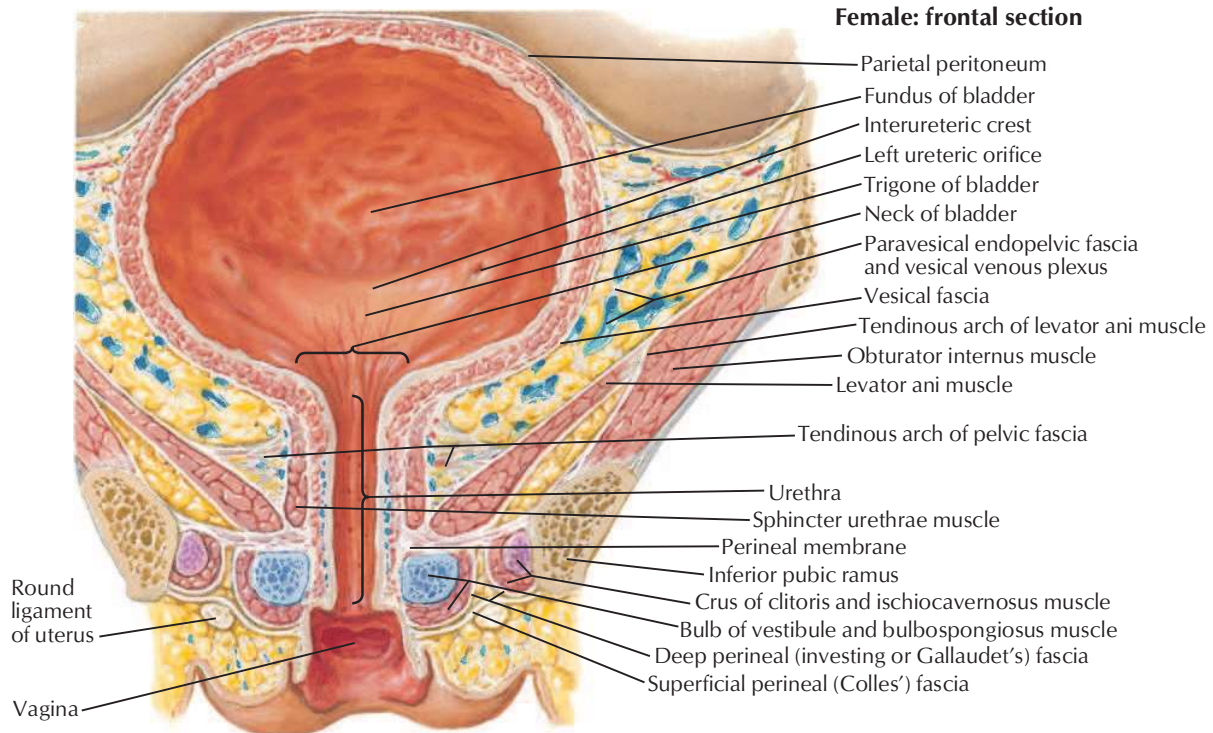


Superior view with peritoneum and vesical fascia removed

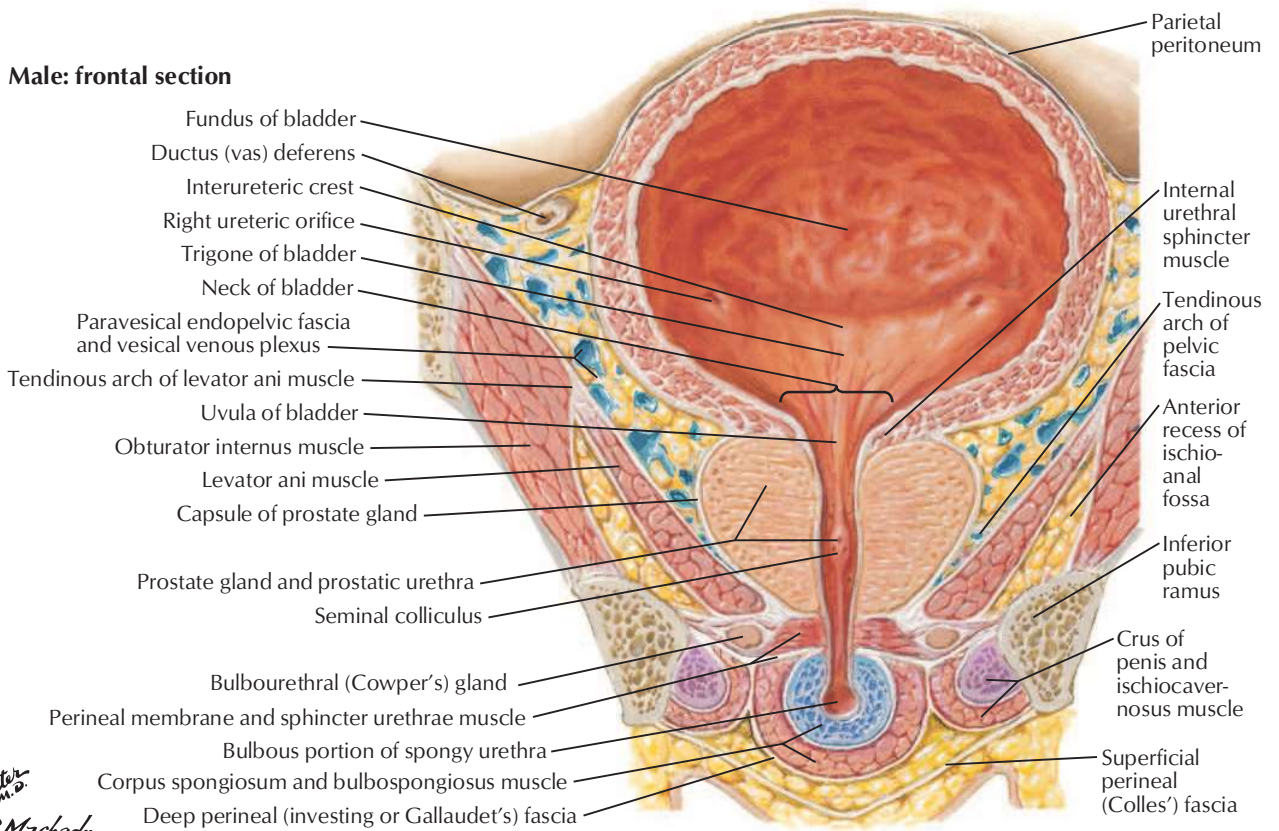


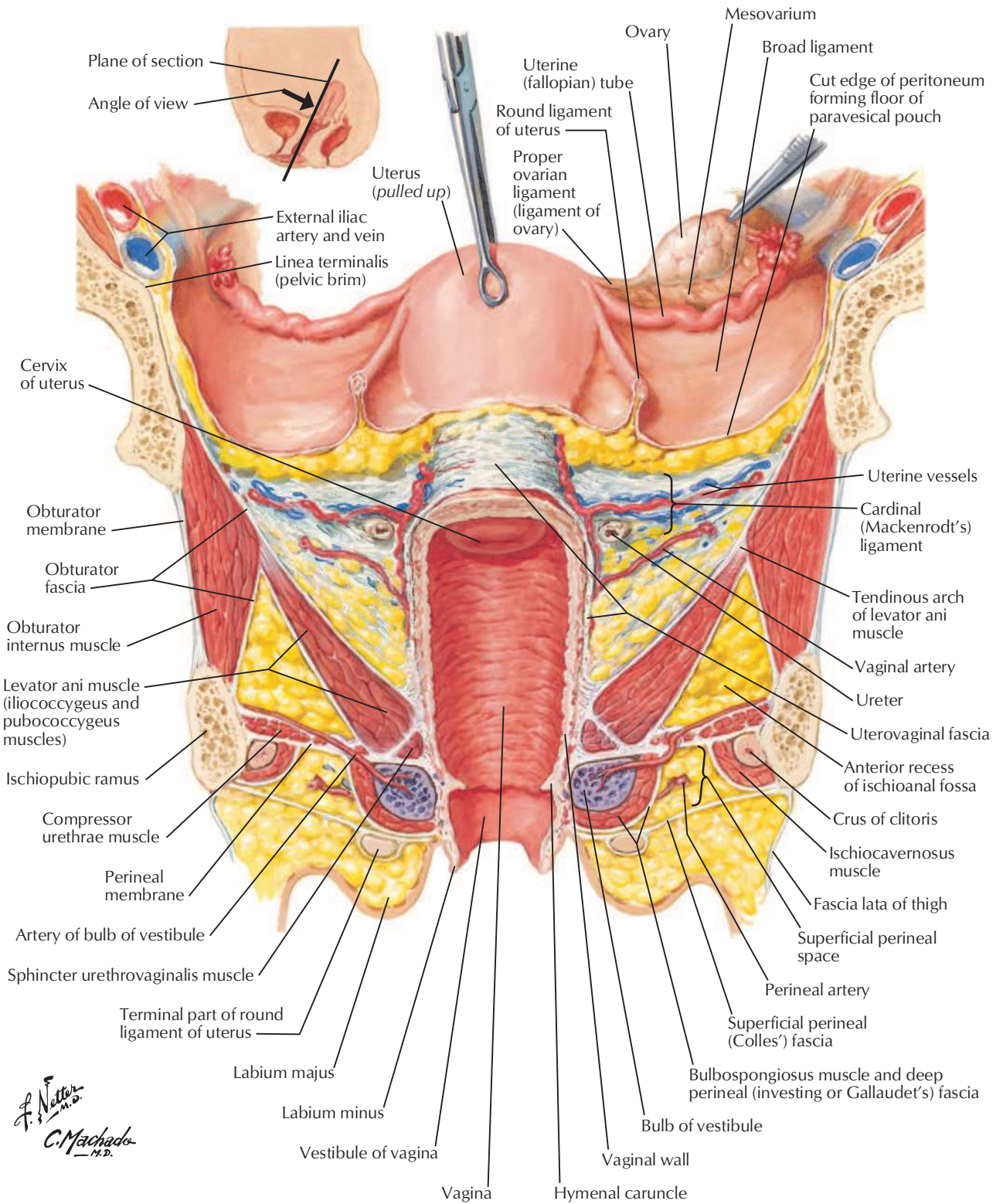
F. Netter
 M.D.
 C. Machado
 M.D.



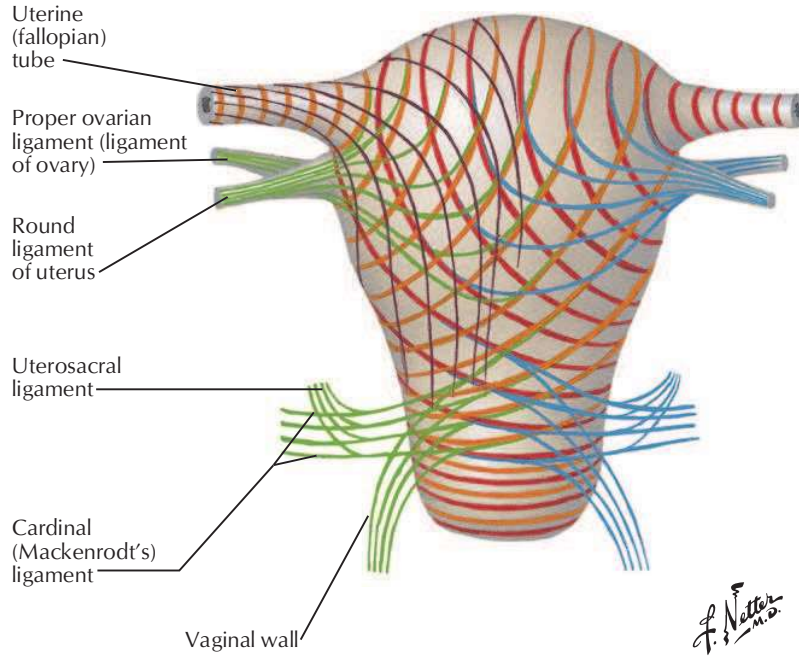


Male: frontal section

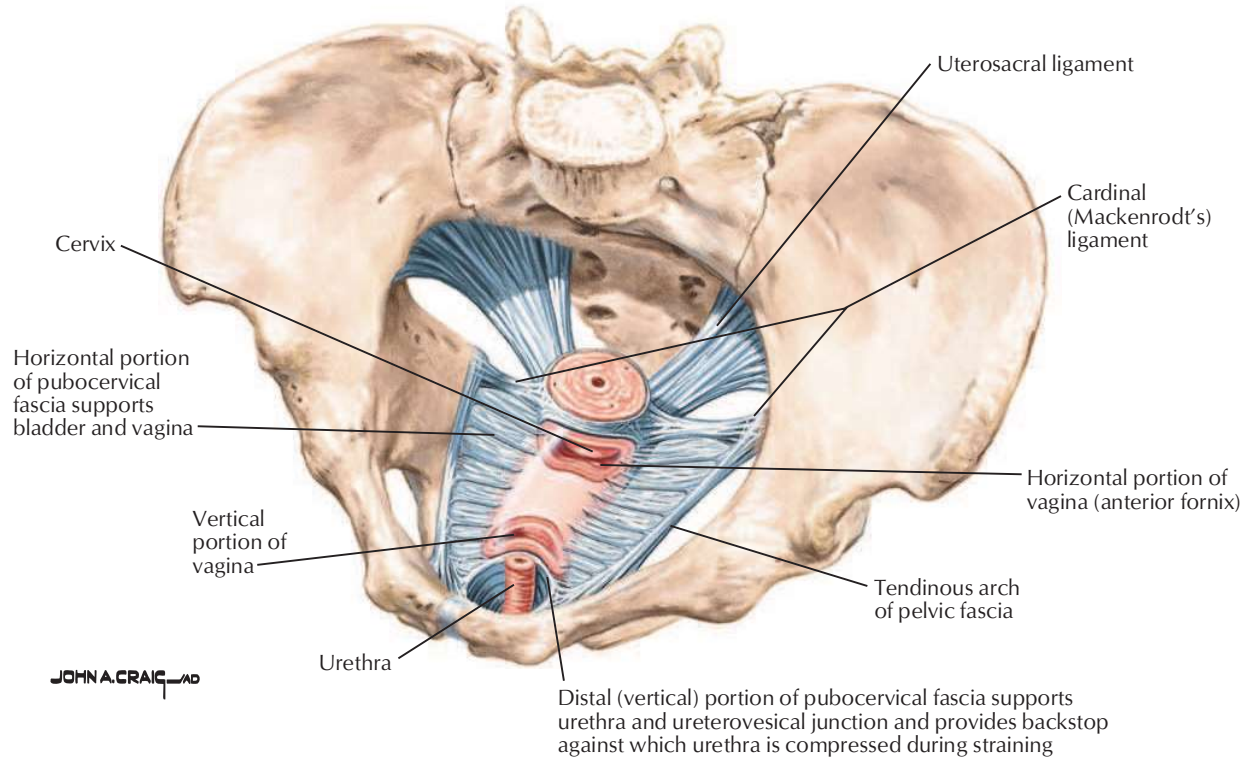


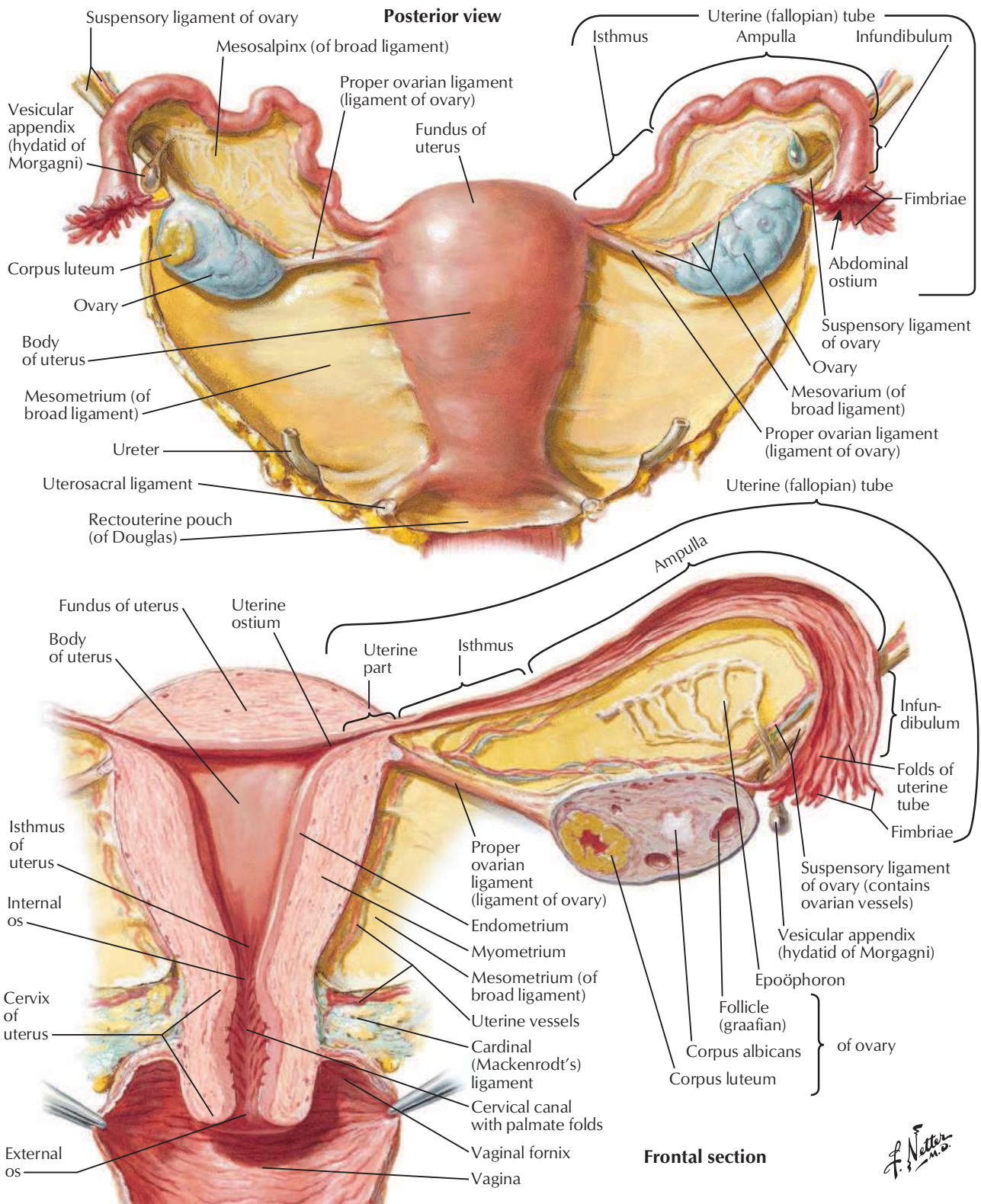


Fascial ligaments of uterus

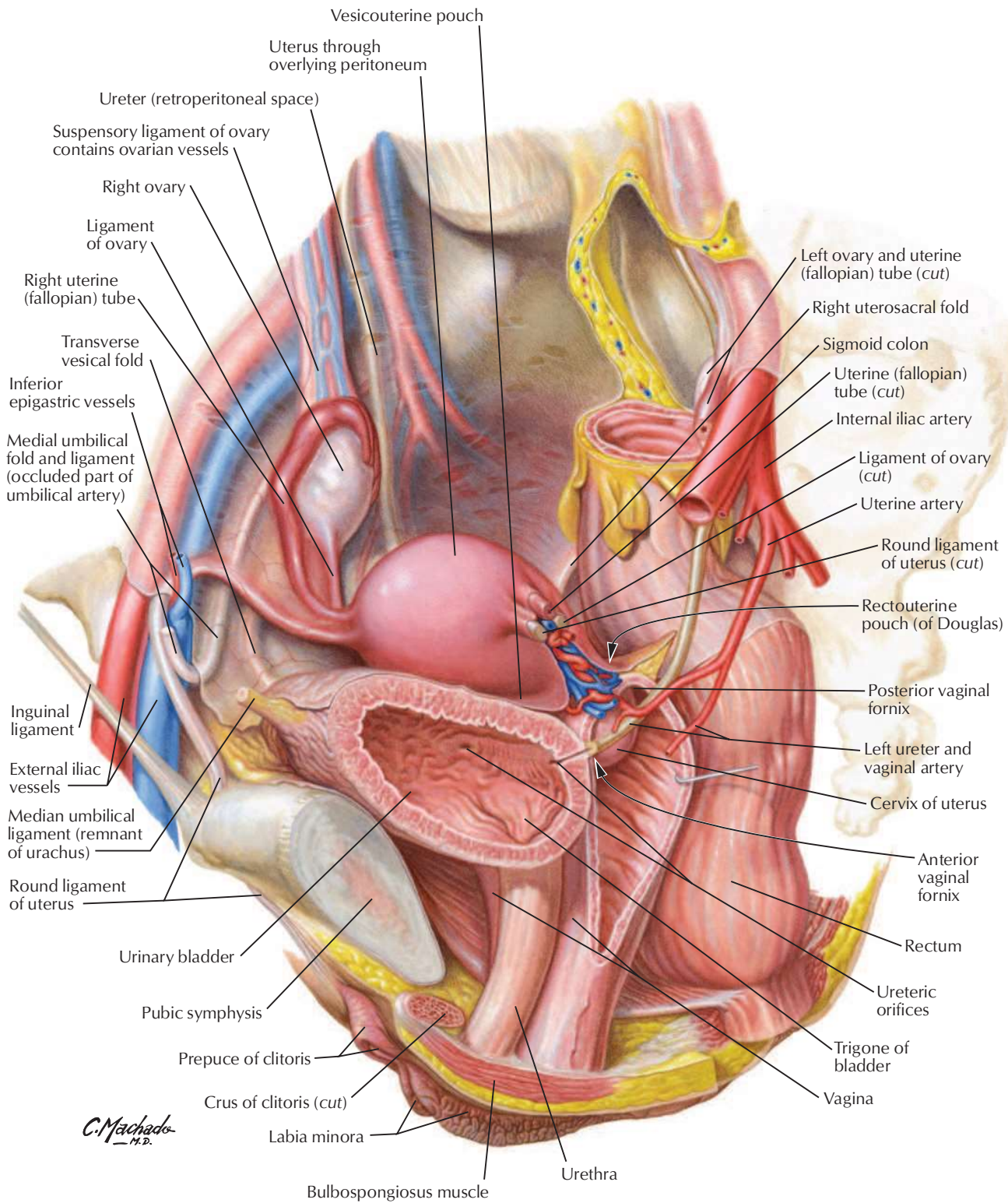


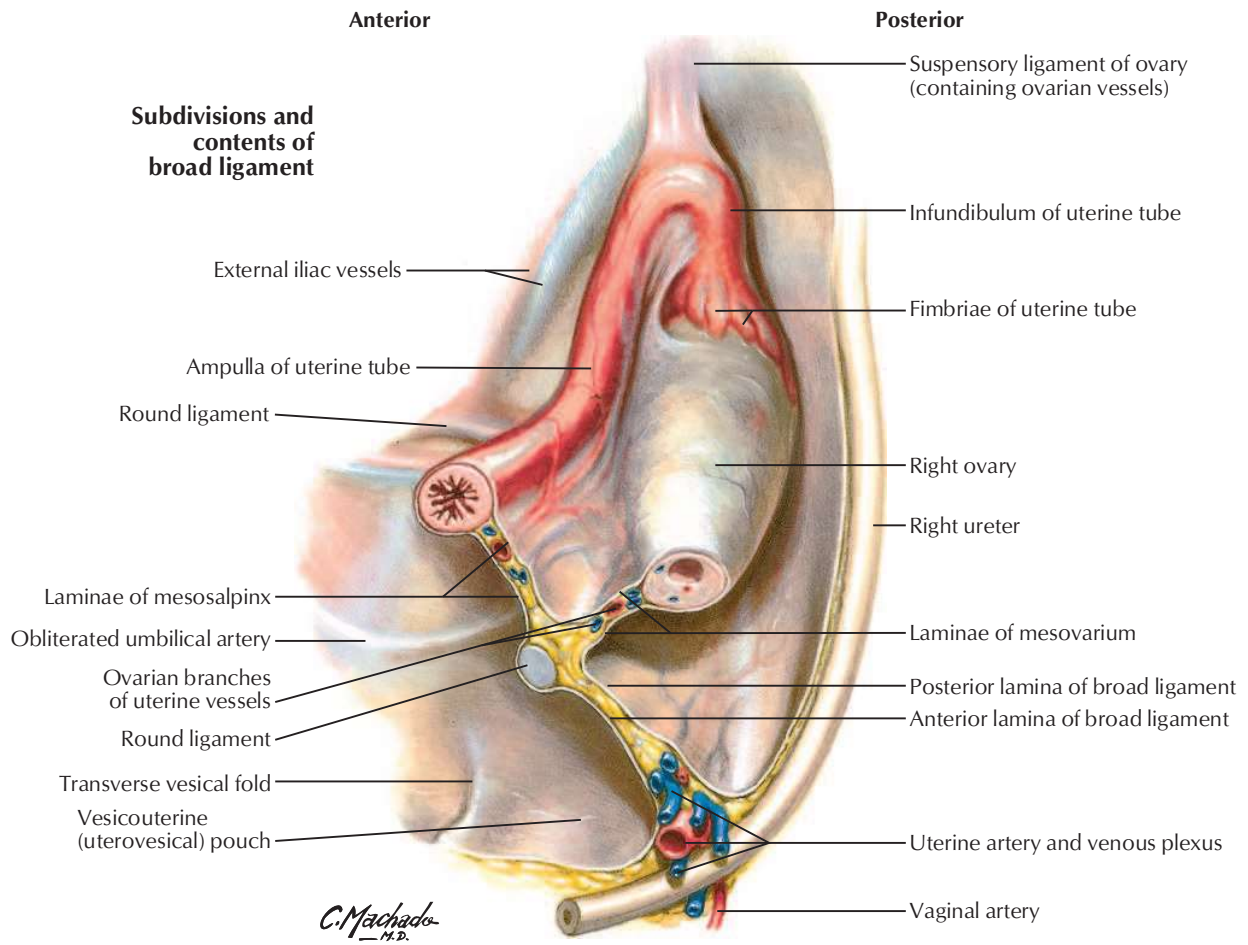
Pelvic fascia and ligaments



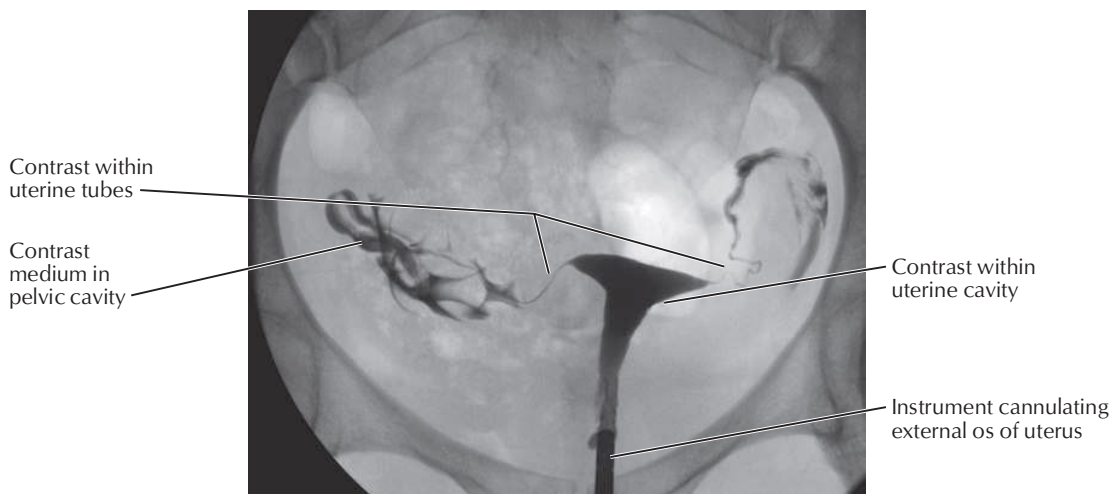

F. Netter M.D.



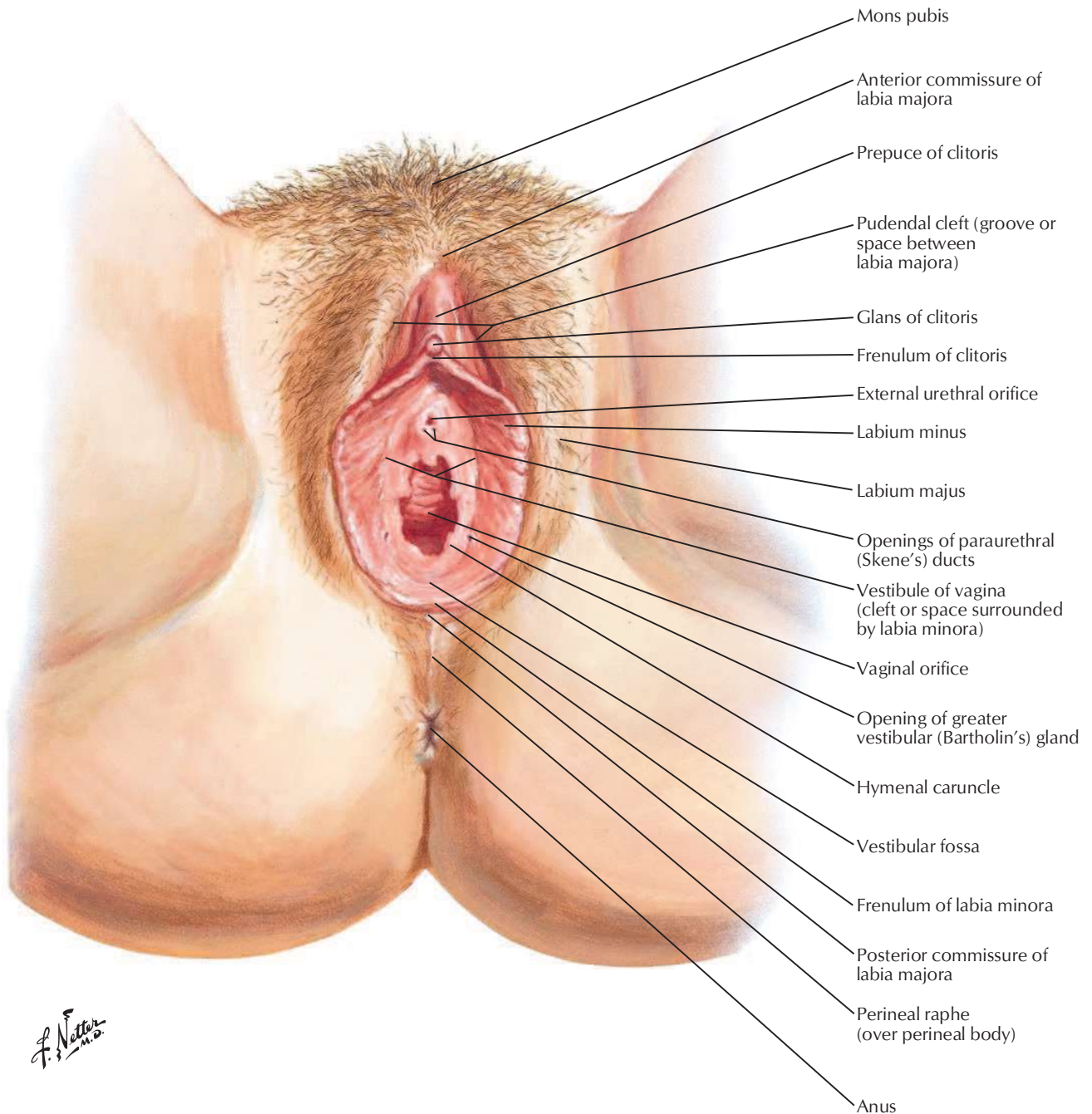


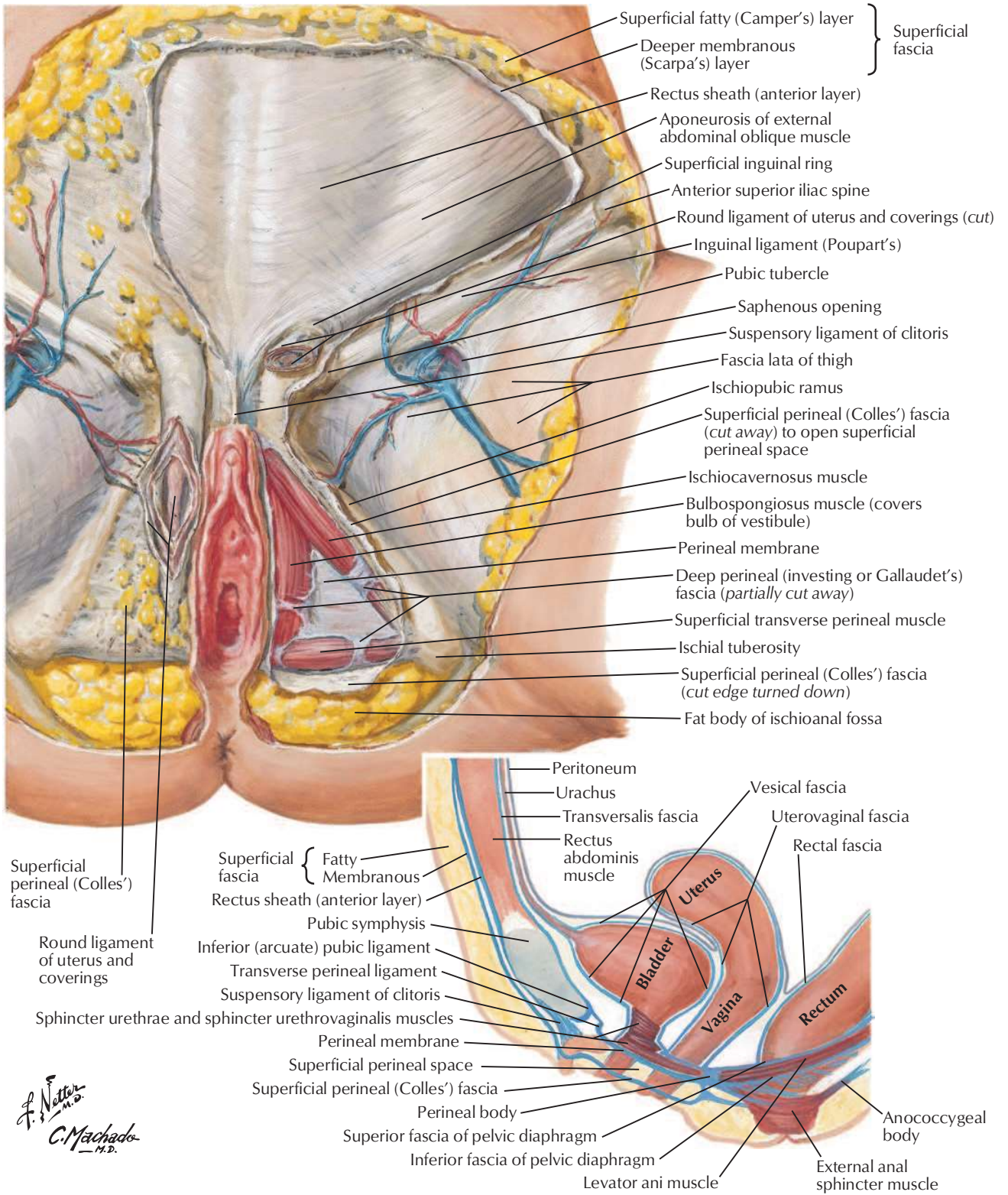
Anteroposterior fluoroscopic image obtained during hysterosalpingography



Female Perineum and External Genitalia (Pudendum or Vulva)

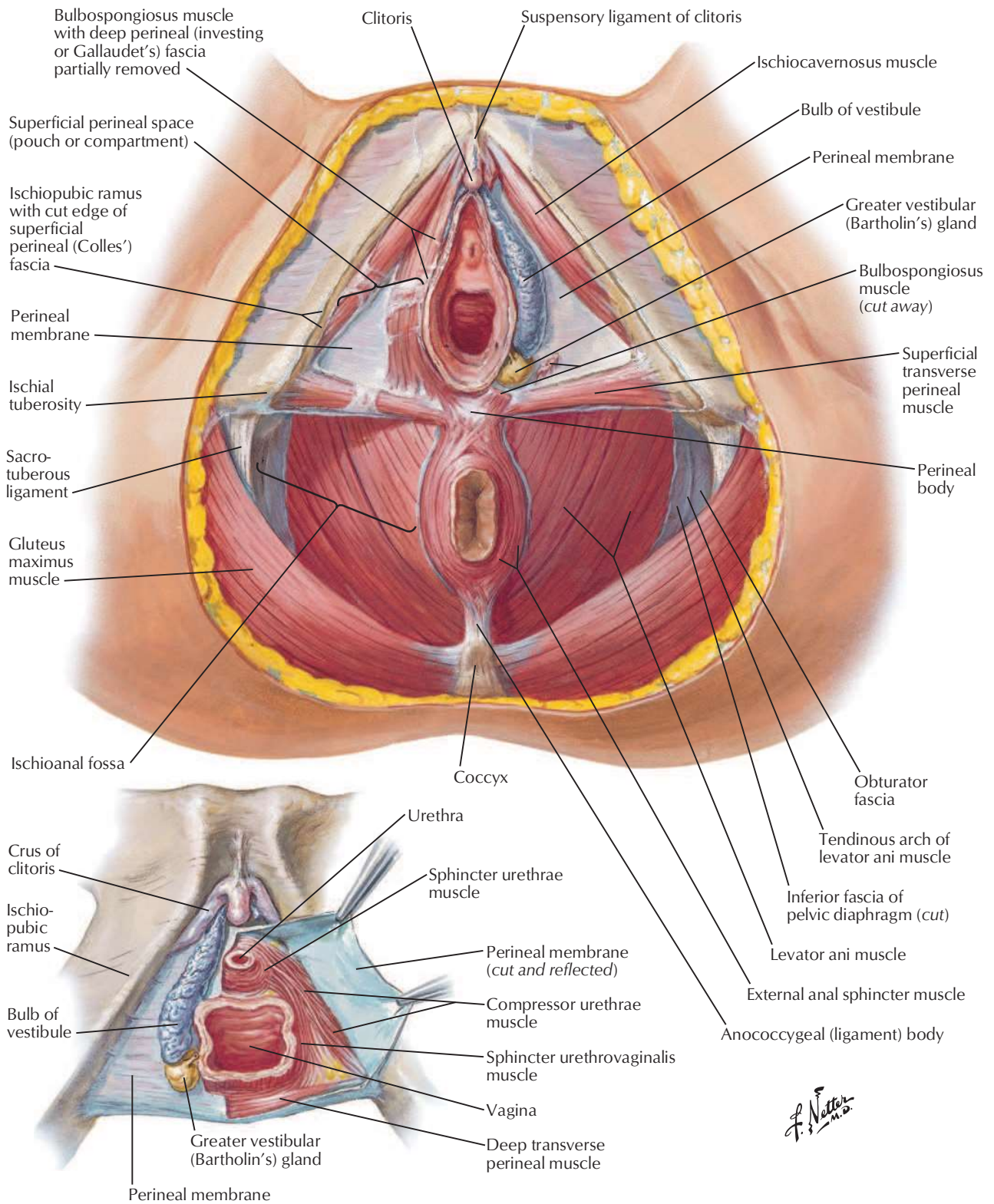
See also [Plates 386, 389, 395](#)



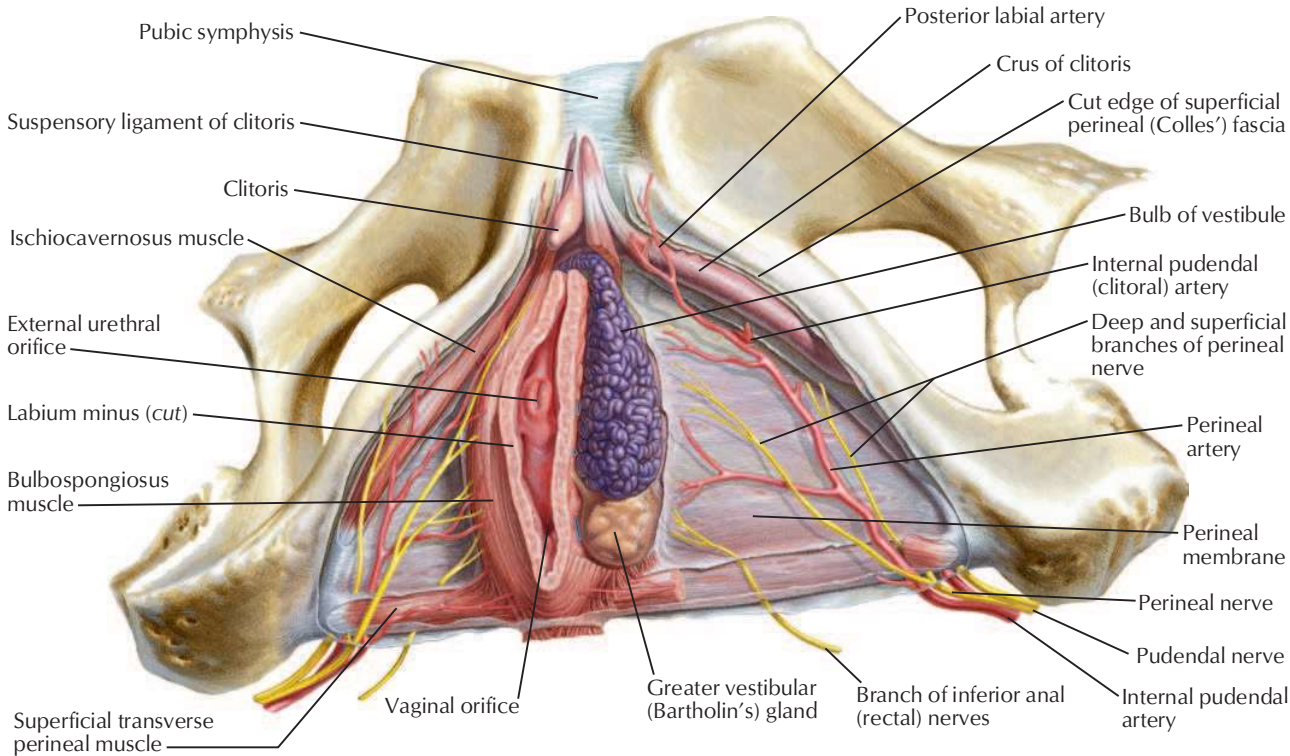


F. Netter M.D.
C. Machado M.D.

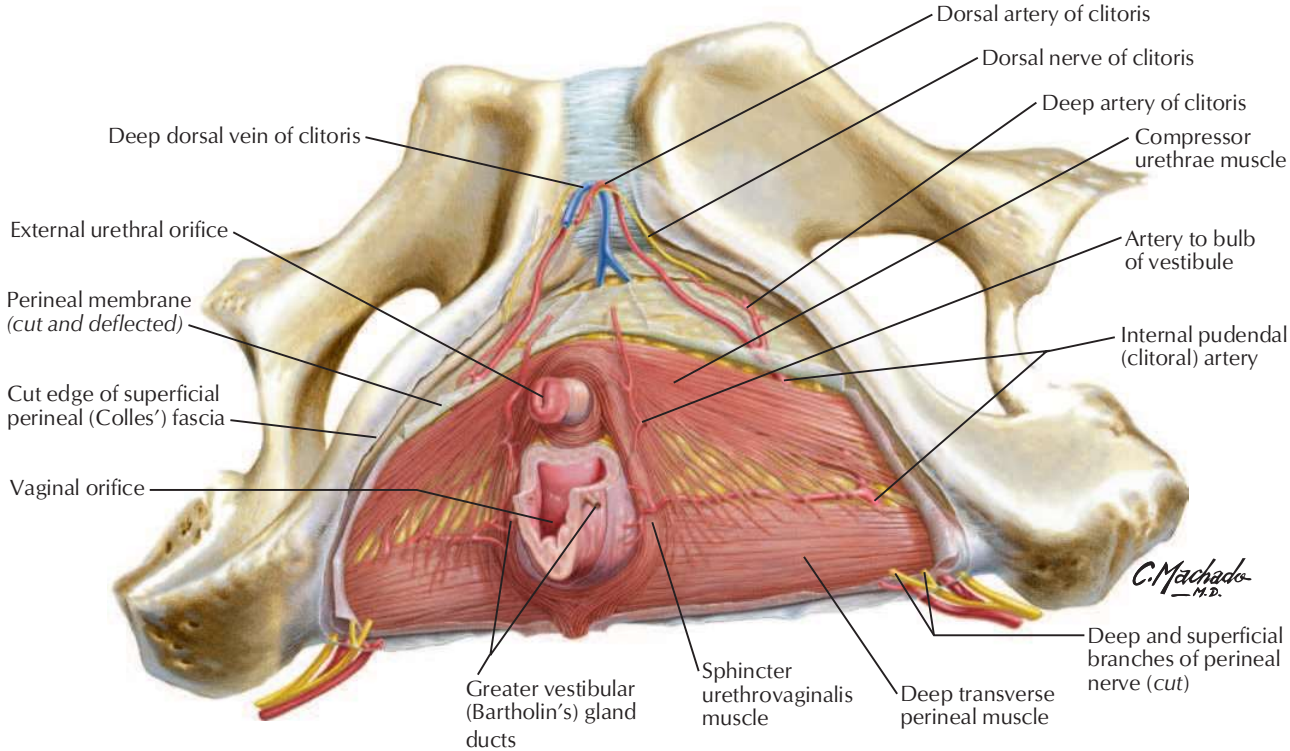
Female Perineum and Deep Perineum



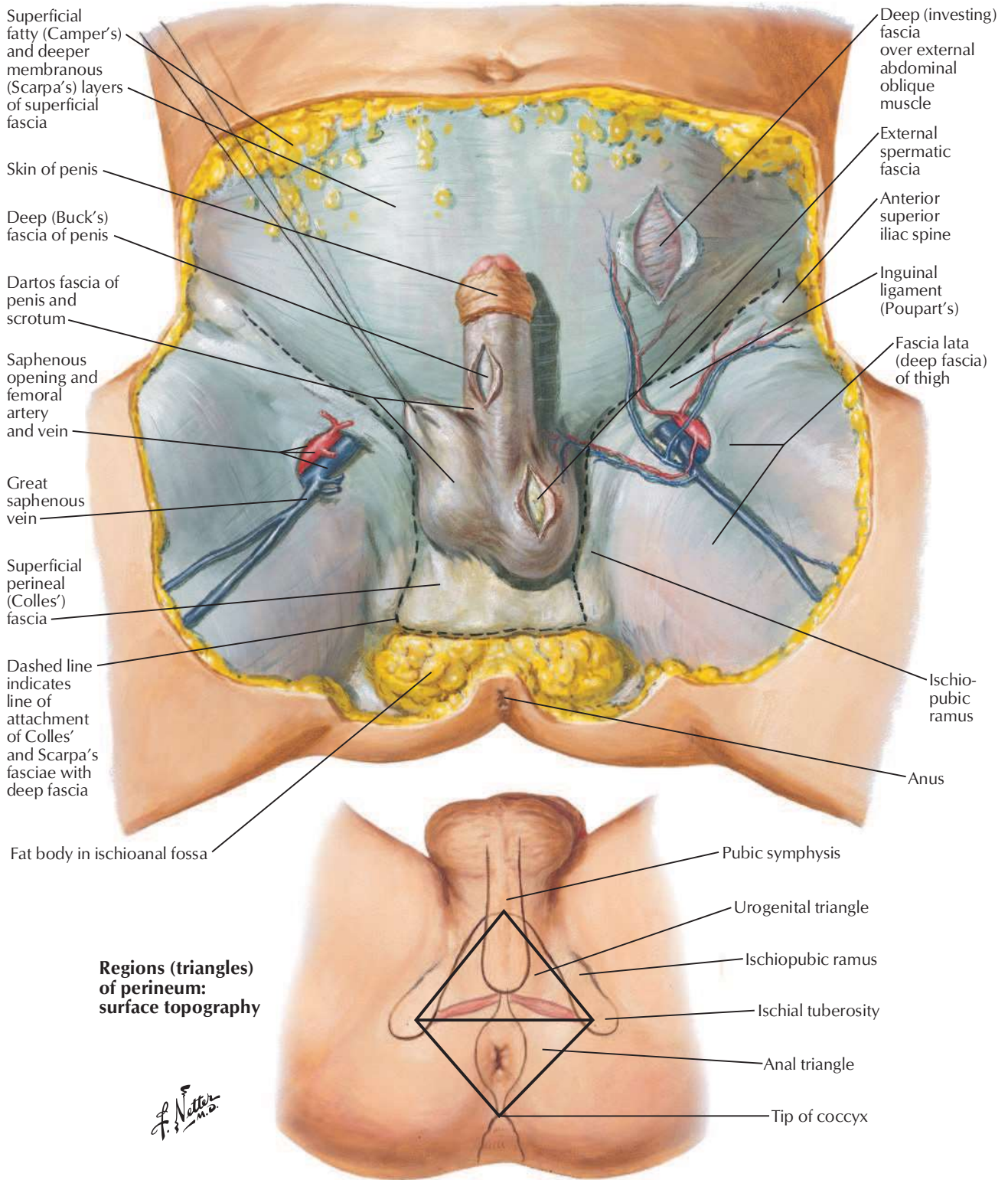
Superficial perineal space

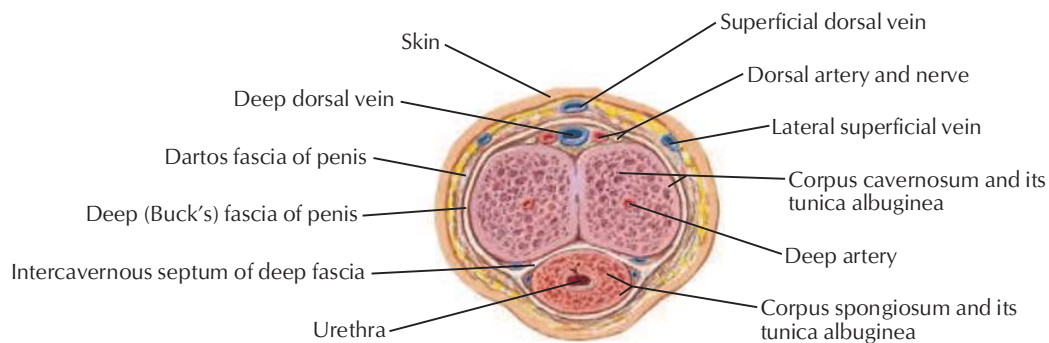
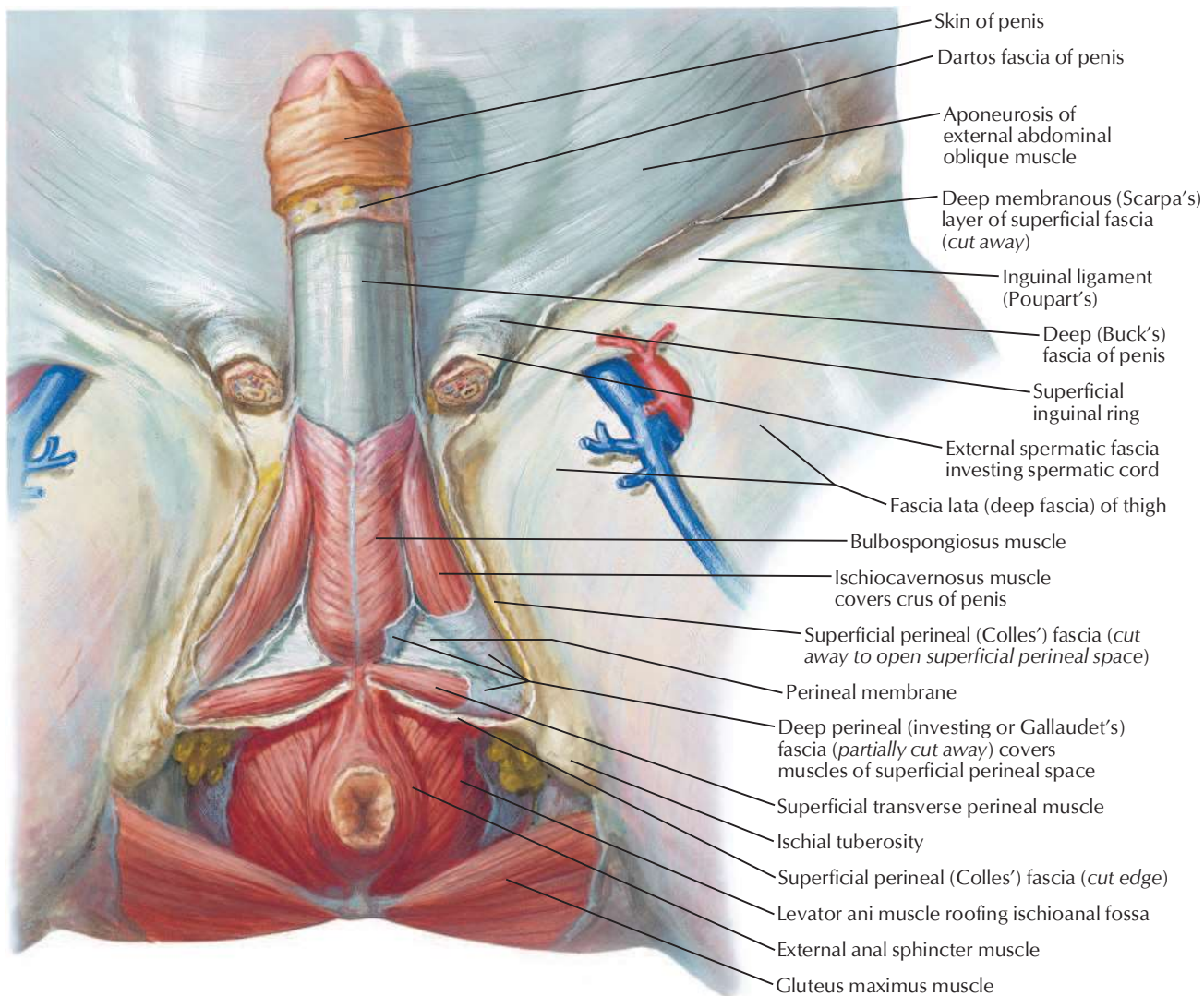


Deep perineal space



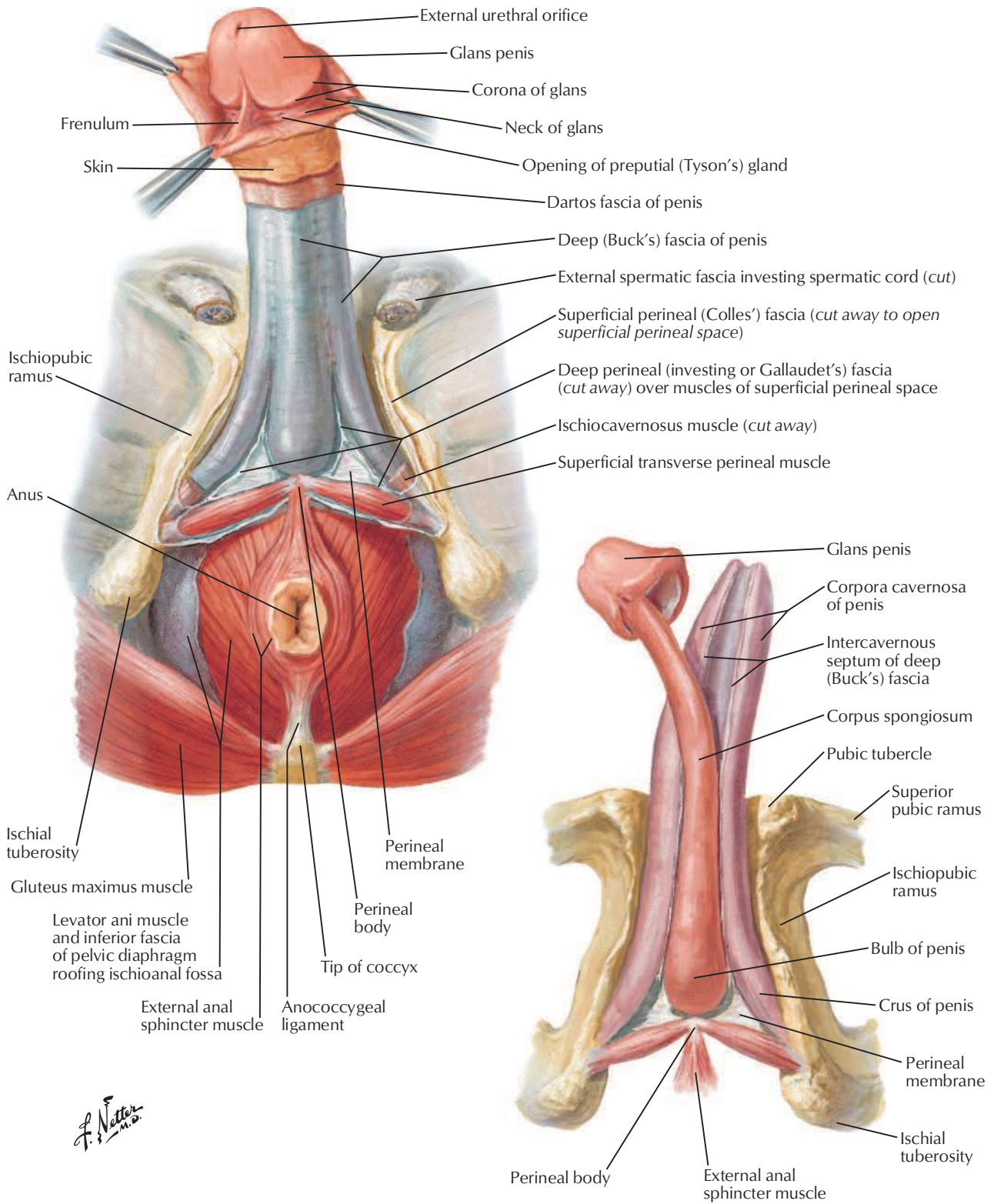
Male Perineum and External Genitalia (Superficial Dissection)



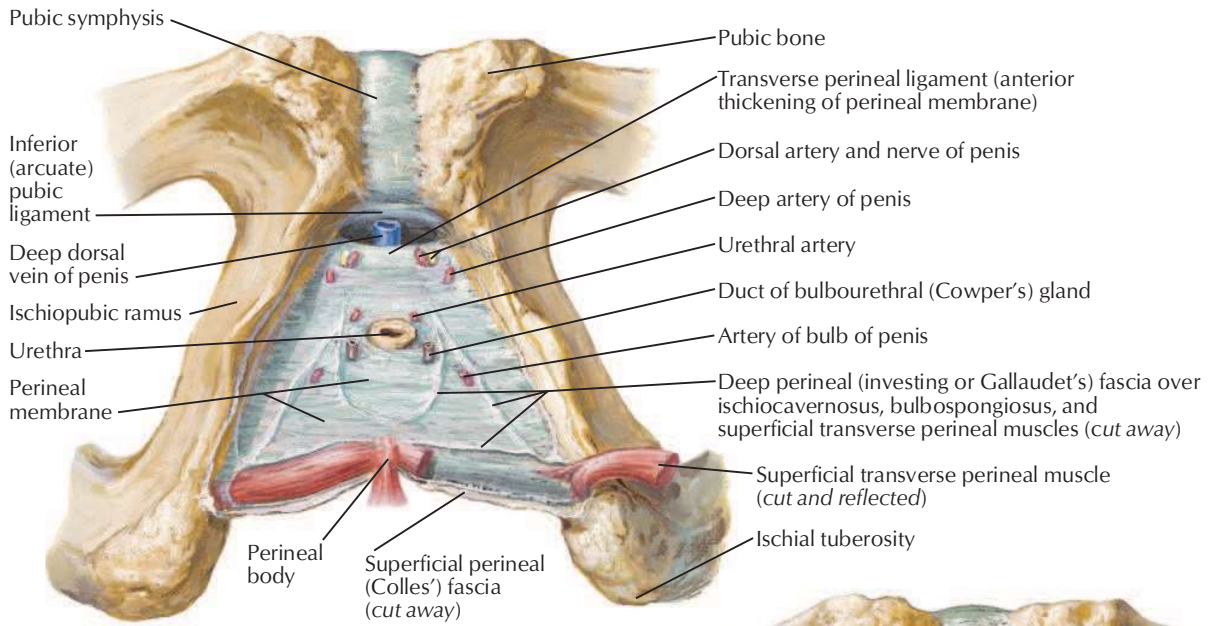


Transverse section through body of penis

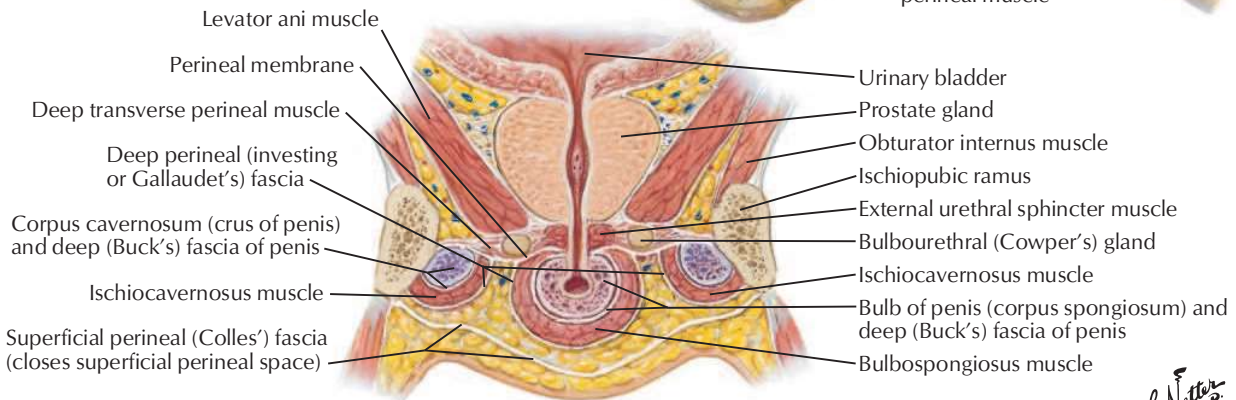
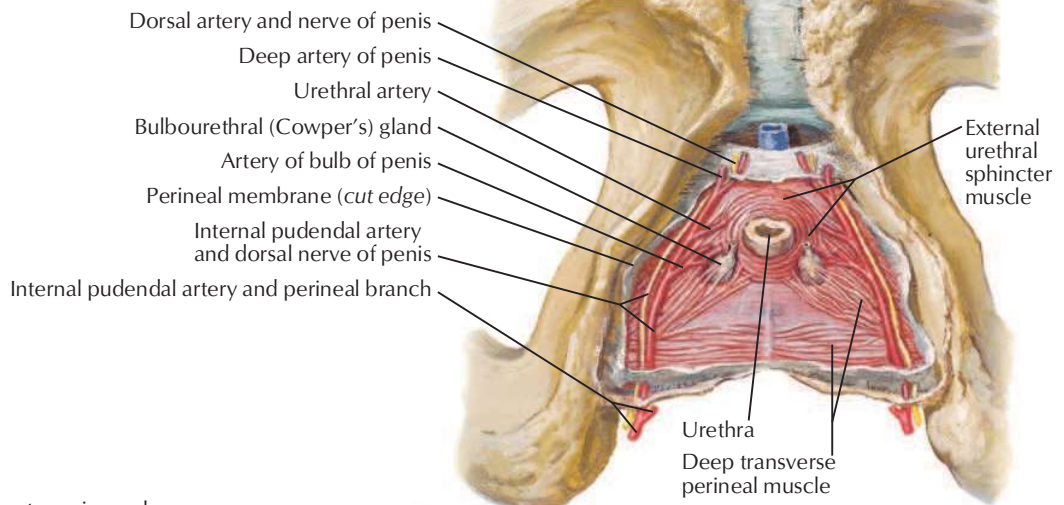
F. Netter M.D.



F. Netter M.D.



Inferior views

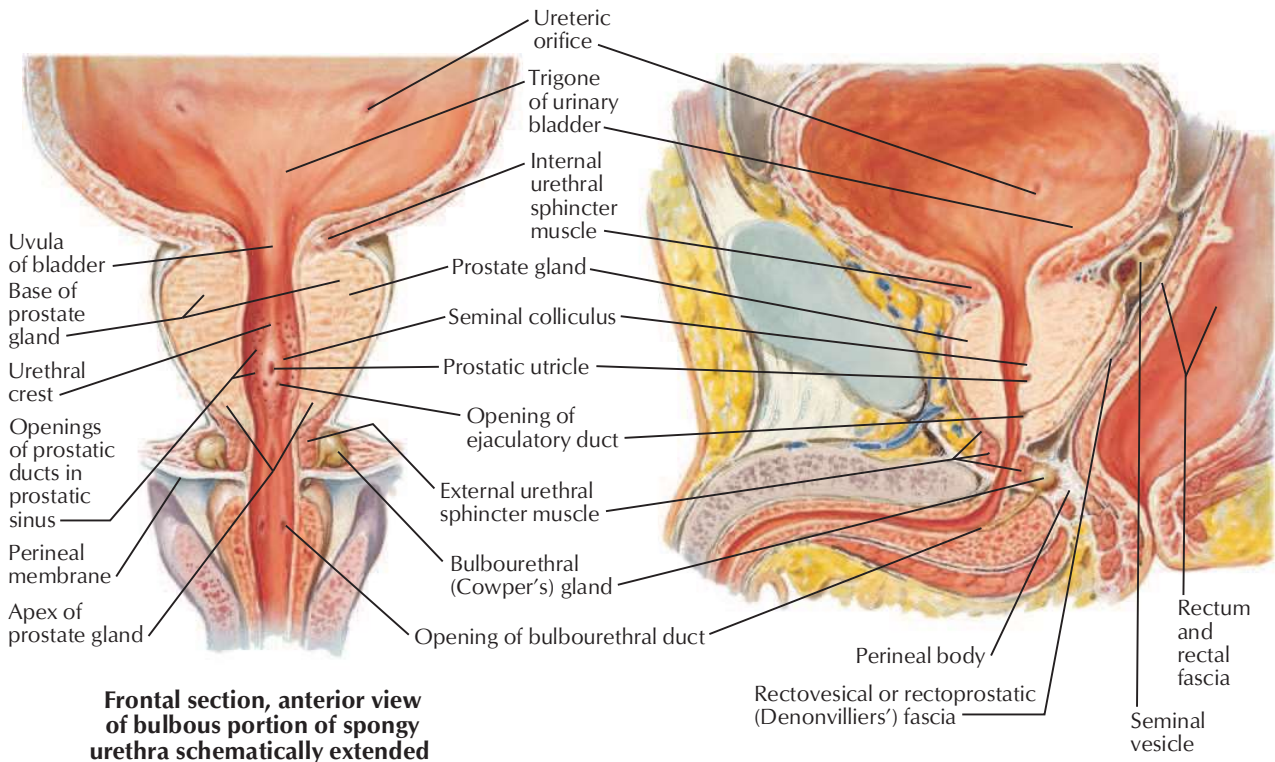


Frontal section, anterior view of perineum: schema

F. Netter M.D.
 C. Machado M.D.

Prostate Gland and Seminal Vesicles

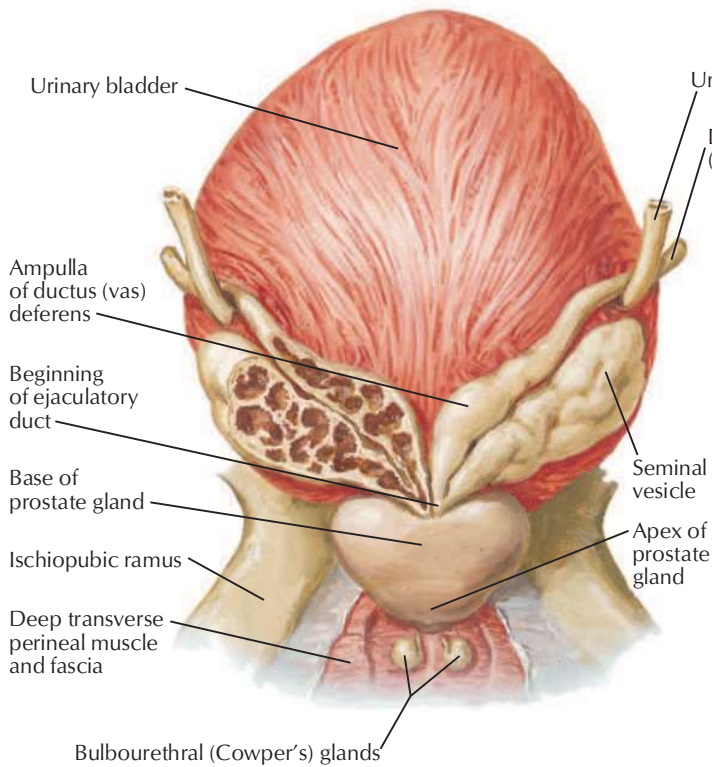
See also [Plates 349, 352, 385](#)



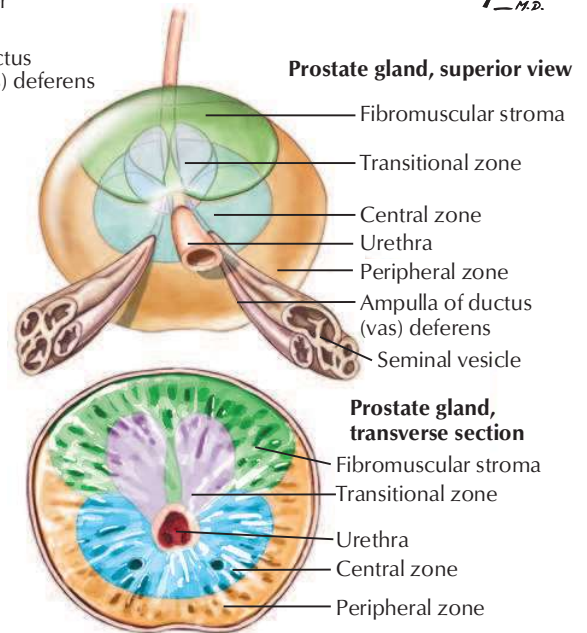
Frontal section, anterior view of bulbous portion of spongy urethra schematically extended

Sagittal section

F. Netter M.D.
C. Machado M.D.



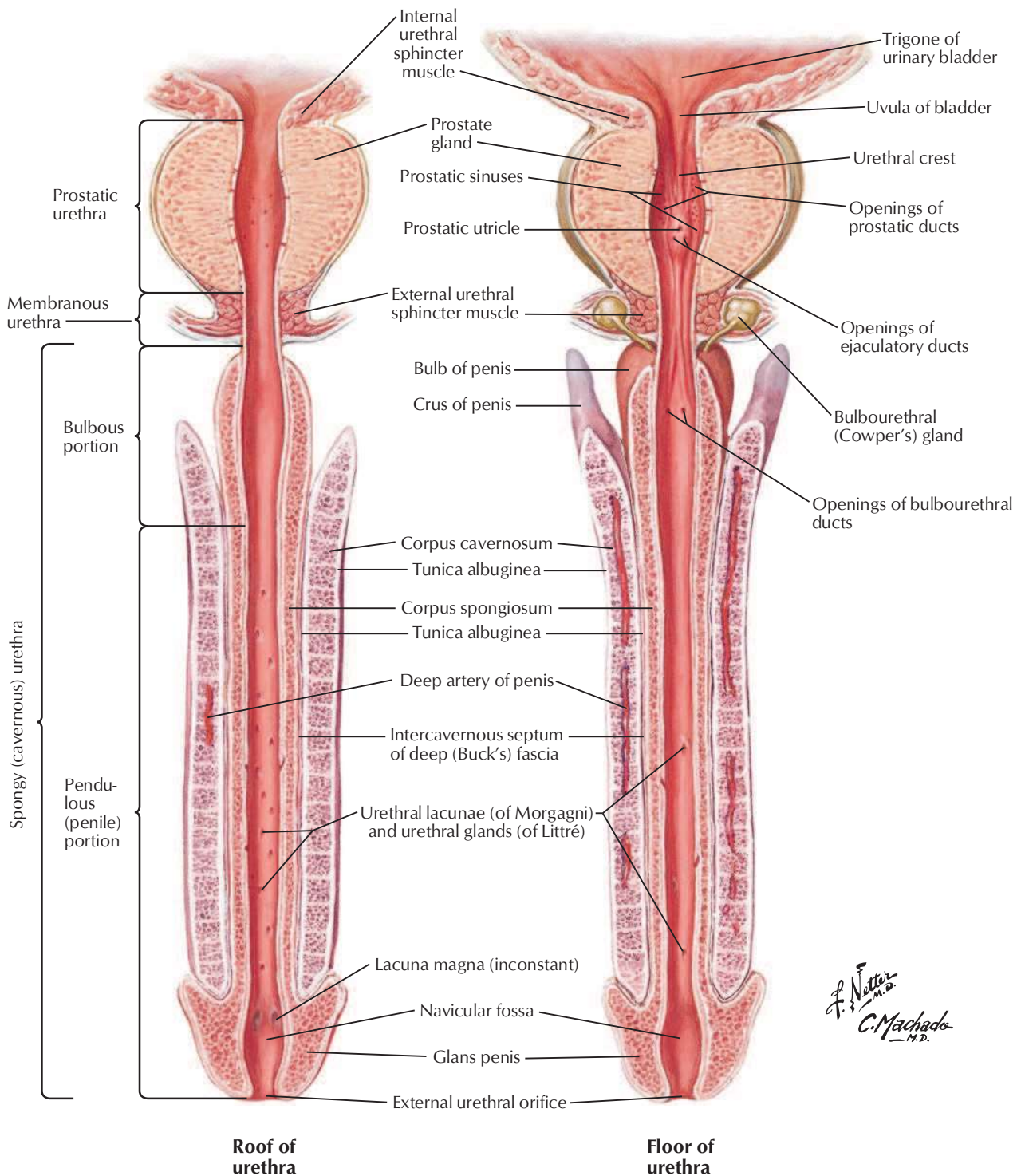
Posterior view

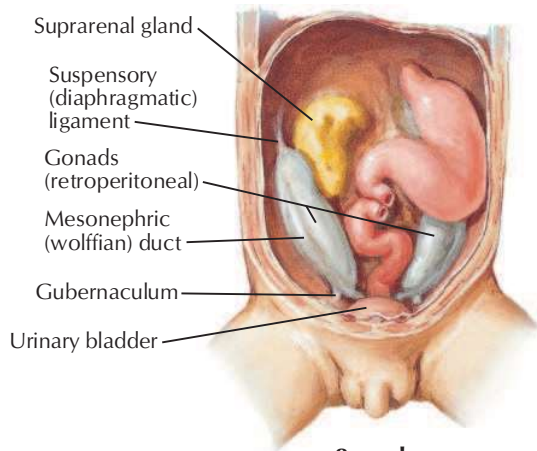


Prostate gland, superior view

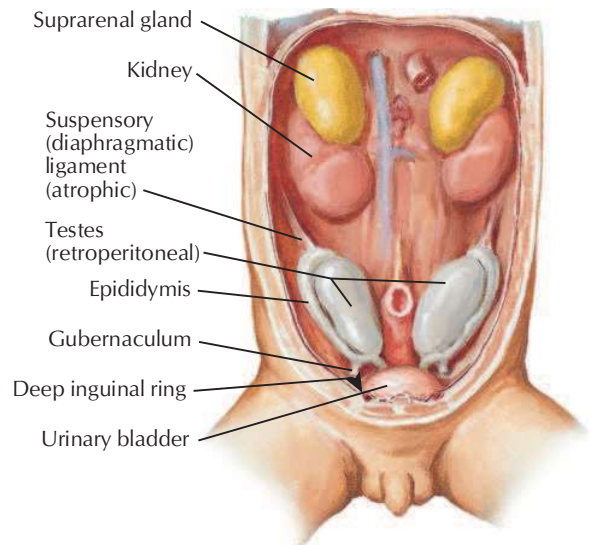
Prostate gland, transverse section

Posterior view

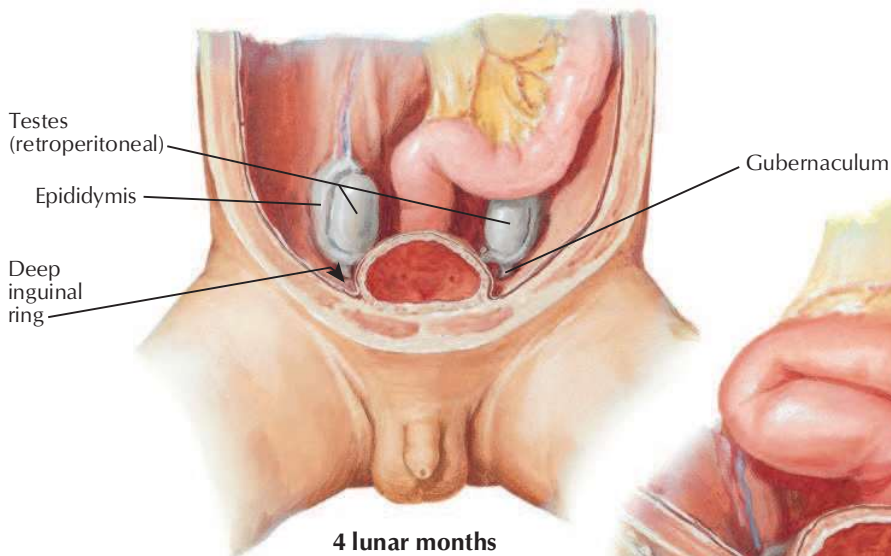




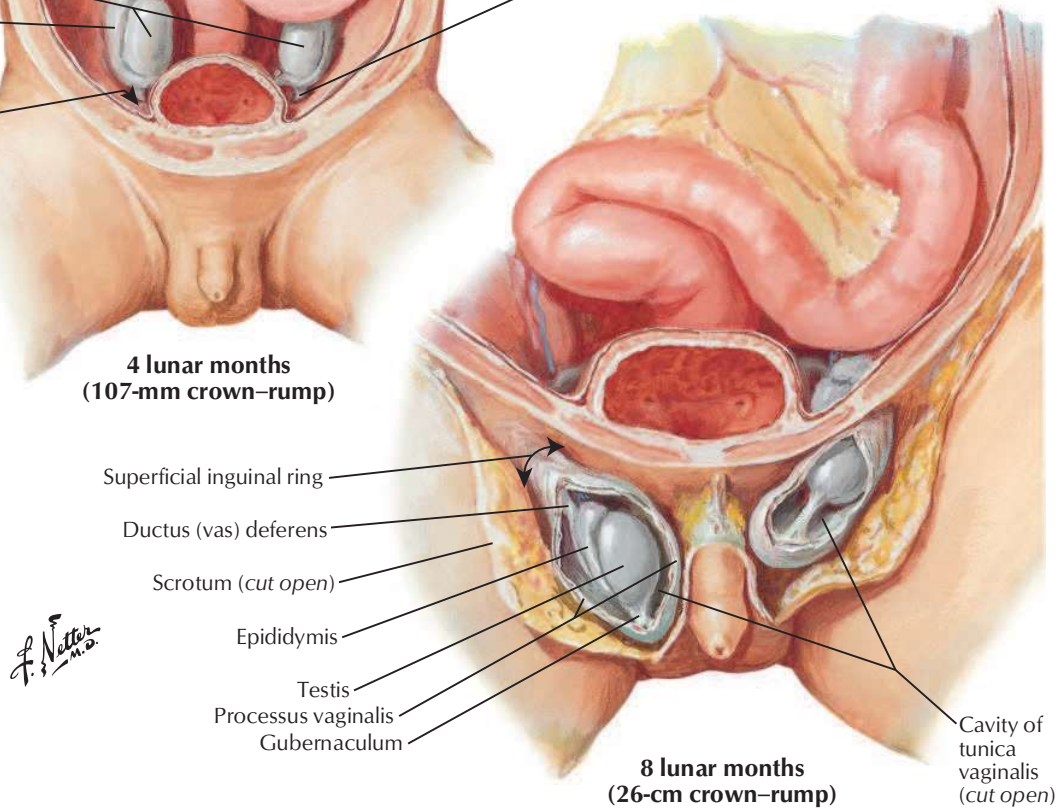
8 weeks
(22.5-mm crown-rump)



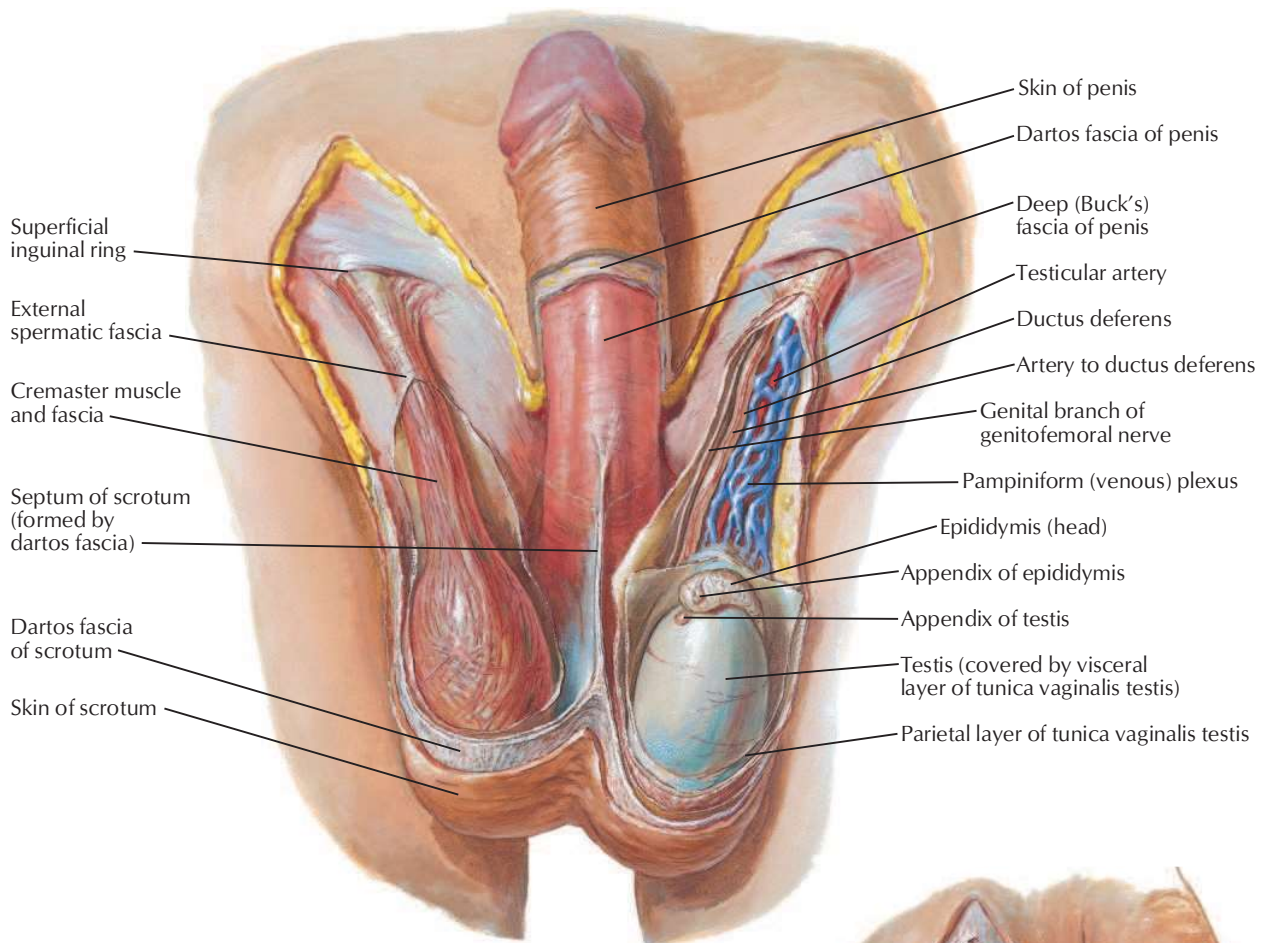
11 weeks
(43-mm crown-rump)



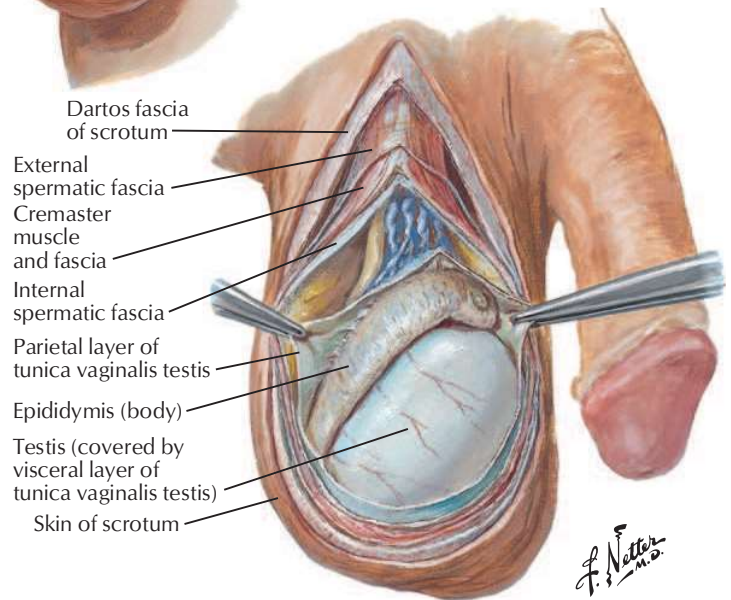
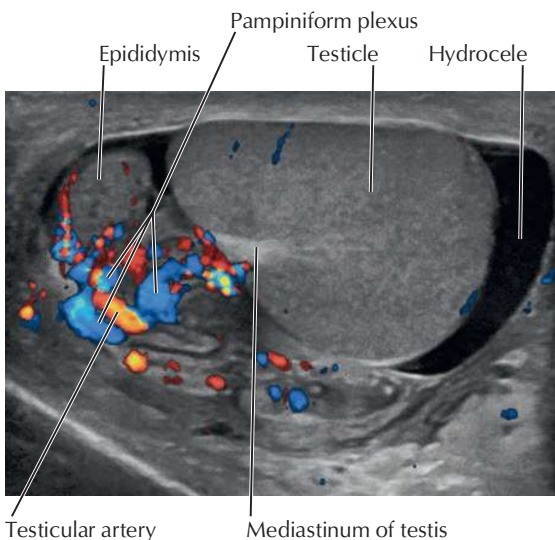
4 lunar months
(107-mm crown-rump)

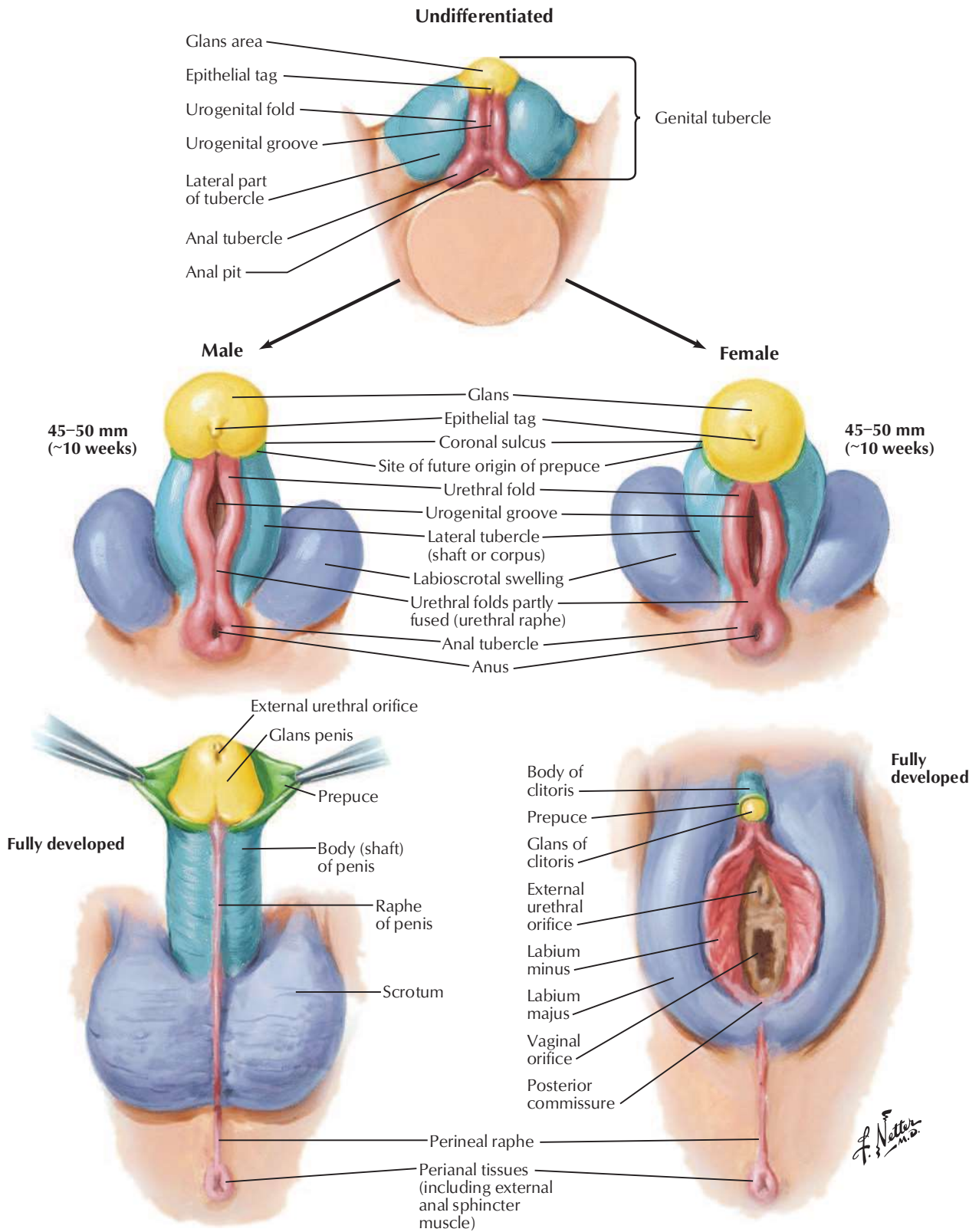


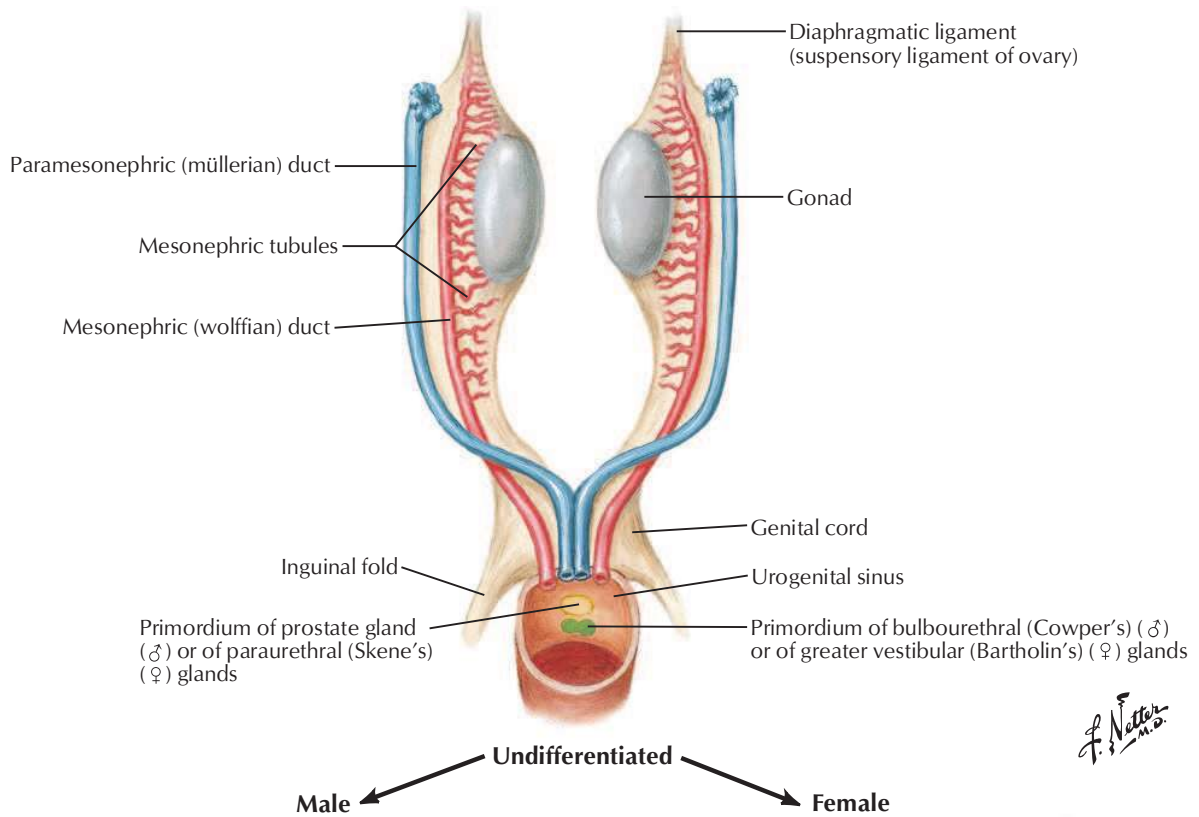
8 lunar months
(26-cm crown-rump)



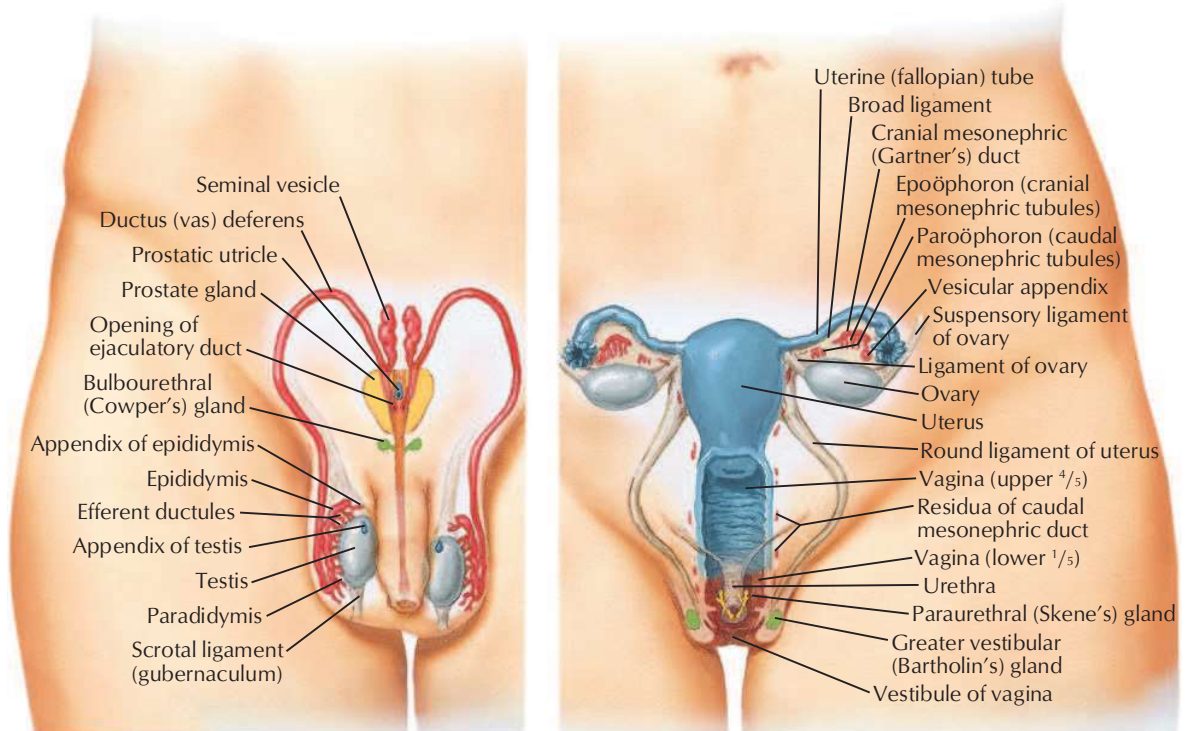
**Color Doppler ultrasound:
 transverse view of testicle**

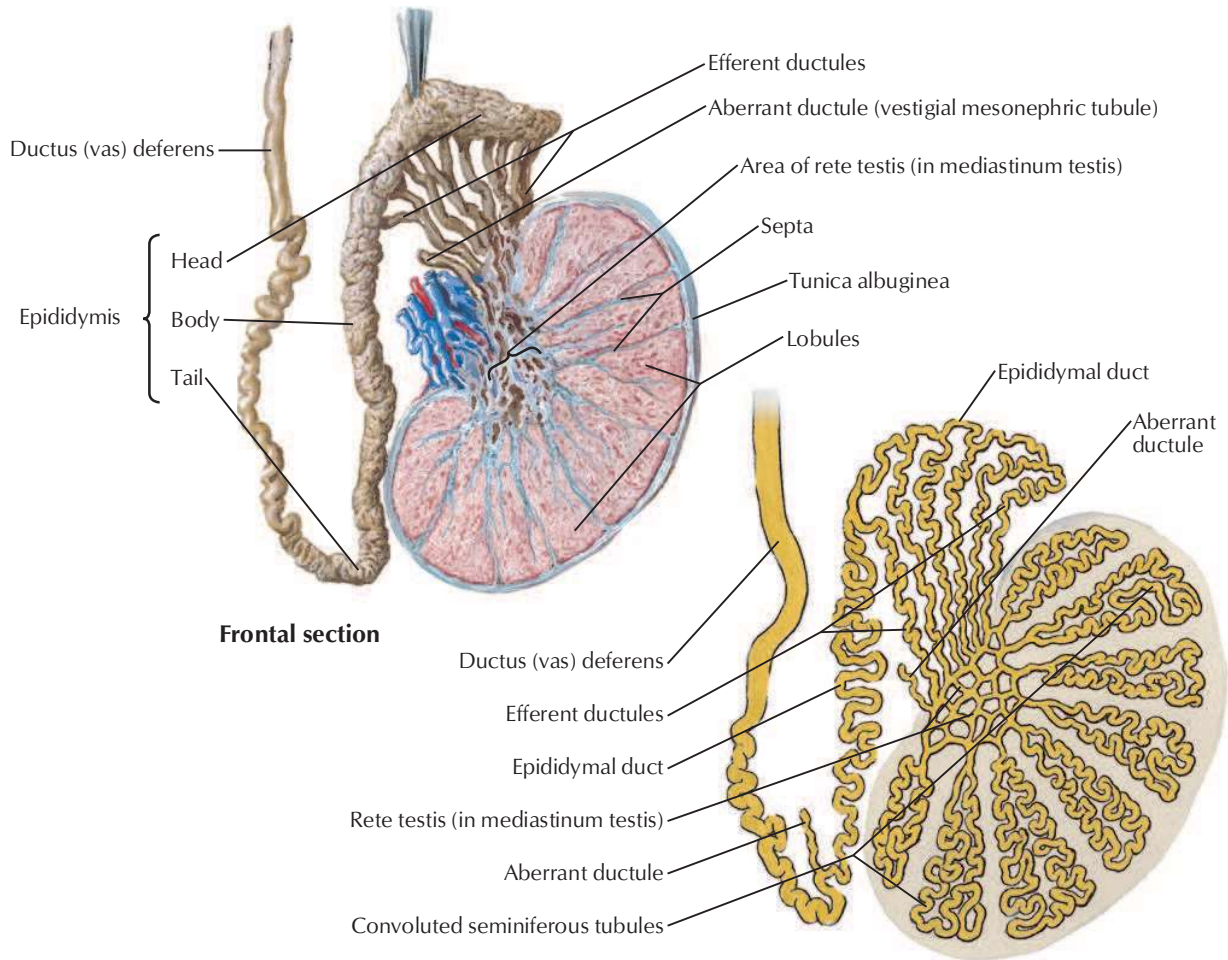






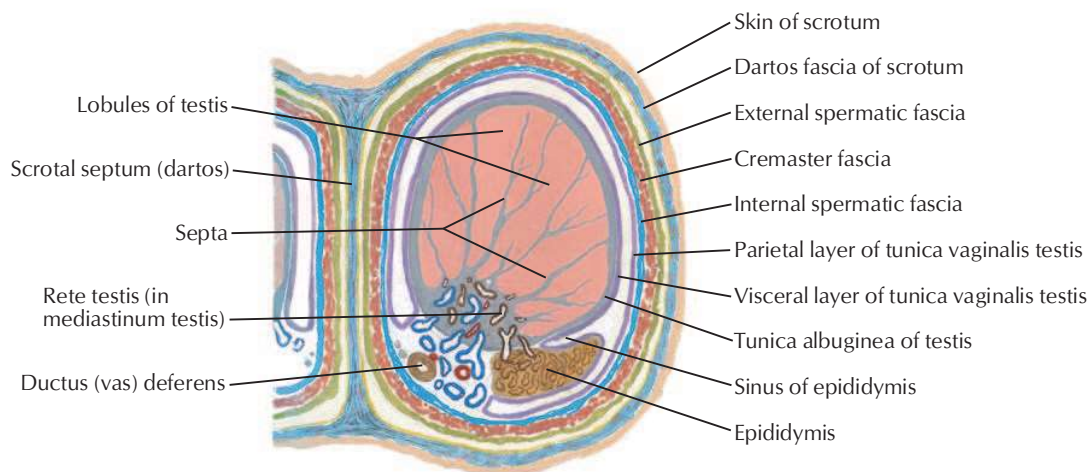
F. Netter M.D.



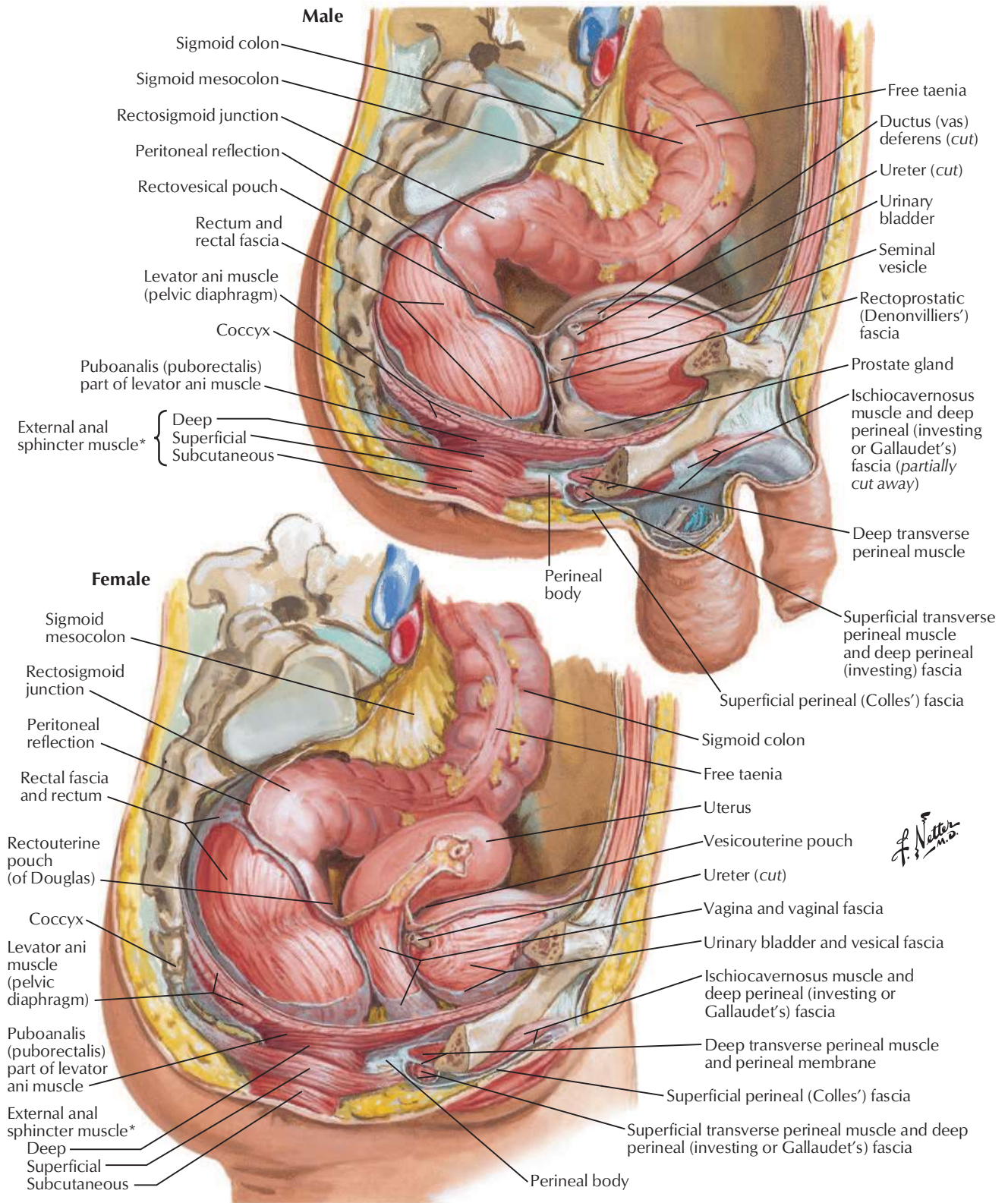


Frontal section

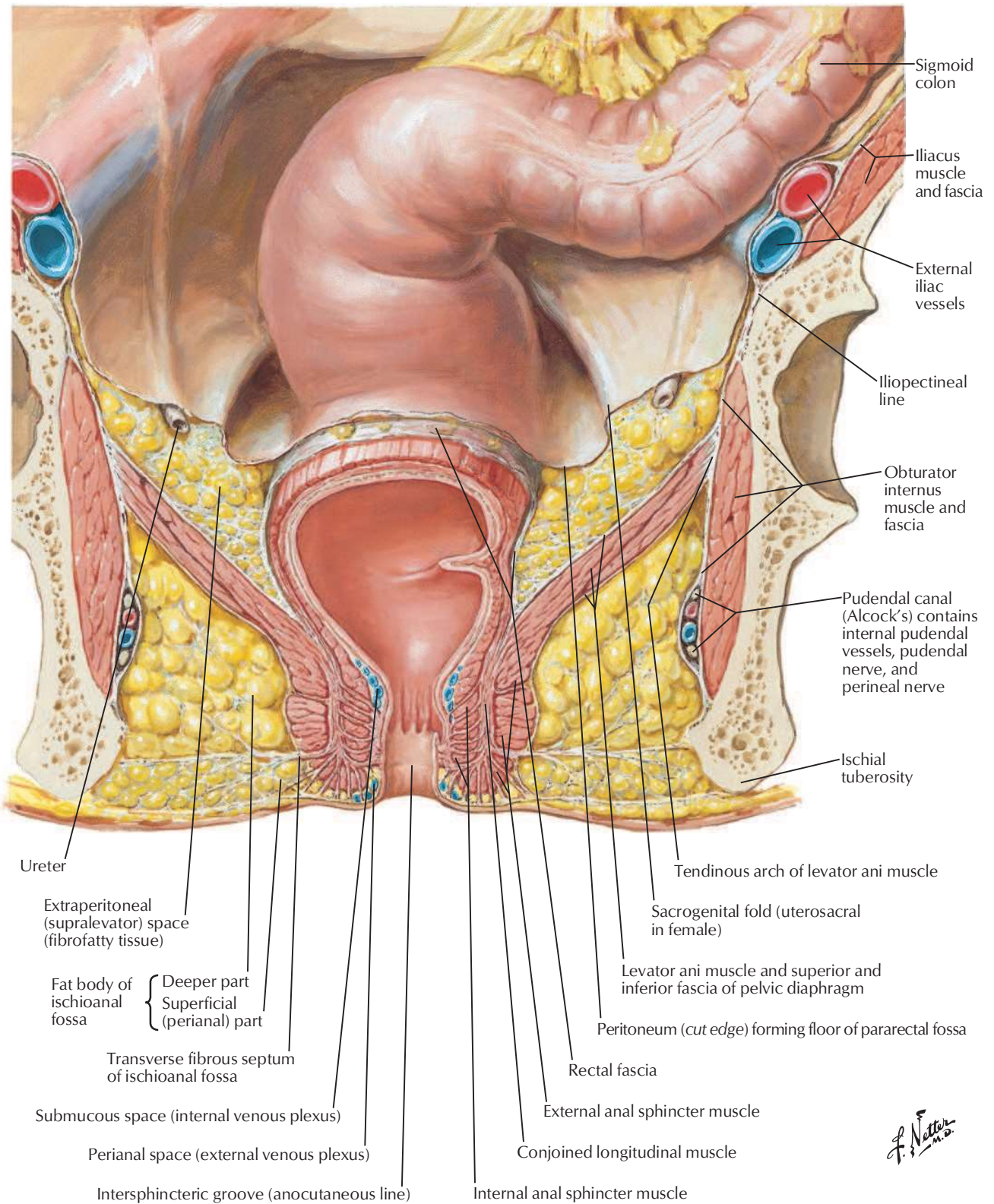
Schema

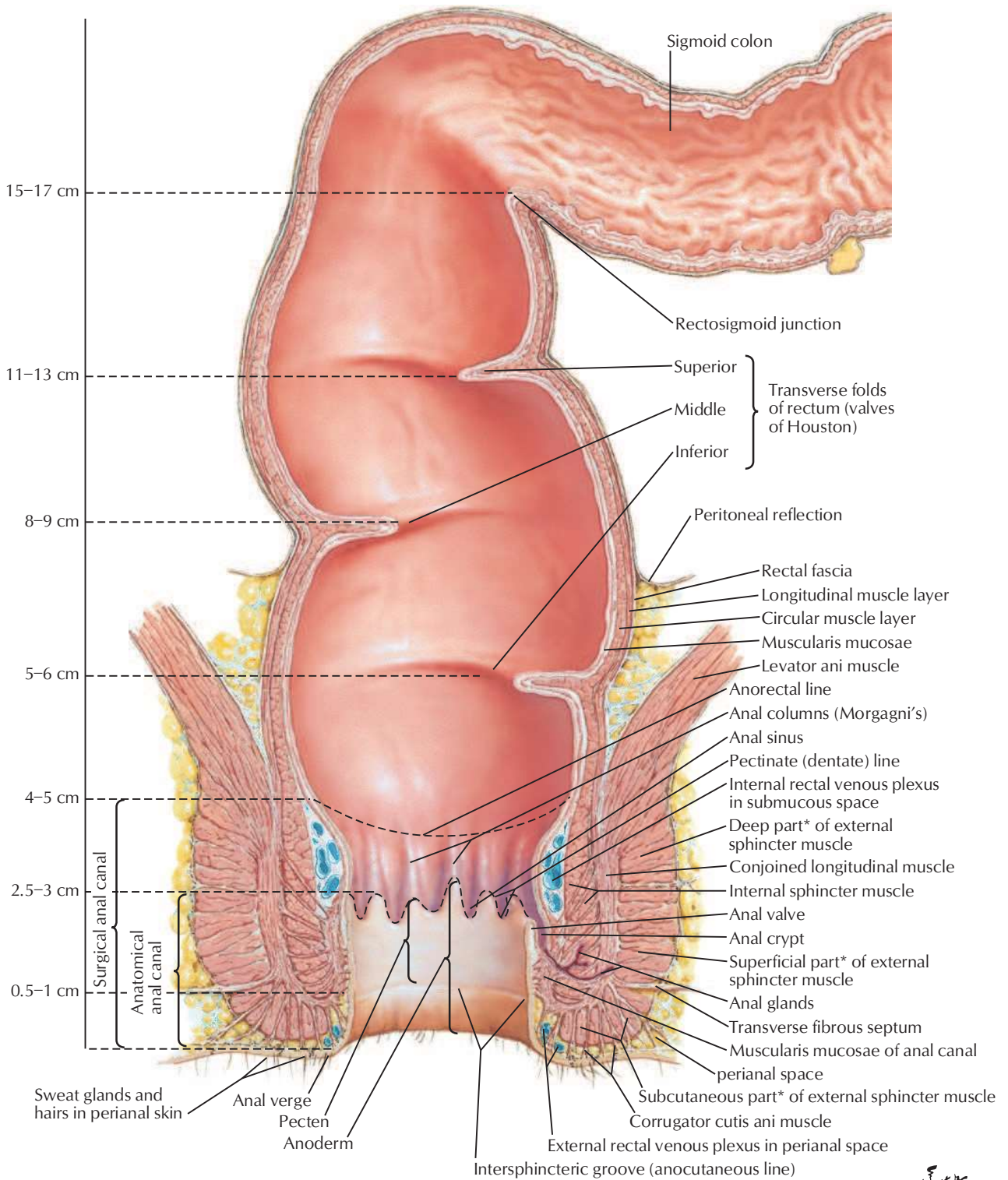


Cross section through scrotum and testis



*Parts variable and often indistinct



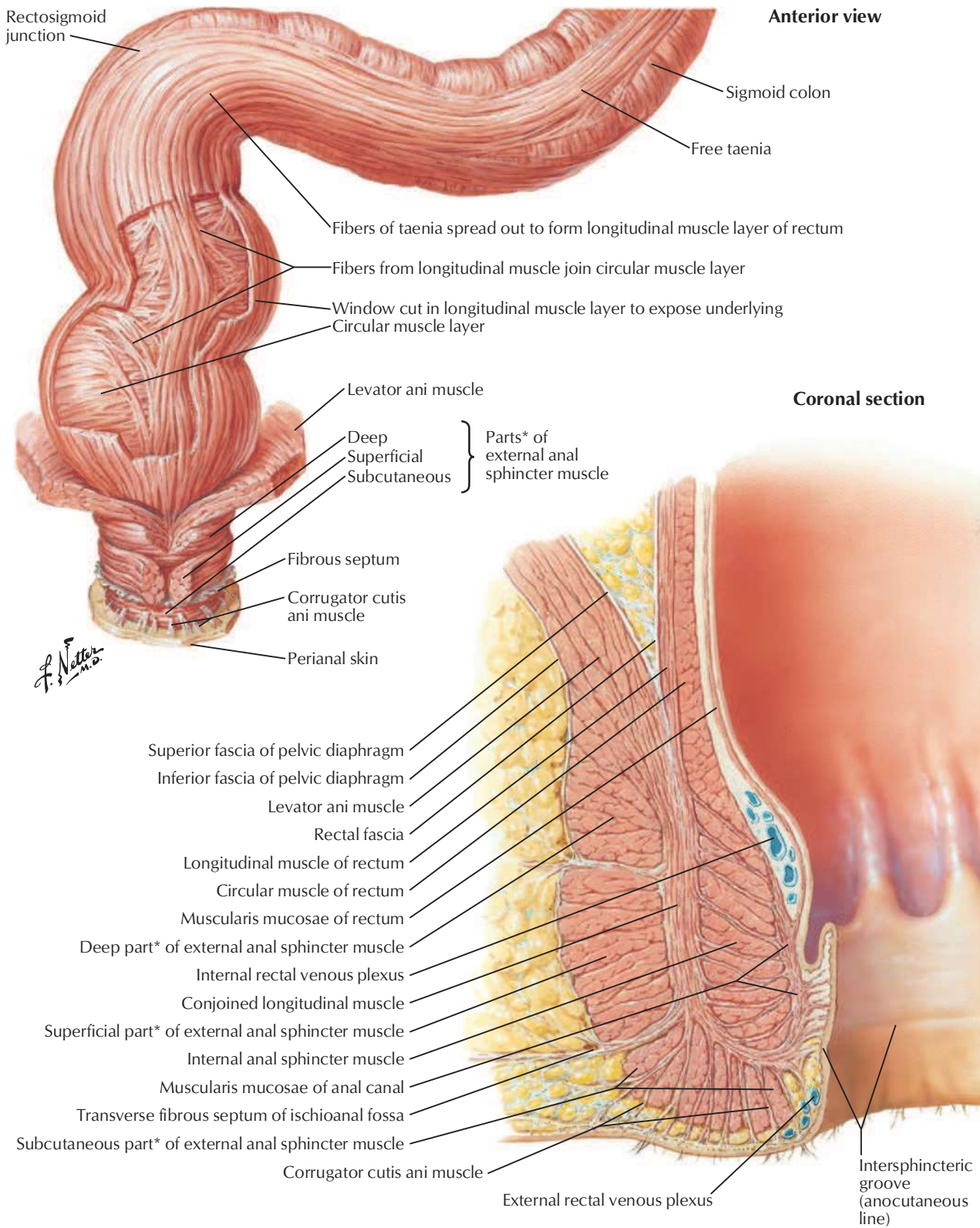


*Parts variable and often indistinct

F. Netter M.D.

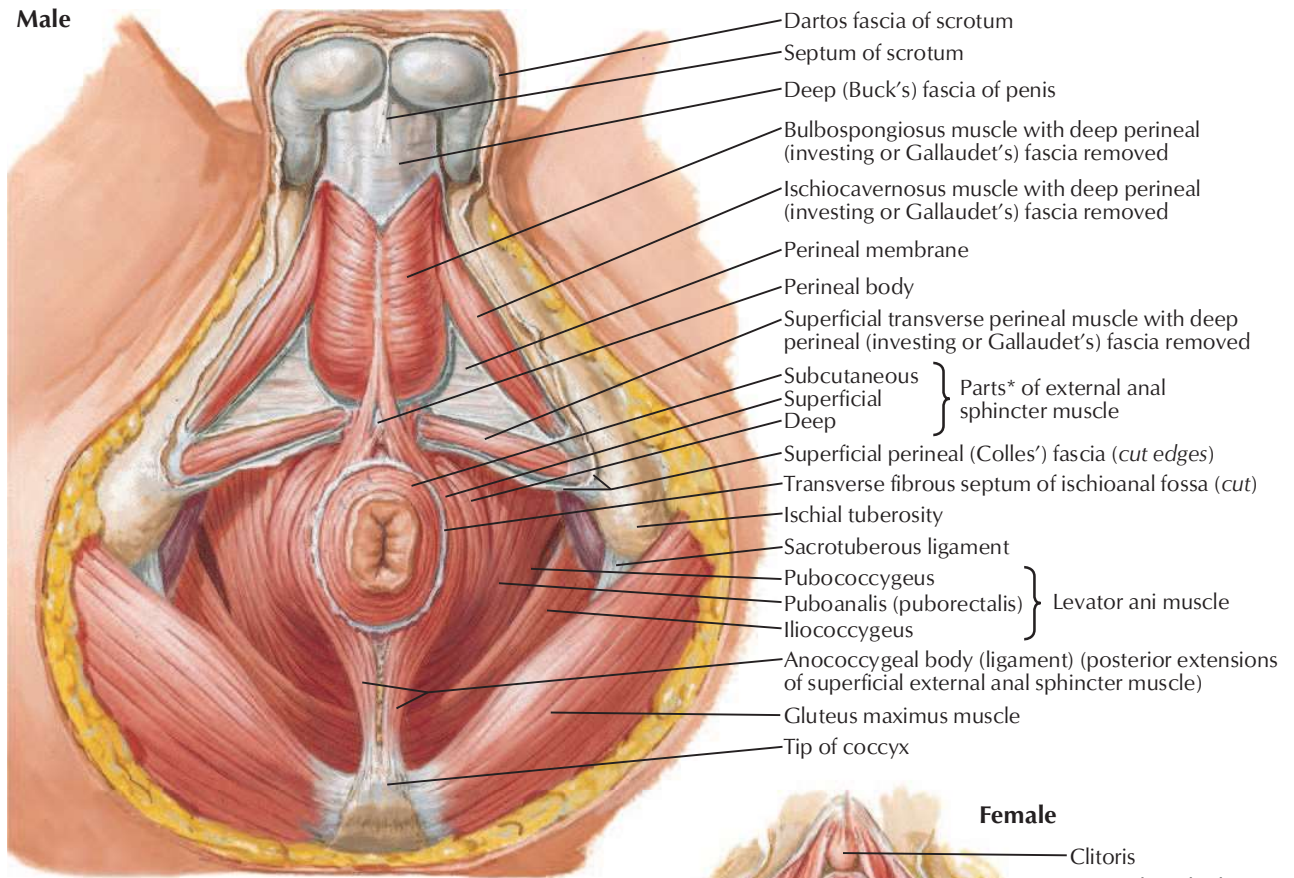
Anorectal Musculature

See also [Plate 381](#)

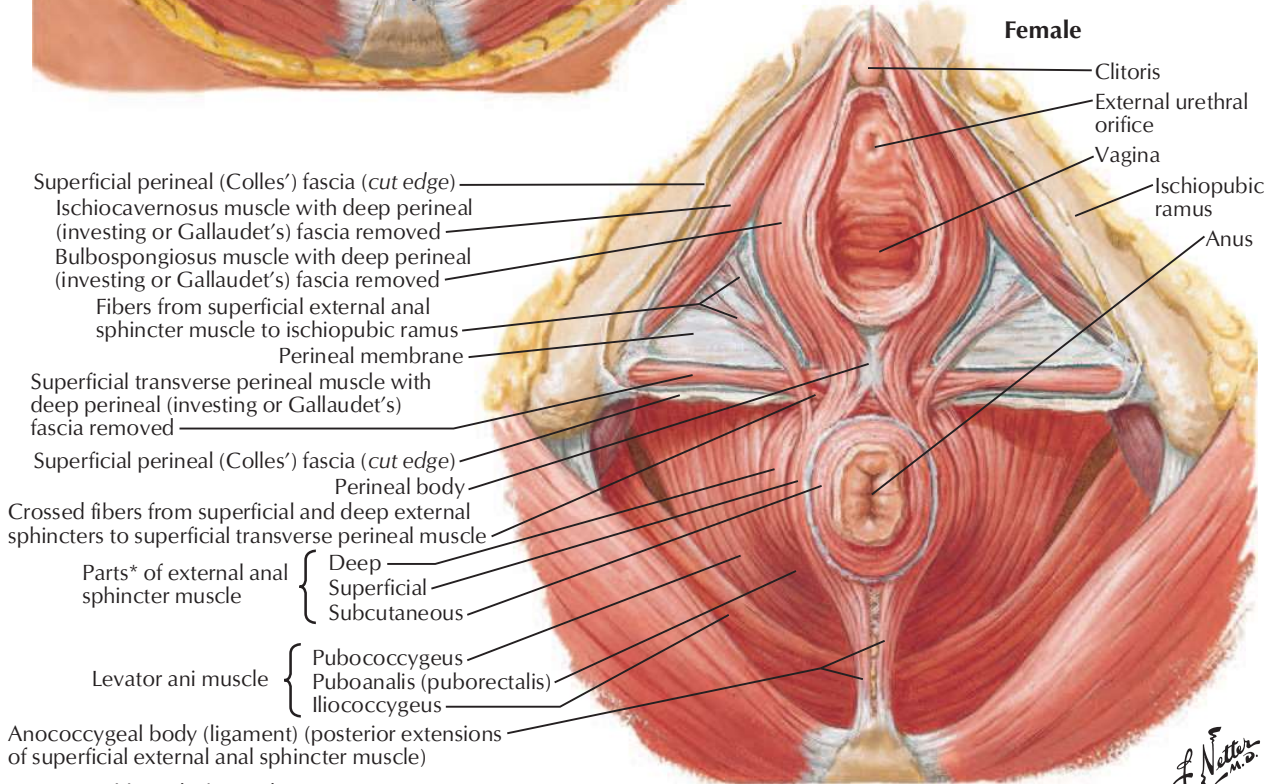


*Parts variable and often indistinct

Male



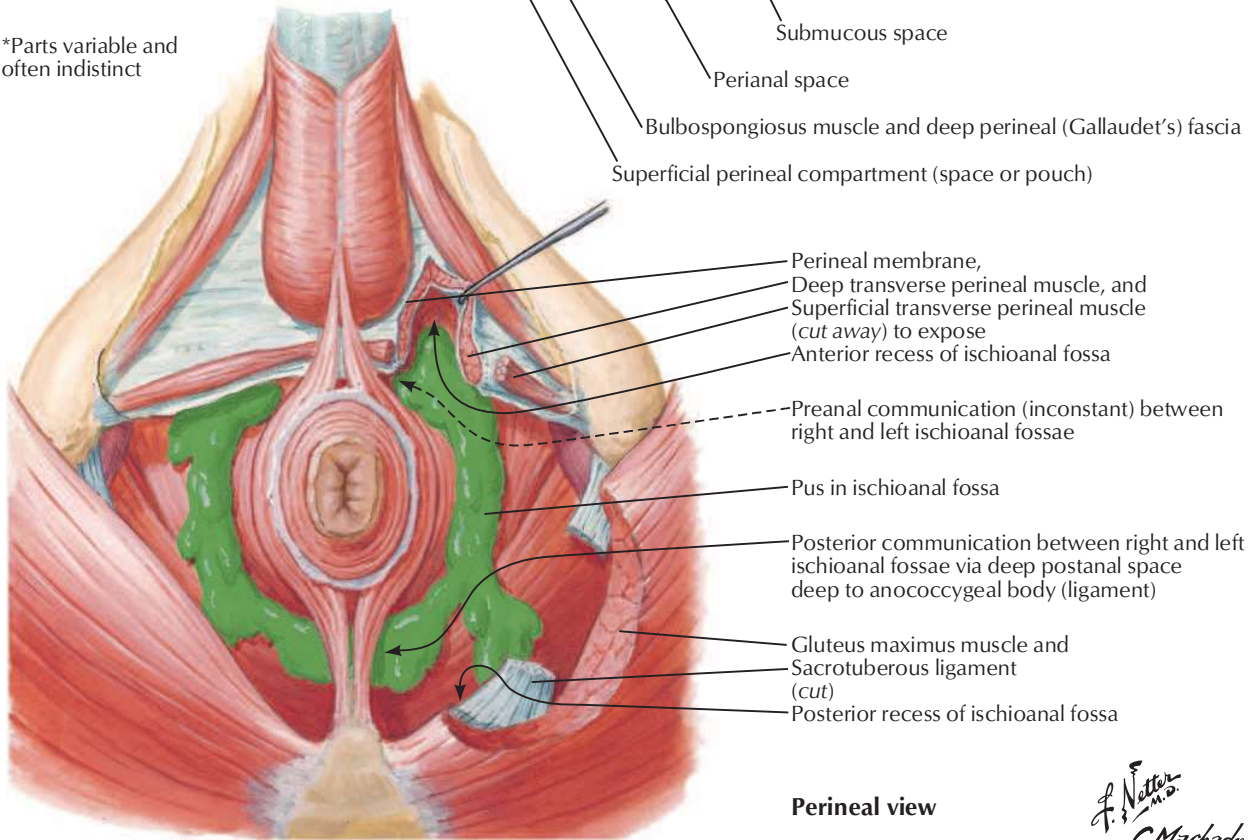
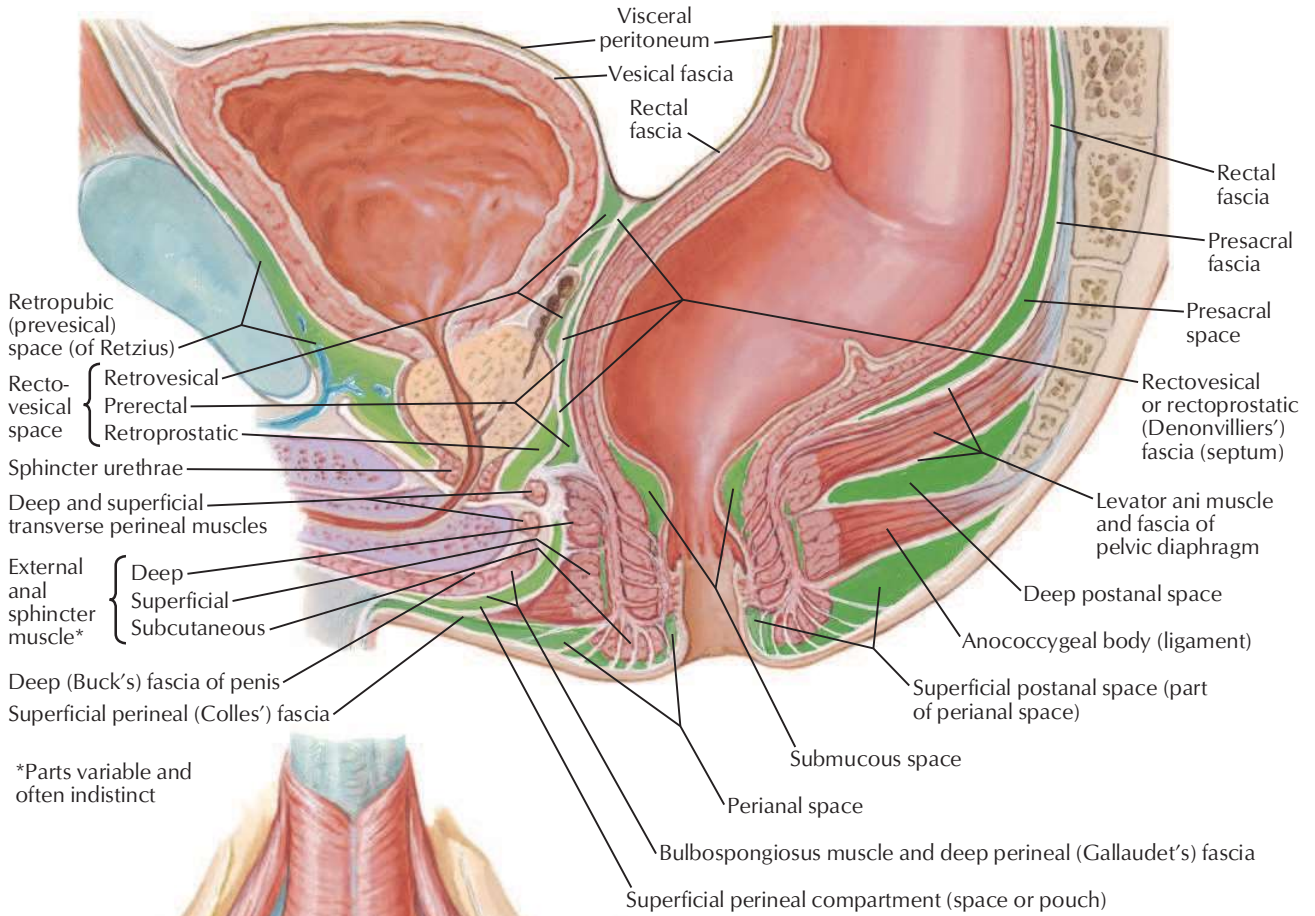
Female



F. Netter M.D.

*Parts variable and often indistinct

Sagittal section

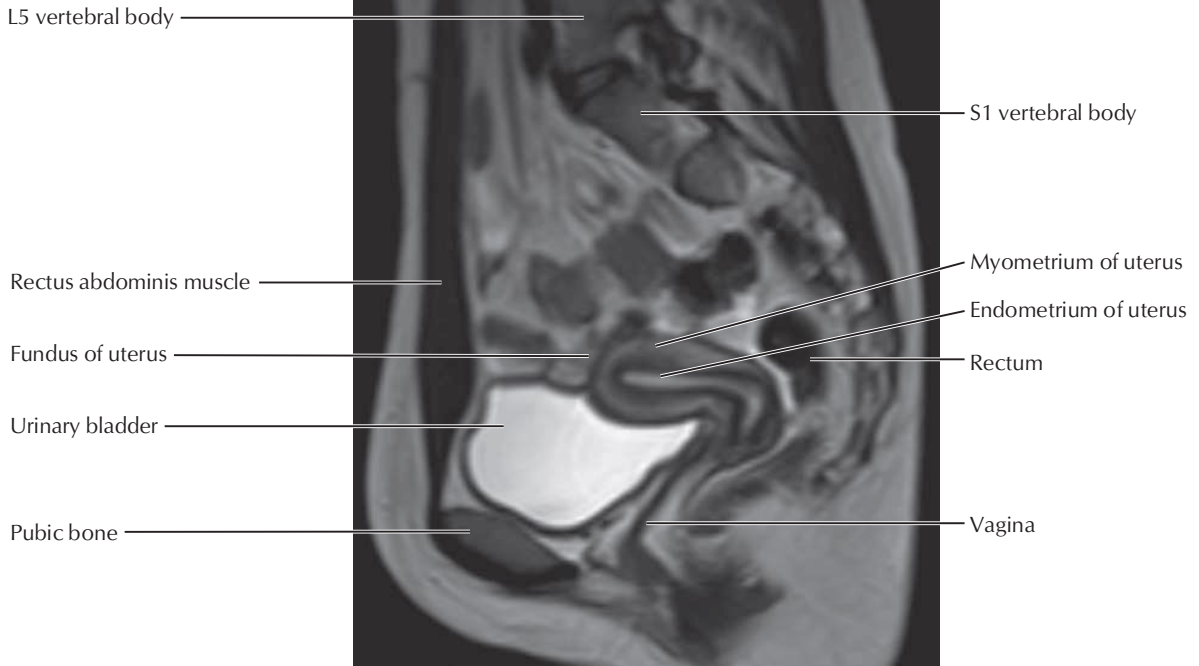


Perineal view

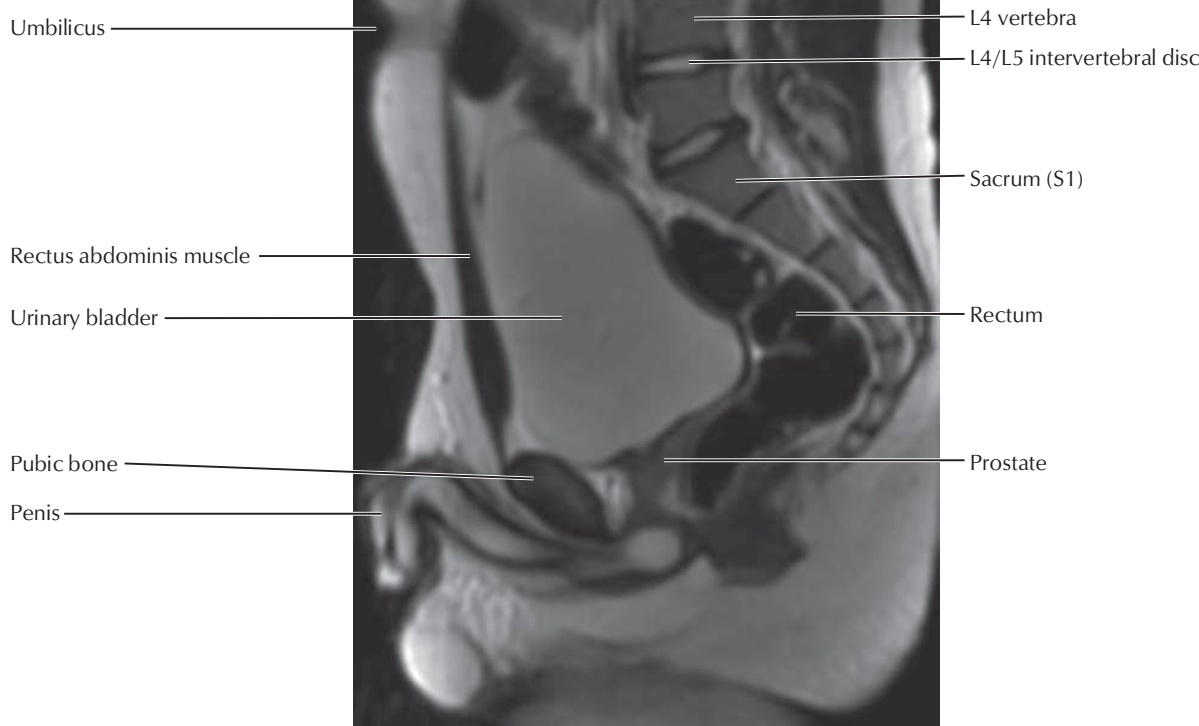
F. Netter M.D.
 C. Machado M.D.

Spread of perineal abscess in perineal spaces

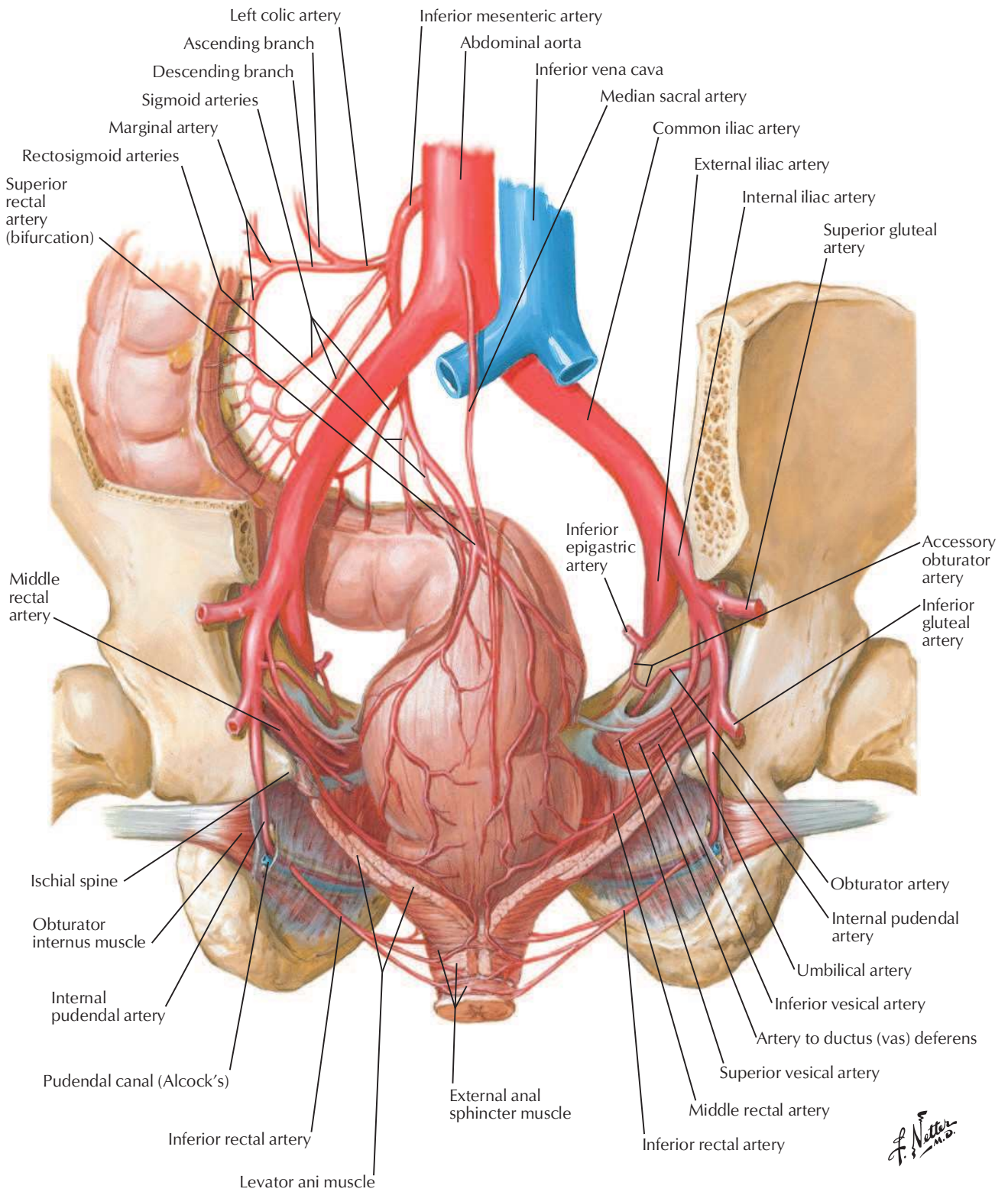
MRI of female pelvis (without intravenous contrast medium)

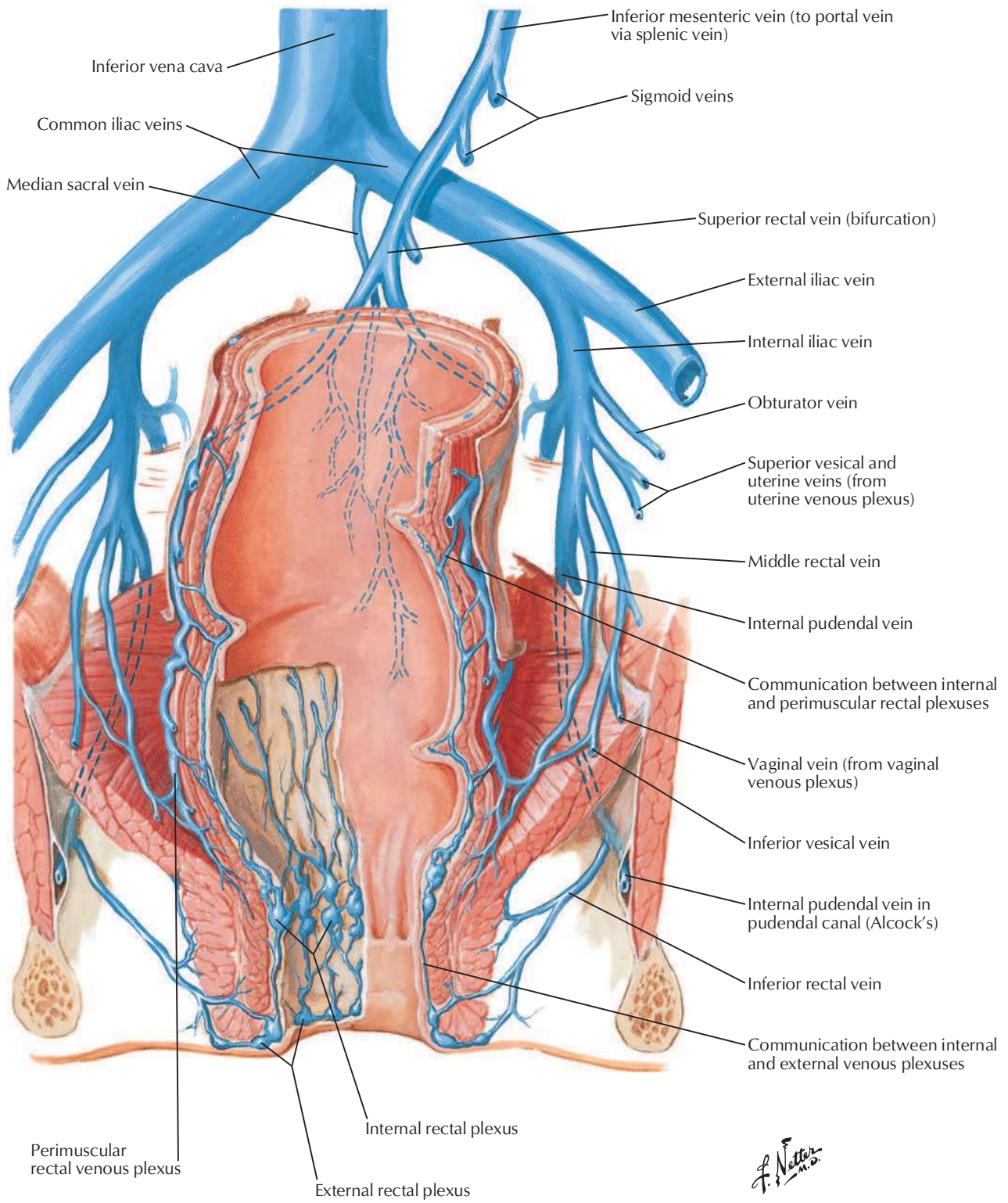


MRI of male pelvis (without intravenous contrast medium)

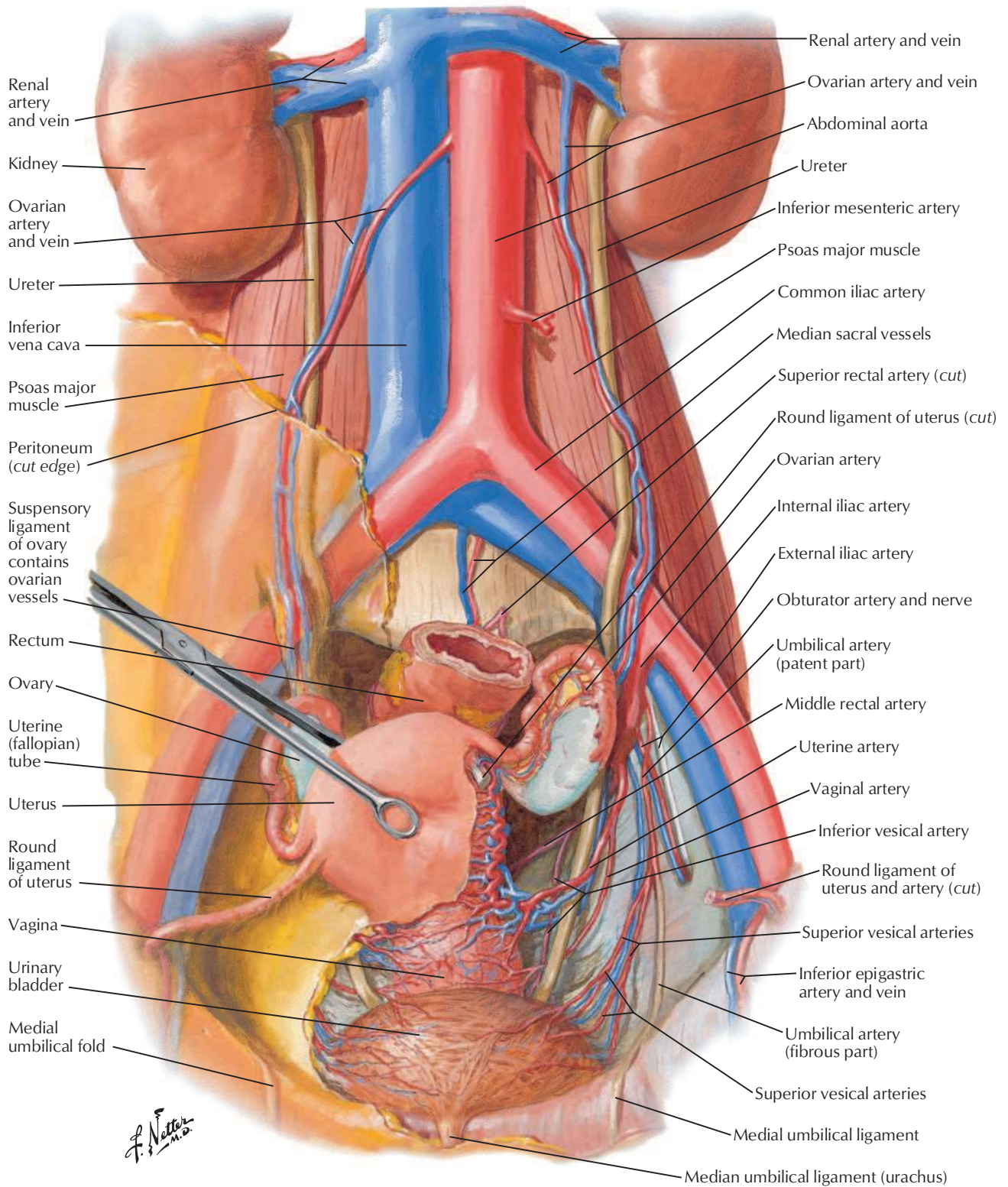


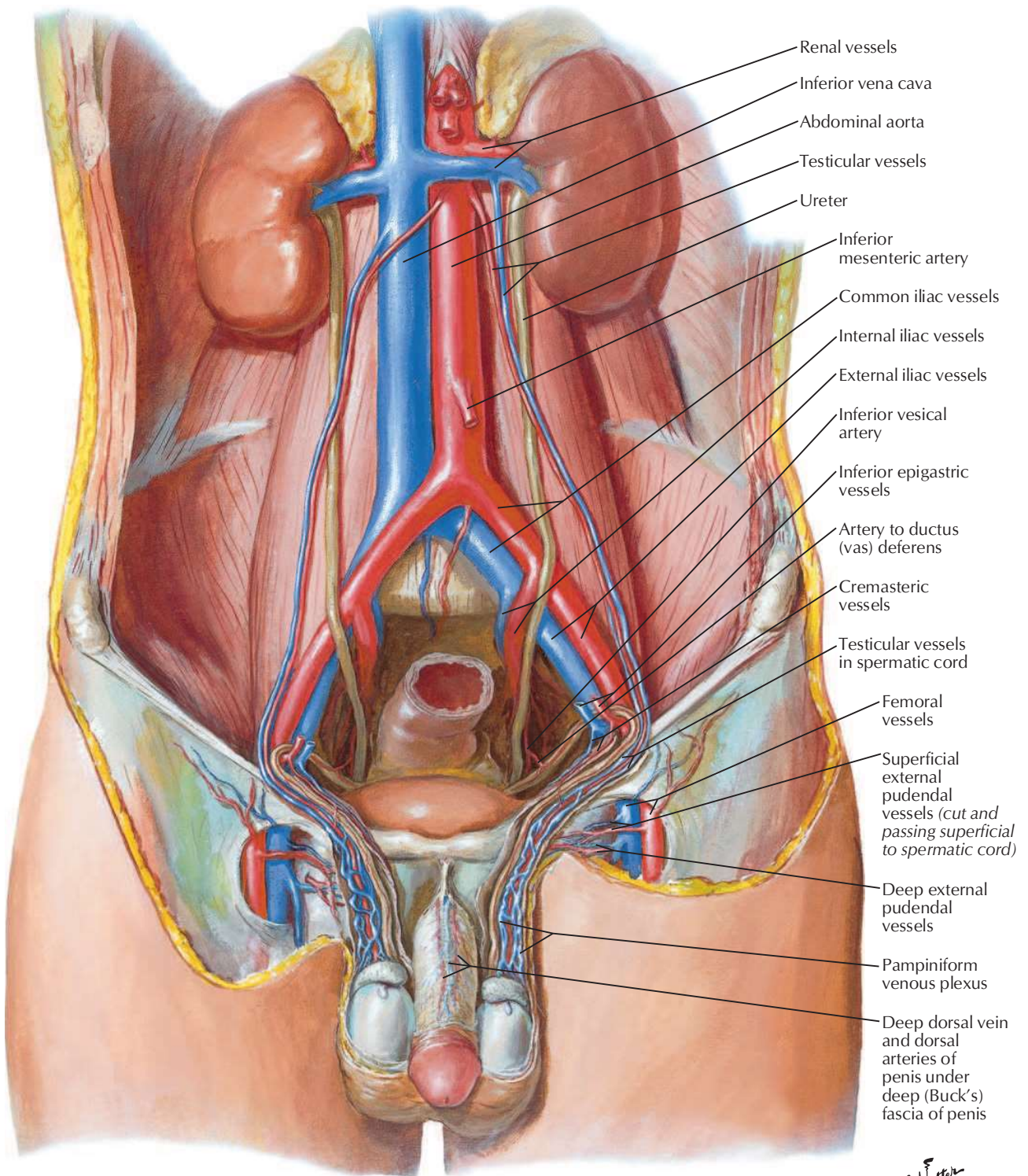
Arteries of Rectum and Anal Canal: Male Posterior View



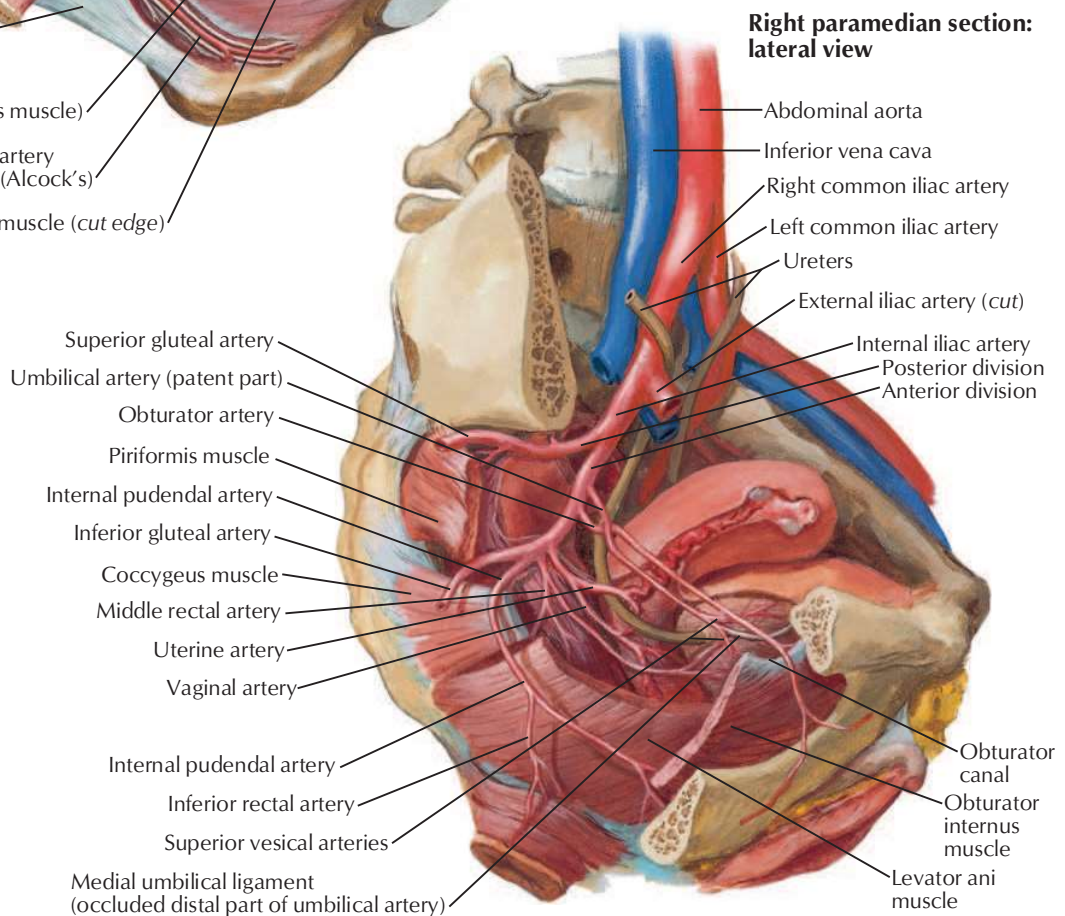
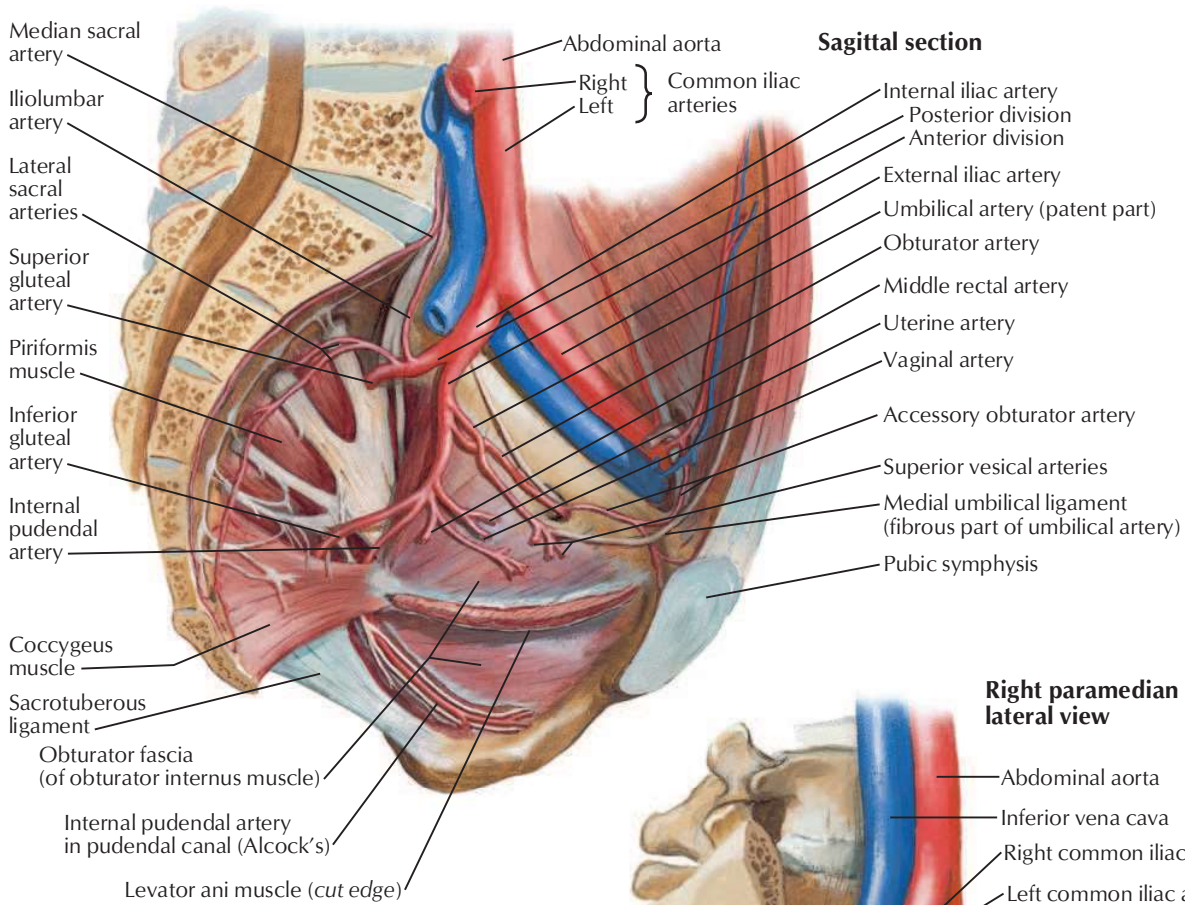


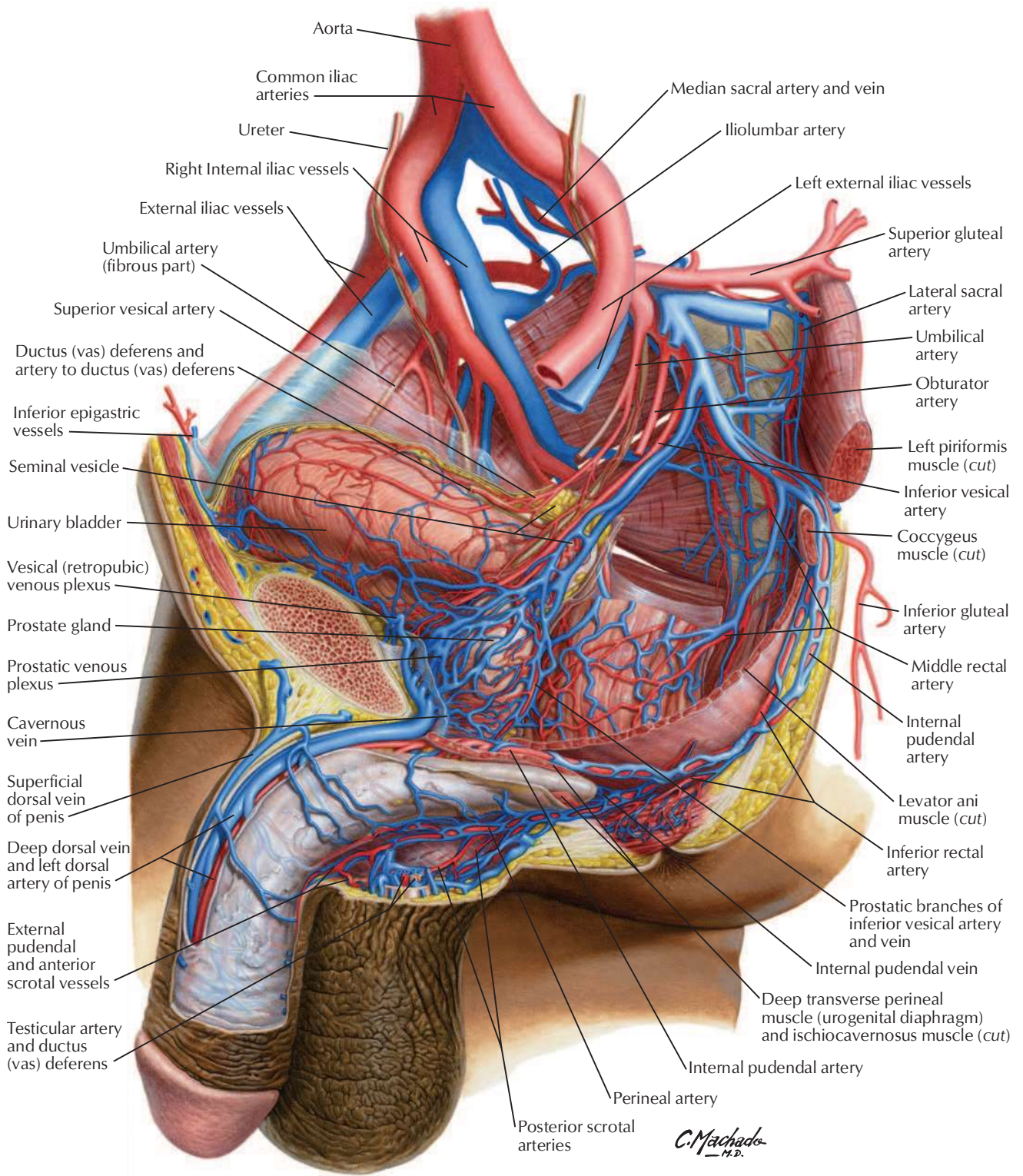
Arteries and Veins of Pelvic Organs: Female Anterior View



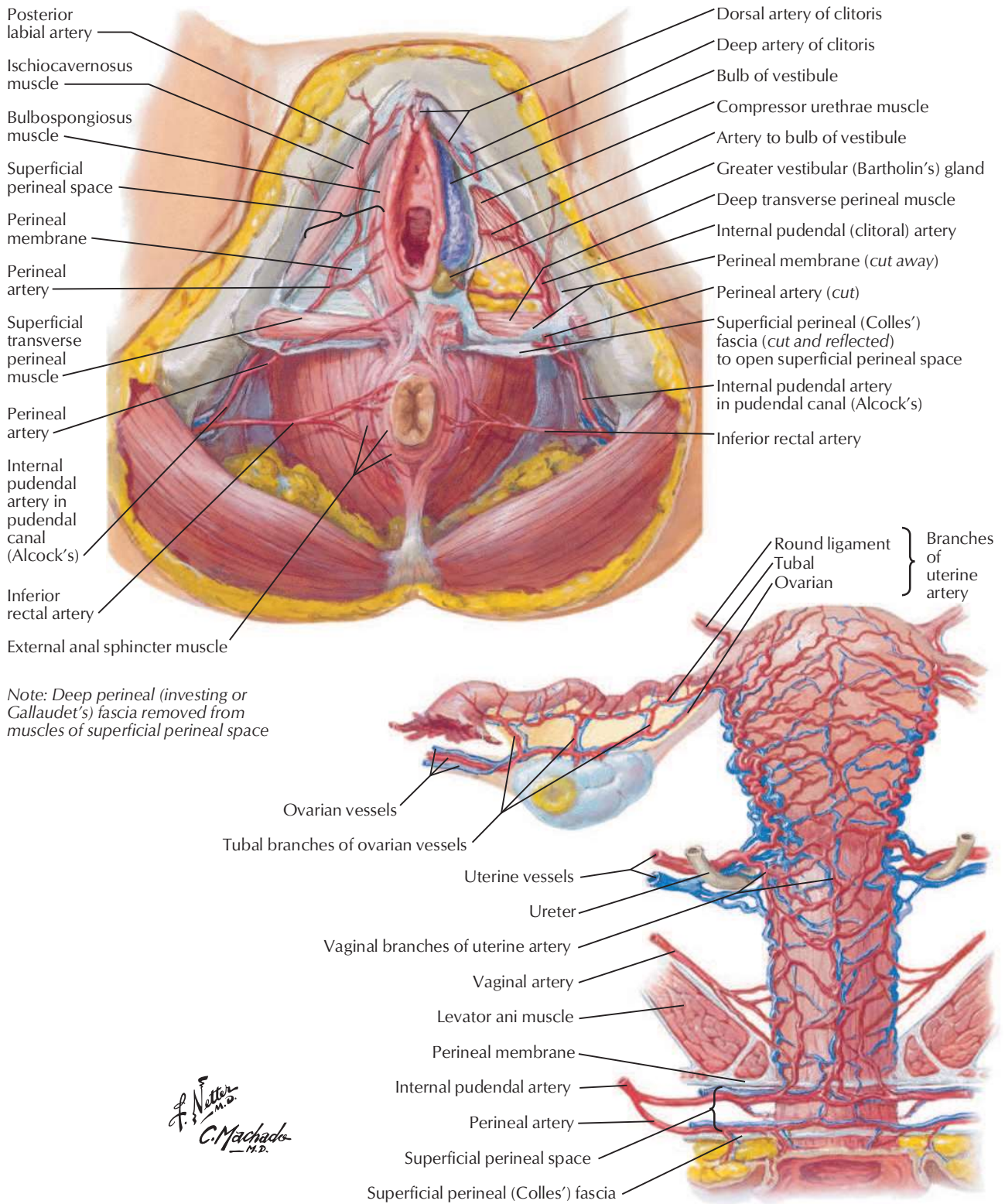


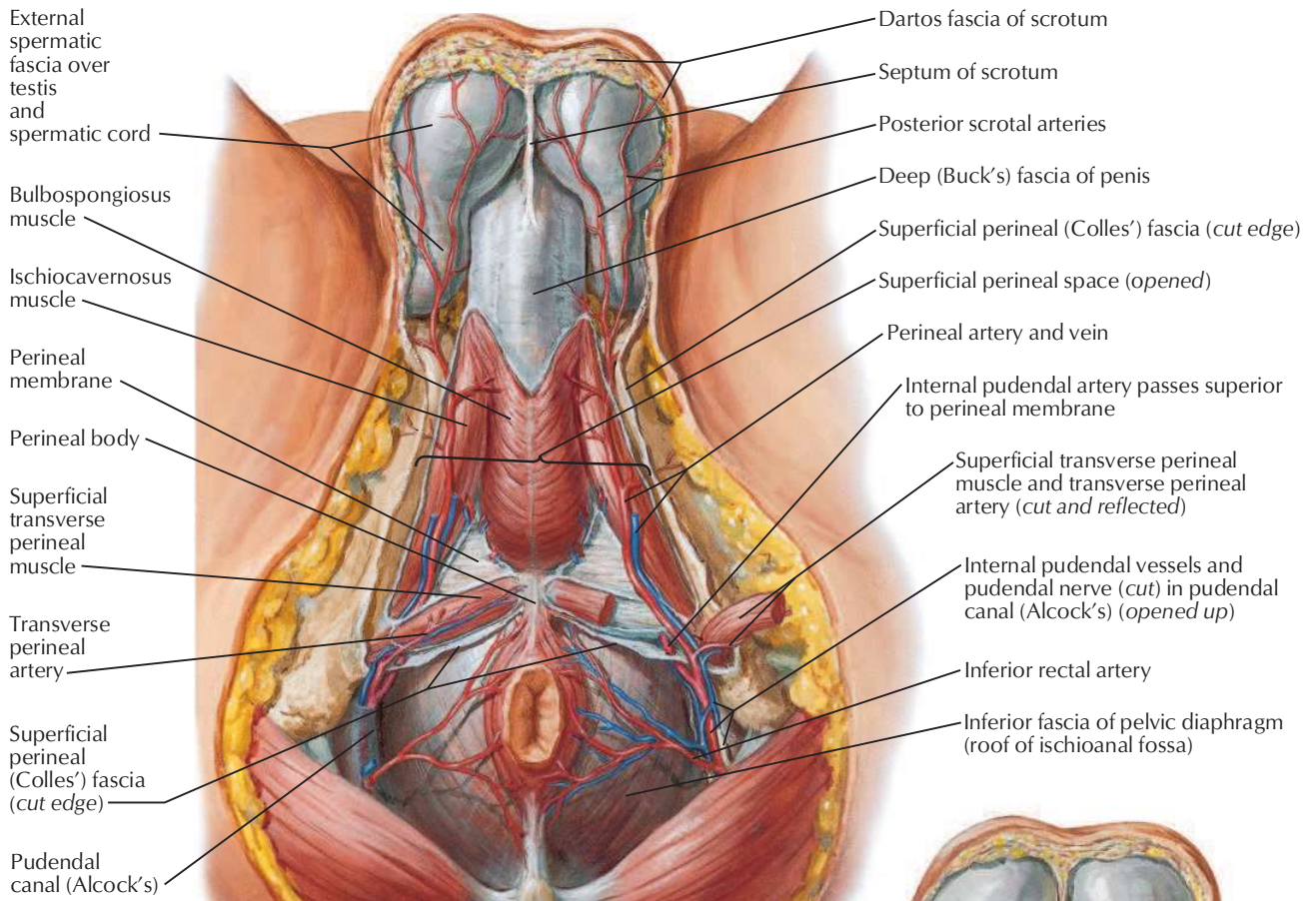
F. Netter M.D.





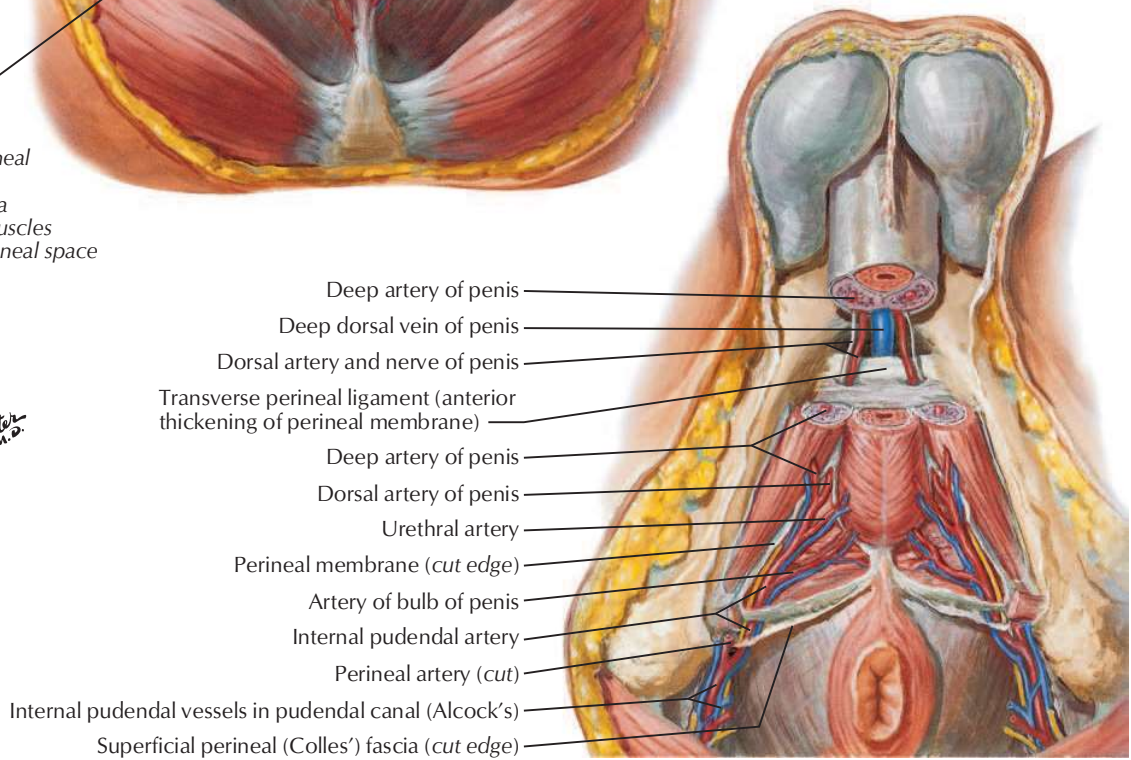
Arteries and Veins of Perineum and Uterus



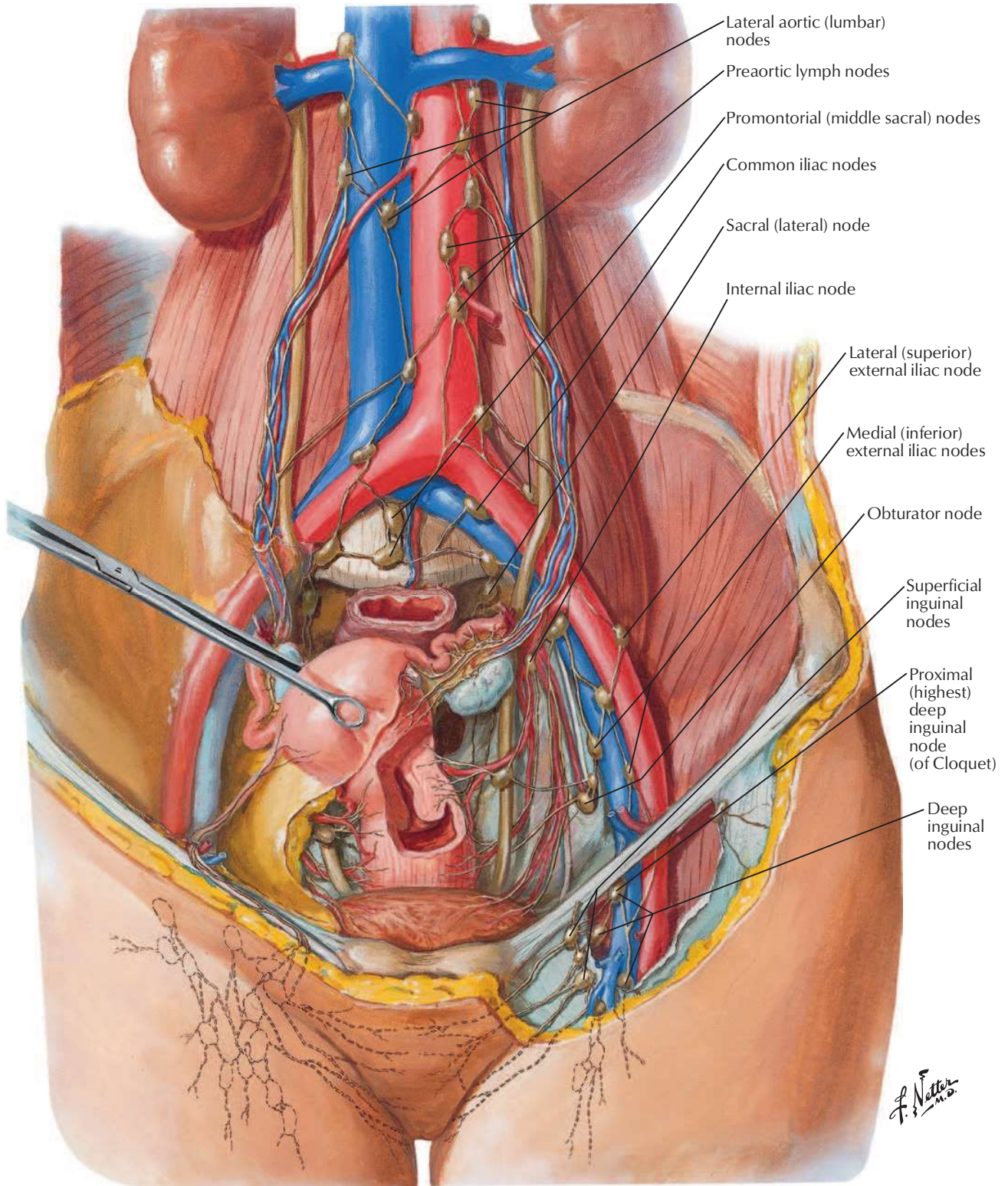


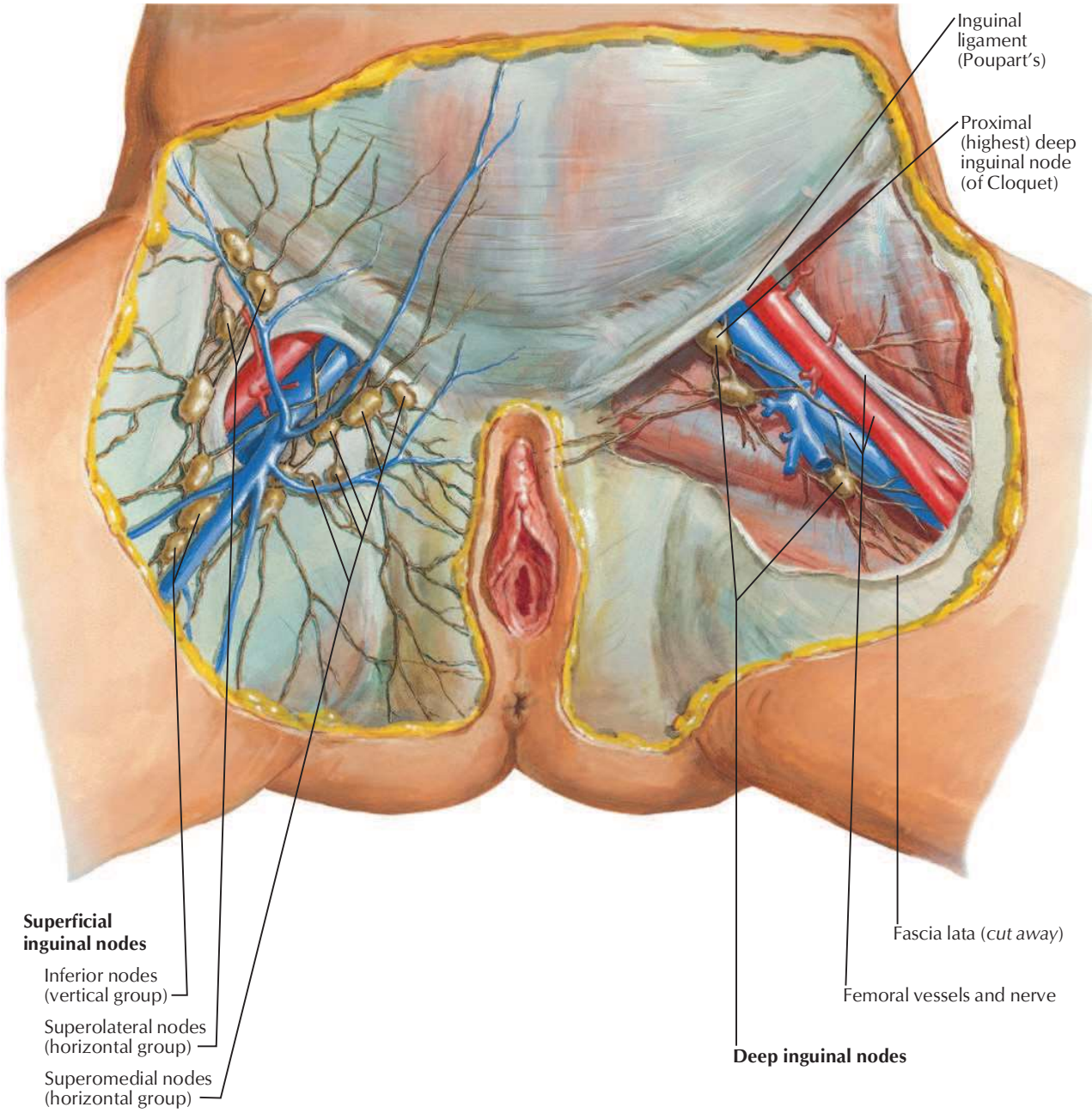
Note: Deep perineal (investing or Gallaudet's) fascia removed from muscles of superficial perineal space

F. Netter M.D.

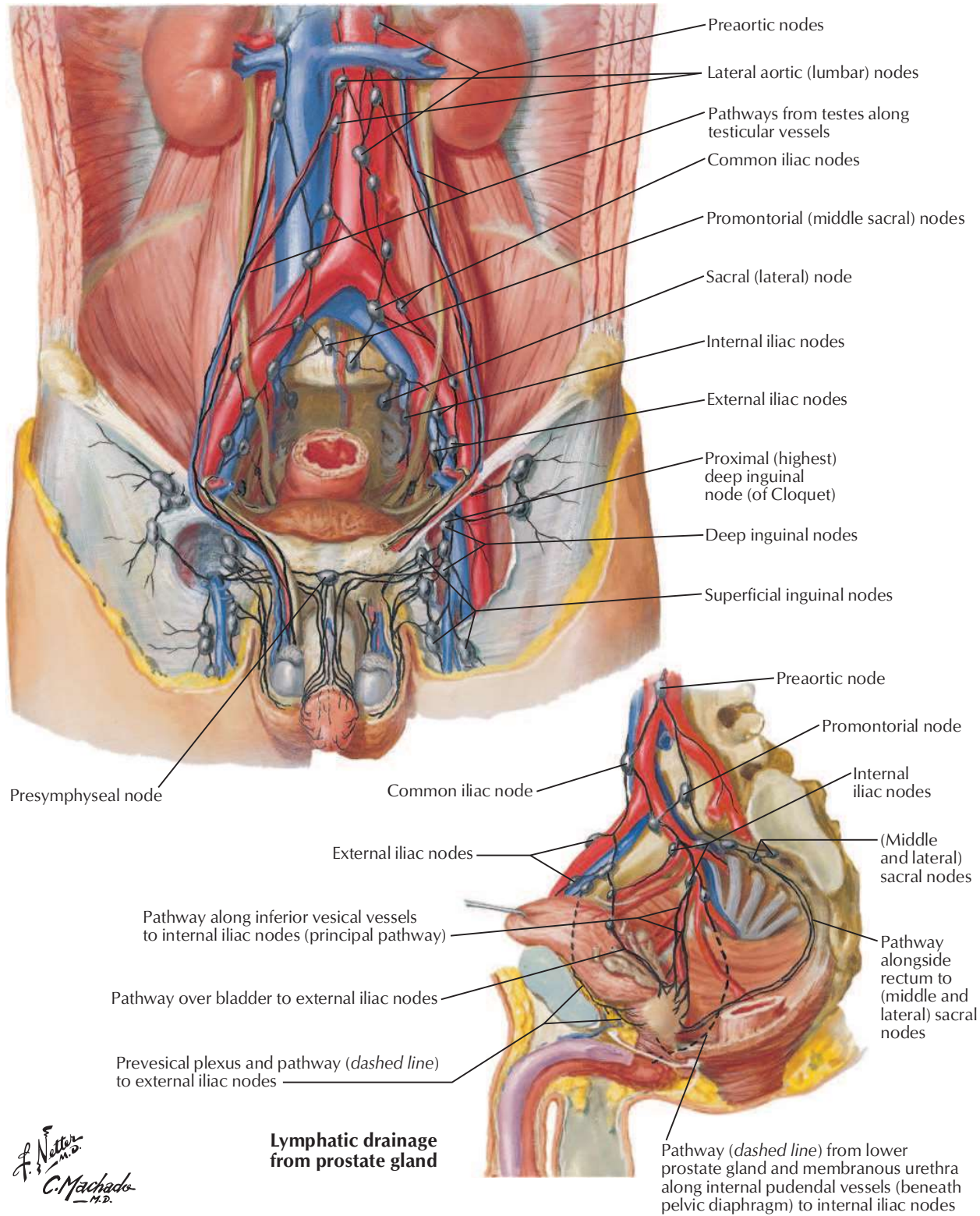


Lymph Vessels and Nodes of Pelvis and Genitalia: Female



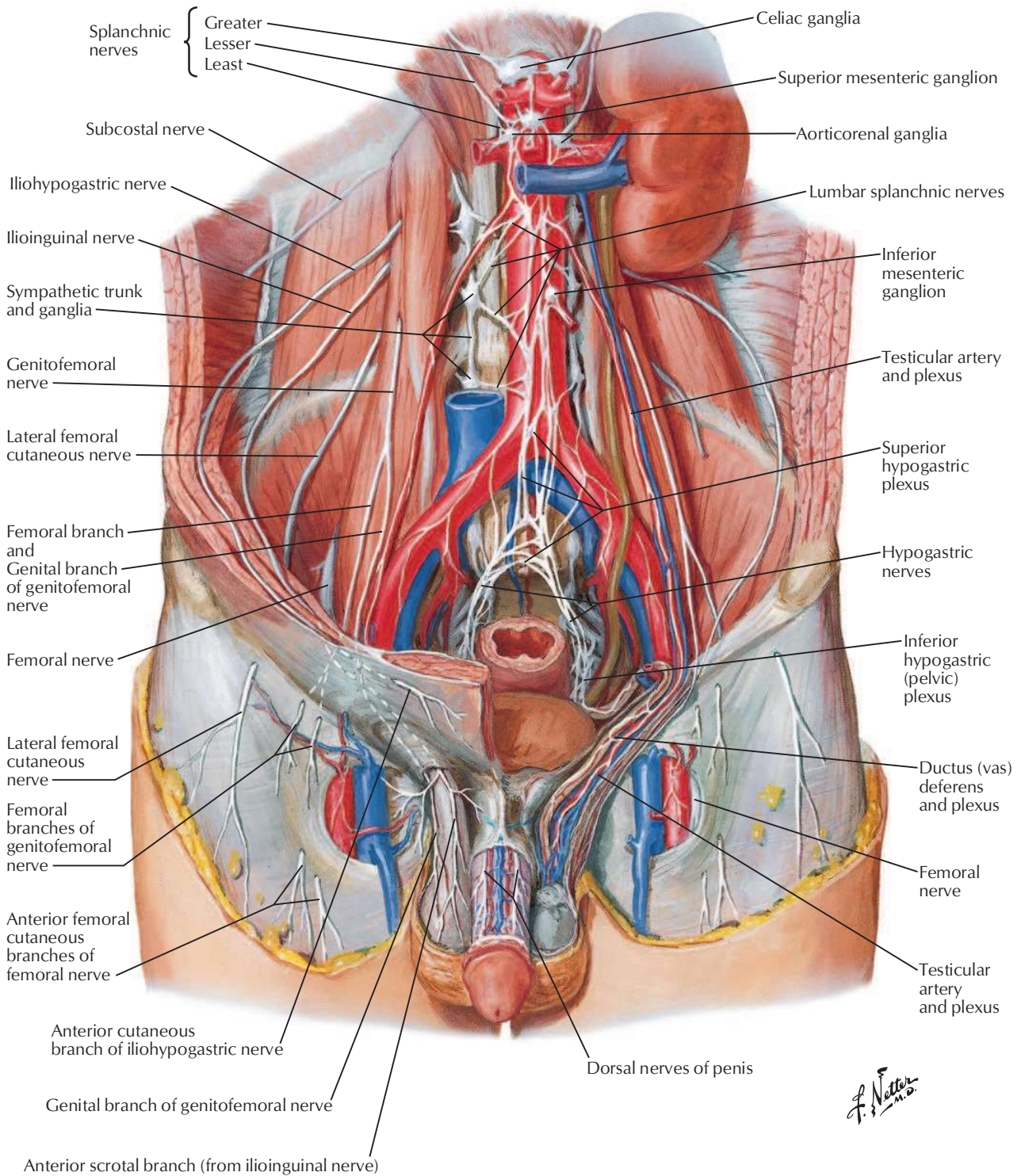


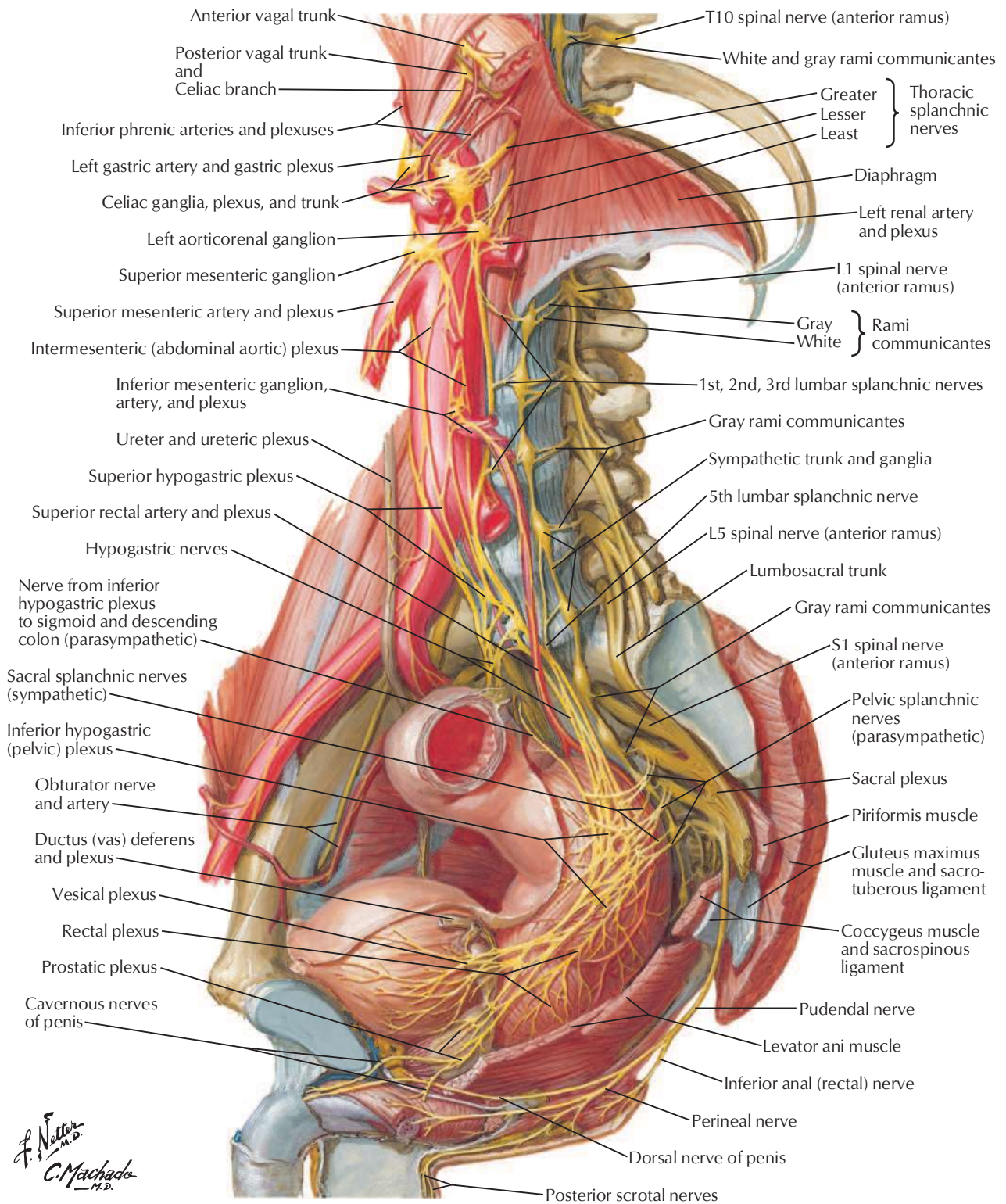
F. Netter M.D.



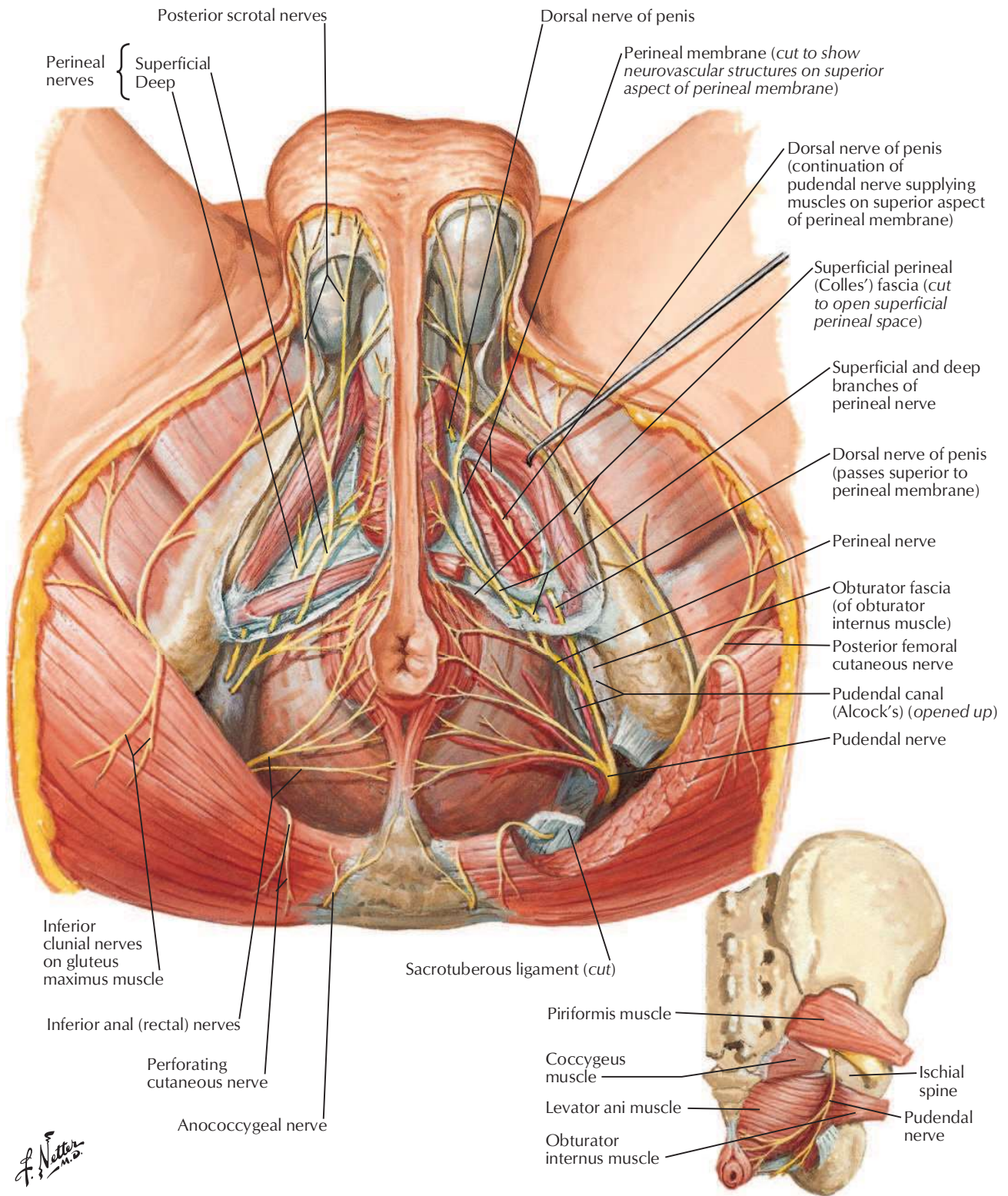
F. Netter
M.D.
C. Machado
— M.D.

Lymphatic drainage from prostate gland





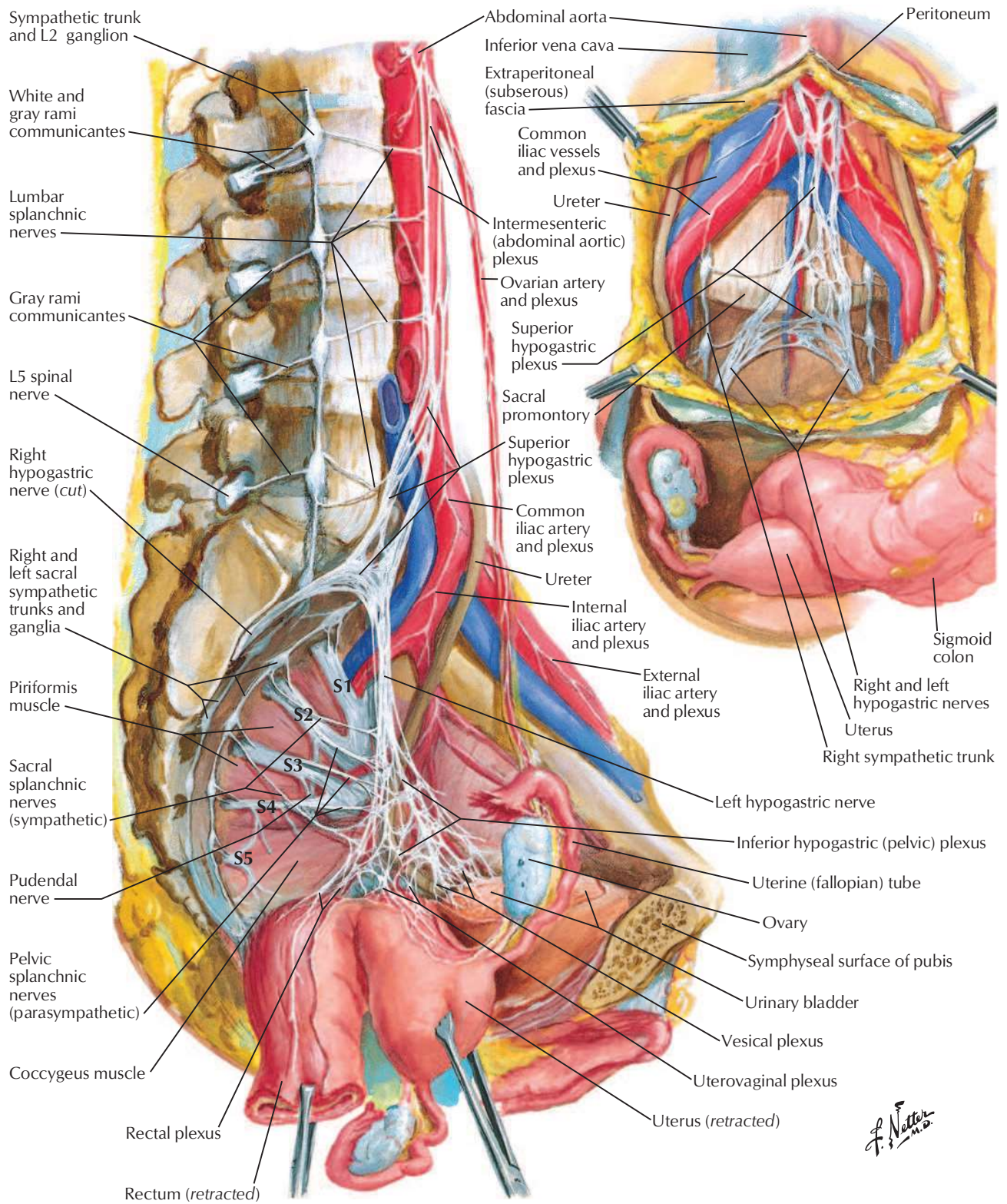
F. Netter M.D.
C. Machado M.D.

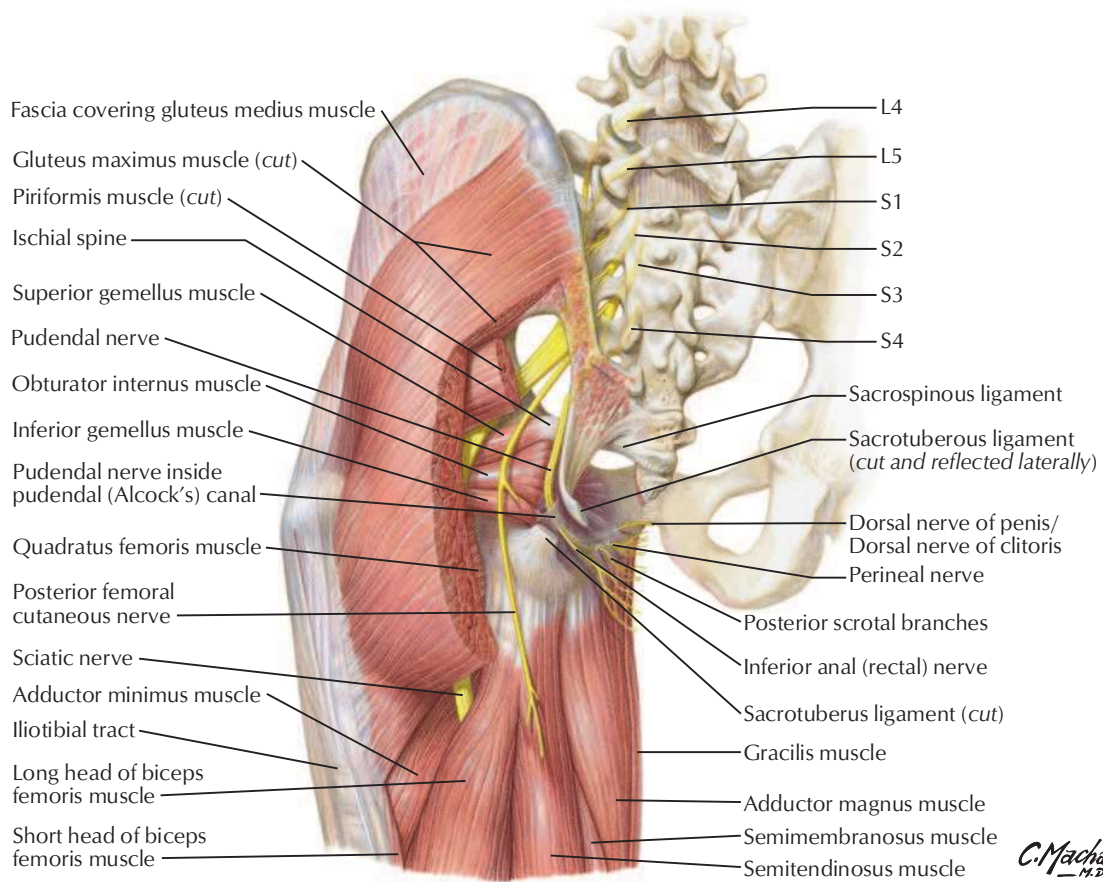
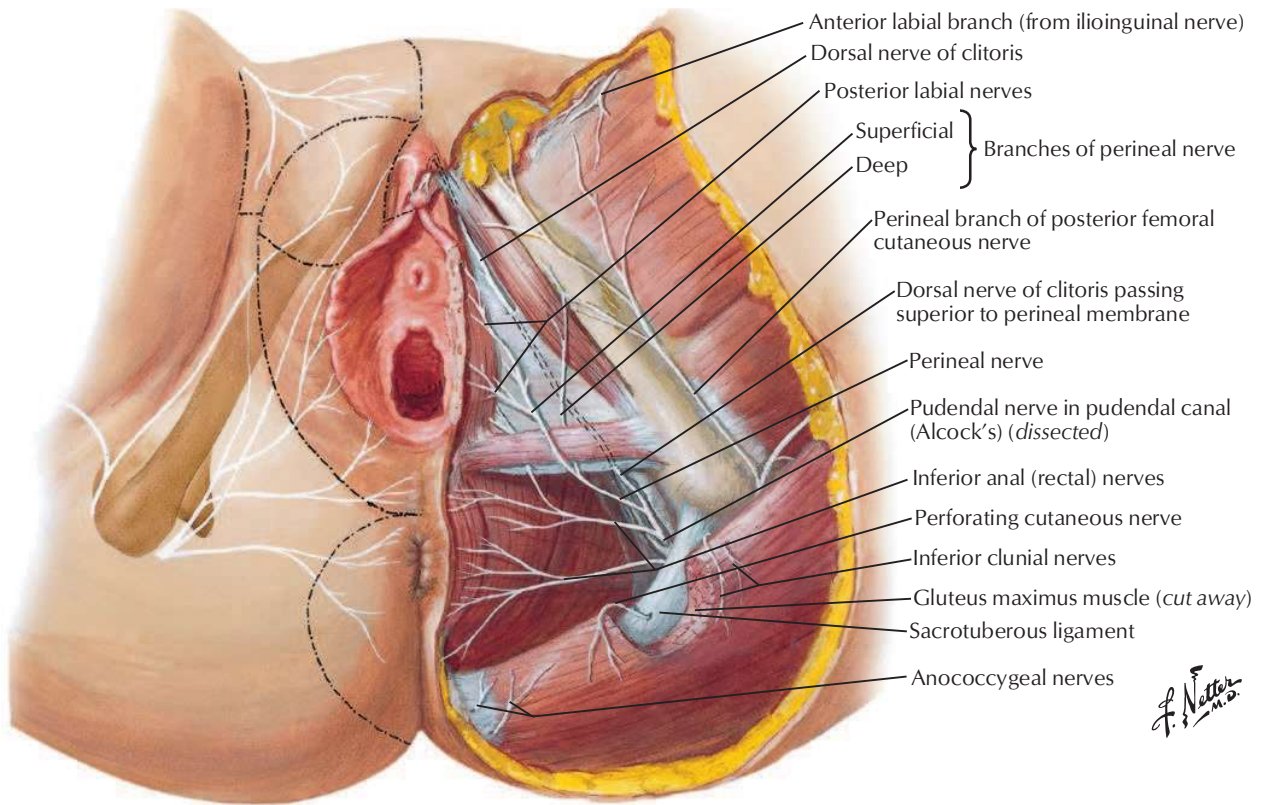


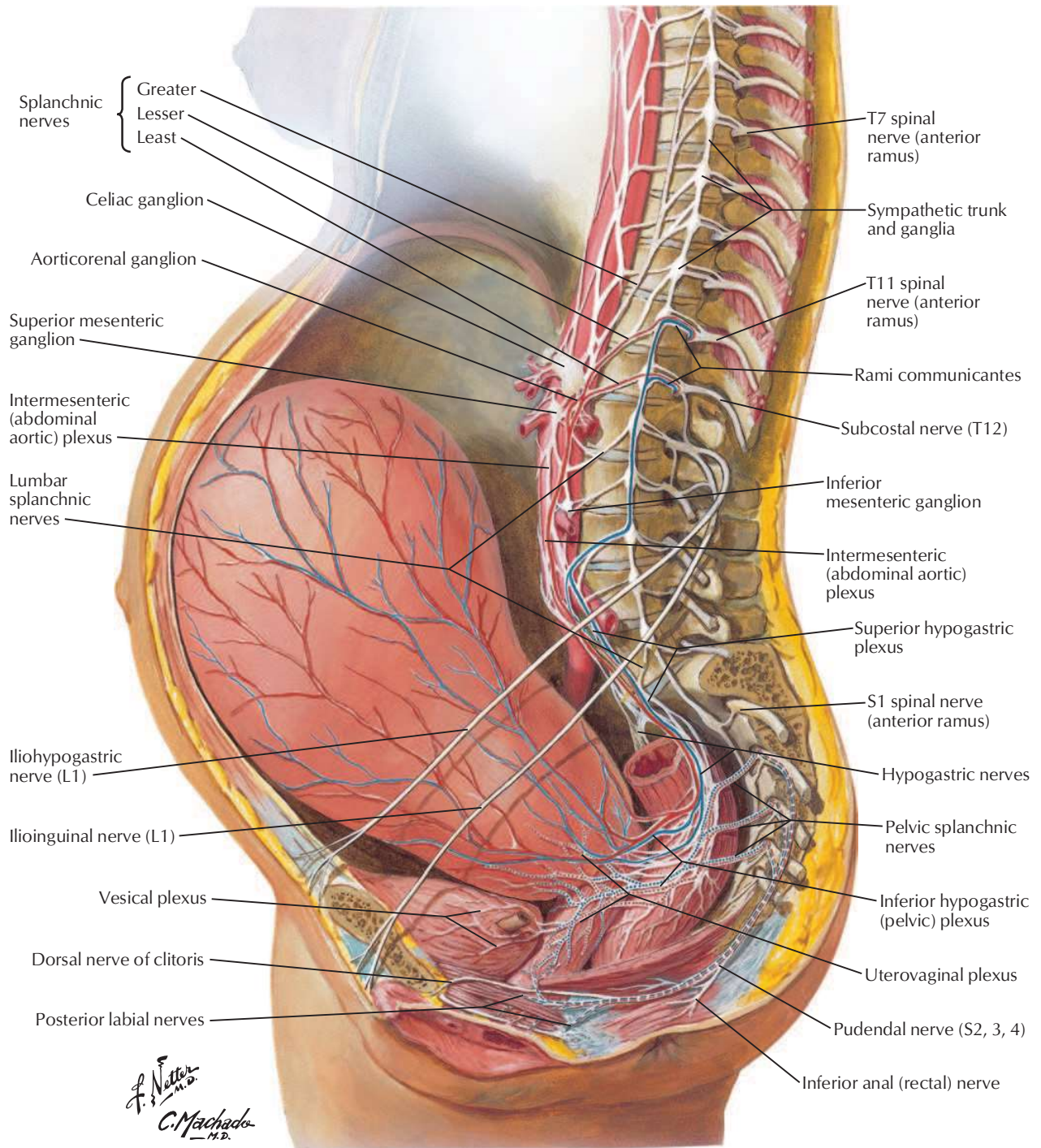
F. Netter M.D.

Nerves of Pelvic Viscera: Female

See also [Plate 300](#)





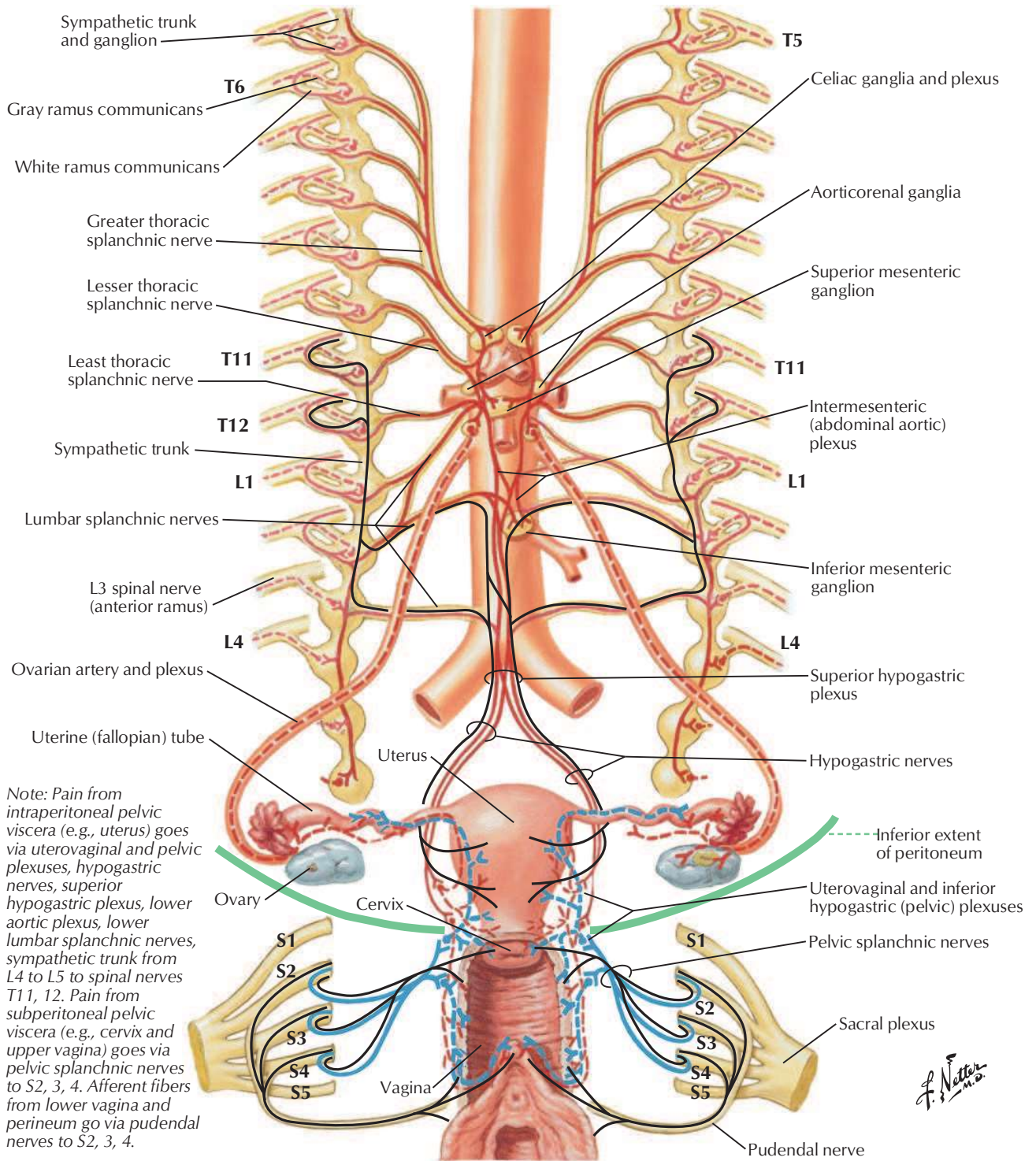


F. Netter M.D.
C. Machado M.D.

— Sensory fibers from uterine body and fundus accompany sympathetic fibers via hypogastric plexuses to T11, 12 (L1?)
— Motor fibers to uterine body and fundus (sympathetic)

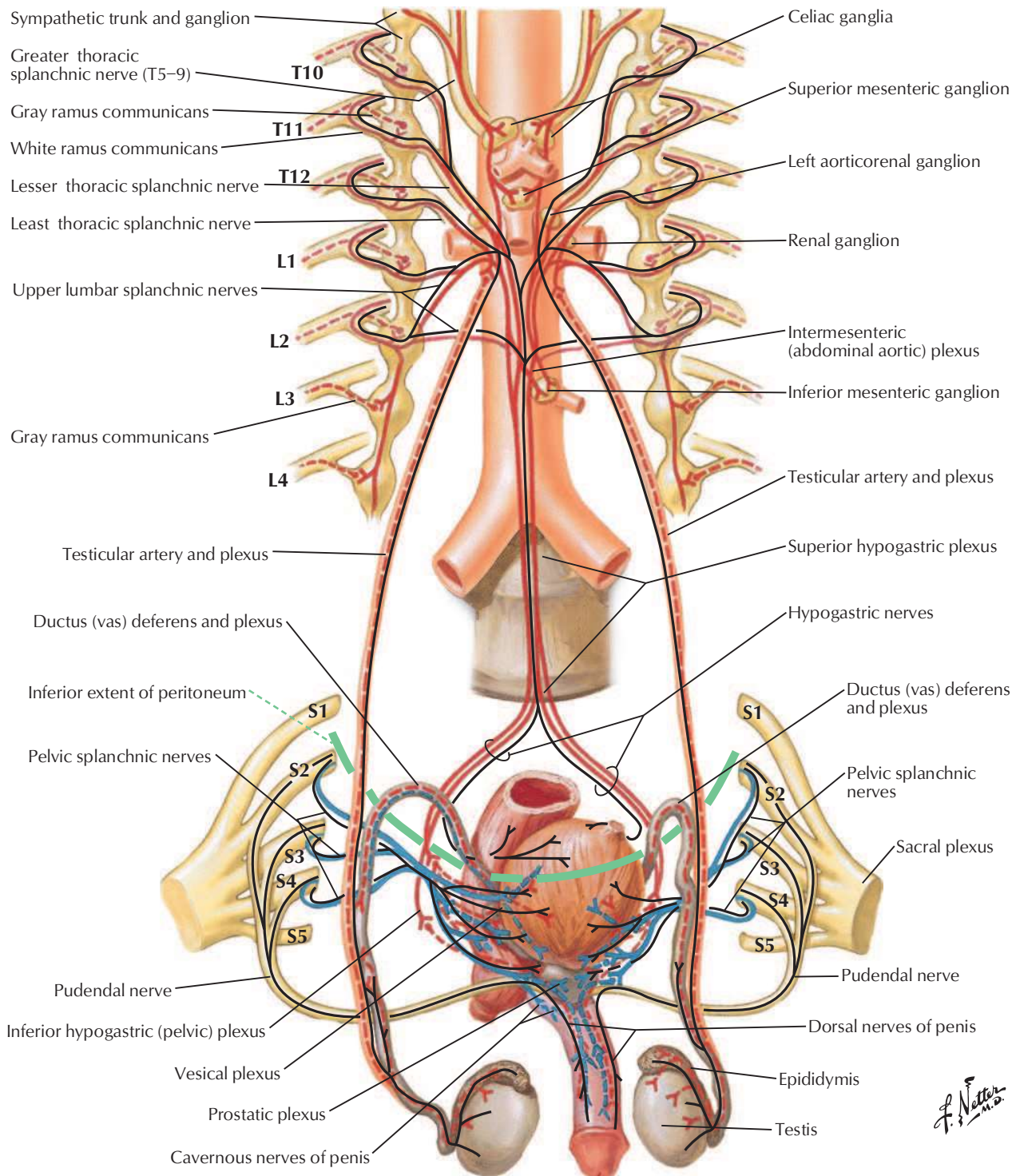
..... Sensory fibers from cervix and upper vagina accompany pelvic splanchnic nerves (parasympathetic) to S2, 3, 4
..... Motor fibers to lower uterine segment, cervix, and upper vagina (parasympathetic)

--- Sensory fibers from lower vagina and perineum accompany somatic fibers via pudendal nerve to S2, 3, 4
--- Motor fibers to lower vagina and perineum via pudendal nerve (somatic)

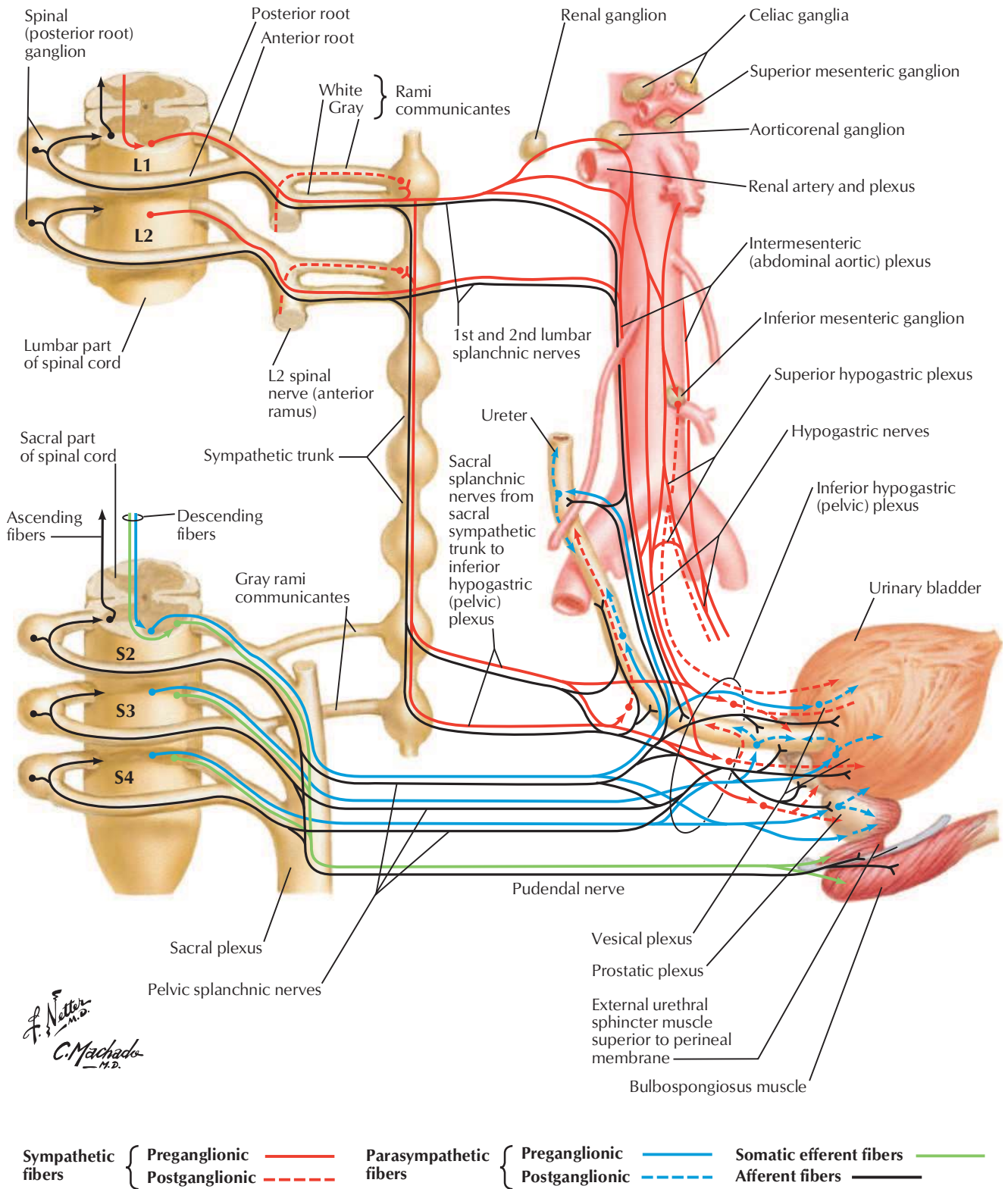


Sympathetic fibers	{ Preganglionic ——— Postganglionic - - -	Parasympathetic fibers	{ Preganglionic ——— Postganglionic - - -	Afferent fibers ———

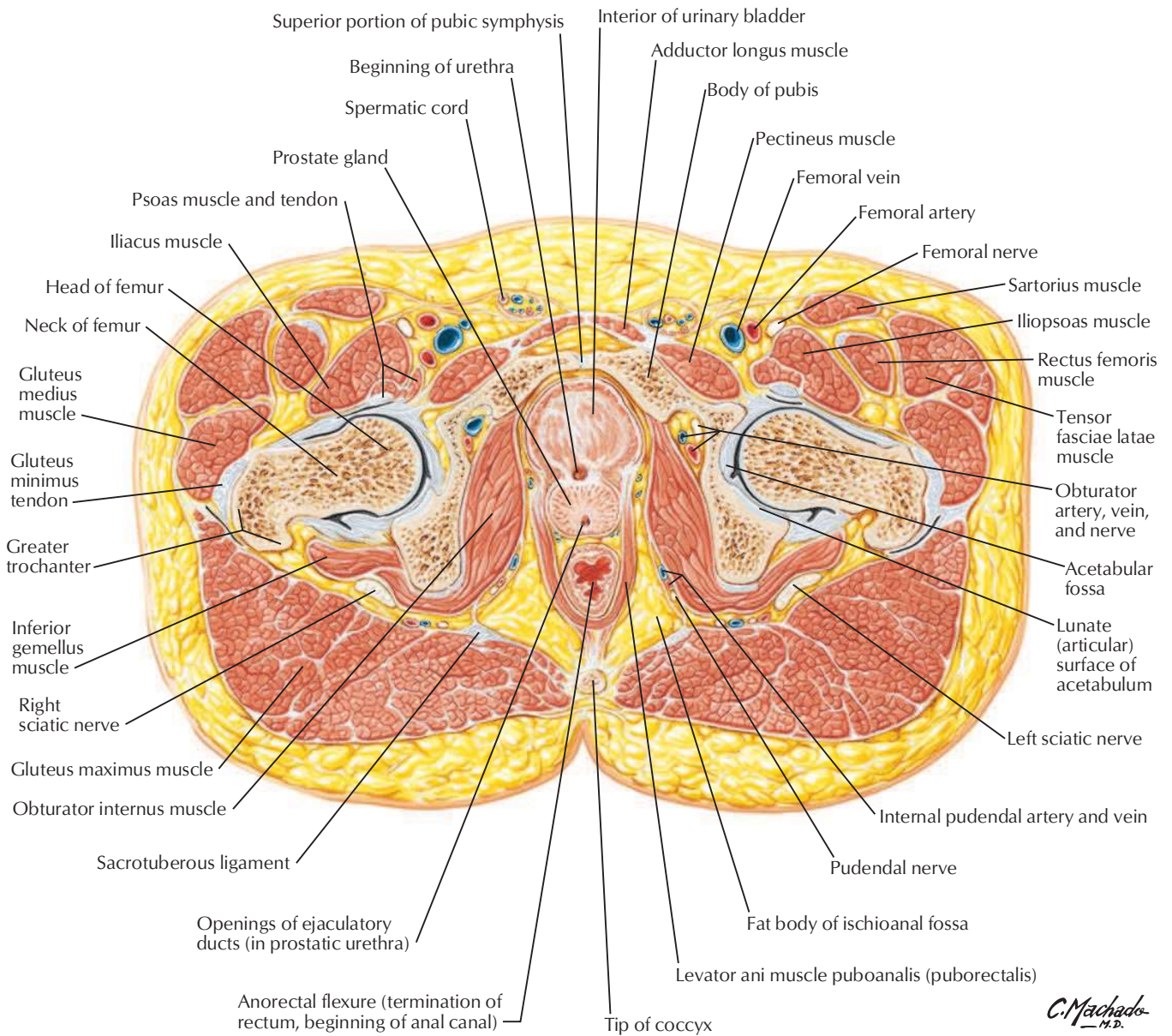
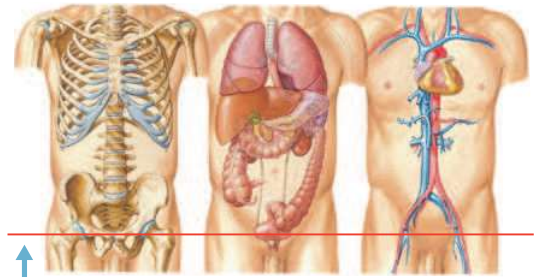
Innervation of Male Reproductive Organs: Schema

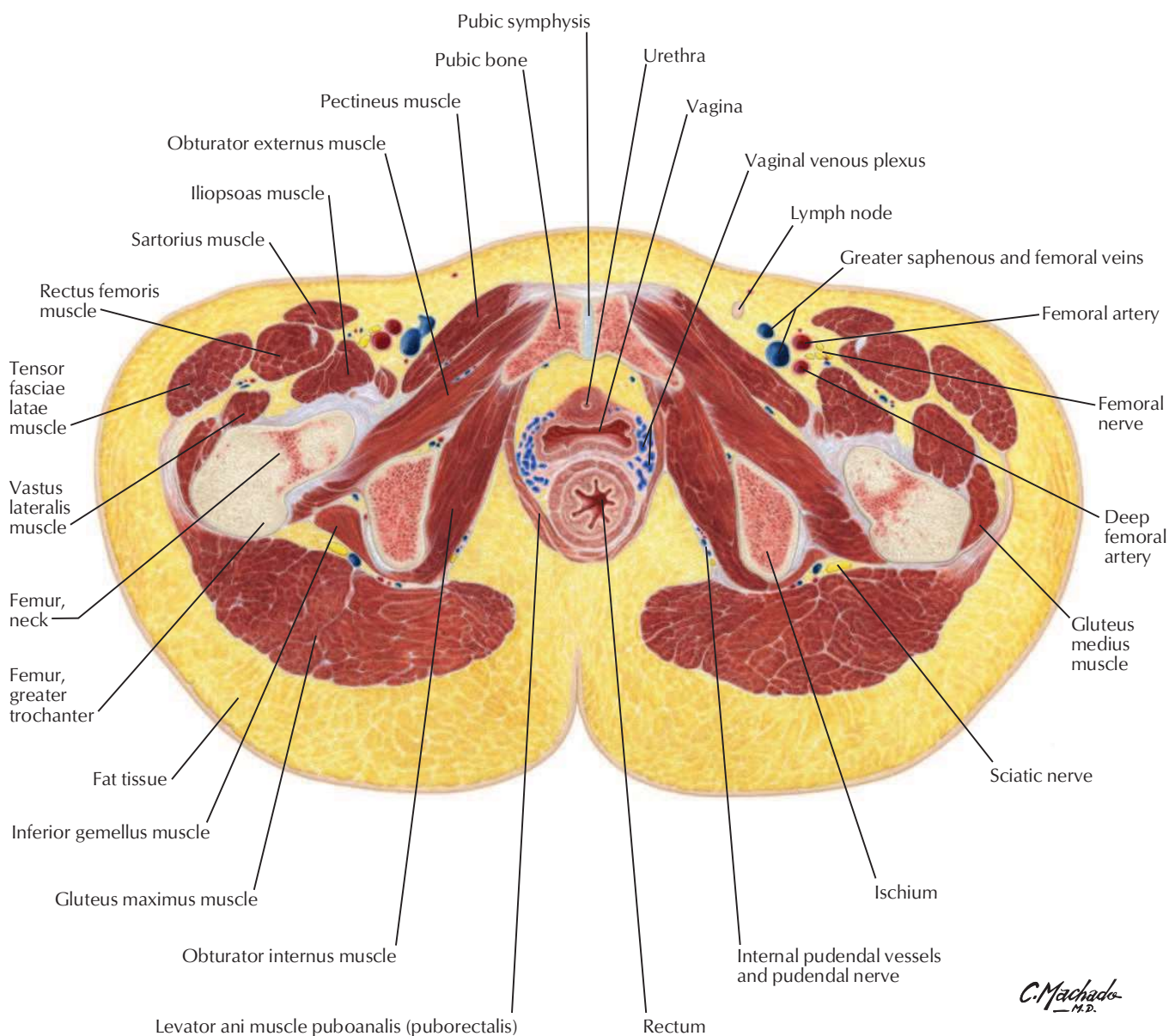
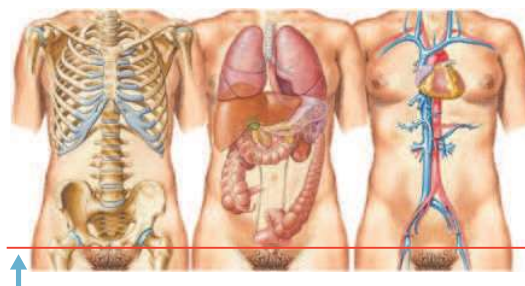


Sympathetic fibers	{	Preganglionic	—	Parasympathetic fibers	{	Preganglionic	—	Afferent fibers	—
		Postganglionic	- - -			Postganglionic	- - -		



Male Pelvis: Cross Section of Bladder–Prostate Gland Junction









C. Machado
M.D.

ANATOMICAL STRUCTURES	CLINICAL IMPORTANCE	PLATE NUMBERS
 SKELETAL SYSTEM		
Pubic symphysis	Palpable landmark used to obtain pelvic measurements (e.g., diagonal conjugate) that are used to assess adequacy of pelvis for childbirth; during prenatal examinations, used for estimating fetal growth (symphysis–fundal height measurement)	336
Ischial spine	Palpable landmark used to estimate interspinous diameter for childbirth and to locate pudendal nerve for pudendal nerve block	336
Ischial tuberosity	Palpable landmark used to estimate width of pelvic outlet for childbirth	336
Superior pubic ramus	Often fractured by compression of pelvis in anteroposterior plane by crush injury	338
Ischial spine	Pudendal nerve blocks target pudendal nerve at its entry into lesser sciatic foramen, approximately 1 cm inferior and medial to attachment of sacrospinous ligament on ischial spine	384, 393
 MUSCULAR SYSTEM		
Pelvic diaphragm (levator ani and coccygeus muscles)	Provides support to urethrovesical angle, helping to maintain urinary continence; weakness or injury during childbirth can lead to stress incontinence in women	340, 351
Endopelvic fascia	Weakness or tearing of endopelvic fascial ligaments (e.g., pubovesical or cardinal ligaments) facilitates prolapse of pelvic organs	350, 353
Perineal body	Tearing of perineal body can lead to prolapse of pelvic organs or loss of continence	360
 DIGESTIVE SYSTEM		
Rectum	Examined by digital rectal examination to detect internal hemorrhoids, fecal impaction, and rectal cancer; provides access to colon for colonoscopy	373, 375
Peritoneum	Common site for metastatic spread of ovarian cancer via peritoneal fluid in peritoneal cavity	344, 345
 URINARY SYSTEM		
Urinary bladder	Landmark used to identify structures of pelvis during ultrasound examination	349, 350
Ureter	May be injured during hysterectomy because of its close relationship to uterine artery	346, 347
 REPRODUCTIVE SYSTEM		
Rectouterine pouch (of Douglas)	Region examined with ultrasound to detect presence of abdominal or pelvic fluid; common site of ectopic pregnancy; may be accessed via posterior vaginal fornix	345, 346
Uterus	Palpated during prenatal examinations to assess fetal growth and during pelvic examinations; examined with ultrasound to detect abnormalities (e.g., fibroids)	345, 355
Cervix of uterus	Epithelium of transformation zone of cervix is prone to dysplasia and malignancy; cells are sampled from this region during pap examination	353, 355
Vagina	Posterior vaginal fornix allows access to rectouterine pouch of Douglas	345
Prostate gland	Prone to benign hypertrophy with aging; prostate cancer is second most common cancer in men	349, 366

Table 6.1

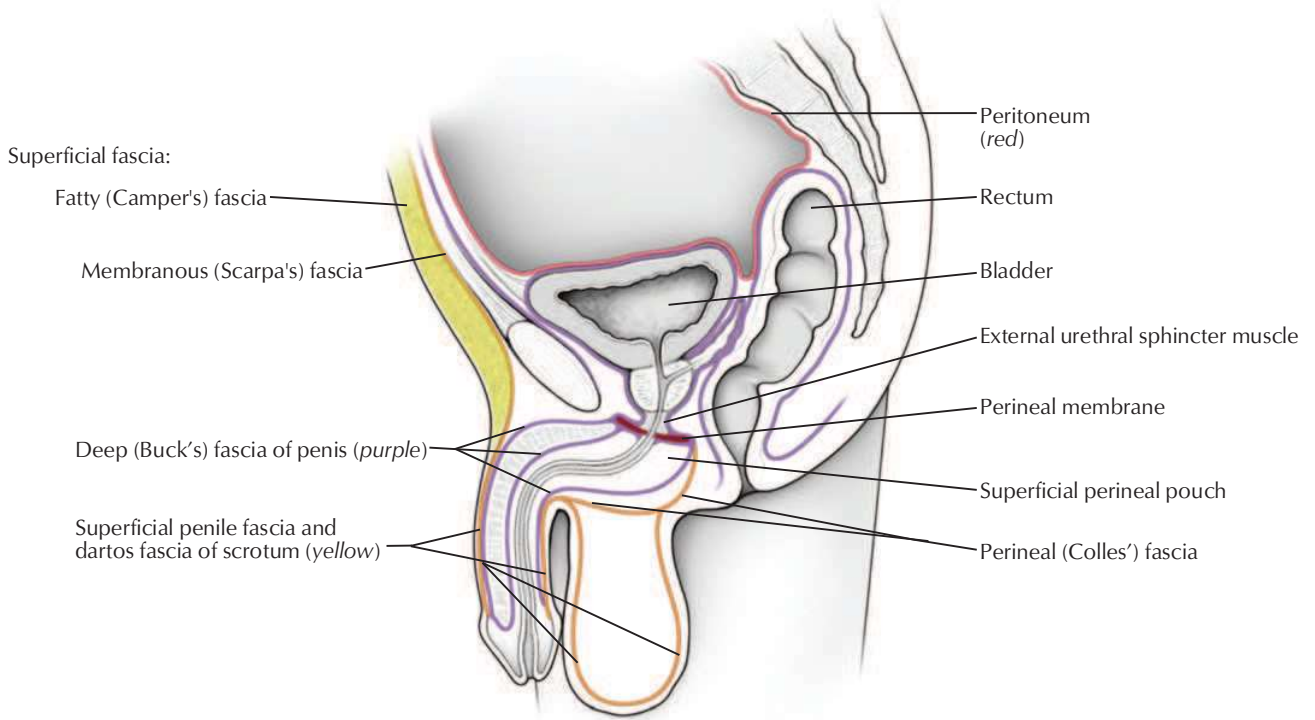
ANATOMICAL STRUCTURES	CLINICAL IMPORTANCE	PLATE NUMBERS
 REPRODUCTIVE SYSTEM—Continued		
Ovary	Examined with ultrasound to identify cysts or for oocyte collection	344, 355
Ductus (vas) deferens	Ligated during vasectomy for sterilization in males	349, 369
 NERVOUS SYSTEM		
Pudendal nerve	Pudendal block is performed to anesthetize perineum for childbirth or minor surgical procedures in perineum	395
Inferior rectal nerve	Anesthetized in ischioanal fossa for surgical excision of external hemorrhoids	393
Prostatic plexus/cavernous nerves	Disruption of these nerves during procedures (e.g., prostate surgery) can produce inability to achieve erection	392
 CARDIOVASCULAR SYSTEM		
Pampiniform venous plexus	Dilation can cause testicular varicocele, most commonly on left side due to differences in drainage pattern of right and left gonadal veins	369
Uterine artery	Ligated or cauterized during hysterectomy; embolization is performed to treat uterine fibroids	382, 386
Arteries of penis (deep, dorsal), cavernous tissue	Blockage or loss of vascular smooth muscle function can lead to erectile dysfunction	387
Internal iliac veins	Provide communication between prostatic venous plexus and veins draining vertebral column, which is route of spread for prostate cancer	385
Rectal veins (superior, middle, inferior)	Portal hypertension may cause dilated rectal veins (hemorrhoids) because portosystemic anastomoses develop between rectal veins	381, 299
 LYMPHATIC SYSTEM		
Pelvic and paraaortic (lateral aortic, lumbar) lymph nodes	Spread of ovarian cancer cells via venous drainage to inferior vena cava and lungs and via lymphatics	388
Paraaortic and tracheobronchial lymph nodes	Prostate cancer cells may spread via lymphatics	390
Preaortic and paraaortic (lateral aortic, lumbar) lymph nodes	Receive lymphatic drainage from ovary, uterine tube, and uterine fundus in women and from testis in men; cancers in these organs may therefore spread to retroperitoneum	388, 390
Pelvic lymph nodes	Lymph node sampling or dissection is performed to assess spread of gynecologic malignancies	388

*Selections were based largely on clinical data as well as commonly covered clinical correlations in gross anatomy courses.

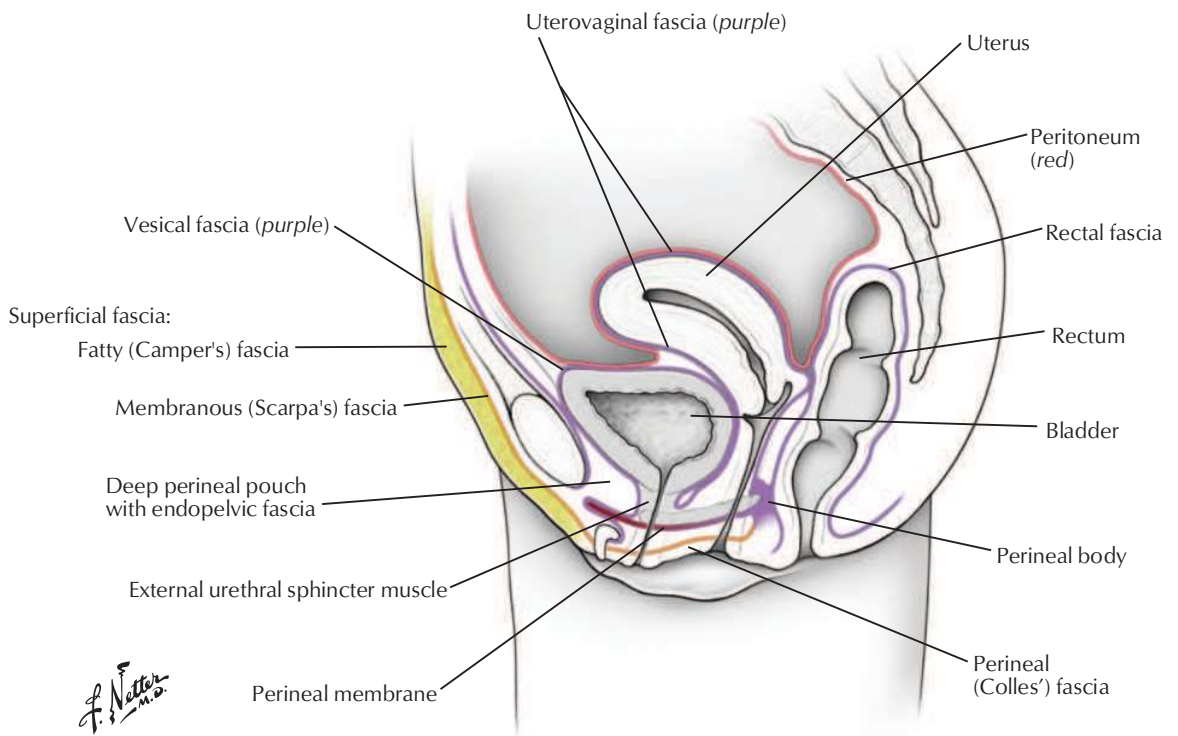
MUSCLE	MUSCLE GROUP	PROXIMAL ATTACHMENT (ORIGIN)	DISTAL ATTACHMENT (INSERTION)	INNERVATION	BLOOD SUPPLY	MAIN ACTIONS
Bulbospongiosus	Perineal	<i>Male:</i> median raphe, bulb of penis, perineal body <i>Female:</i> perineal body	<i>Male:</i> perineal membrane, corpus cavernosum, bulb of penis <i>Female:</i> dorsum of clitoris, inferior fascia of urogenital diaphragm, bulb of vestibule, pubic arch	Deep branch of perineal nerve from pudendal nerve	Internal pudendal artery and its branch (perineal artery)	<i>Male:</i> compresses bulb of penis, forces blood into body of penis during erection, removes urine from urethra and semen during ejaculation <i>Female:</i> constricts vaginal orifice, assists in expressing secretions of greater vestibular gland, forces blood into body of clitoris
Coccygeus	Pelvic floor	Ischial spine, sacrospinous ligament	Inferior sacrum, coccyx	Anterior rami of lower sacral nerves	Inferior gluteal artery	Supports pelvic viscera, draws coccyx forward
Compressor urethrae (female only)	Perineal	Ischiopubic ramus	Anterior aspect of urethra	Perineal branches of pudendal nerve	Perineal branch of internal pudendal artery	Sphincter of urethra
Cremaster	Spermatic cord	Lower edge of internal abdominal oblique and middle of inguinal ligament	Pubic tubercle, crest of pubis	Genital branch of genitofemoral nerve	Cremasteric branch of inferior epigastric artery	Retracts testicle
Deep transverse perineal	Perineal	Inner surface of inferior ischial rami	<i>Male:</i> medial tendinous raphe and perineal body <i>Female:</i> sides of vagina	Perineal branches of pudendal nerve	Perineal branch of internal pudendal artery	Stabilizes perineal body, supports prostate gland/vagina
External anal sphincter	Perineal	Tip of coccyx, anococcygeal ligament	Deeper fibers surround anal canal, attach posteriorly to coccyx and anteriorly to central point of perineum	Perineal and inferior rectal branches of pudendal nerve	Inferior rectal and transverse perineal artery	Closes anal orifice
Iliacus	Anterior thigh	Superior 2/3 of iliac fossa, ala of sacrum, anterior sacroiliac ligaments	Lesser trochanter of femur and body inferior to it, to psoas major tendon	Femoral nerve	Iliac branches of iliolumbar artery	Flexes thigh at hips and stabilizes hip joint, acts with psoas major
Ischiocavernosus	Perineal	Inferior internal surface of ischiopubic ramus, ischial tuberosity	Crus of penis or clitoris	Deep branch of perineal nerve from pudendal nerve	Internal pudendal artery and its branch (perineal artery)	Forces blood into body of penis and clitoris during erection
Levator ani (iliococcygeus, pubococcygeus, and puboanalis)	Pelvic floor	Body of pubis, tendinous arch of obturator fascia, ischial spine	Perineal body, coccyx, anococcygeal raphe, walls of prostate gland or vagina, rectum, anal canal	Anterior rami of lower sacral nerves, perineal nerve	Inferior gluteal artery, internal pudendal artery and its branches (inferior rectal and perineal arteries)	Supports pelvic viscera, raises pelvic floor
Obturator internus	Gluteal region	Pelvic surface of obturator membrane and surrounding bone	Medial surface of greater trochanter of femur	Nerve to obturator internus muscle	Internal pudendal and obturator arteries	Laterally rotates extended thigh, abducts flexed thigh at hip
Piriformis	Gluteal region	Anterior surface of sacral segments 2–4, sacrotuberous ligament	Superior border of greater trochanter of femur	Anterior rami of L5, S1, S2	Superior and inferior gluteal arteries, internal pudendal artery	Laterally rotates extended thigh, abducts flexed thigh at hip

Variations in spinal nerve contributions to the innervation of muscles, their arterial supply, their attachments, and their actions are common themes in human anatomy. Therefore, expect differences between texts and realize that anatomical variation is normal.

MUSCLE	MUSCLE GROUP	PROXIMAL ATTACHMENT (ORIGIN)	DISTAL ATTACHMENT (INSERTION)	INNERVATION	BLOOD SUPPLY	MAIN ACTIONS
Sphincter urethrae	Perineal	External fibers from junction of inferior pubic and ischial rami and adjacent fascia; internal fibers pass medially to surround membranous urethra	<i>Male</i> : median raphe in front and behind urethra <i>Female</i> : encloses urethra, attaches to sides of vagina	Perineal branches of pudendal nerve	Perineal branch of internal pudendal artery	Compresses urethra at end of micturition; in female also compresses distal vagina
Sphincter urethrovaginalis (female only)	Perineal	Perineal body	Passes forward and anteriorly around urethra	Perineal branches of pudendal nerve	Perineal branch of pudendal artery	Sphincter of urethra and vagina
Superficial transverse perineal	Perineal	Ischial rami and tuberosities	Central tendon (perineal body)	Perineal branches of pudendal nerve	Perineal branch of internal pudendal artery	Stabilizes central tendon

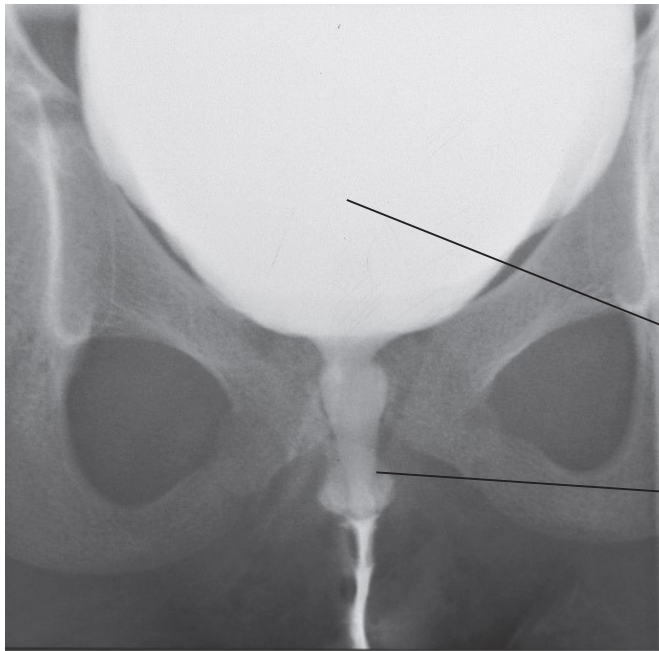


Median section of male



Median section of female

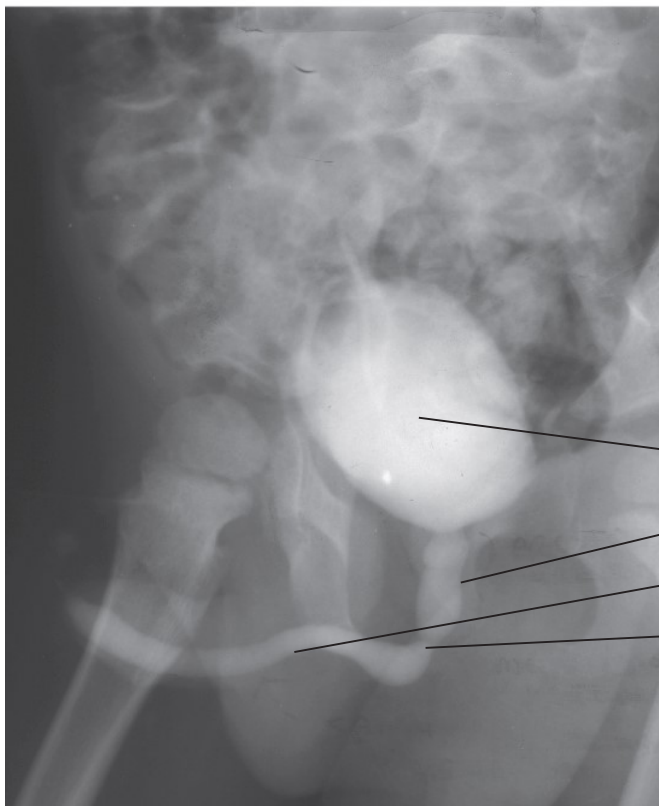
F. Netter M.D.



Cystourethrogram of urethra in 8-year-old girl

Bladder

Urethra



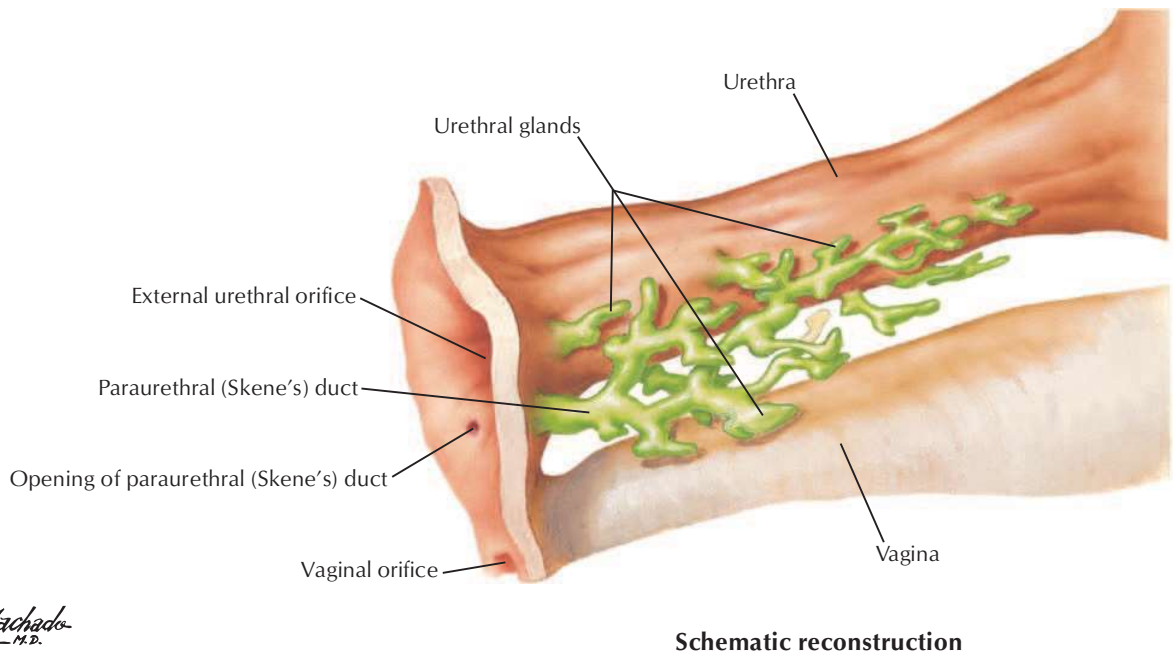
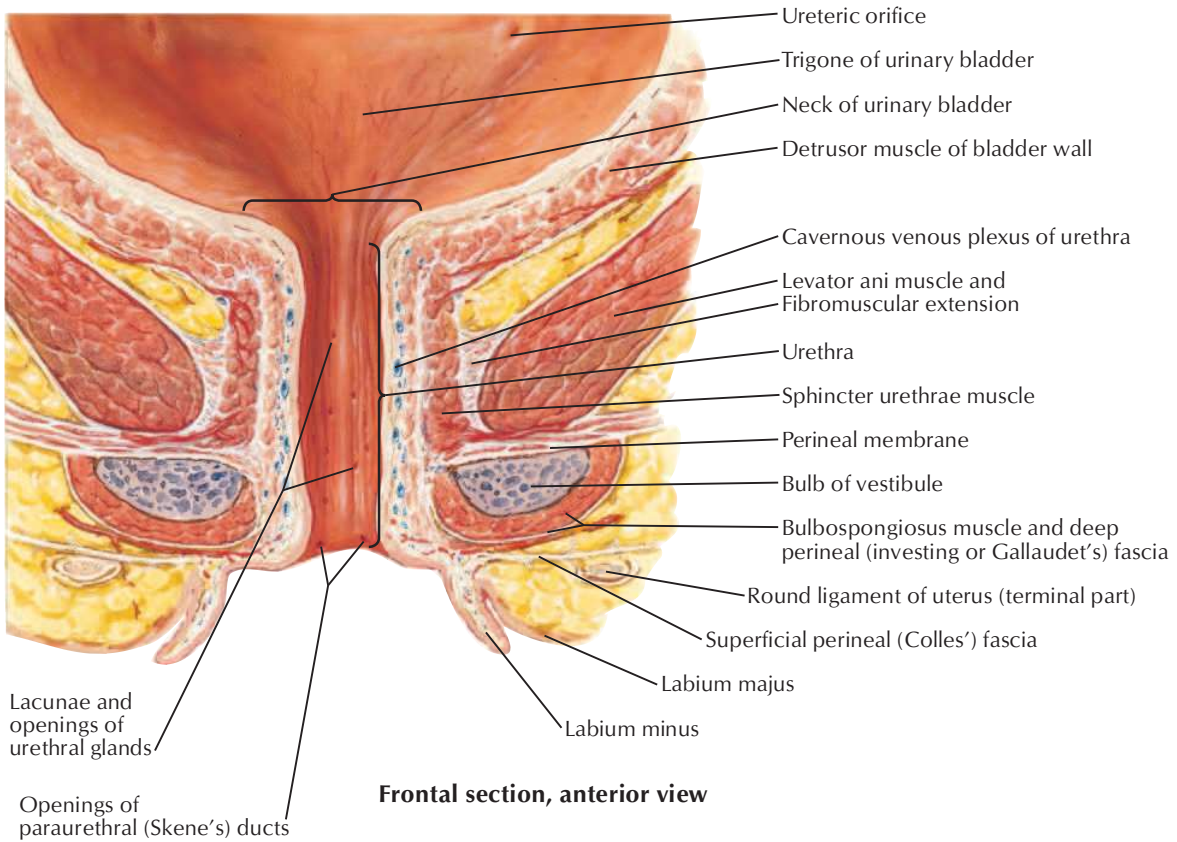
Voiding cystourethrogram in 2-year-old boy

Bladder

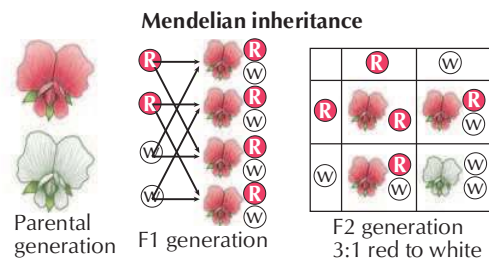
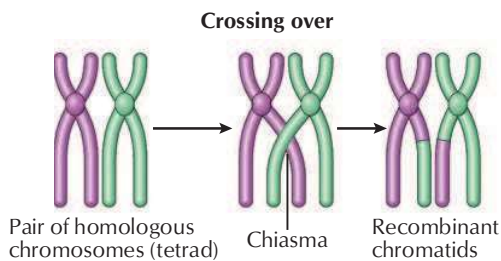
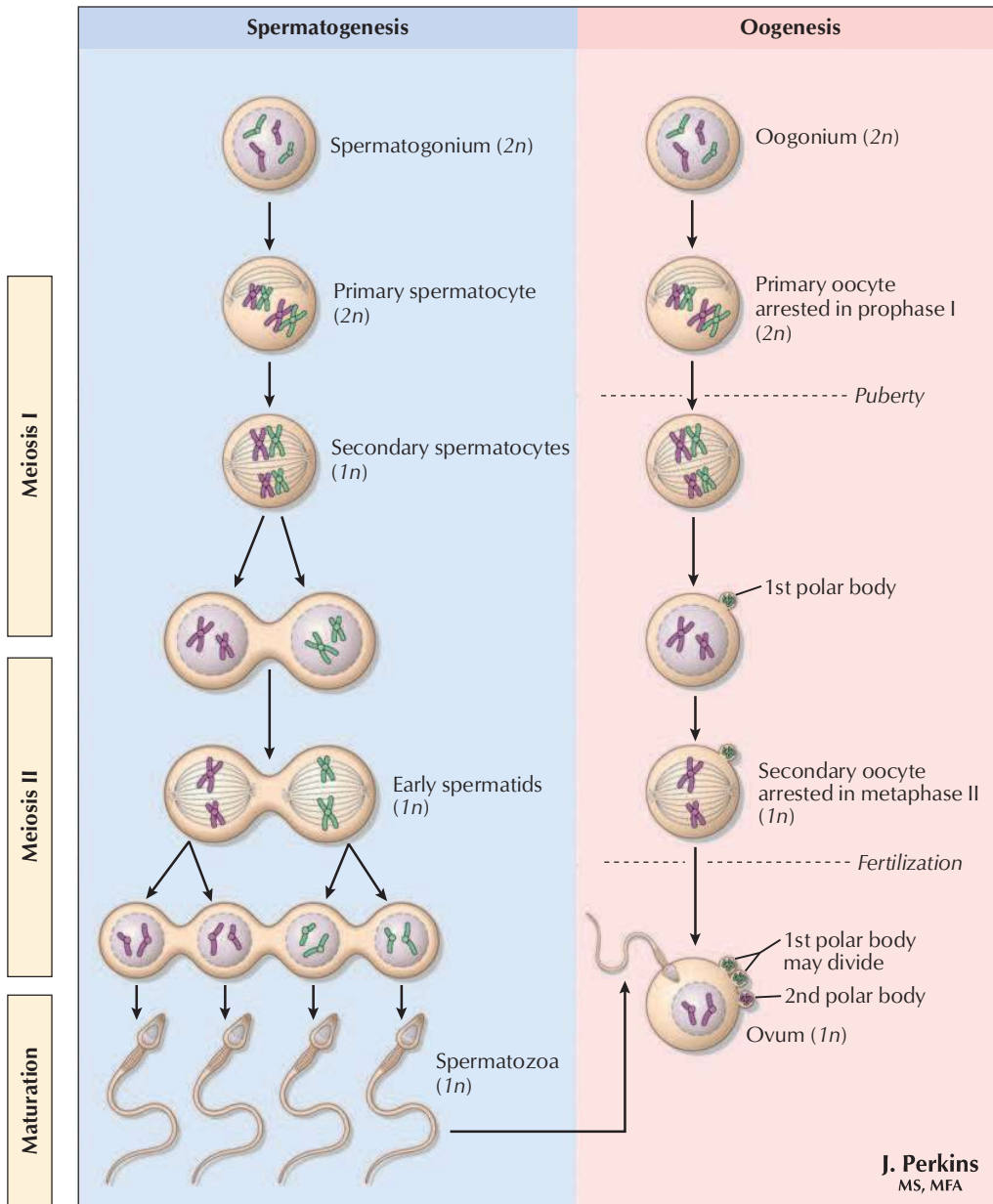
Prostatic urethra

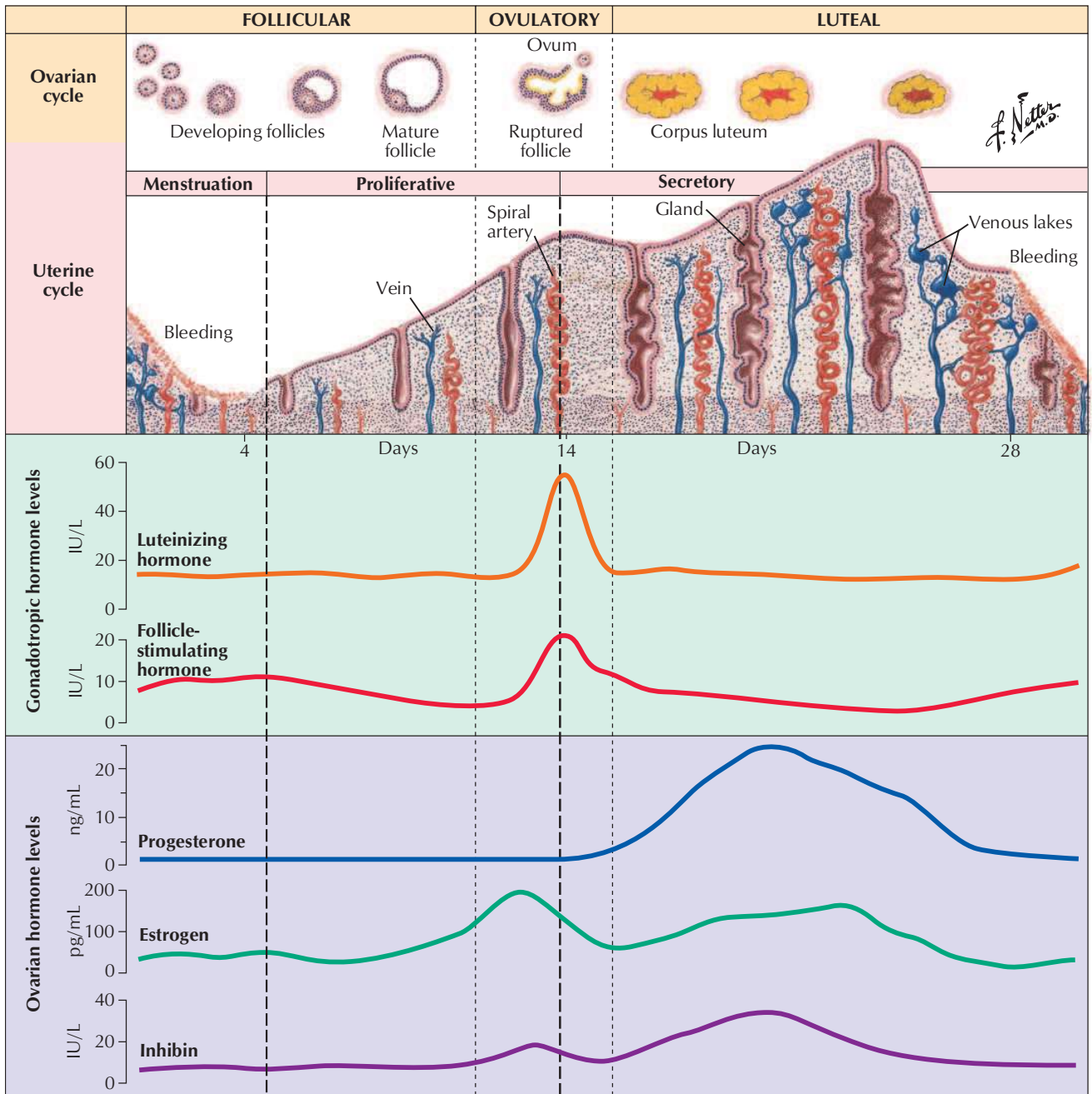
Spongy urethra

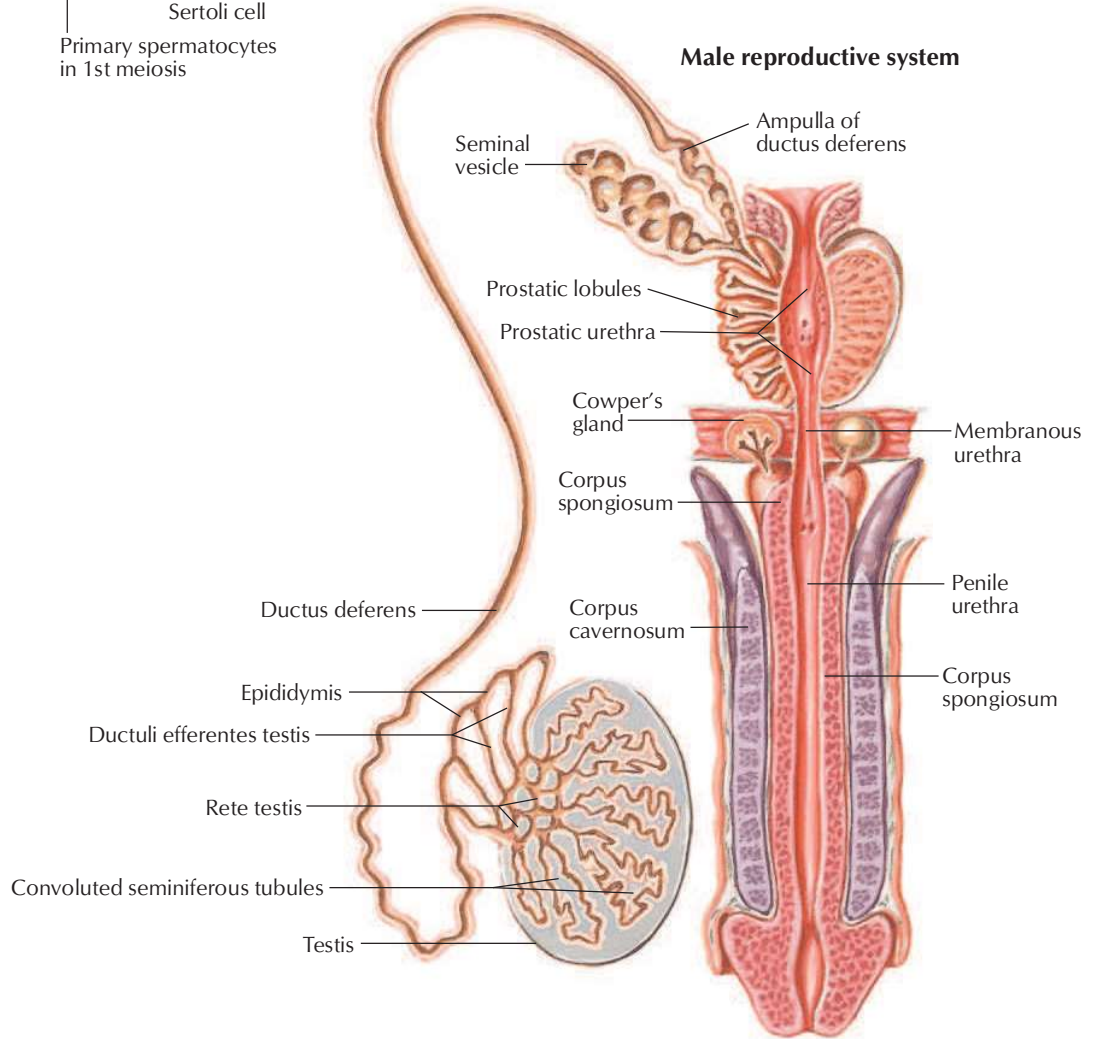
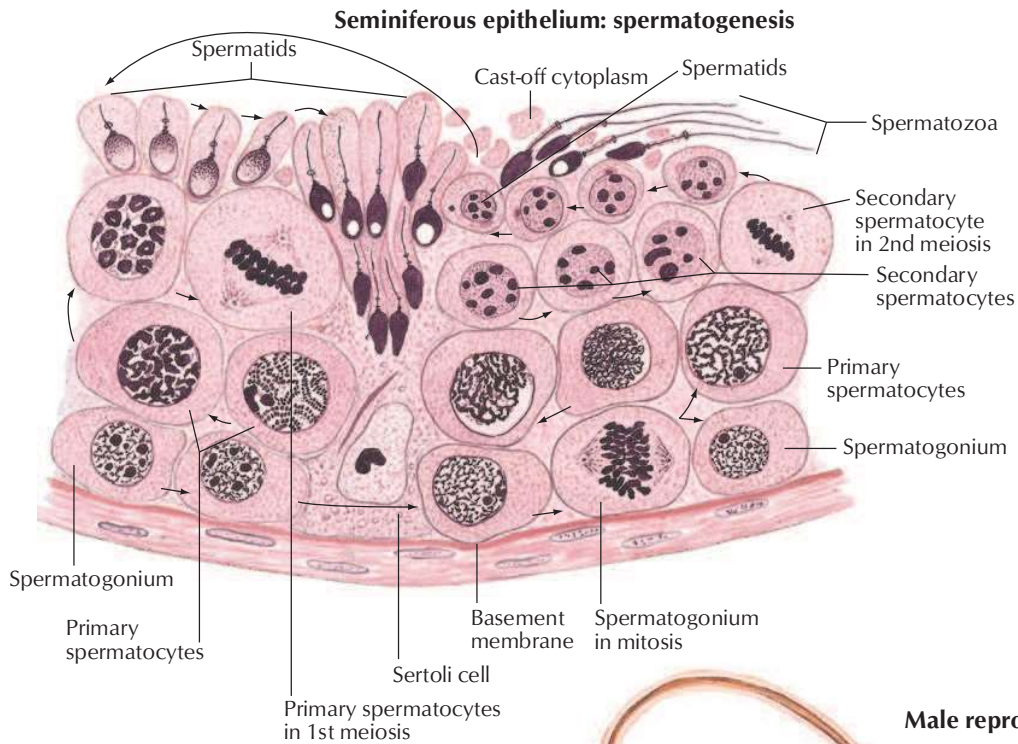
Membranous urethra

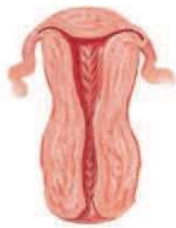


F. Netter M.D.
C. Machado M.D.

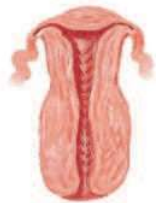




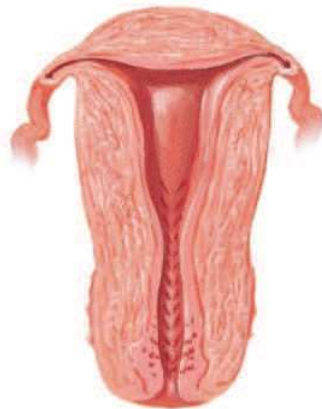


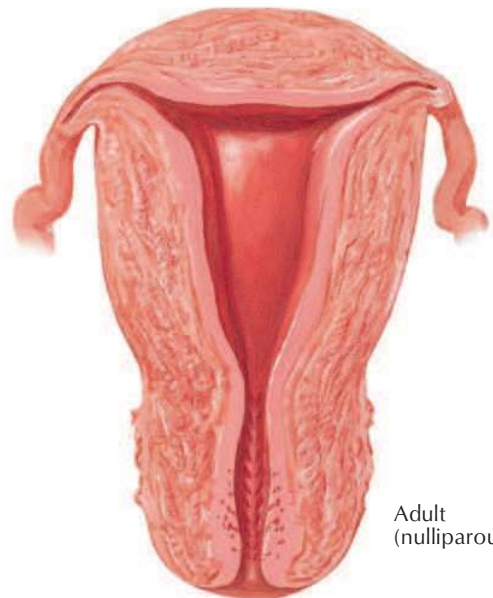
Newborn



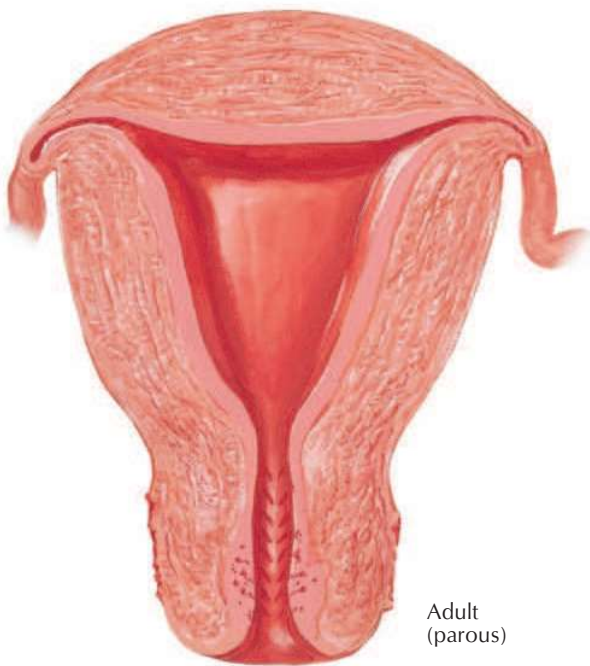
4 years



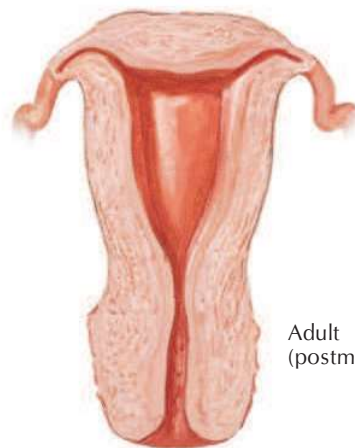
Puberty



Adult (nulliparous)

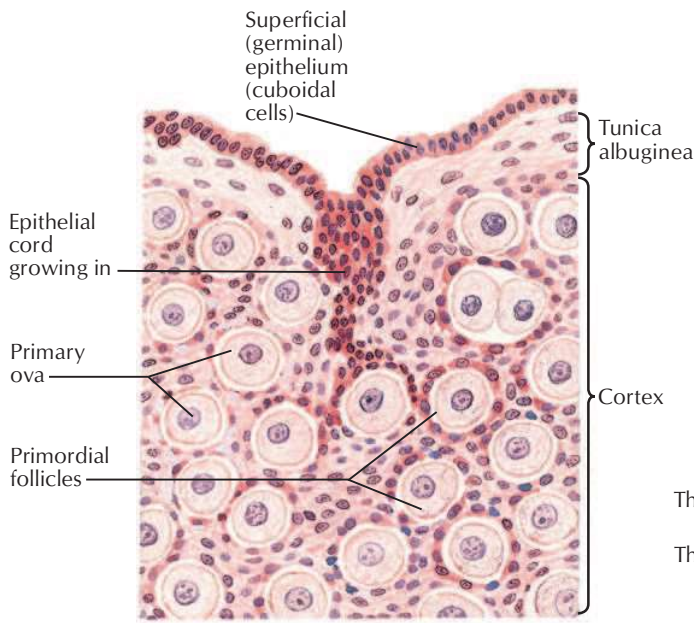


Adult (parous)

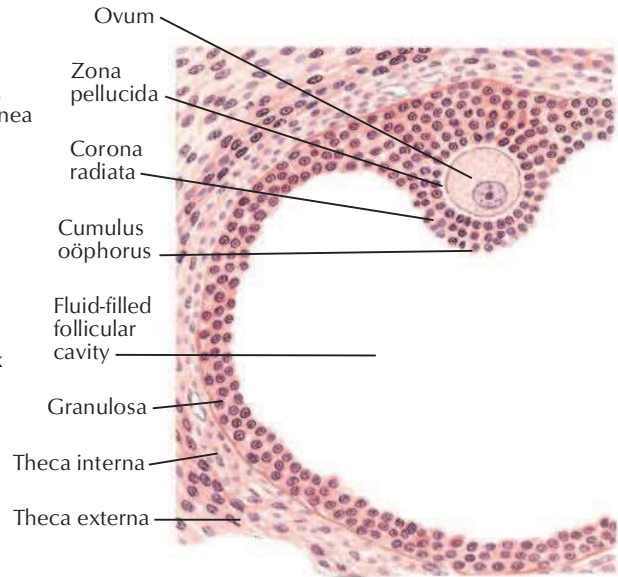


Adult (postmenopausal)

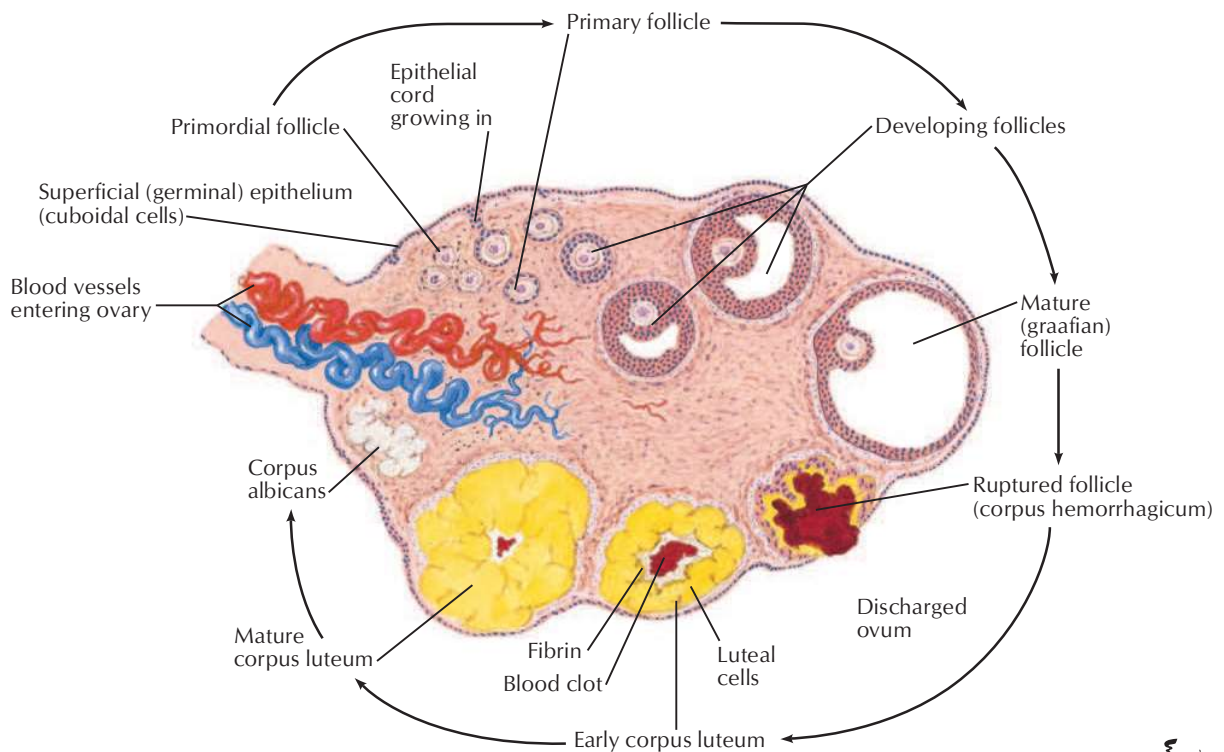
F. Netter M.D.



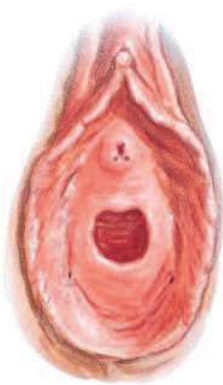Infant ovary



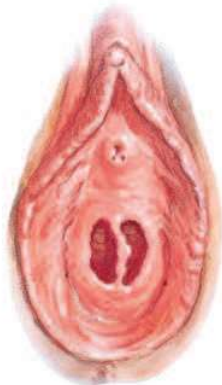Ripening follicle



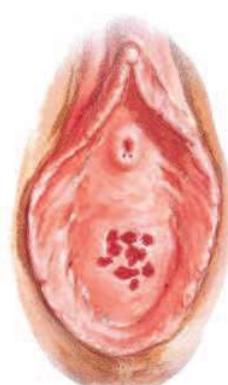
Stages of ovum and follicle



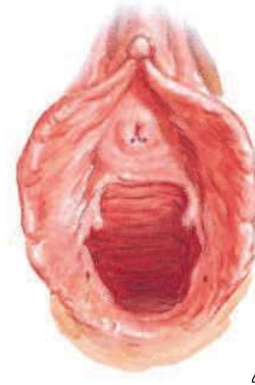
Annular hymen



Septate hymen



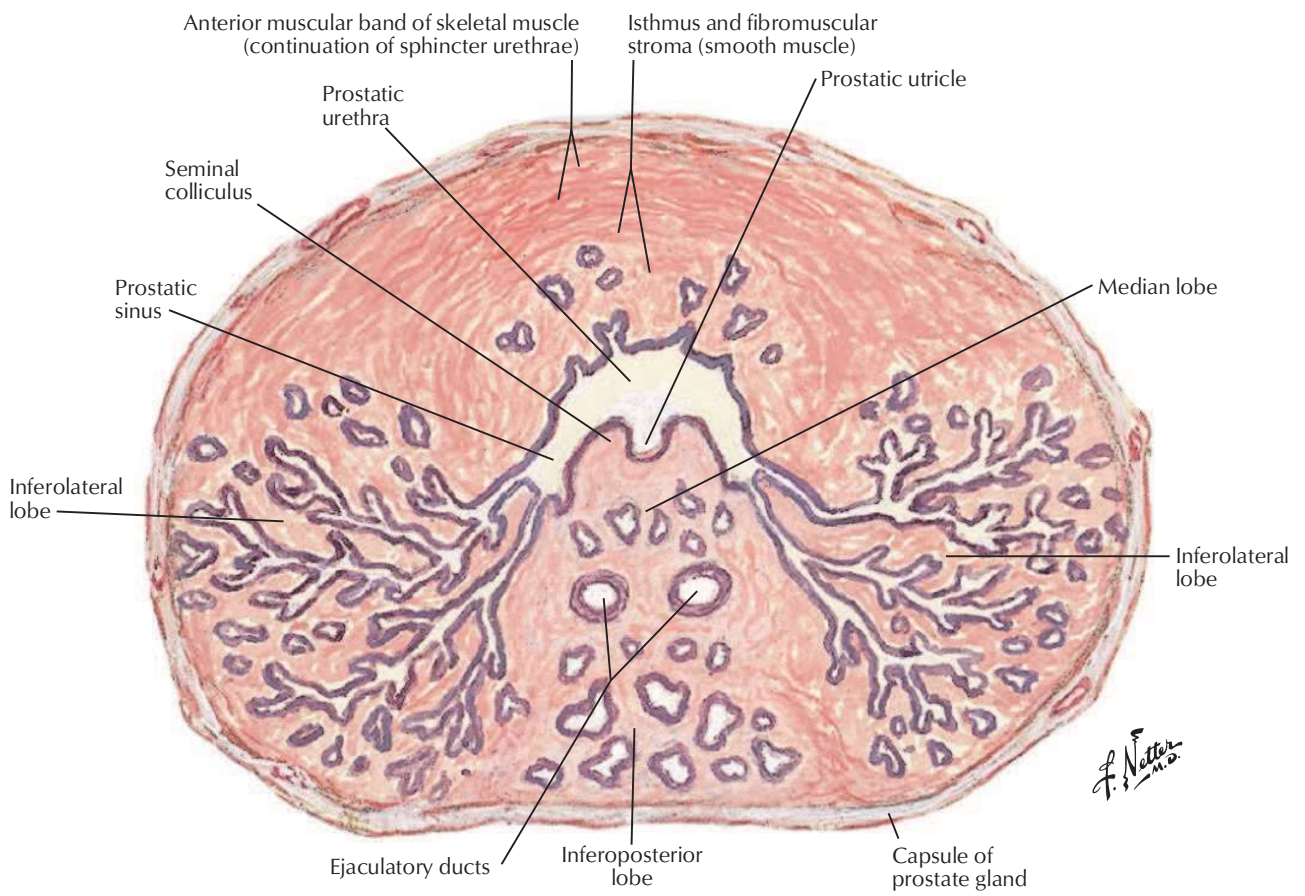
Cribriform hymen



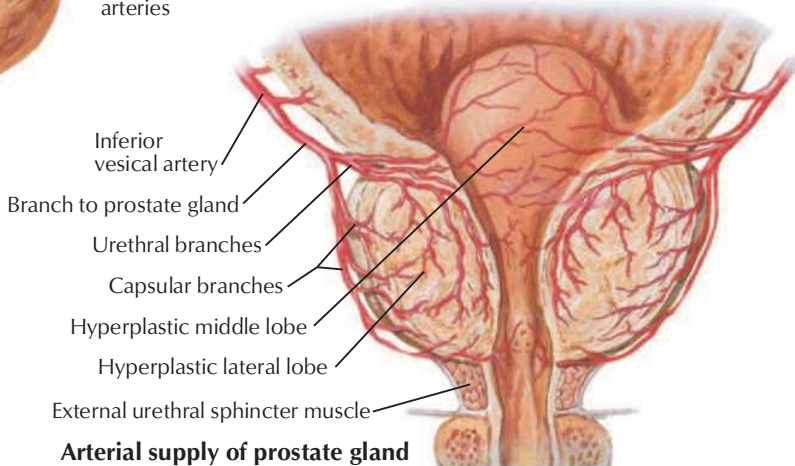
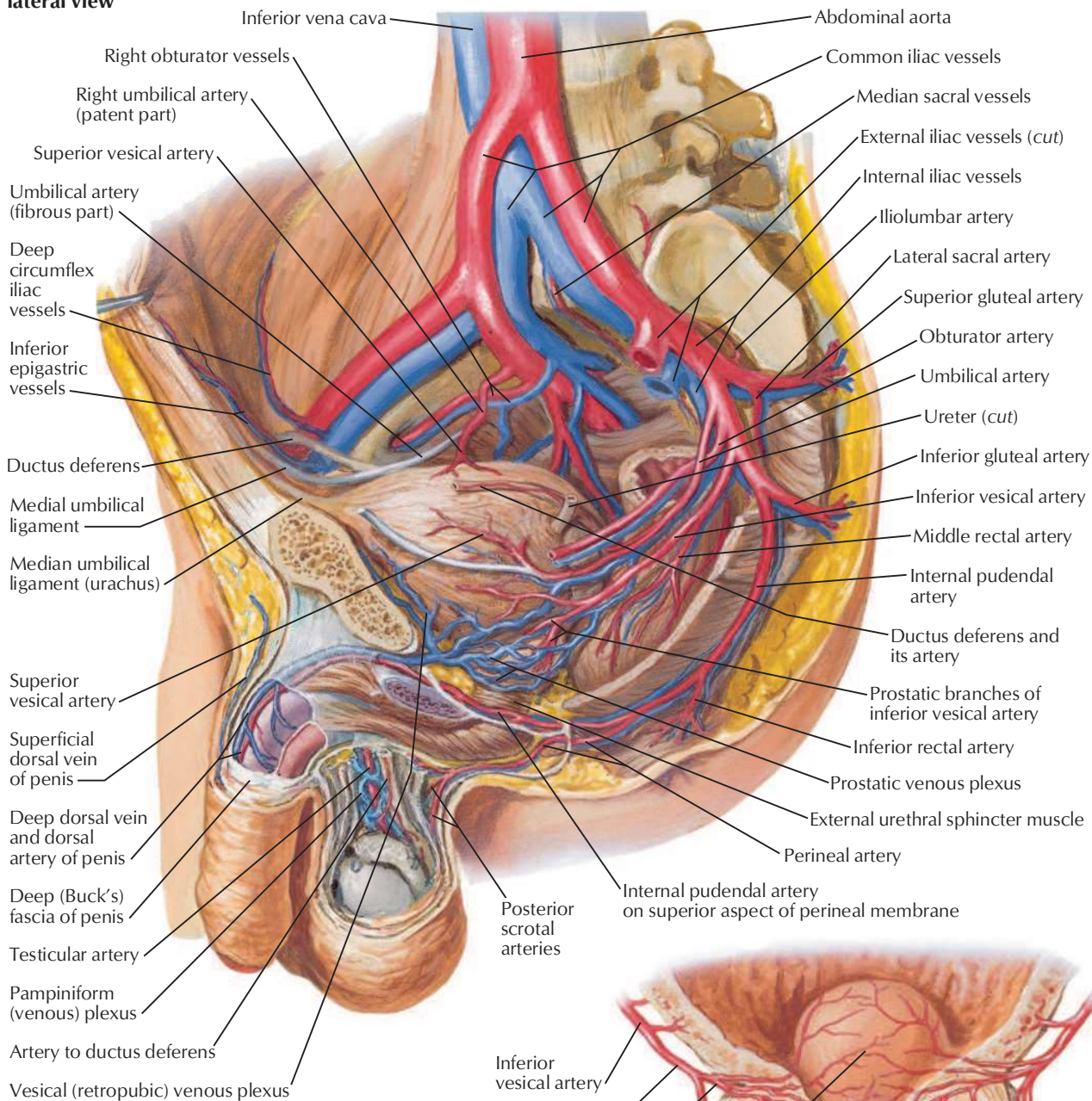
Parous introitus

F. Netter M.D.

Cross Section Through Prostate



**Left paramedian section:
lateral view**



Arterial supply of prostate gland
(frontal section, anterior view of specimen with benign hyperplasia)

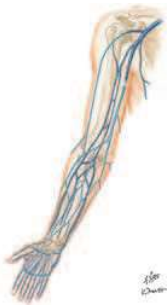This page intentionally left blank

UPPER LIMB

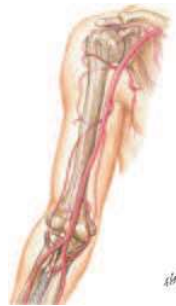7

Surface Anatomy	402	Neurovasculature	462-469
Cutaneous Anatomy	403-407	Regional Imaging	470
Shoulder and Axilla	408-420	Structures With High Clinical	
Arm	421-425	Significance	Tables 7.1-7.2
Elbow and Forearm	426-441	Muscle Tables	Tables 7.3-7.6
Wrist and Hand	442-461	Electronic Bonus Plates	BP99-BP106

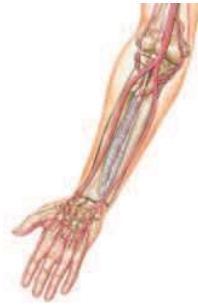ELECTRONIC BONUS PLATES



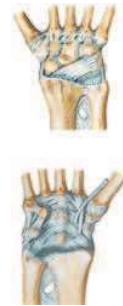BP99 Veins of Upper Limb



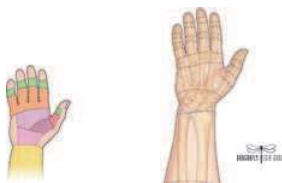
BP100 Arteries of Arm and Proximal Forearm



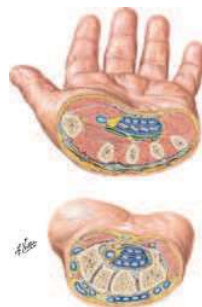BP101 Arteries of Forearm and Hand



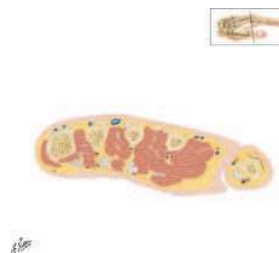BP102 Ligaments of Wrist and Hand



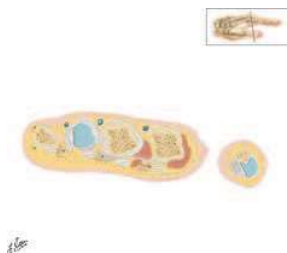BP103 Flexor and Extensor Zones of Hand



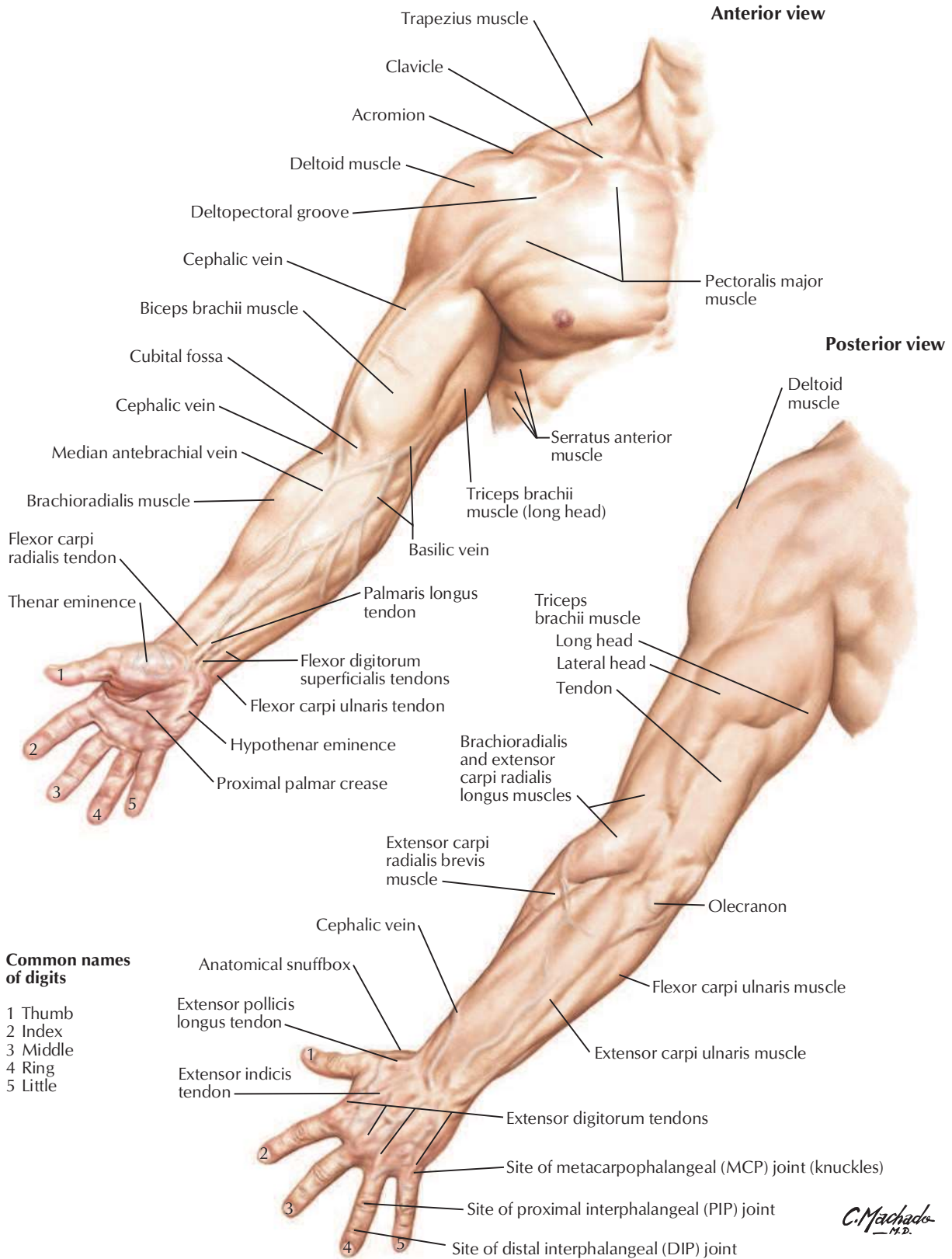
BP104 Section Through Metacarpal and Distal Carpal Bones



BP105 Cross Section of Hand: Axial View



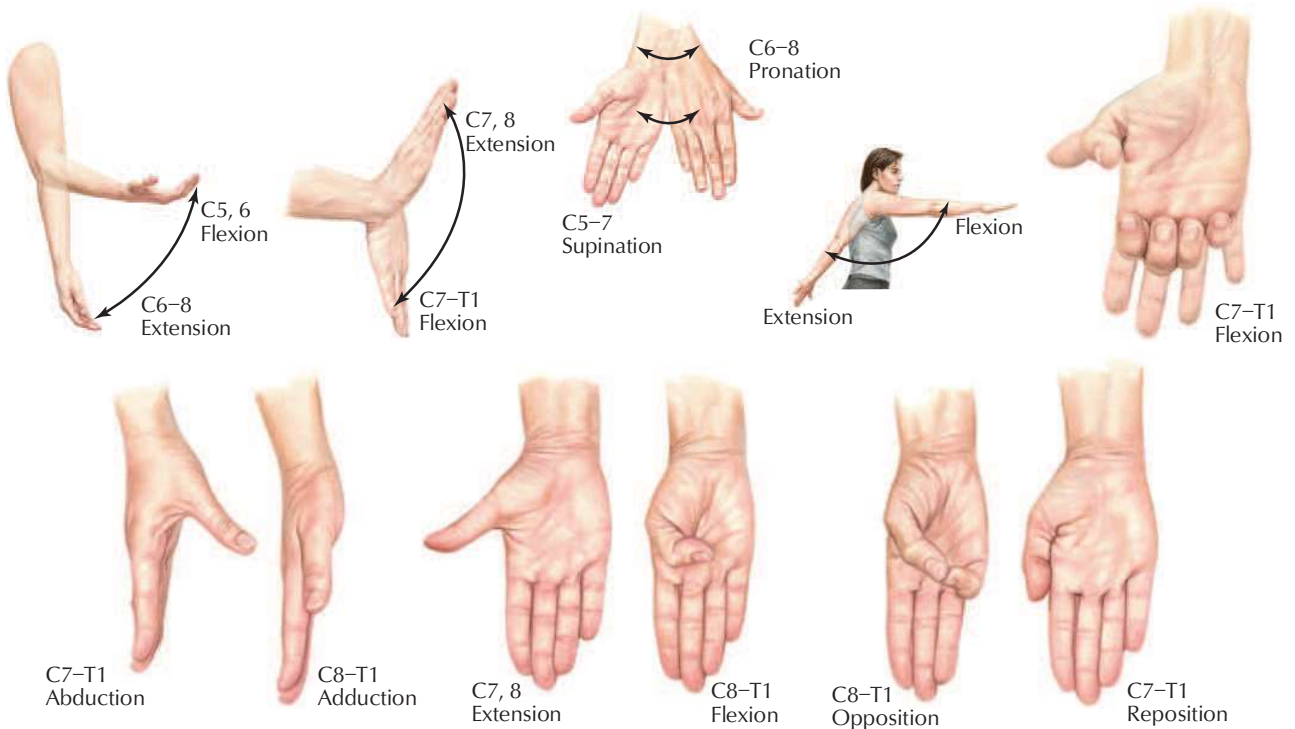
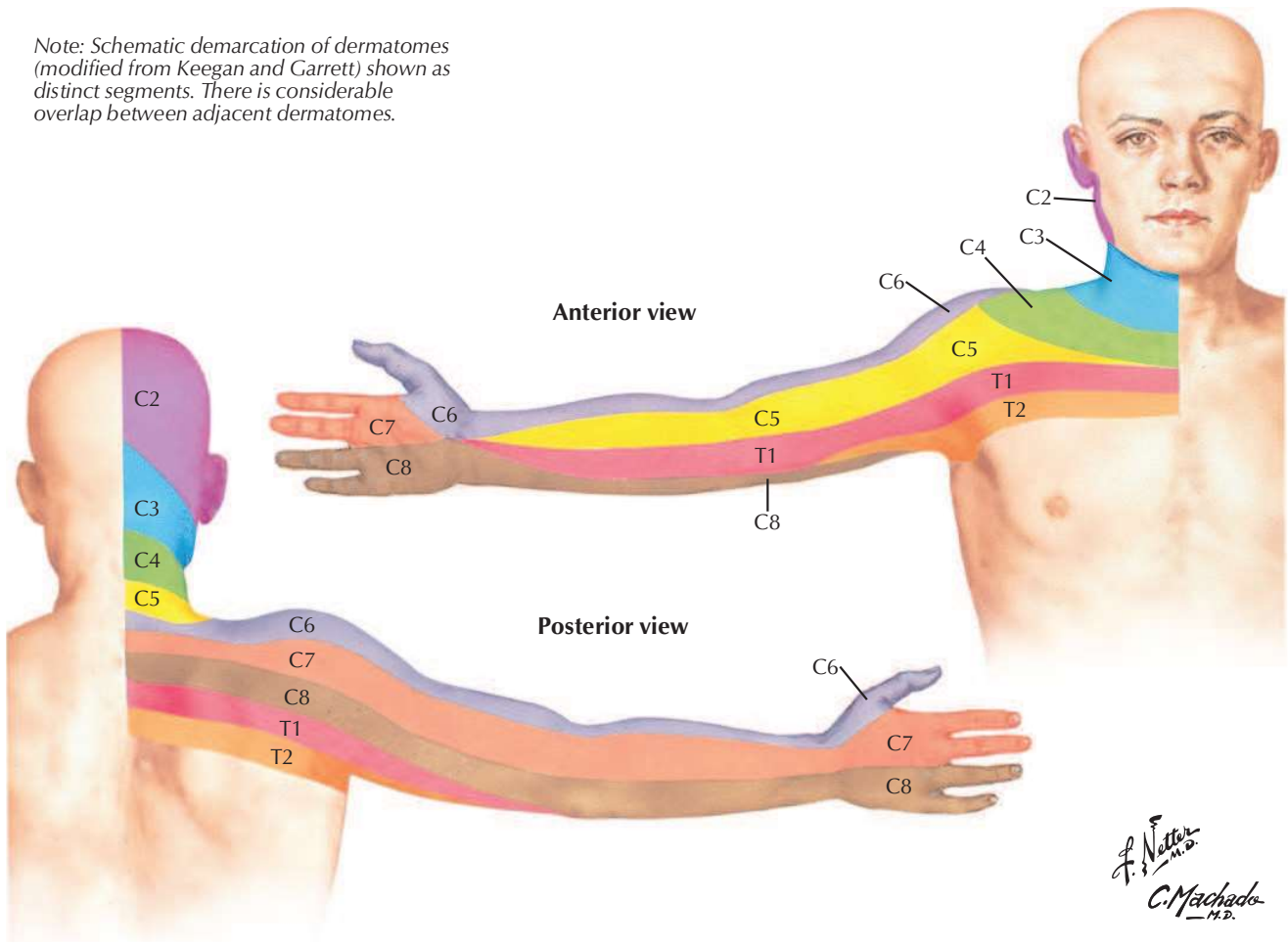
BP106 Cross Section of Hand: Axial View (continued)



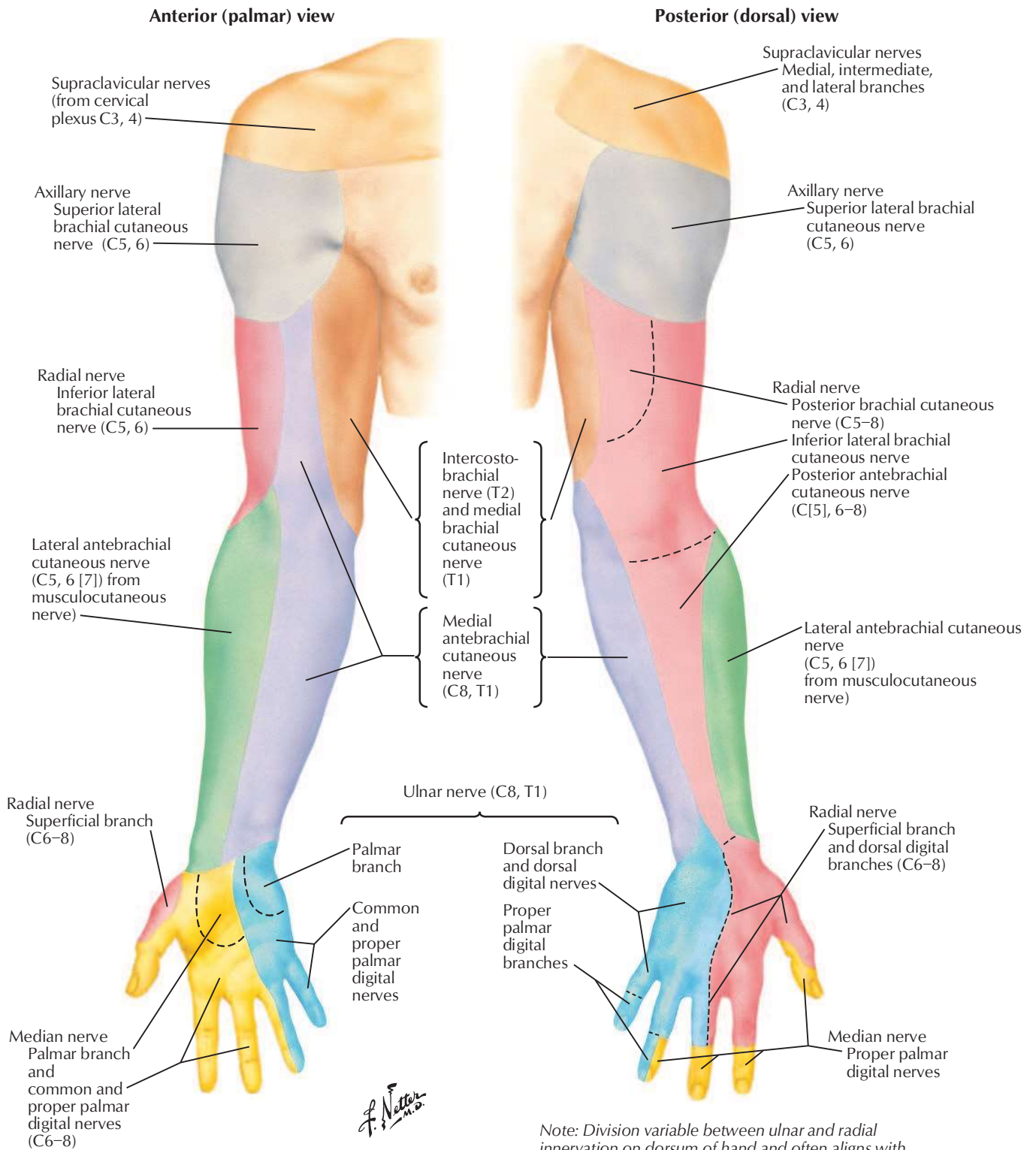
Dermatomes of Upper Limb and Segmental Nerve Function

See also [Plate 171](#)

Note: Schematic demarcation of dermatomes (modified from Keegan and Garrett) shown as distinct segments. There is considerable overlap between adjacent dermatomes.



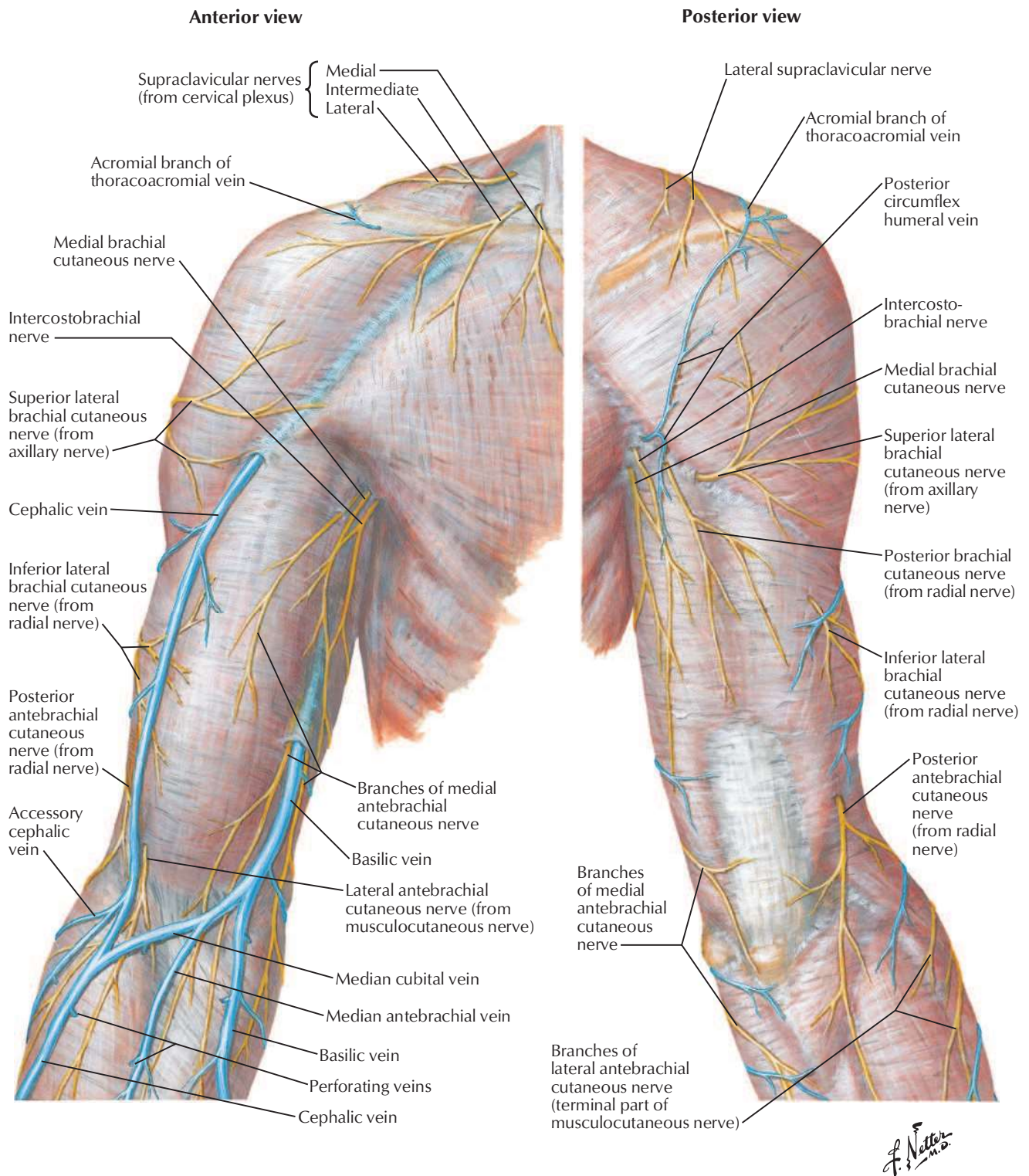
See also [Plates 172, 462, 464](#)



Note: Division variable between ulnar and radial innervation on dorsum of hand and often aligns with middle of 4th digit instead of 3rd digit as shown.

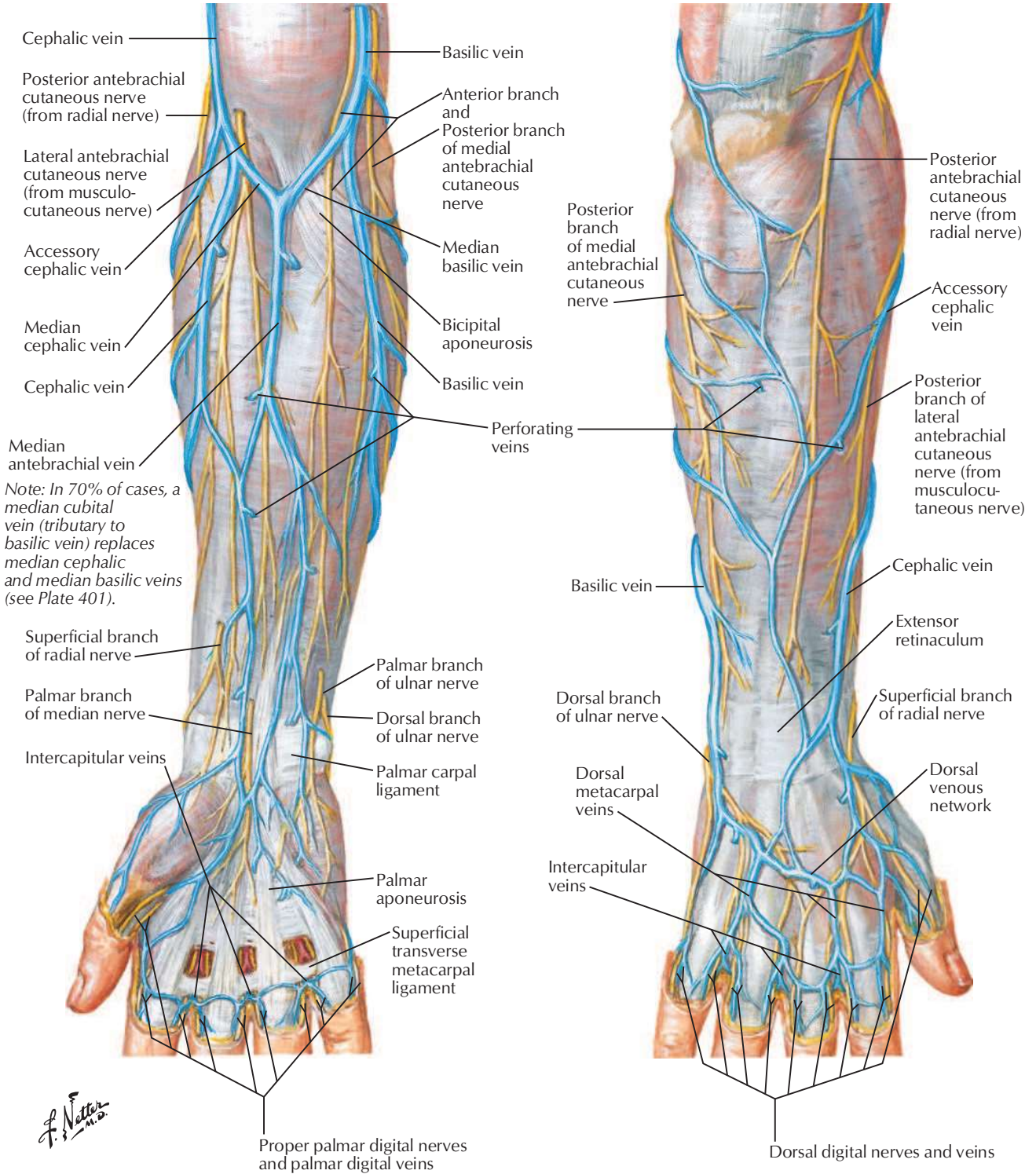
Cutaneous Nerves and Superficial Veins of Proximal Upper Limb

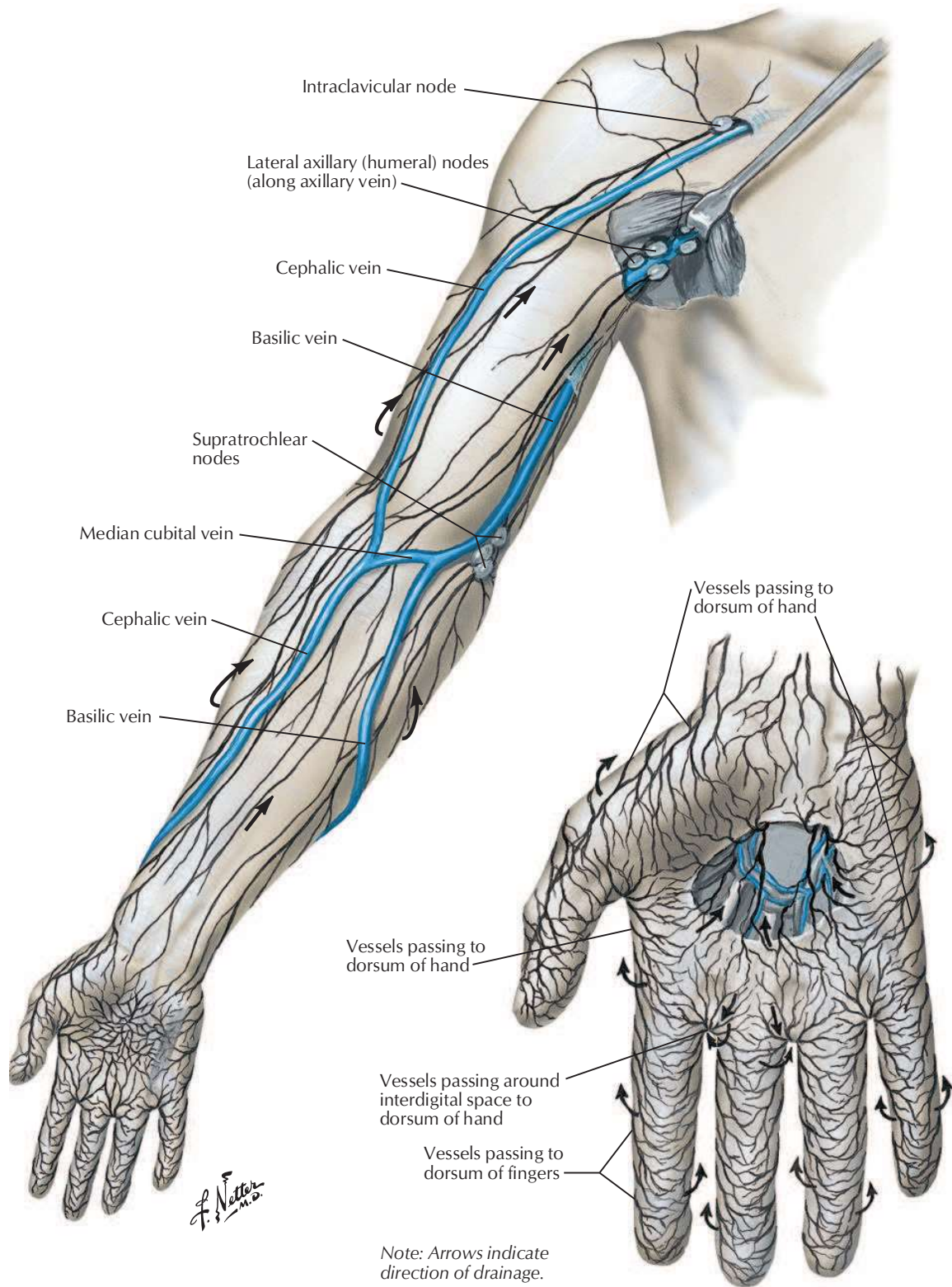
See also [Plates 259, 407](#)



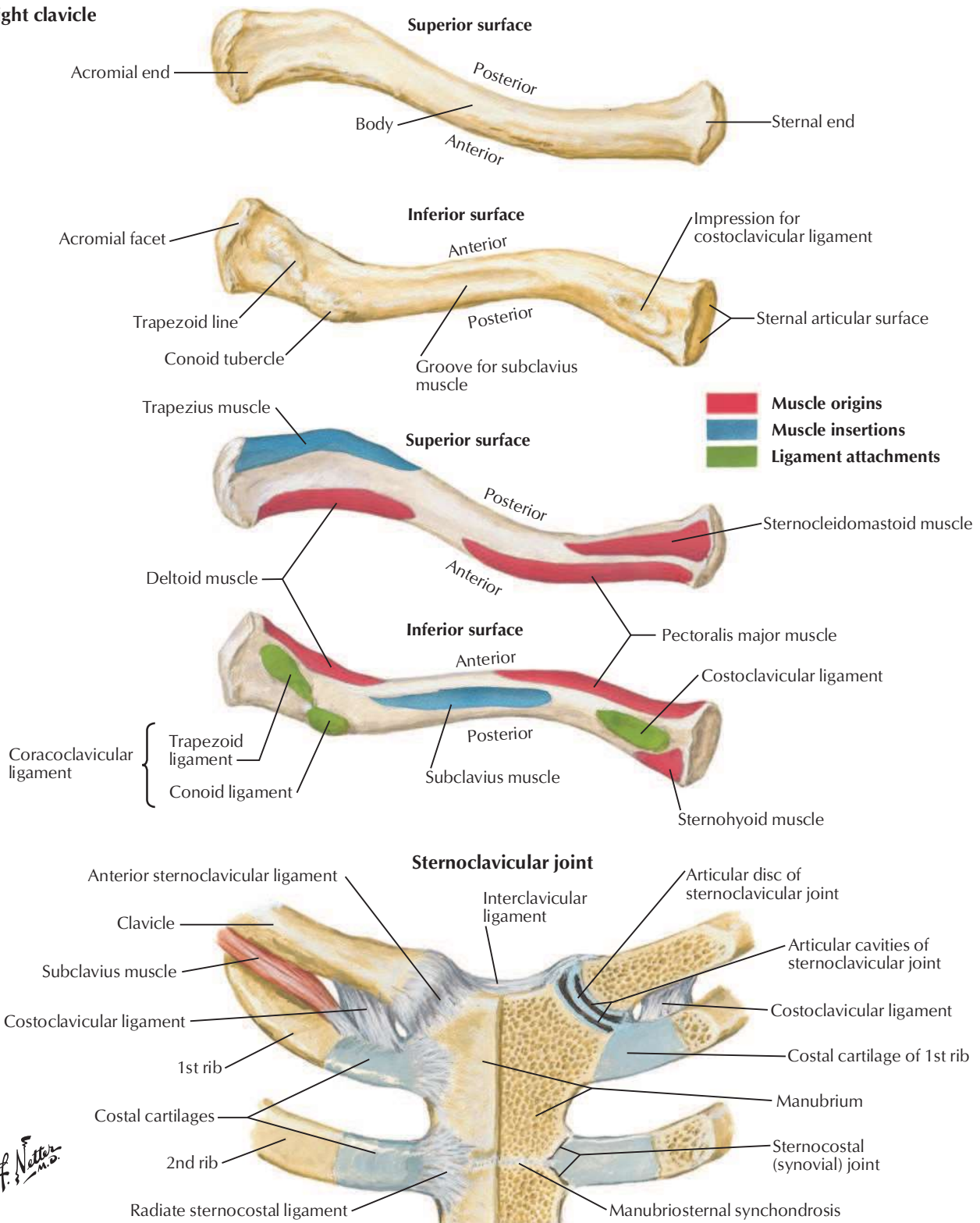
Anterior (palmar) view

Posterior (dorsal) view



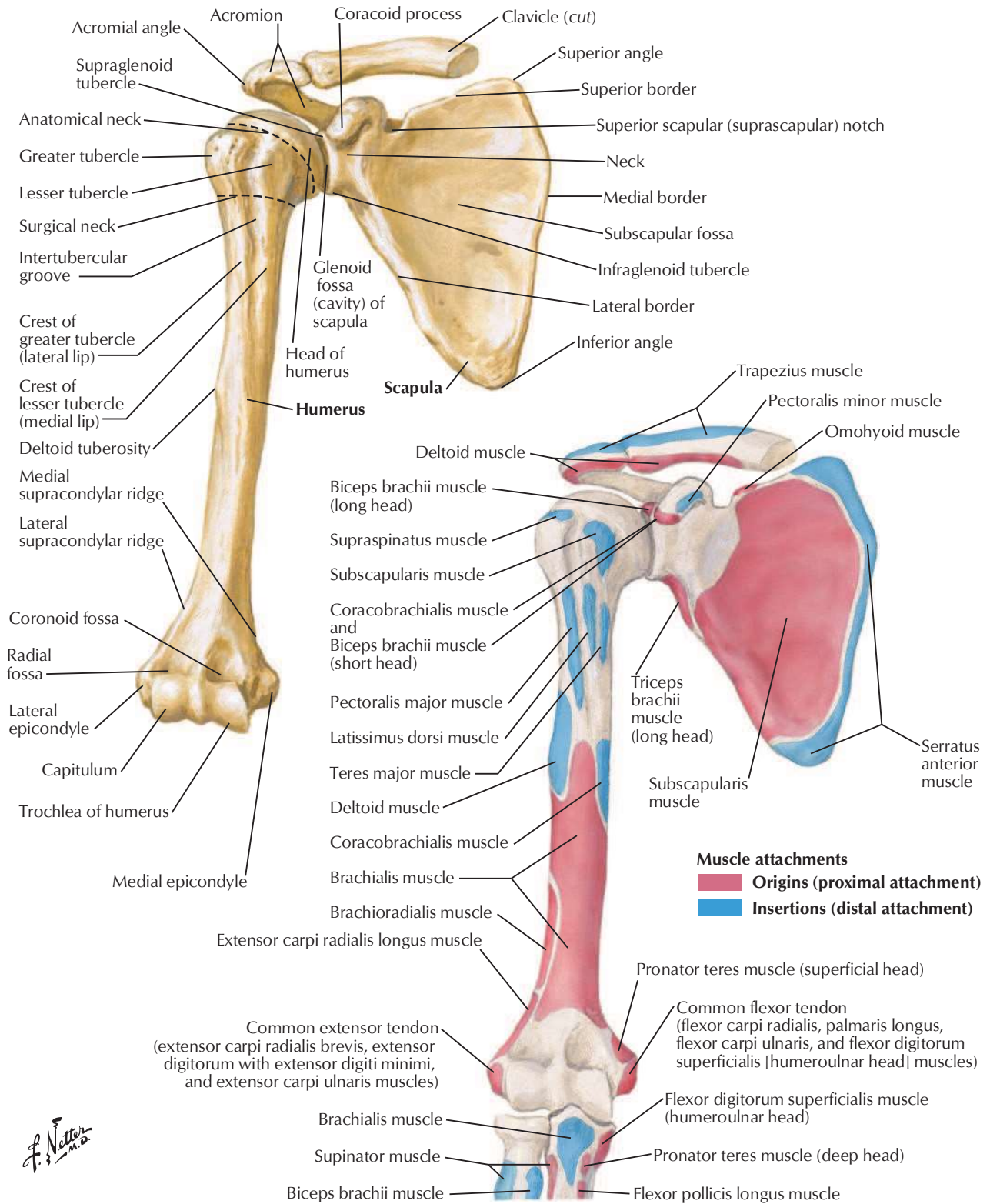


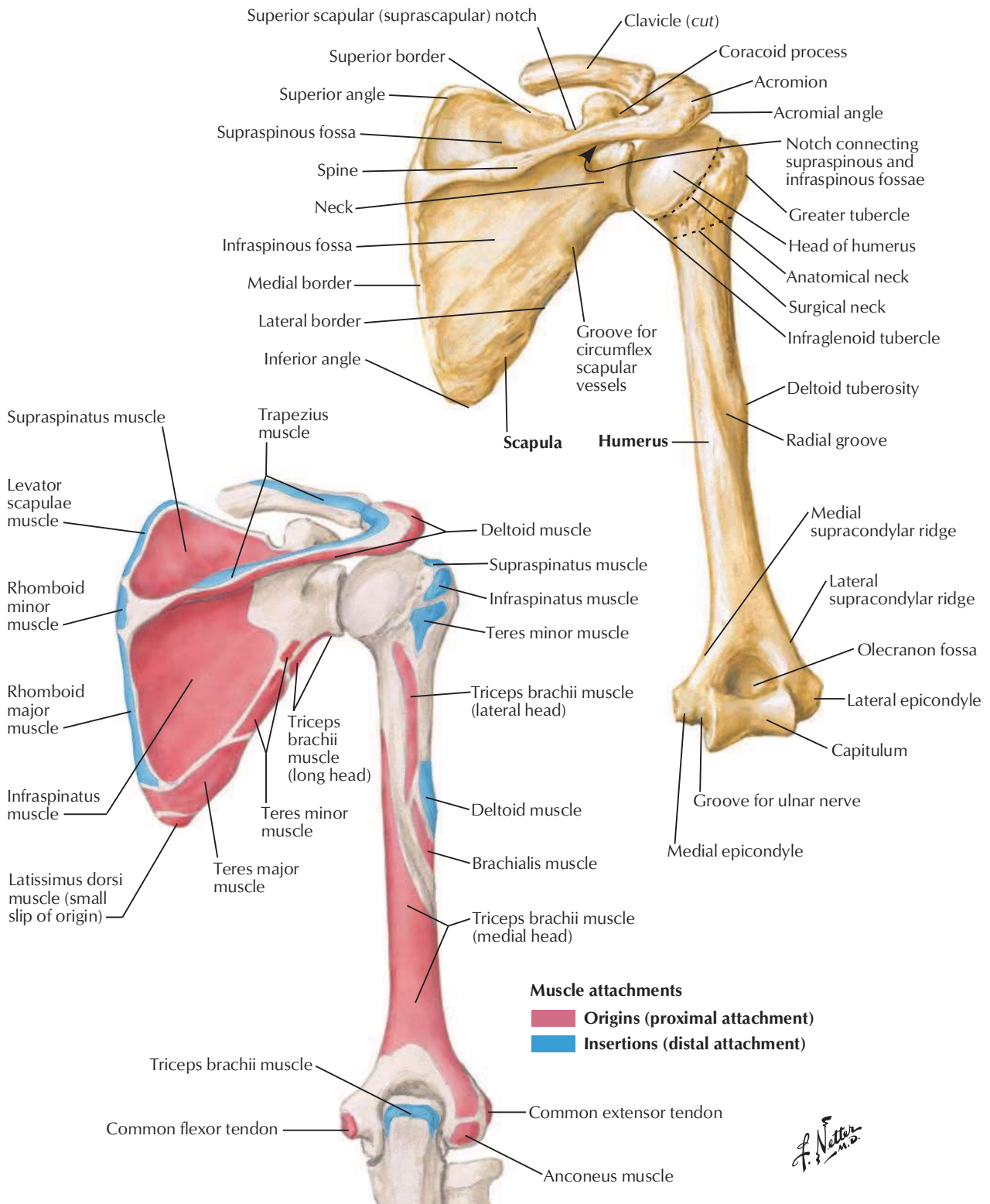
Right clavicle



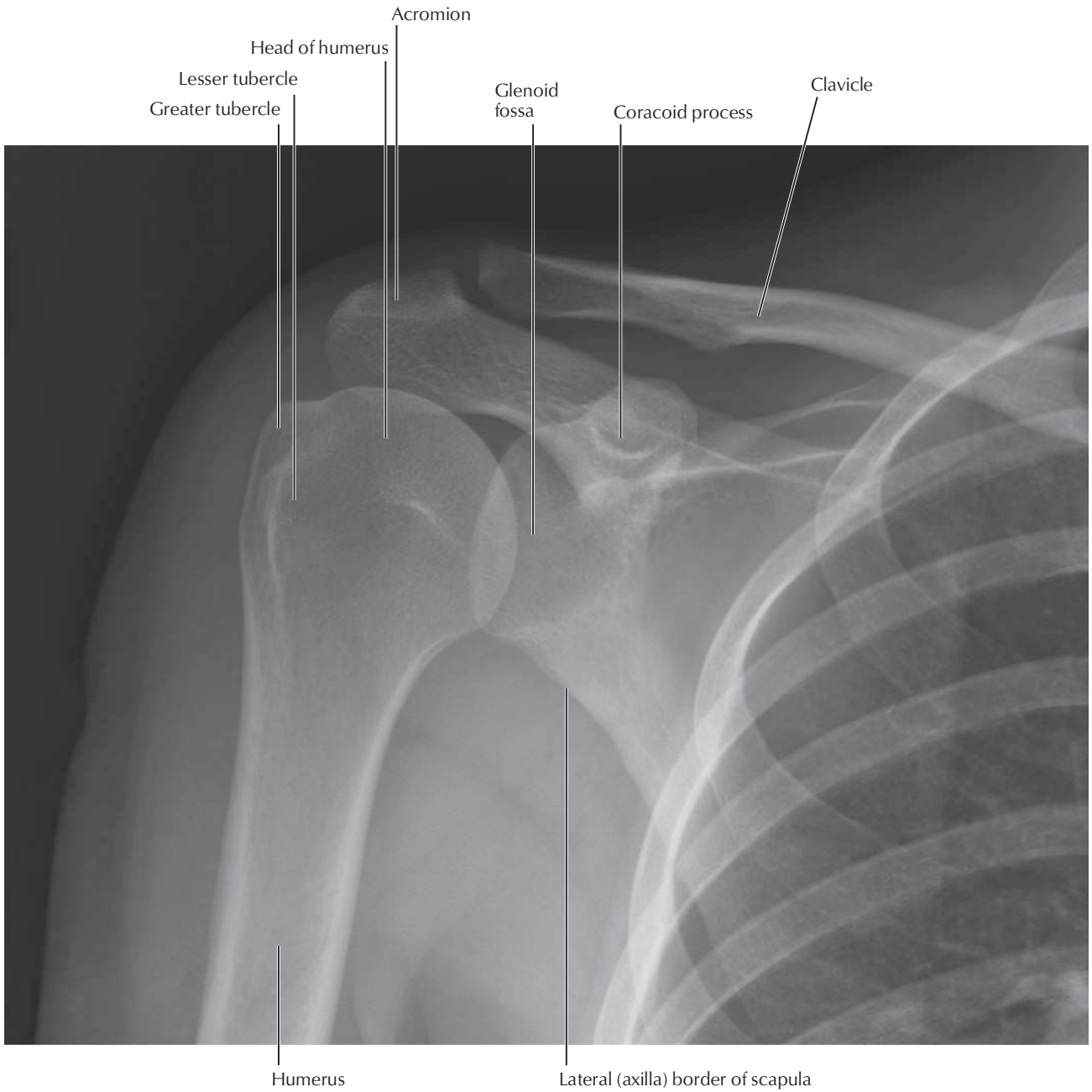
Humerus and Scapula: Anterior Views

See also **Plates 192, 411**

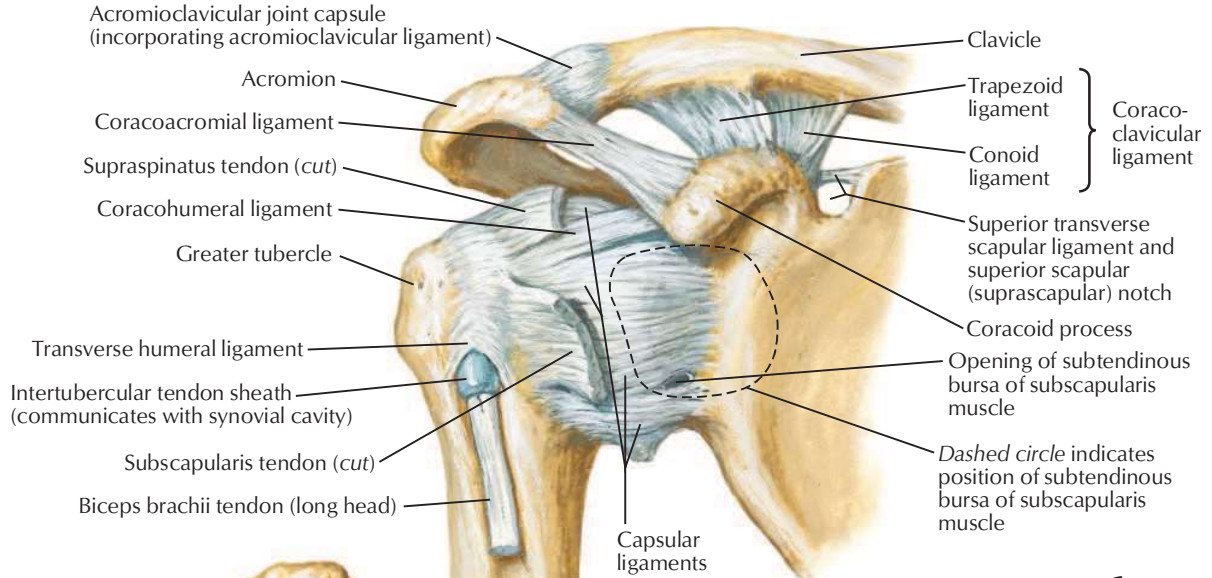




Anteroposterior Radiograph of Shoulder

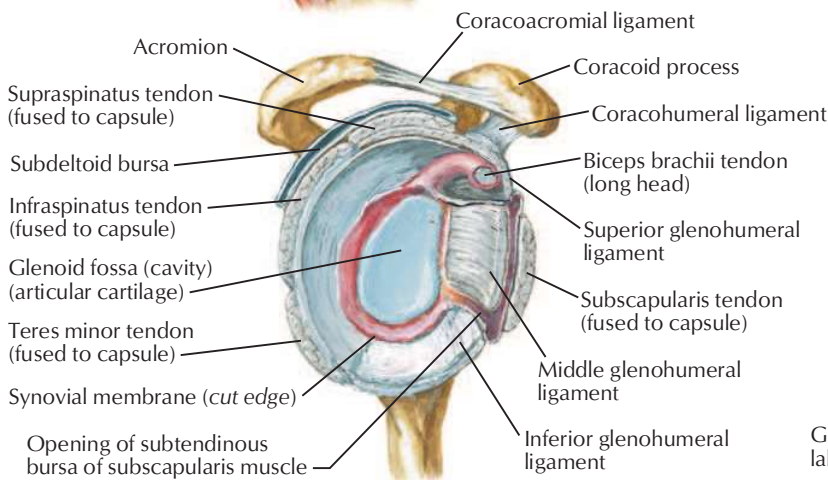
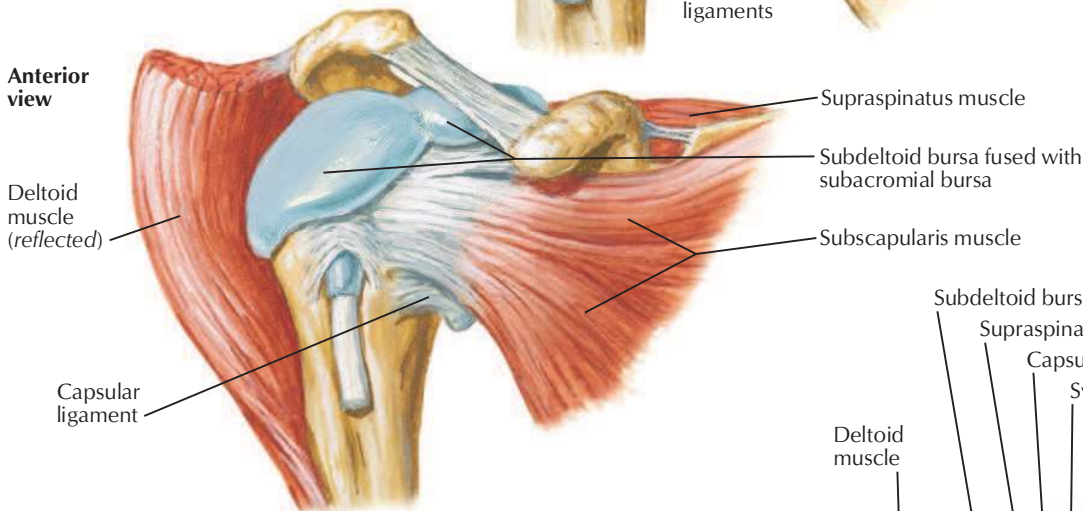


Anterior view

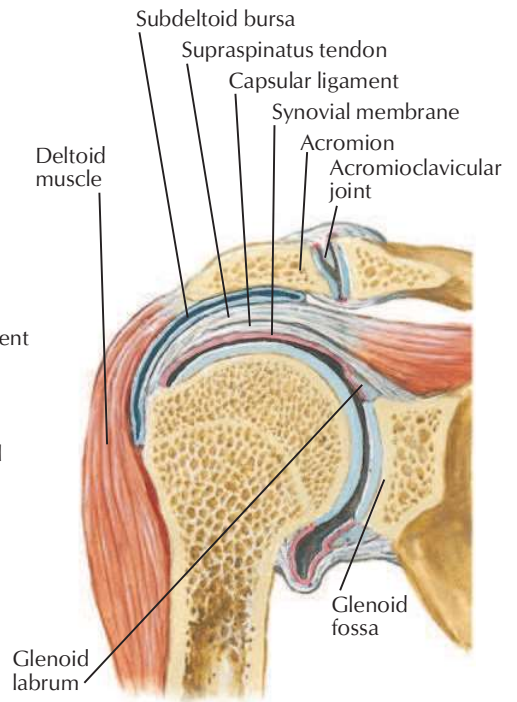


F. Netter M.D.

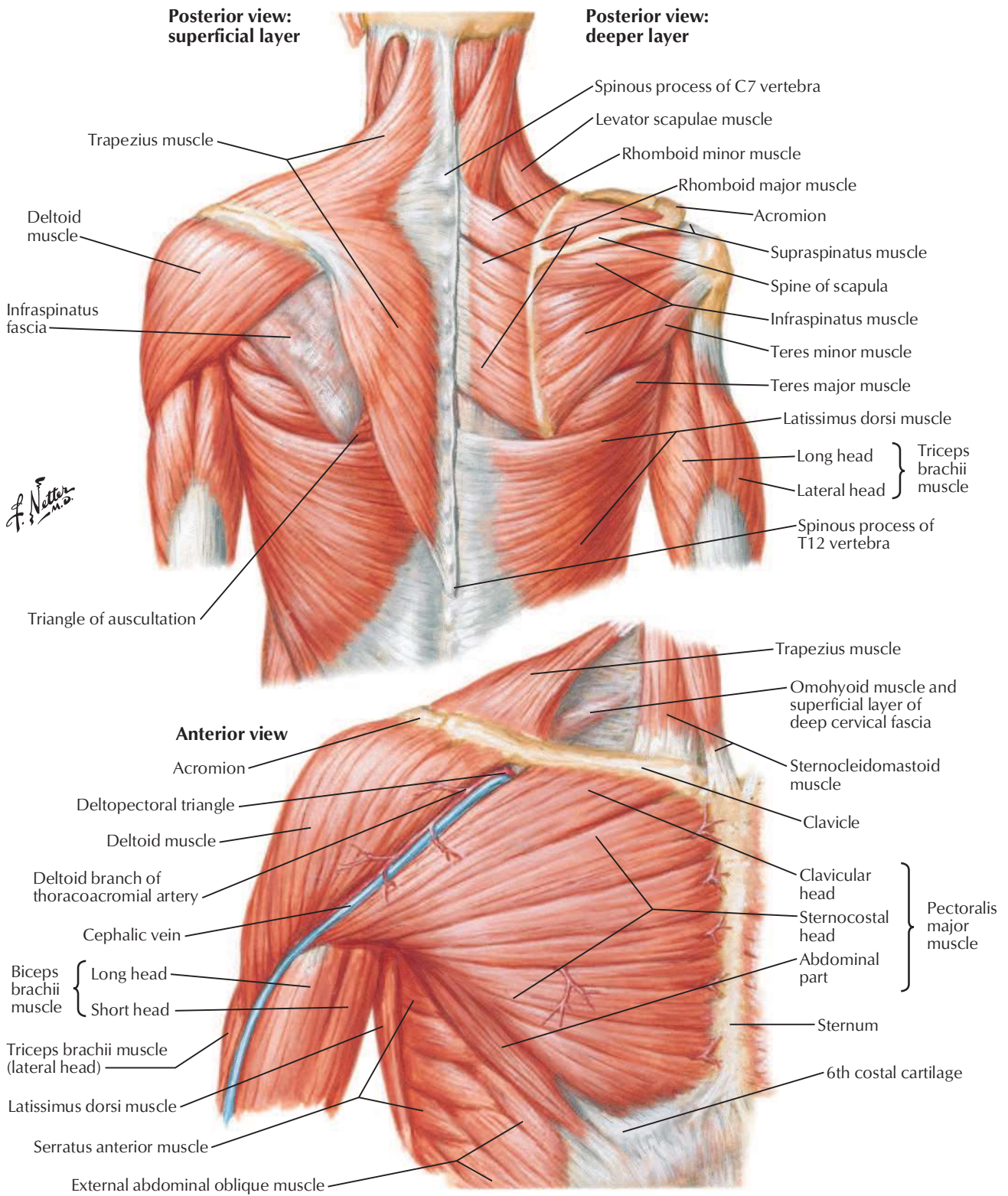
Anterior view

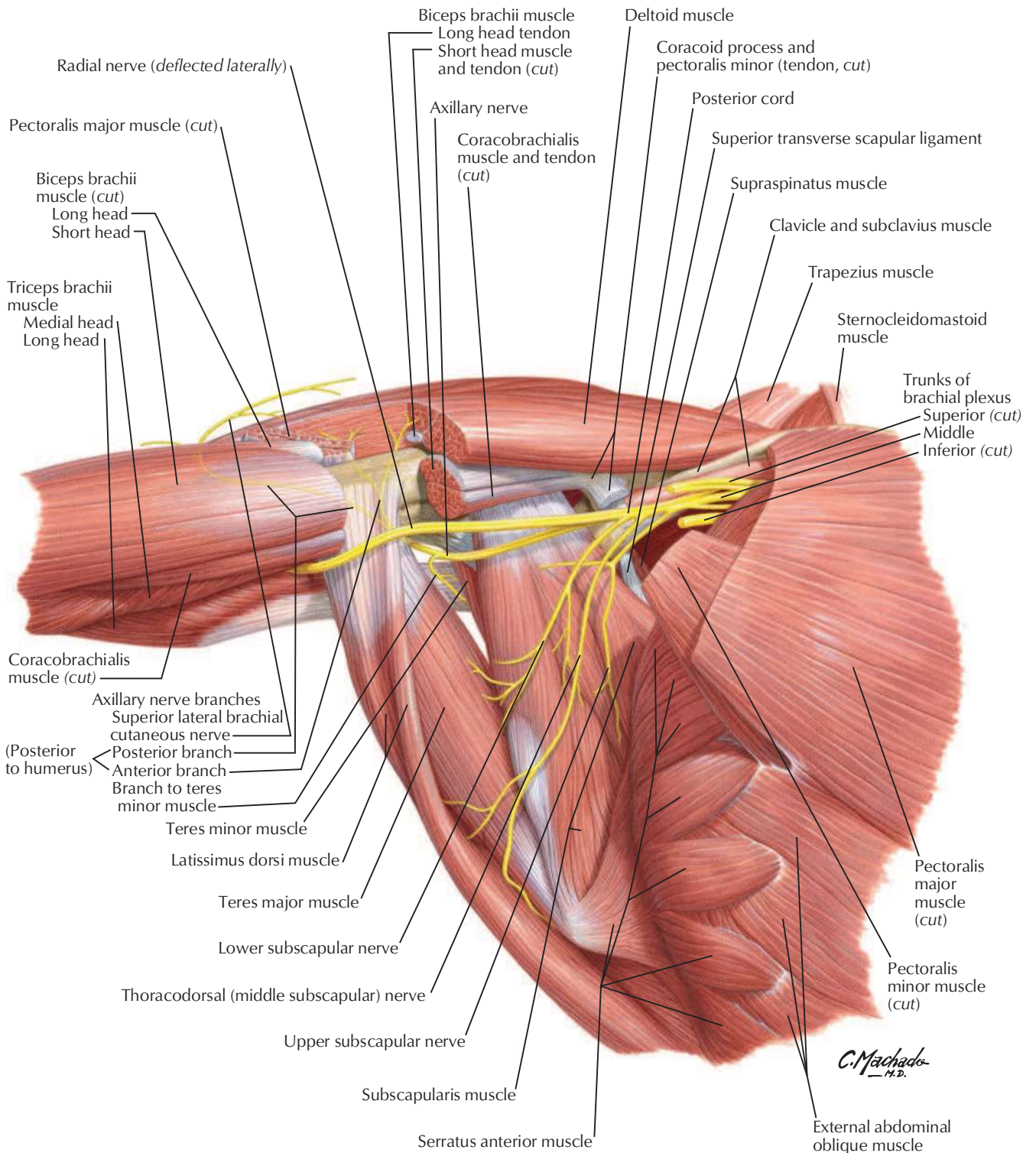


Joint opened: lateral view



Coronal section through shoulder girdle

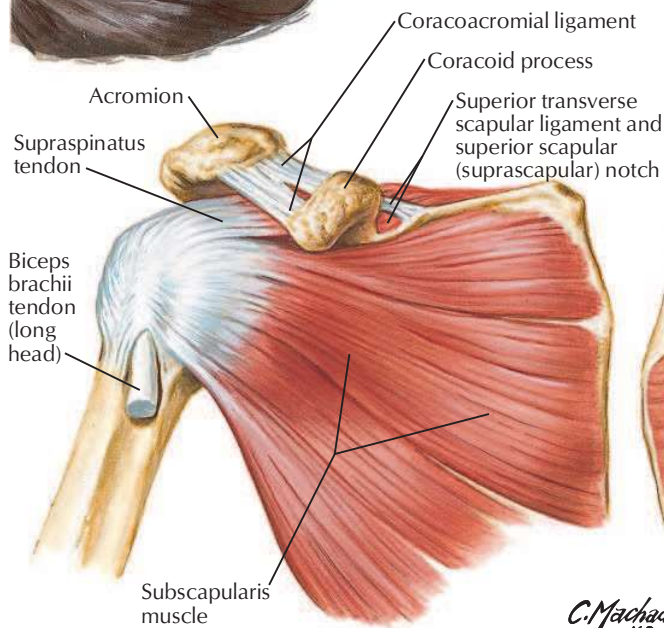
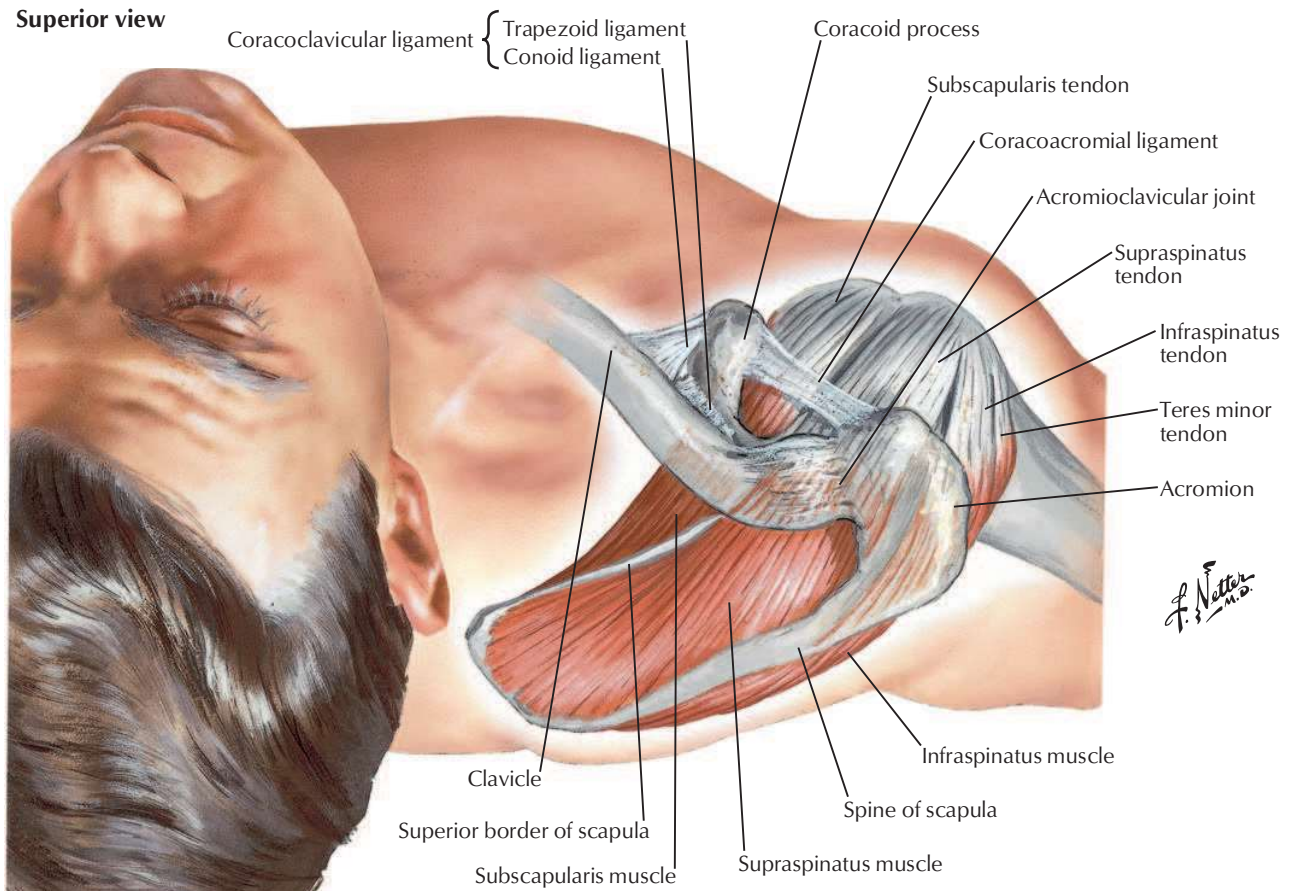




Muscles of Rotator (Compressor) Cuff

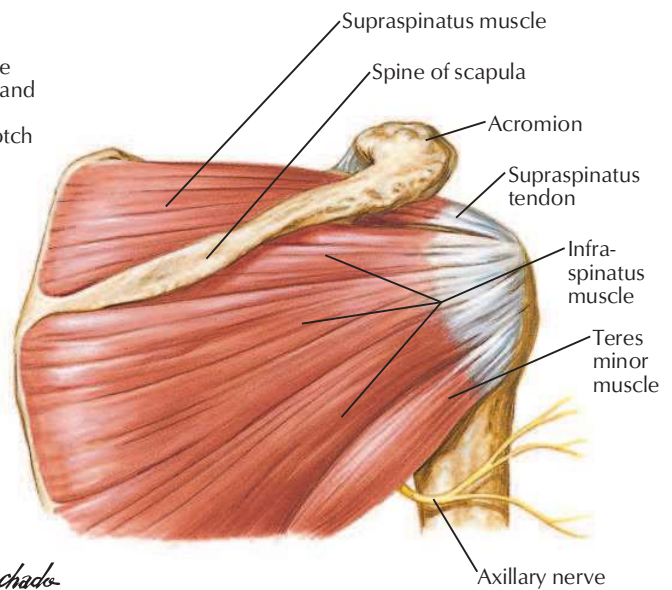
See also [Plates 412, 421, 422](#)

Superior view

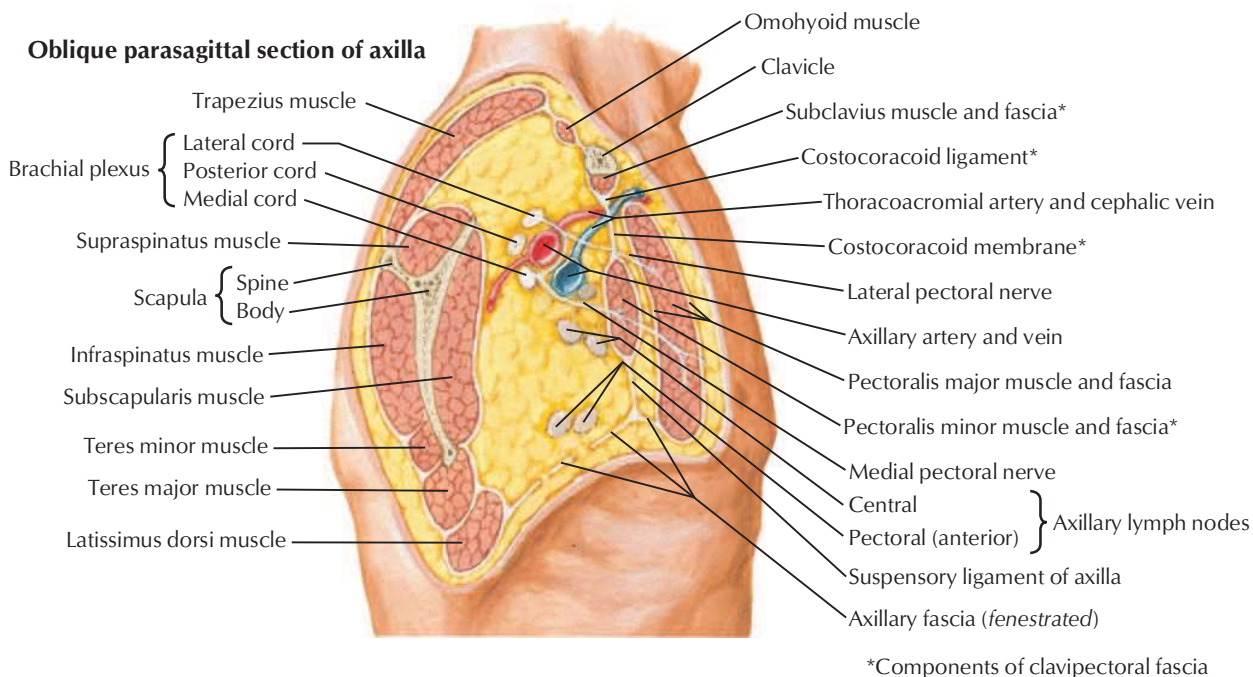
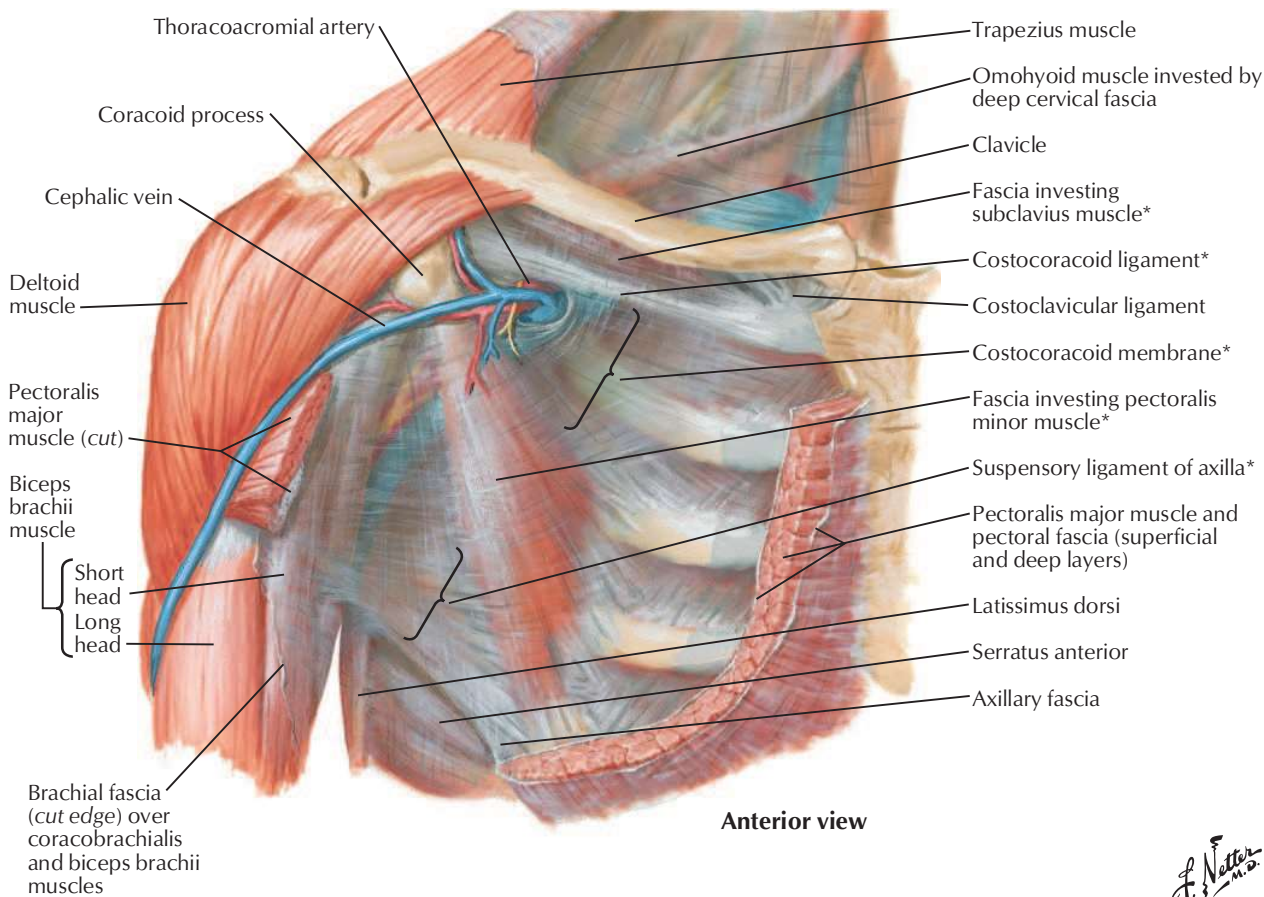


Anterior view

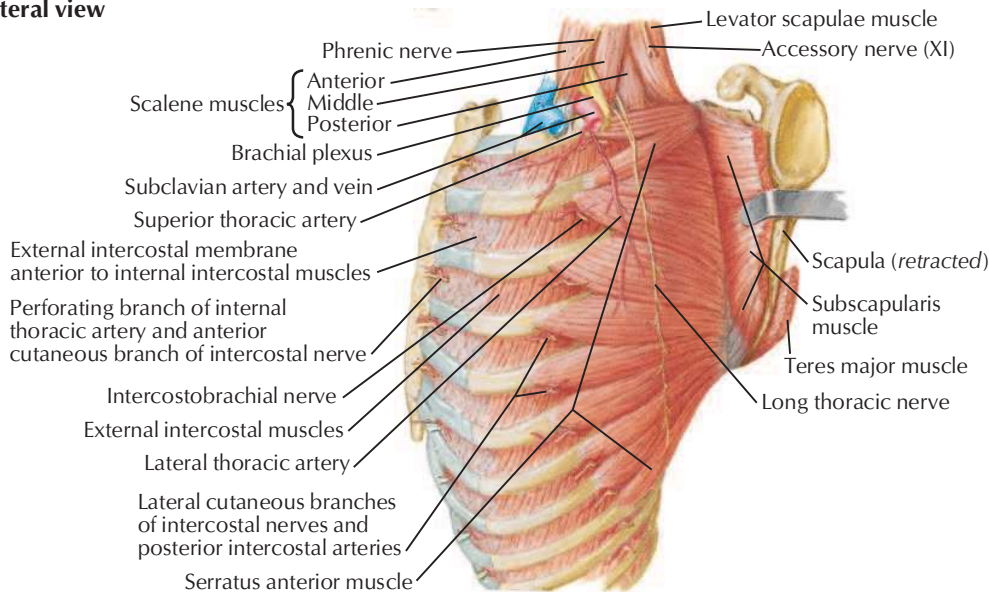
C. Machado M.D.



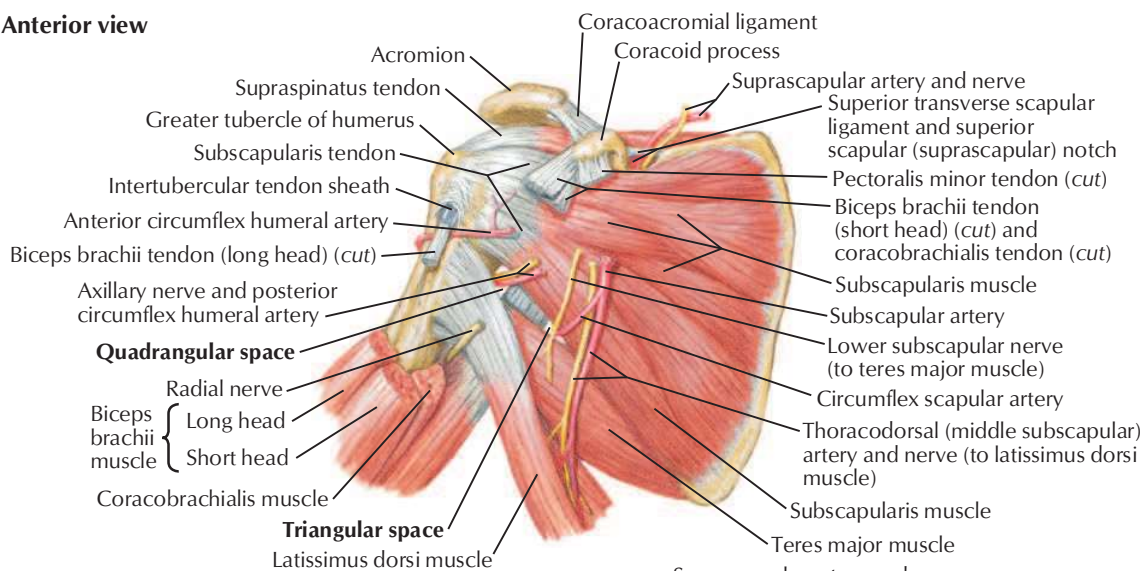
Posterior view



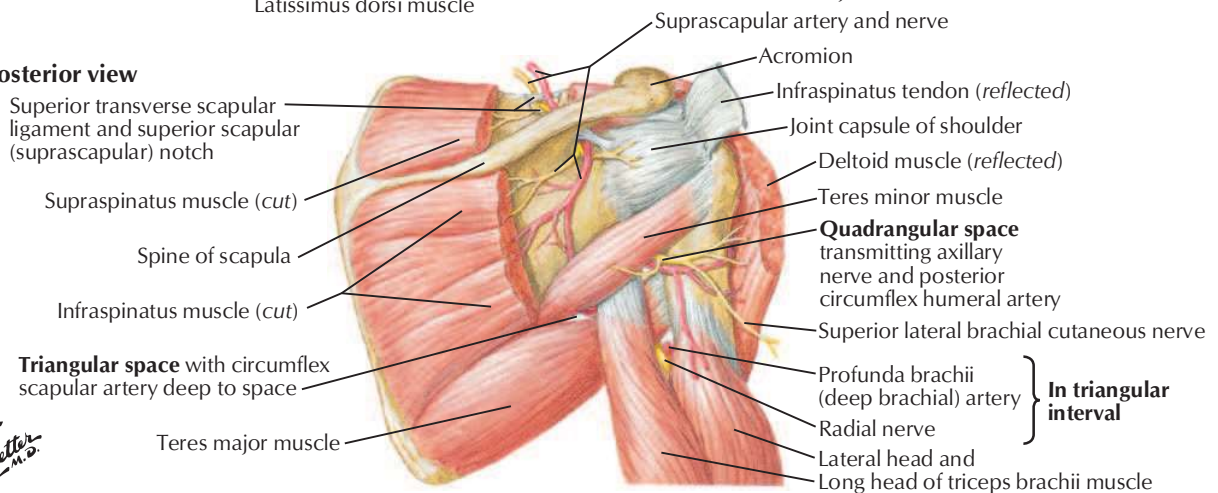
Lateral view

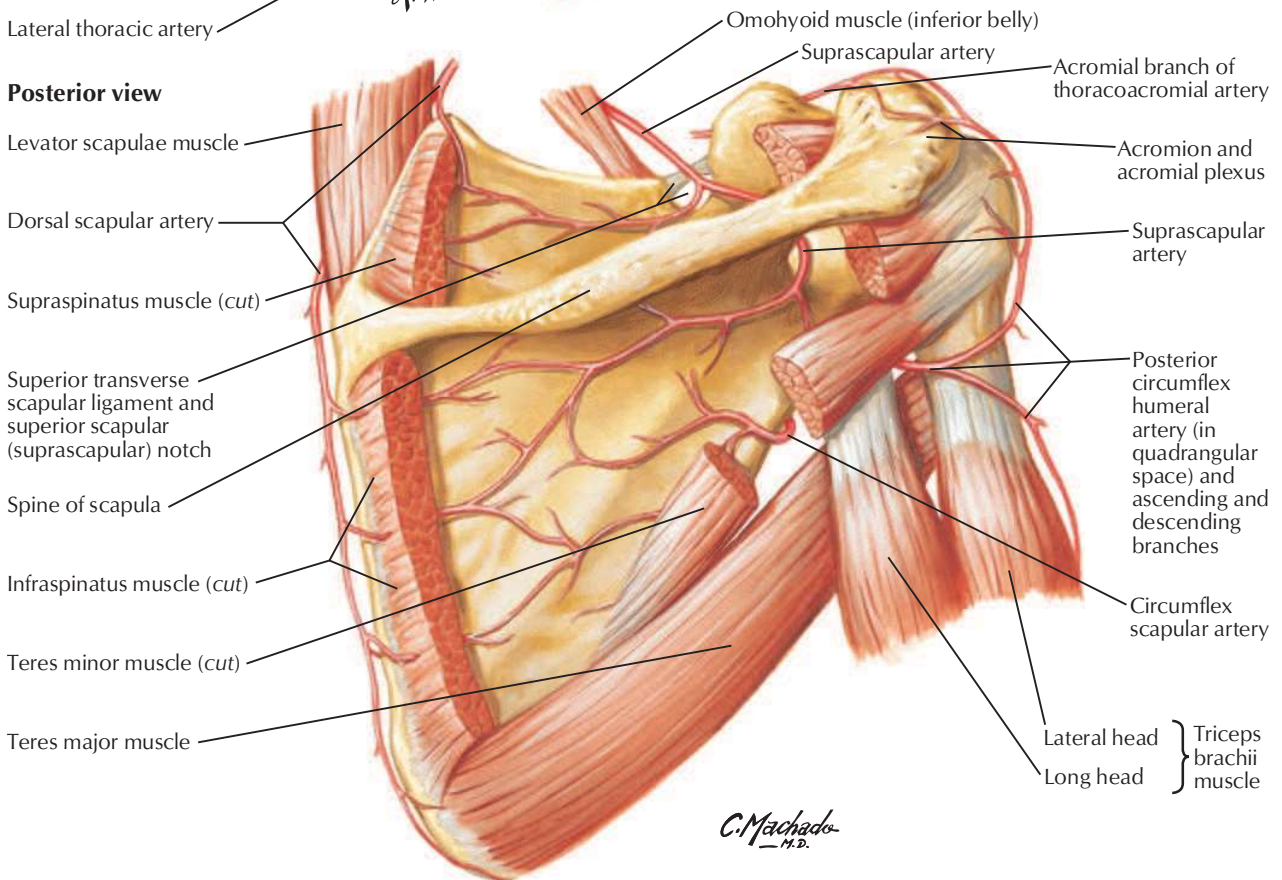
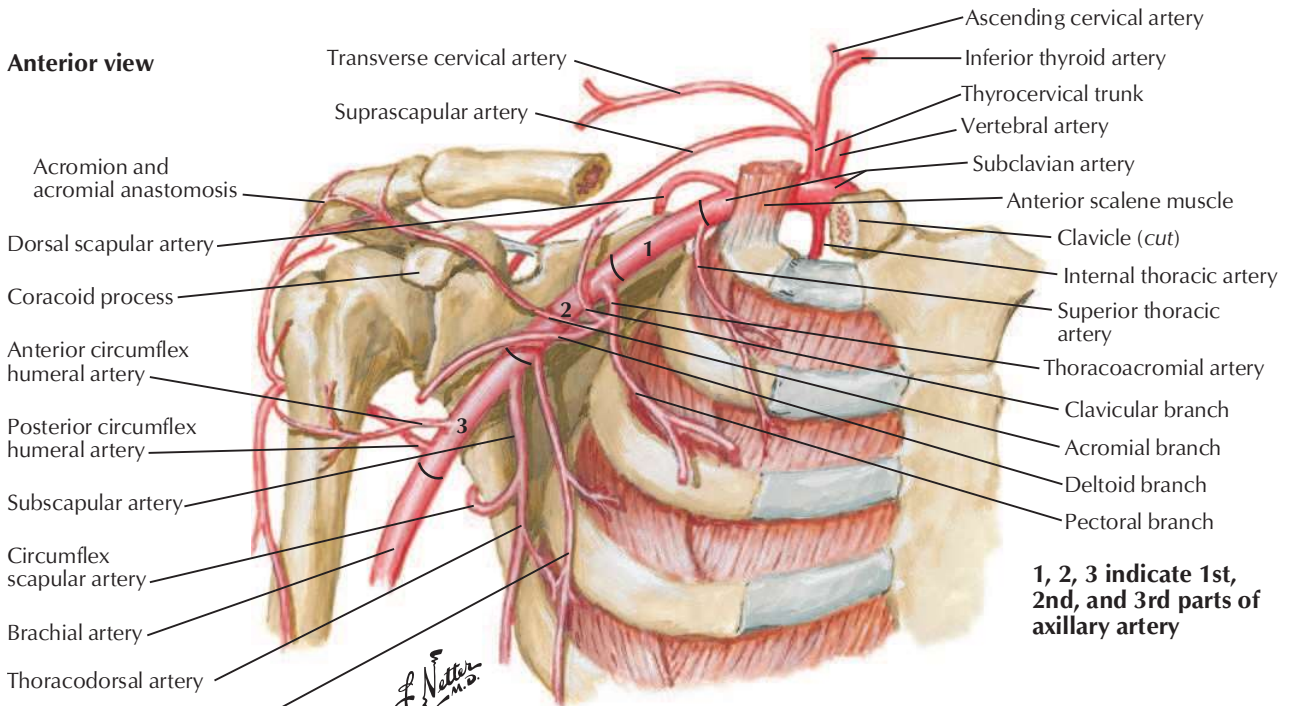


Anterior view



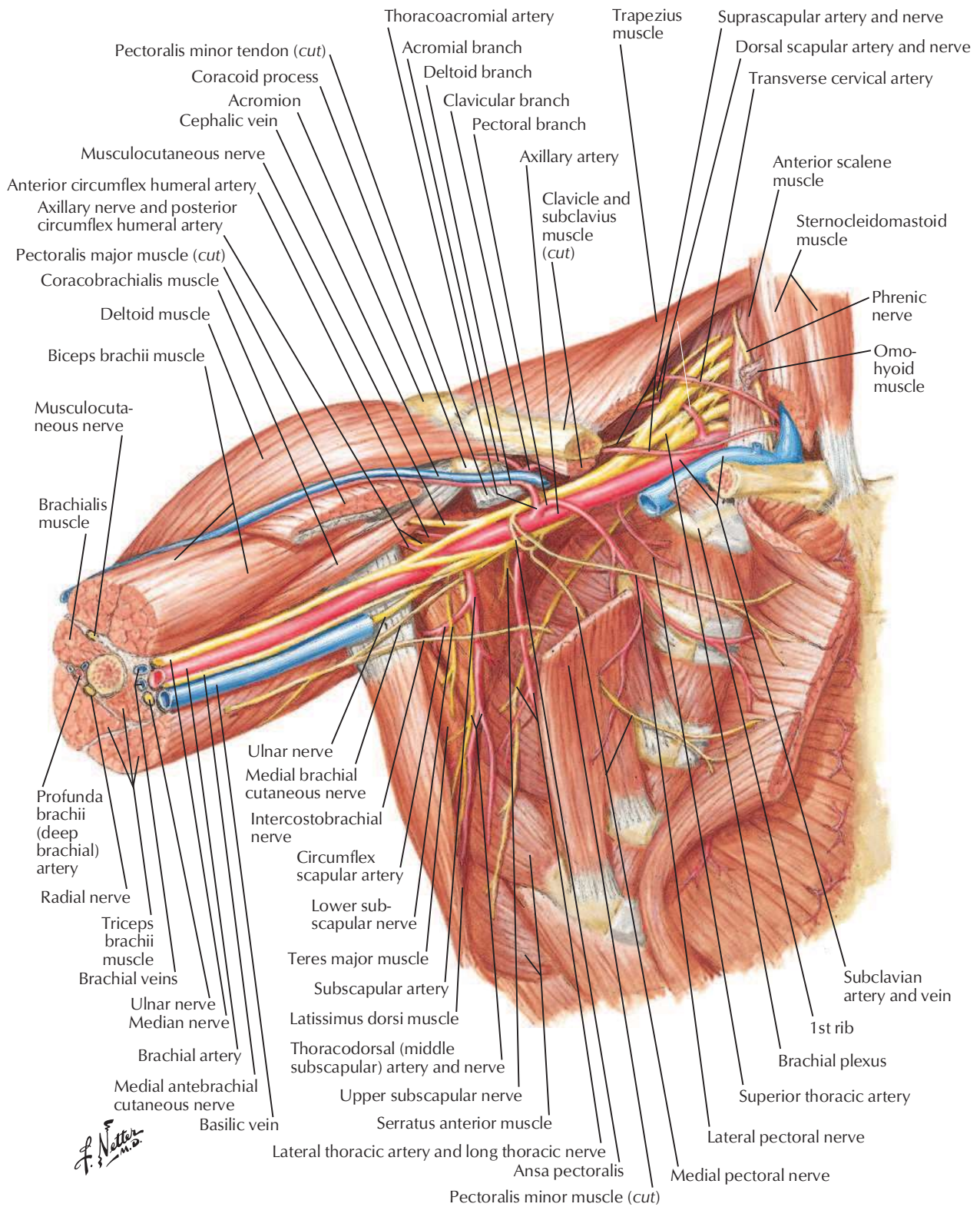
Posterior view



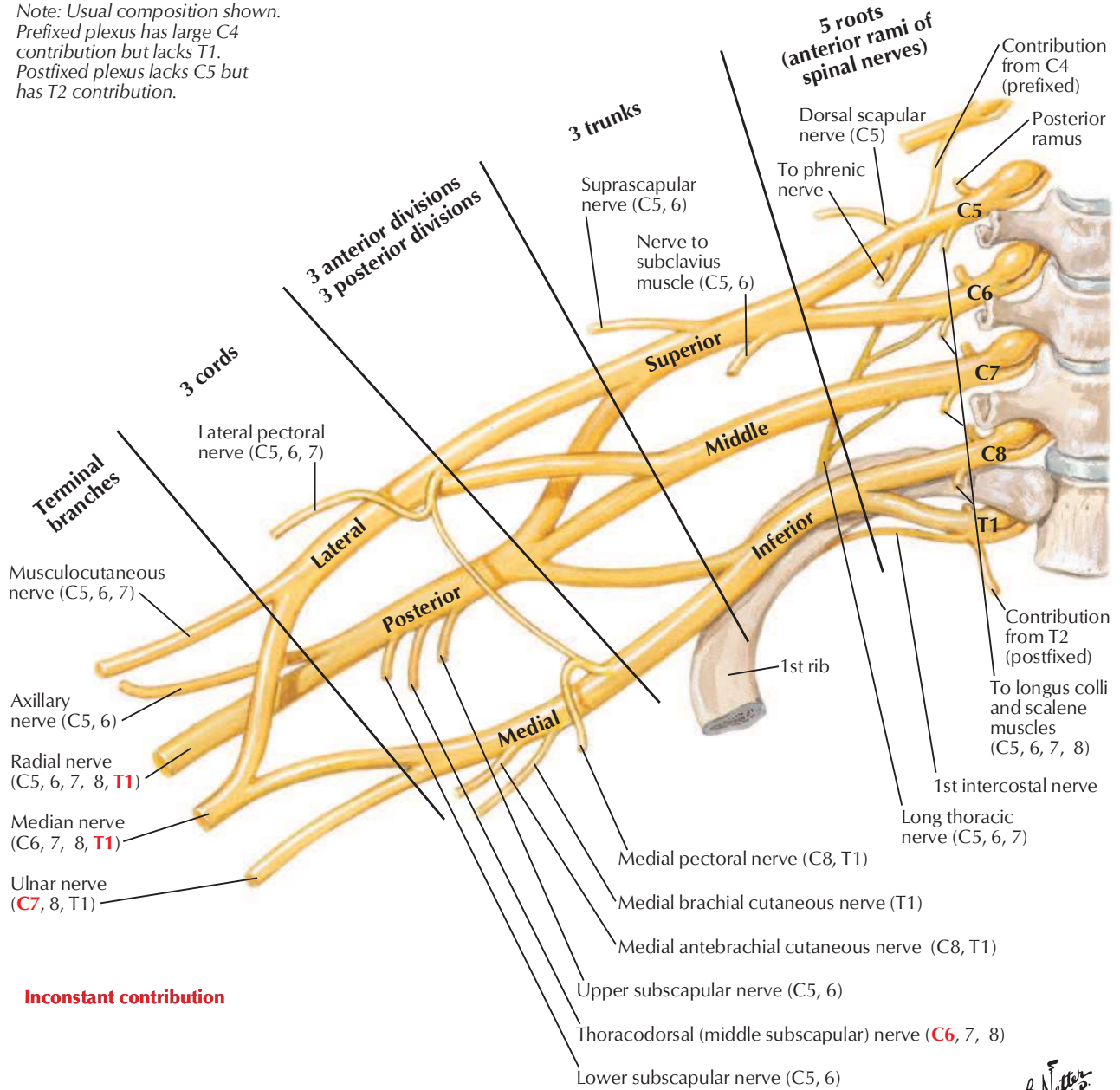


Axilla: Anterior View

See also [Plates 414, 417](#)



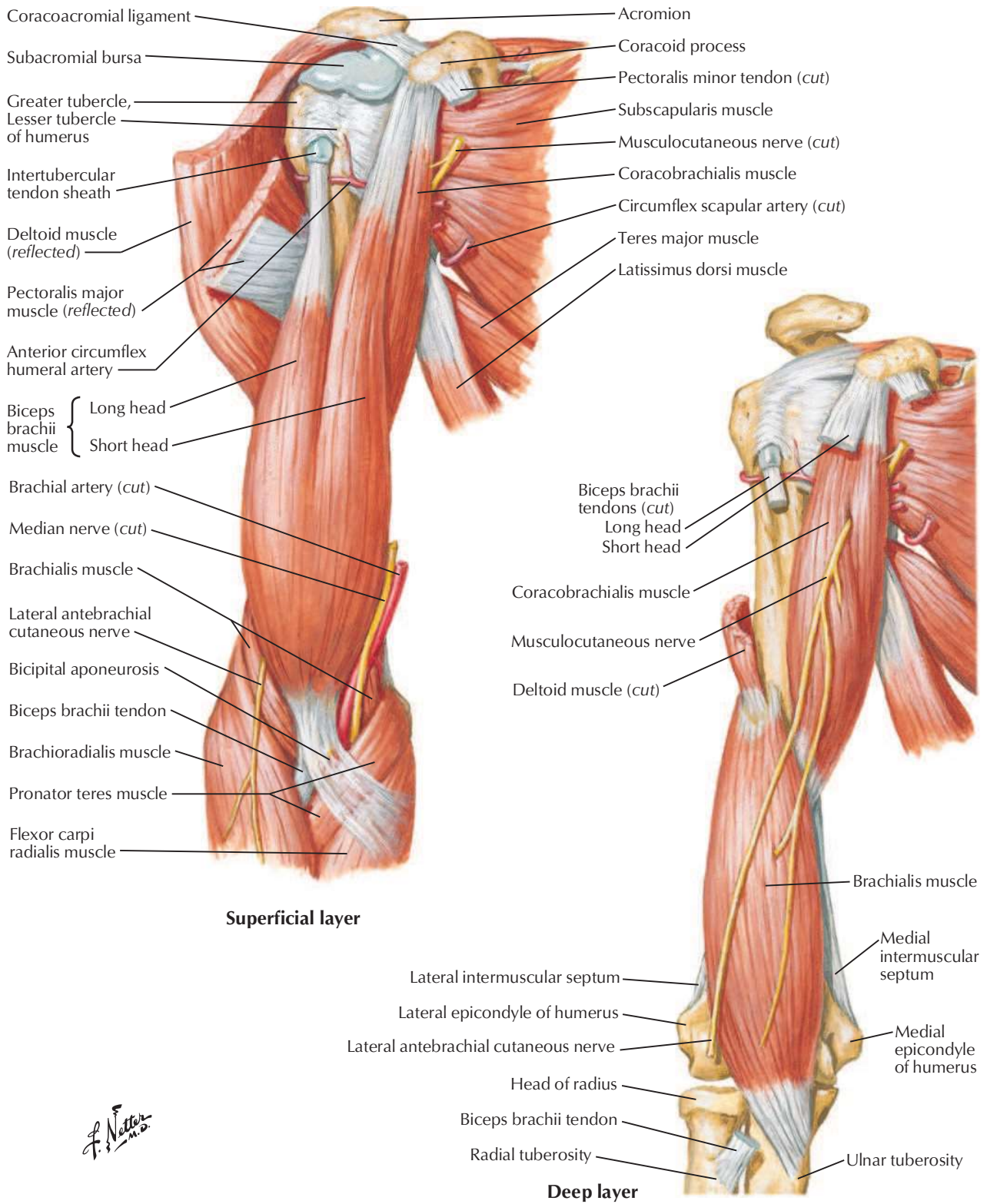
Note: Usual composition shown.
 Prefixed plexus has large C4 contribution but lacks T1.
 Postfixed plexus lacks C5 but has T2 contribution.

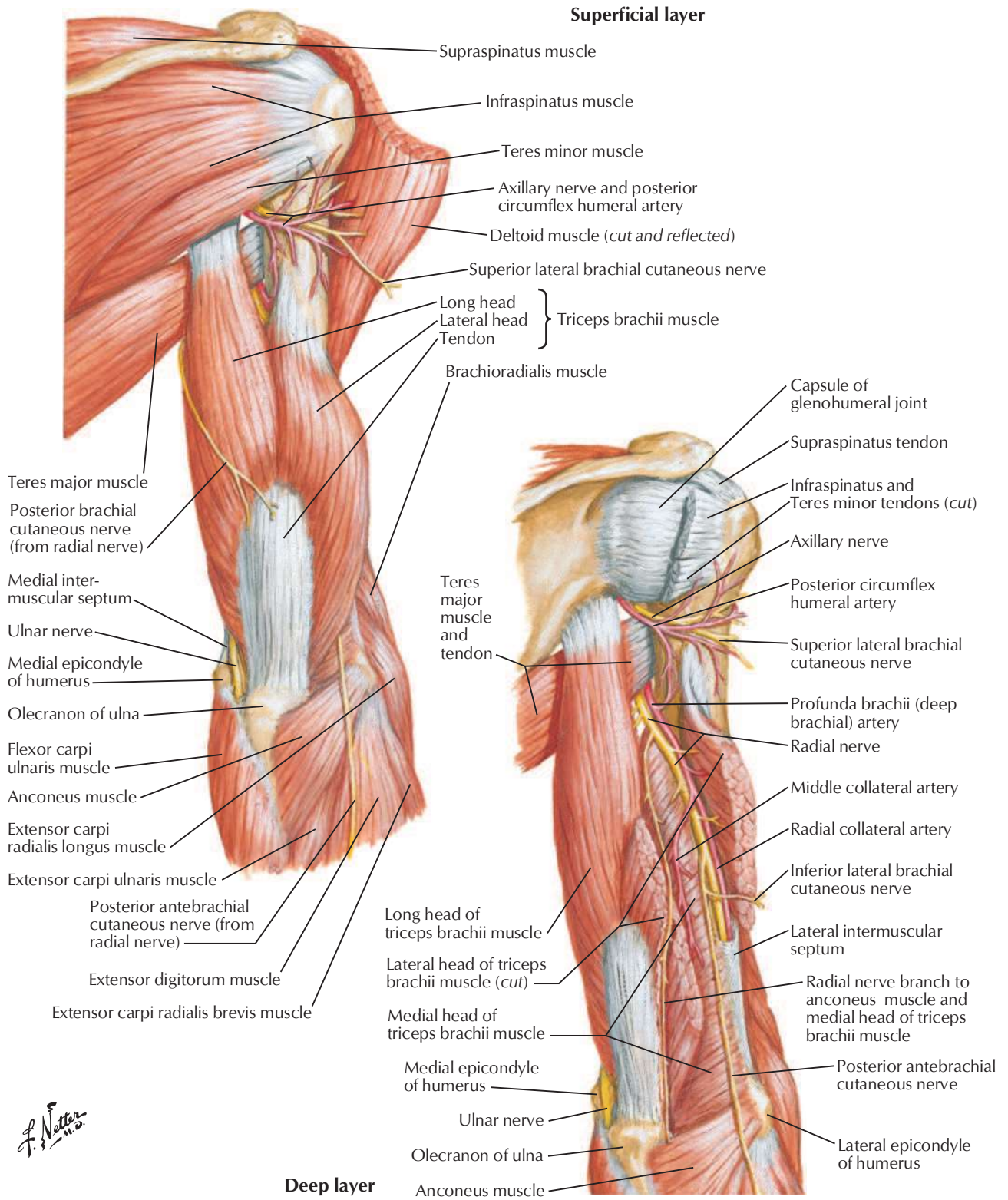


F. Netter M.D.

Muscles of Arm: Anterior Views

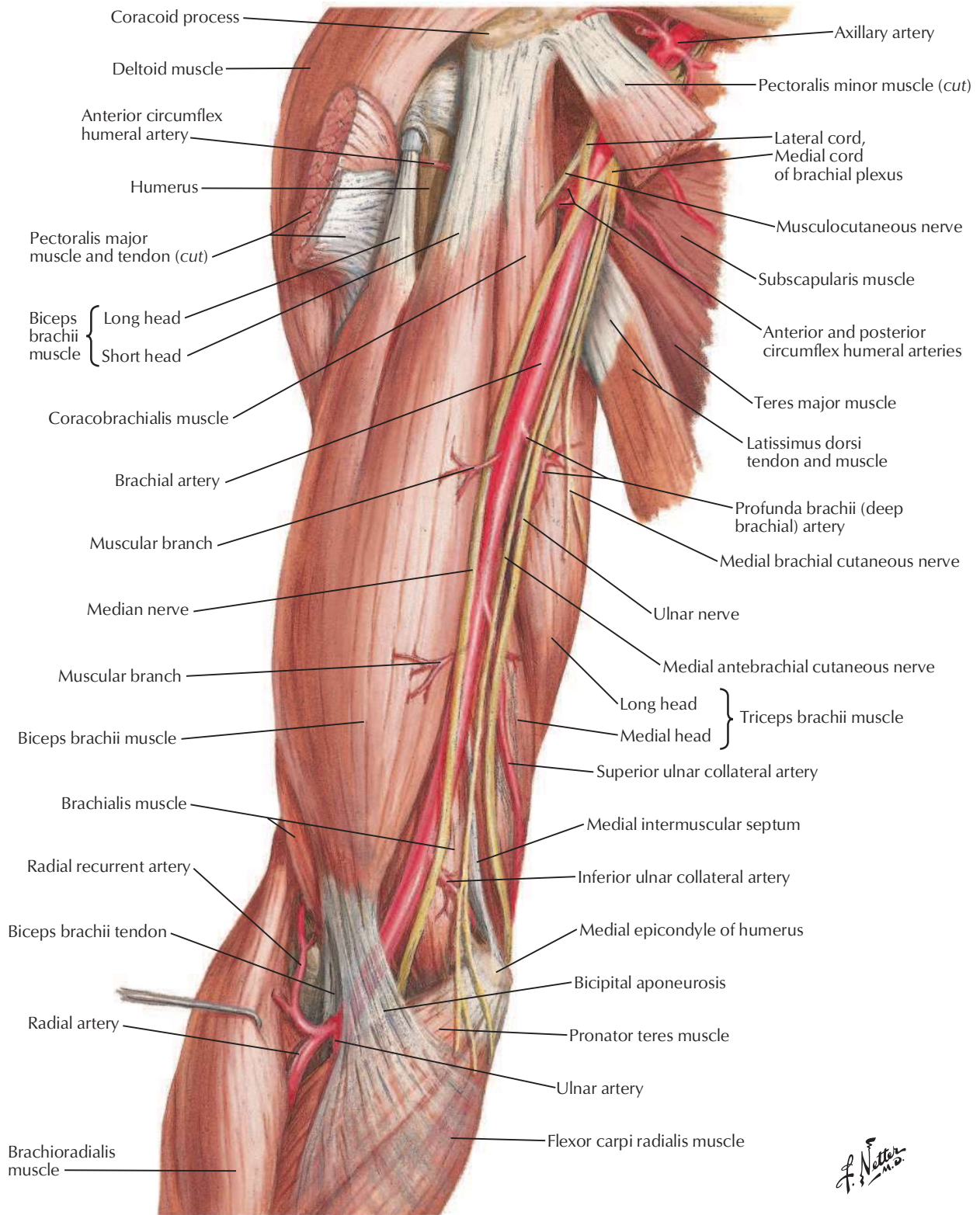
See also **Plates 415, 465**

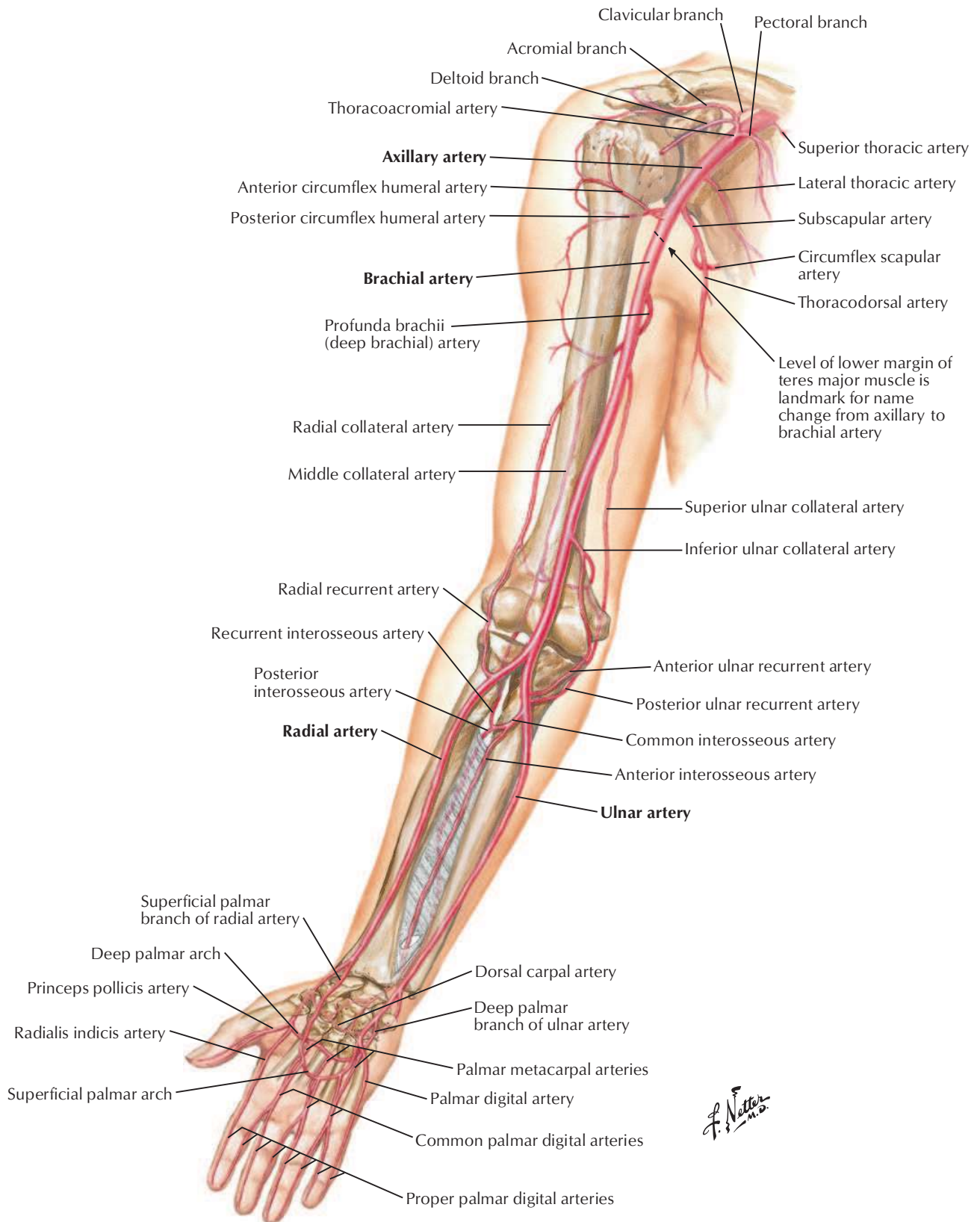


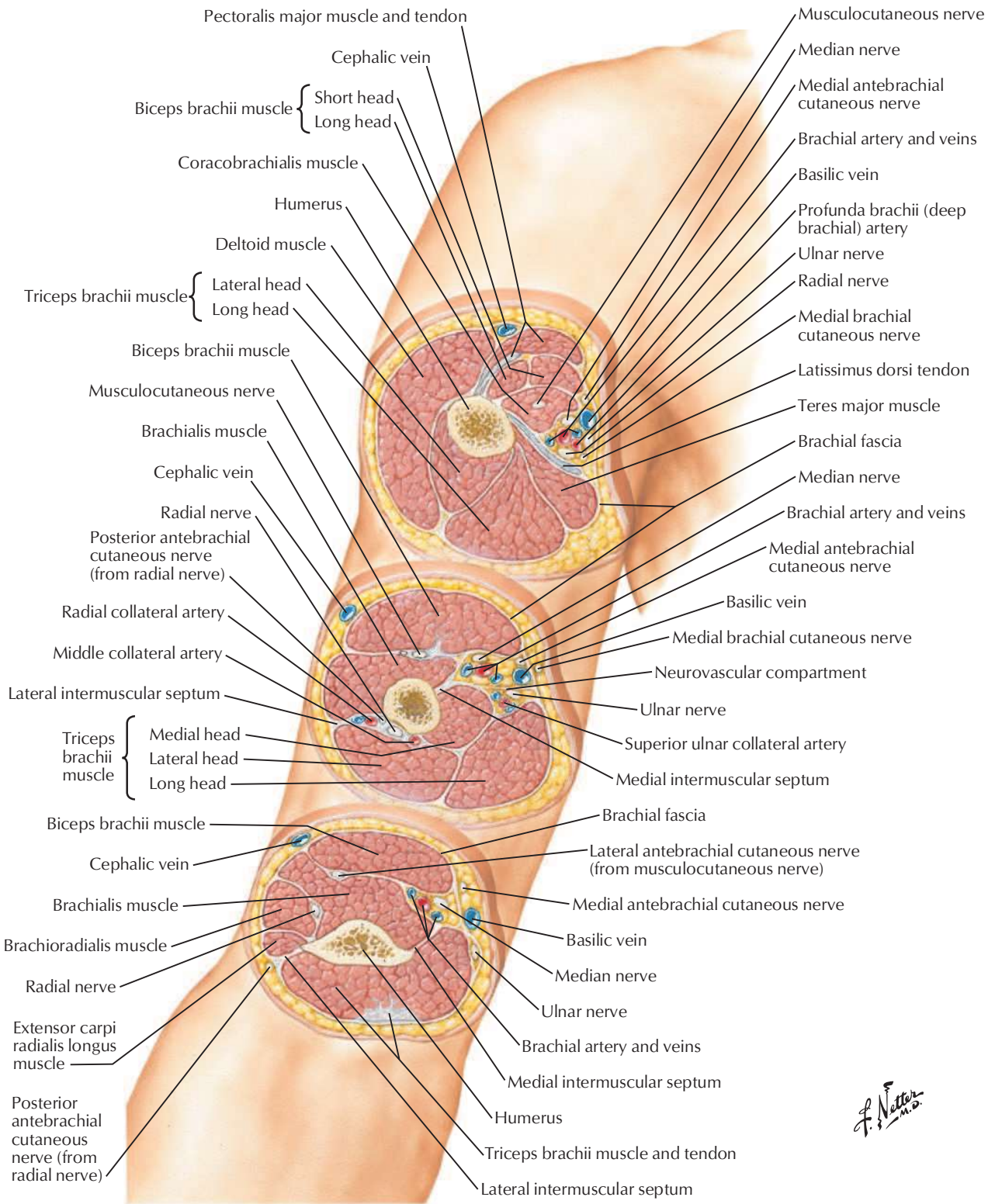


F. Netter M.D.

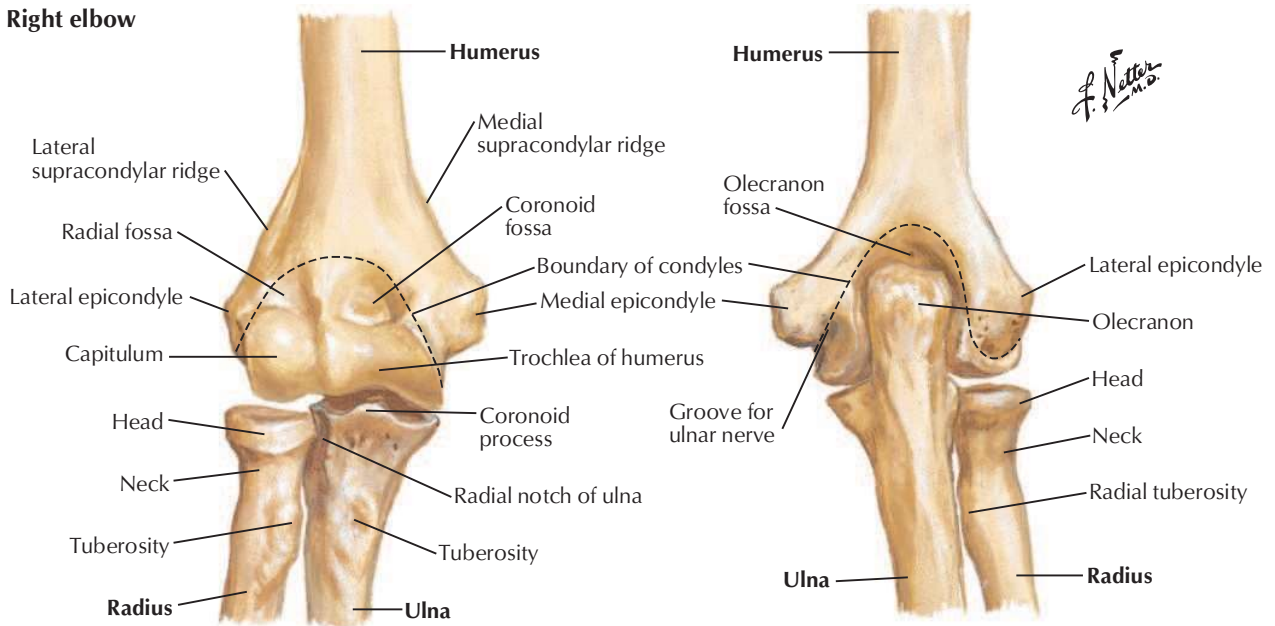
Brachial Artery in Situ





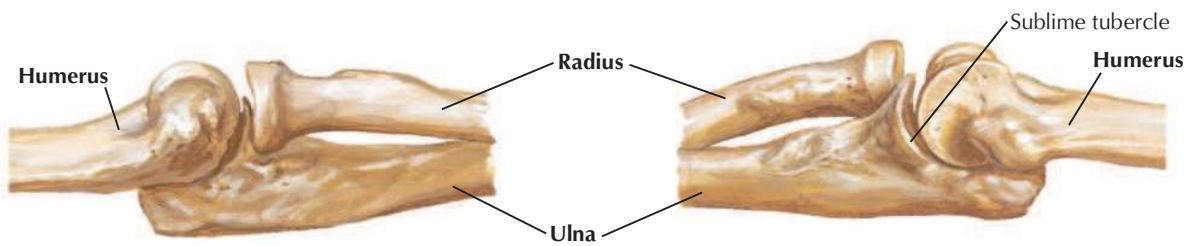


Right elbow



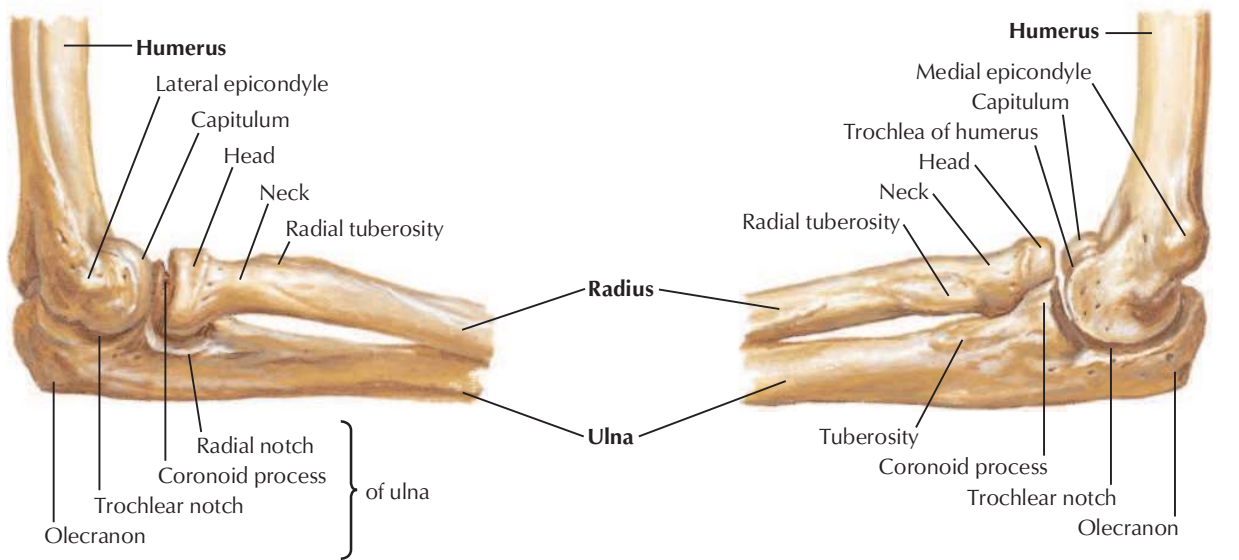
In extension: anterior view

In extension: posterior view



In extension: lateral view

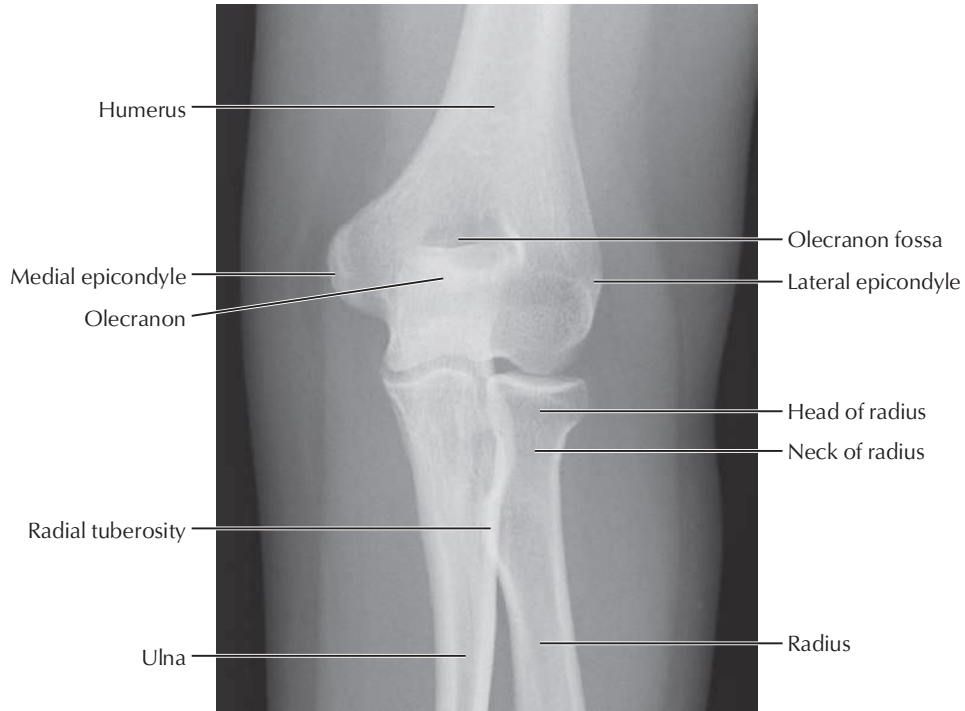
In extension: medial view



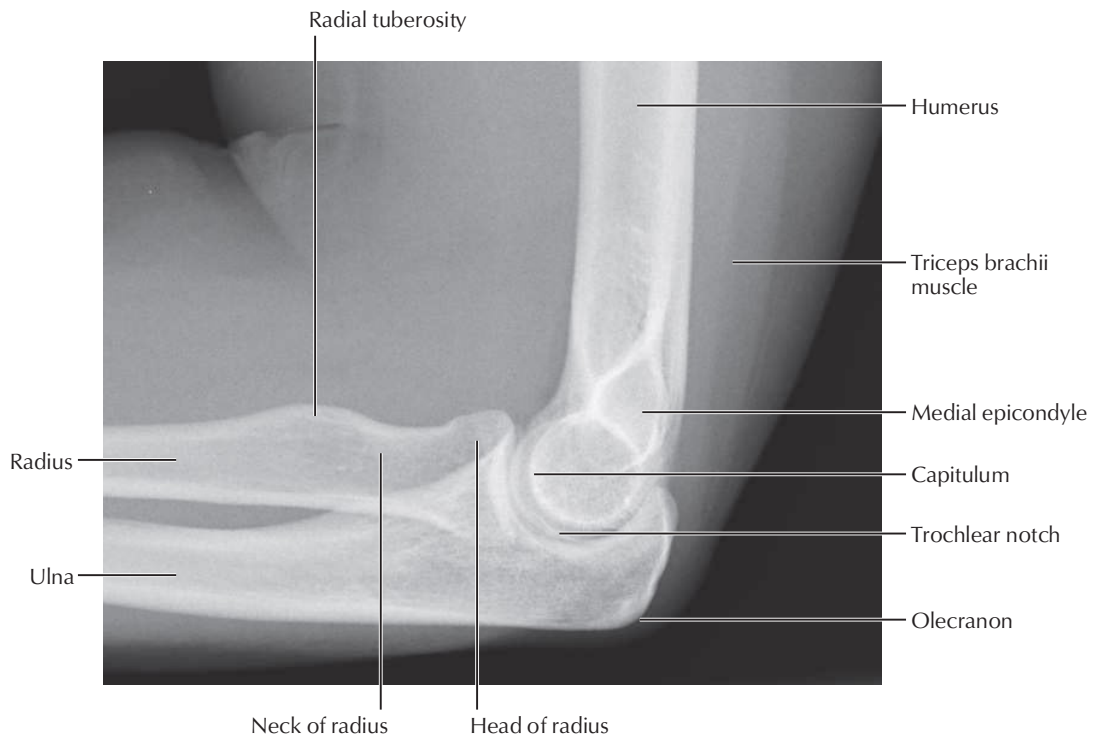
In 90 degrees of flexion: lateral view

In 90 degrees of flexion: medial view

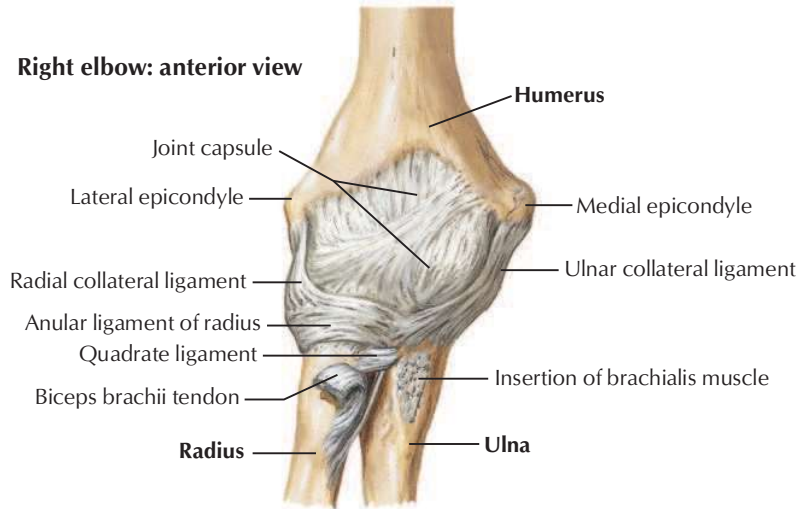
Anteroposterior view



Lateral view

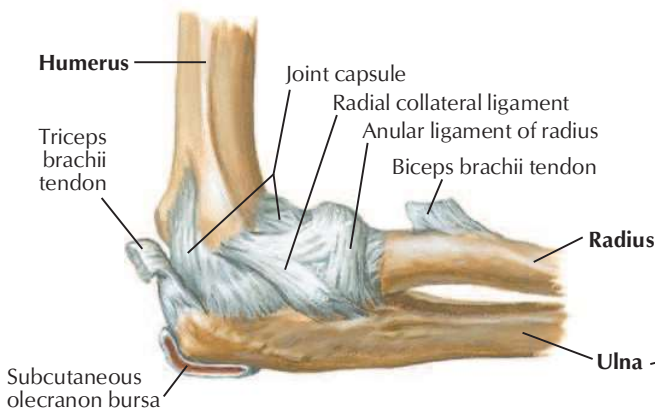


Right elbow: anterior view

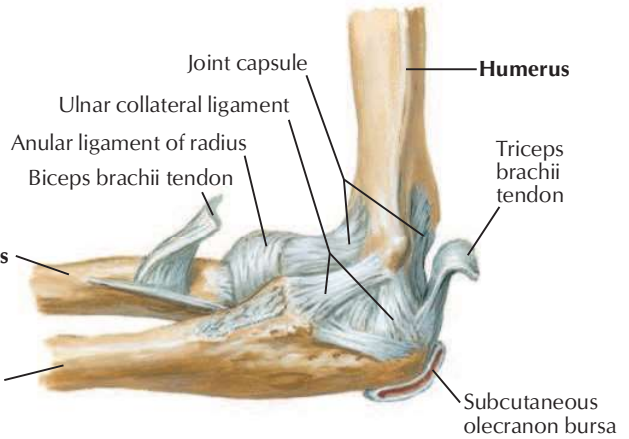


F. Netter M.D.

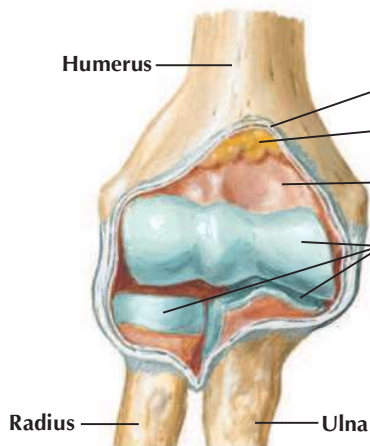
In 90 degrees of flexion: lateral view



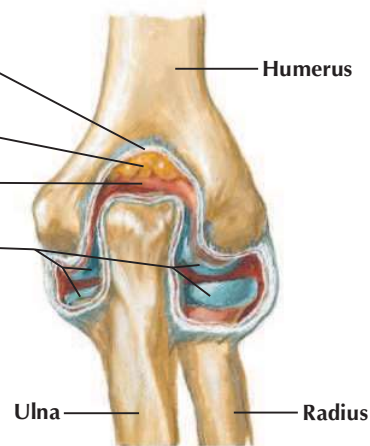
In 90 degrees of flexion: medial view



Opened joint: anterior view

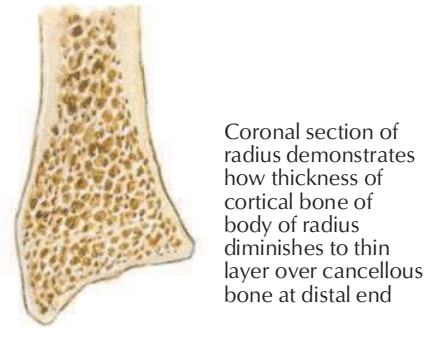
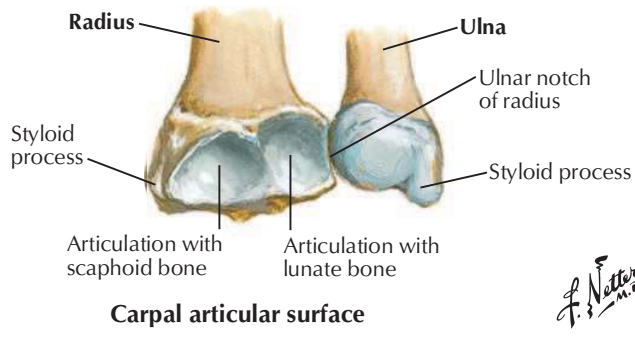
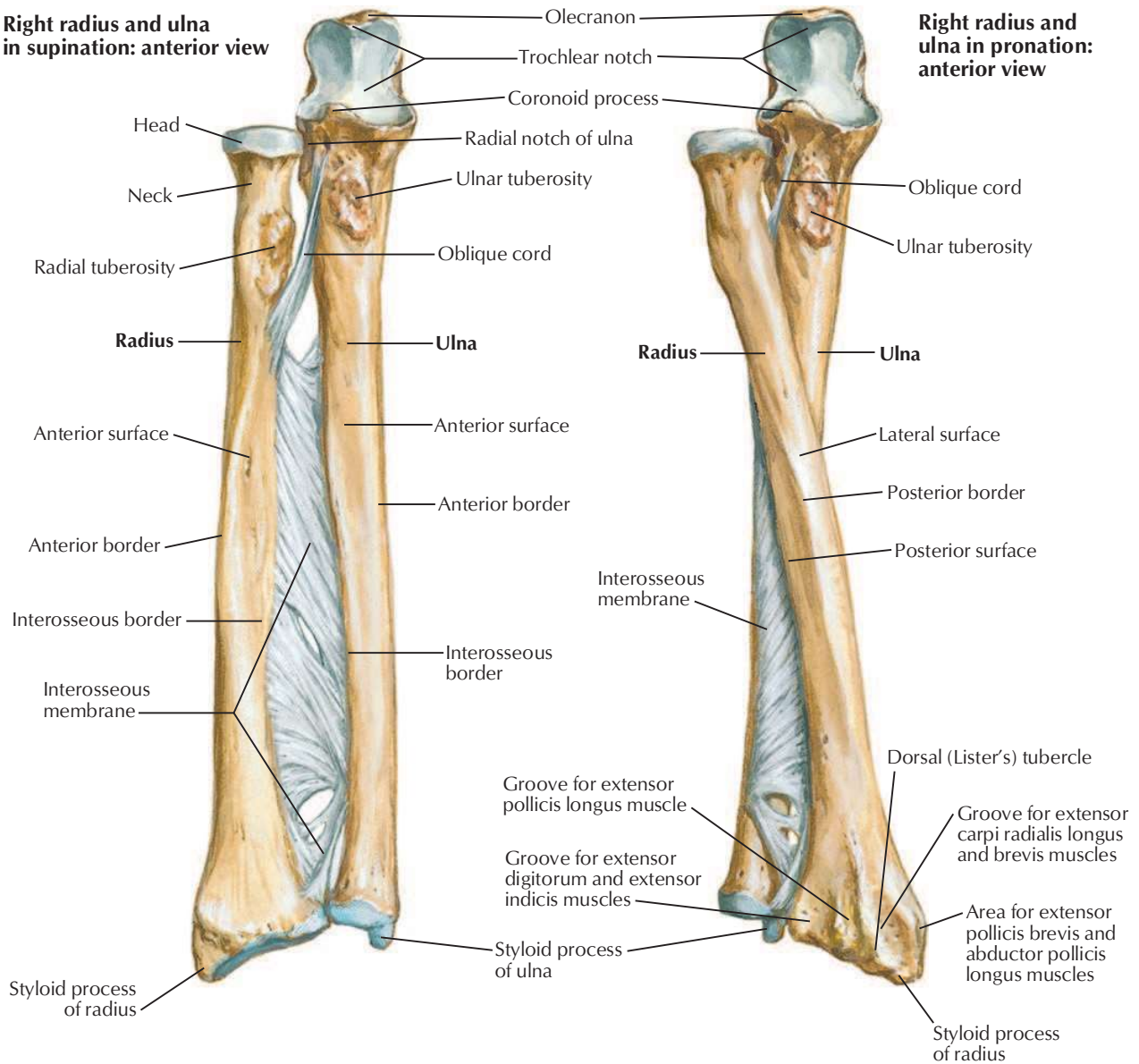


Opened joint: posterior view

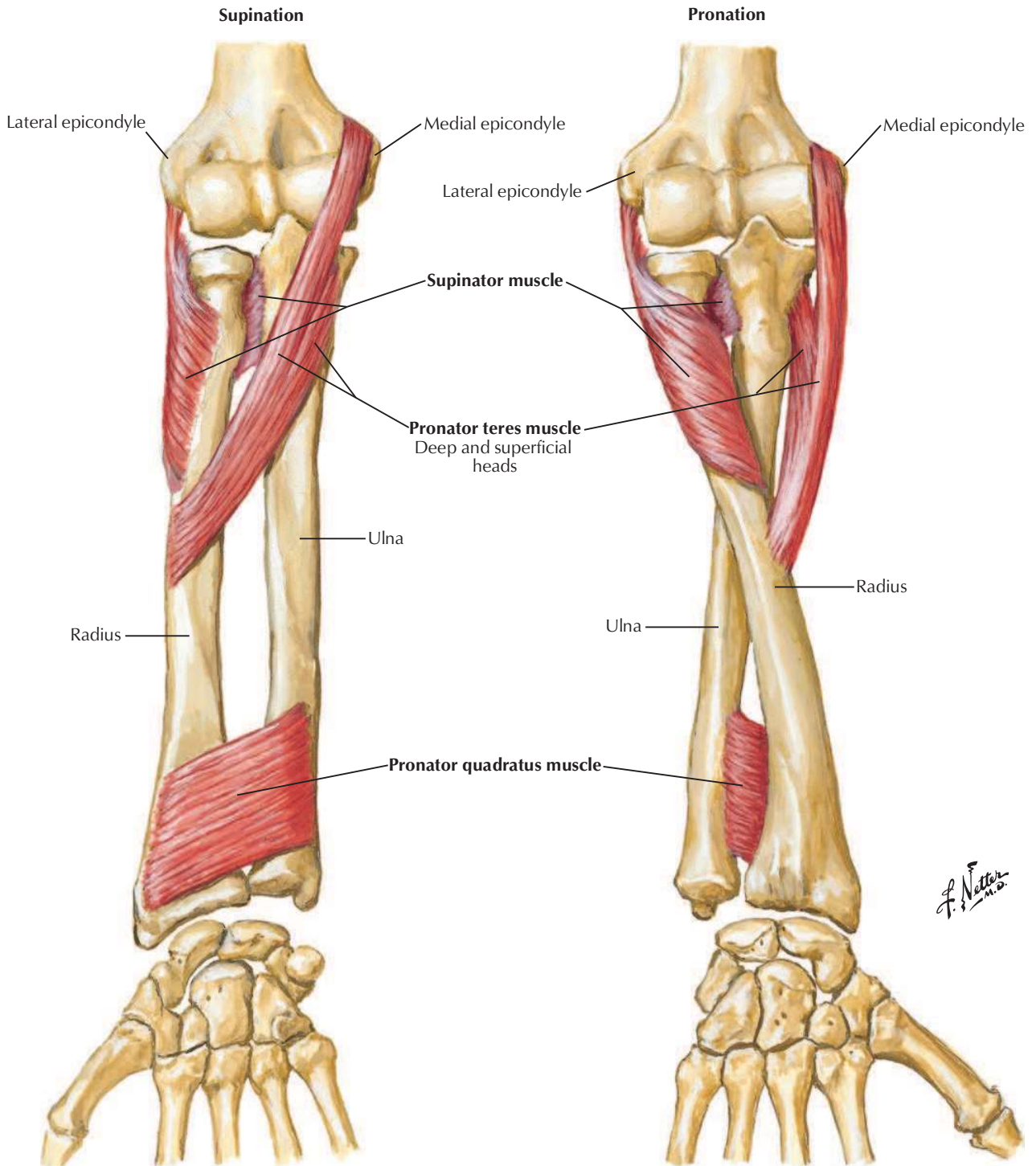


Right radius and ulna in supination: anterior view

Right radius and ulna in pronation: anterior view

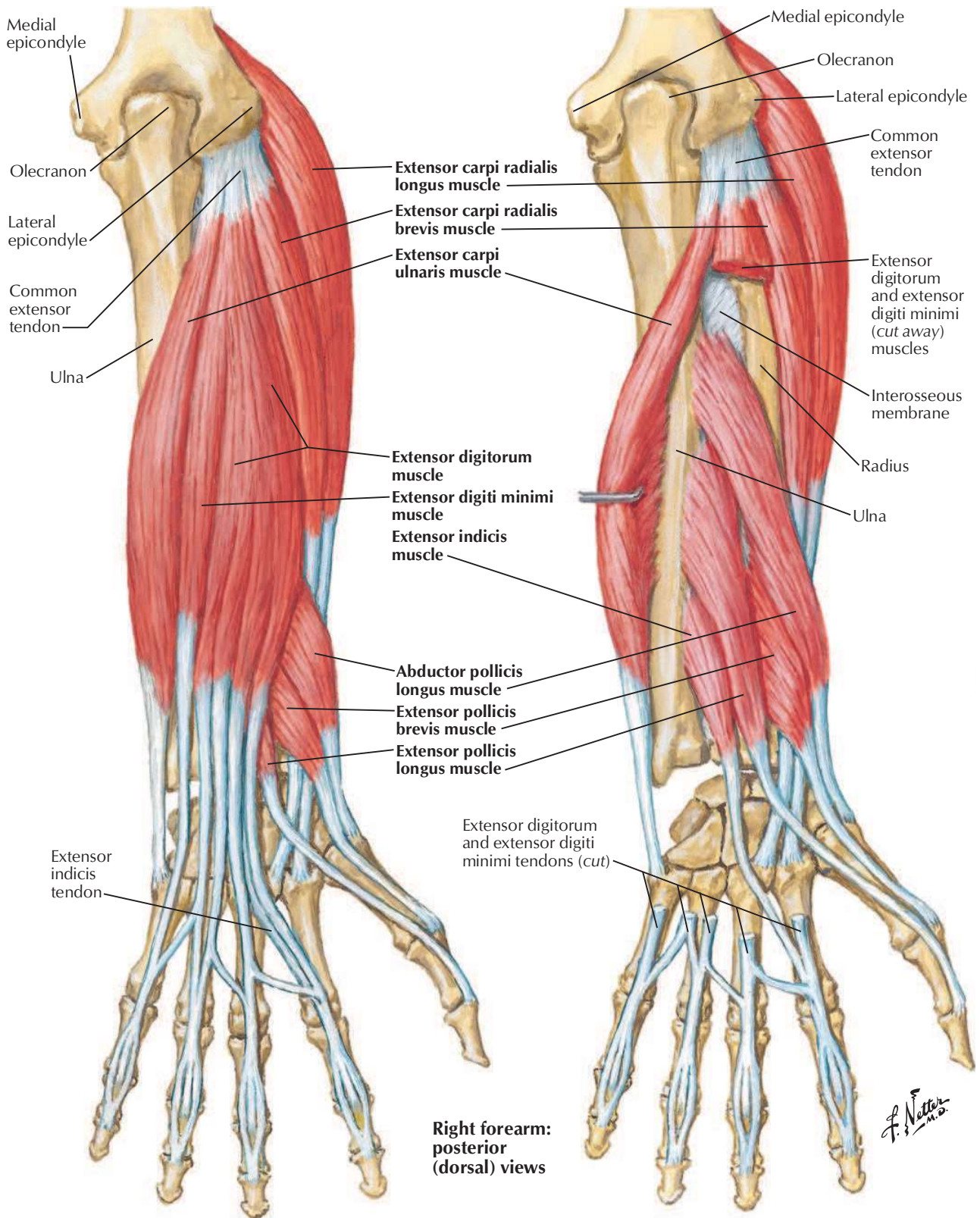


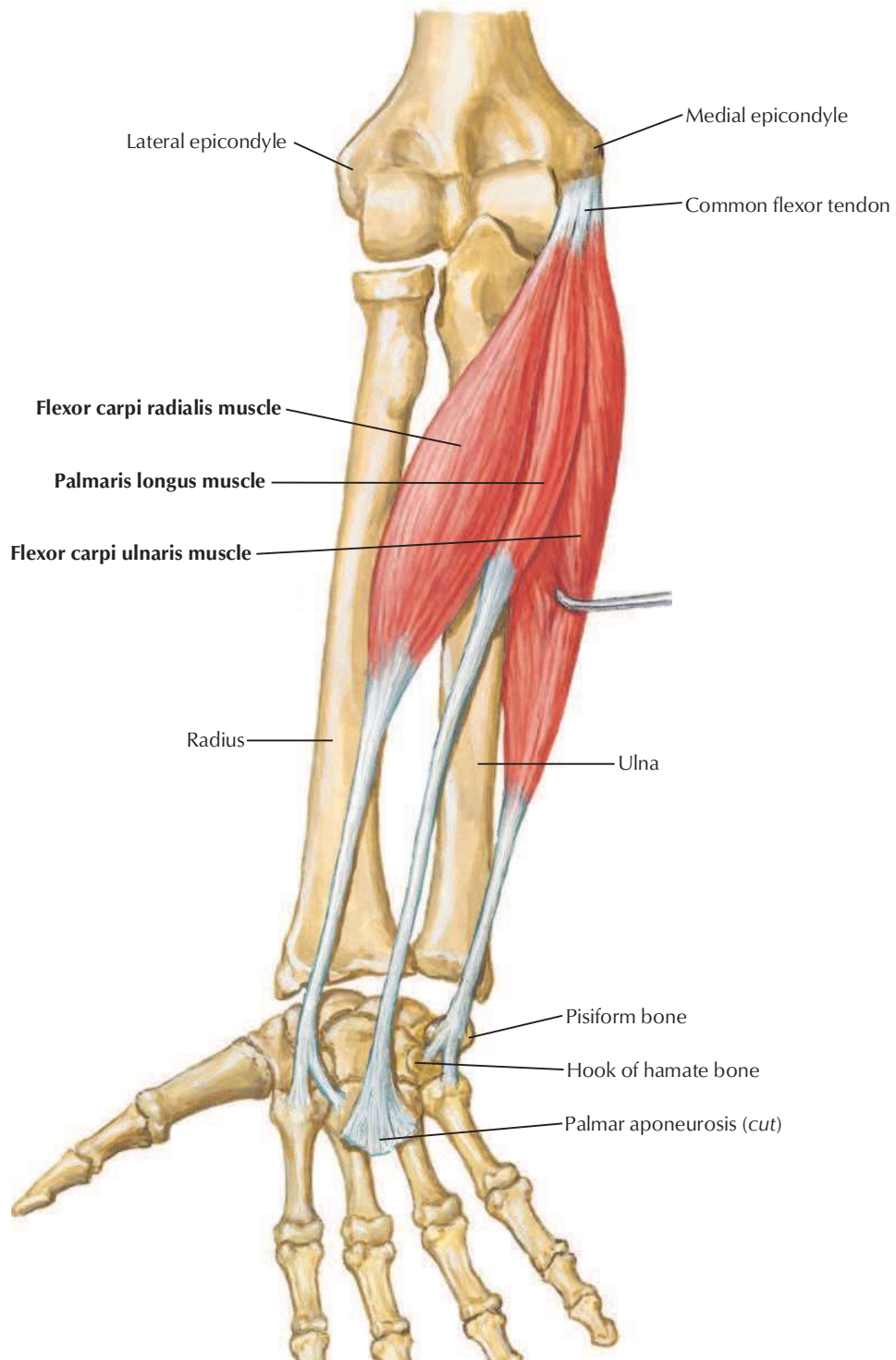
Right forearm: anterior view



Individual Muscles of Forearm: Extensors of Wrist and Digits

See also [Plate 441](#)

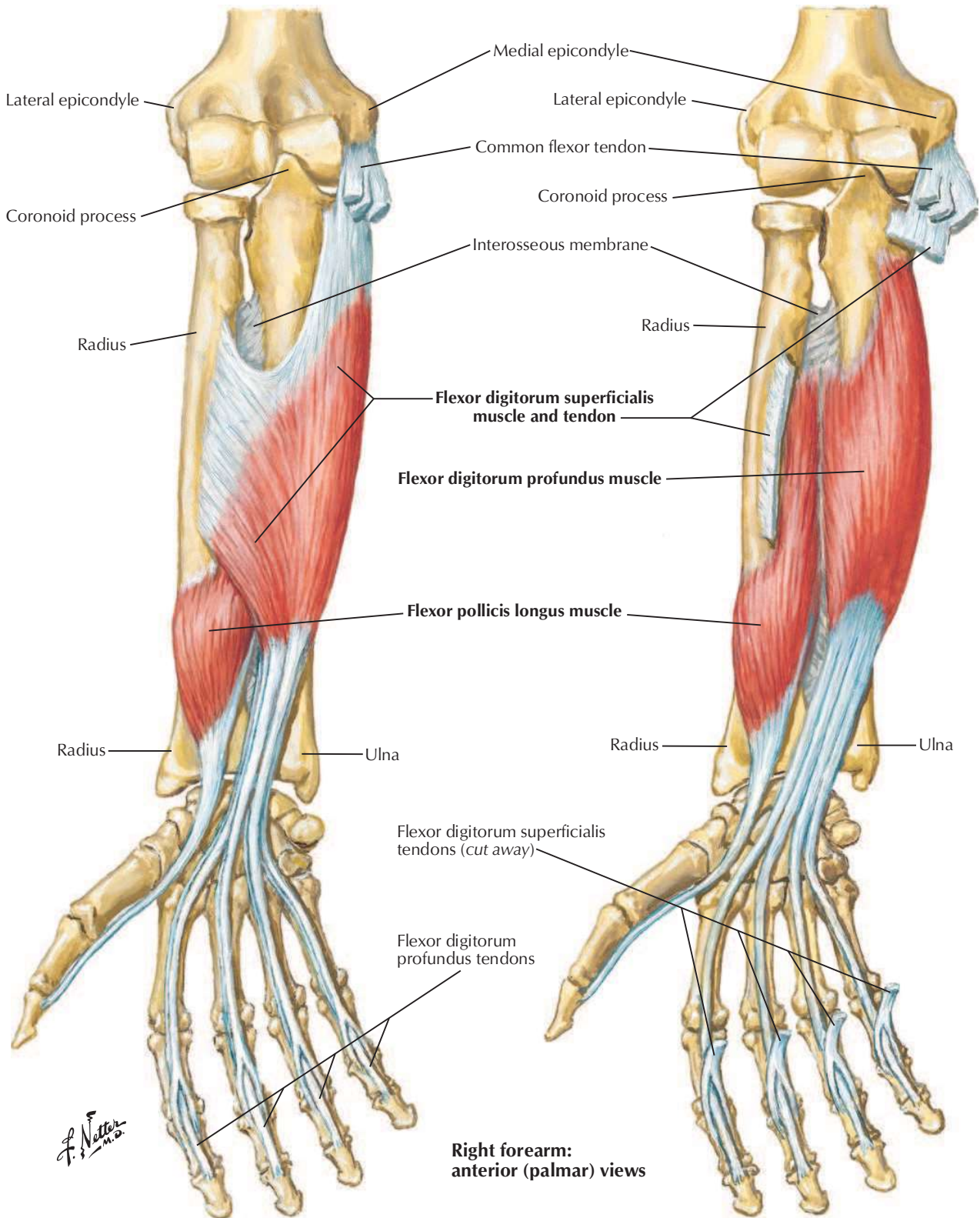


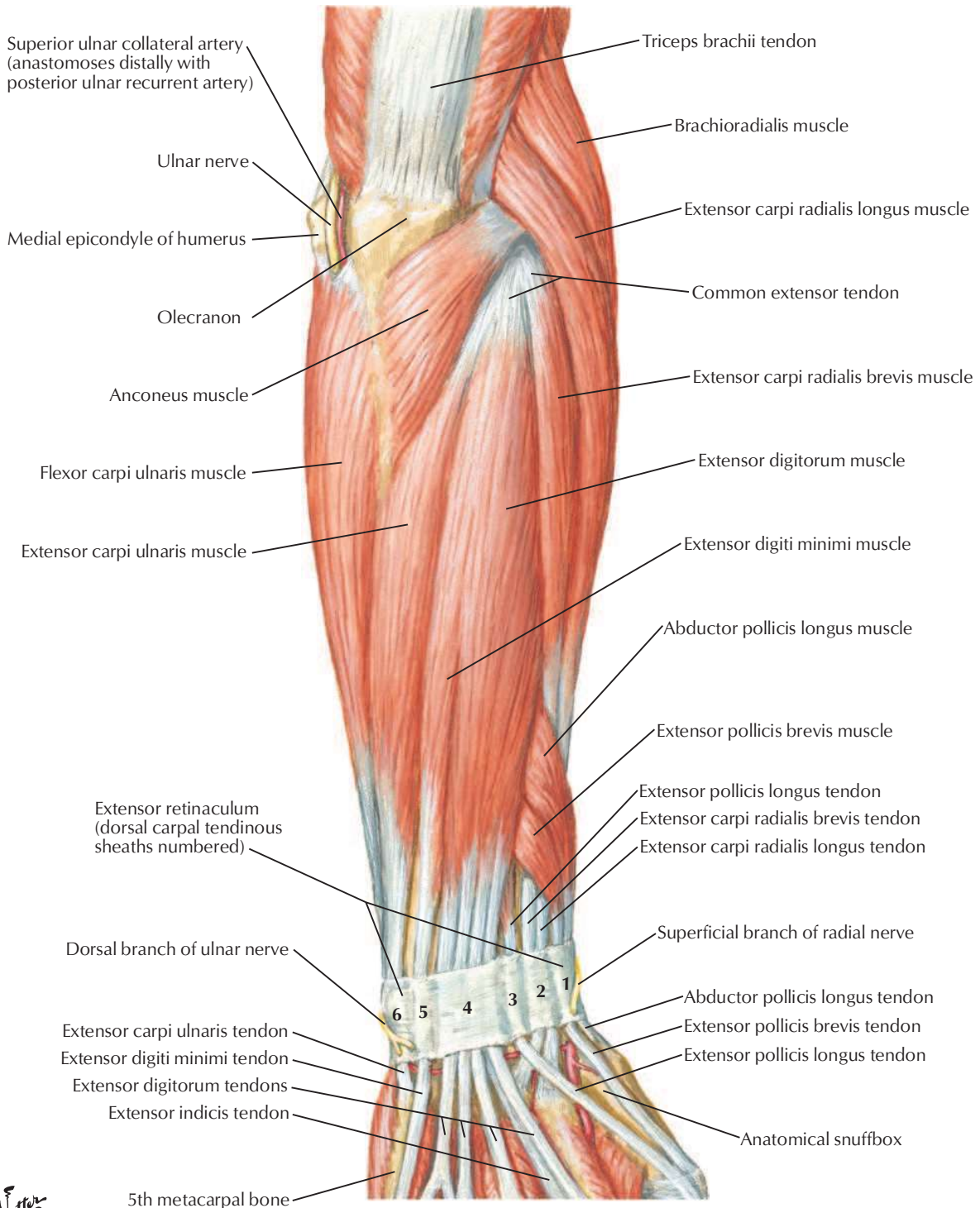


Right forearm:
anterior (palmar) view

F. Netter M.D.

Individual Muscles of Forearm: Flexors of Digits

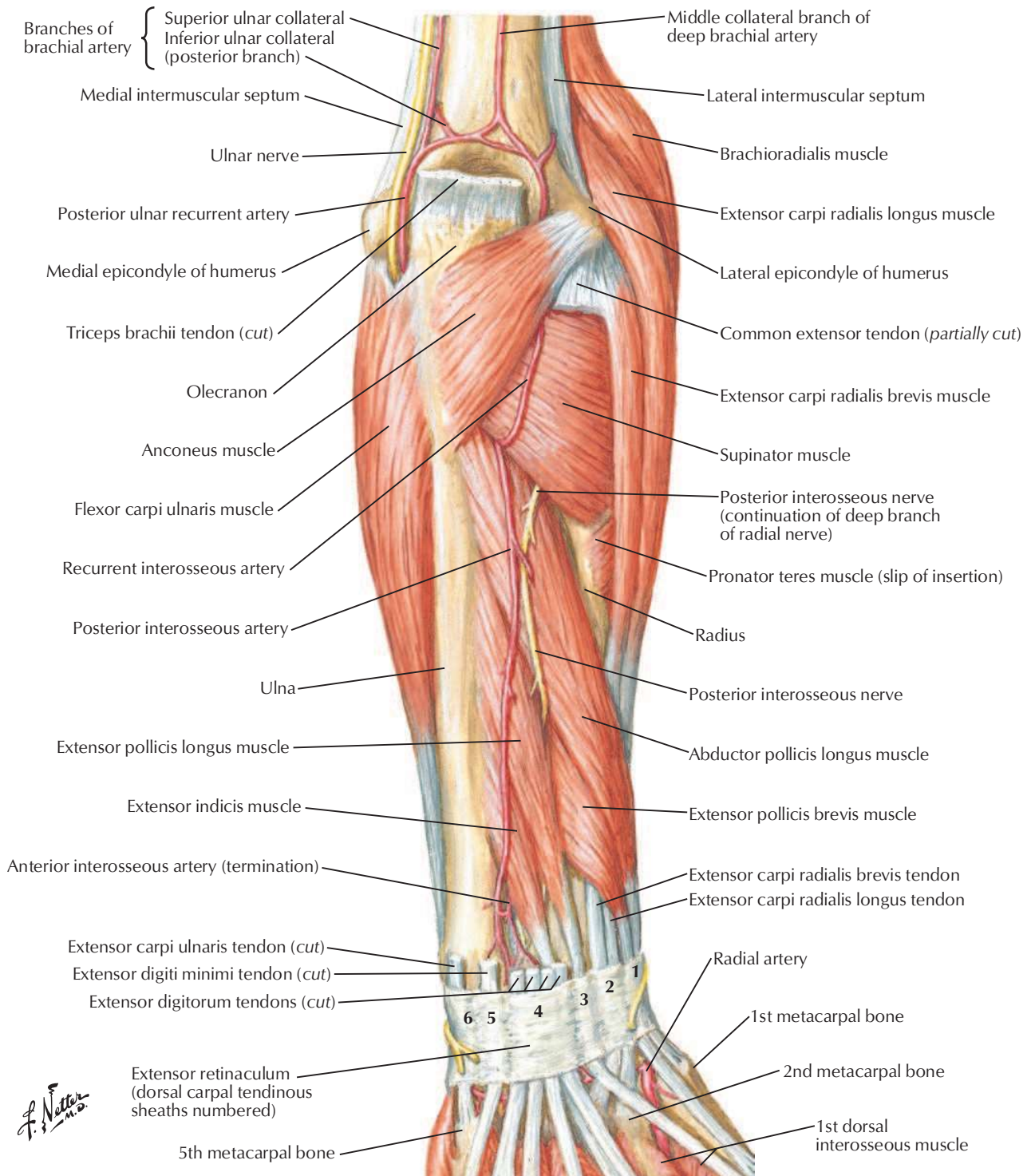


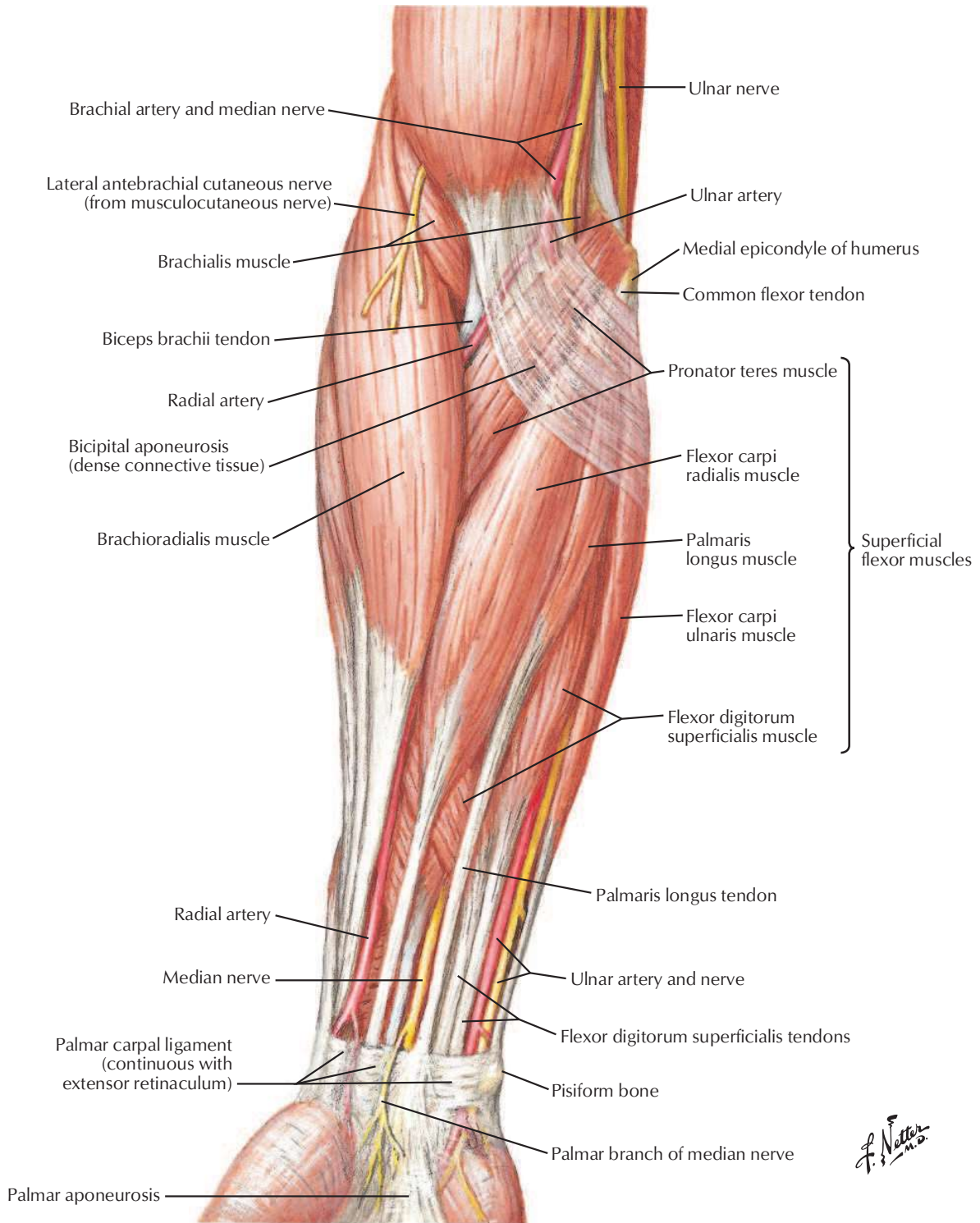


F. Netter M.D.

Muscles of Forearm (Deeper Layer): Posterior View

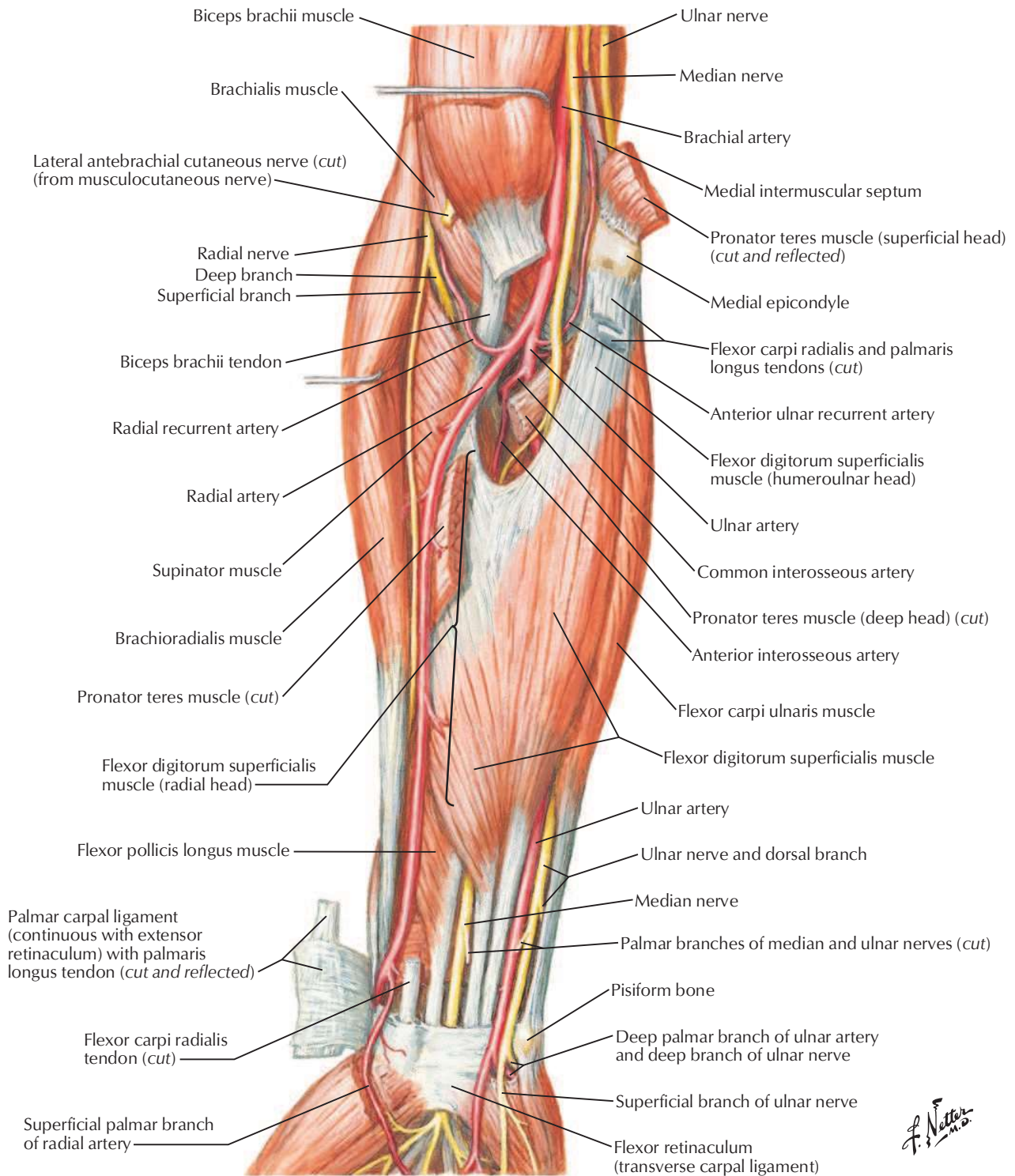
See also [Plate 460](#)

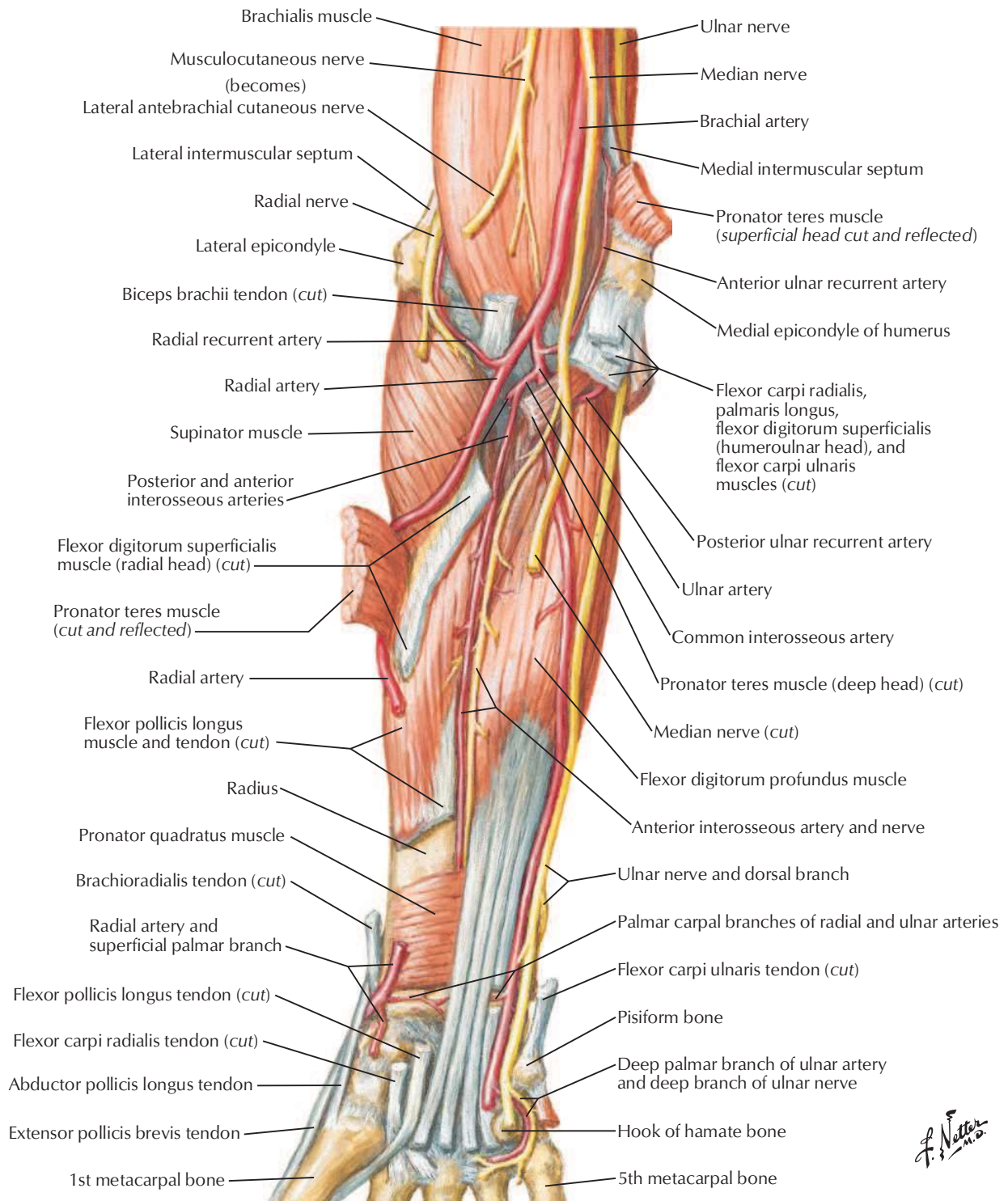




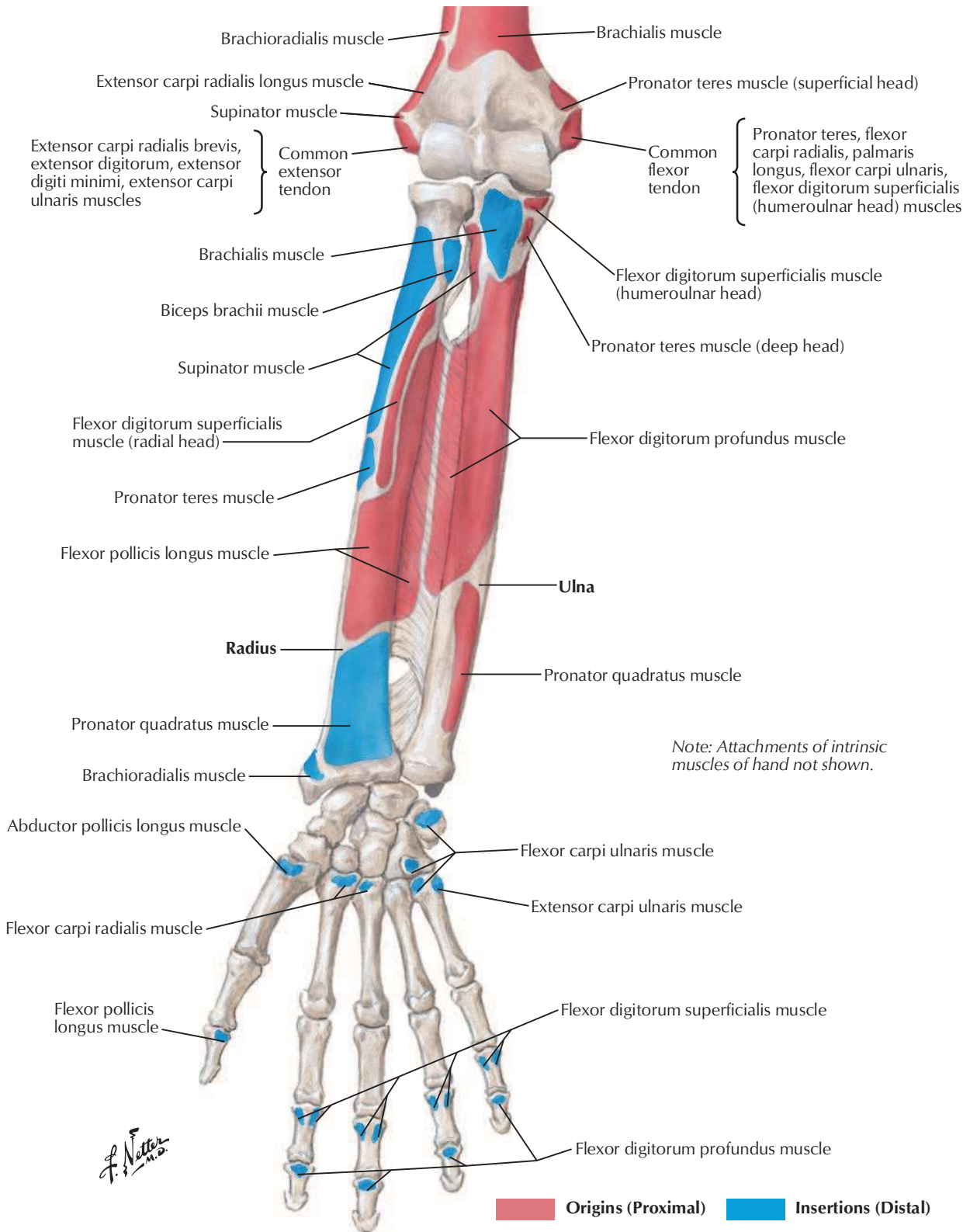
Muscles of Forearm (Intermediate Layer): Anterior View

See also [Plates 424, 466](#)

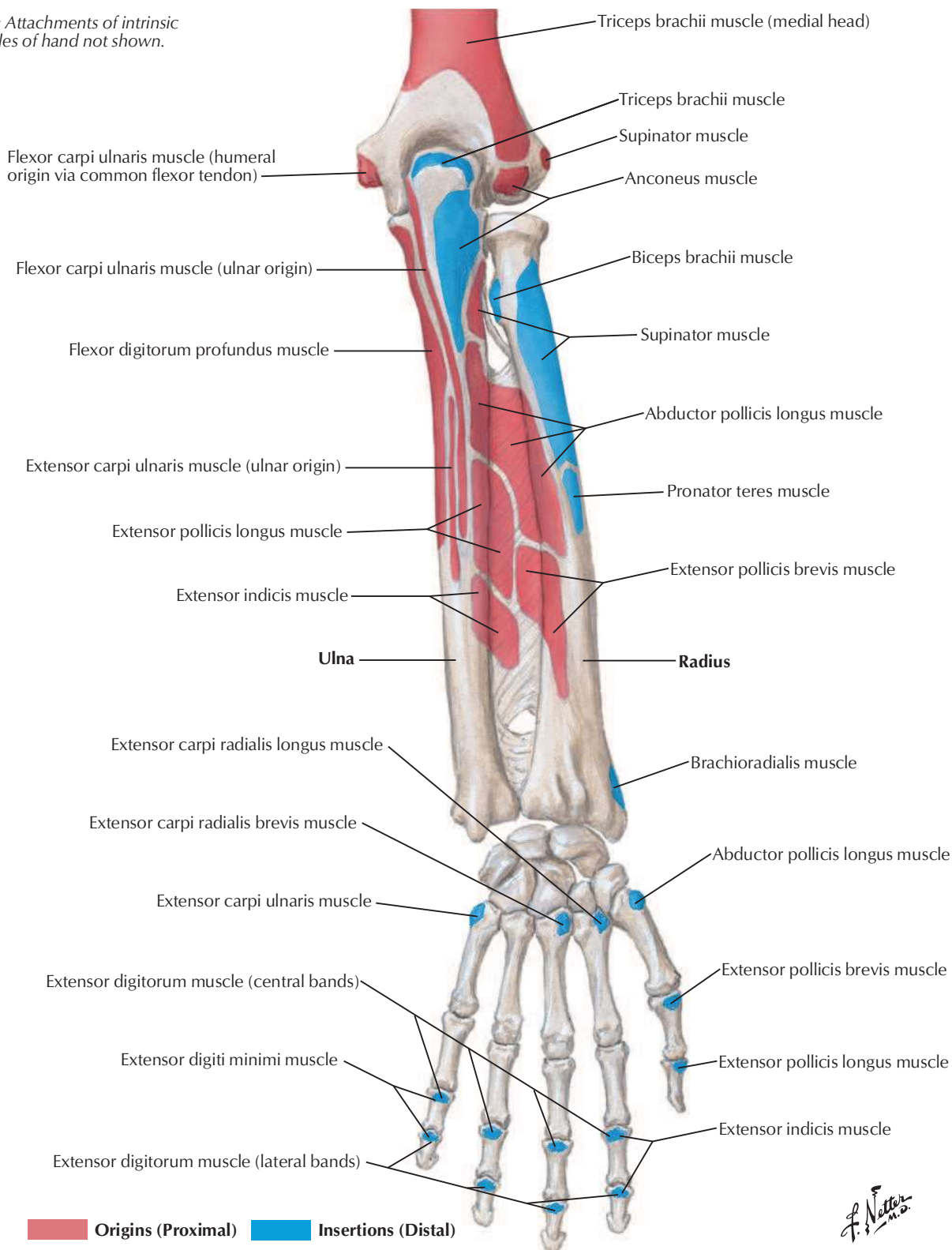




Attachments of Muscles of Forearm: Anterior View

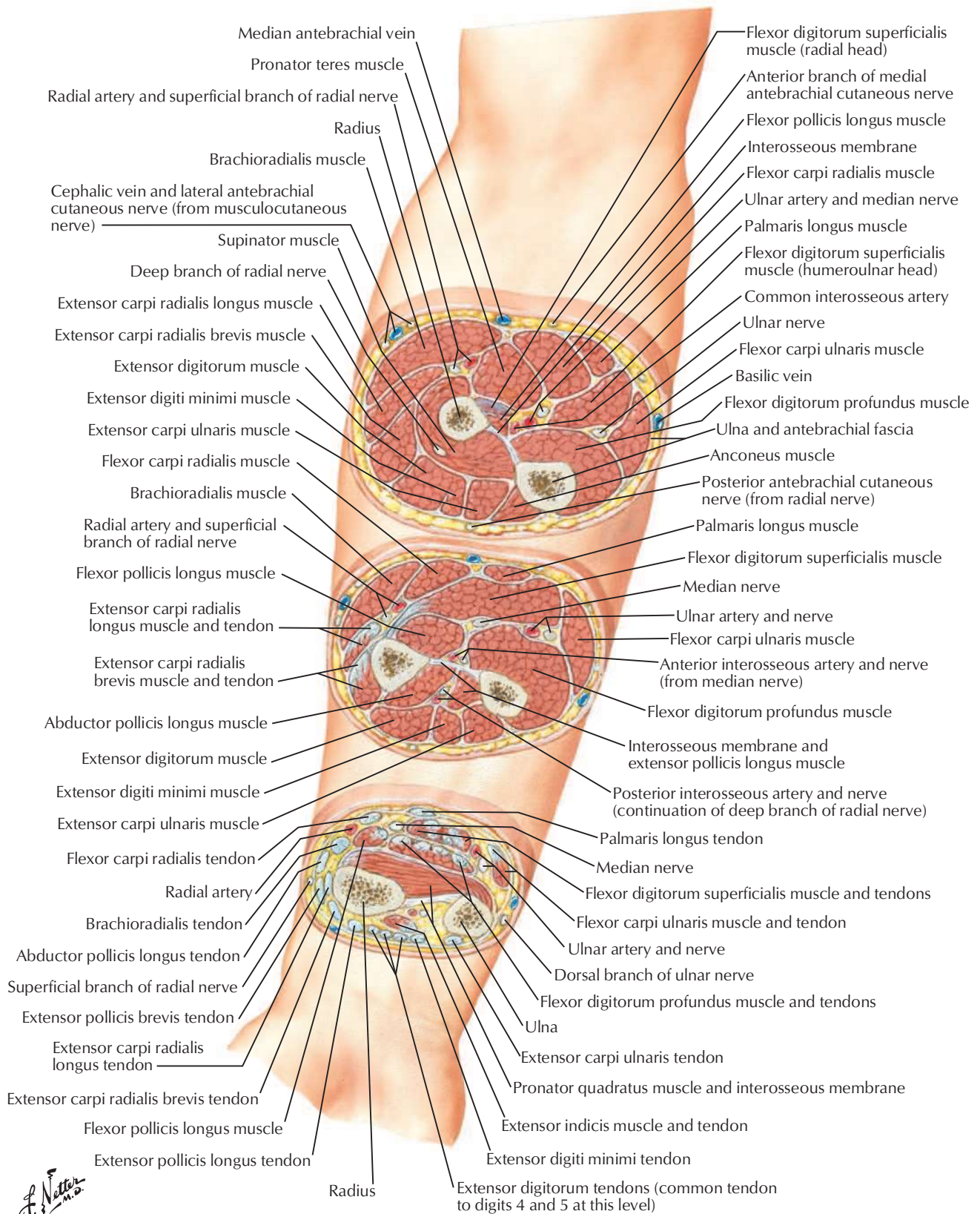


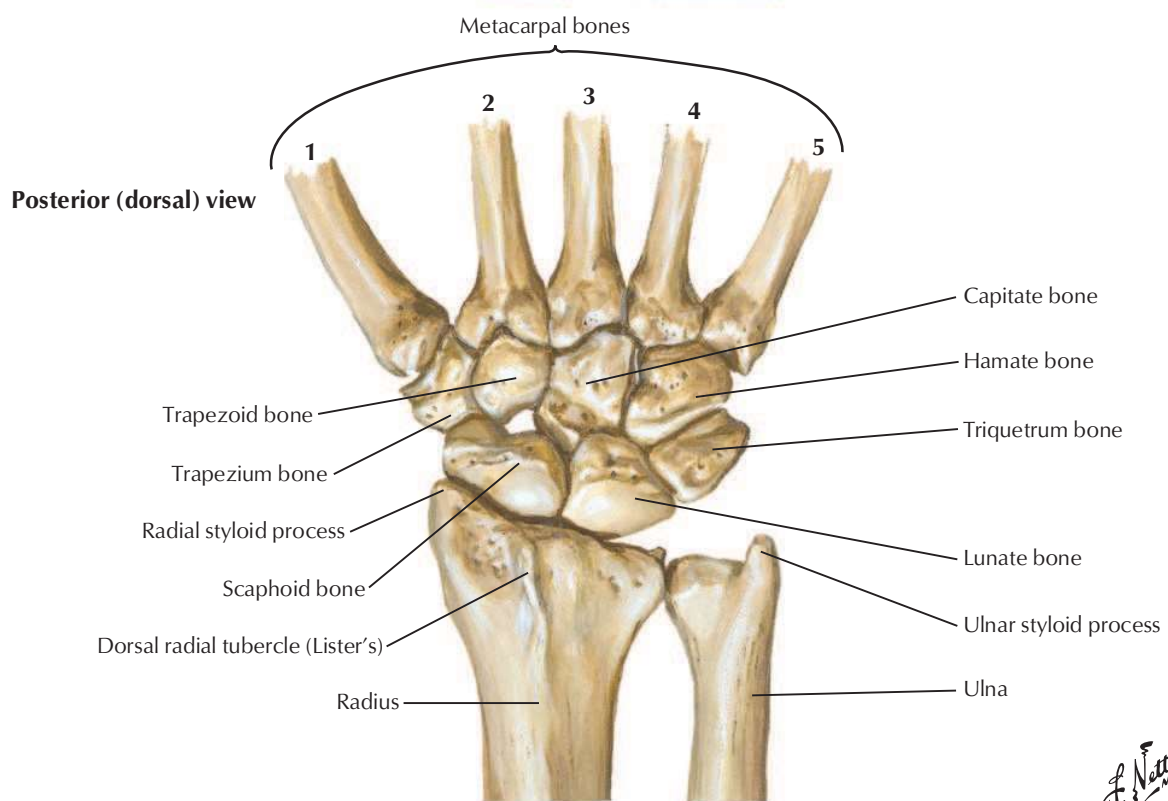
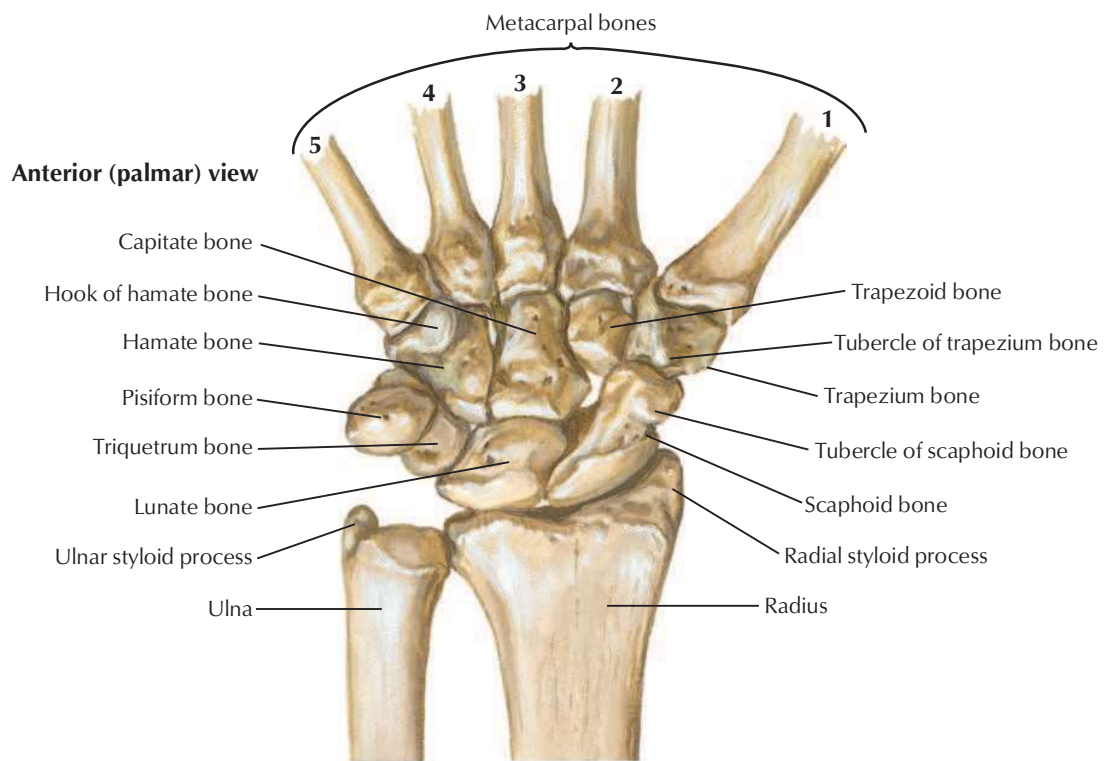
Note: Attachments of intrinsic muscles of hand not shown.



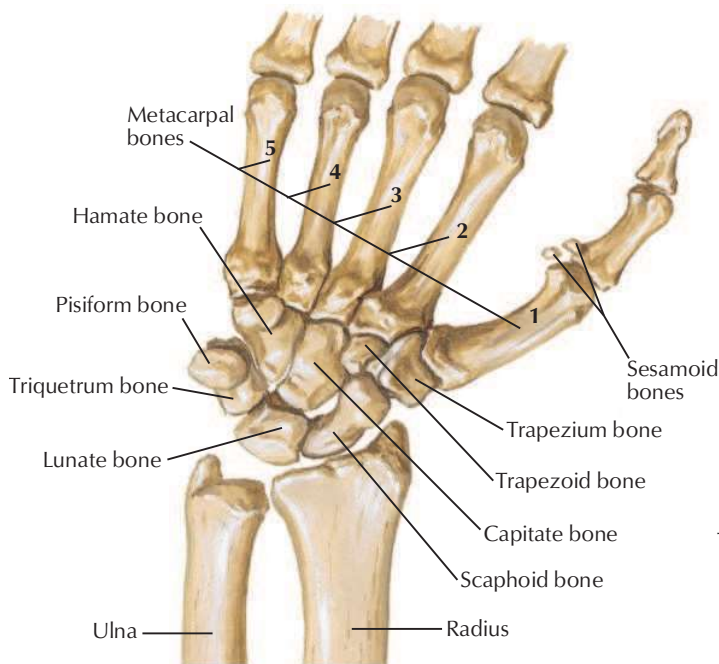
F. Netter M.D.

Forearm: Serial Cross Sections, Anterior View

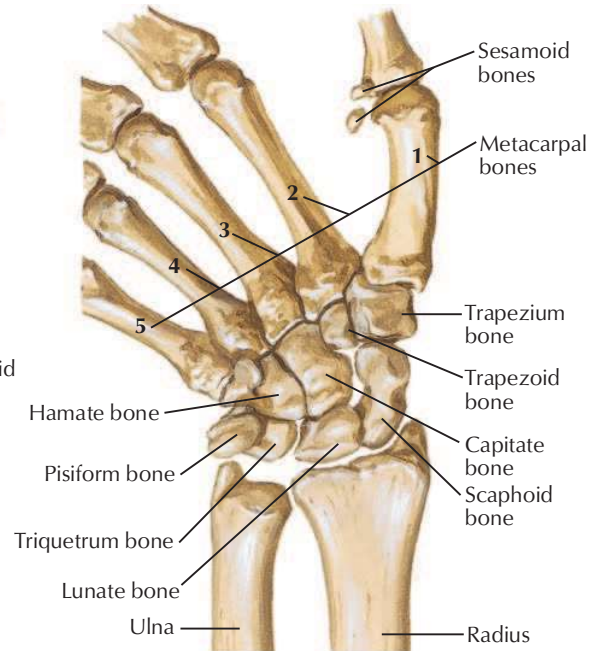




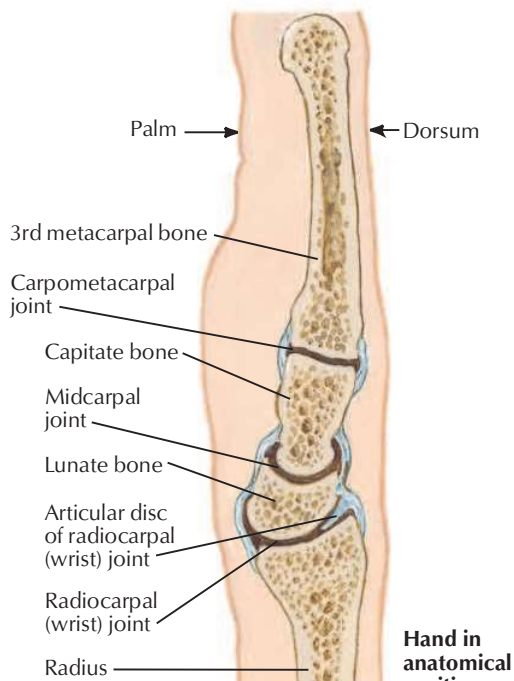
F. Netter M.D.



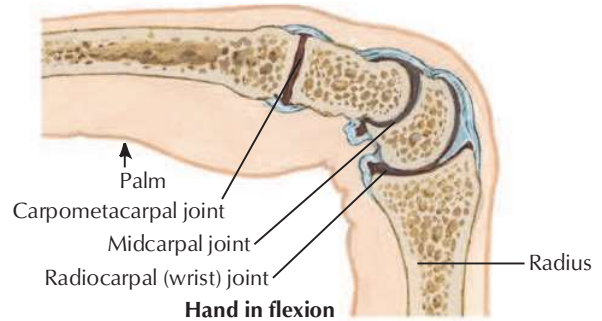
Position of carpal bones with hand in abduction: anterior (palmar) view



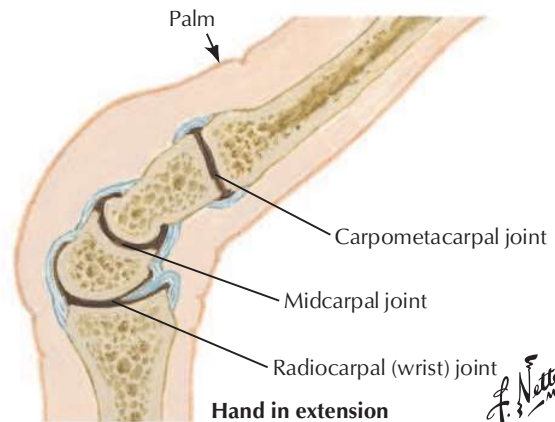
Position of carpal bones with hand in adduction: anterior (palmar) view



Sagittal sections through wrist and middle finger

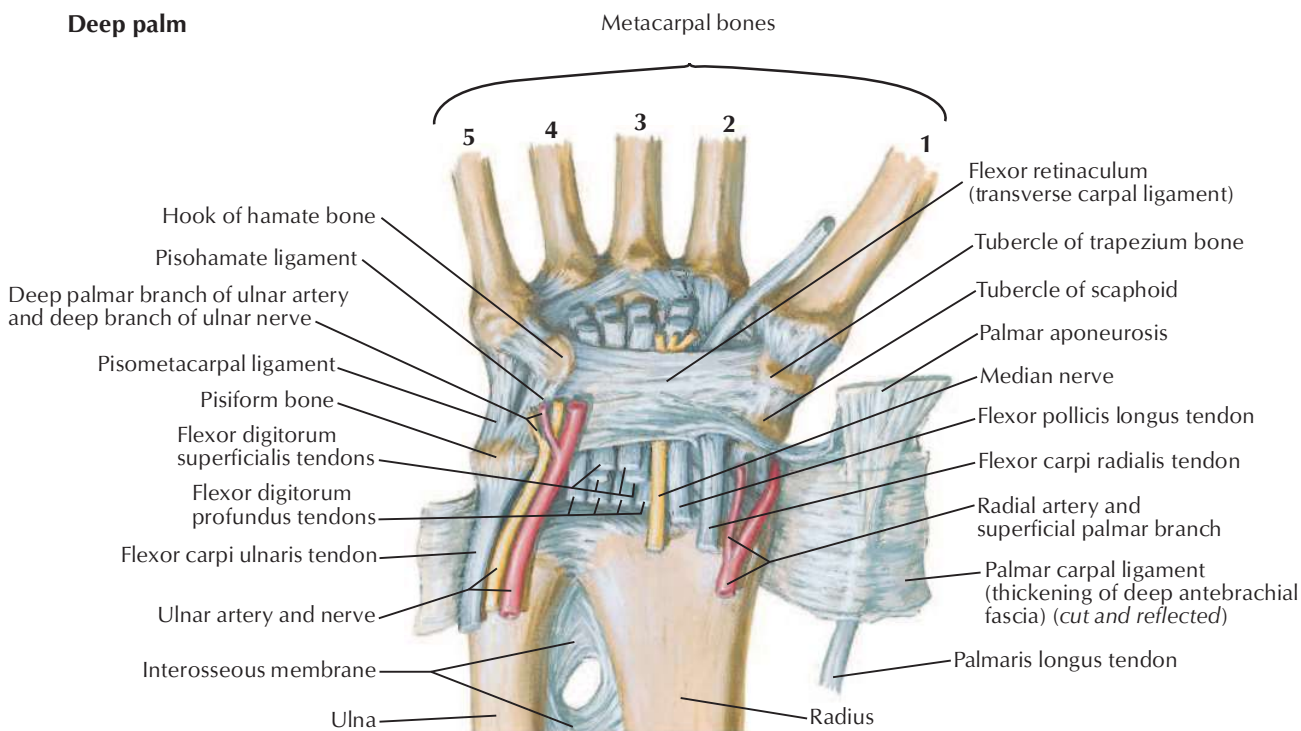


Hand in flexion

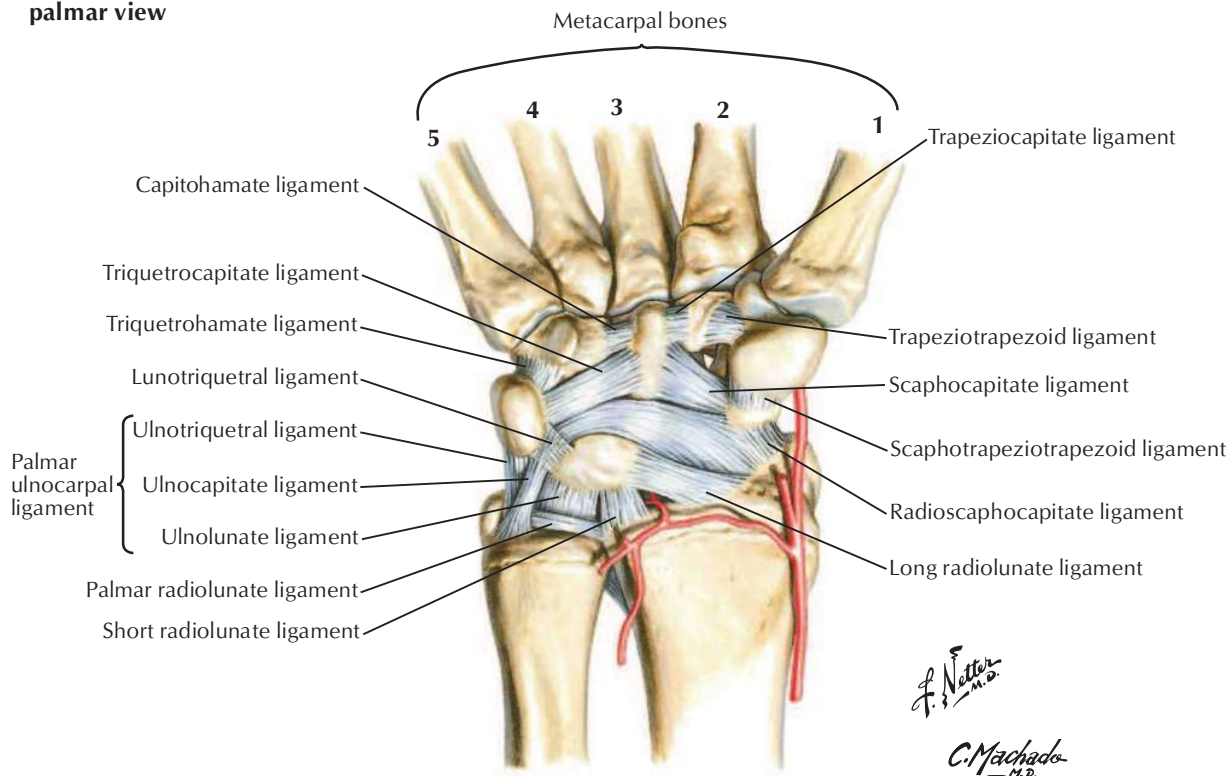


Hand in extension

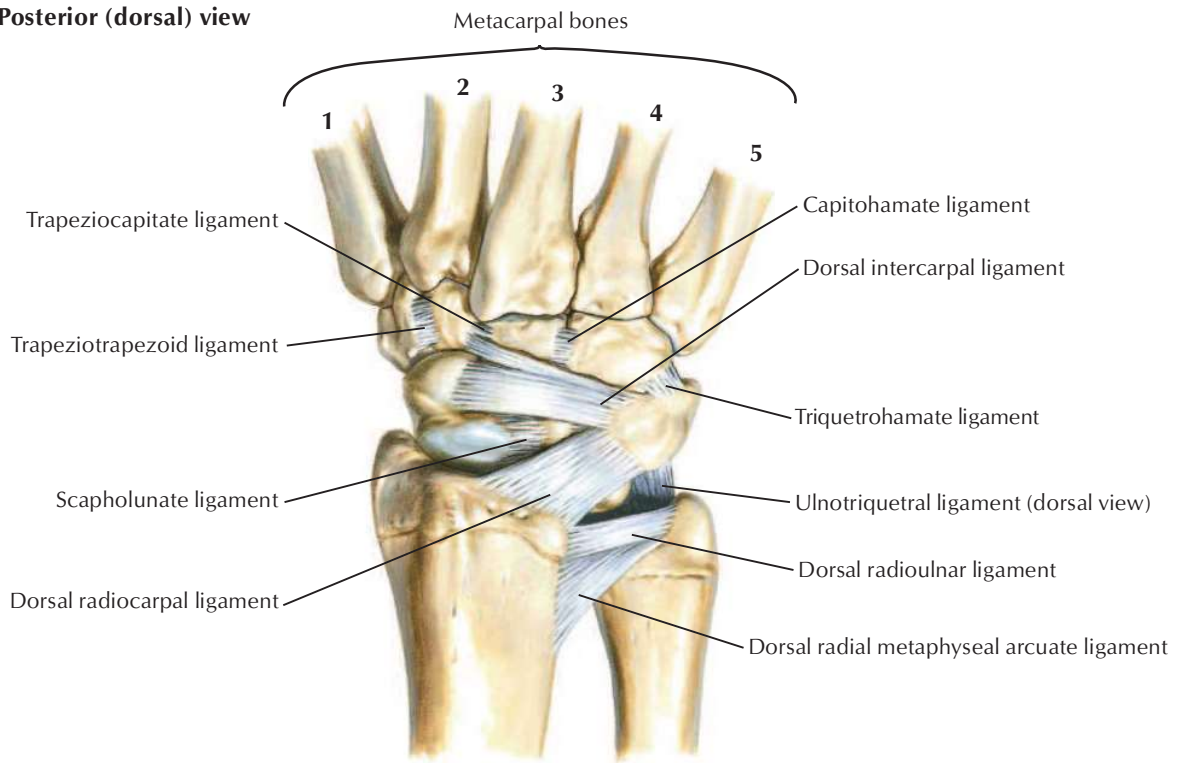
Deep palm



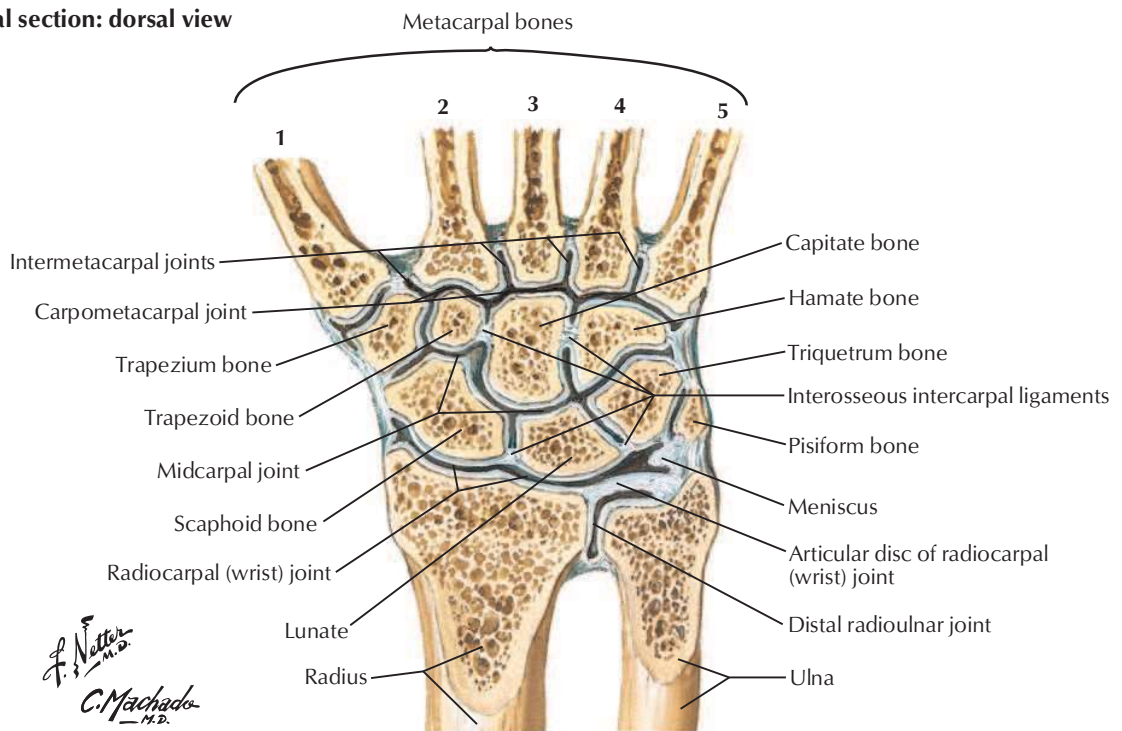
Flexor retinaculum removed: palmar view



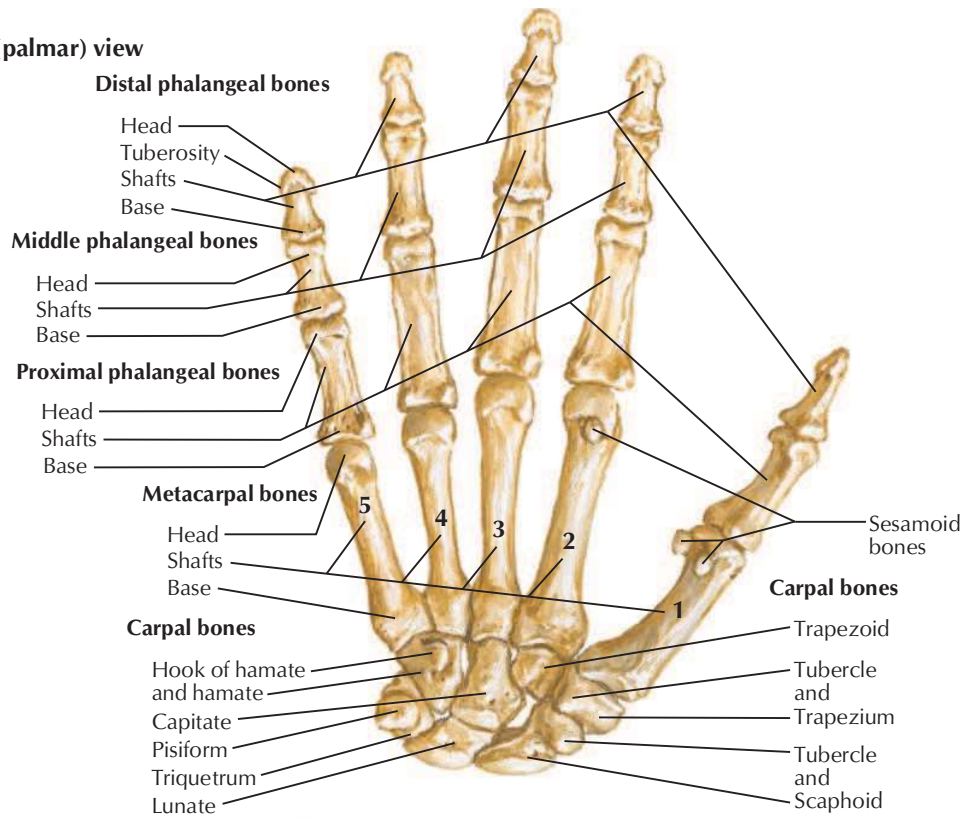
Posterior (dorsal) view



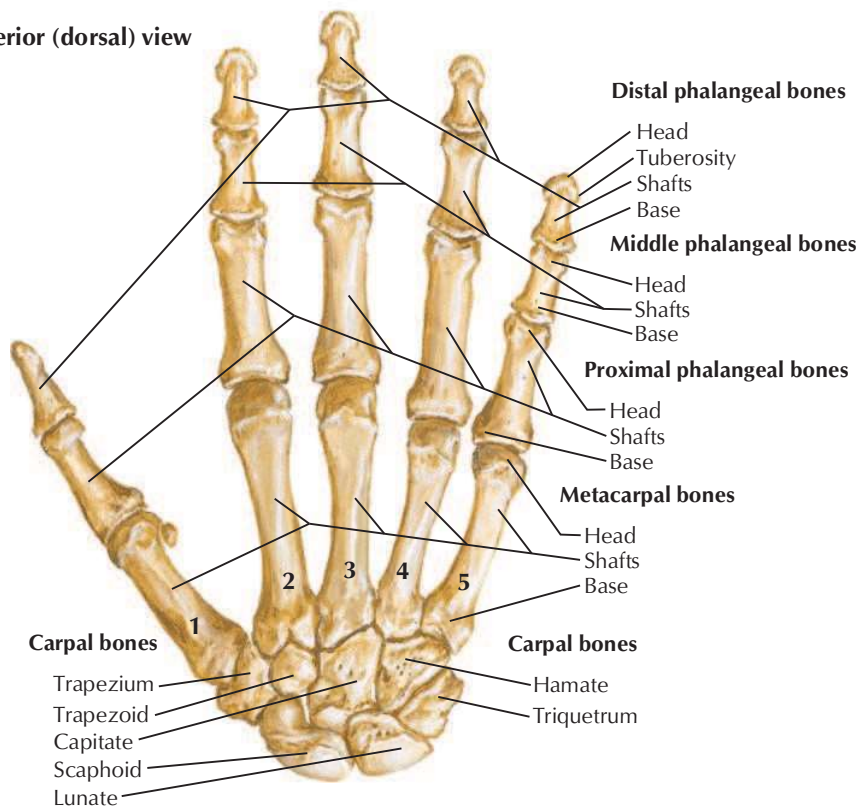
Coronal section: dorsal view



Right hand: anterior (palmar) view



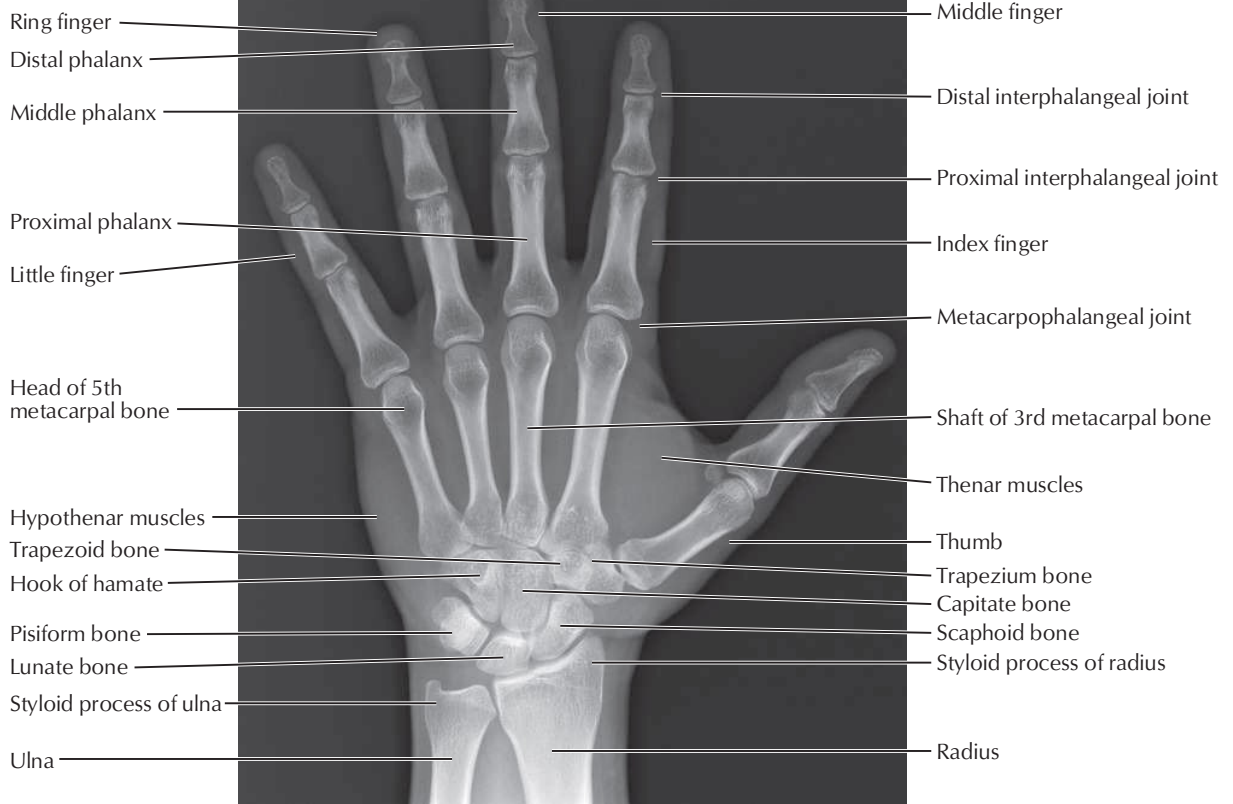
Right hand: posterior (dorsal) view



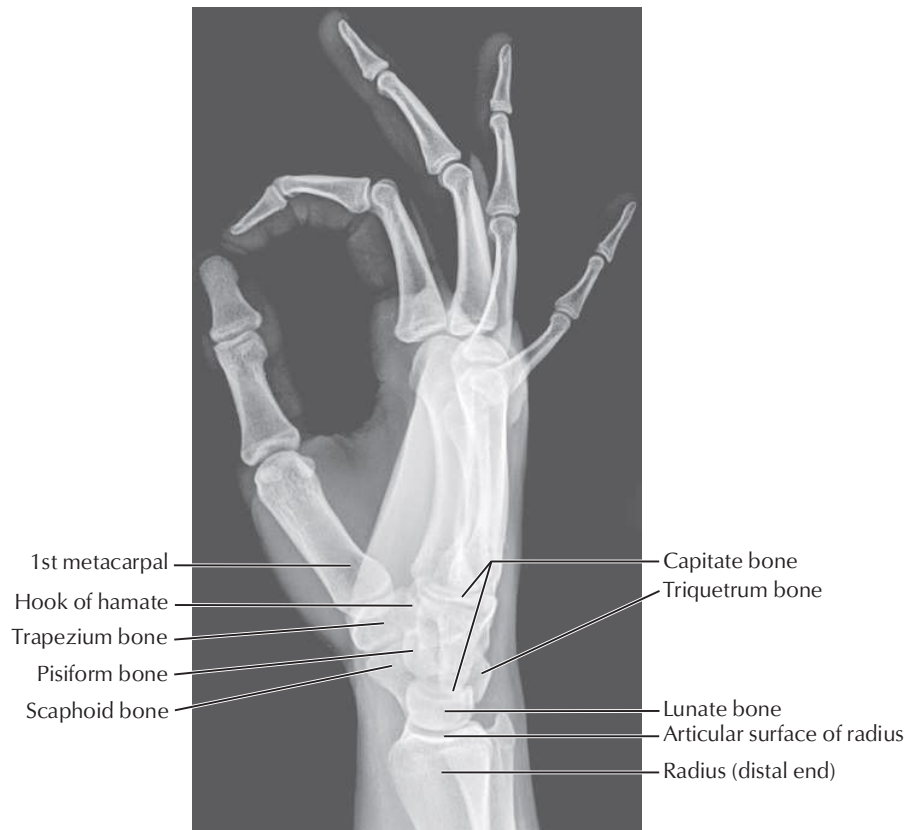
F. Netter M.D.

See also **Plate 446**

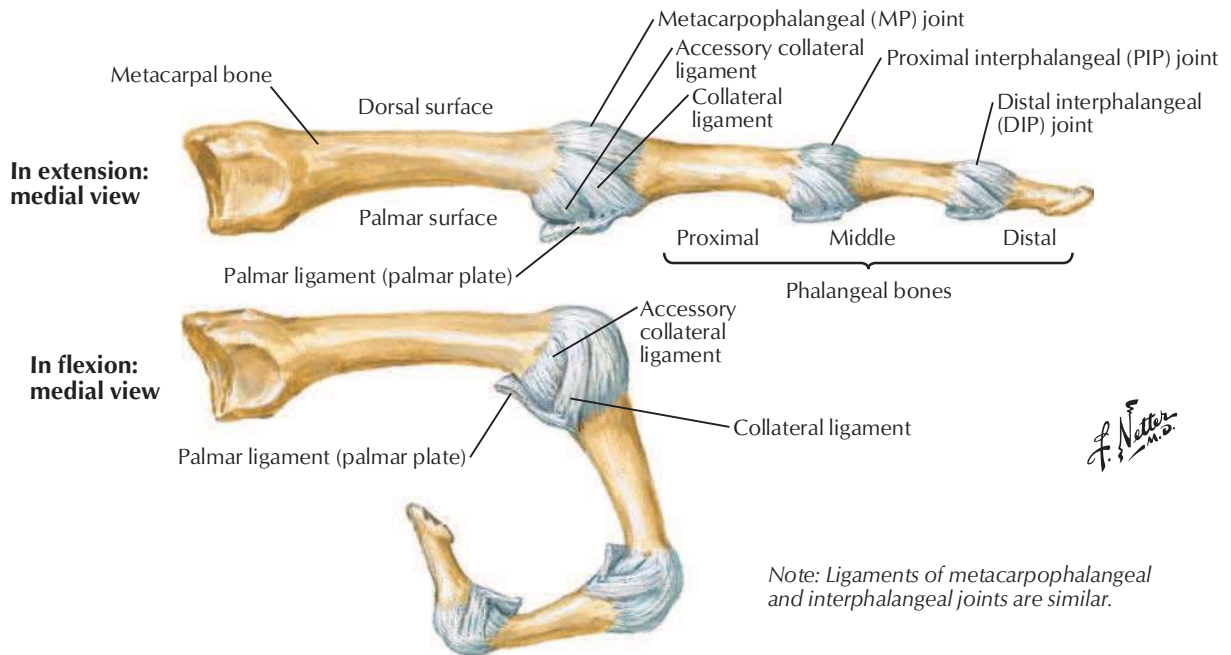
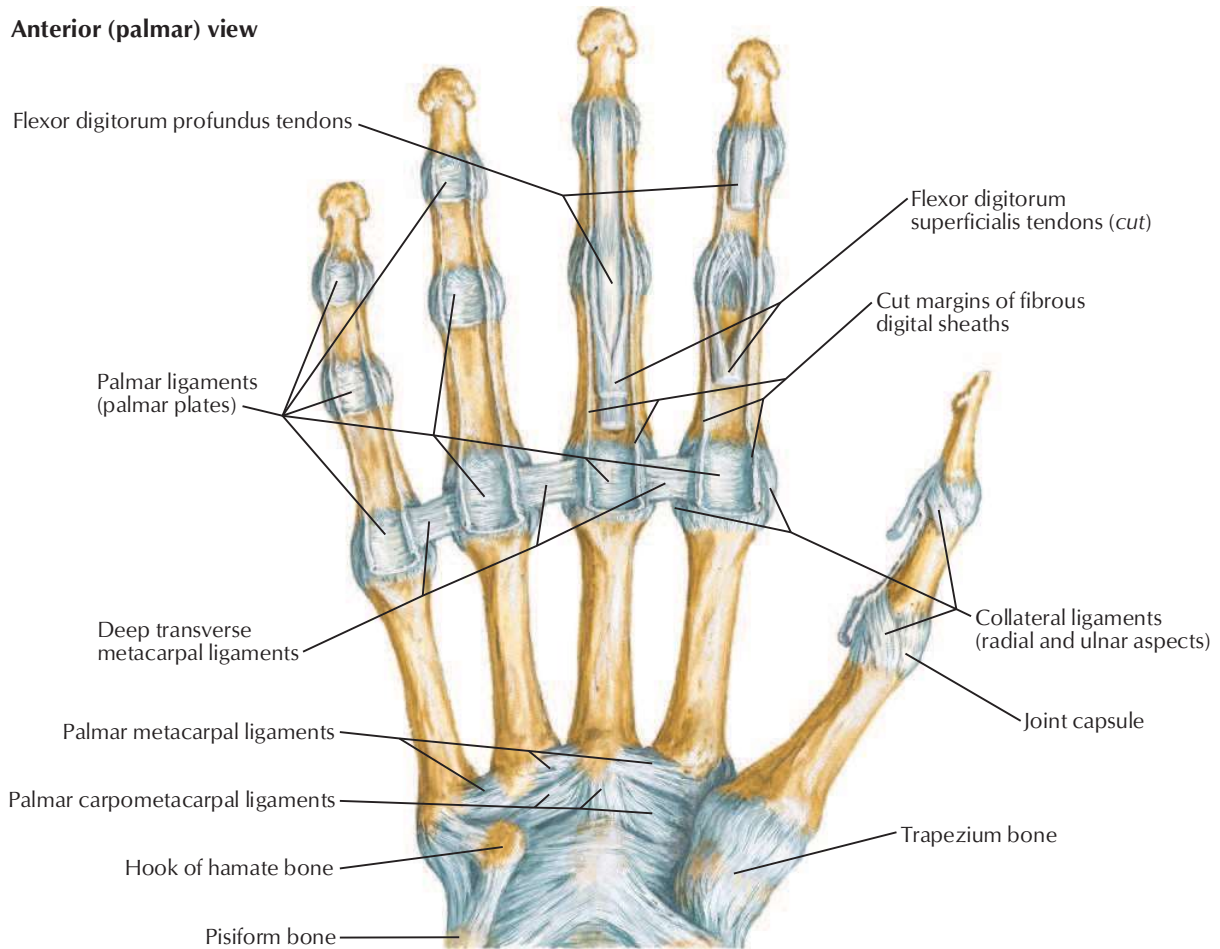
Anteroposterior view



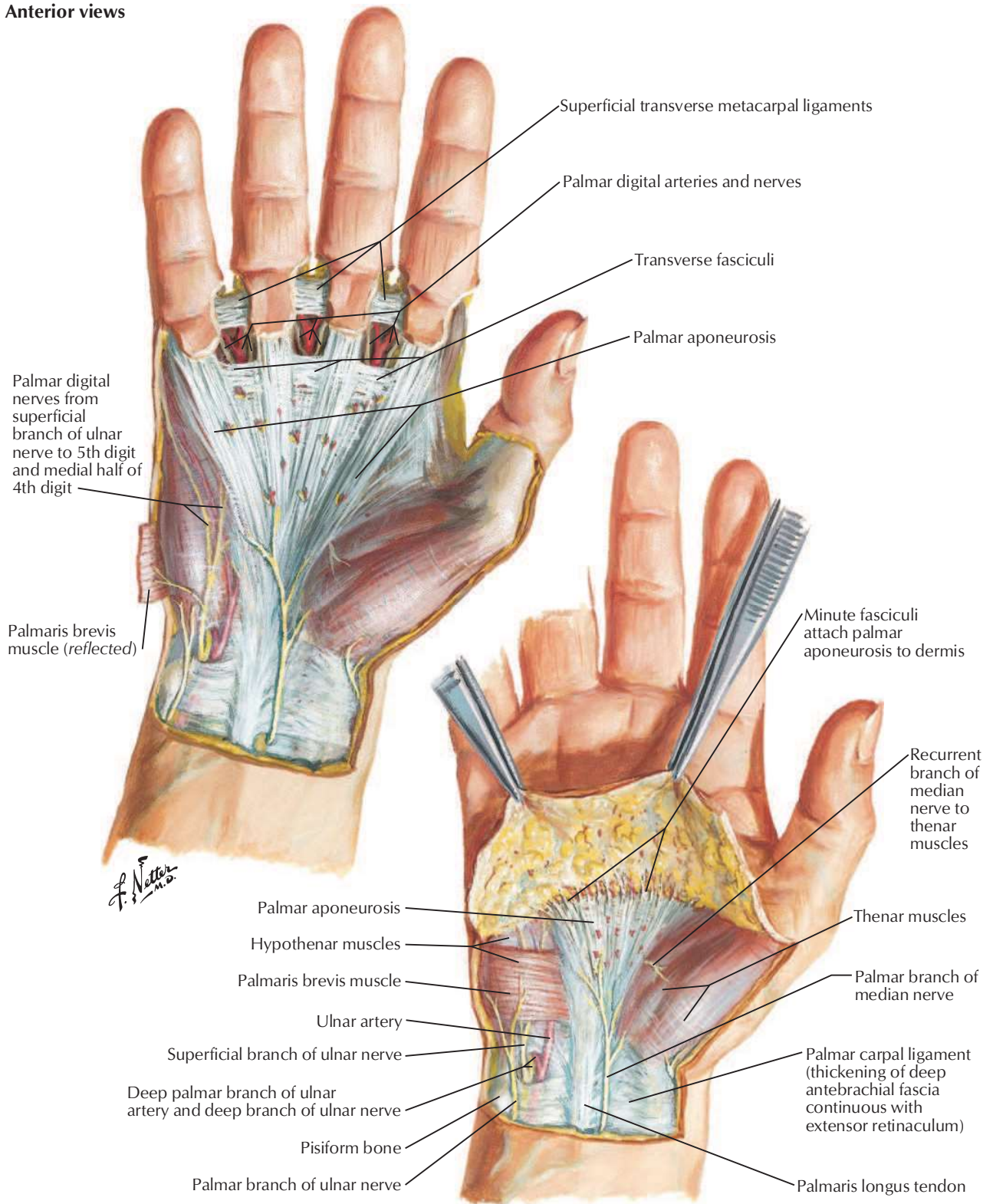
Lateral view

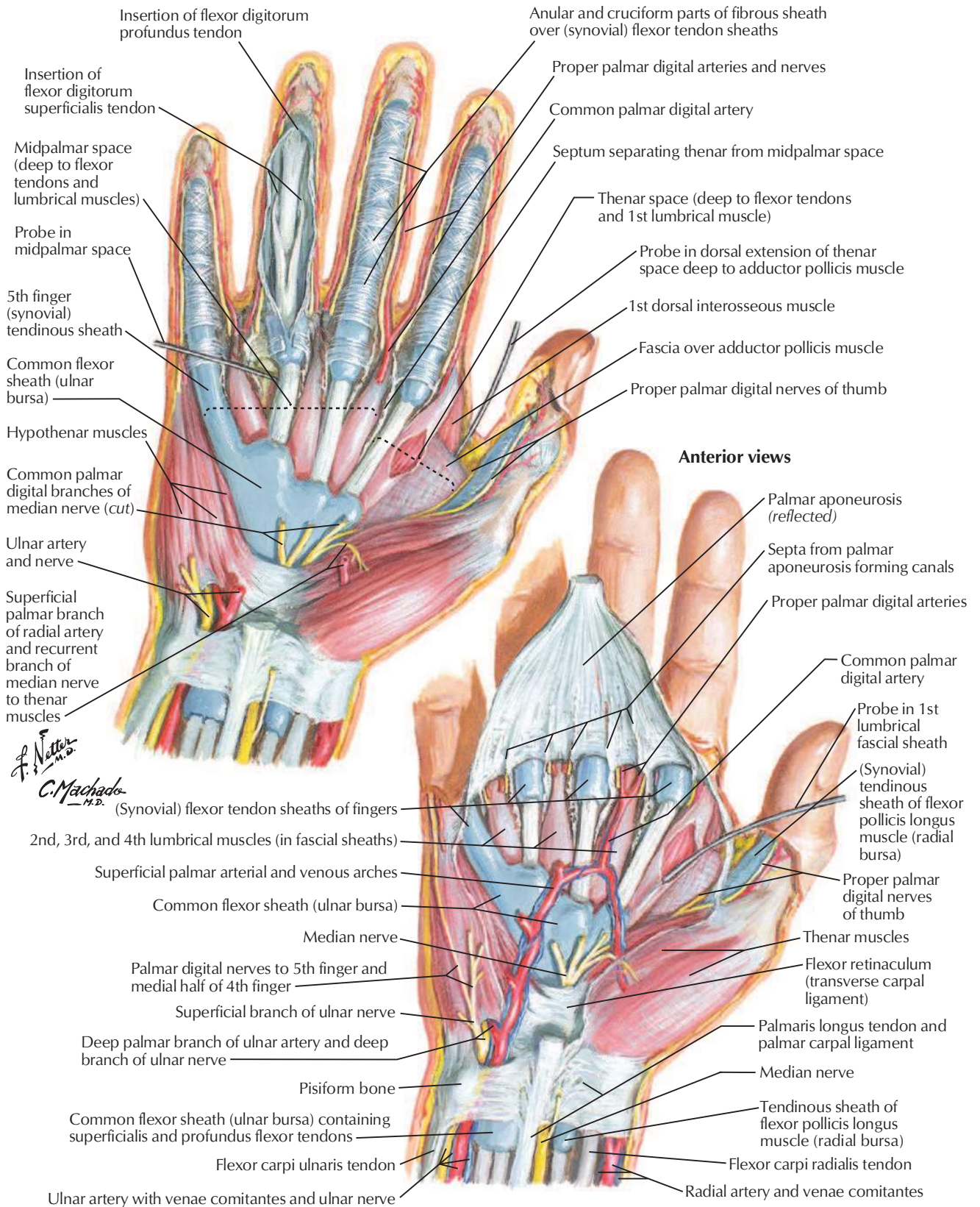


Anterior (palmar) view



Anterior views

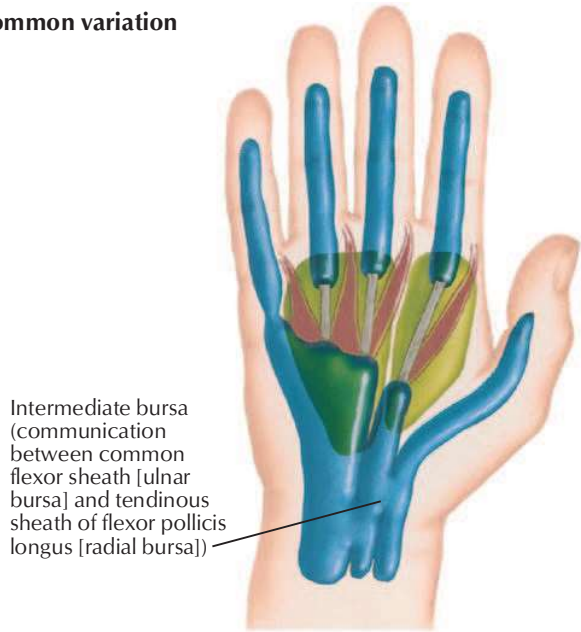




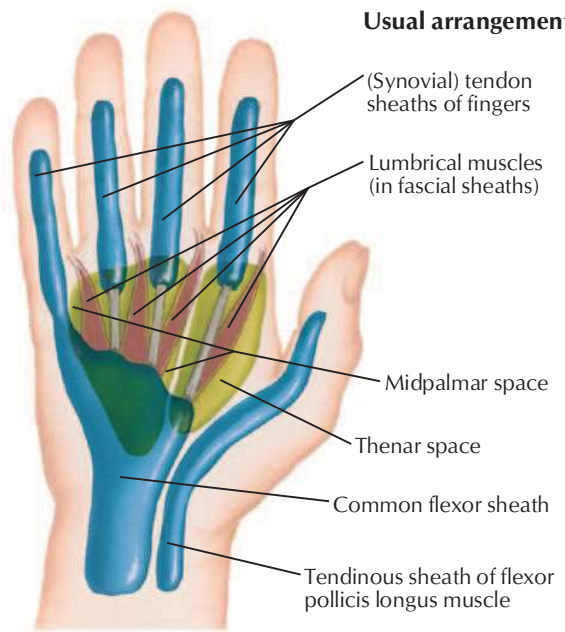
Lumbrical Muscles and Bursae, Spaces, and Sheaths: Schema

See also **Plate 448**

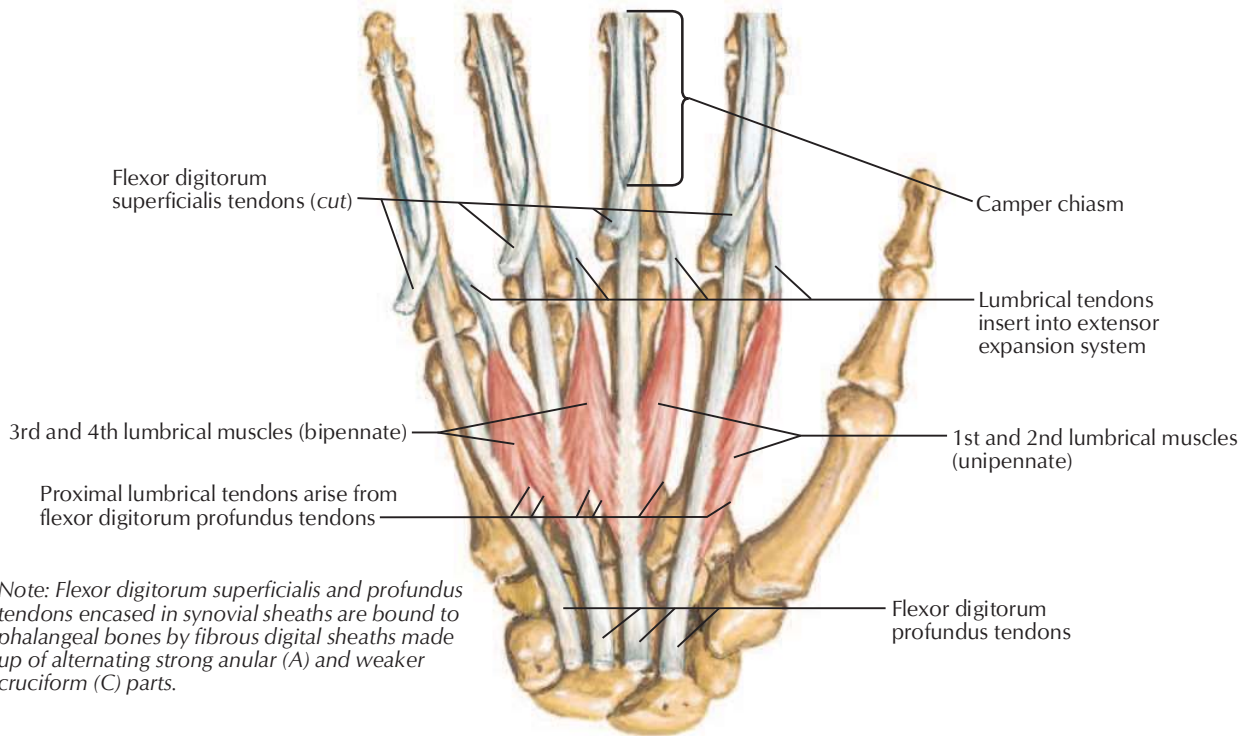
Common variation



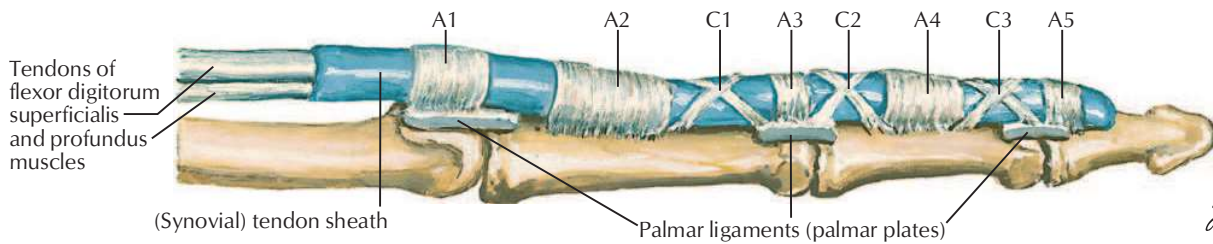
Usual arrangement

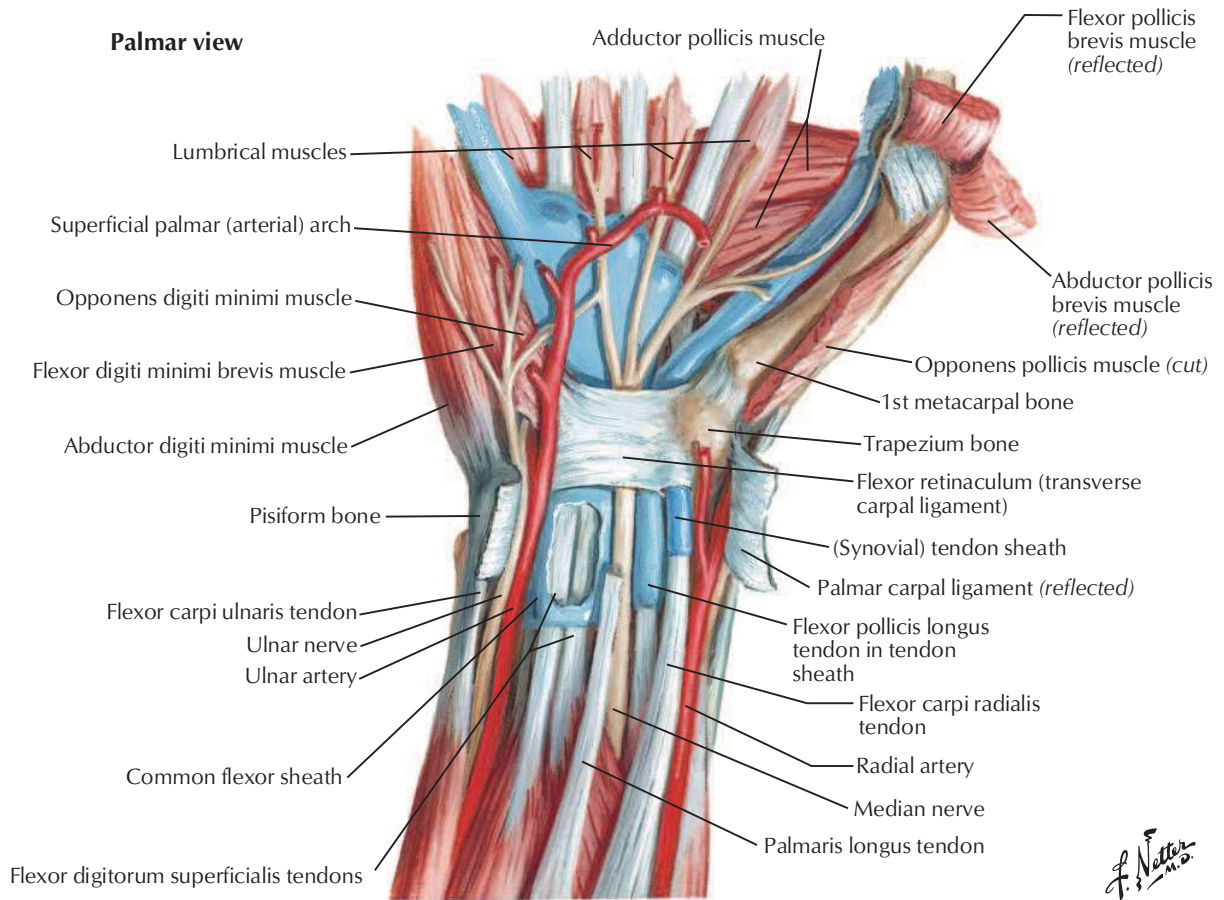


Lumbrical muscles: schema

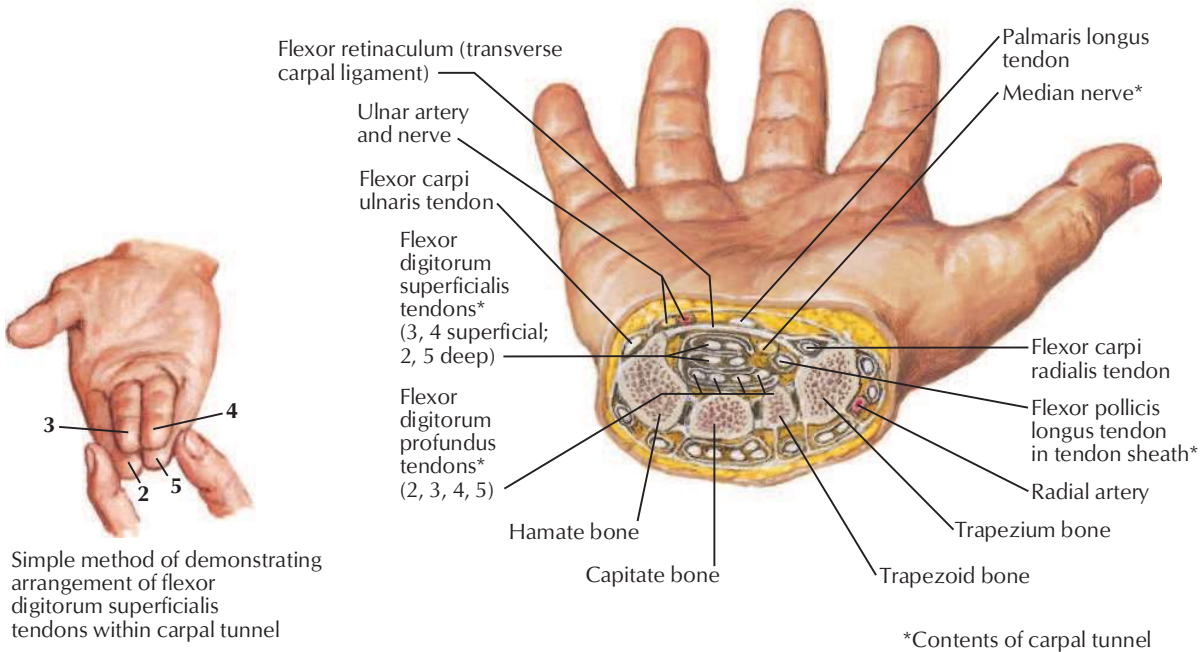


Note: Flexor digitorum superficialis and profundus tendons encased in synovial sheaths are bound to phalangeal bones by fibrous digital sheaths made up of alternating strong annular (A) and weaker cruciform (C) parts.

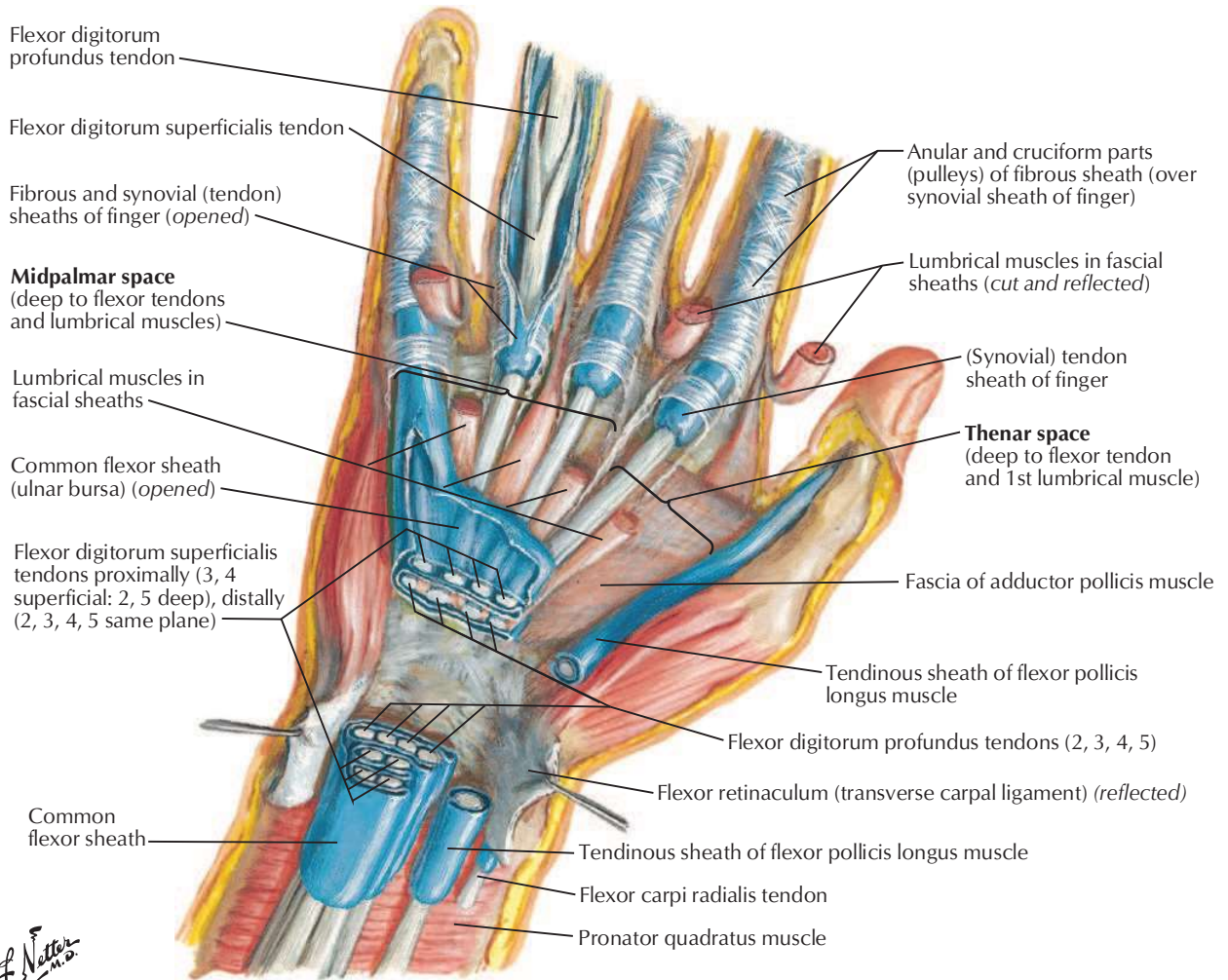




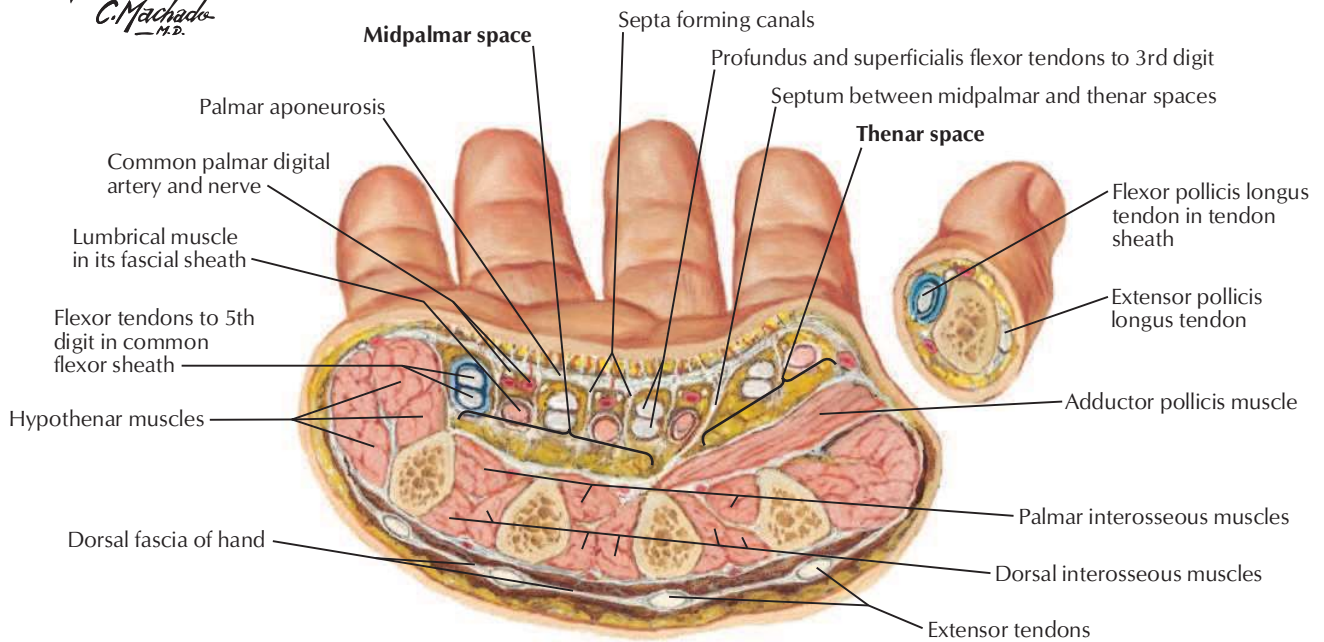
Cross section of wrist demonstrating carpal tunnel

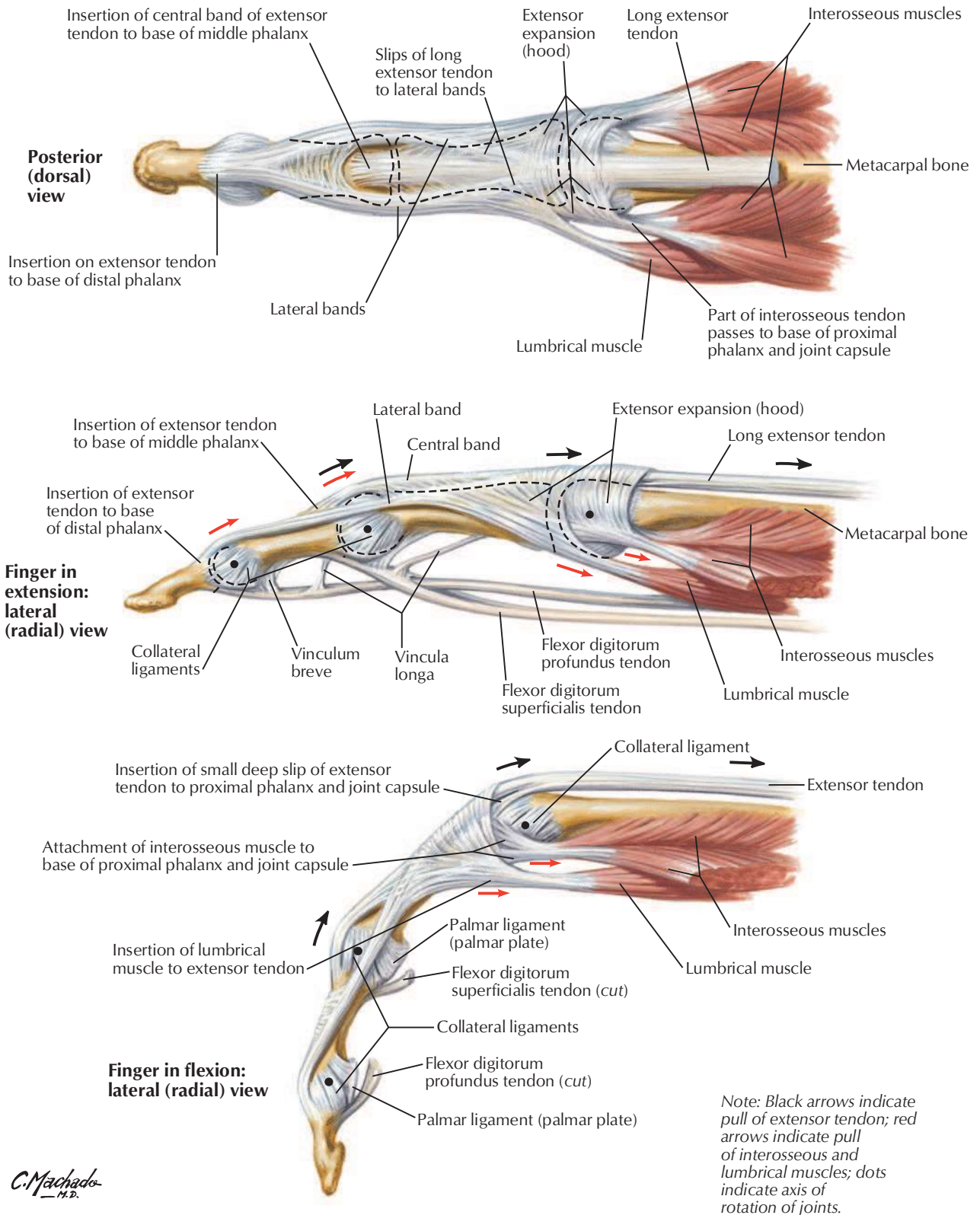


Bursae, Spaces, and Tendon Sheaths of Hand

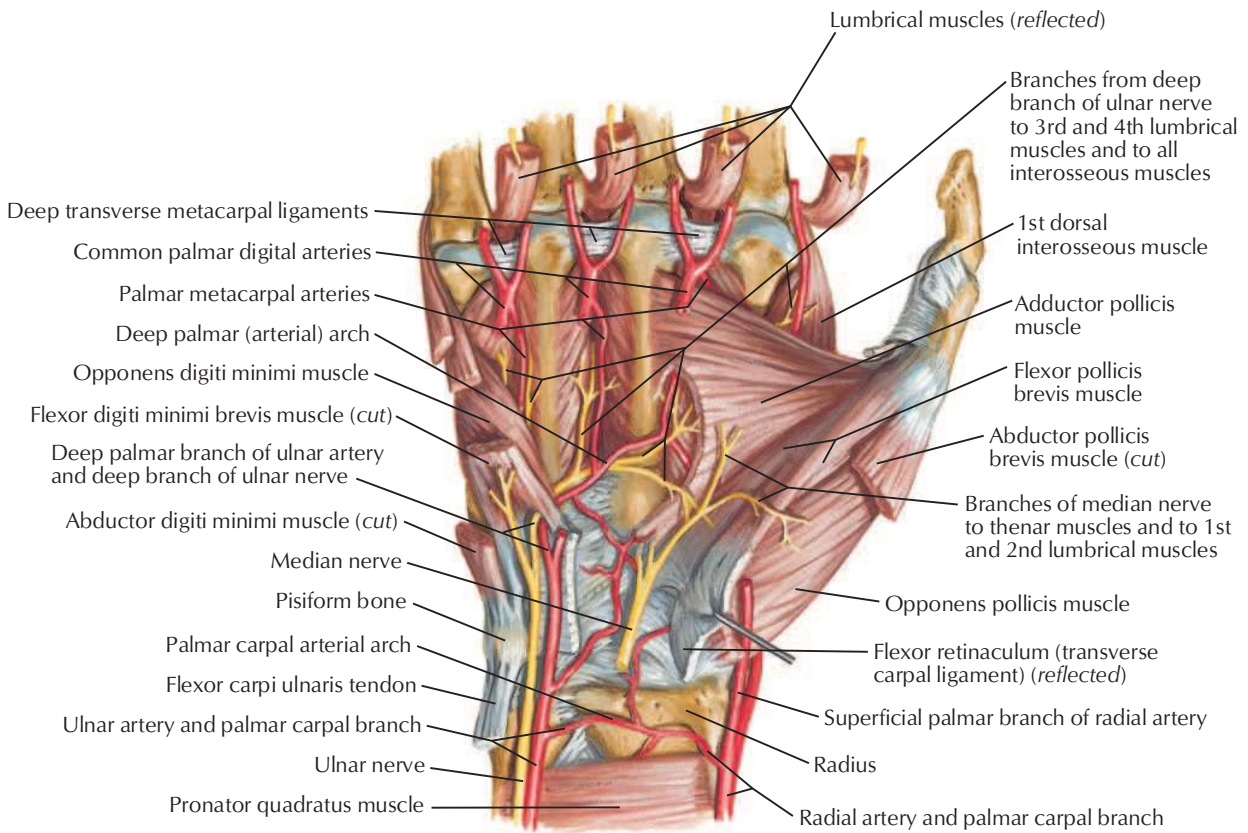


F. Netter M.D.
C. Machado M.D.

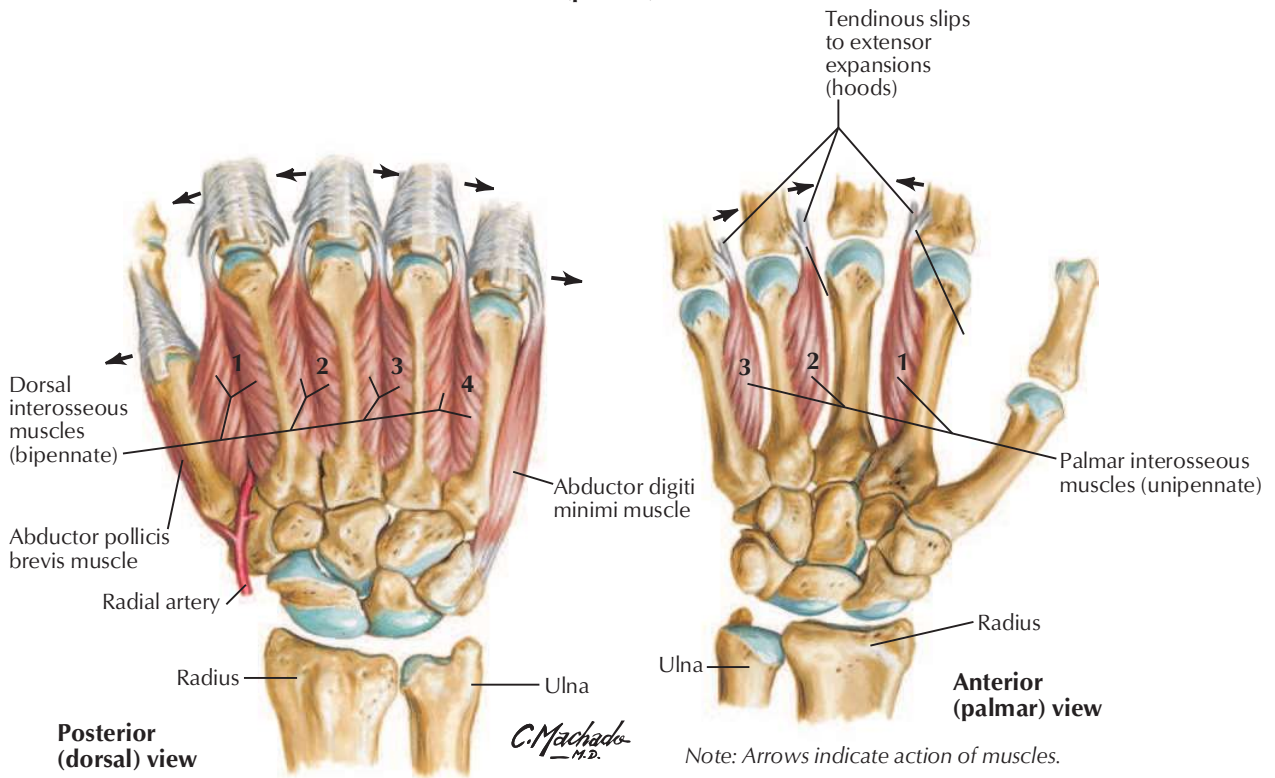


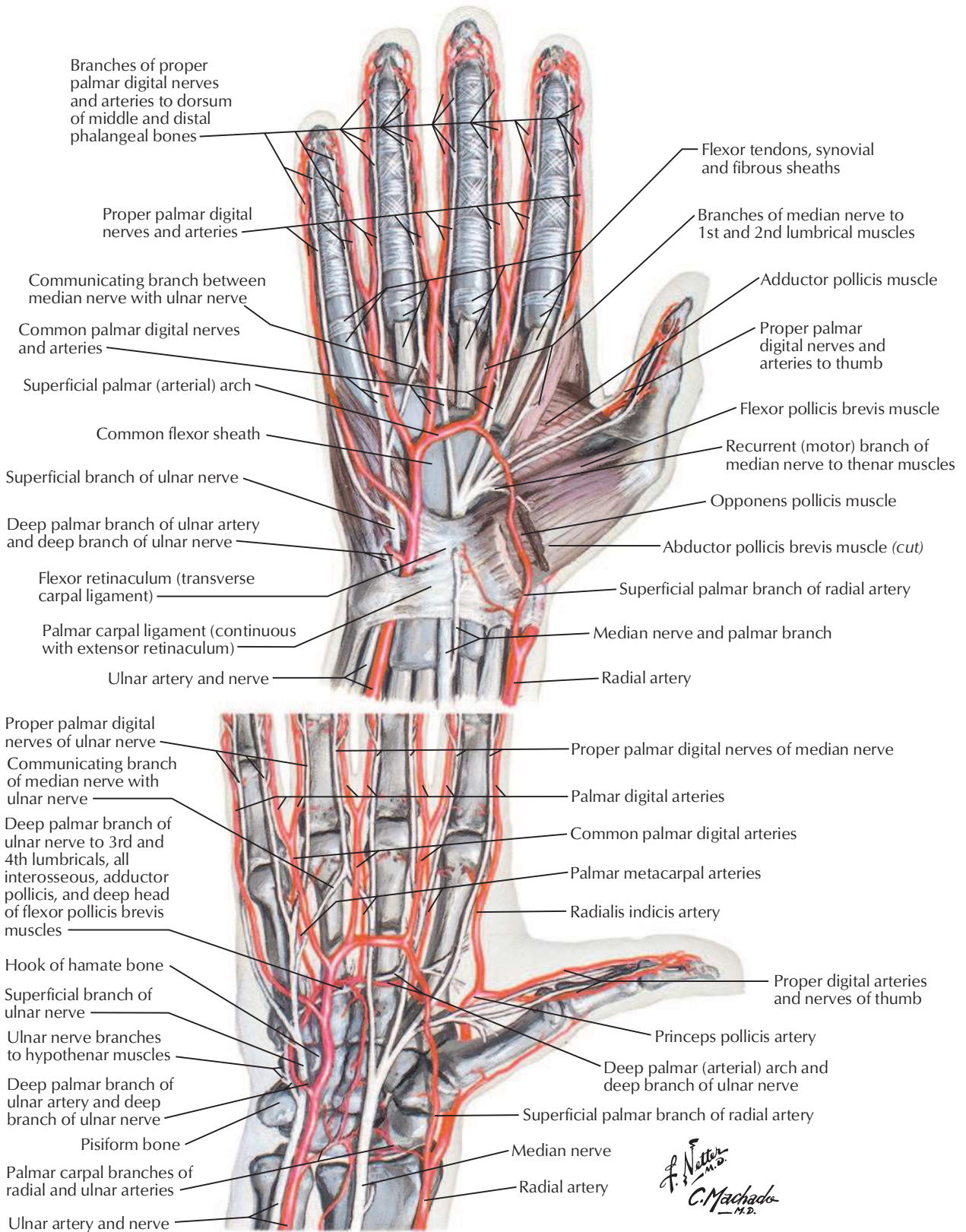


C. Machado
—M.D.

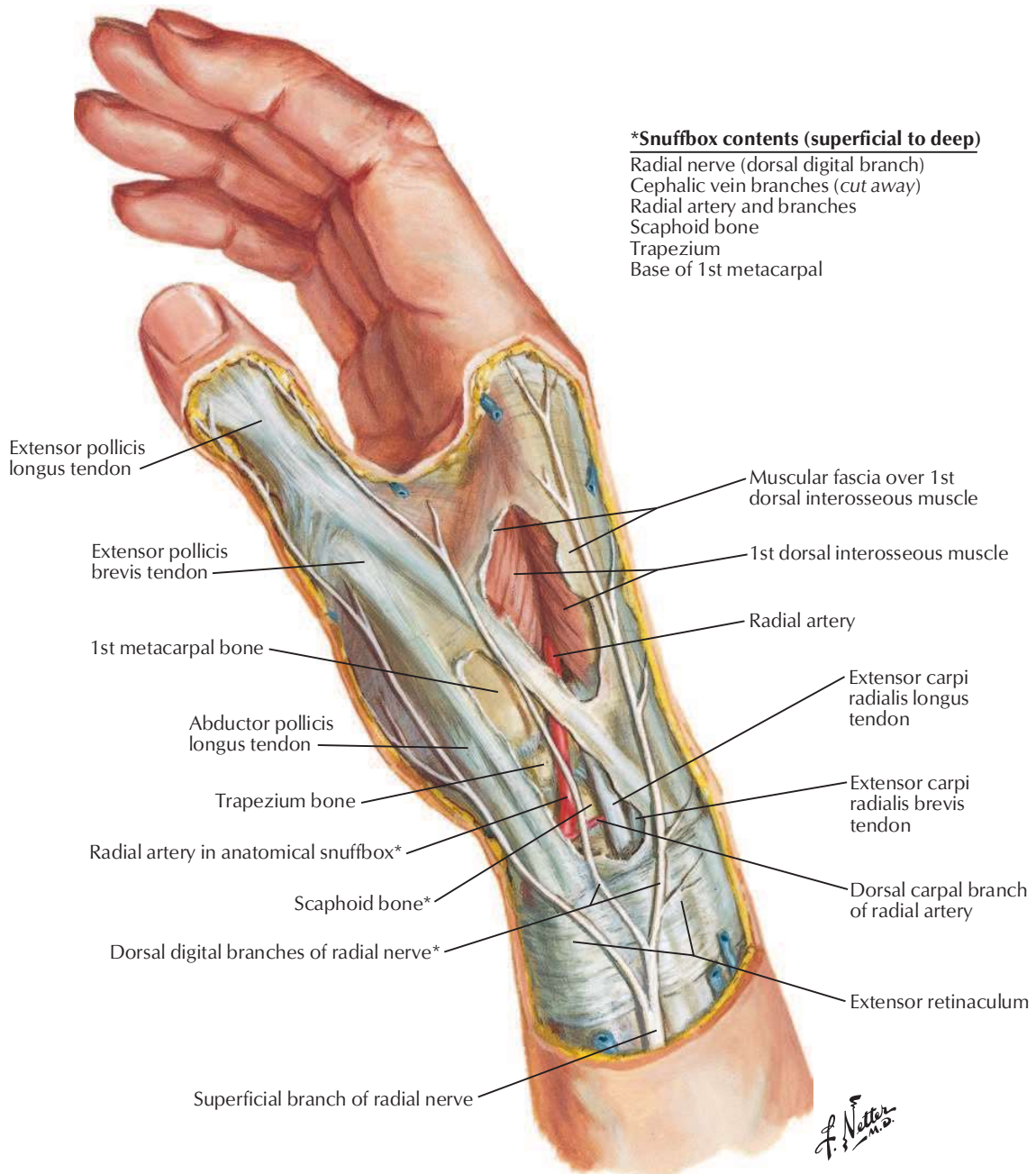


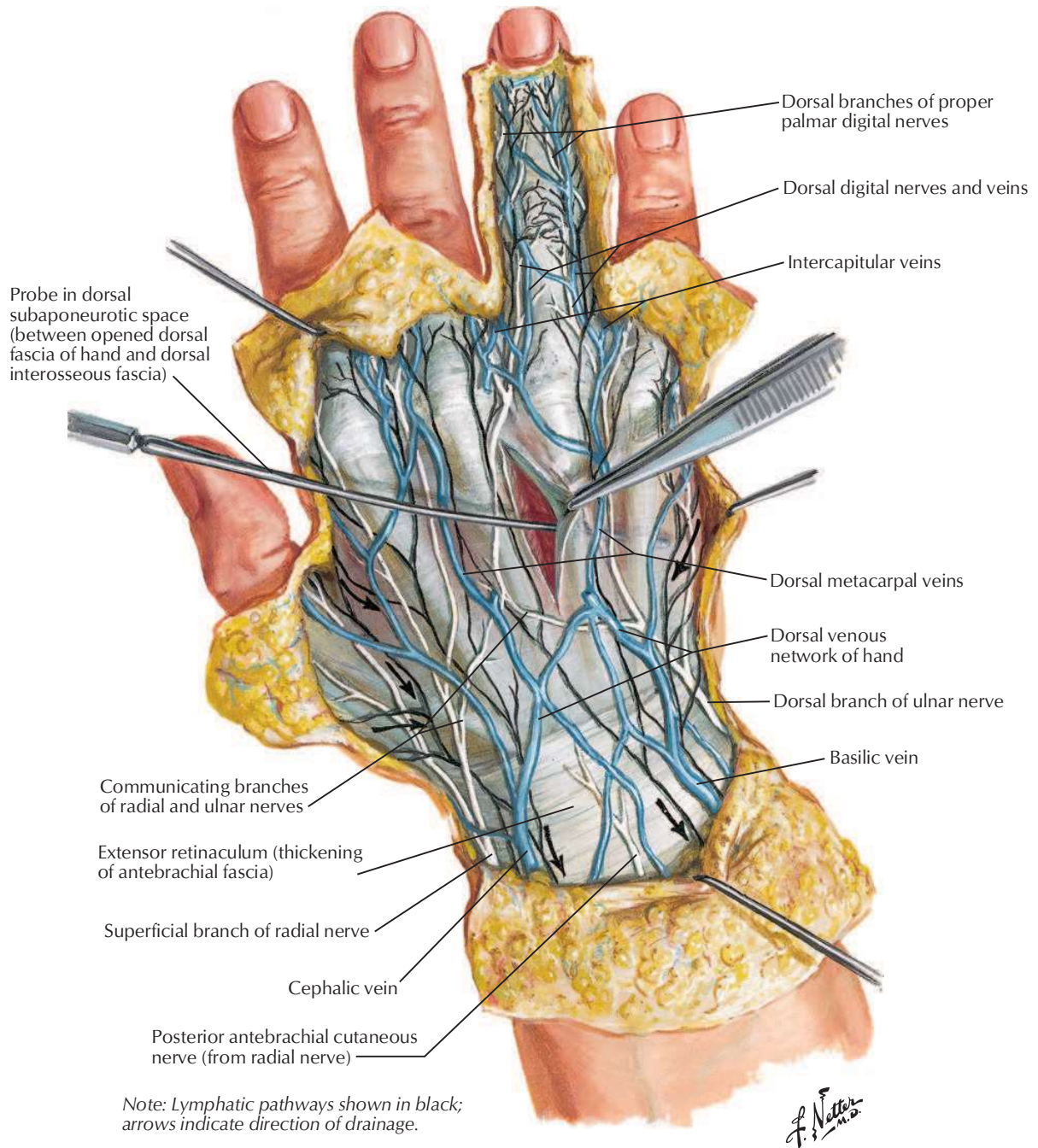
Anterior (palmar) view

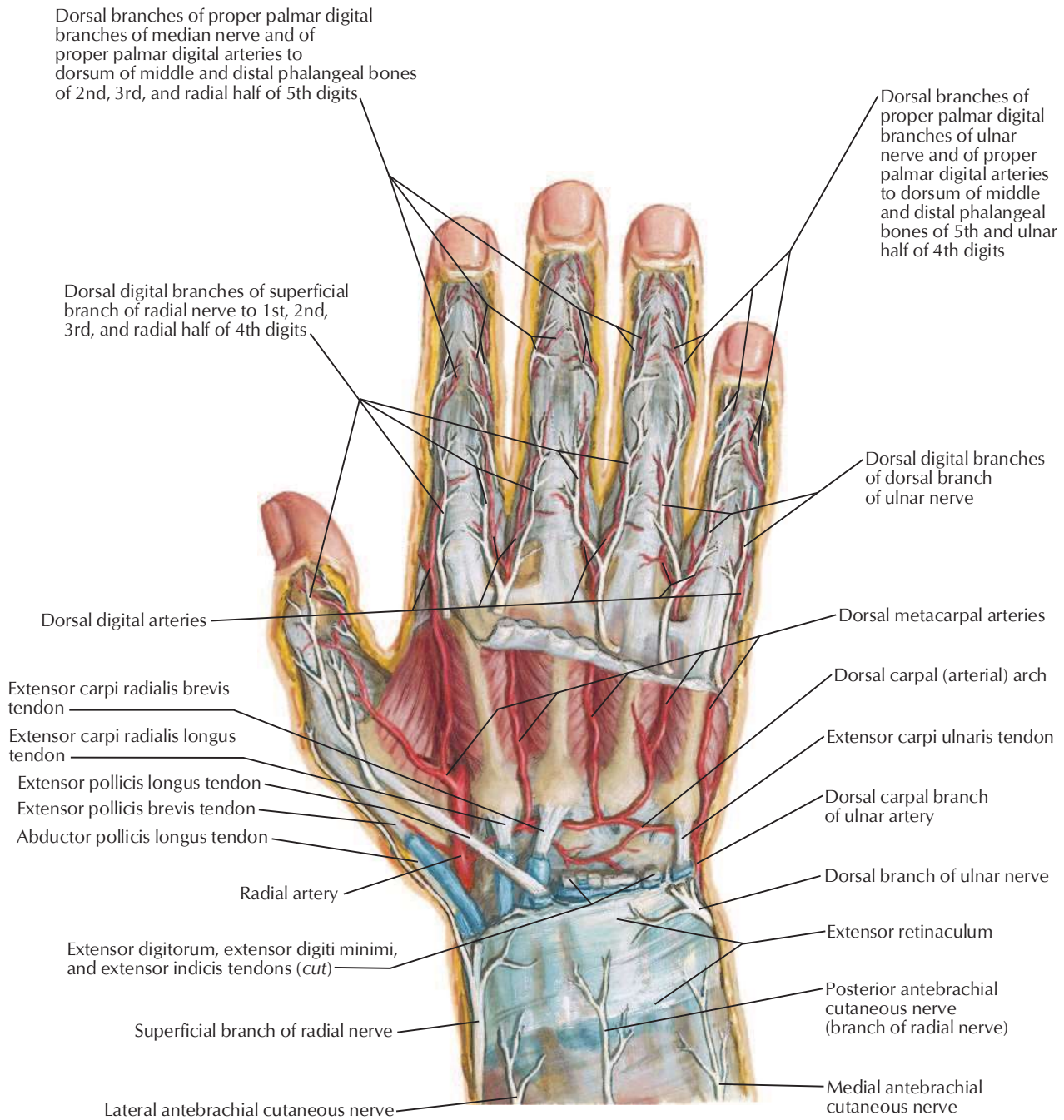


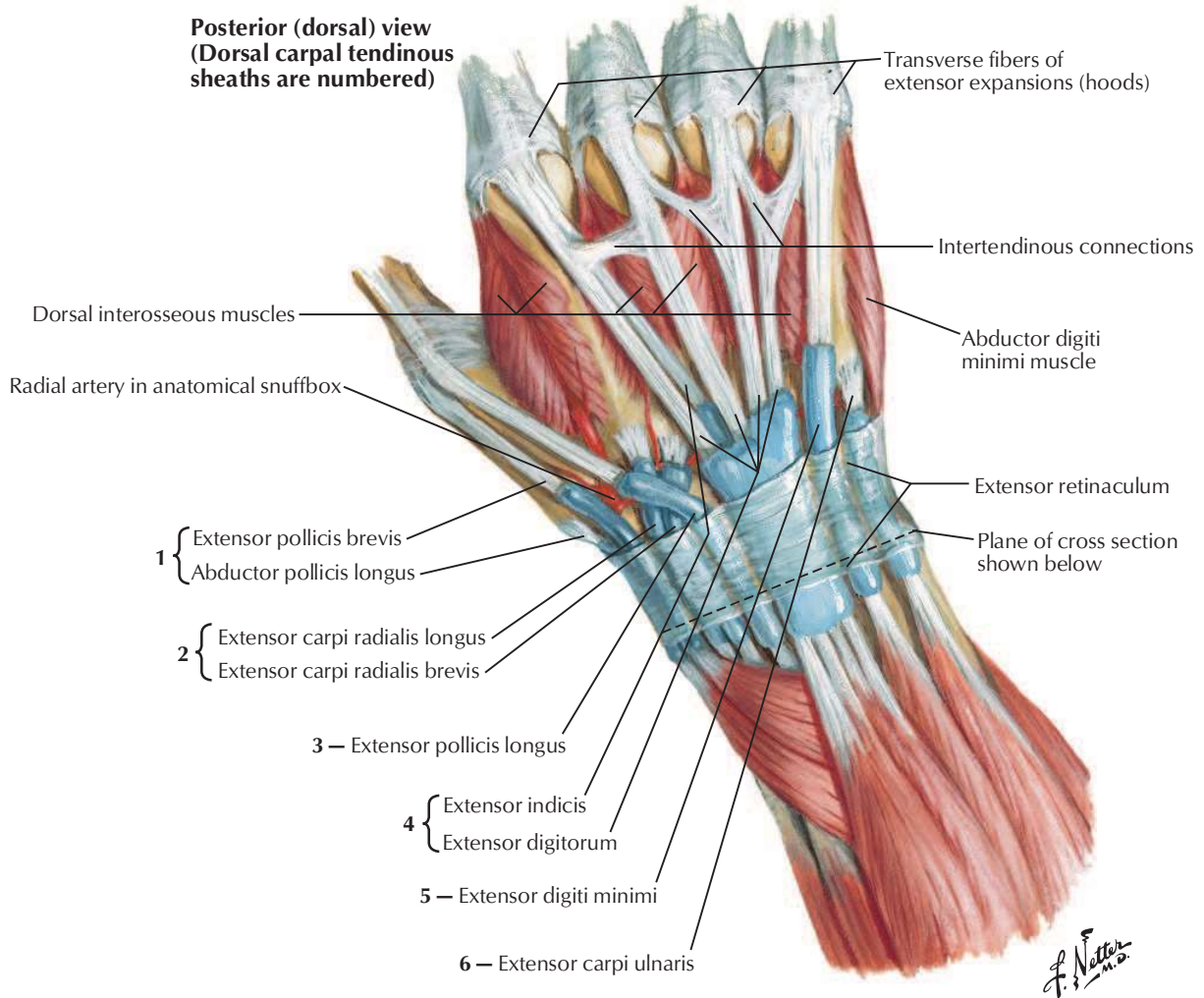


F. Netter M.D.
C. Machado M.D.

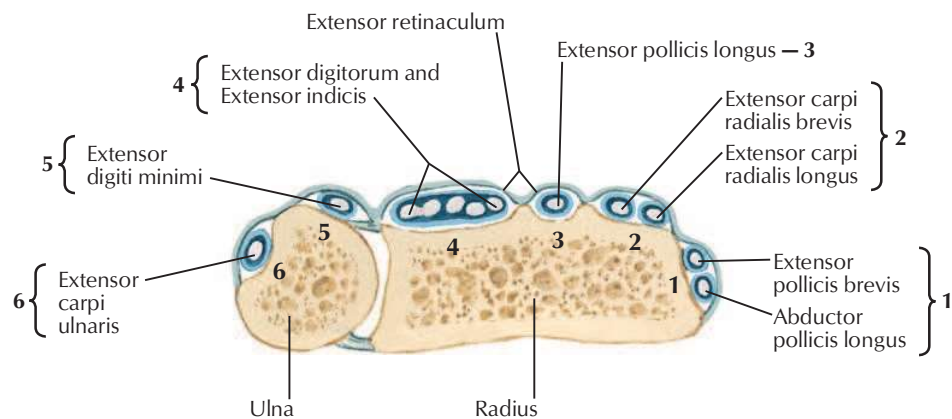


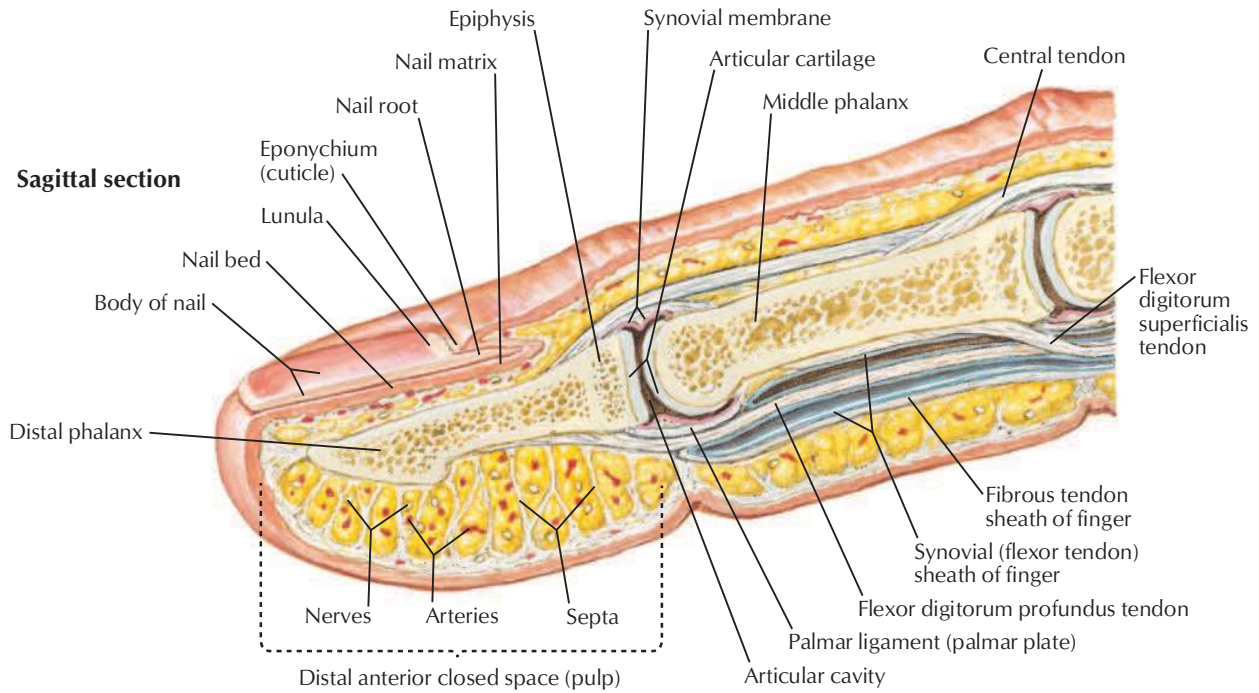




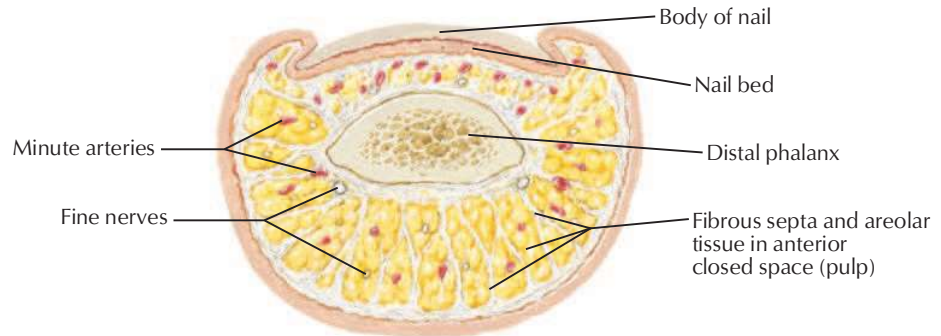


Cross section of most distal portion of forearm

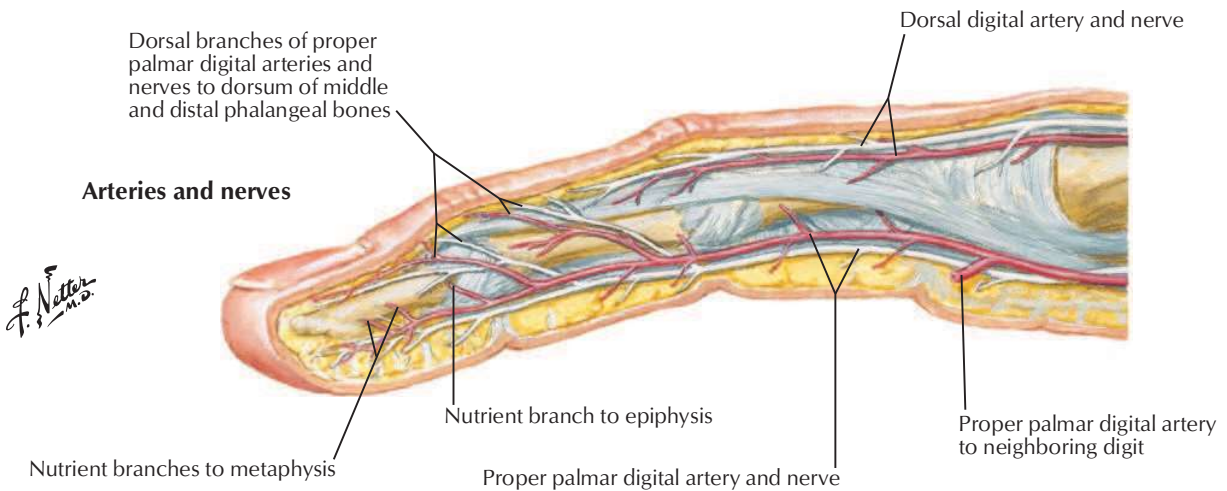


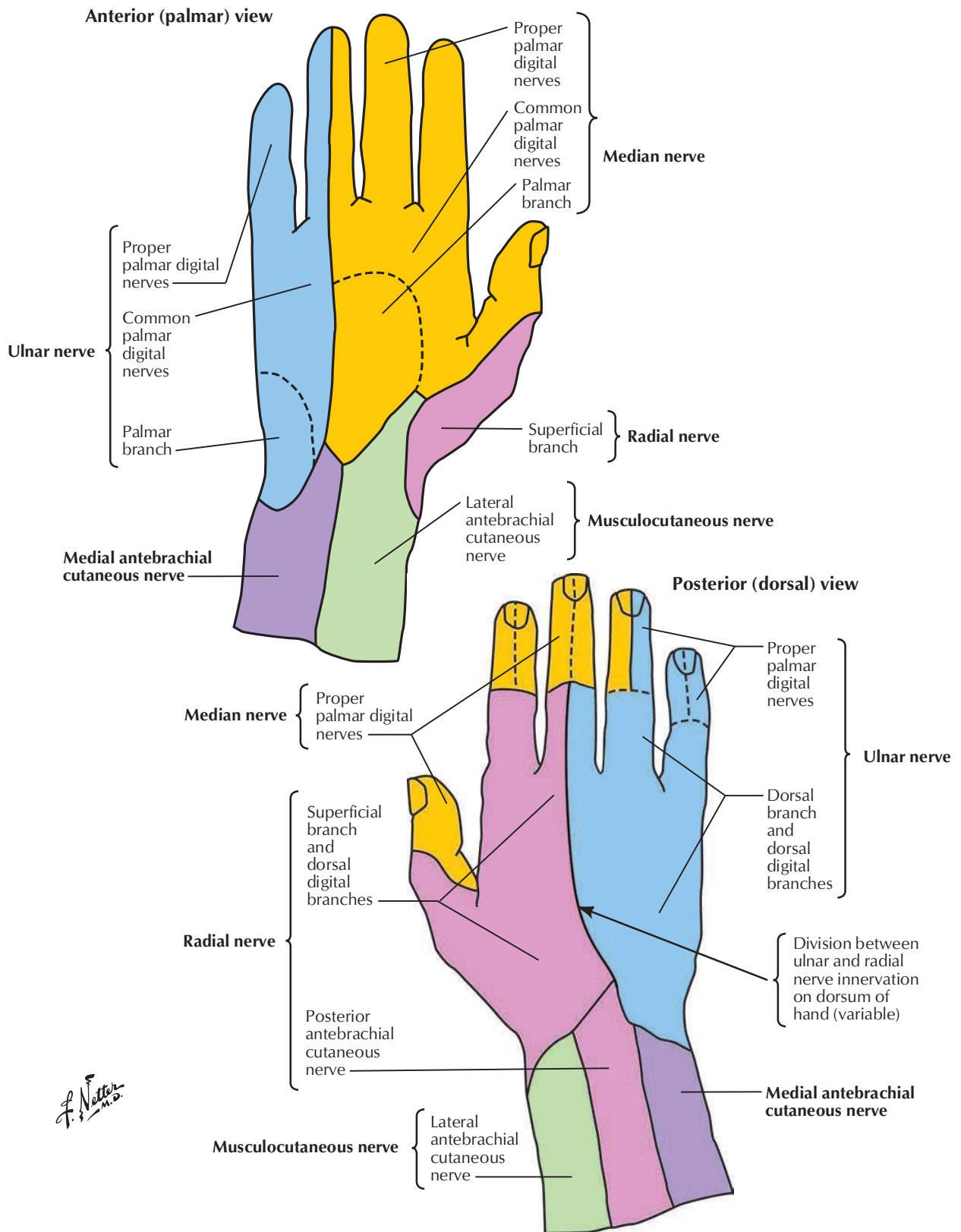


Cross section through distal phalanx



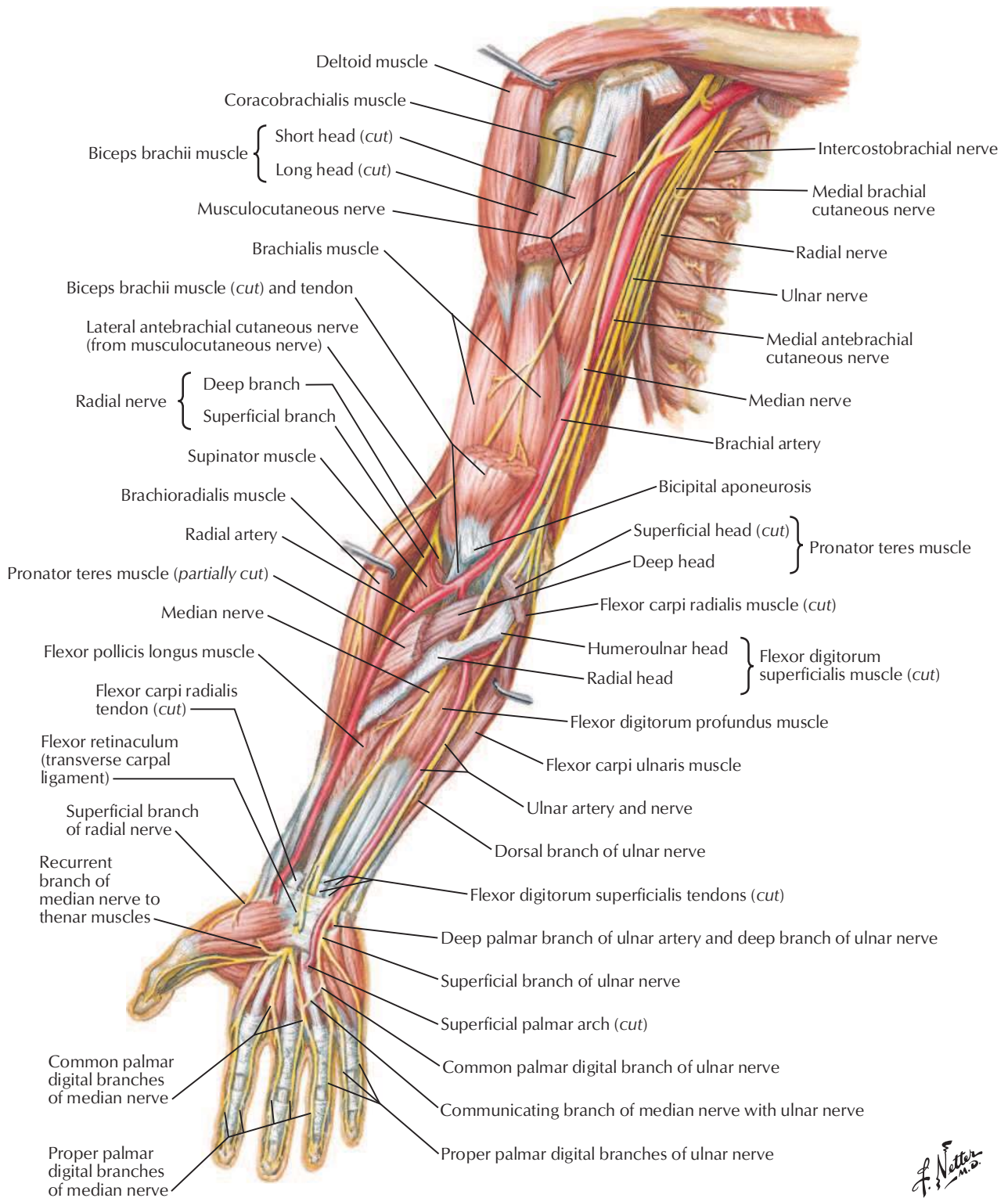
Arteries and nerves

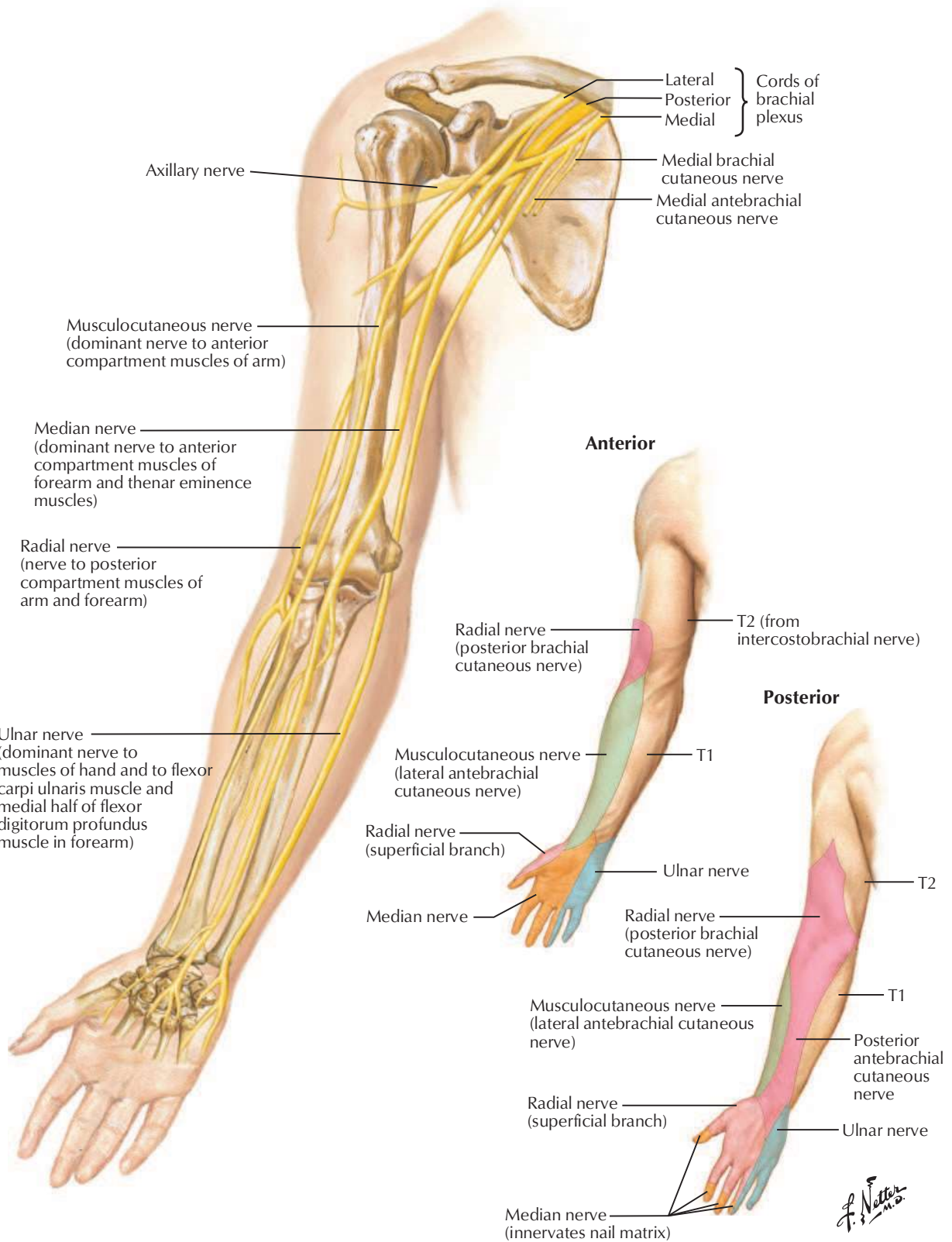




Arteries and Nerves of Upper Limb: Anterior View

See also [Plates 423, 438](#)

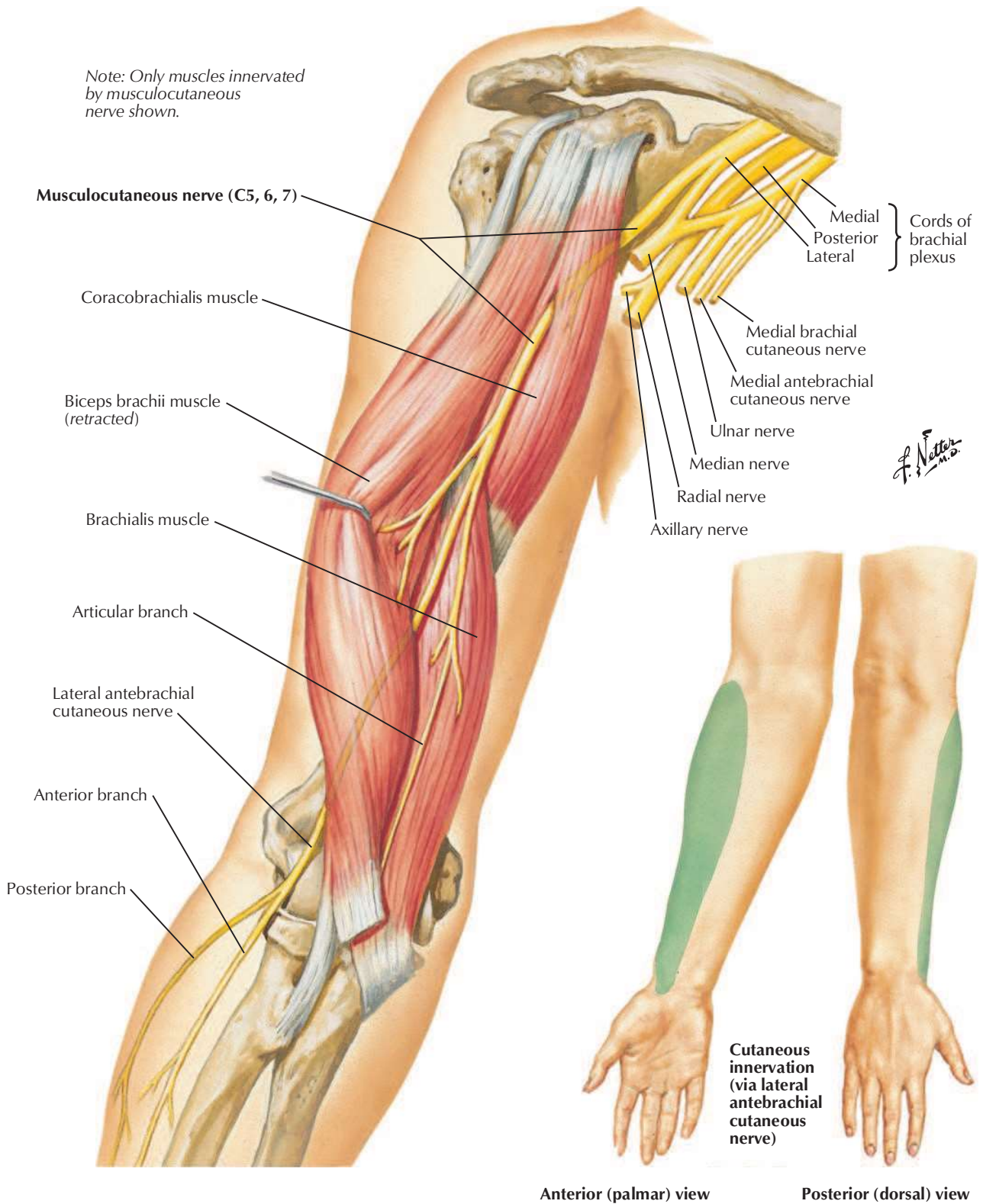




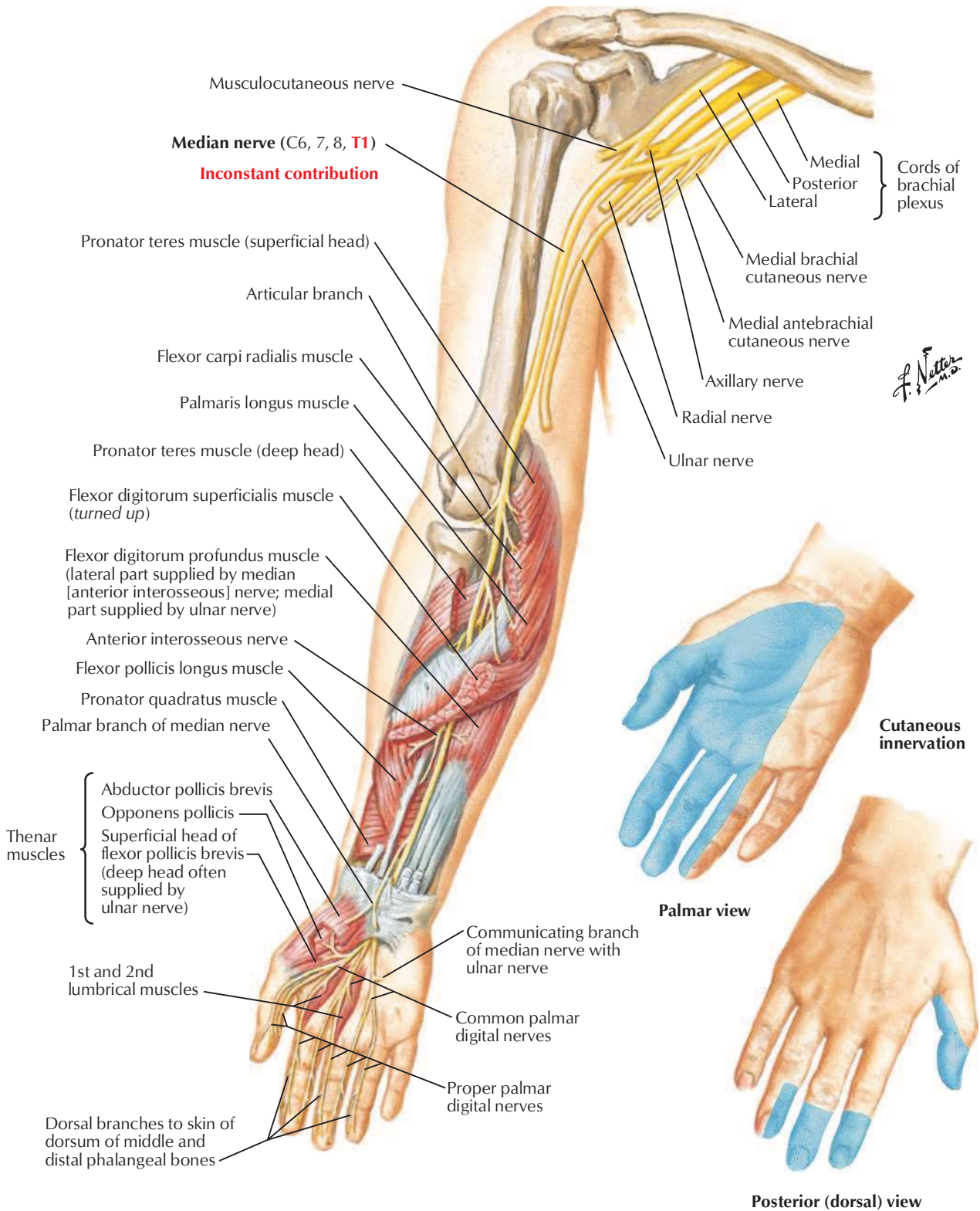
Musculocutaneous Nerve: Anterior View

See also [Plate 421](#)

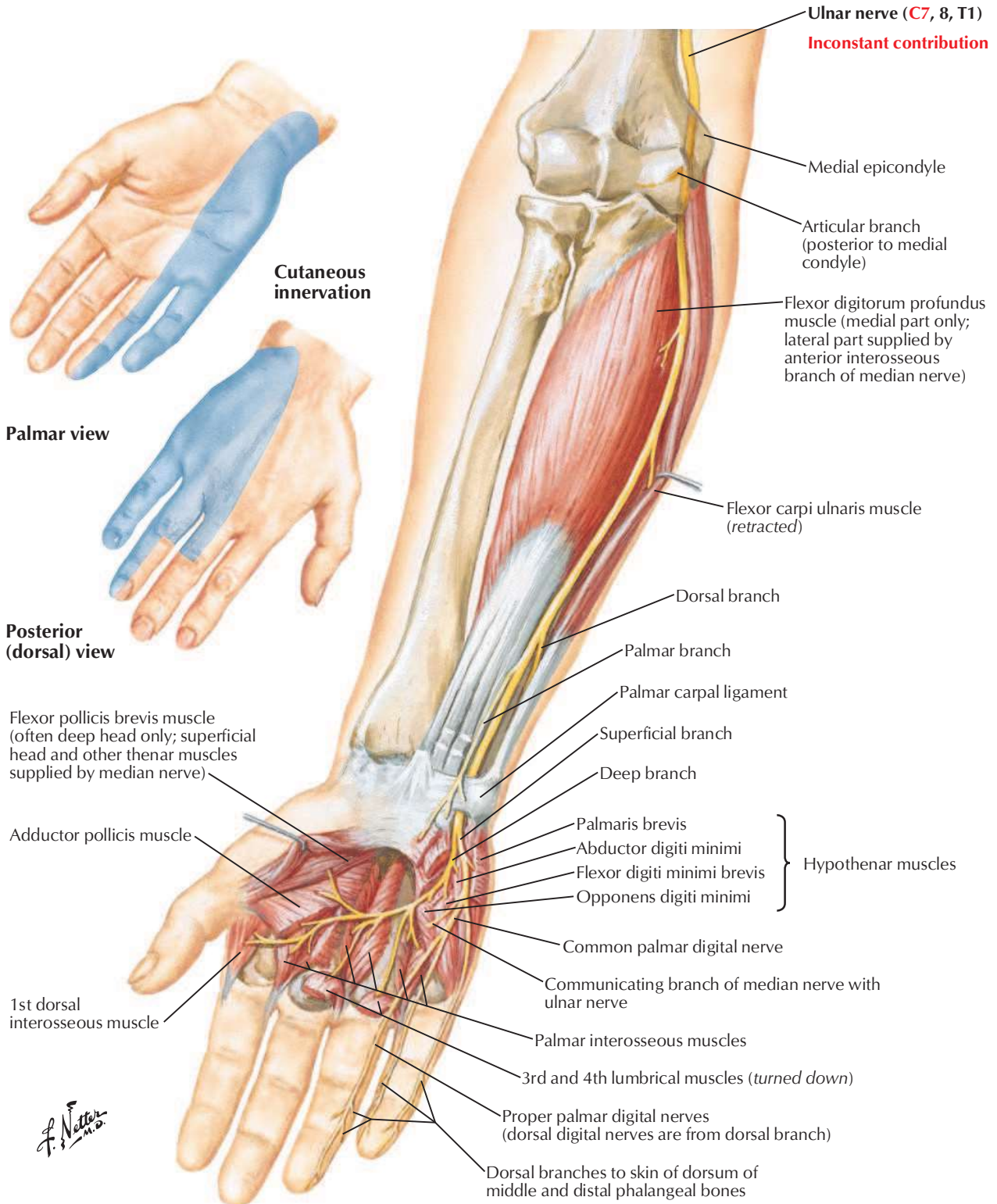
Note: Only muscles innervated by musculocutaneous nerve shown.

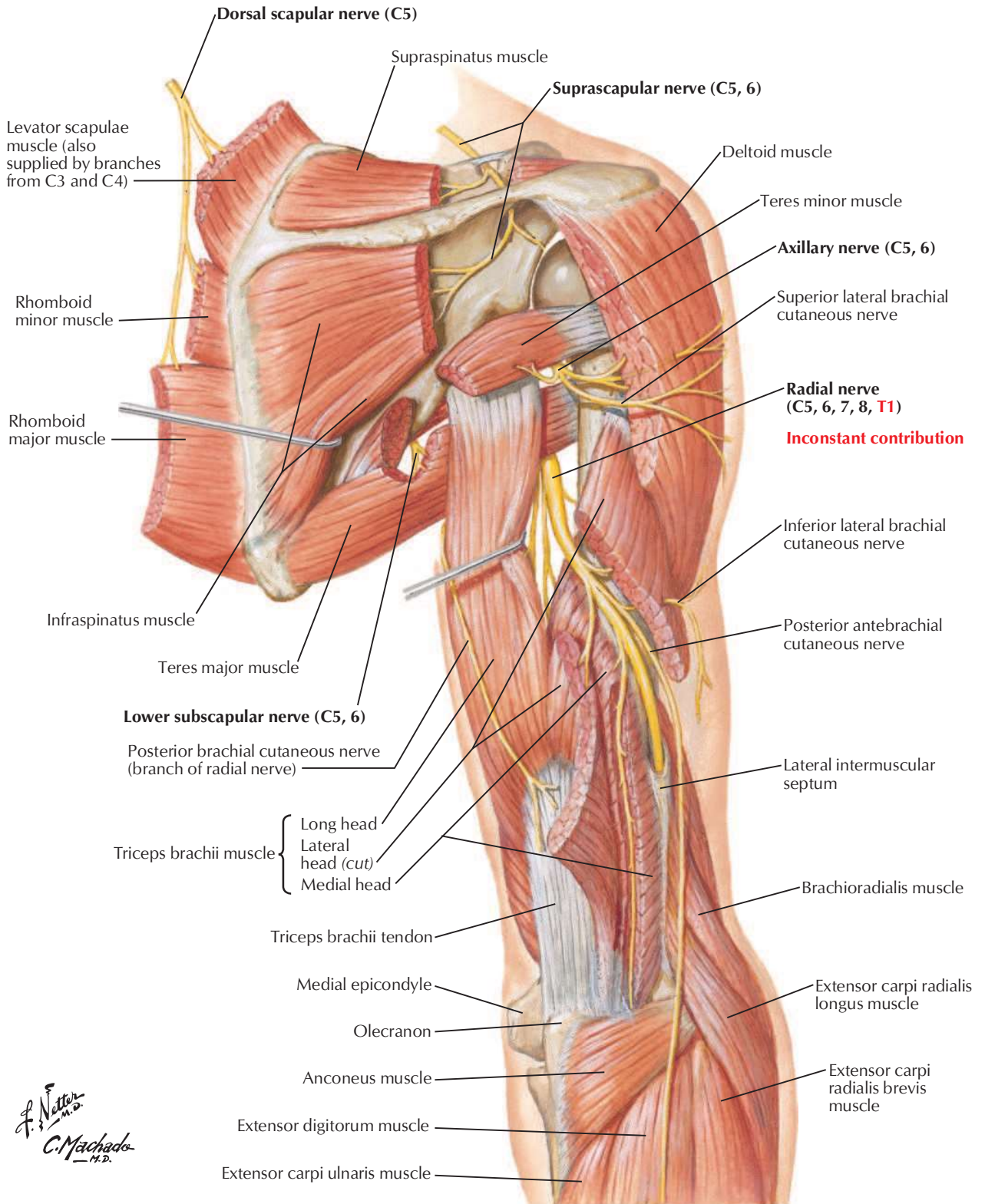


Note: Only muscles innervated by median nerve shown.



Note: Only muscles innervated by ulnar nerve shown.

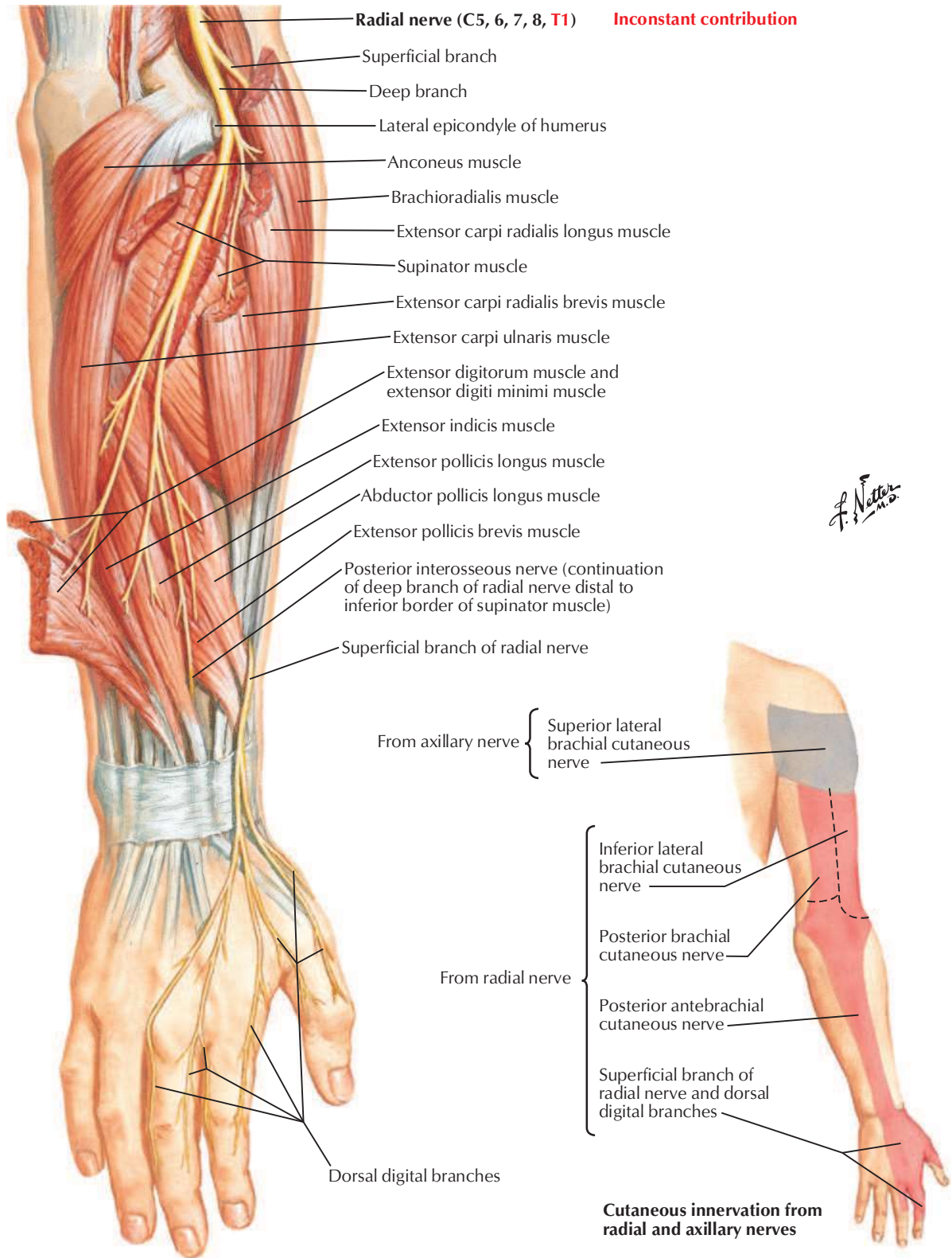




F. Netter M.D.
C. Machado M.D.

Radial Nerve in Forearm and Hand

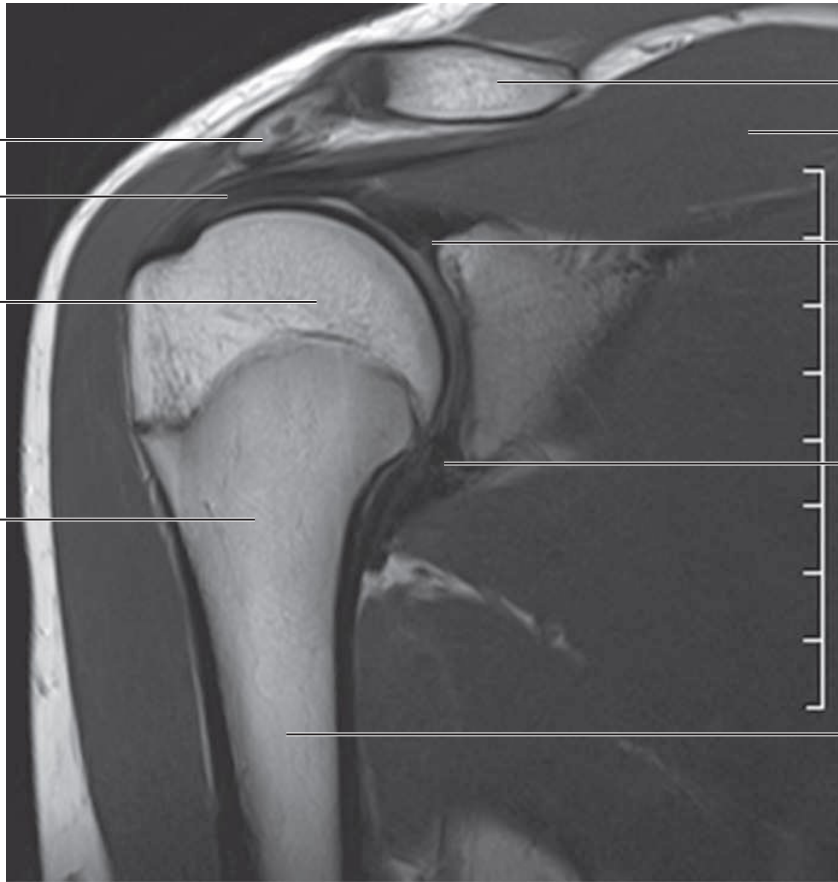
See also [Plates 434, 457](#)



See also [Plates 245, 412](#)

Coronal Proton-Density MRI of Glenohumeral Joint

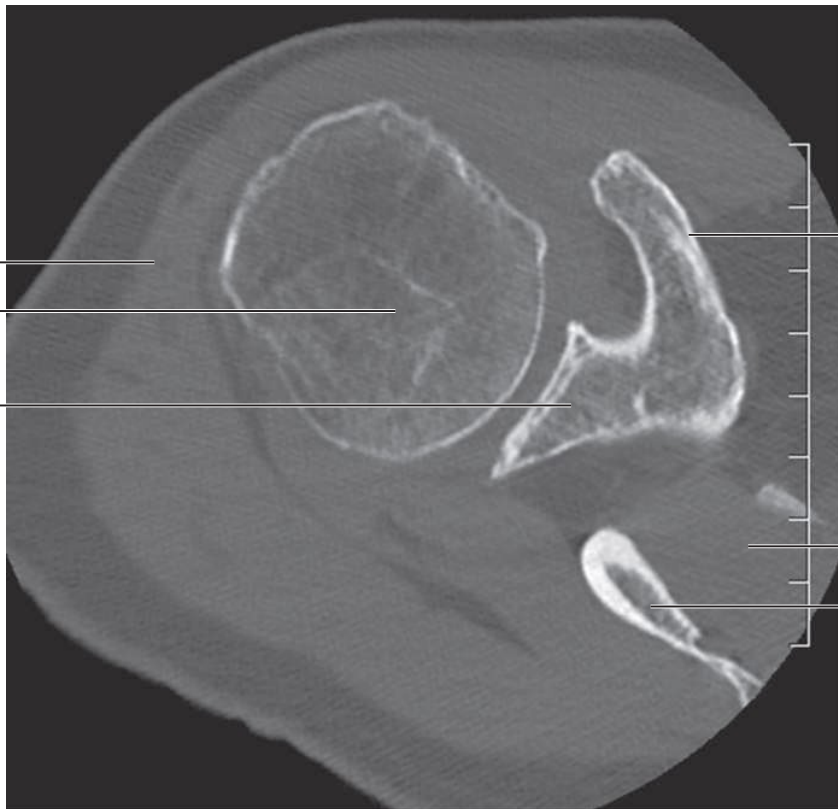
- Acromion
- Supraspinatus tendon
- Head of humerus
- Surgical neck



- Clavicle
- Supraspinatus muscle
- Glenoid labrum
- Glenoid labrum
- Humerus

Axial CT Image of Glenohumeral Joint


- Deltoid muscle
- Head of humerus
- Glenoid fossa



- Coracoid process
- Supraspinatus muscle
- Spine of scapula

ANATOMICAL STRUCTURES	CLINICAL IMPORTANCE	PLATE NUMBERS
 SKELETAL SYSTEM		
Clavicle	Most clavicular fractures are caused from a fall on an outstretched arm or direct trauma delivered to the lateral side of the shoulder. Middle third of the clavicle is most commonly fractured due to the changing bony morphology of the clavicle, its strutlike function, and ligament attachments.	408, 409
Humerus	The proximal humerus, especially the surgical neck, is fractured due to low-energy falls in the elderly and high-energy trauma in youth. The axillary nerve is in harm's way and the circumflex humeral arteries can be injured. Midshaft fractures are also relatively common and place the radial nerve in harm's way.	409–411
Ulna	Subcutaneous location of olecranon makes it vulnerable to fracture by direct trauma, especially when elbow is flexed; ulnar styloid process may also be fractured in distal radial fractures	426, 429
Radius	Fractures of distal radius are most common fracture of upper extremity, typically caused by fall on outstretched hand	429
Scaphoid	Most commonly fractured carpal bone; fracture is often due to fall on outstretched hand	439, 440, 442
 MUSCULAR SYSTEM		
Rotator (compressor) cuff muscles	Injuries to this group of muscles can be from an acute injury or chronic overuse injury leading to common causes of shoulder pain and disability	412, 415, 422
Supraspinatus tendon	Most commonly injured rotator (compressor) cuff muscle tendon complex. Often torn beneath the acromion	415–417, 422
Biceps brachii tendon	Proximally the long head of the biceps tendon tears in the elderly from falls on an outstretched arm, and distally the biceps tendon is used to perform flexor compartment reflex assessing the C5 and C6 spinal nerves	421, 423
Long head of biceps brachii	When long head has been ruptured, it pulls off supraglenoid tubercle and retracts down into arm; muscle bulges (Popeye deformity) at midshaft of humerus	421
Posterior forearm muscles	Repetitive use of muscles arising from common extensor origin can damage tendons and produce pain over lateral epicondyle, associated with tennis elbow	431
Anterior forearm muscles	Repetitive use of muscles arising from common flexor origin can damage tendons and produce pain over medial epicondyle, associated with golfer's elbow	432, 433
 NERVOUS SYSTEM		
Long thoracic nerve	Injury may produce "winged scapula" caused by denervation of serratus anterior	417, 419
Axillary nerve	Position of nerve close to medial aspect of humeral head makes it vulnerable to injury with fractures of surgical neck of humerus or humeral dislocations	422
Median nerve	Commonly compressed in carpal tunnel, producing pain and paresthesia in lateral three and one-half digits	450, 466
Recurrent branch of median nerve	May be injured in superficial lacerations of palm over thenar eminence	449
Ulnar nerve	Vulnerable to compression or injury where it passes posterior to medial epicondyle of humerus, and at wrist in ulnar tunnel (Guyon's canal)	463, 467
Radial nerve	Vulnerable to compression or injury where it lies against humerus in radial groove (e.g., with humeral fracture); common symptom is "wrist drop" due to weakness of wrist extensors	468, 469

Table 7.1

ANATOMICAL STRUCTURES	CLINICAL IMPORTANCE	PLATE NUMBERS
 CARDIOVASCULAR SYSTEM		
Median cubital vein	Accessed in cubital fossa for venipuncture	405
Suprascapular, dorsal scapular, and circumflex scapular arteries	Provide collateral circulation around scapula, allowing blood to reach distal part of upper extremity if axillary artery is blocked or compressed	418
Brachial artery	Palpated in cubital fossa to assess brachial pulse prior to taking blood pressure measurement	423, 424
Radial artery	Palpated at lateral aspect of wrist to assess radial pulse	424

*Selections were based largely on clinical data as well as commonly covered clinical correlations in gross anatomy courses.

MUSCLE	MUSCLE GROUP	PROXIMAL ATTACHMENT (ORIGIN)	DISTAL ATTACHMENT (INSERTION)	INNERVATION	BLOOD SUPPLY	MAIN ACTIONS
Abductor digiti minimi	Hand	Pisiform bone and tendon of flexor carpi ulnaris	Medial side of base of proximal phalanx of little finger (5th digit)	Ulnar nerve (deep branch)	Deep palmar branch of ulnar artery	Abducts little finger
Abductor pollicis brevis	Hand	Flexor retinaculum, tubercles of scaphoid and trapezium bones	Base of proximal phalanx of thumb	Median nerve (recurrent branch)	Superficial palmar branch of radial artery	Abducts thumb
Abductor pollicis longus	Posterior forearm	Posterior surface of ulna, radius, and interosseous membrane	Base of 1st metacarpal	Radial nerve (posterior interosseous)	Posterior interosseous artery	Abducts and extends thumb at carpometacarpal joint
Adductor pollicis	Hand	<i>Oblique head:</i> bases of 2nd and 3rd metacarpals and capitate bone and adjacent bones <i>Transverse head:</i> anterior surface of 3rd metacarpal	Base of proximal phalanx of thumb	Ulnar nerve (deep branch)	Deep palmar arch	Adducts thumb
Anconeus	Arm	Posterior surface of lateral epicondyle of humerus	Lateral surface of olecranon and posterior proximal ulna	Radial nerve	Deep brachial artery	Assists triceps brachii in extending elbow, abducts ulna in pronation
Biceps brachii	Arm	<i>Long head:</i> supraglenoid tubercle of scapula <i>Short head:</i> coracoid process of scapula	Radial tuberosity, fascia of forearm via bicipital aponeurosis	Musculocutaneous nerve	Muscular branches of brachial artery	Flexes and supinates forearm at elbow
Brachialis	Arm	Distal half of anterior surface of humerus	Coronoid process and tuberosity of ulna	Musculocutaneous nerve and radial nerve	Radial recurrent artery, muscular branches of brachial artery	Flexes forearm at elbow
Brachioradialis	Posterior forearm	Proximal 2/3 of lateral supracondylar ridge of humerus	Lateral side of distal end of radius	Radial nerve	Radial recurrent artery	Weak flexion of forearm when forearm is midpronated
Coracobrachialis	Arm	Coracoid process of scapula	Middle third of medial surface of humerus	Musculocutaneous nerve	Muscular branches of brachial artery	Flexes and adducts arm at shoulder
Deltoid	Shoulder	Lateral third of clavicle, acromion, spine of scapula	Deltoid tuberosity of humerus	Axillary nerve	Posterior circumflex humeral artery, deltoid branch of thoracoacromial artery	<i>Clavicular part:</i> flexes and medially rotates arm <i>Acromial part:</i> abducts arm beyond initial 15 degrees done by supraspinatus <i>Spinous part:</i> extends and laterally rotates arm
Dorsal interosseous muscles	Hand	Sides of two adjacent metacarpal bones	Base of proximal phalangeal bones, extensor expansion of digits 2–4	Ulnar nerve (deep branch)	Deep palmar arch	Abduct digits; flex digits at metacarpophalangeal joint and extend interphalangeal joints
Extensor carpi radialis brevis	Posterior forearm	Lateral epicondyle of humerus	Base of 3rd metacarpal and slip to 2nd metacarpal	Radial nerve (deep branch)	Radial artery, radial recurrent artery	Extends and abducts hand at wrist
Extensor carpi radialis longus	Posterior forearm	Distal third of lateral supracondylar ridge of humerus	Base of 2nd metacarpal and slip to 3rd metacarpal	Radial nerve	Radial artery, radial recurrent artery	Extends and abducts hand at wrist
Extensor carpi ulnaris	Posterior forearm	Lateral epicondyle of humerus and posterior border of ulna	Base of 5th metacarpal	Radial nerve (posterior interosseous nerve)	Posterior interosseous artery	Extends and adducts hand at wrist

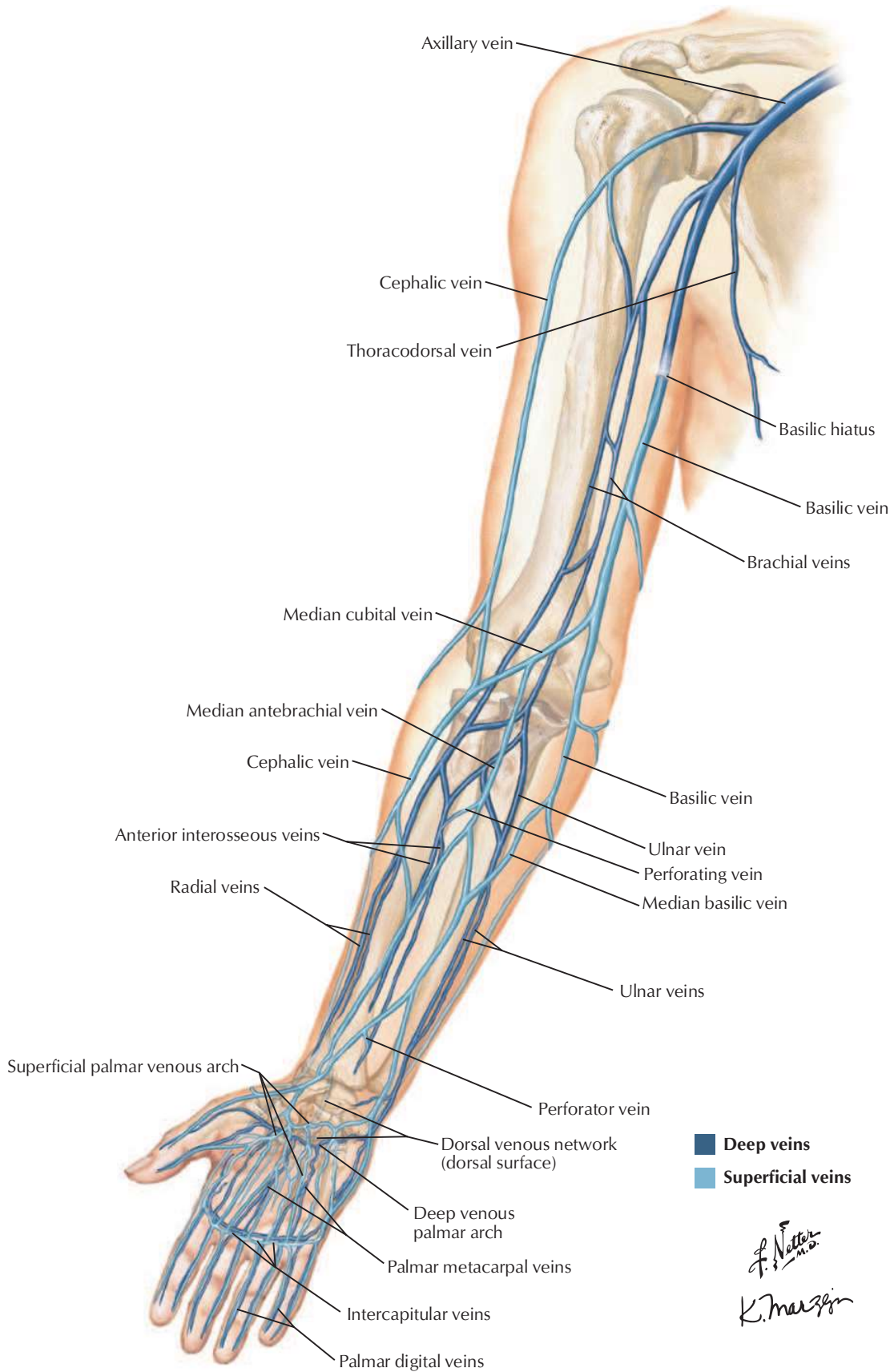
Variations in spinal nerve contributions to the innervation of muscles, their arterial supply, their attachments, and their actions are common themes in human anatomy. Therefore, expect differences between texts and realize that anatomical variation is normal.

MUSCLE	MUSCLE GROUP	PROXIMAL ATTACHMENT (ORIGIN)	DISTAL ATTACHMENT (INSERTION)	INNERVATION	BLOOD SUPPLY	MAIN ACTIONS
Extensor digiti minimi	Posterior forearm	Lateral epicondyle of humerus	Extensor expansion of 5th digit	Radial nerve (posterior interosseous nerve)	Posterior interosseous artery	Extends 5th digit
Extensor digitorum	Posterior forearm	Lateral epicondyle of humerus	Extensor expansions of medial four digits	Radial nerve (posterior interosseous nerve)	Posterior interosseous artery	Extends medial four digits, assists in wrist extension
Extensor indicis	Posterior forearm	Posterior surface of ulna and interosseous membrane	Extensor expansion of 2nd digit	Radial nerve (posterior interosseous nerve)	Posterior interosseous artery	Extends 2nd digit and helps extend hand at wrist
Extensor pollicis brevis	Posterior forearm	Posterior surface of radius and interosseous membrane	Dorsal base of proximal phalanx of thumb	Radial nerve (posterior interosseous nerve)	Posterior interosseous artery	Extends proximal phalanx of thumb at carpometacarpal joint
Extensor pollicis longus	Posterior forearm	Posterior surface of middle third of ulna, interosseous membrane	Dorsal base of distal phalanx of thumb	Radial nerve (posterior interosseous nerve)	Posterior interosseous artery	Extends distal phalanx of thumb at interphalangeal and metacarpophalangeal joints
Flexor carpi radialis	Anterior forearm	Medial epicondyle of humerus	Base of 2nd metacarpal	Median nerve	Radial artery	Flexes and abducts hand at wrist
Flexor carpi ulnaris	Anterior forearm	<i>Superficial head:</i> medial epicondyle of humerus <i>Deep head:</i> olecranon and posterior border of ulna	Pisiform bone, hook of hamate bone, base of 5th metacarpal	Ulnar nerve	Posterior ulnar recurrent artery	Flexes and adducts hand at wrist
Flexor digiti minimi brevis	Hand	Flexor retinaculum and hook of hamate bone	Medial side of base of proximal phalanx of little finger	Ulnar nerve (deep branch)	Deep palmar branch of ulnar artery	Flexes proximal phalanx of little finger
Flexor digitorum profundus	Anterior forearm	Medial and anterior surface of proximal 3/4 of ulna and interosseous membrane	Palmar base of distal phalangeal bones of medial four digits	<i>Medial part:</i> ulnar nerve <i>Lateral part:</i> median nerve	Anterior interosseous artery, muscular branches of ulnar artery	Flexes distal phalangeal bones of medial four digits, assists with flexion of hand at wrist
Flexor digitorum superficialis	Anterior forearm	<i>Humero-ulnar head:</i> medial epicondyle of humerus coronoid process of ulna, ulnar collateral ligament <i>Radial head:</i> superior half of anterior radius	Bodies of middle phalangeal bones of medial four digits	Median nerve	Ulnar and radial arteries	Flexes middle and proximal phalangeal bones of medial four digits, flexes hand at wrist
Flexor pollicis brevis	Hand	Flexor retinaculum and tubercle of trapezium bone	Lateral side of base of proximal phalanx of thumb	Median nerve (recurrent branch)	Superficial palmar branch of radial artery	Flexes proximal phalanx of thumb
Flexor pollicis longus	Anterior forearm	Anterior surface of radius and interosseous membrane	Palmar base of distal phalanx of thumb	Median nerve (anterior interosseous nerve)	Anterior interosseous artery	Flexes phalangeal bones of thumb
Infraspinatus	Shoulder	Infraspinous fossa of scapula and deep fascia	Greater tubercle of humerus	Suprascapular nerve	Suprascapular artery	Lateral rotation of arm
Latissimus dorsi	Shoulder	Spinous processes of T7–L5, thoracolumbar fascia, iliac crest, and last three ribs	Intertubercular sulcus of humerus	Thoracodorsal nerve	Thoracodorsal artery, dorsal perforating branches of 9th, 10th, and 11th posterior intercostal, subcostal, and first three lumbar arteries	Extends, adducts, and medially rotates humerus
Levator scapulae	Superficial back	Posterior tubercles of transverse processes of C1–C4	Medial border of scapula from superior angle to spine	Anterior rami of C3–C4 and dorsal scapular nerve	Dorsal scapular artery, transverse cervical artery, ascending cervical artery	Elevates scapula medially, inferiorly rotates glenoid fossa
Lumbrical, first and second	Hand	Lateral two tendons of flexor digitorum profundus	Lateral sides of extensor expansion of digits 2 and 3	Median nerve (digital branches)	Superficial and deep palmar arches	Extend digits at interphalangeal joints, flex metacarpophalangeal joints

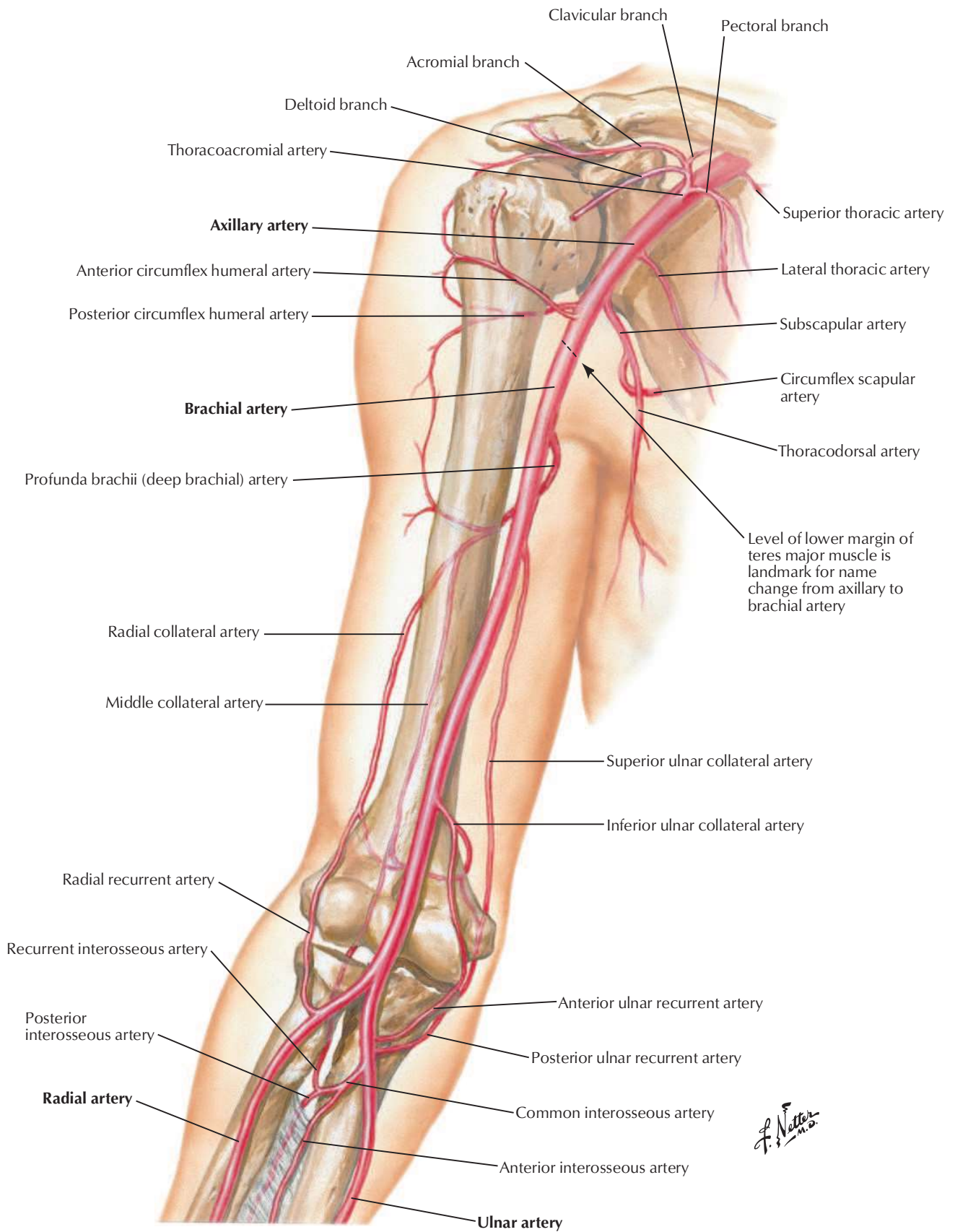
MUSCLE	MUSCLE GROUP	PROXIMAL ATTACHMENT (ORIGIN)	DISTAL ATTACHMENT (INSERTION)	INNERVATION	BLOOD SUPPLY	MAIN ACTIONS
Lumbrical, third and fourth	Hand	Medial three tendons of flexor digitorum profundus	Lateral sides of extensor expansion of digits 4 and 5	Ulnar nerve (deep branch)	Superficial and deep palmar arches	Extend digits at interphalangeal joints, flex metacarpophalangeal joints
Opponens digiti minimi	Hand	Flexor retinaculum and hook of hamate bone	Palmar surface of 5th metacarpal	Ulnar nerve (deep branch)	Deep palmar branch of ulnar artery	Draws 5th metacarpal anteriorly and rotates it to face thumb
Opponens pollicis	Hand	Flexor retinaculum and tubercle of trapezium bone	Lateral side of 1st metacarpal	Median nerve (recurrent branch)	Superficial palmar branch of radial artery	Draws 1st metacarpal forward and rotates it medially
Palmar interosseous muscles	Hand	Sides of metacarpal bones 2, 4, and 5	Bases of proximal phalanx and extensor expansion of digits 2, 4, and 5	Ulnar nerve (deep branch)	Deep palmar arch	Adducts digits; flexes digits and extends interphalangeal joints
Palmaris brevis	Hand	Palmar aponeurosis and flexor retinaculum	Skin of medial border of palm	Superficial branch of ulnar nerve	Superficial palmar arch	Deepens hollow of hand, assists grip
Palmaris longus	Anterior forearm	Medial epicondyle of humerus	Distal half of flexor retinaculum and palmar aponeurosis	Median nerve	Posterior ulnar recurrent artery	Flexes hand at wrist and tenses palmar aponeurosis
Pectoralis major	Pectoral/axillary regions	Sternal half of clavicle, sternum to 7th rib, cartilages of true ribs, aponeurosis of external abdominal oblique muscle	Lateral lip of intertubercular sulcus of humerus	Medial and lateral pectoral nerves	Pectoral branch of thoracoacromial artery, perforating branches of internal thoracic artery	Flexes, adducts, and medially rotates arm
Pectoralis minor	Pectoral/axillary regions	Outer surface of upper margin of ribs 3–5	Coracoid process of scapula	Medial pectoral nerve	Pectoral branch of thoracoacromial artery, and superior and lateral thoracic arteries	Lowers lateral angle of scapula and protracts scapula
Pronator quadratus	Anterior forearm	Distal fourth of anterior ulna	Distal fourth of anterior radius	Median nerve (anterior interosseous nerve)	Anterior interosseous artery	Pronates forearm
Pronator teres	Anterior forearm	Two heads: medial epicondyle of humerus and coronoid process of ulna	Midway along lateral surface of radius	Median nerve	Anterior ulnar recurrent artery	Pronates forearm and weakly flexes elbow
Rhomboid major	Superficial back	Spinous processes of T2–T5 vertebrae	Medial border of scapula below base of spine of scapula	Dorsal scapular nerve	Dorsal scapular OR deep branch of transverse cervical artery, dorsal perforating branches of upper five or six posterior intercostal arteries	Fixes scapula to thoracic wall and retracts and rotates it to depress glenoid cavity
Rhomboid minor	Superficial back	Nuchal ligament, spines of C7 and T1 vertebrae	Medial border of scapula at spine of scapula	Dorsal scapular nerve	Dorsal scapular artery OR deep branch of transverse cervical artery, dorsal perforating branches of upper five or six posterior intercostal arteries	Fixes scapula to thoracic wall and retracts and rotates it to depress glenoid cavity
Serratus anterior	Shoulder	Lateral surfaces of upper 8–9 ribs	Costal surface of medial border of scapula	Long thoracic nerve	Lateral thoracic artery	Protracts and rotates scapula and holds it against thoracic wall
Subclavius	Shoulder	Upper border of 1st rib and its cartilage	Inferior surface of middle third of clavicle	Nerve to subclavius	Clavicular branch of thoracoacromial artery	Anchors and depresses clavicle

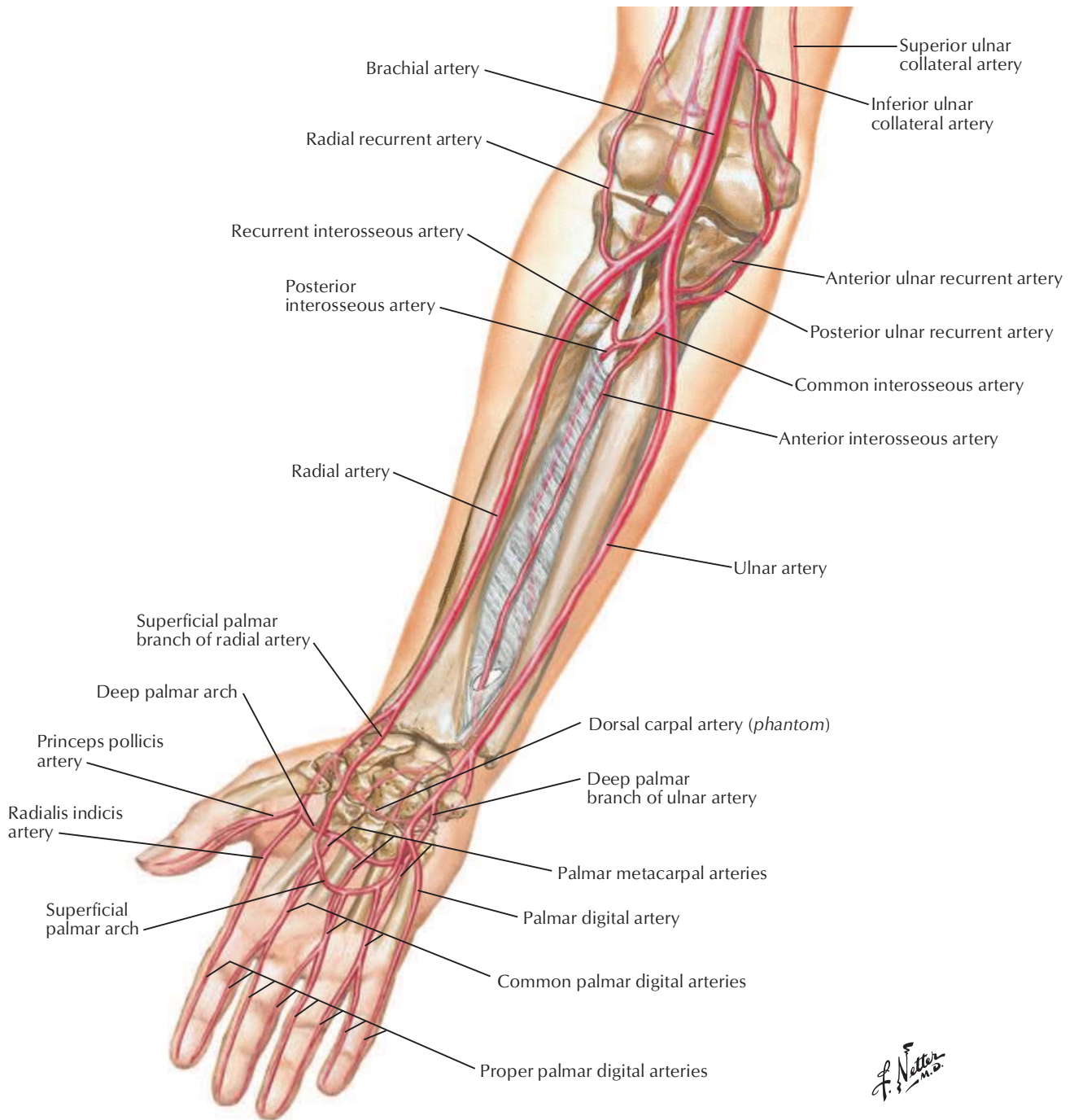
Table 7.5

MUSCLE	MUSCLE GROUP	PROXIMAL ATTACHMENT (ORIGIN)	DISTAL ATTACHMENT (INSERTION)	INNERVATION	BLOOD SUPPLY	MAIN ACTIONS
Subscapularis	Shoulder	Subscapular fossa	Lesser tubercle of humerus	Upper and lower subscapular nerves	Subscapular artery, lateral thoracic artery	Medially rotates and adducts arm; helps hold humeral head in glenoid fossa
Supinator	Posterior forearm	Lateral epicondyle of humerus, radial collateral and annular ligaments, supinator fossa, and crest of ulna	Lateral, posterior, and anterior surfaces of proximal third of radius	Radial nerve (deep branch)	Radial recurrent artery, posterior interosseous arteries	Supinates forearm
Supraspinatus	Shoulder	Supraspinous fossa of scapula and deep fascia	Greater tubercle of humerus	Suprascapular nerve	Suprascapular artery	Initiates arm abduction
Teres major	Shoulder	Posterior surface of inferior angle of scapula	Medial lip of intertubercular sulcus of humerus	Lower subscapular nerve	Circumflex scapular artery	Adducts and medially rotates arm
Teres minor	Shoulder	Upper 2/3 of posterior surface of lateral border of scapula	Inferior facet of greater tubercle of humerus	Axillary nerve	Circumflex scapular artery	Laterally rotates arm
Trapezius	Superficial back	Superior nuchal line, external occipital protuberance, nuchal ligament, spinous processes of C7–T12	Lateral third of clavicle, acromion, and spine of scapula	Accessory nerve (cranial nerve XI)	Transverse cervical artery, dorsal perforating branches of posterior intercostal arteries	Elevates, retracts, and rotates scapula; lower fibers depress scapula
Triceps brachii	Arm	<i>Long head:</i> infraglenoid tubercle of scapula <i>Lateral head:</i> upper half of posterior humerus <i>Medial head:</i> distal 2/3 of medial and posterior humerus	Posterior surface of olecranon process of ulna	Radial nerve	Branch of profunda brachii artery	Extends forearm at elbow; long head stabilizes head of abducted humerus and extends and adducts arm

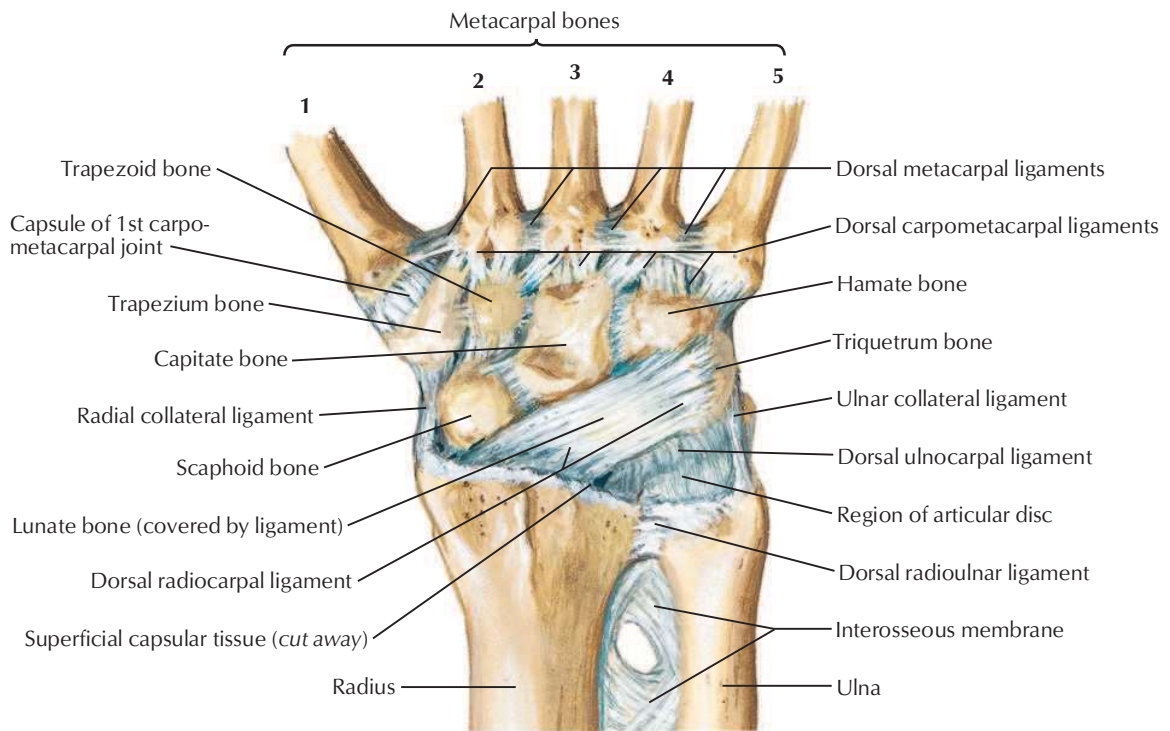


Arteries of Arm and Proximal Forearm

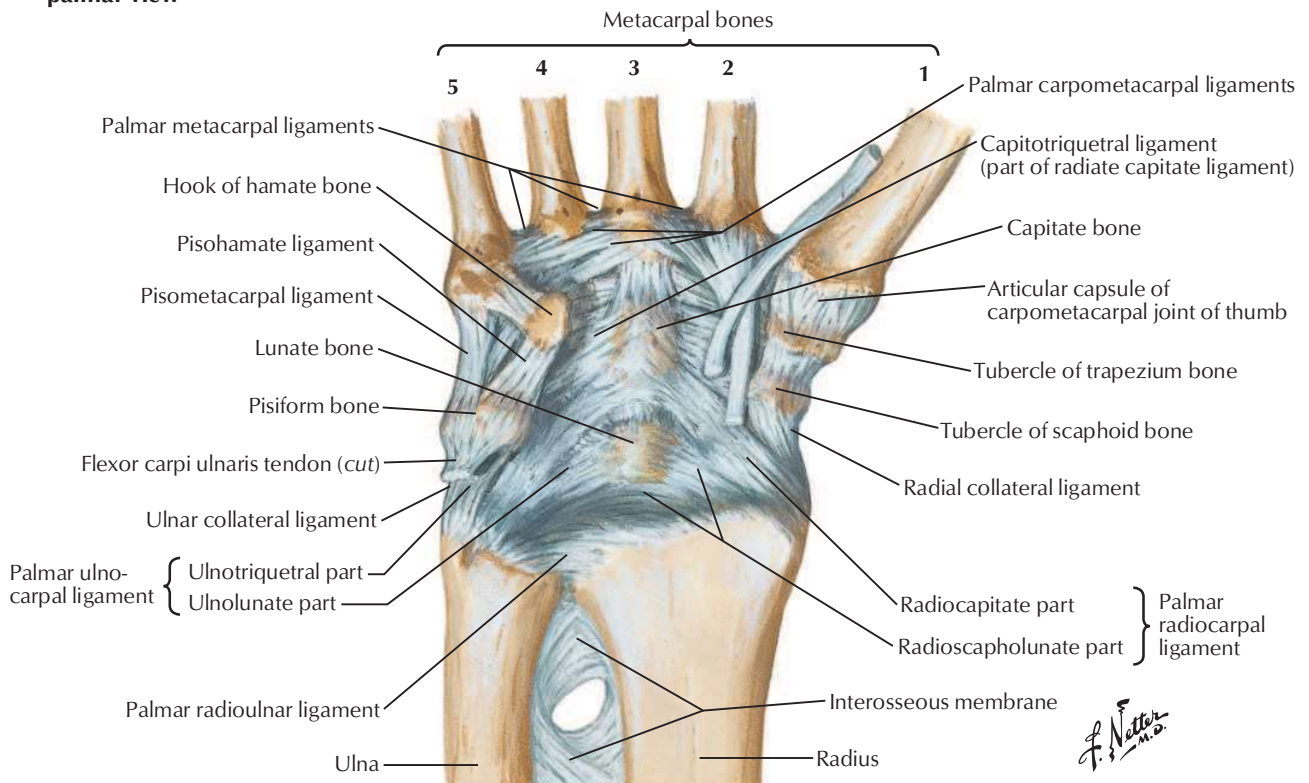




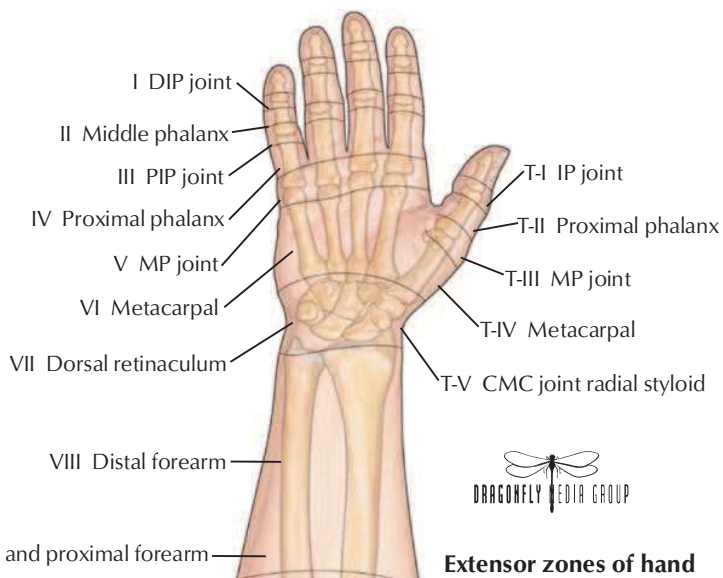
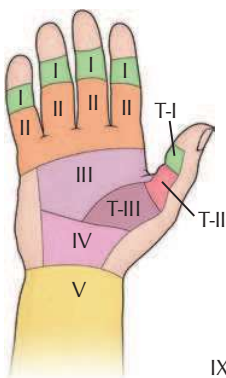
Posterior (dorsal) view



Flexor retinaculum removed: palmar view

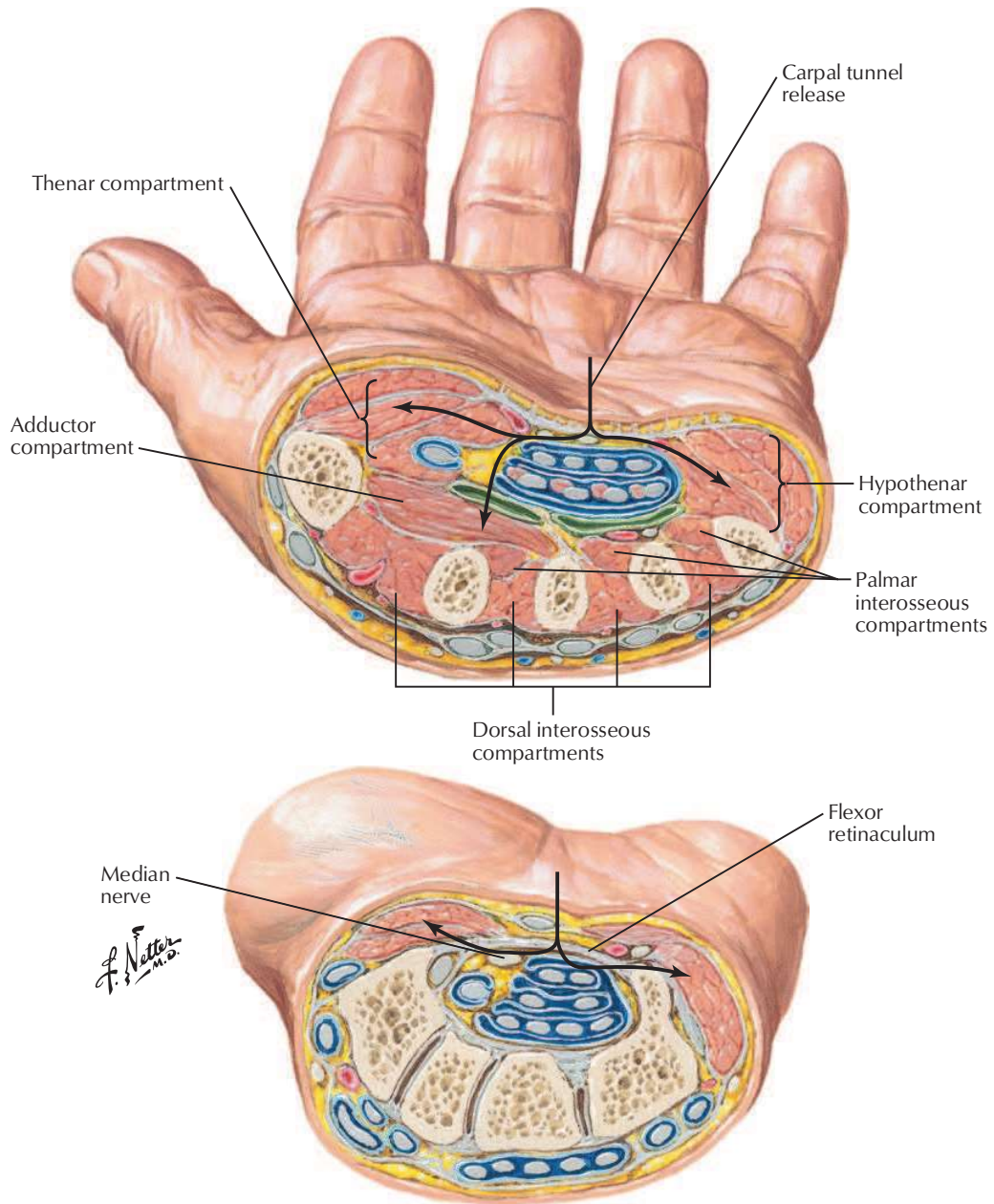


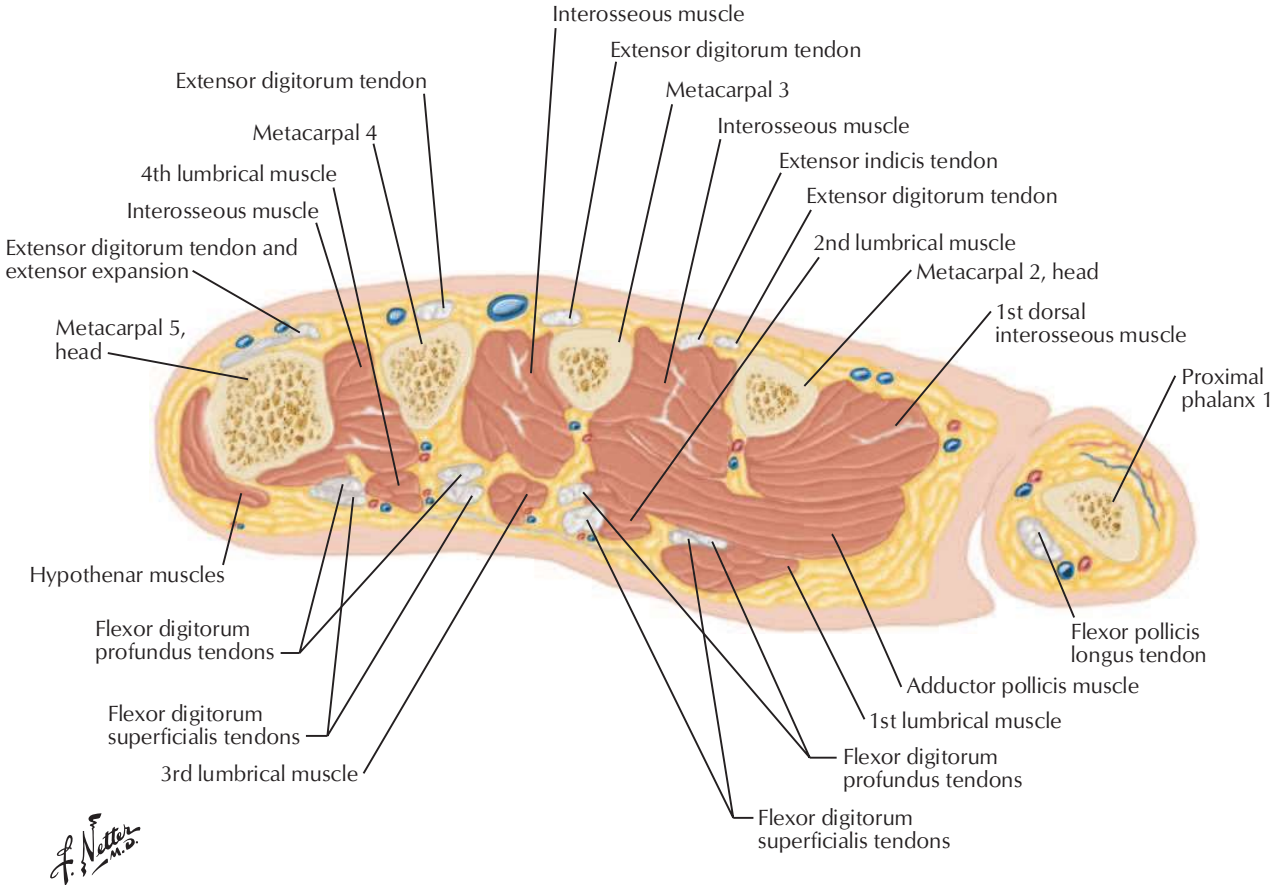
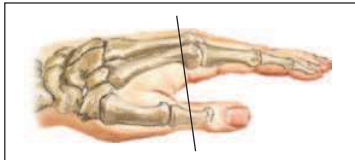
Flexor zones of hand

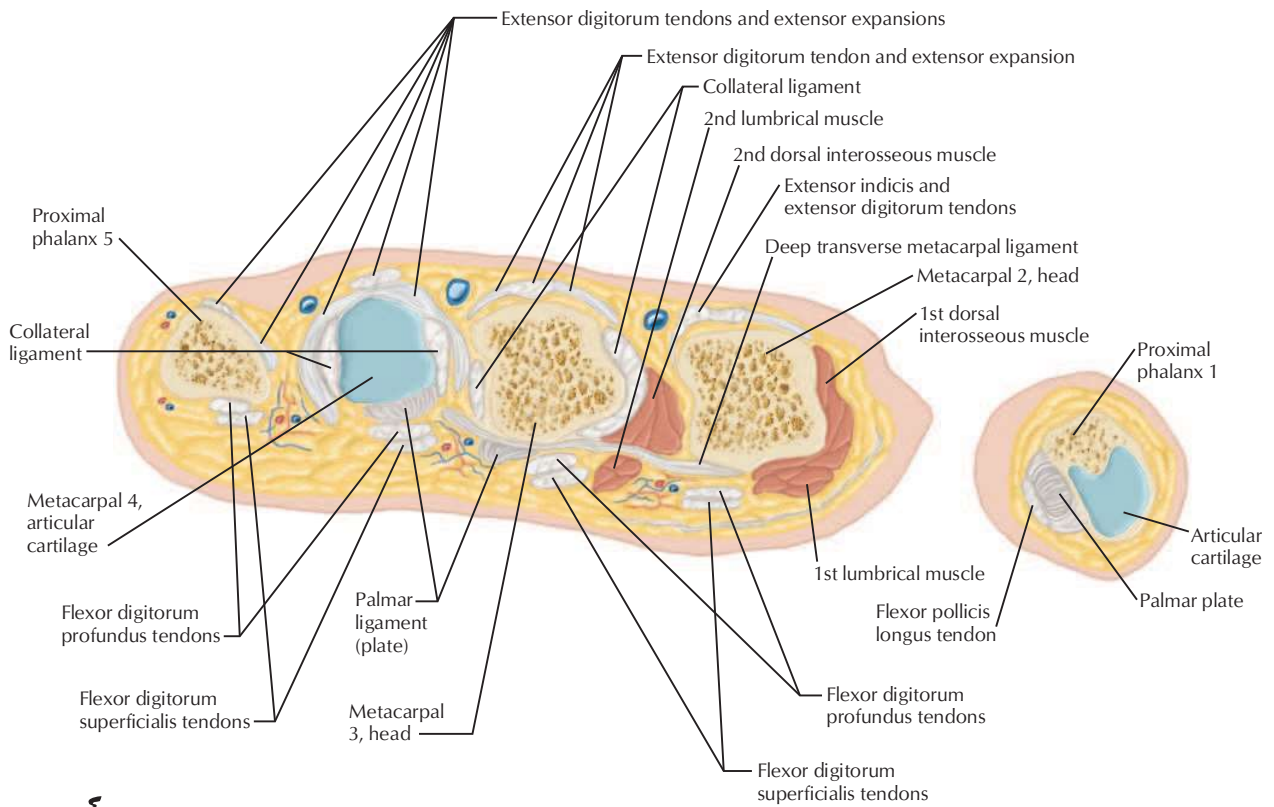
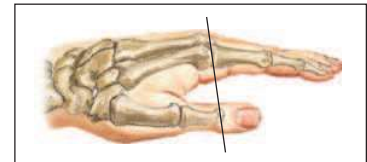


Extensor zones of hand

Section Through Metacarpal and Distal Carpal Bones







This page intentionally left blank

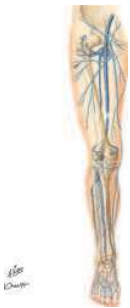LOWER LIMB

8

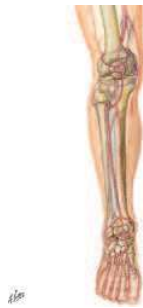Surface Anatomy 471
Cutaneous Anatomy 472-475
Hip and Thigh 476-496
Knee 497-503
Leg 504-514
Ankle and Foot 515-528

Neurovasculature 529-533
Regional Imaging 534-535
Structures with High Clinical Significance Tables 8.1-8.2
Muscle Tables Tables 8.3-8.6
Electronic Bonus Plates BP107-BP117

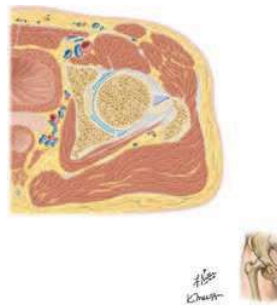ELECTRONIC BONUS PLATES



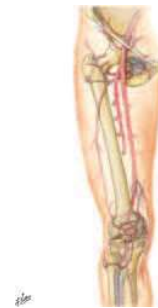BP107 Veins of Lower Limb



BP108 Arteries of Thigh and Knee



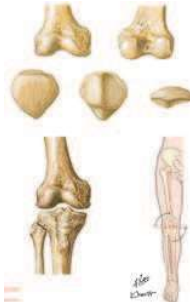BP109 Cross-Sectional Anatomy of Hip: Axial View



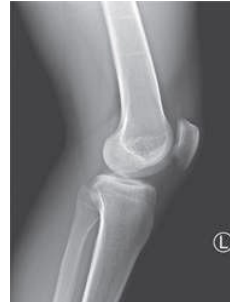BP110 Arteries of Knee and Foot



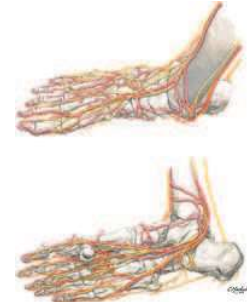
BP111 Leg: Serial Cross Sections



BP112 Osteology of Knee

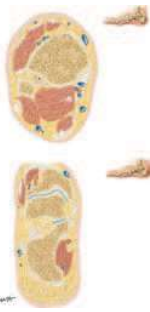

BP113 Knee Radiograph: Lateral View

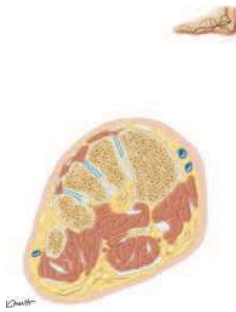

BP114 Anatomy of Foot: Nerves and Arteries

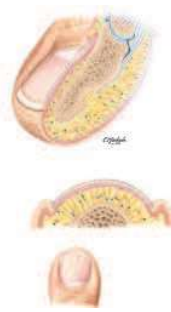
ELECTRONIC BONUS PLATES—*cont'd*



BP115 Cross-Sectional
Anatomy of Ankle and
Foot

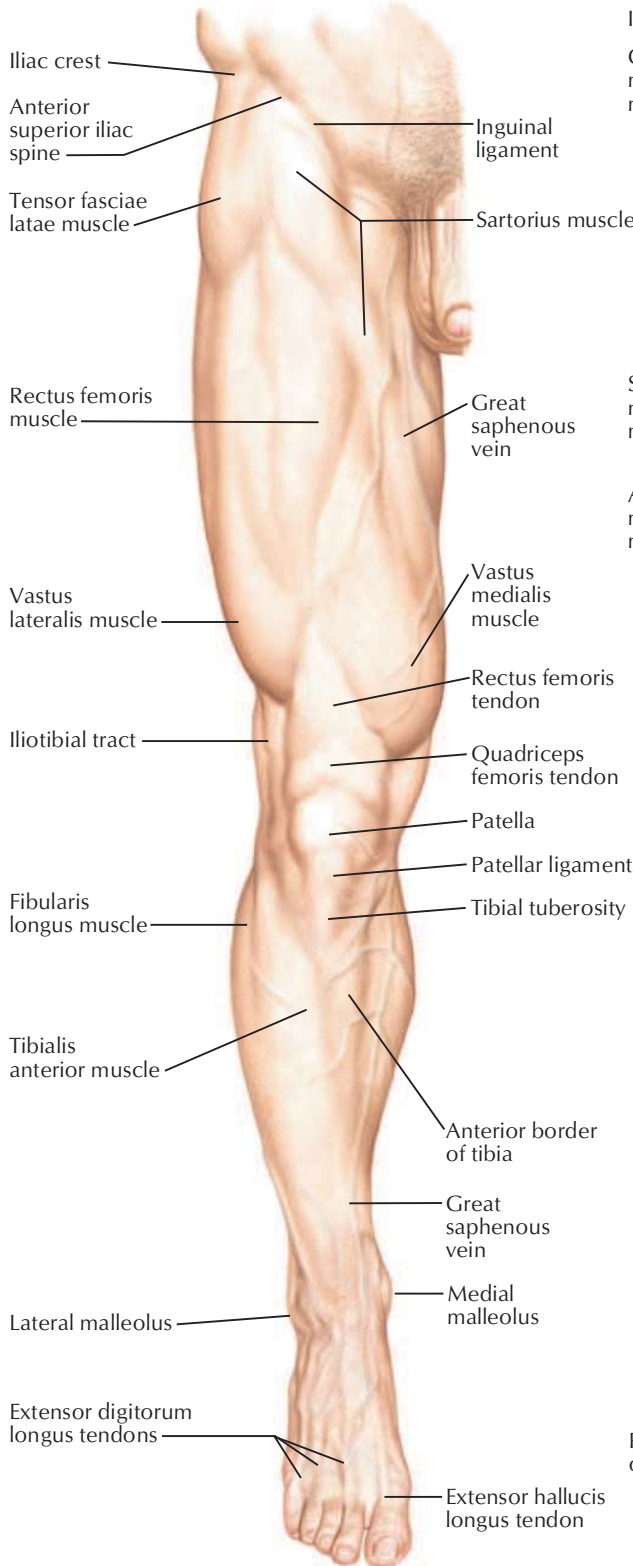


BP116 Cross-Sectional
Anatomy of Ankle and
Foot (continued)

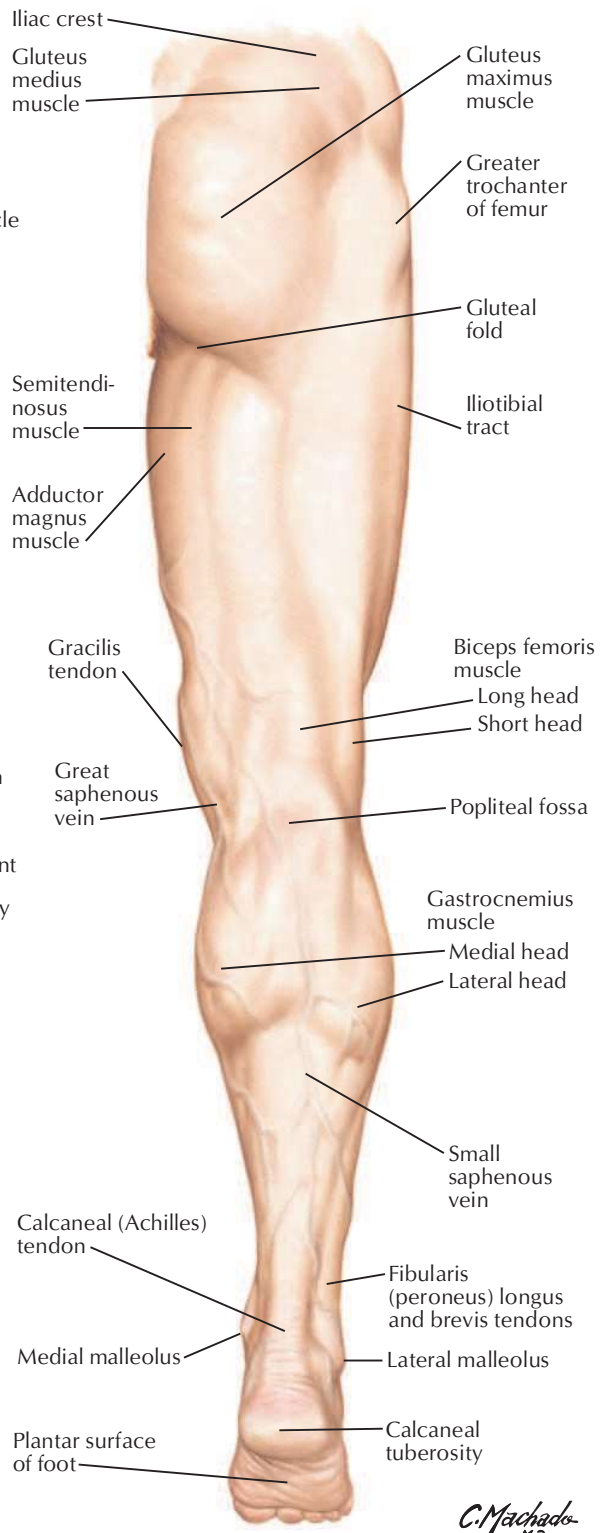


BP117 Anatomy of Toenail

Anterior view



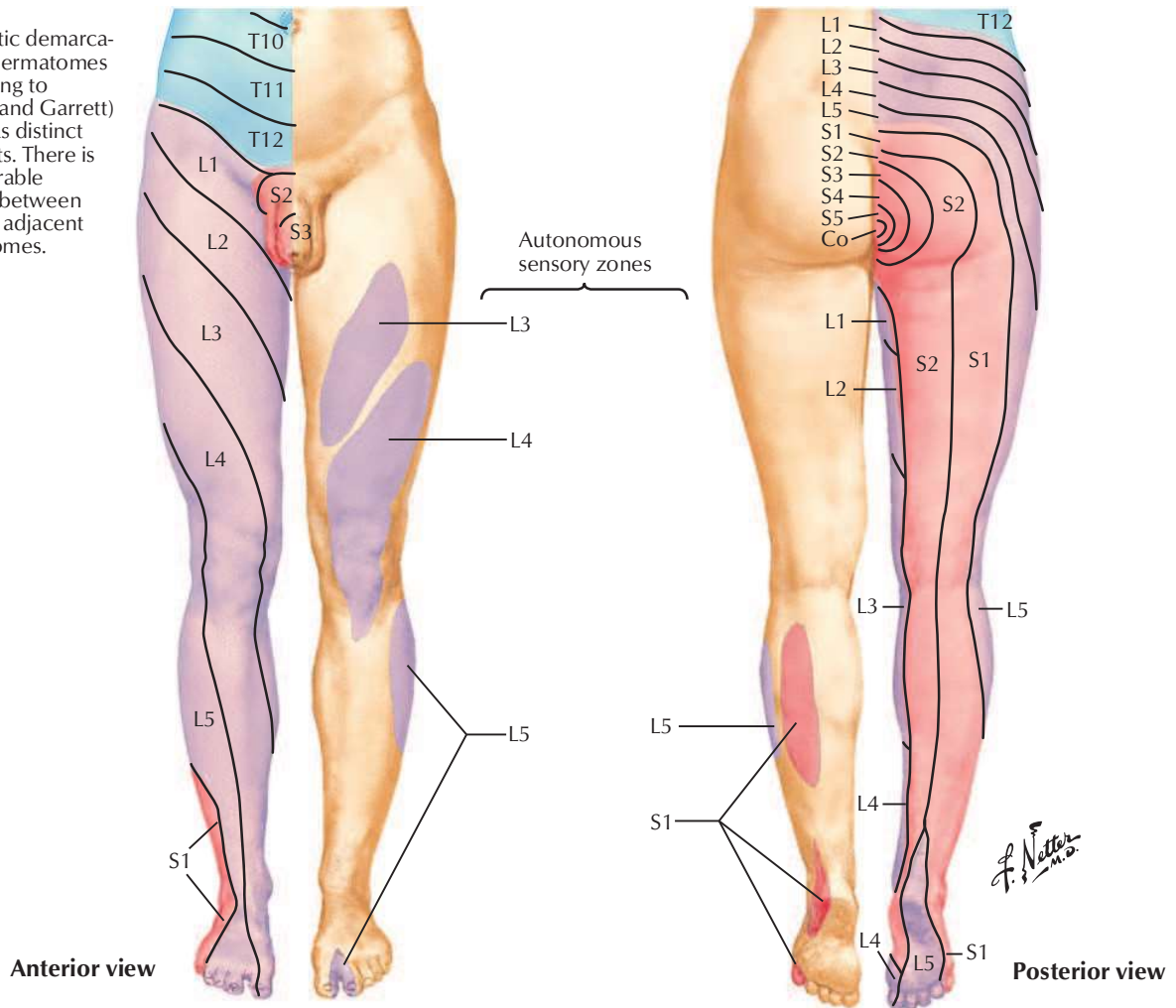
Posterior view



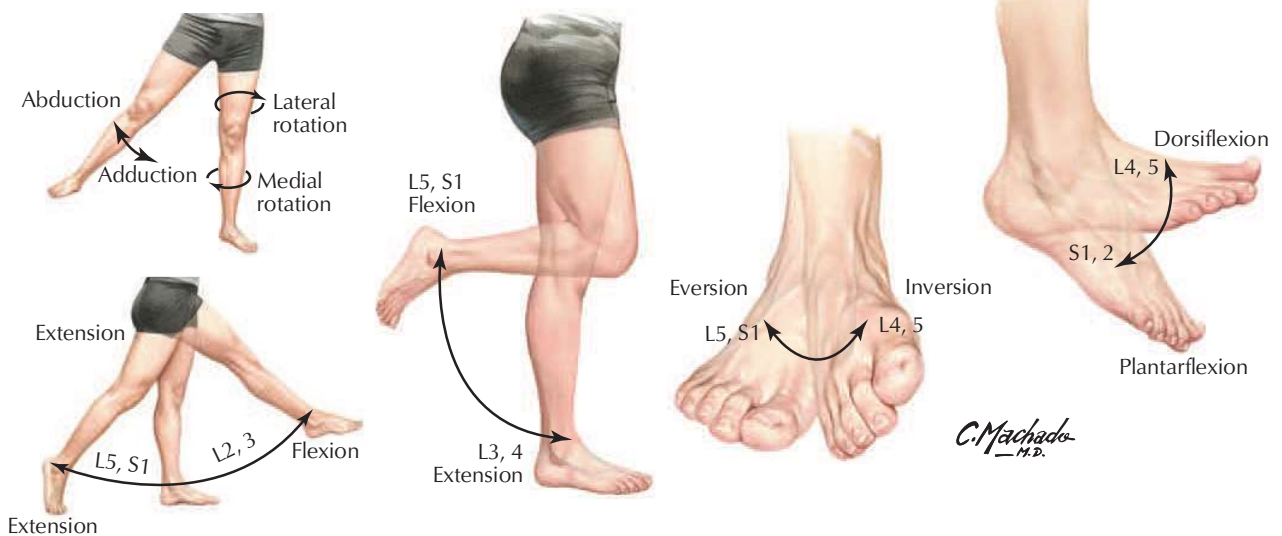
C. Machado
—*MD*

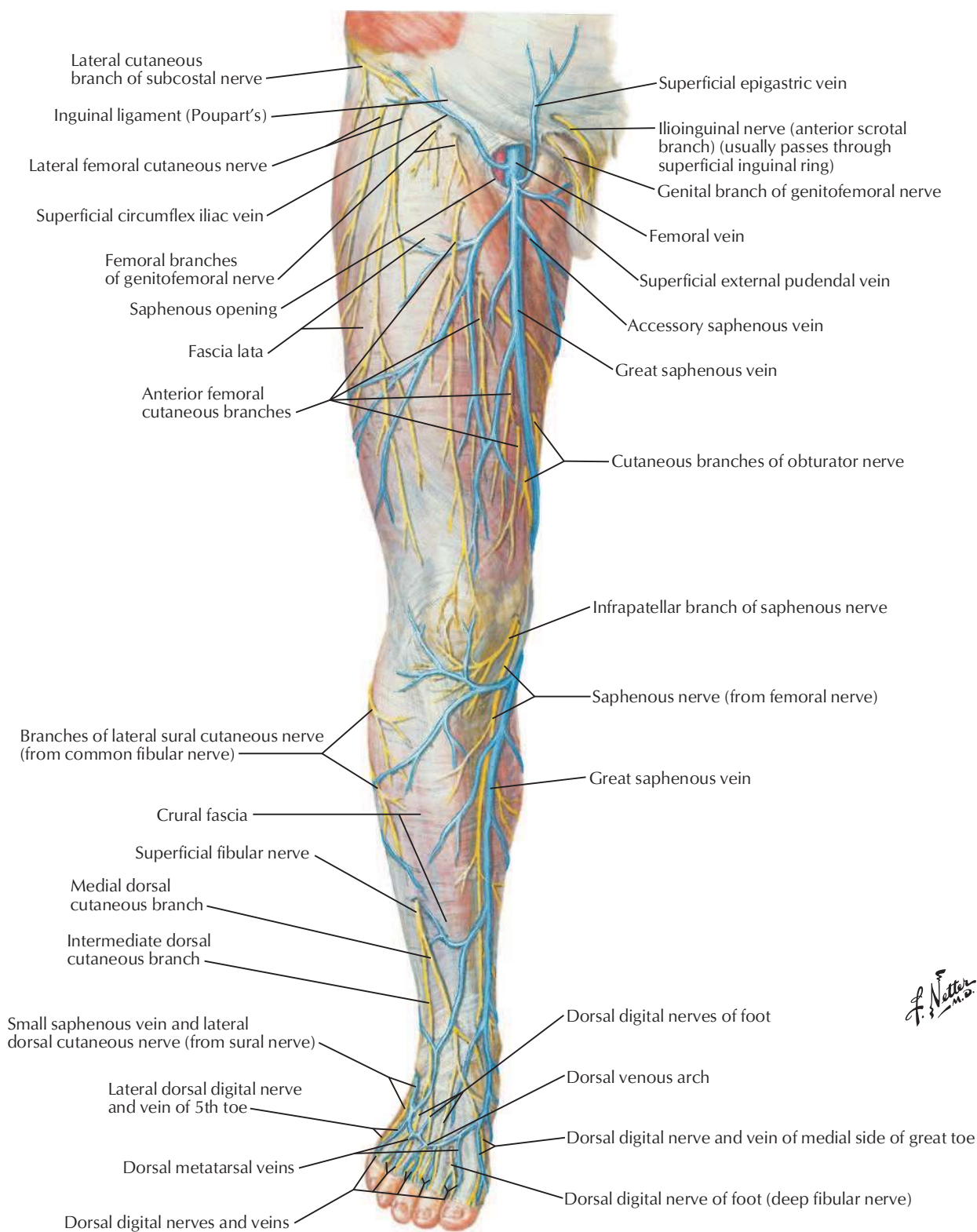
See also [Plate 171](#)

Schematic demarcation of dermatomes (according to Keegan and Garrett) shown as distinct segments. There is considerable overlap between any two adjacent dermatomes.



Segmental innervation of lower limb movements

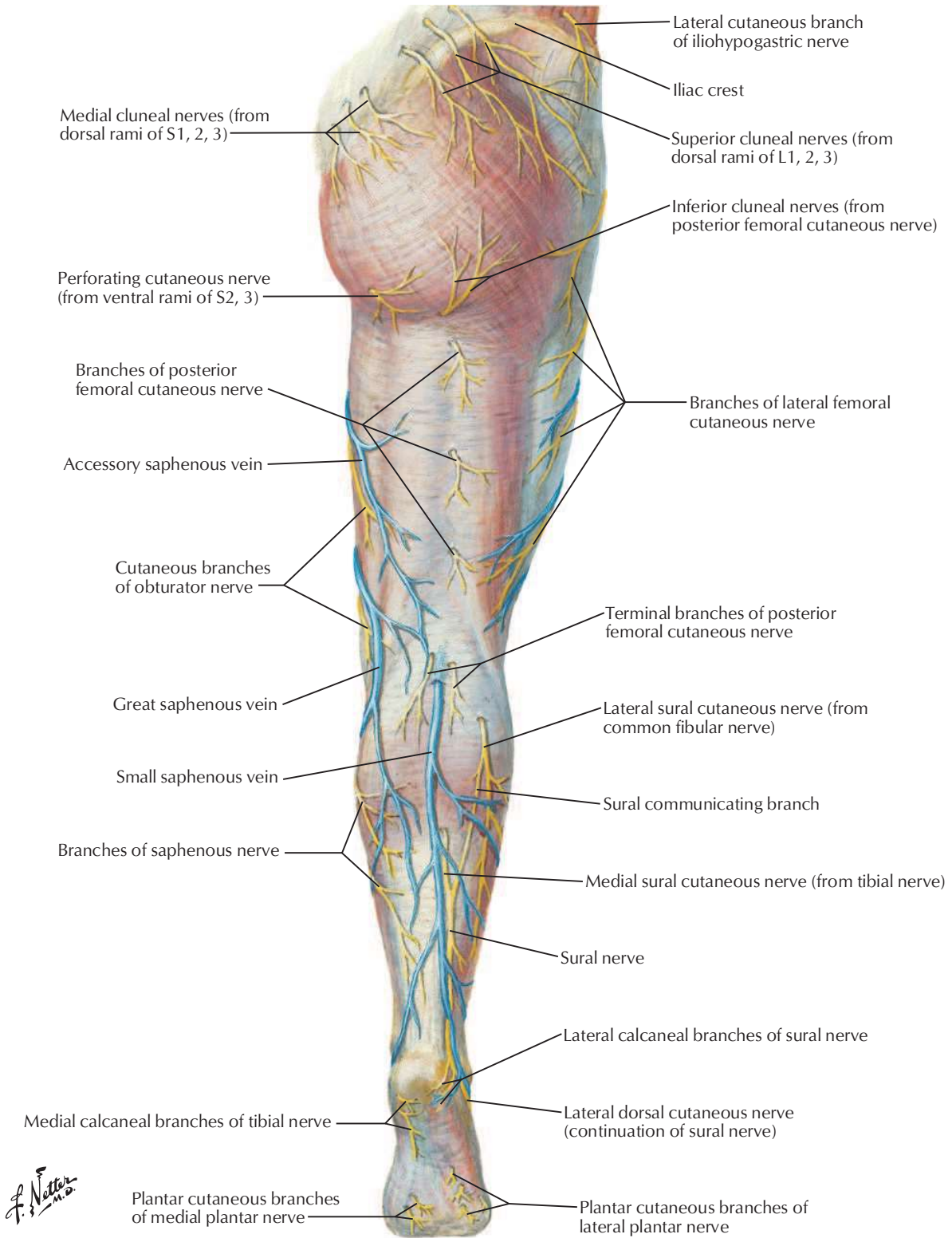


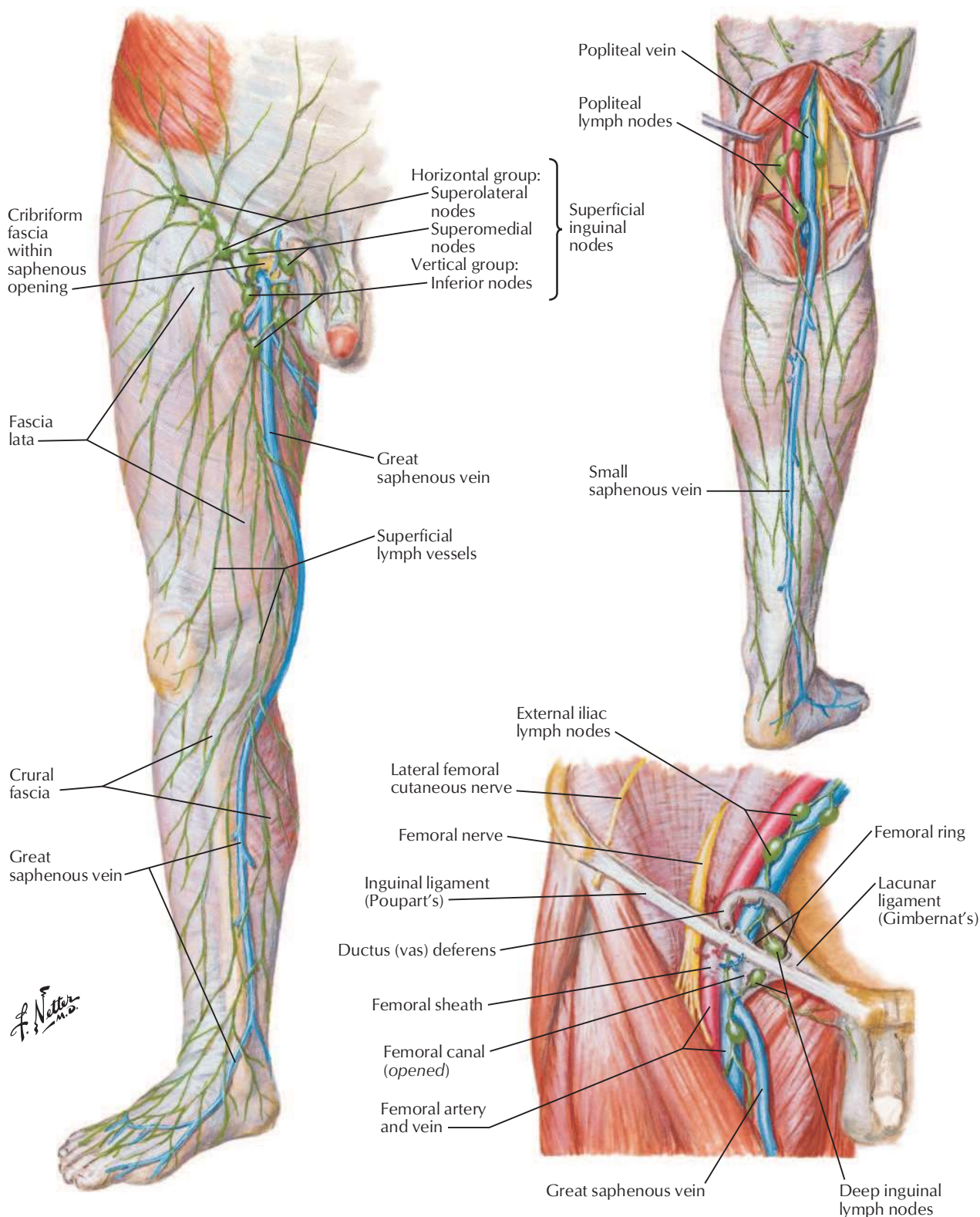


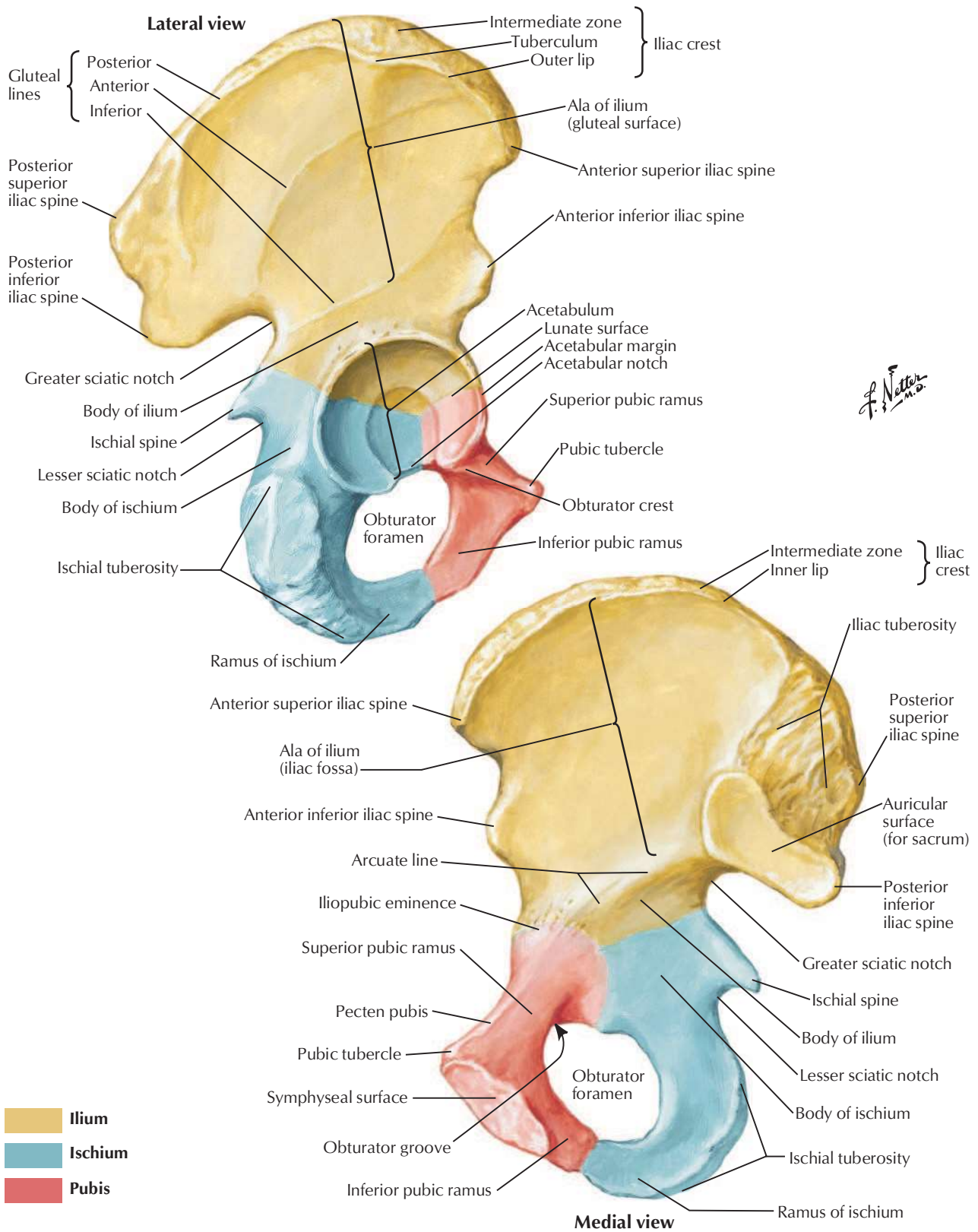
F. Netter M.D.

Superficial Nerves and Veins of Lower Limb: Posterior View

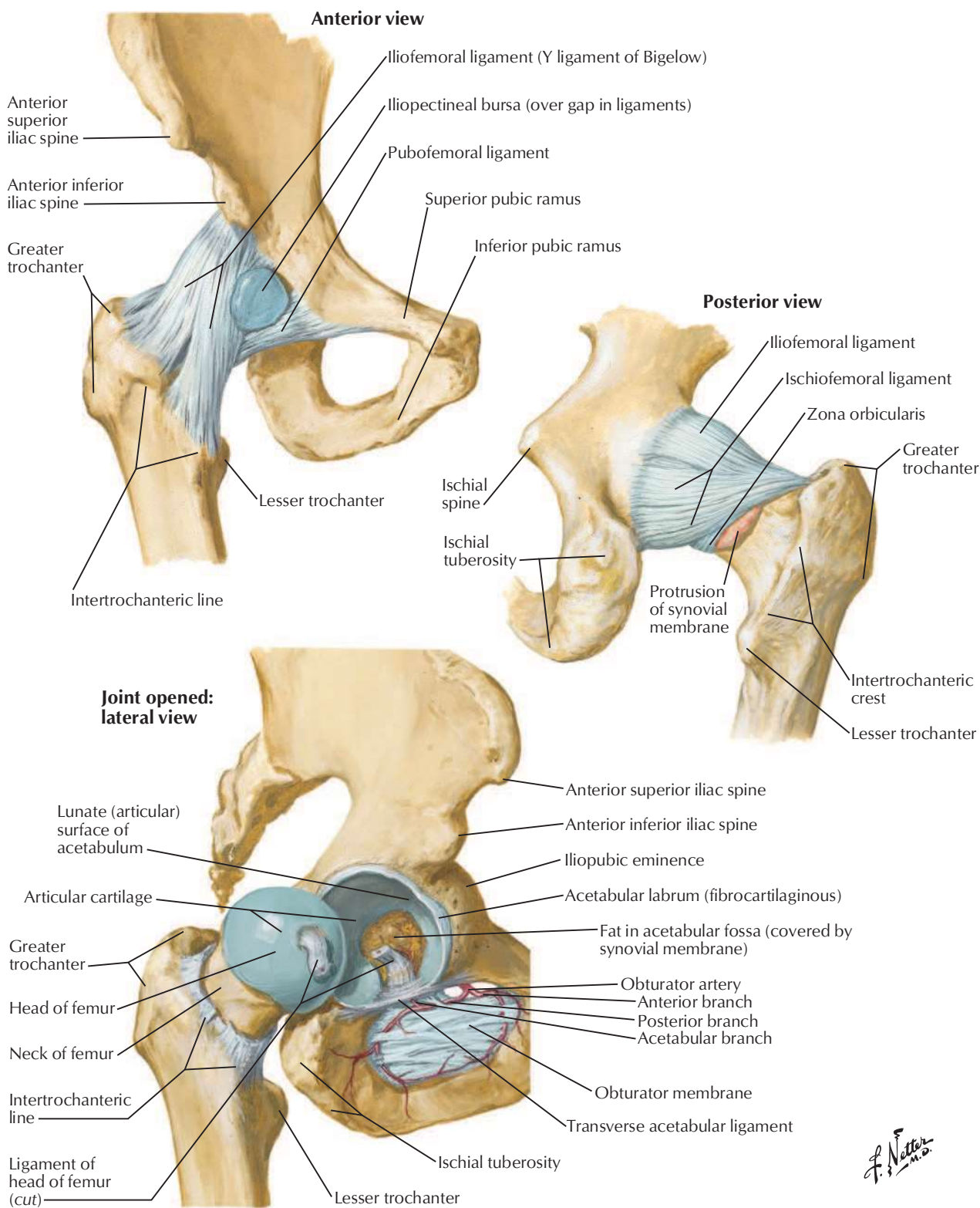
See also [Plates 531, 532](#)







F. Netter M.D.

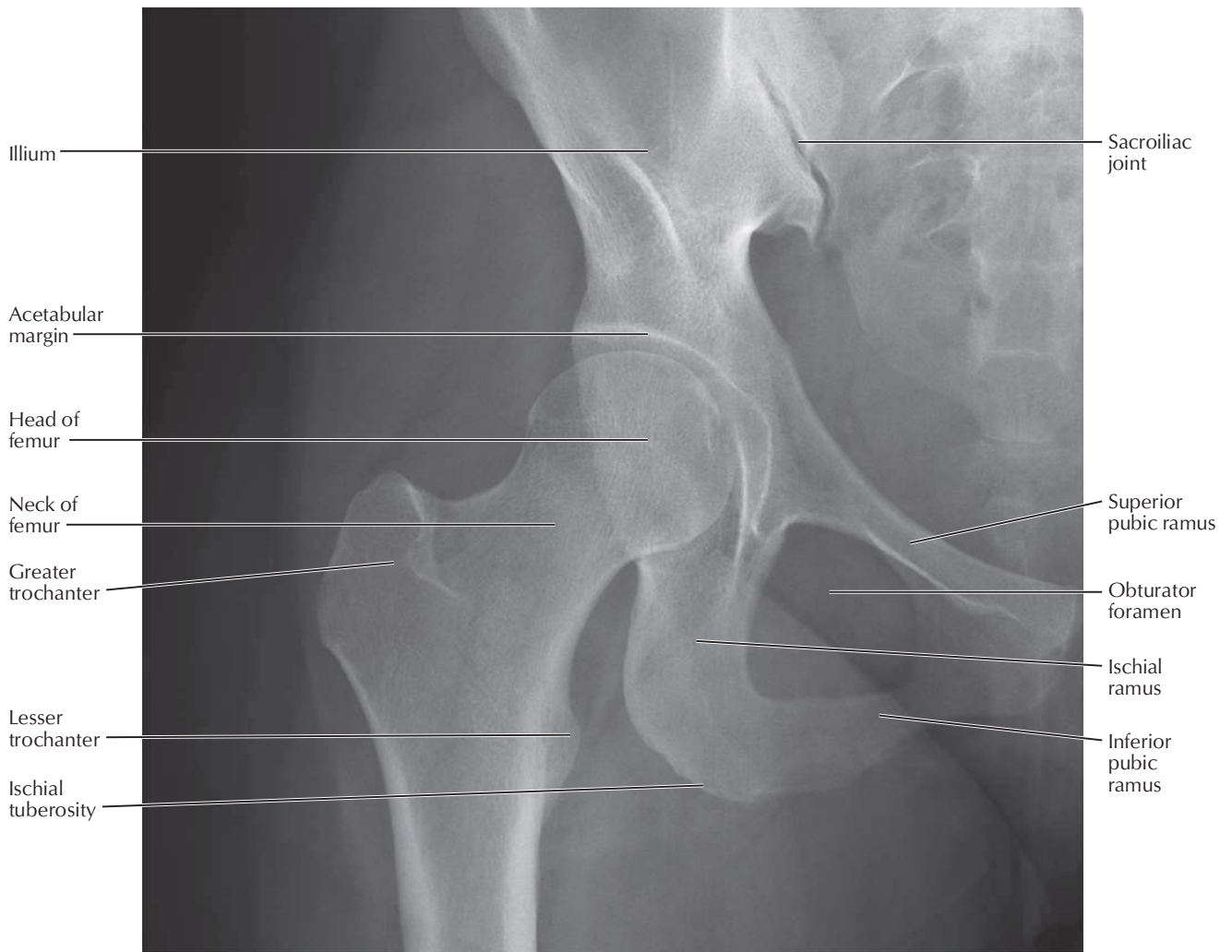


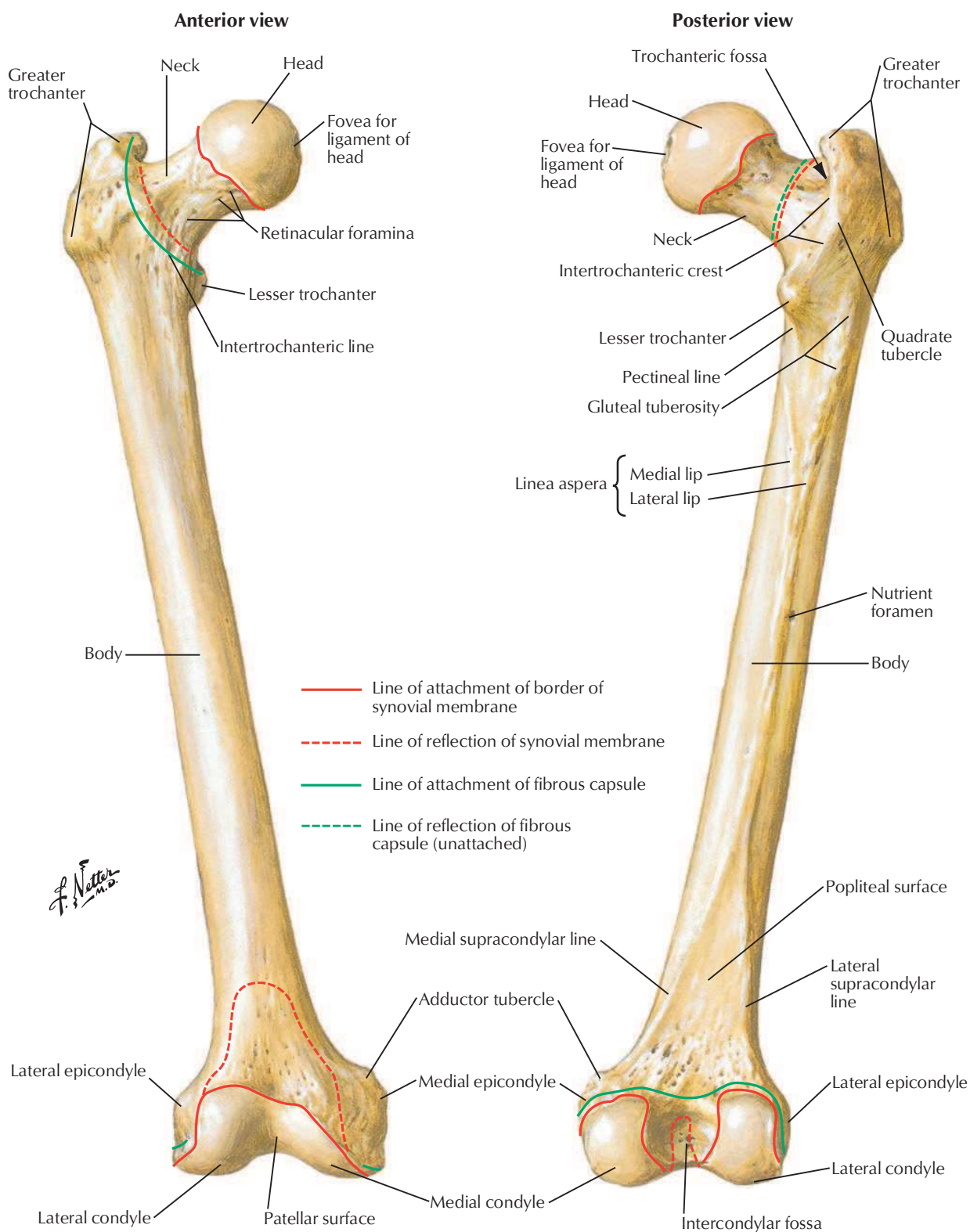
F. Netter M.D.



Hip Joint: Anteroposterior Radiograph

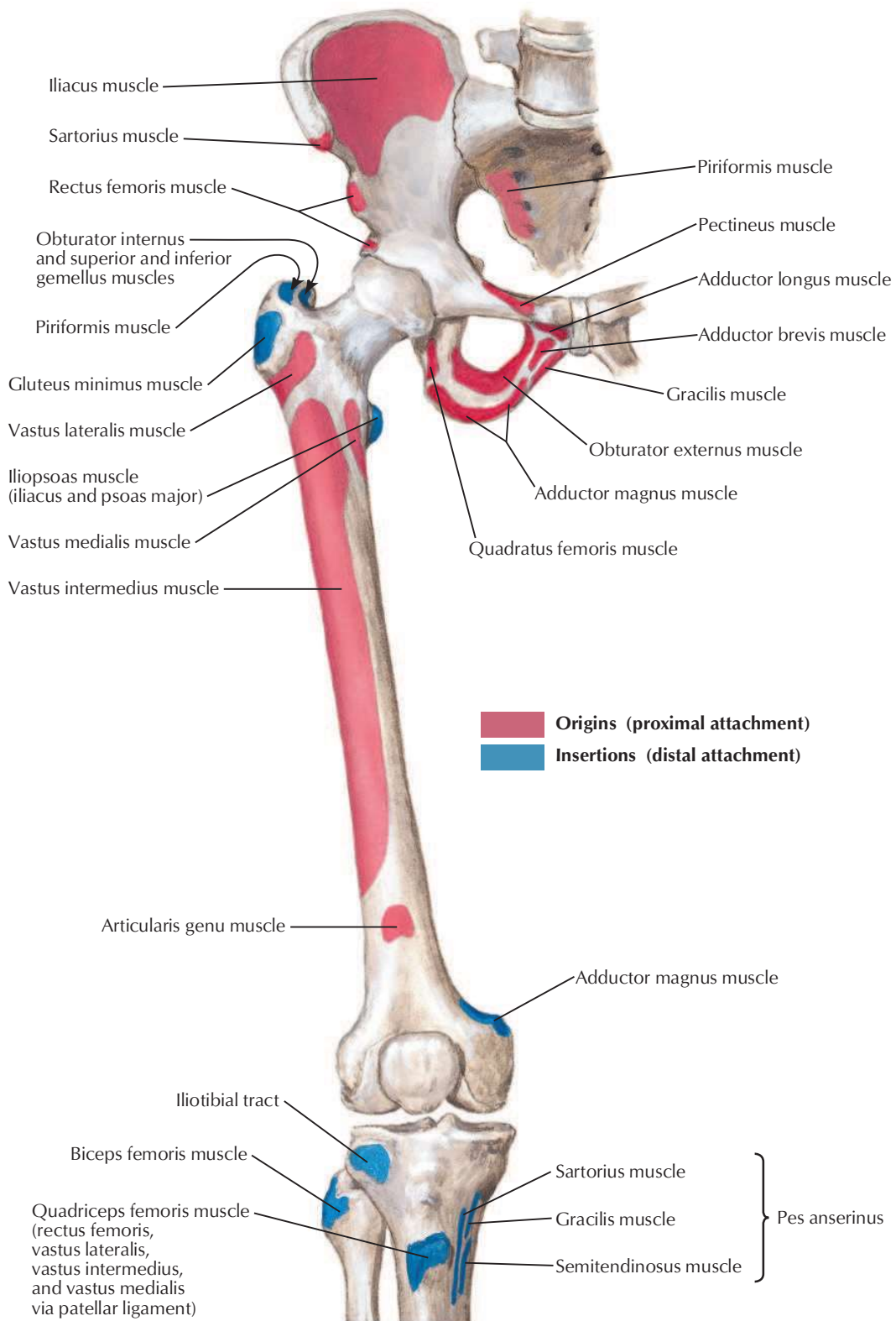
See also [Plates 335, 477, 480](#)

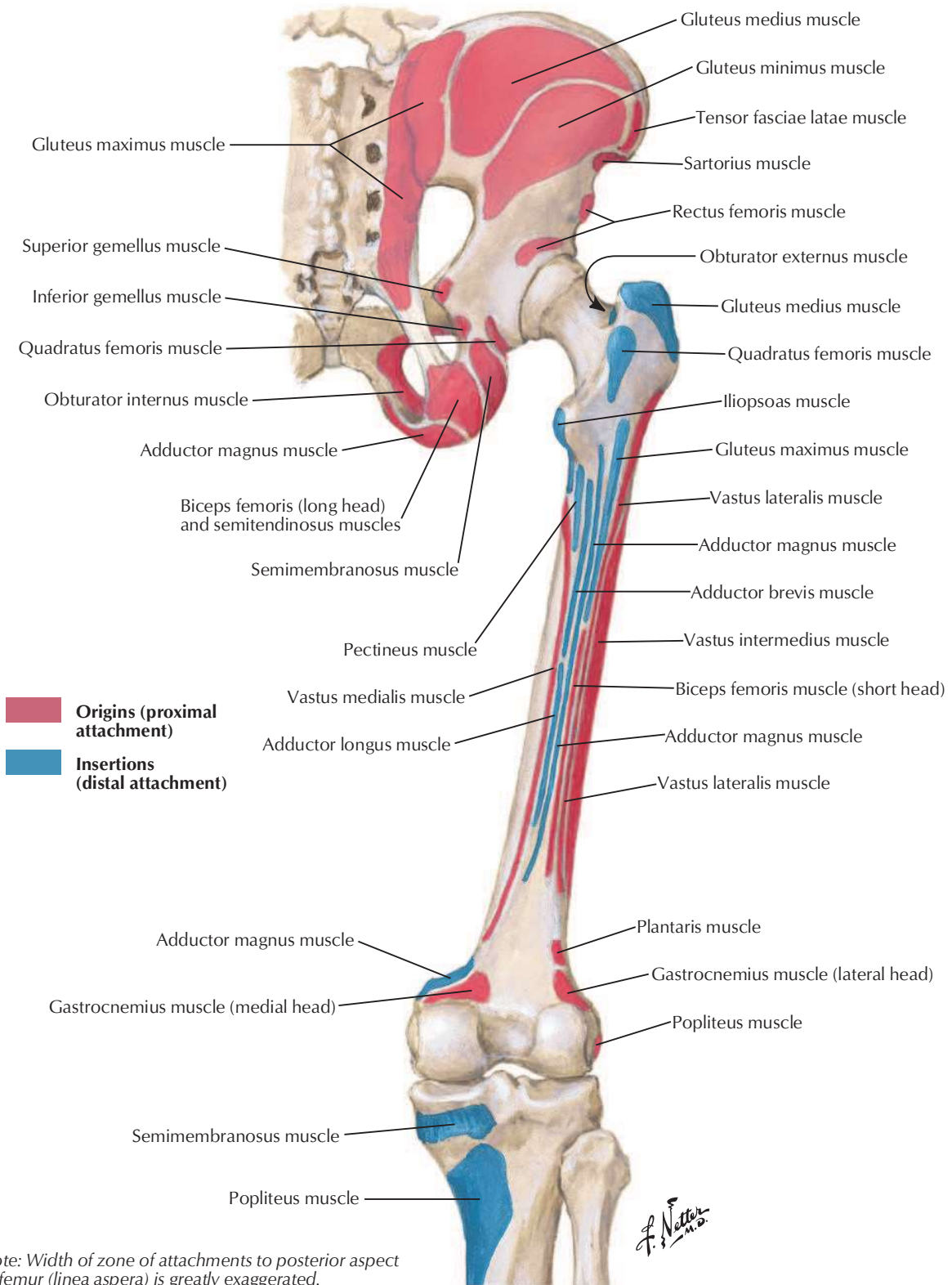




Bony Attachments of Muscles of Hip and Thigh: Anterior View

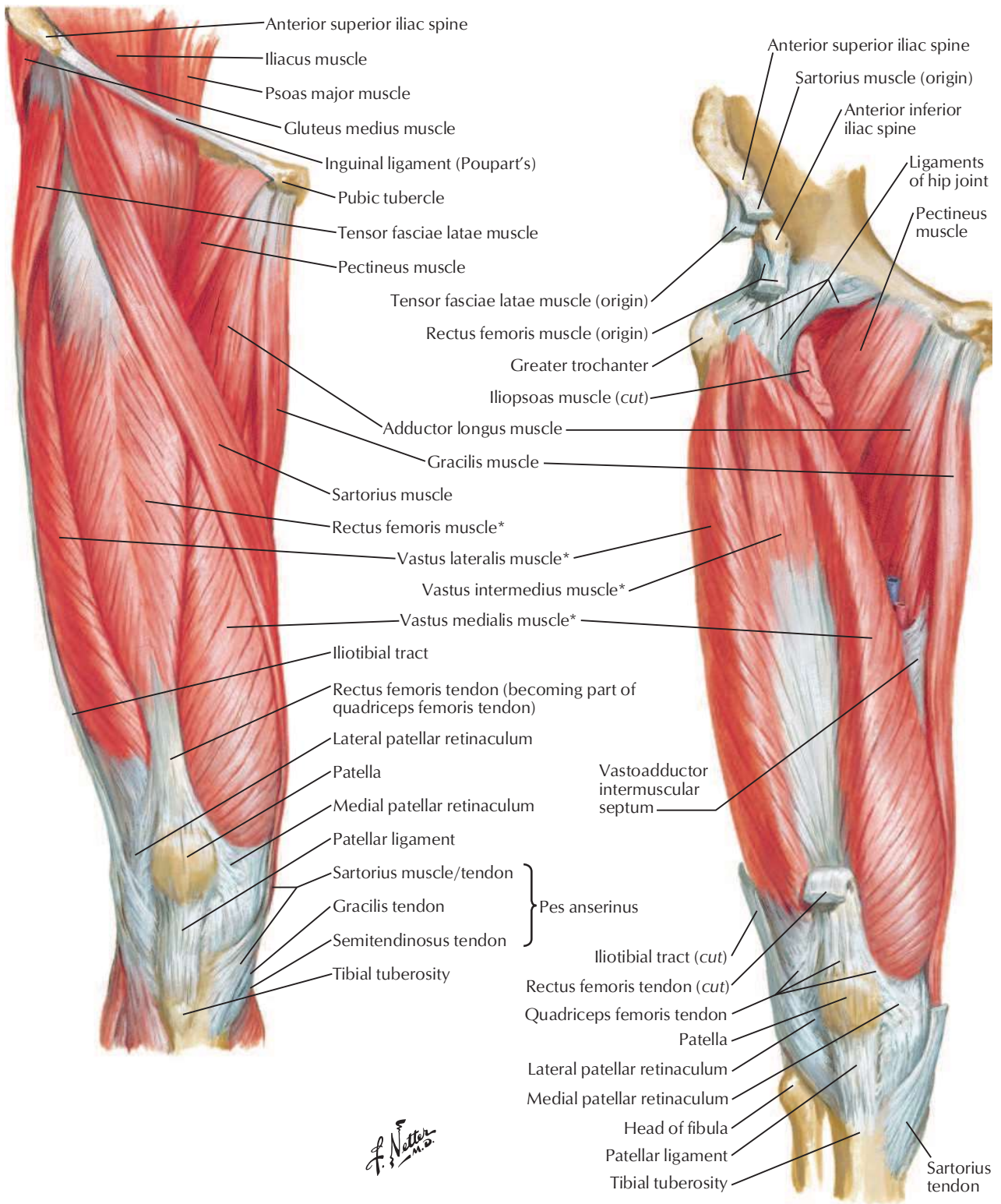
See also [Plates 478, 534](#)





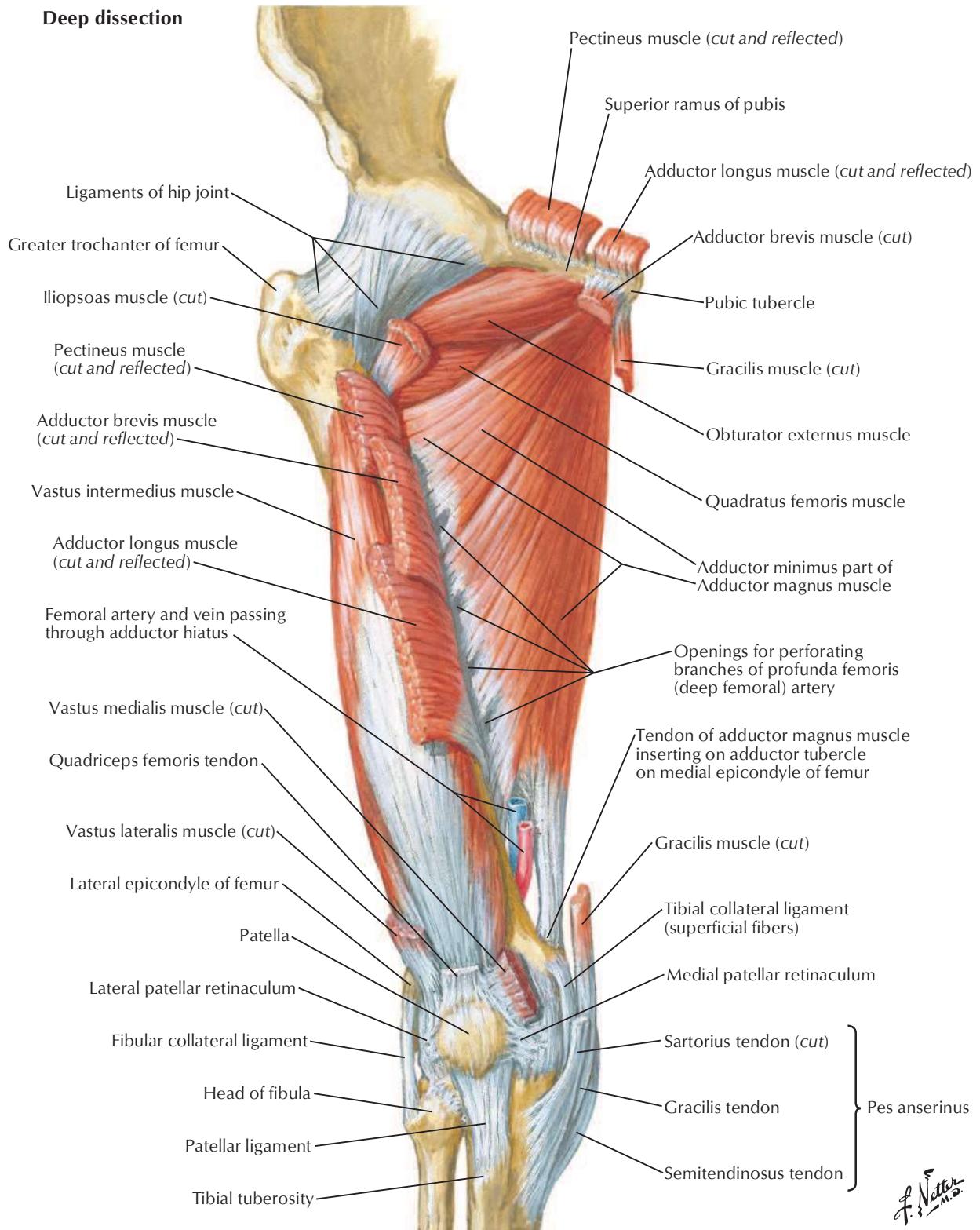
Muscles of Thigh: Anterior Views

See also [Plate 265](#)



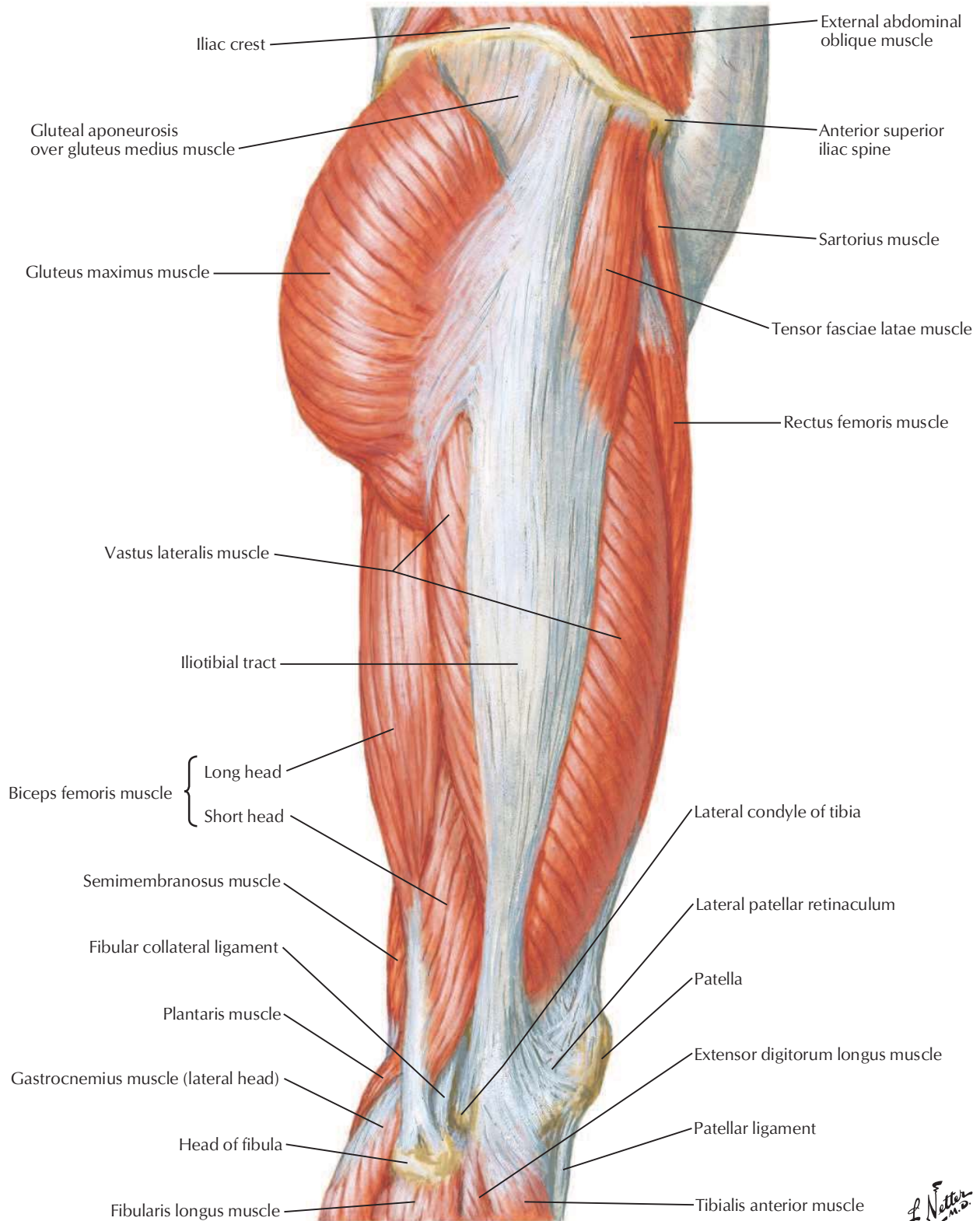
*Muscles of quadriceps femoris

Deep dissection



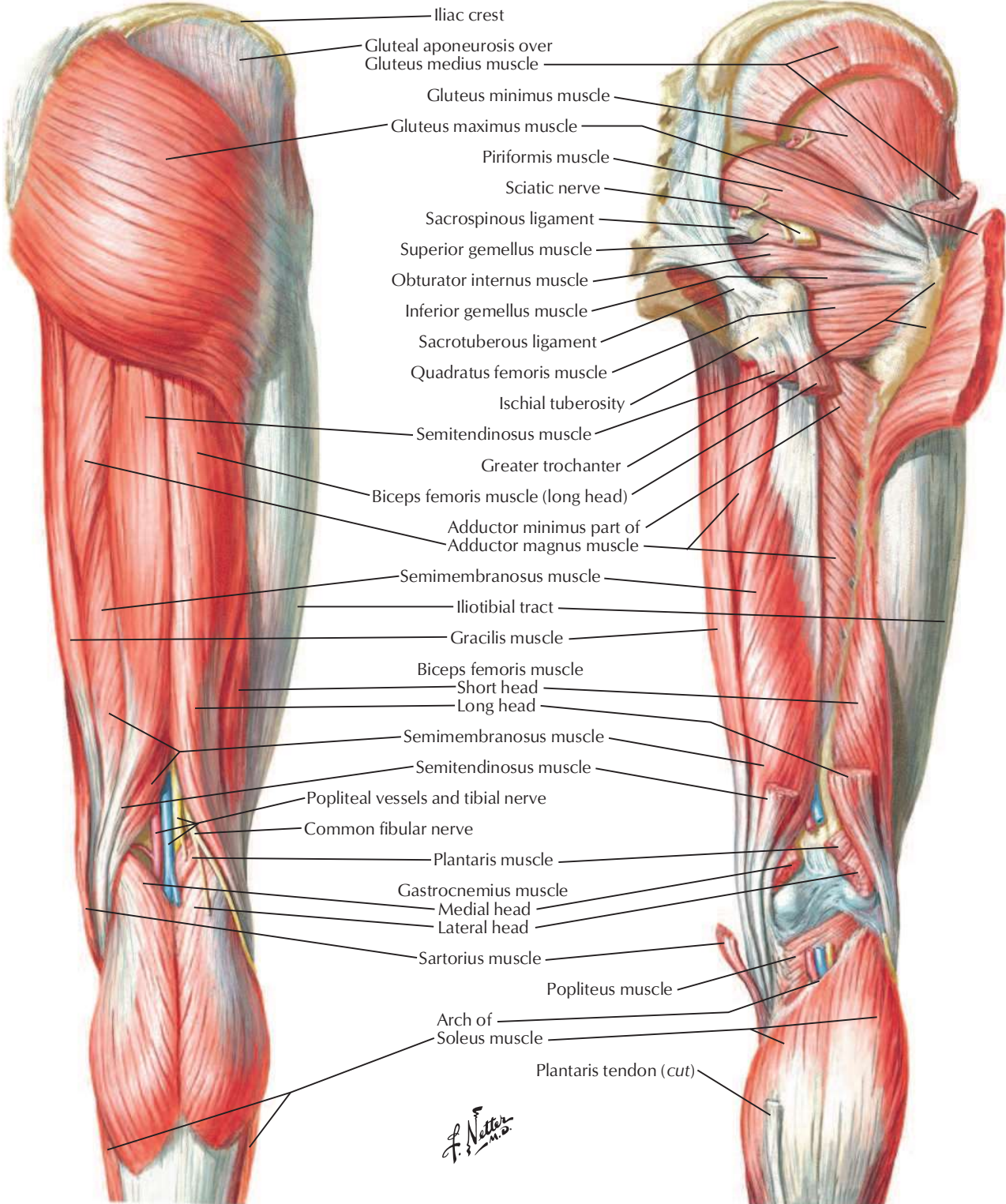
Muscles of Hip and Thigh: Lateral View

See also [Plate 496](#)



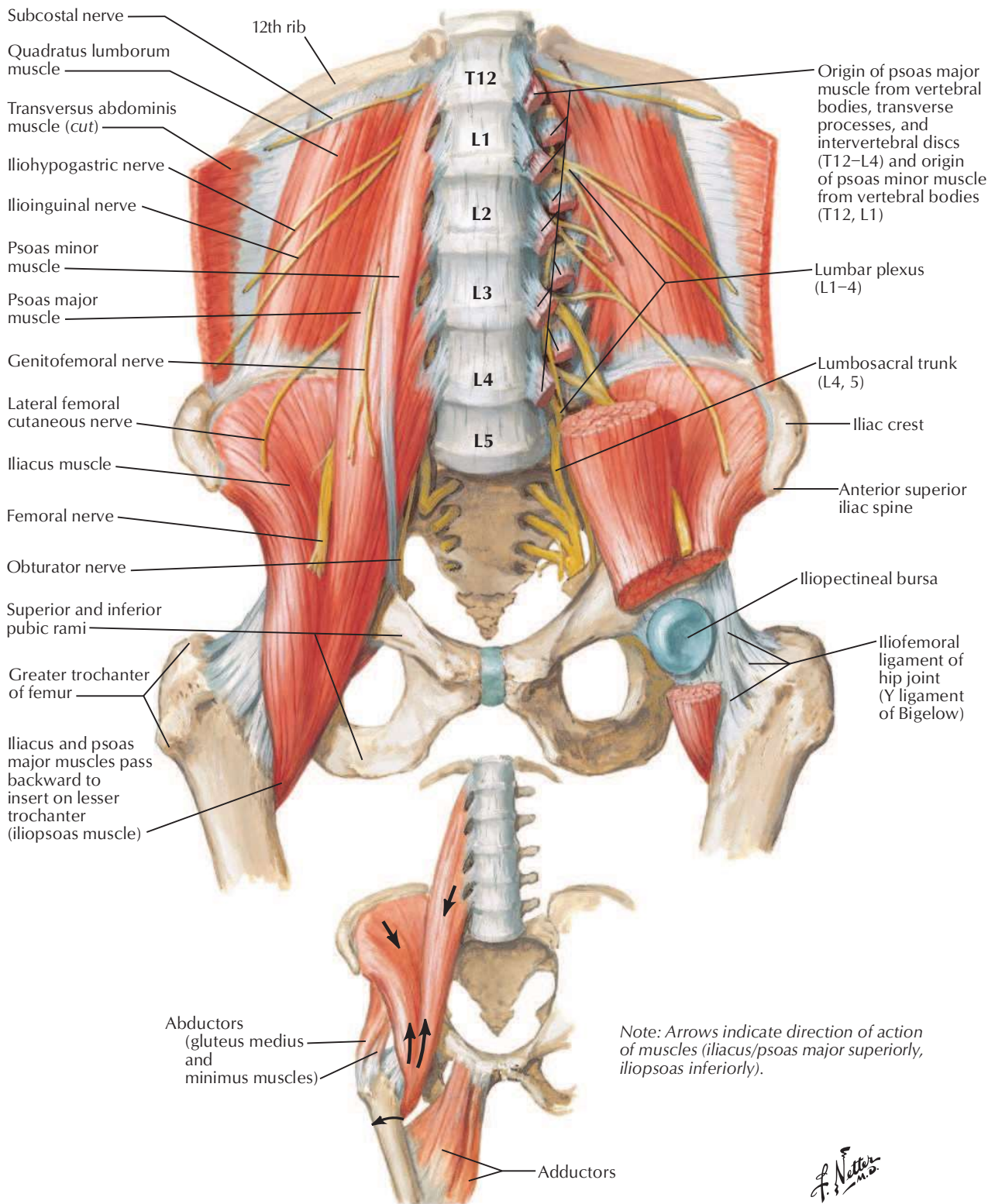
Superficial dissection

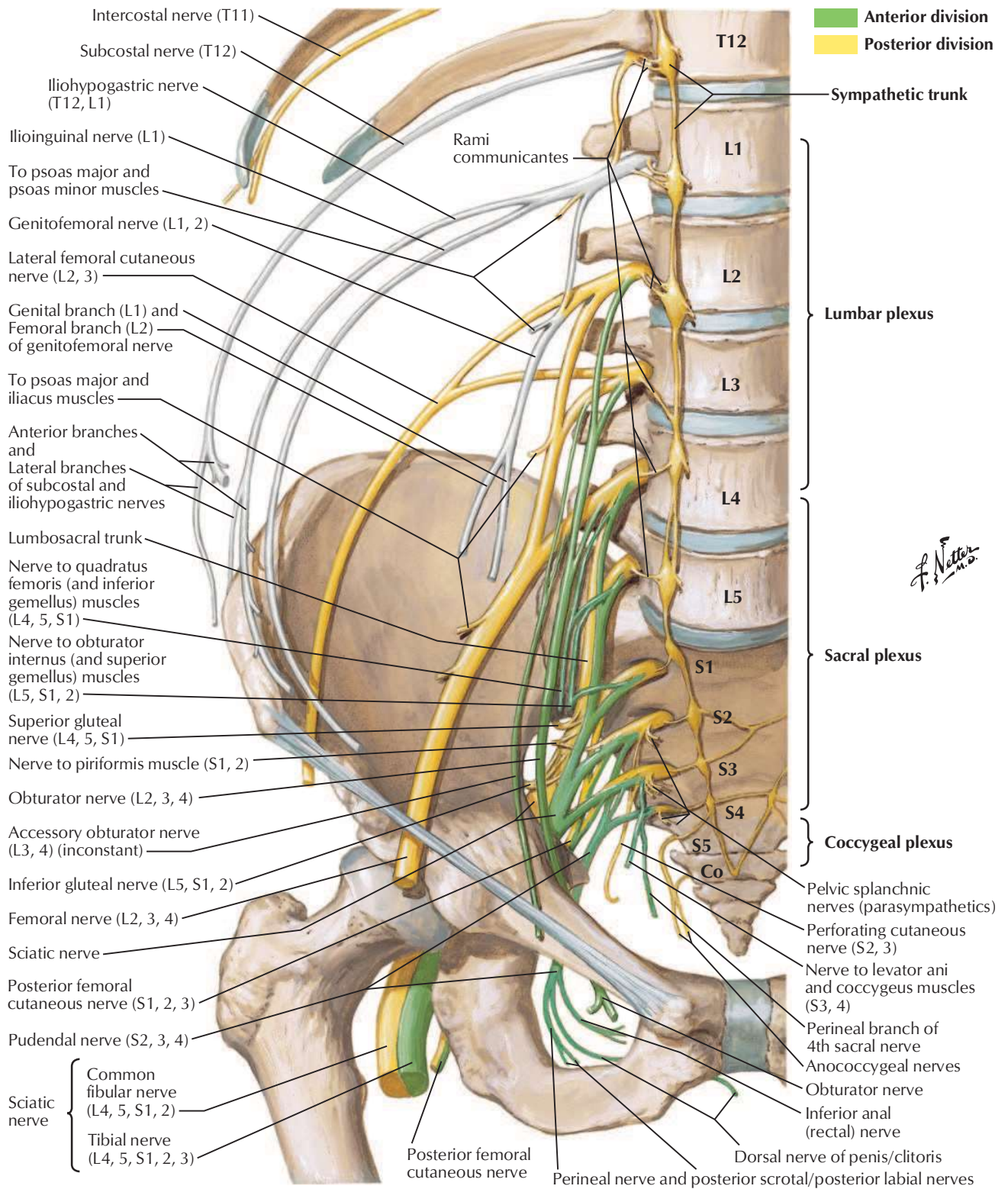
Deeper dissection

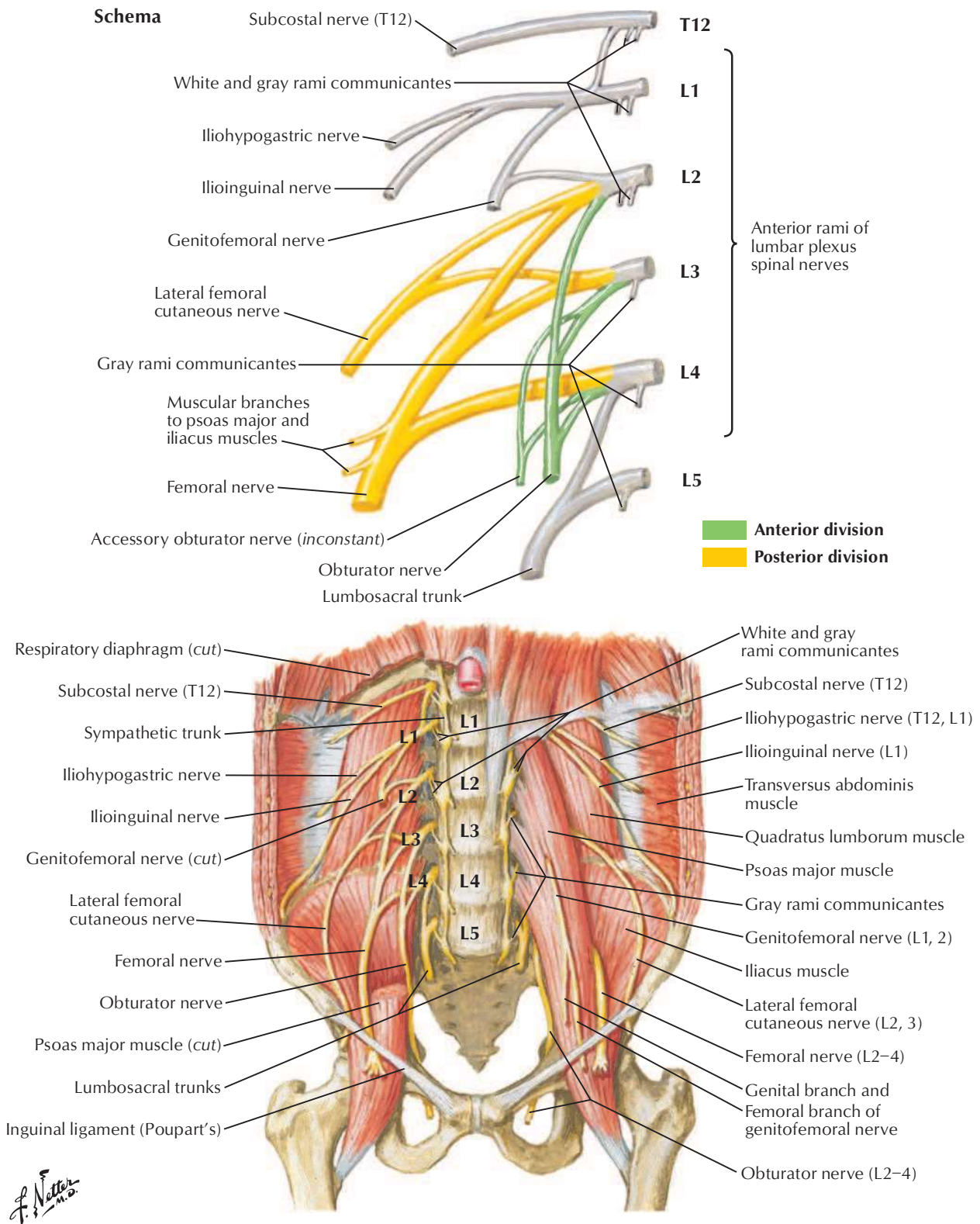


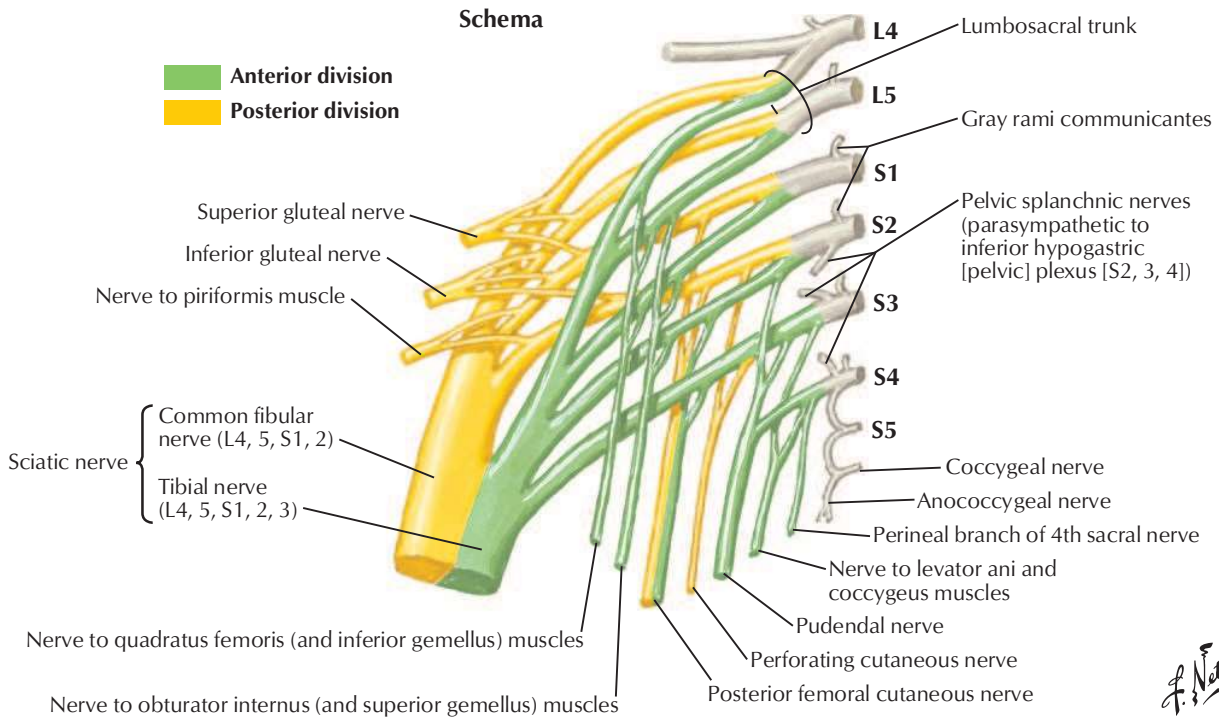
Psoas and Iliacus Muscles

See also **Plates 265, 269**

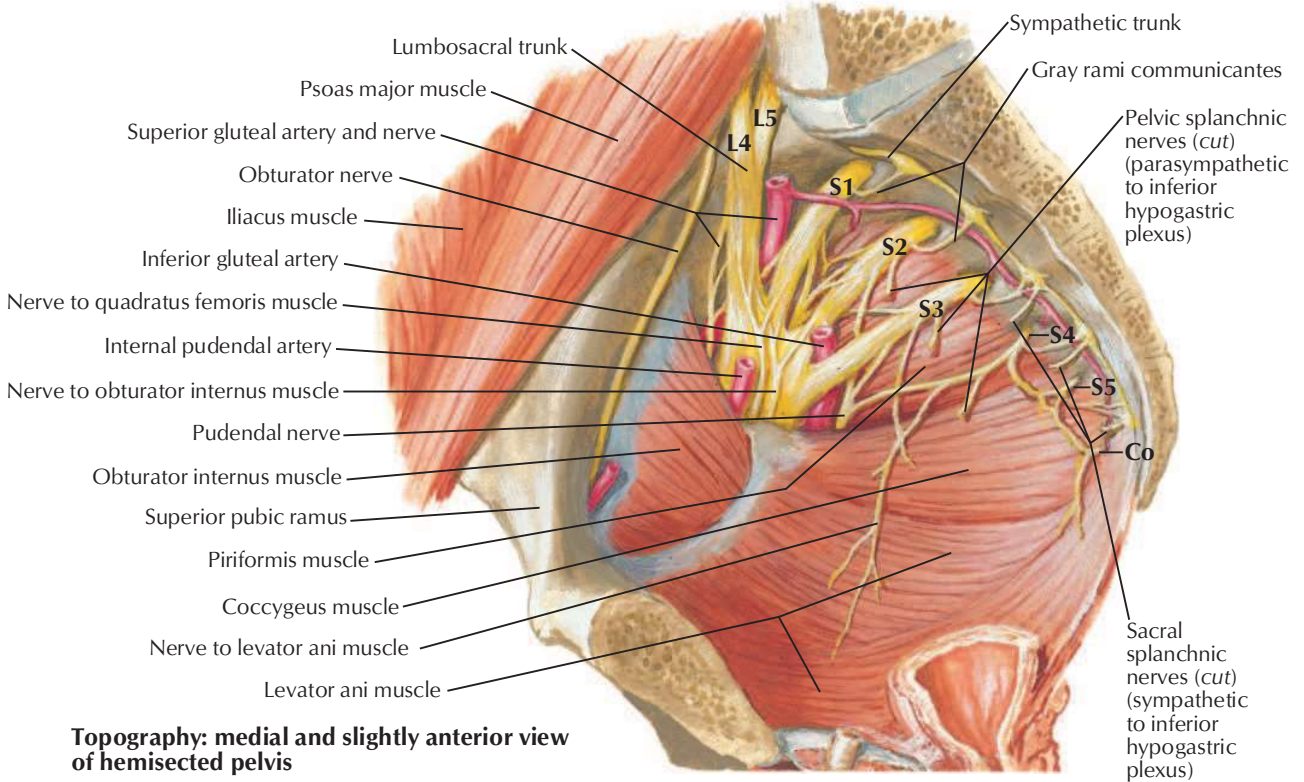




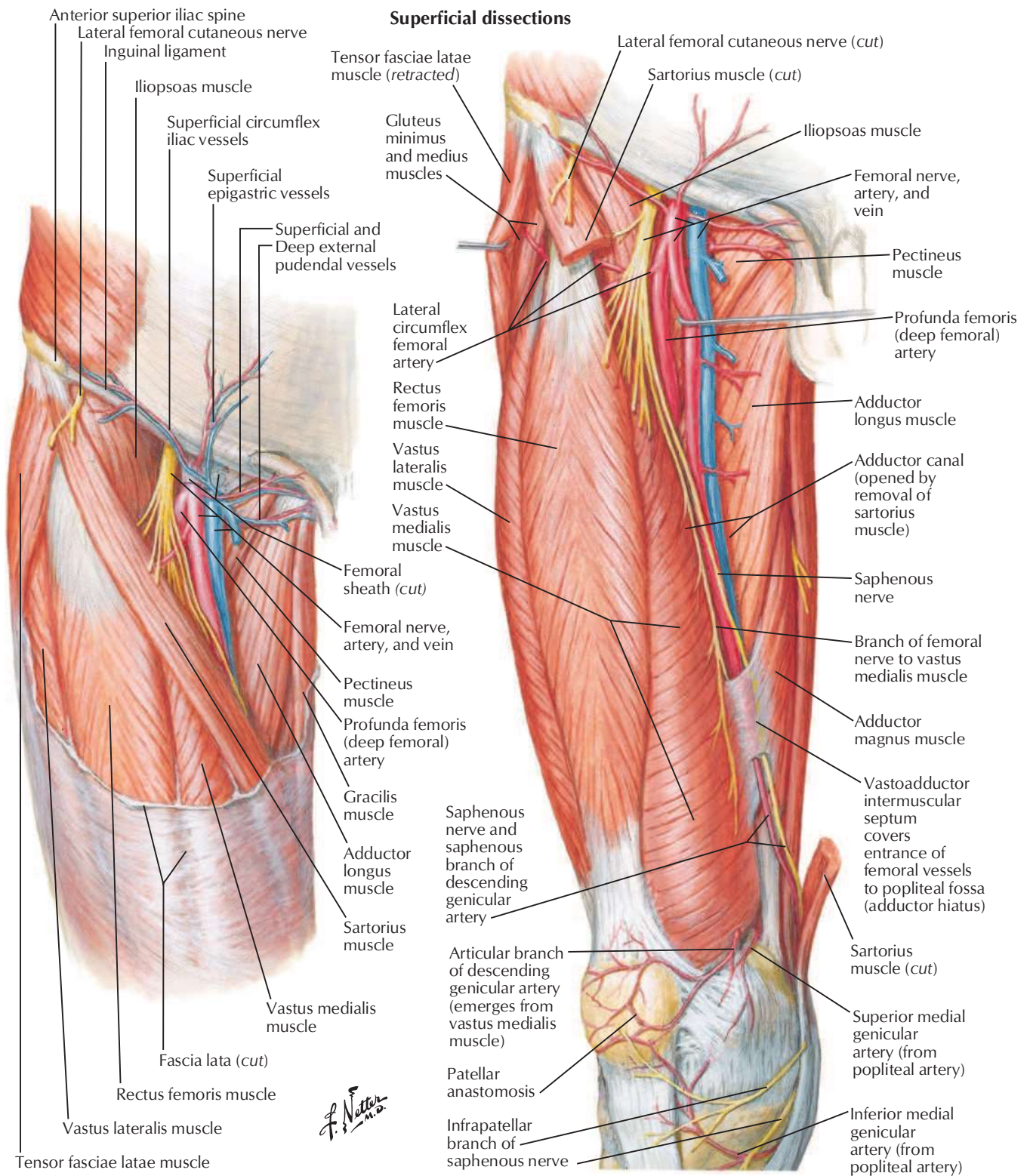




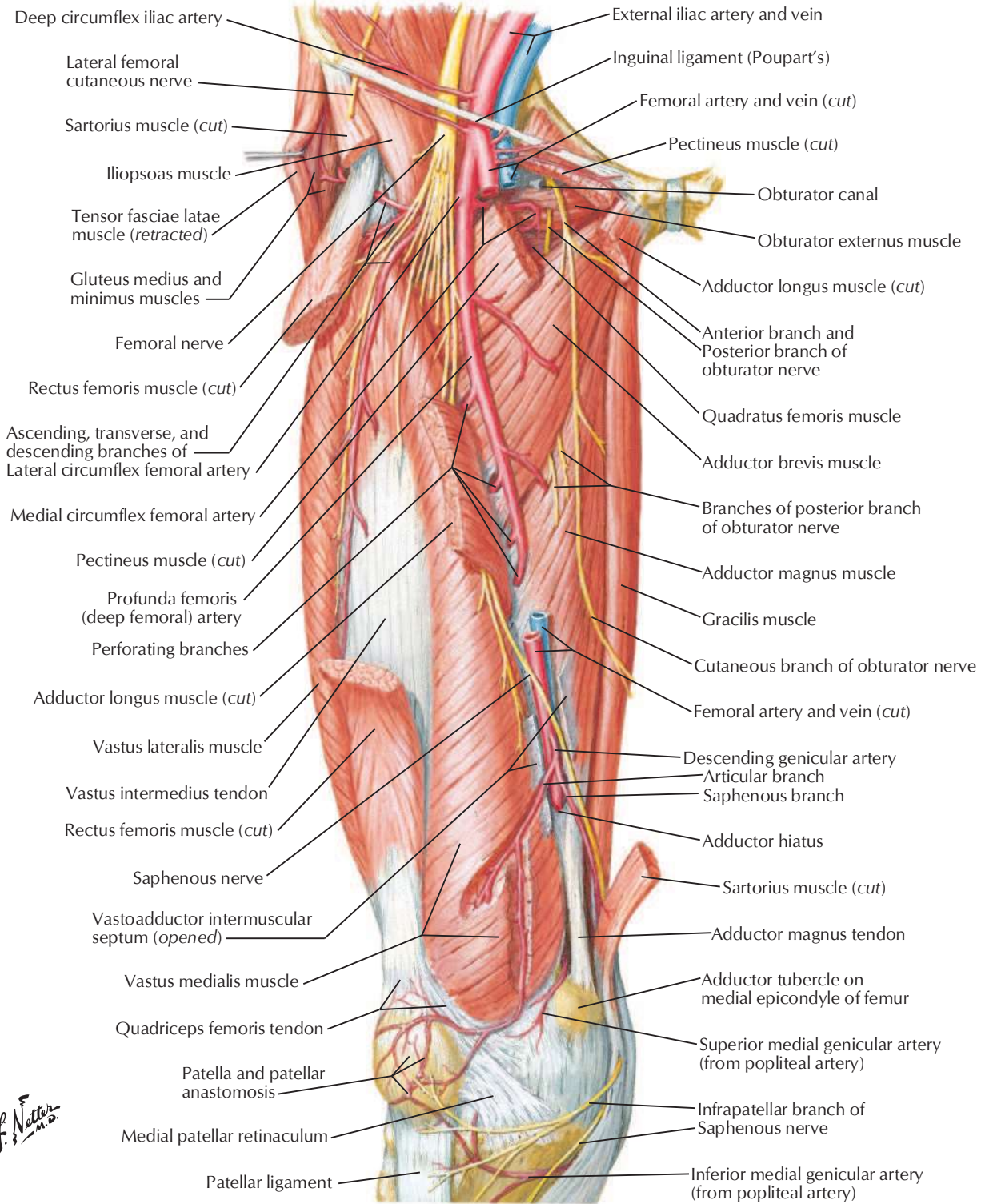
F. Netter M.D.



Topography: medial and slightly anterior view of hemisectioned pelvis

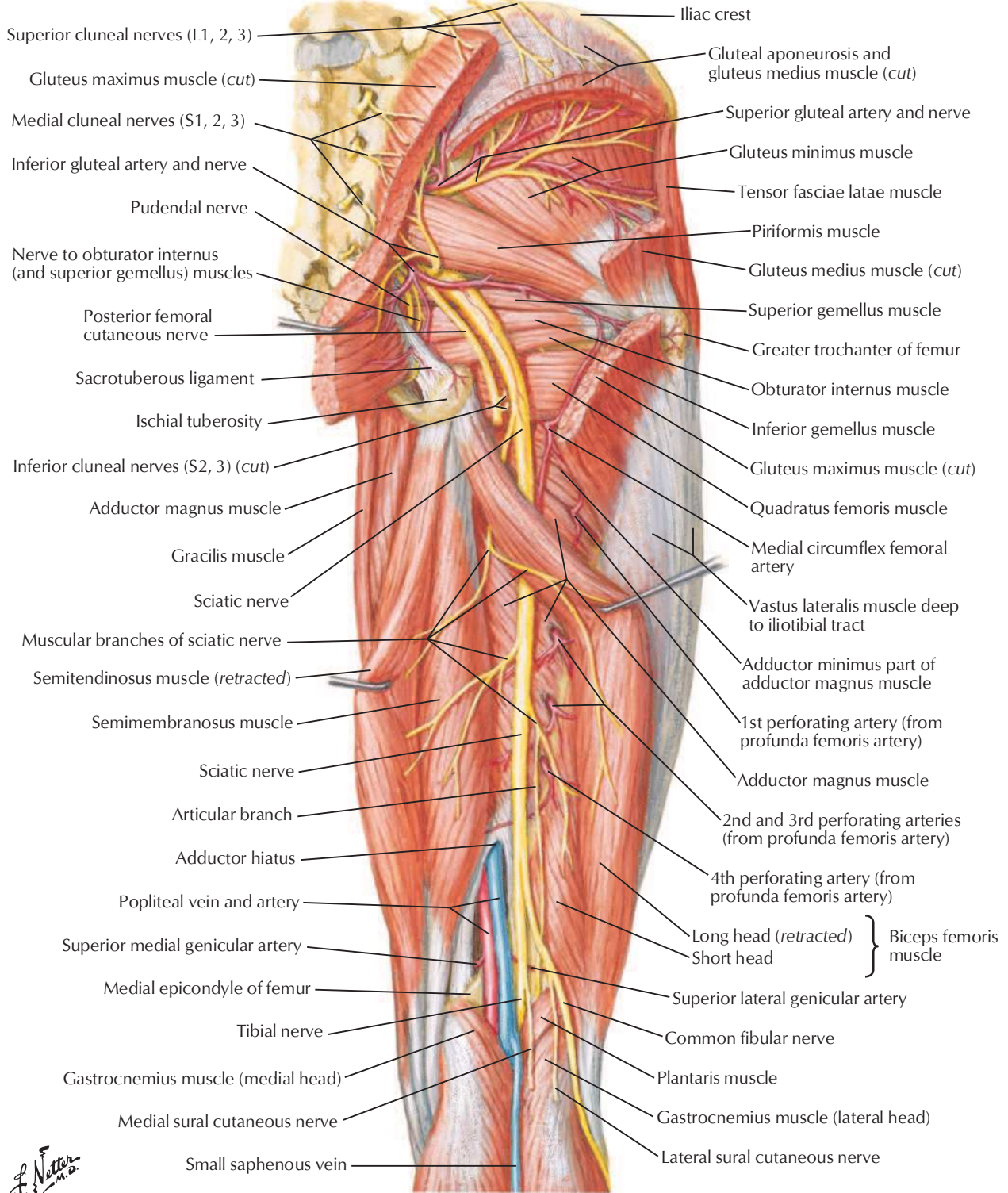


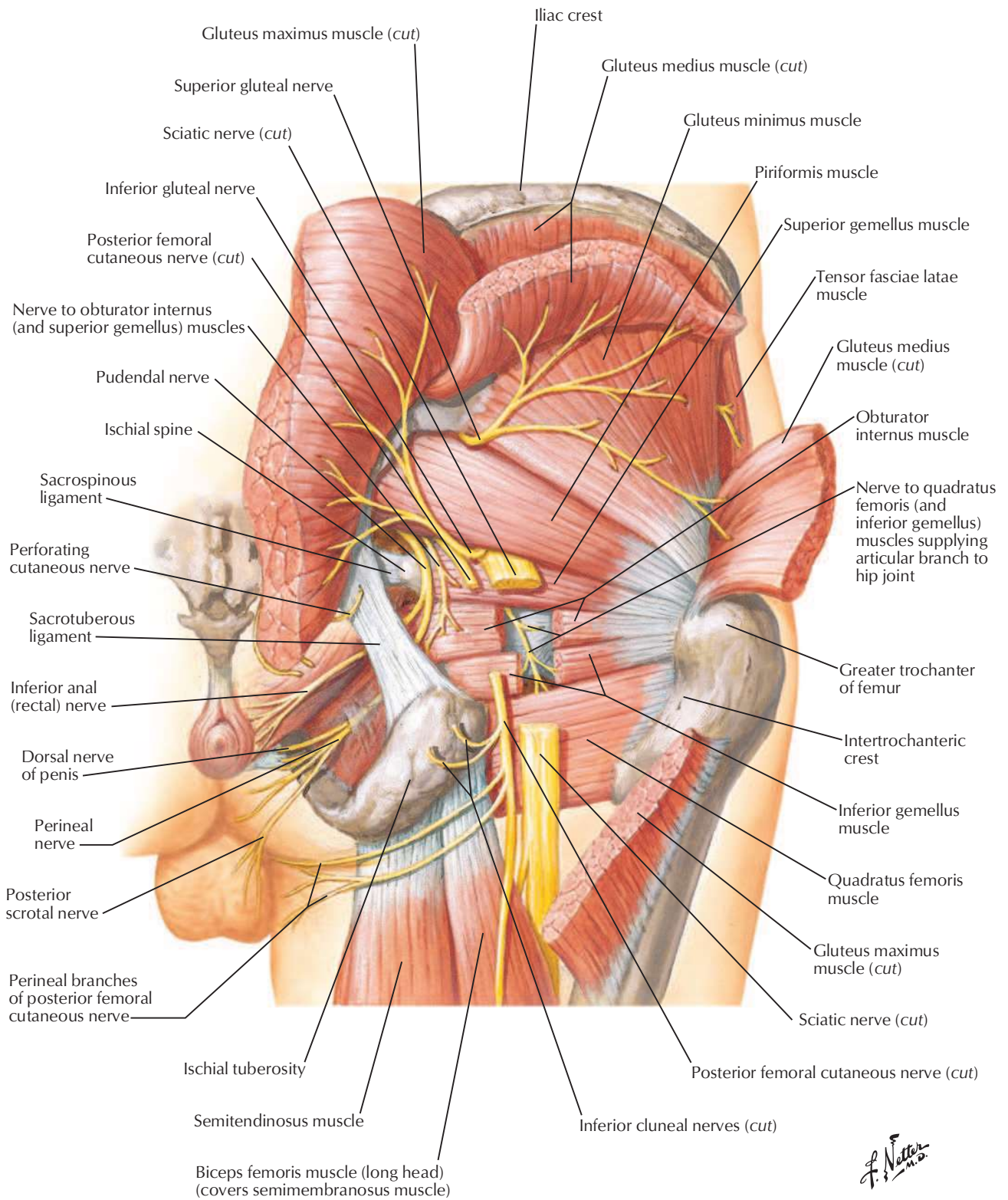
Deep dissection



F. Netter M.D.

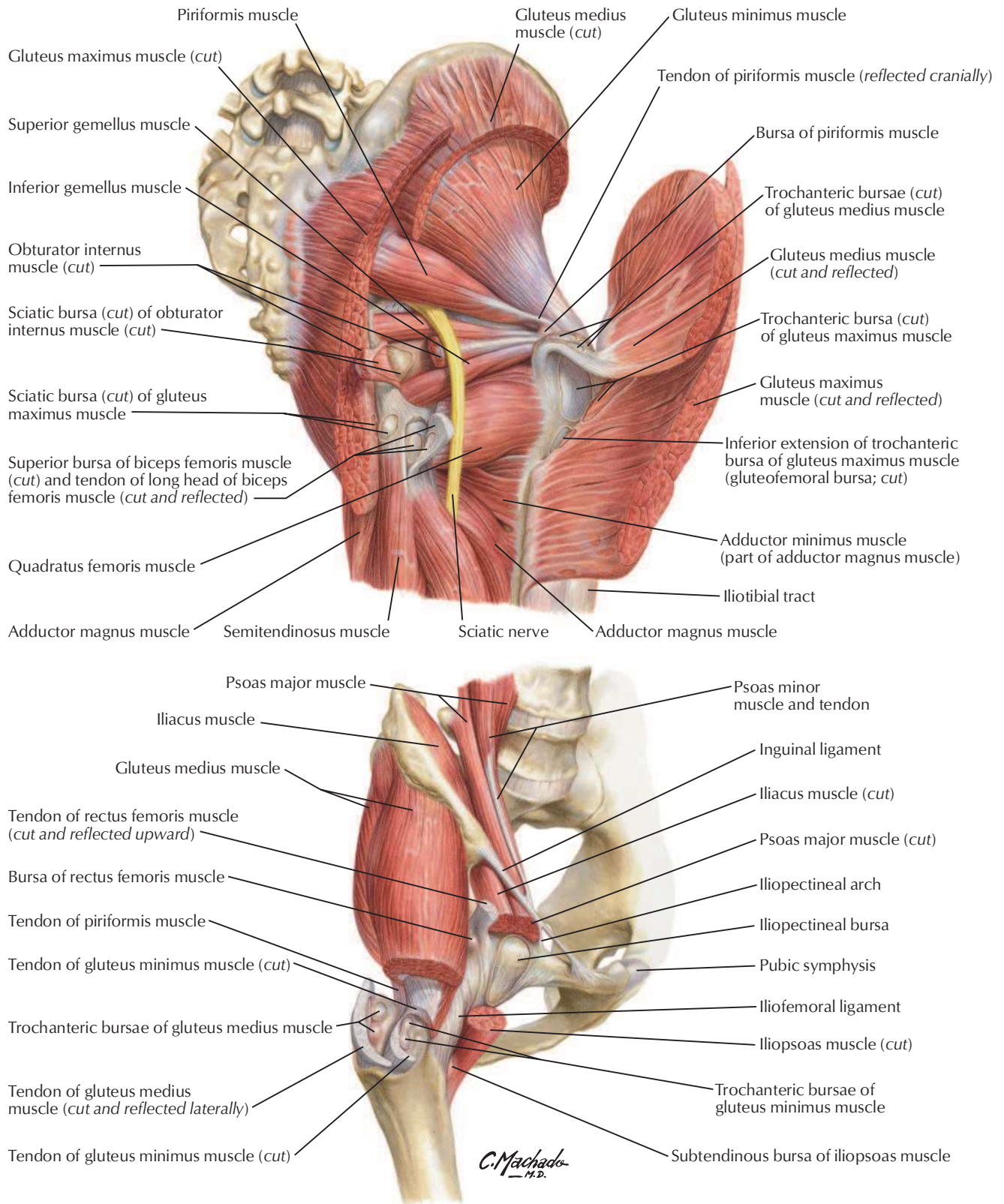
Deep dissection

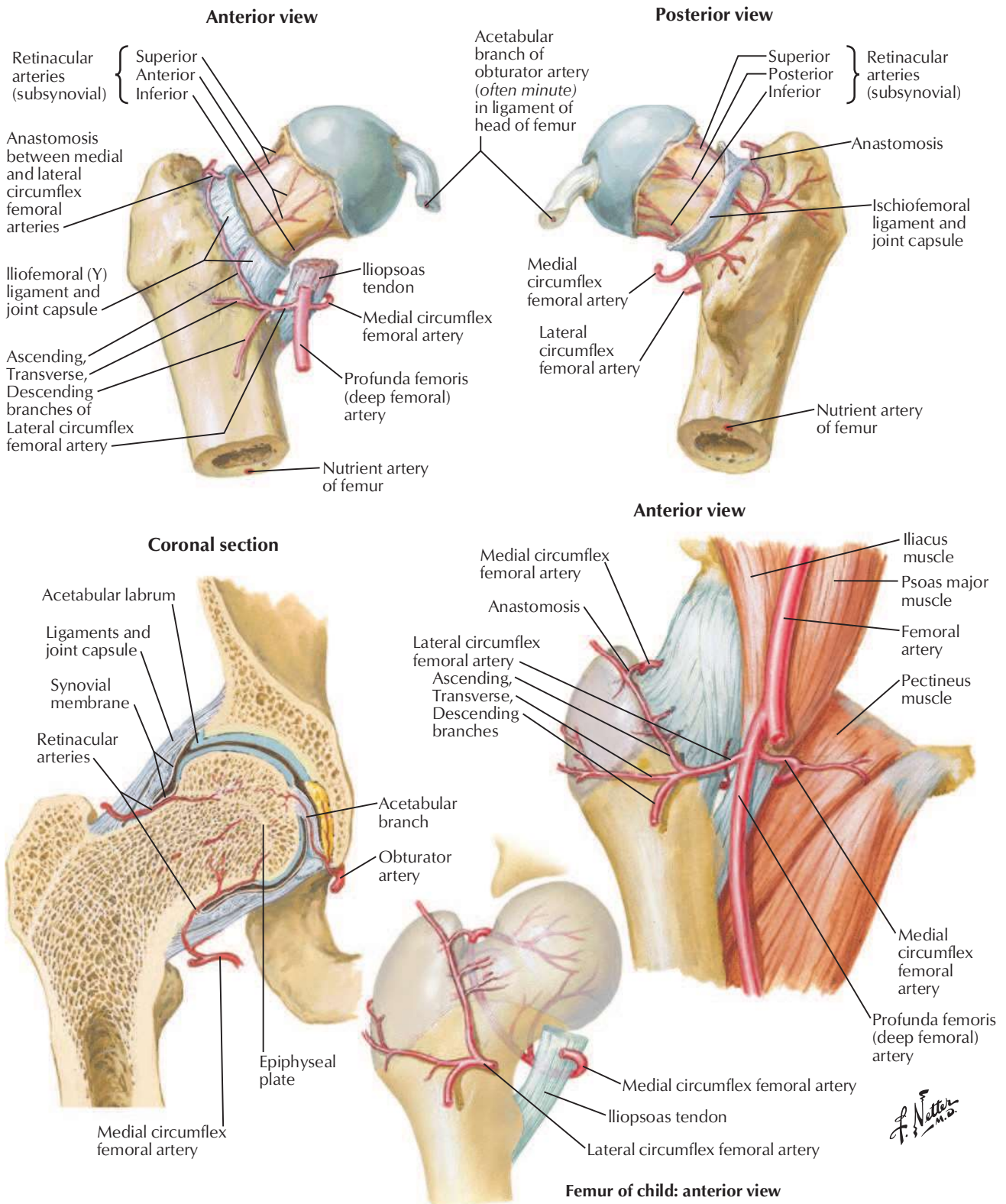


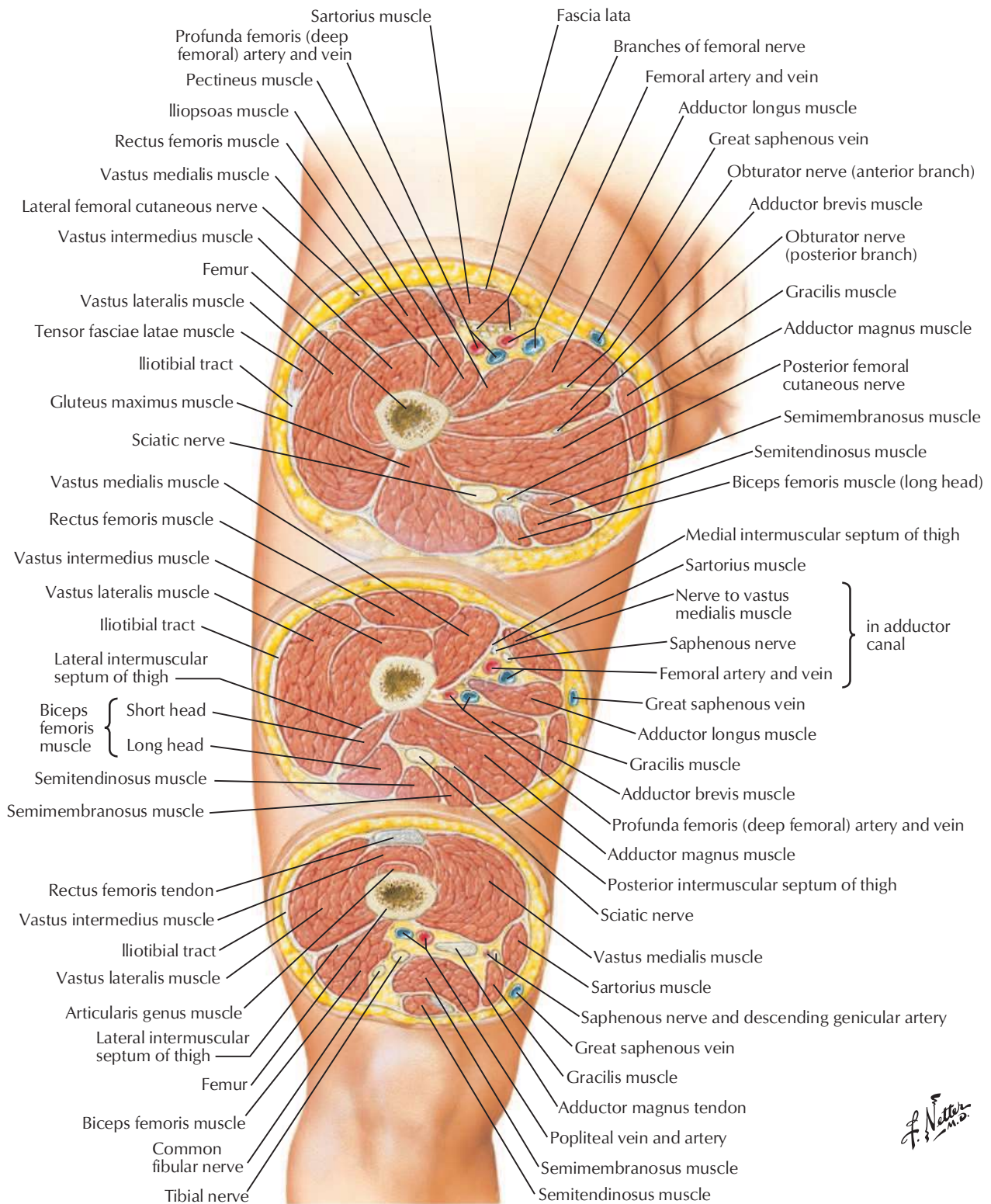


F. Netter M.D.

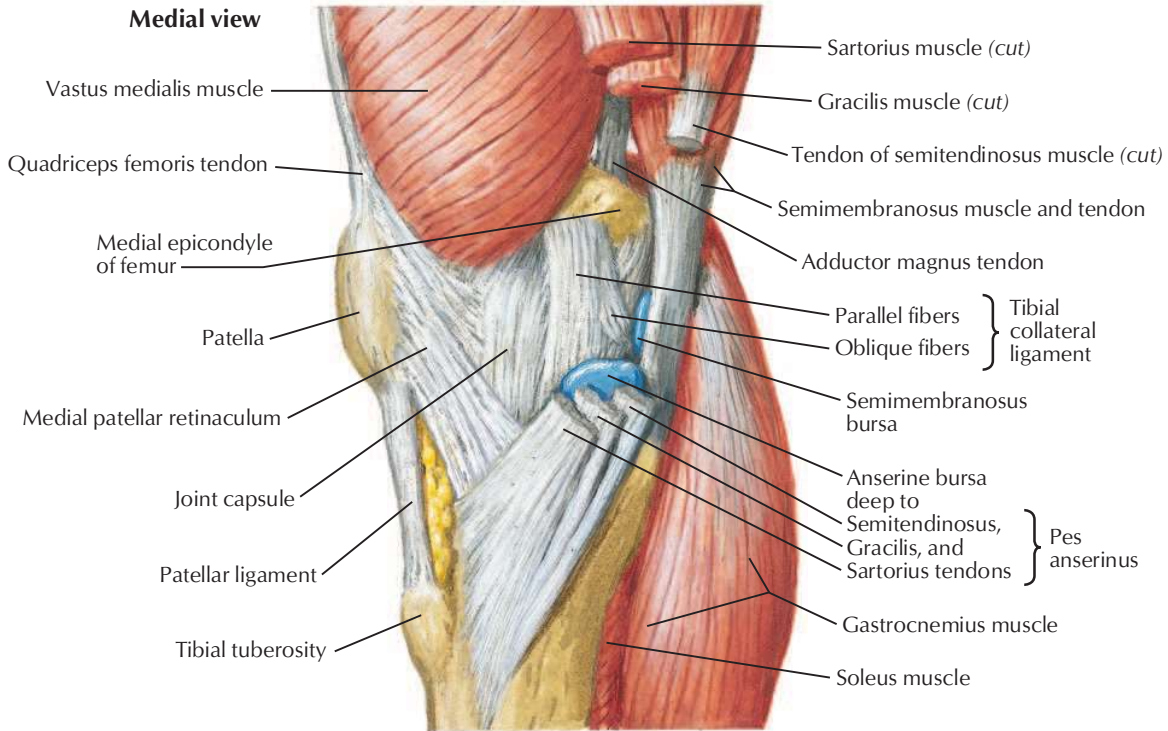
Hip Bursae: Posterior and Anterolateral Views



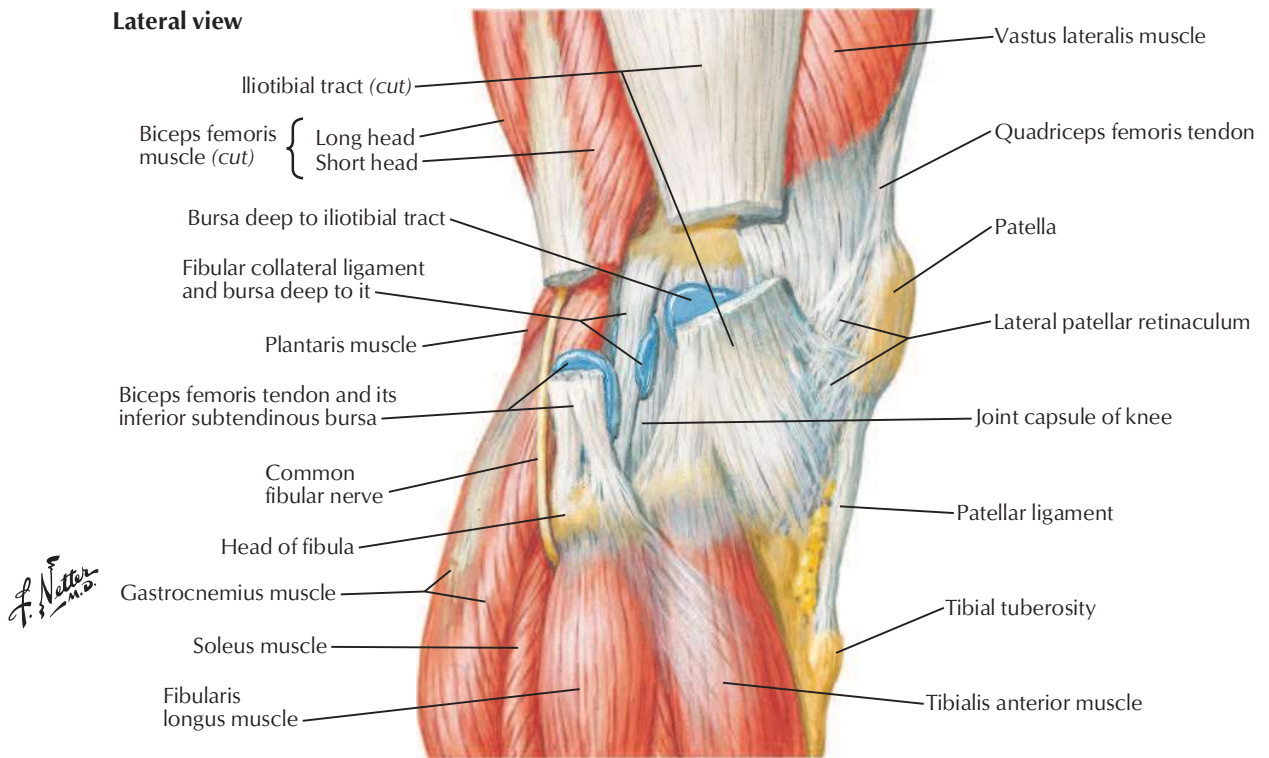




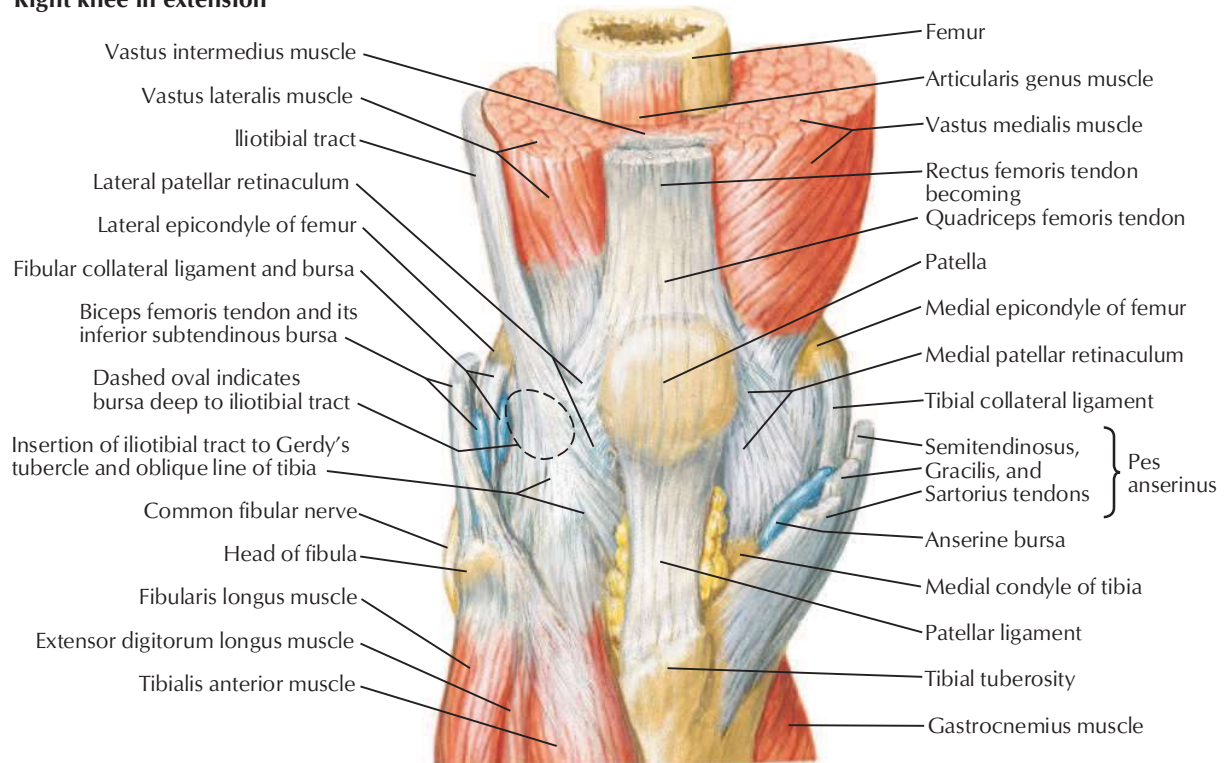
Medial view



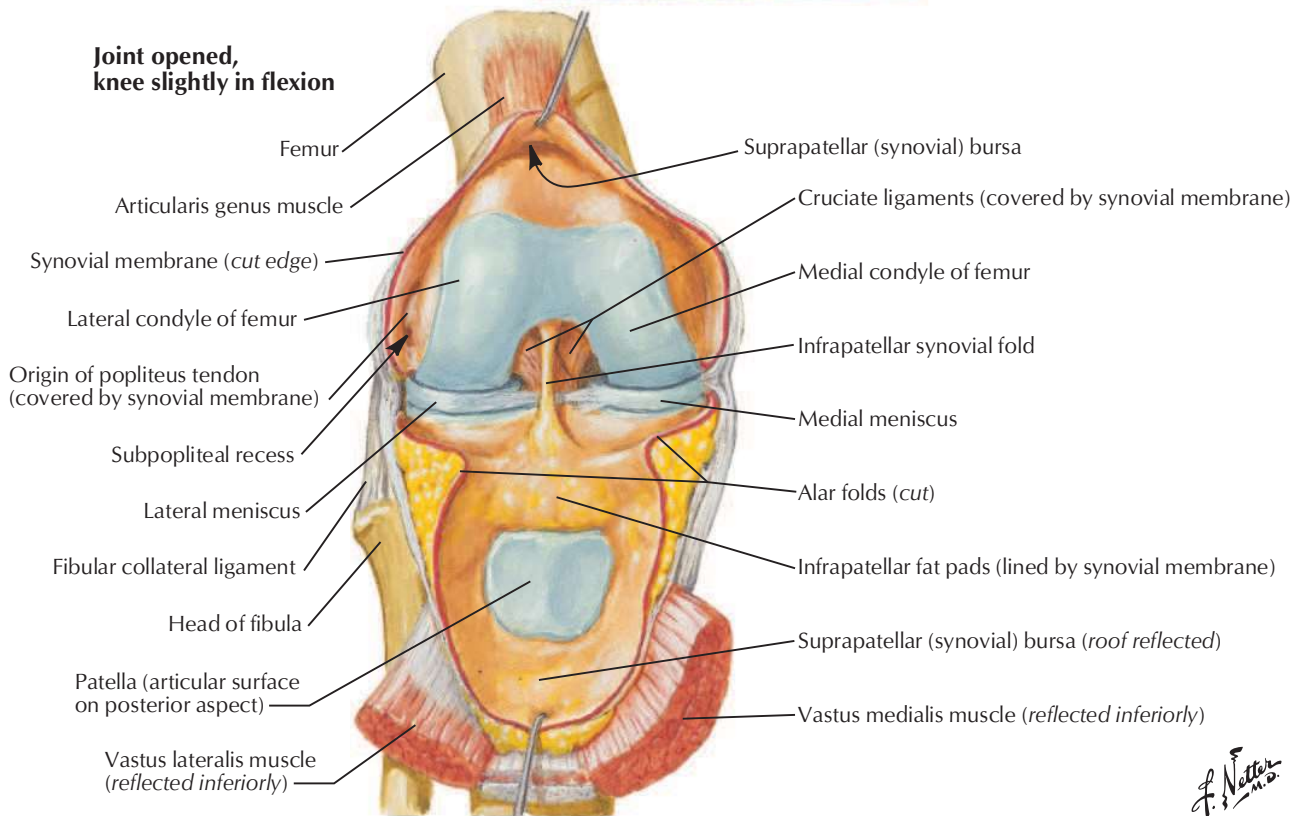
Lateral view



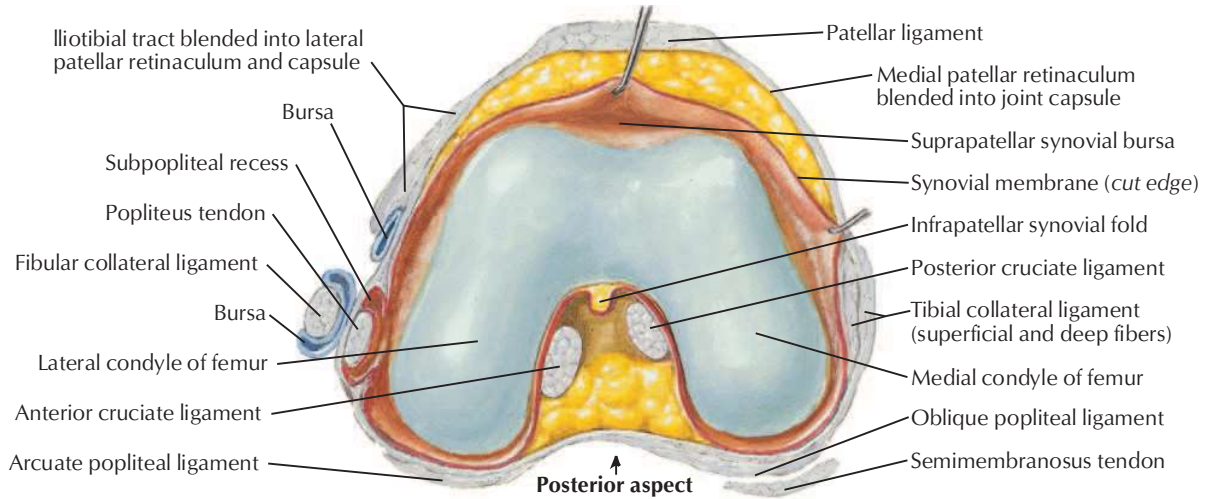
Right knee in extension



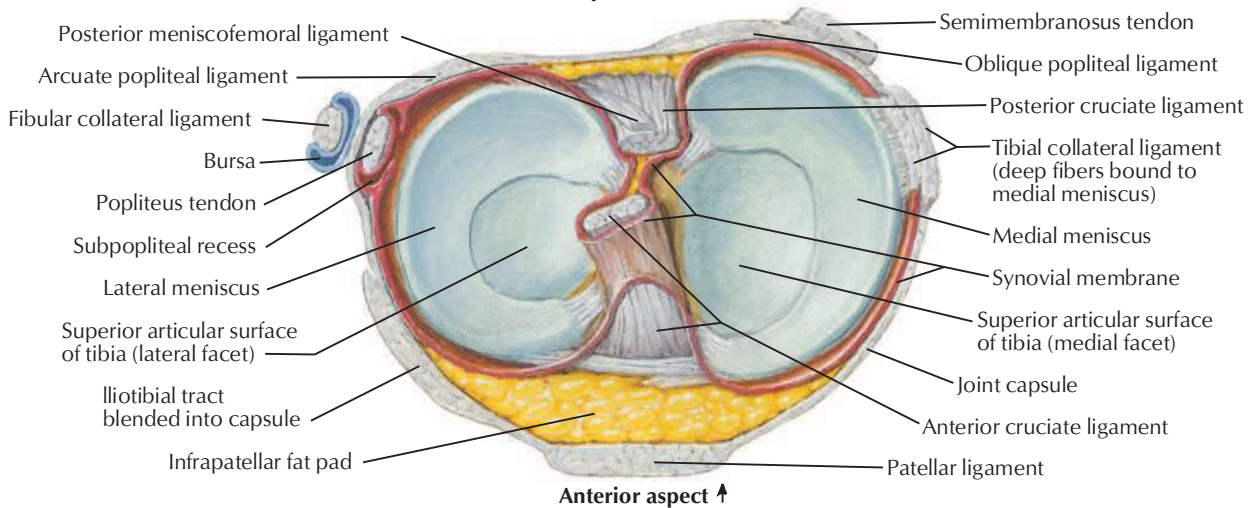
Joint opened, knee slightly in flexion



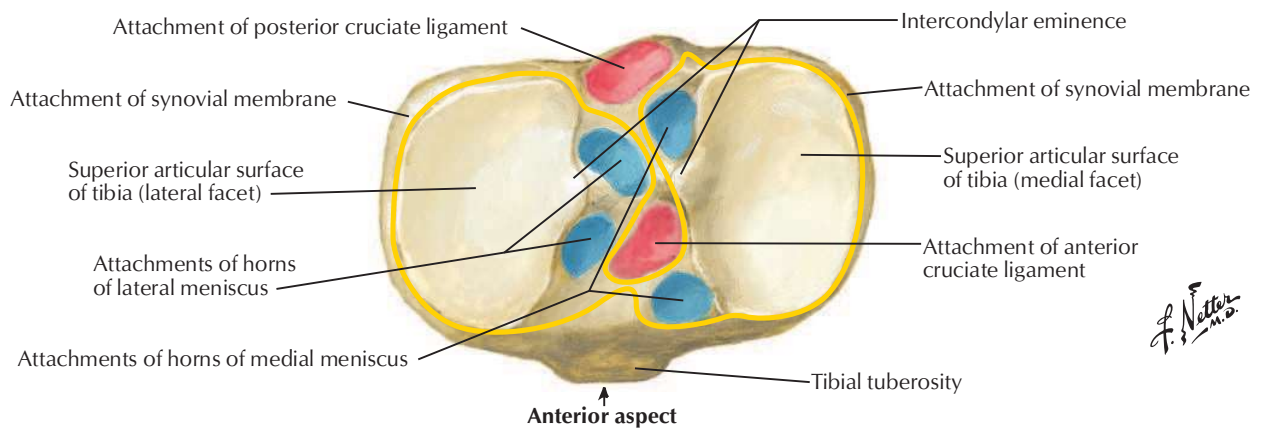
Inferior view



Superior view

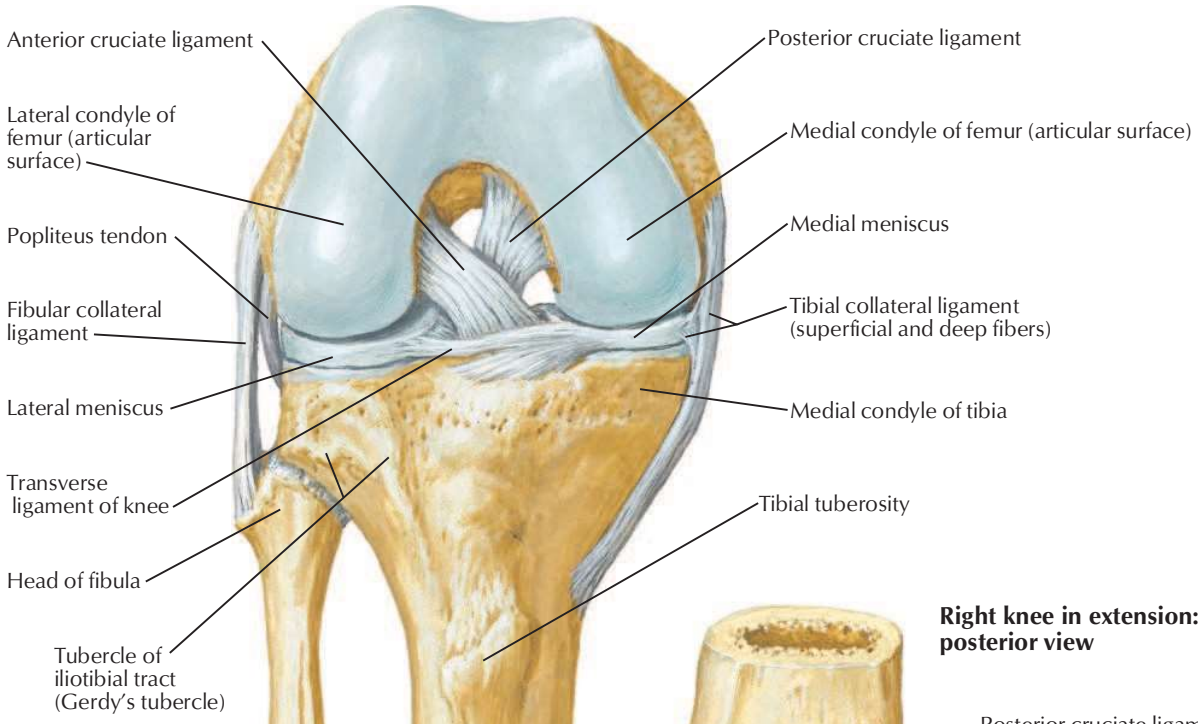


Superior view: ligaments and cartilage removed

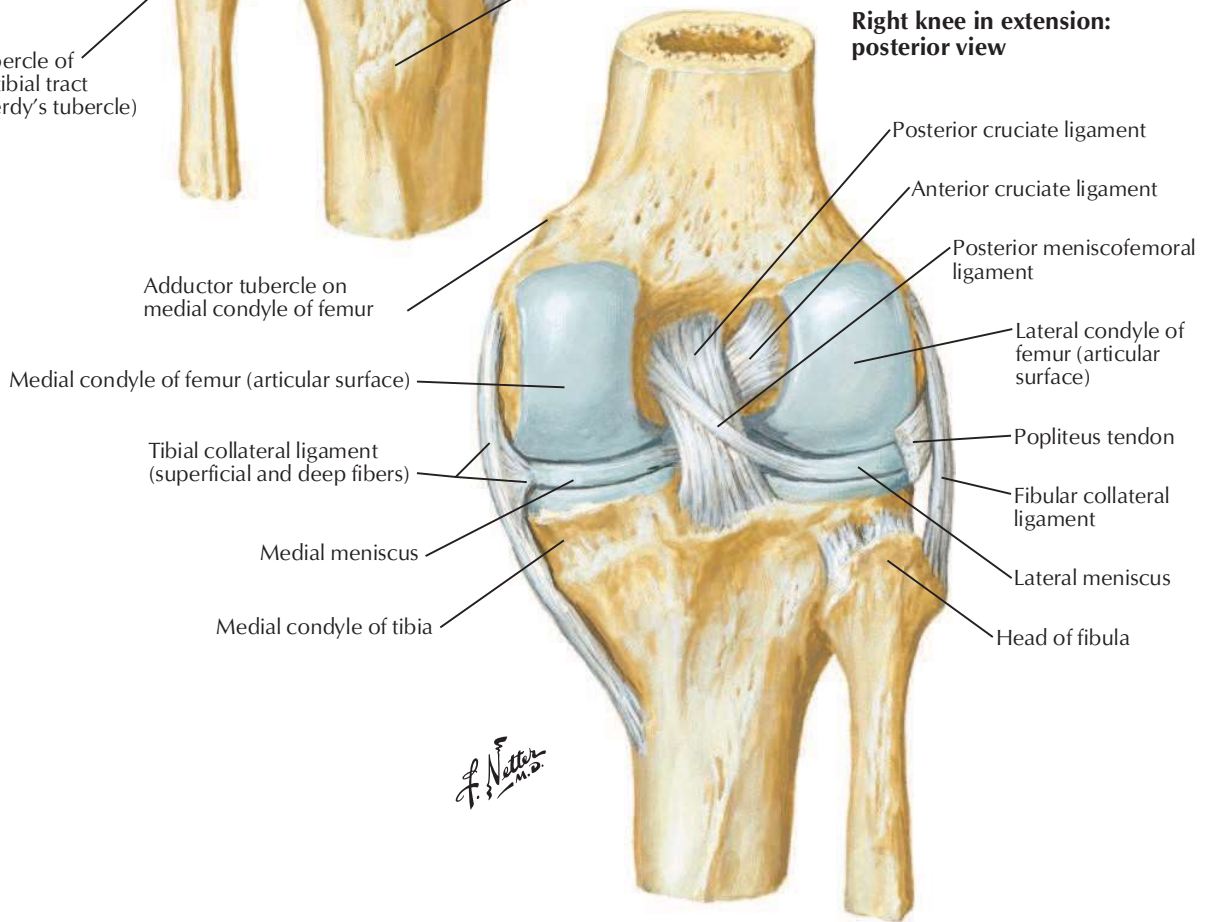


F. Netter M.D.

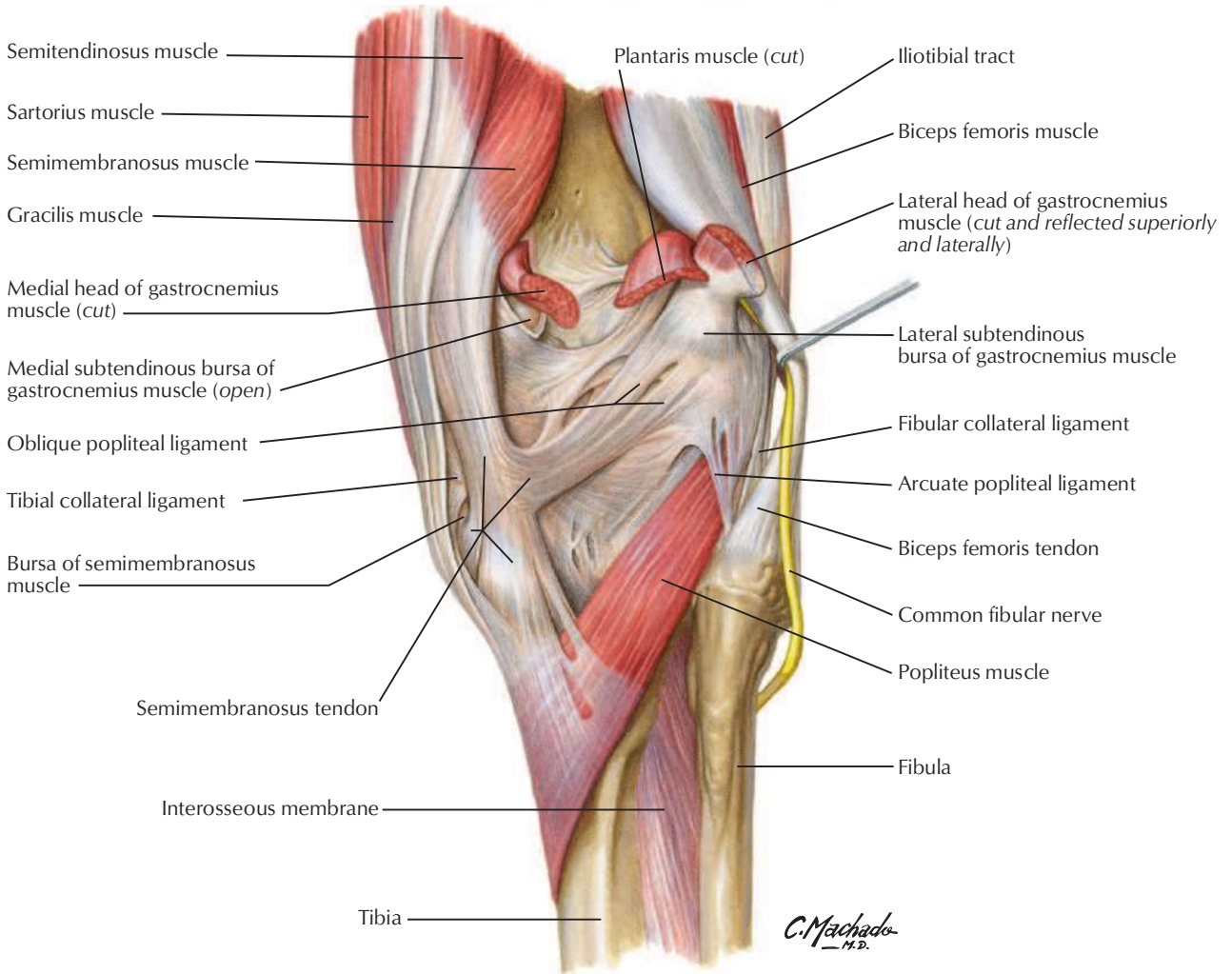
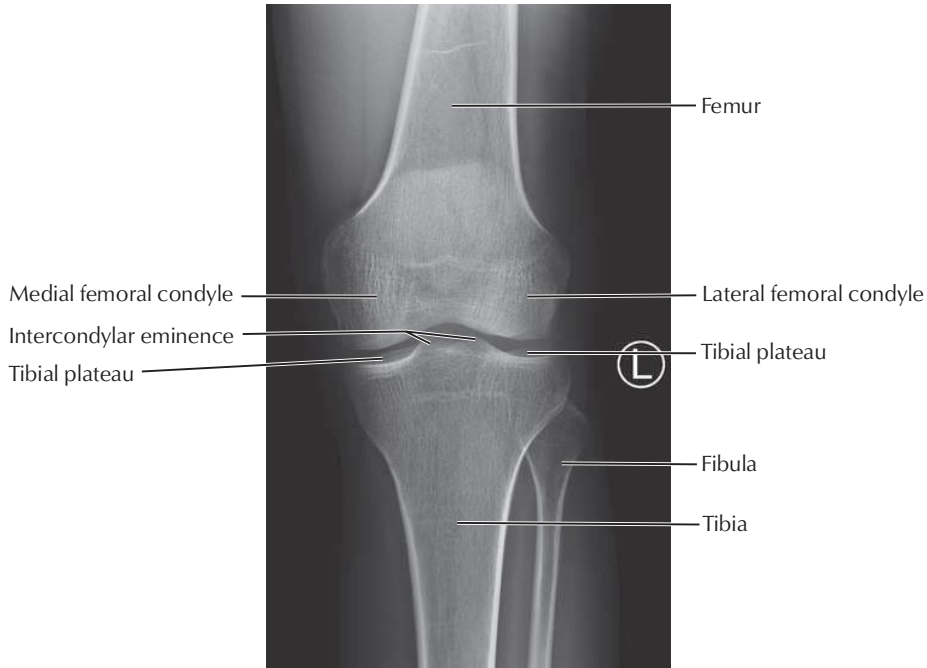
Right knee in flexion: anterior view



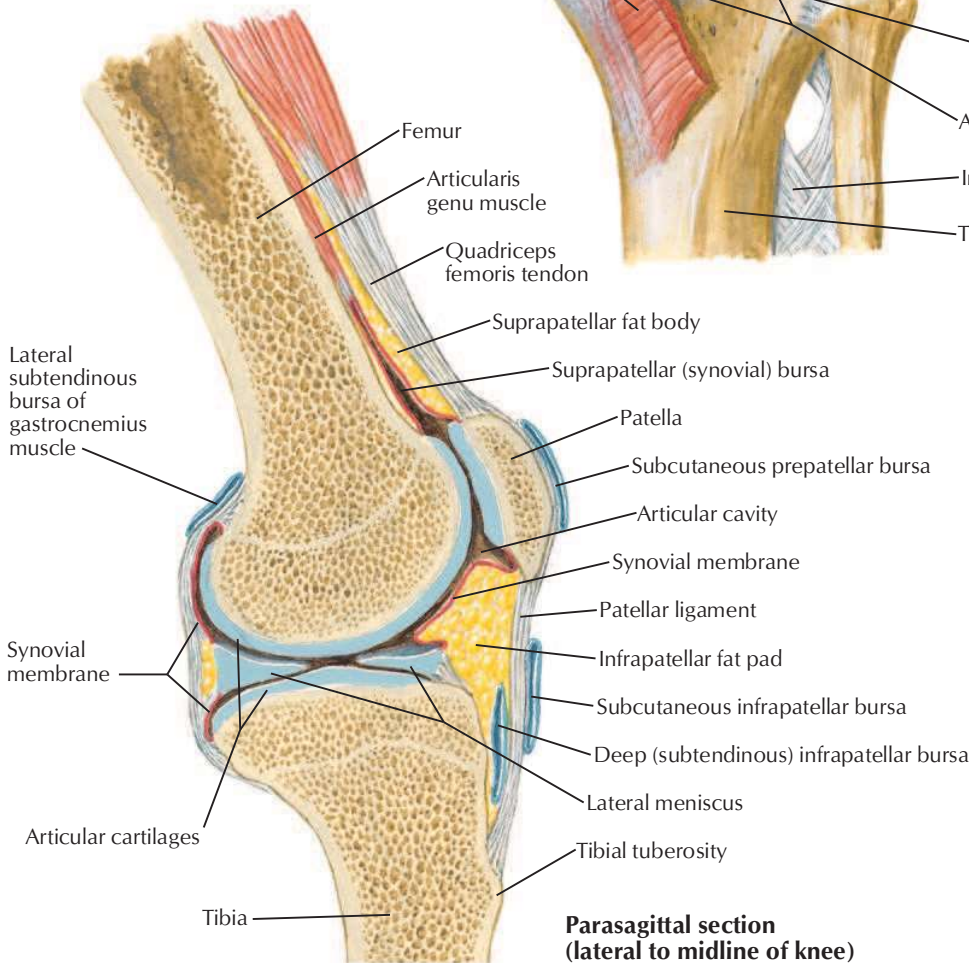
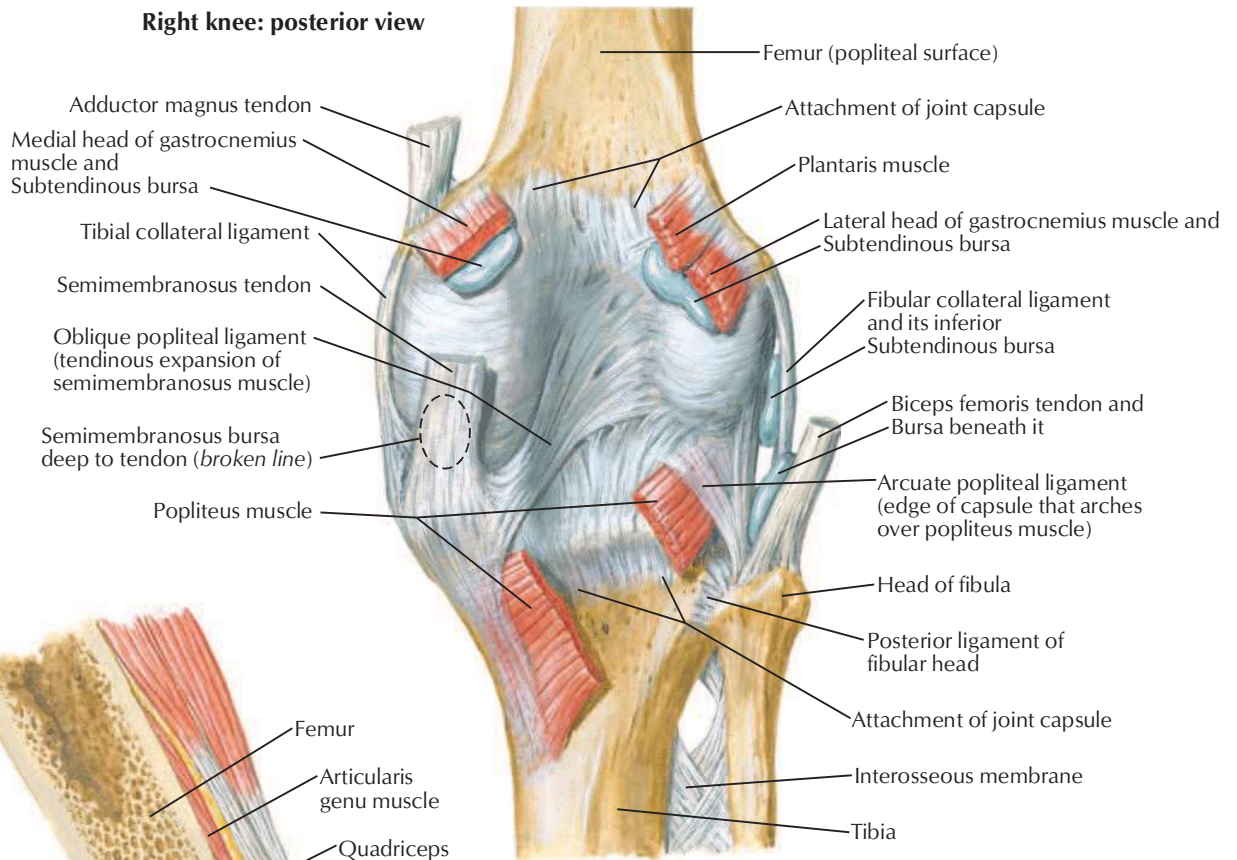
Right knee in extension: posterior view



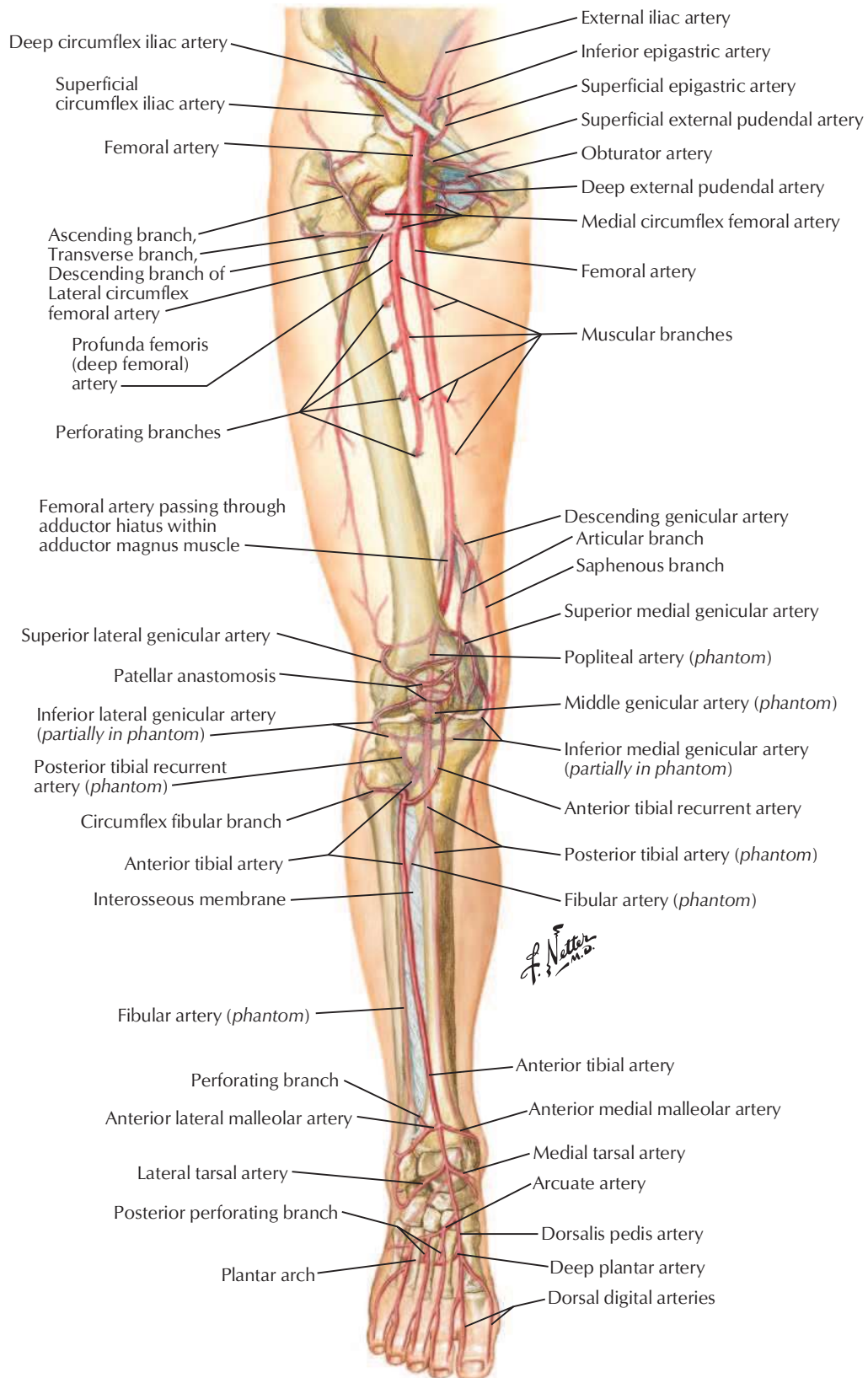
See also [Plate 498](#)



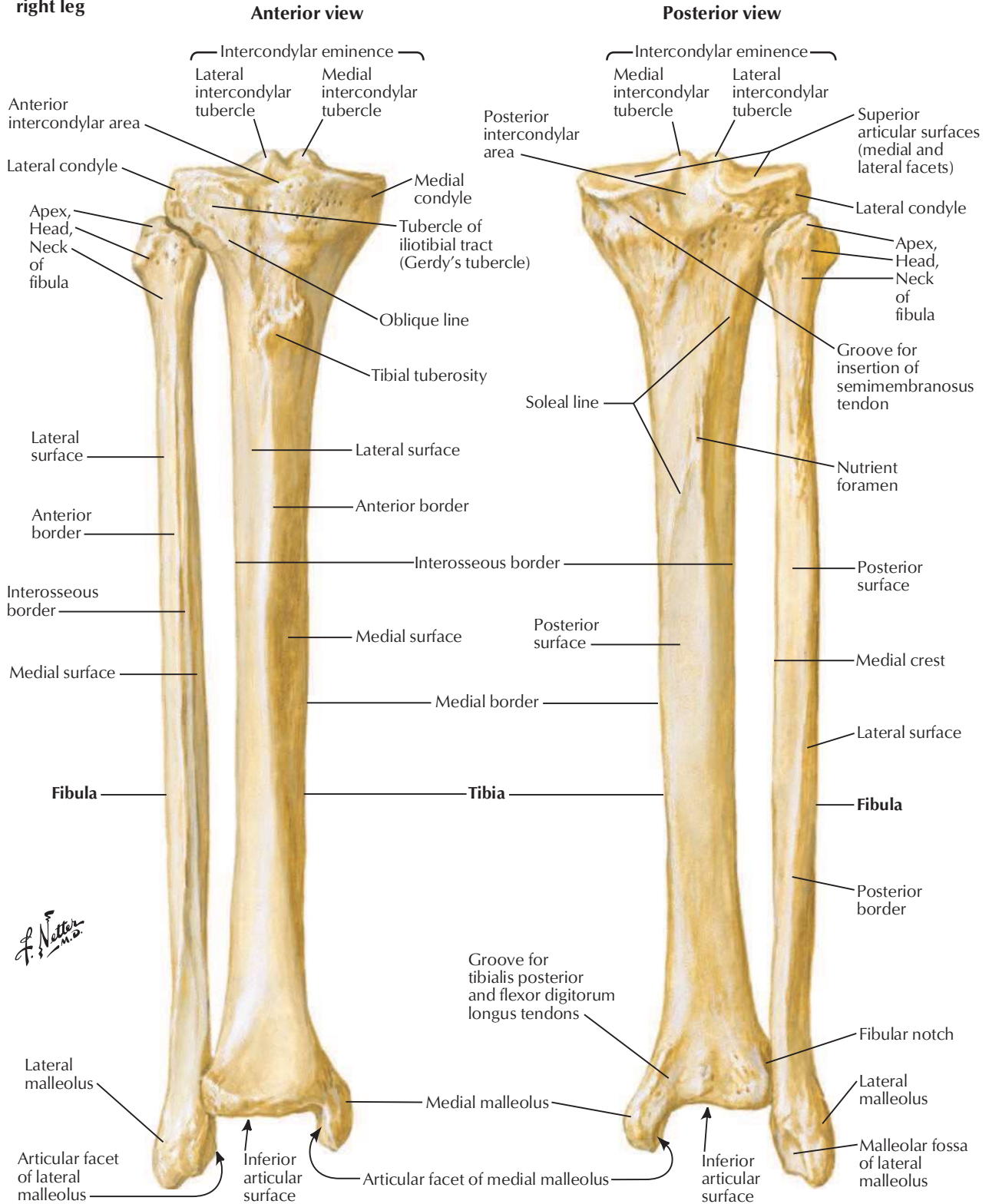
Right knee: posterior view

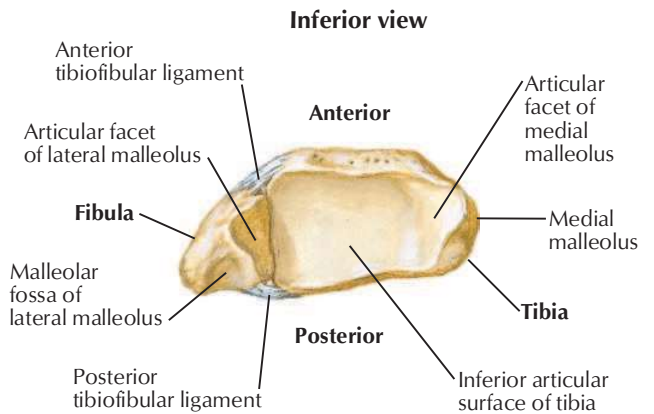
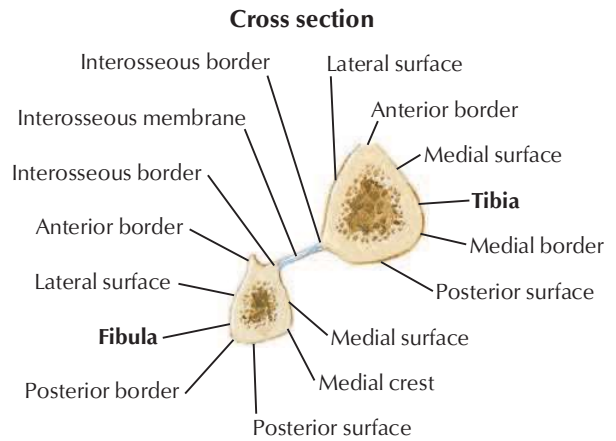
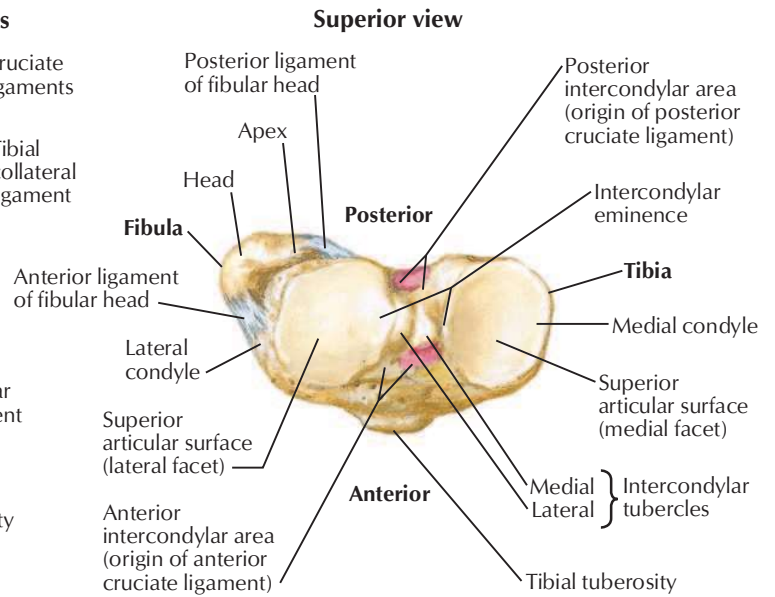
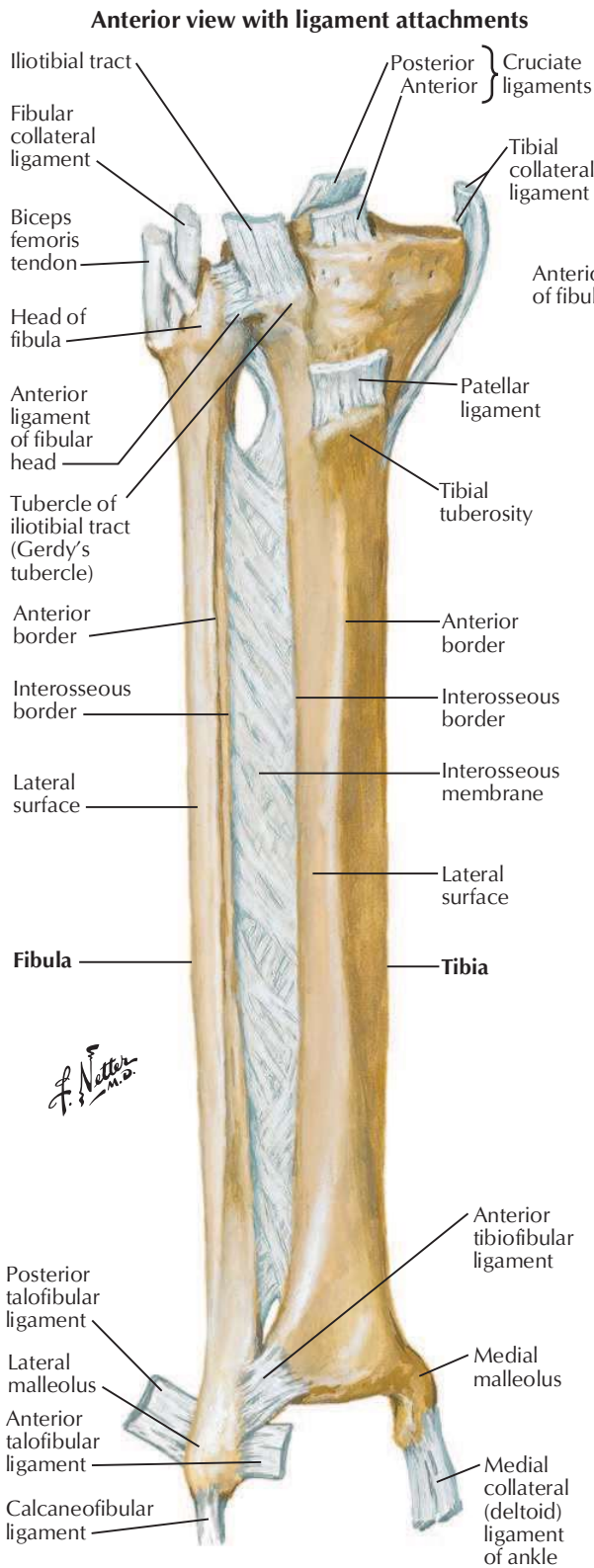


Parasagittal section (lateral to midline of knee)



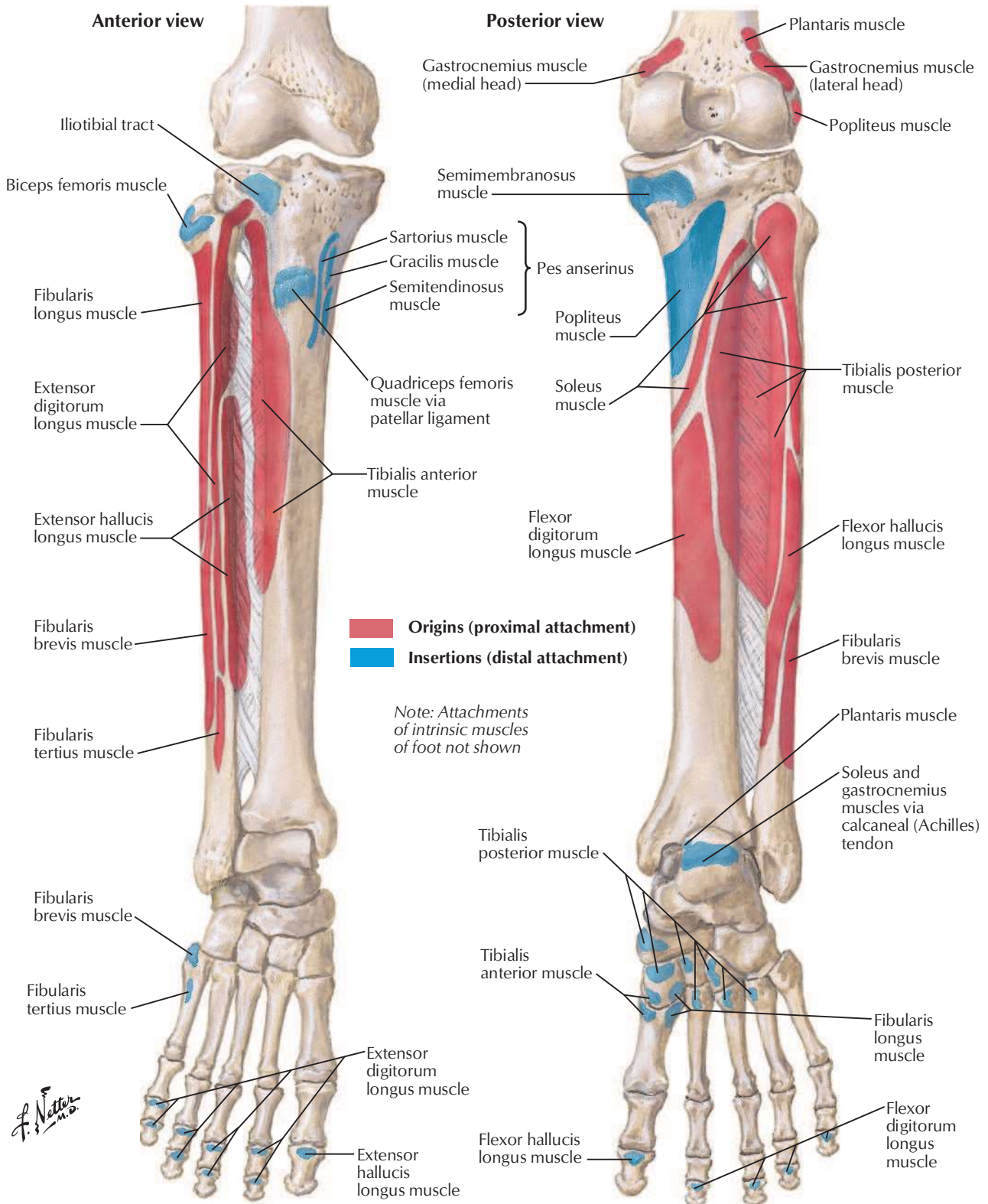
Bones of right leg



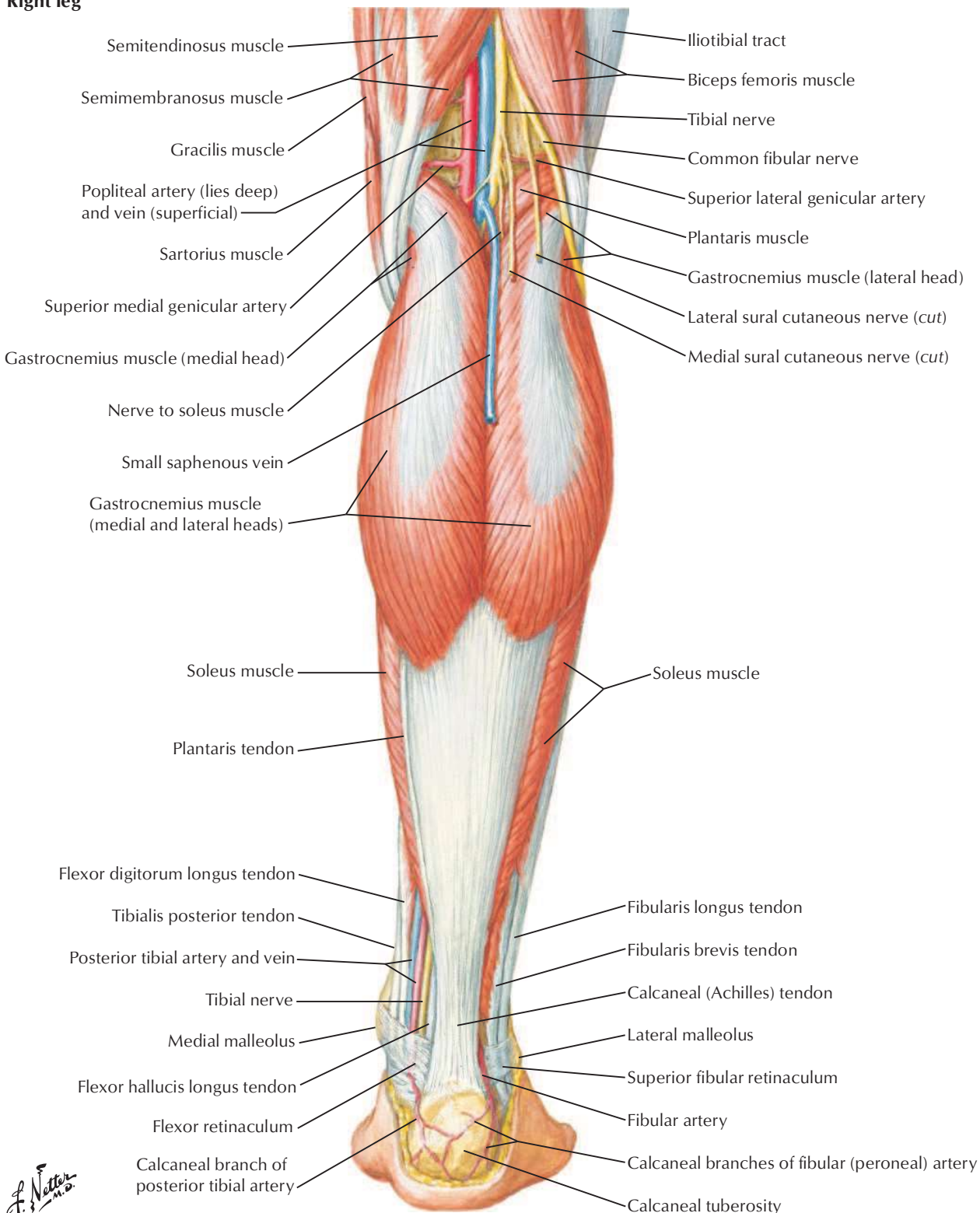


Attachments of Muscles of Leg

See also [Plates 509, 512](#)



Right leg

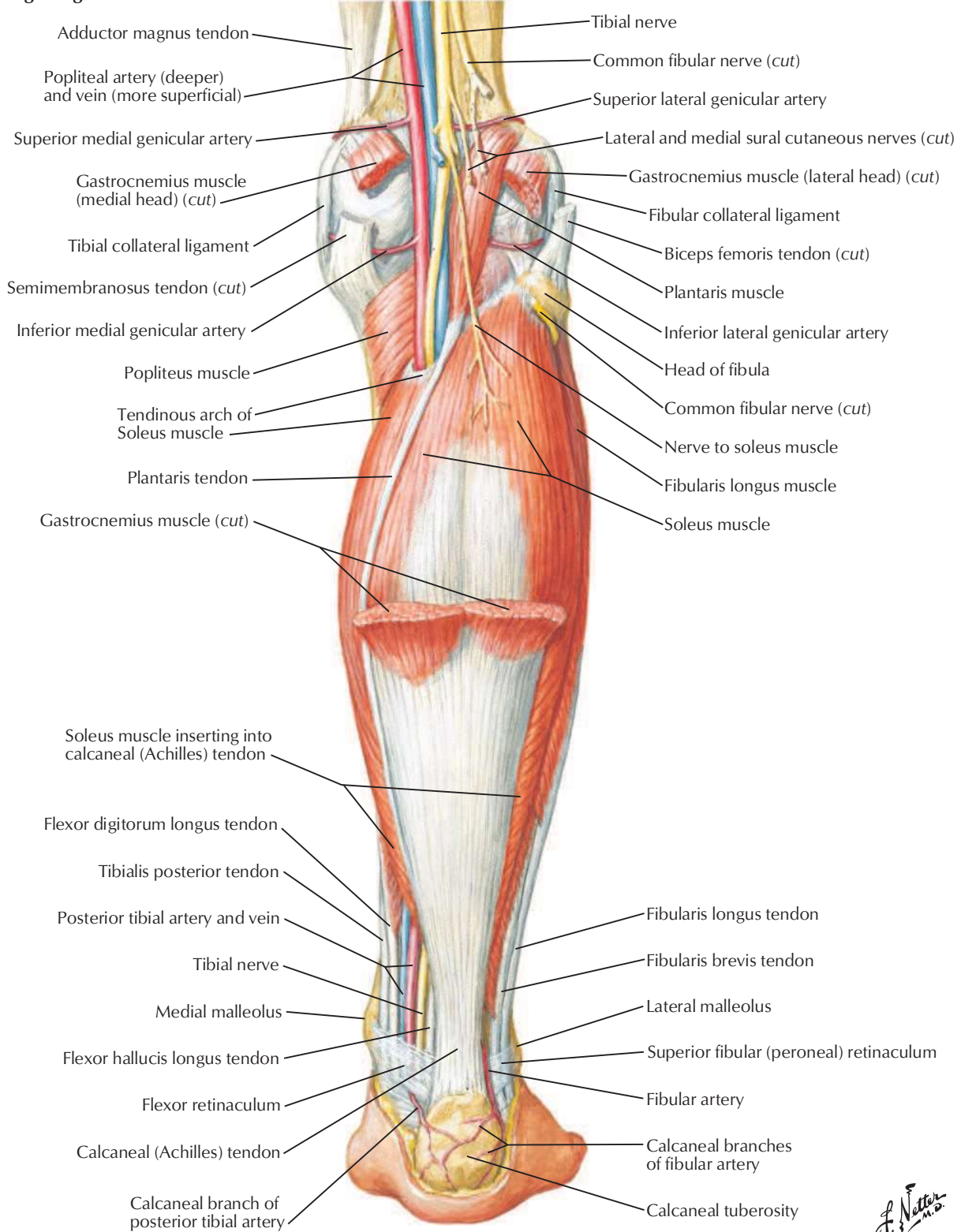


F. Netter M.D.

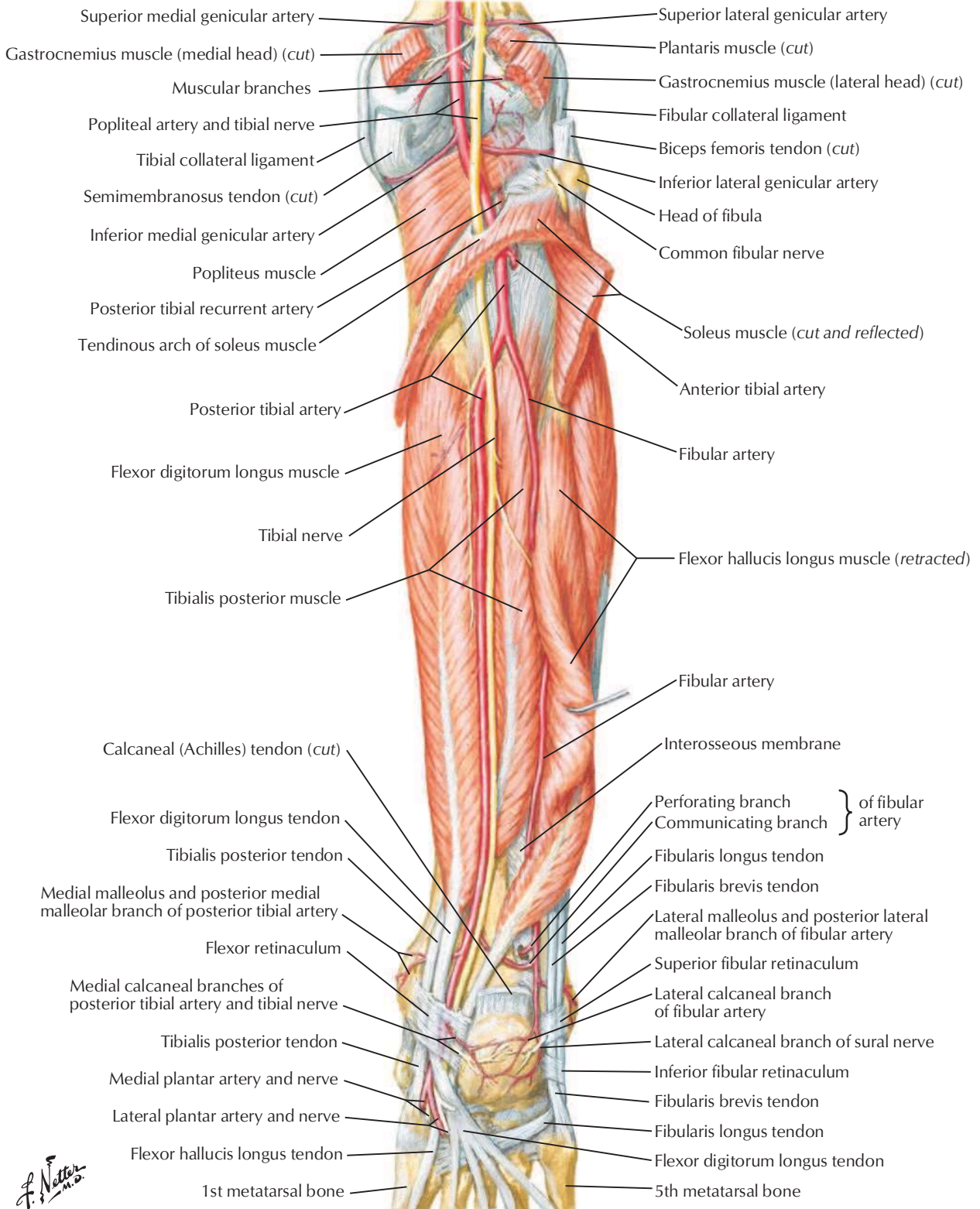
Muscles of Leg (Intermediate Dissection): Posterior View

See also [Plate 532](#)

Right leg



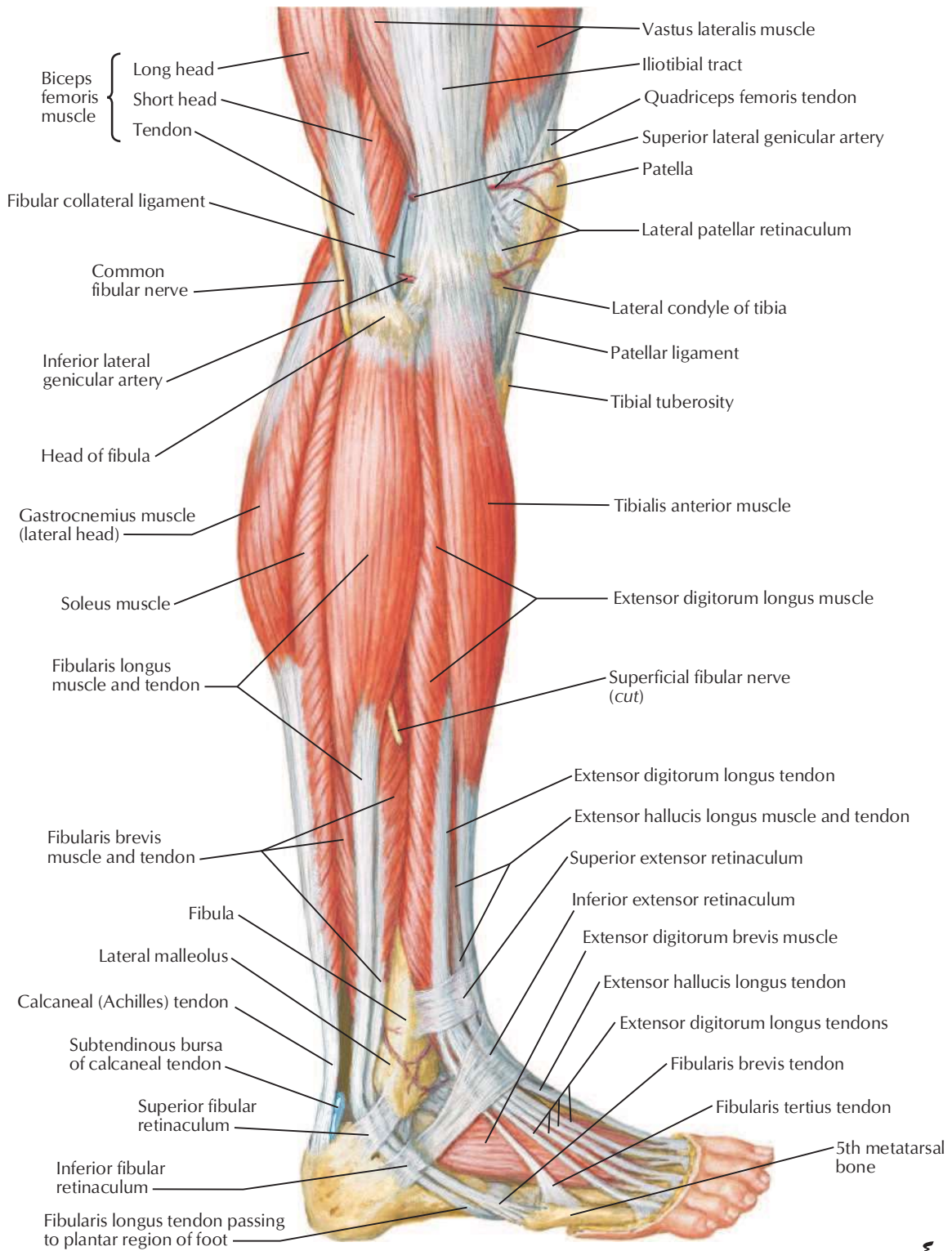
Right leg

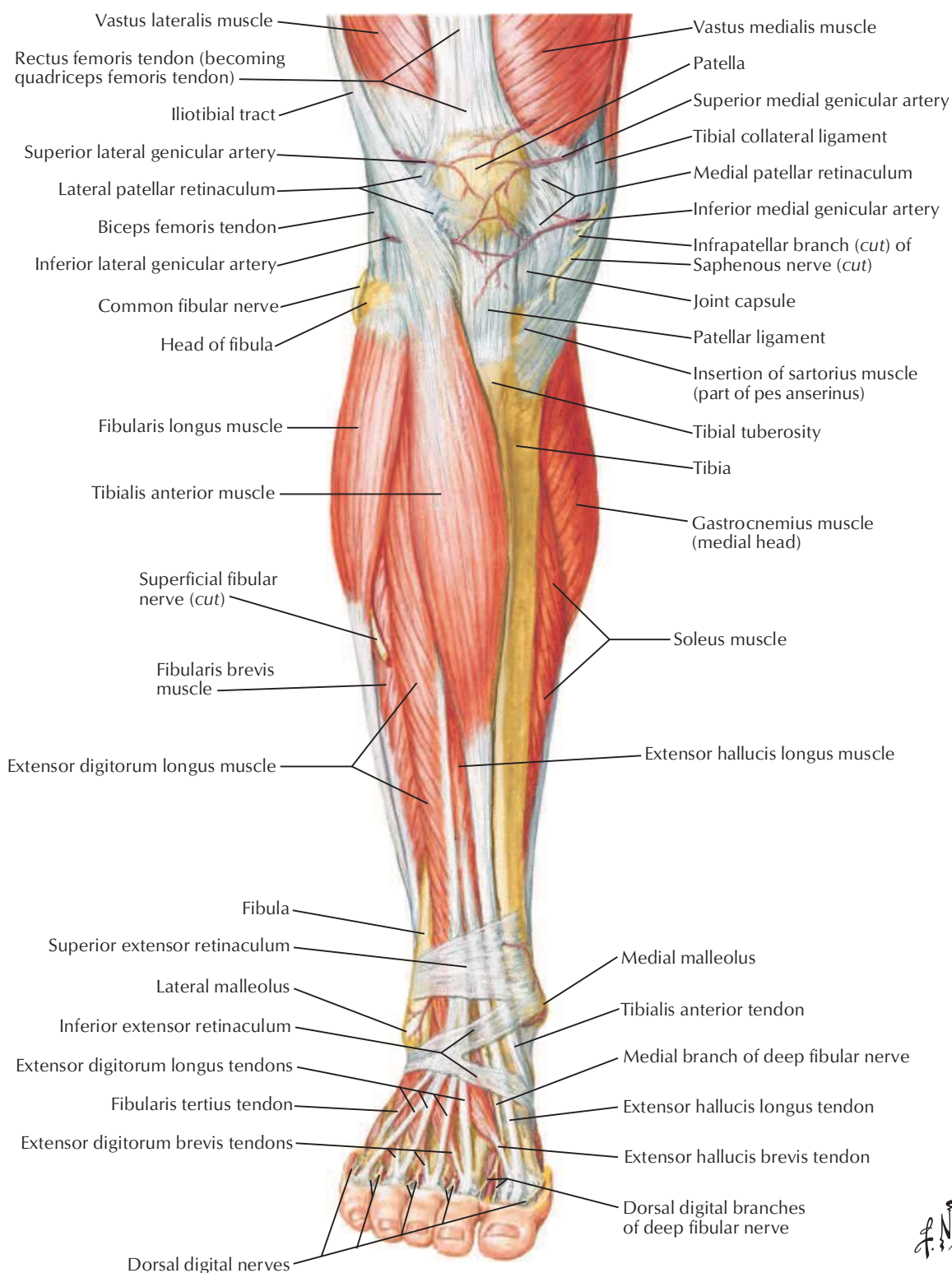


F. Netter M.D.

Muscles of Leg: Lateral View

See also [Plates 520, 533](#)

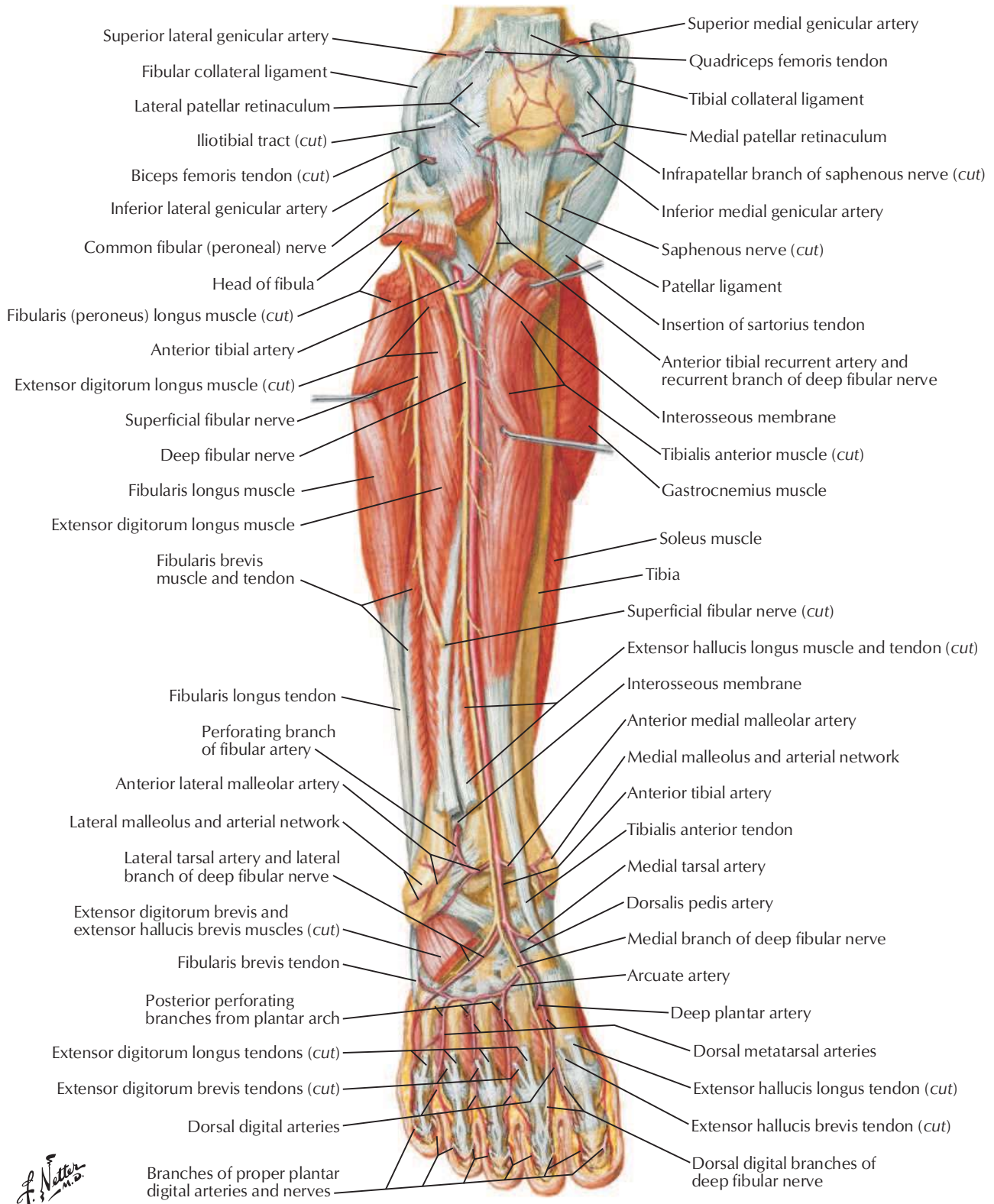


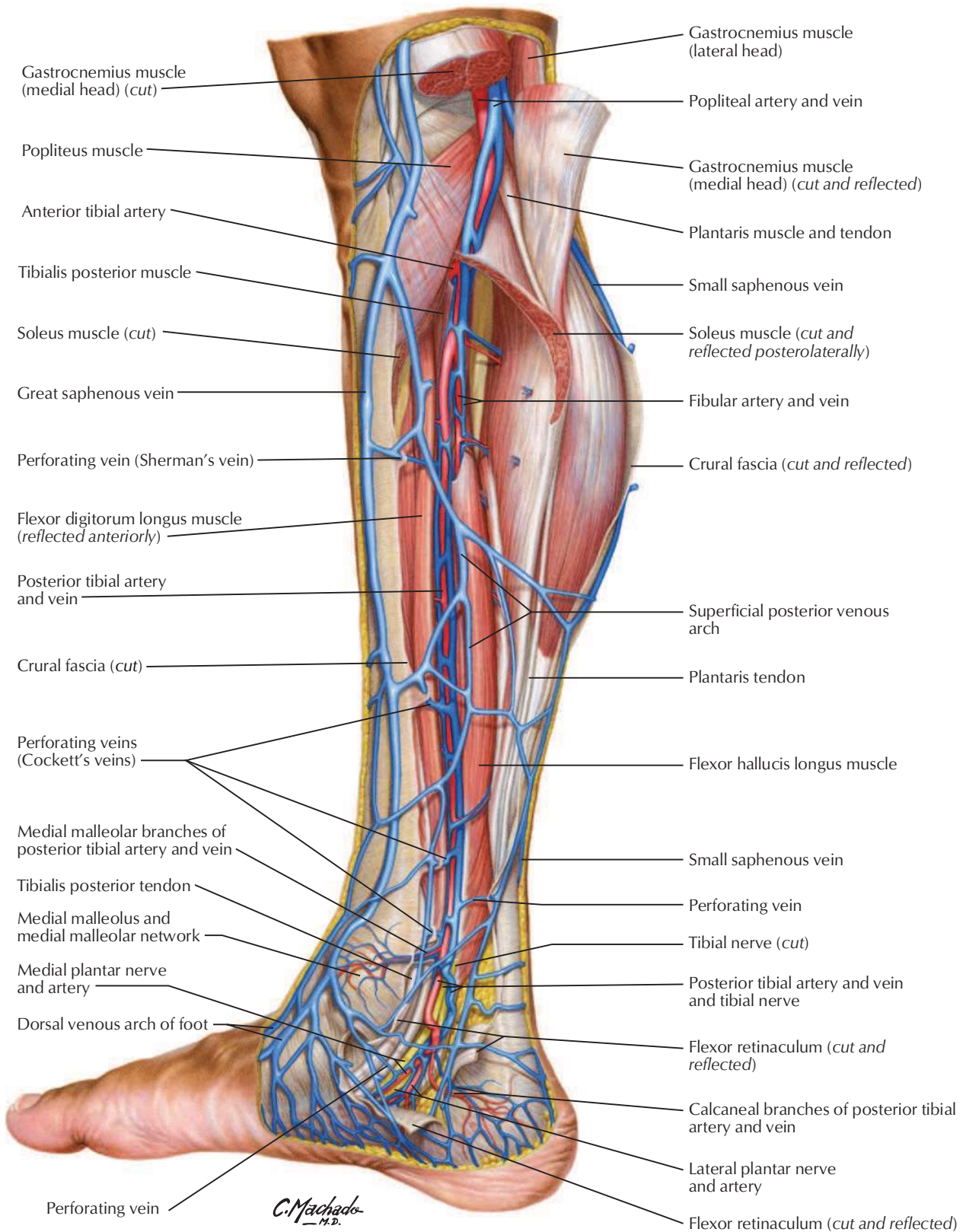


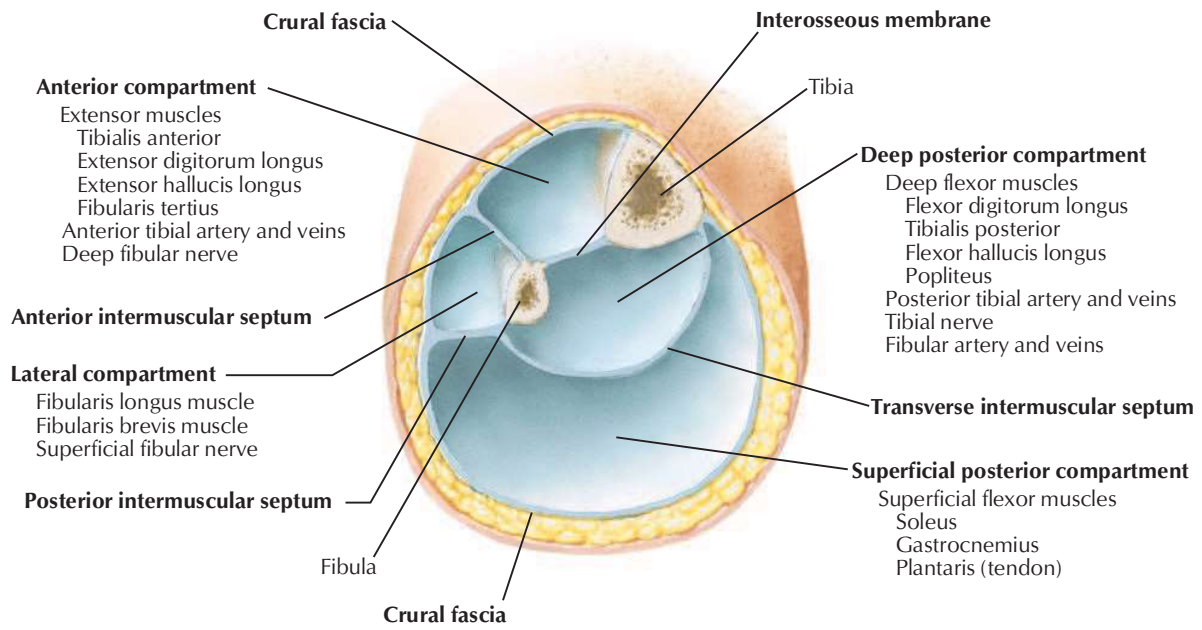
F. Netter M.D.

Muscles of Leg (Deep Dissection): Anterior View

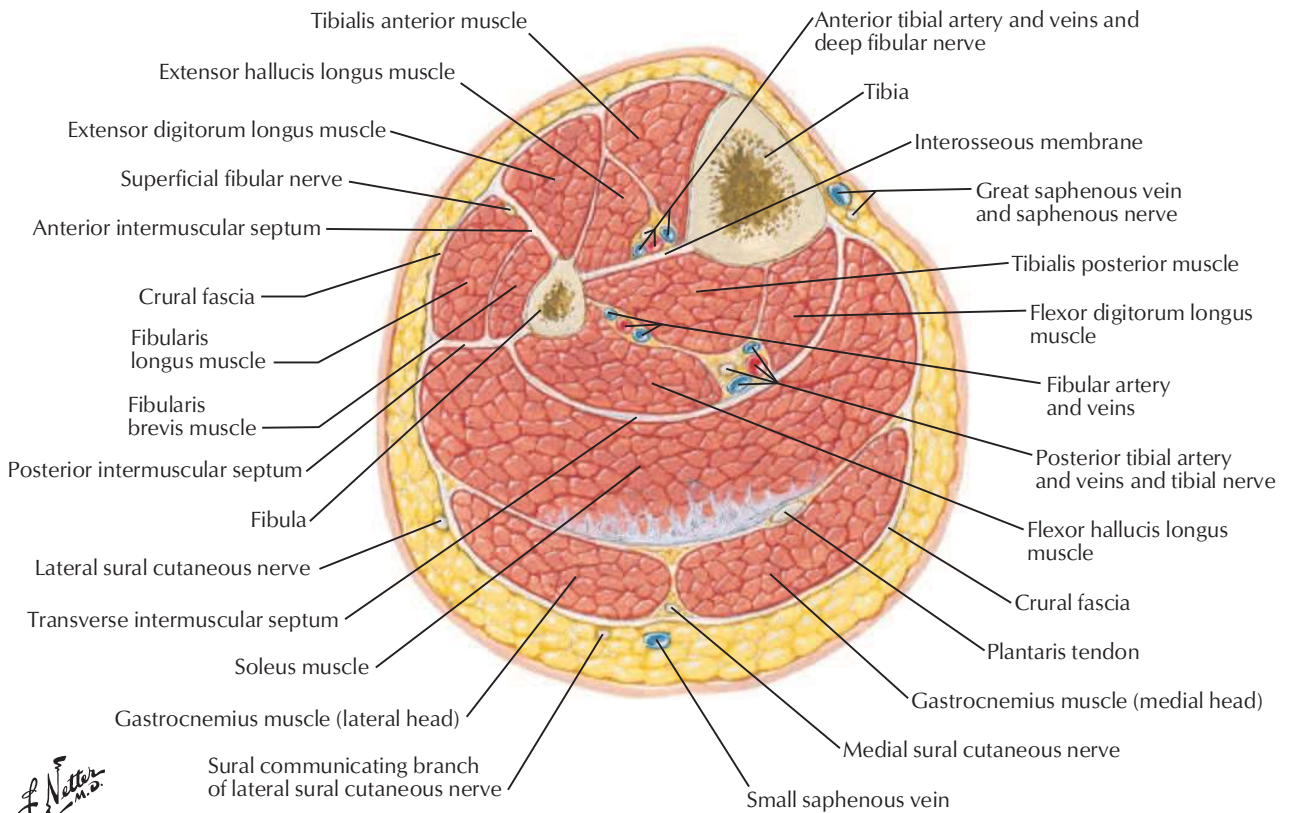
See also [Plates 521, 533](#)

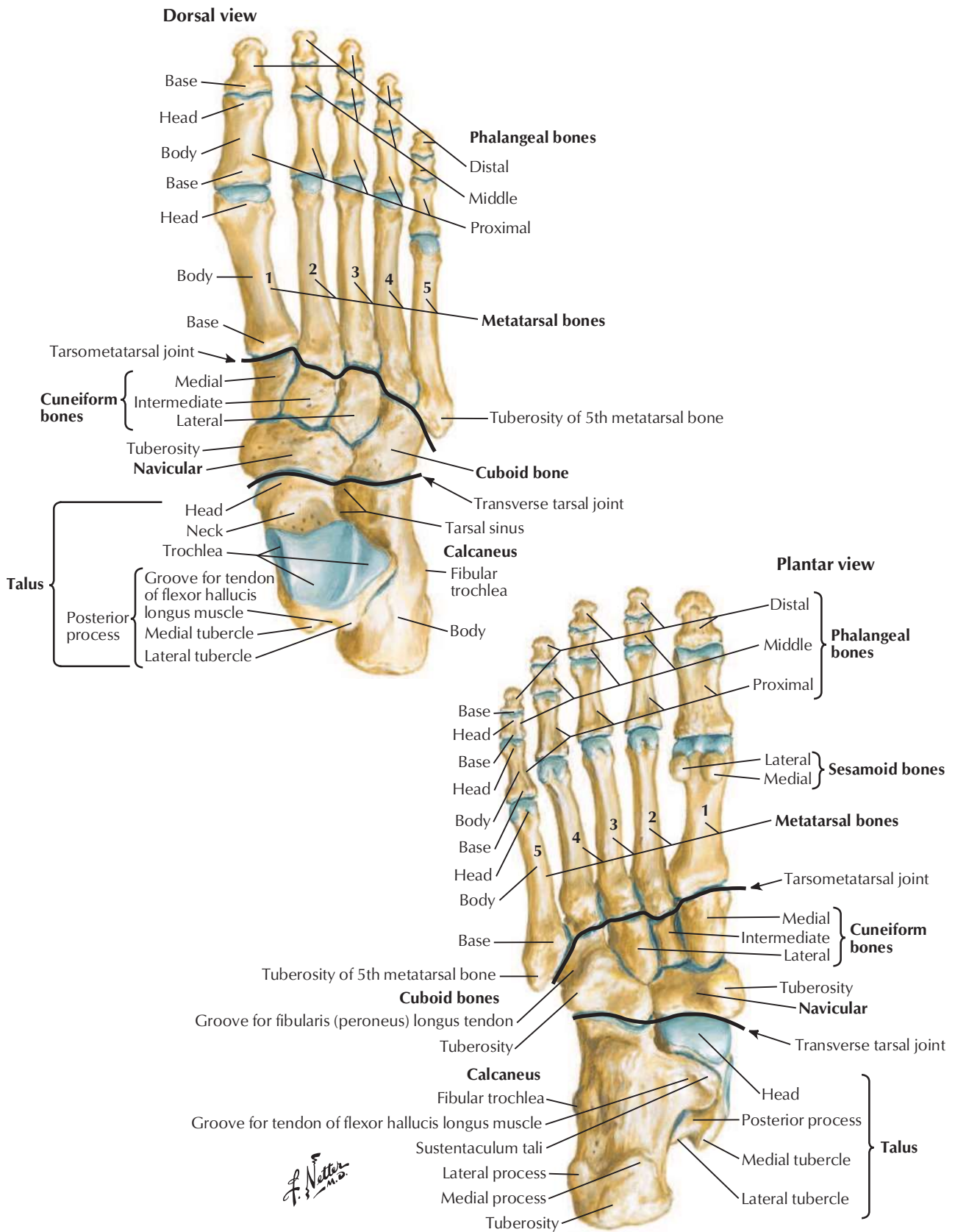


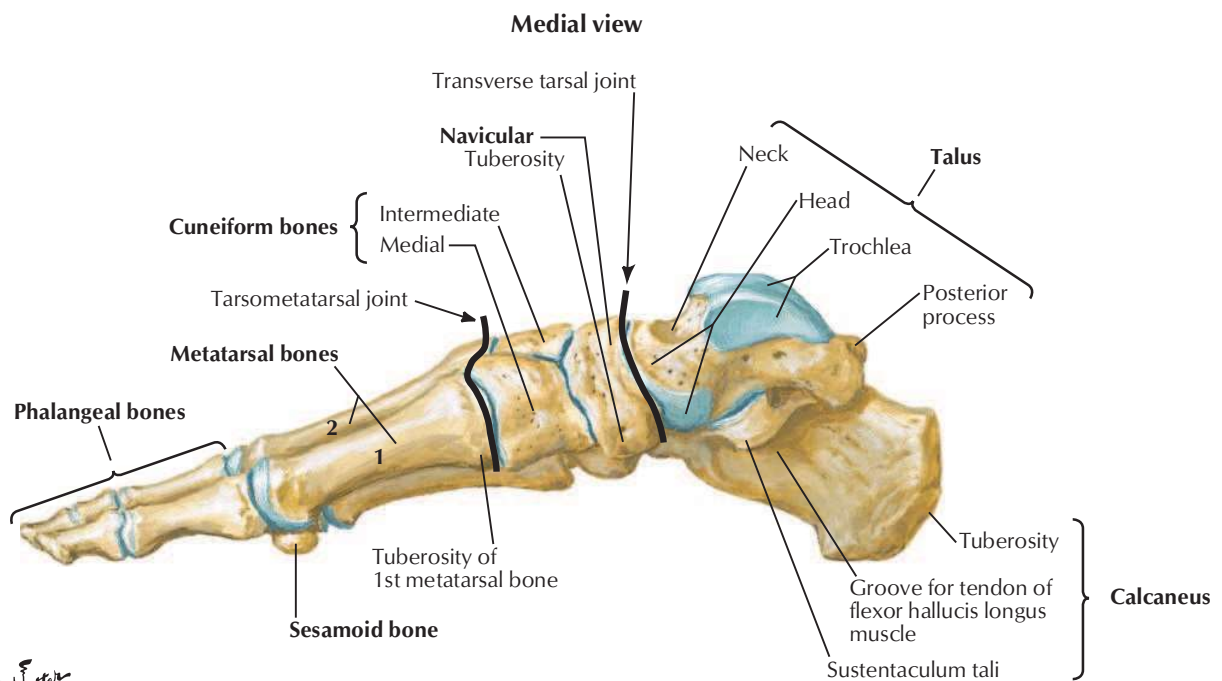
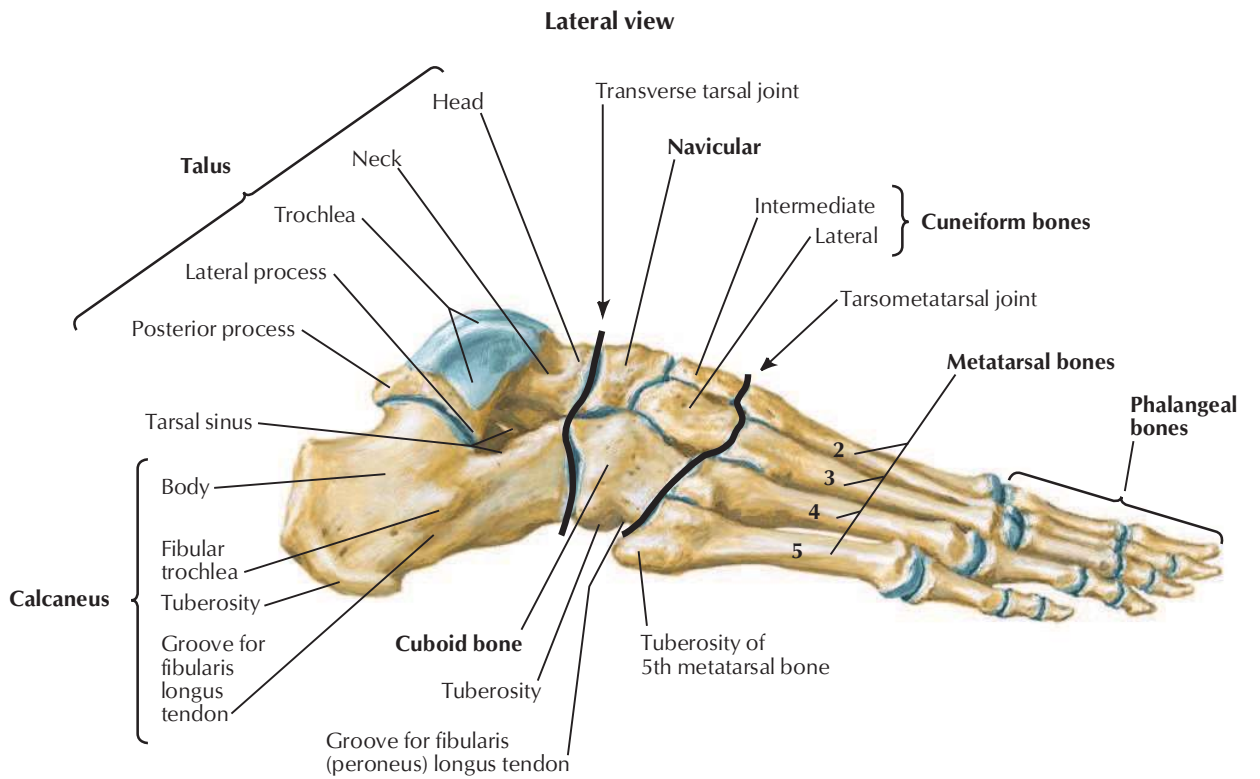




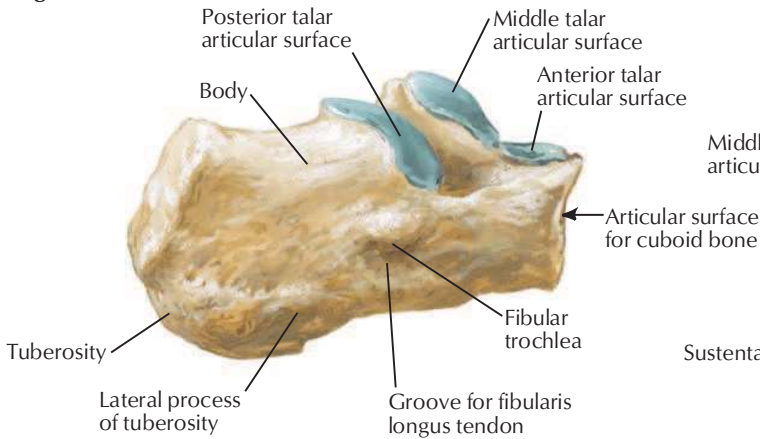
Cross section just above middle of leg



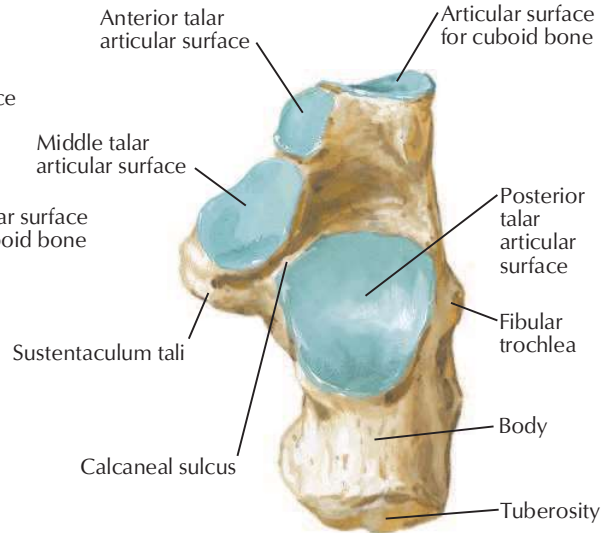




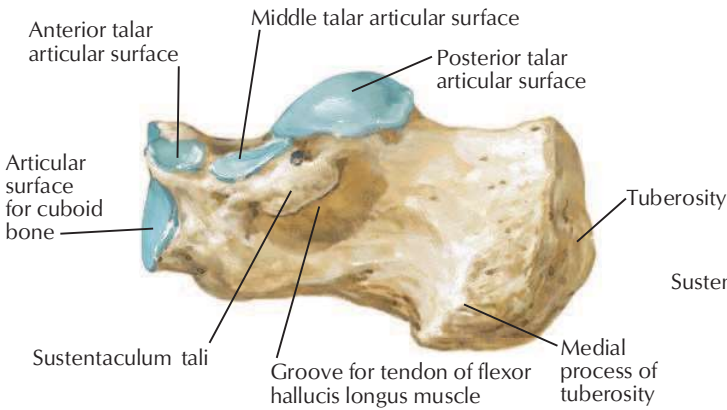
Right foot



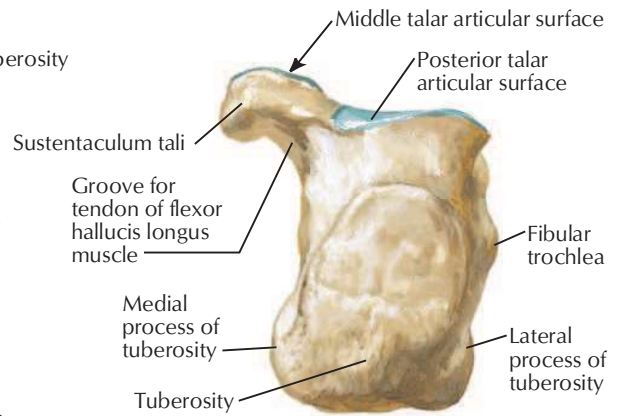
Lateral view



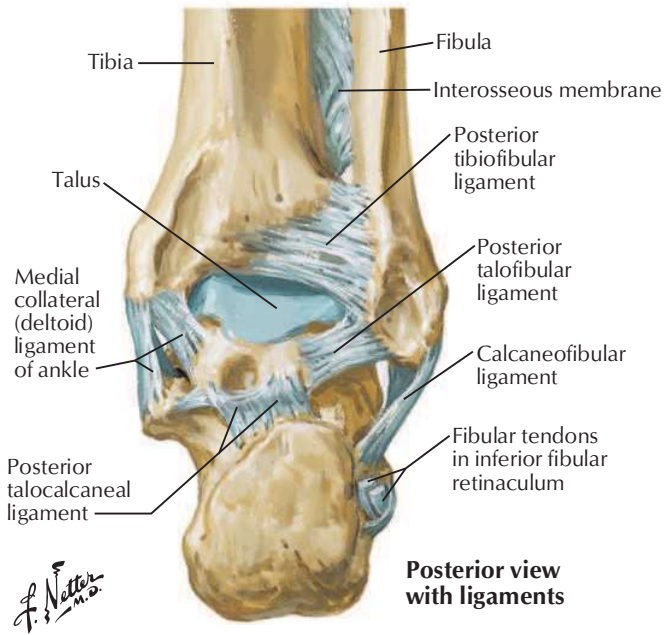
Superior view



Medial view

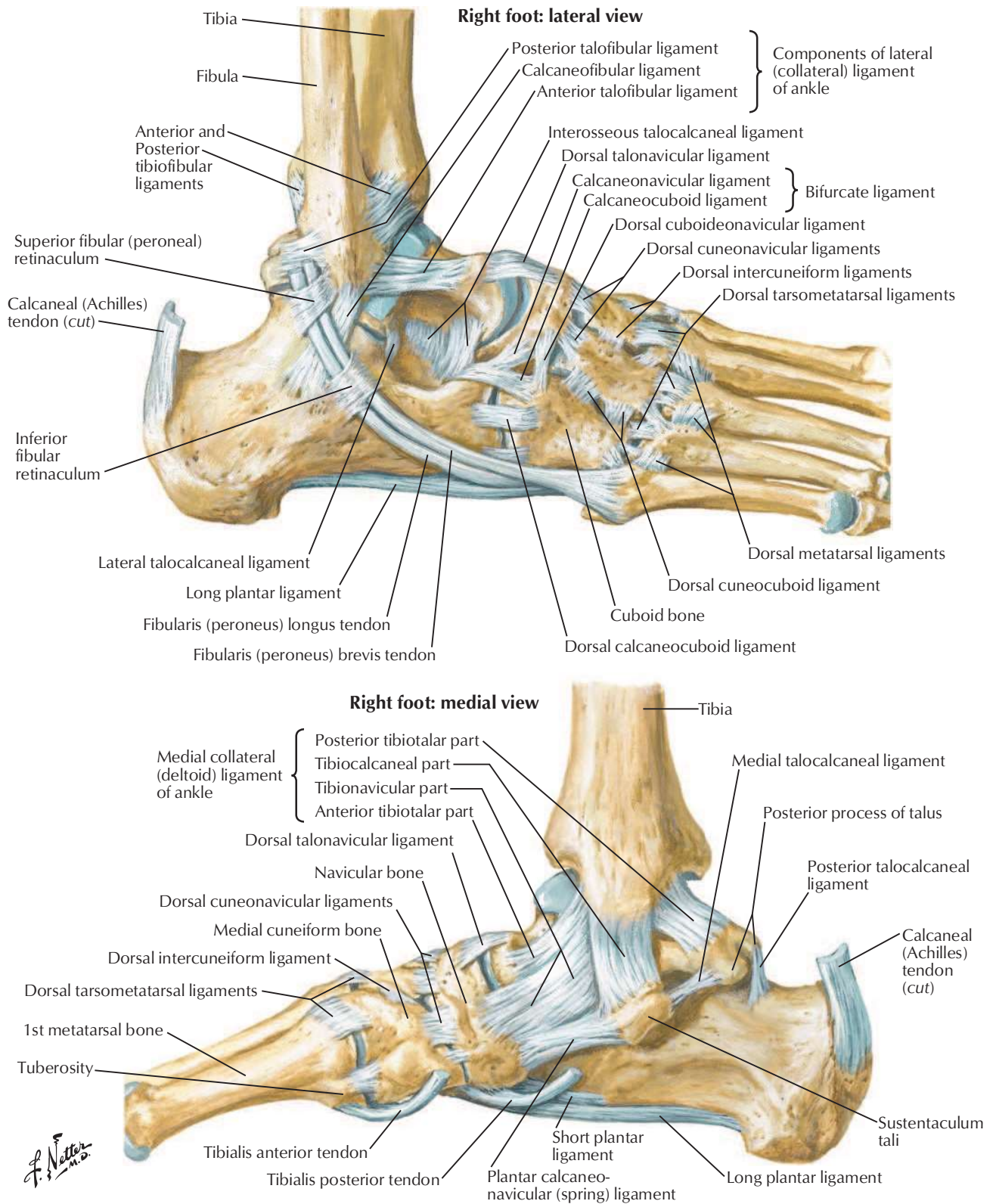


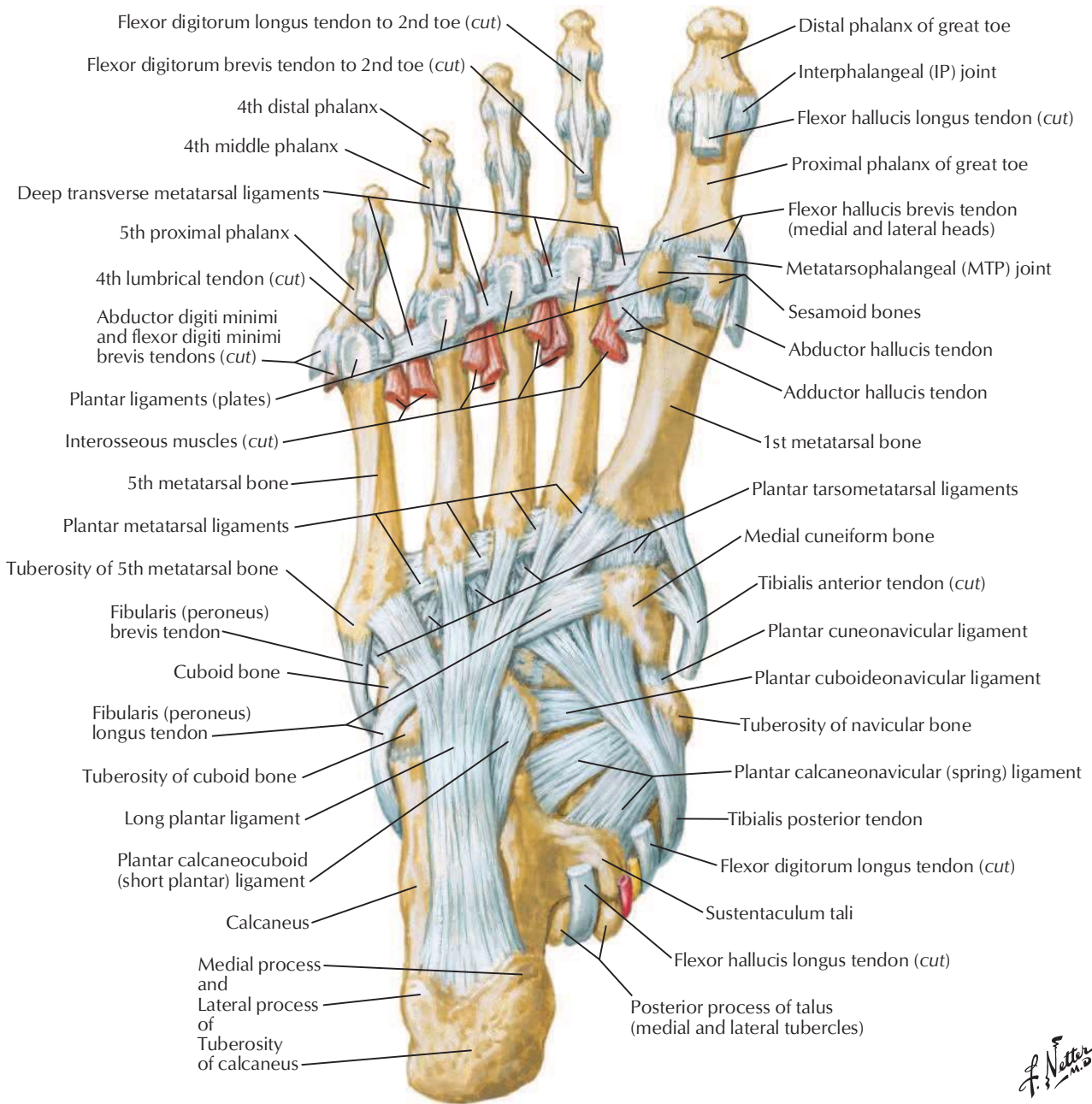
Posterior view



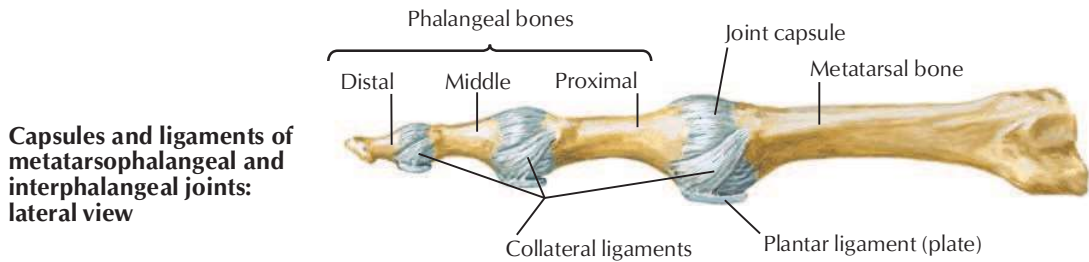
Posterior view with ligaments

F. Netter M.D.





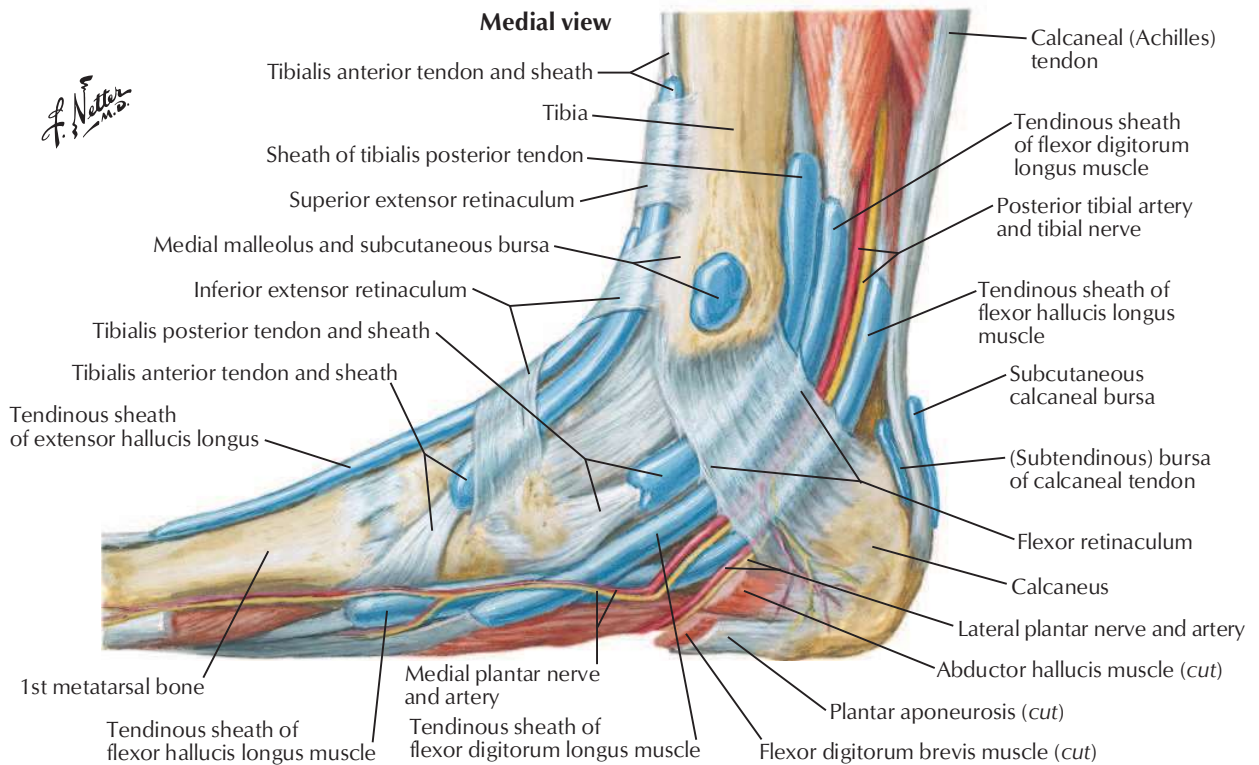
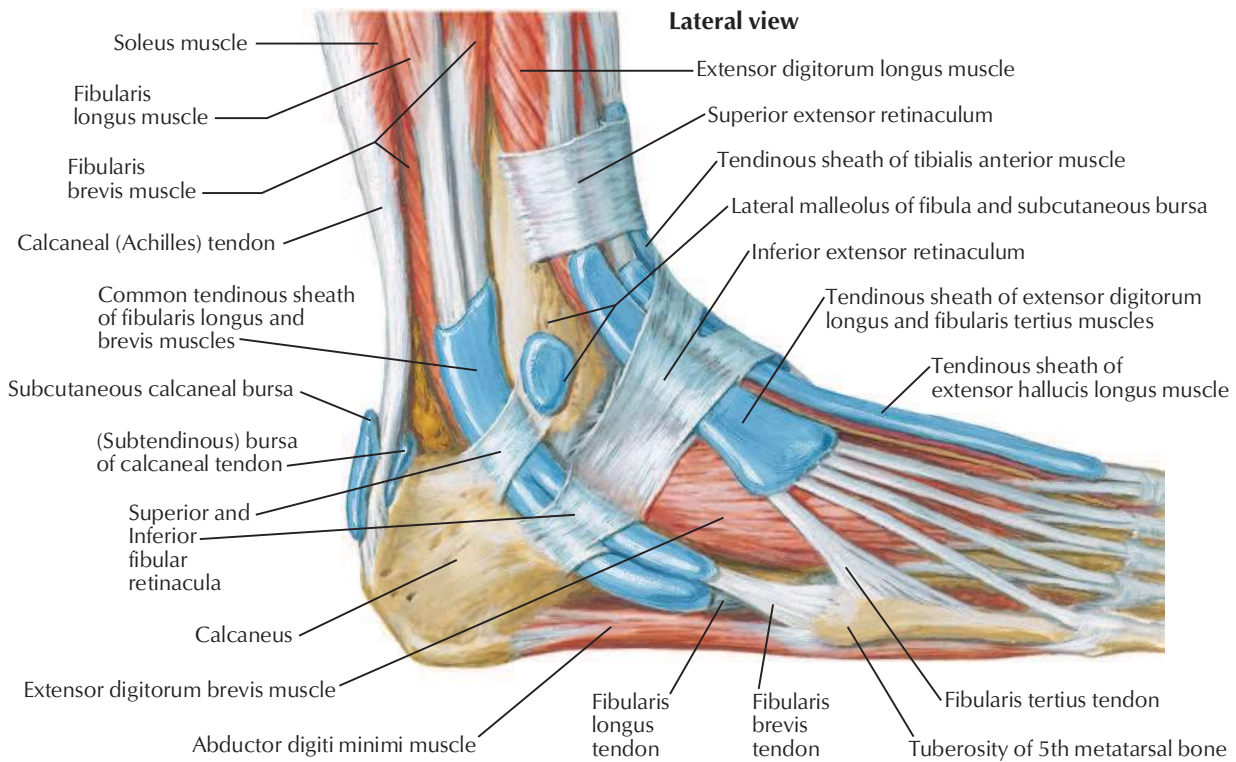
F. Netter M.D.

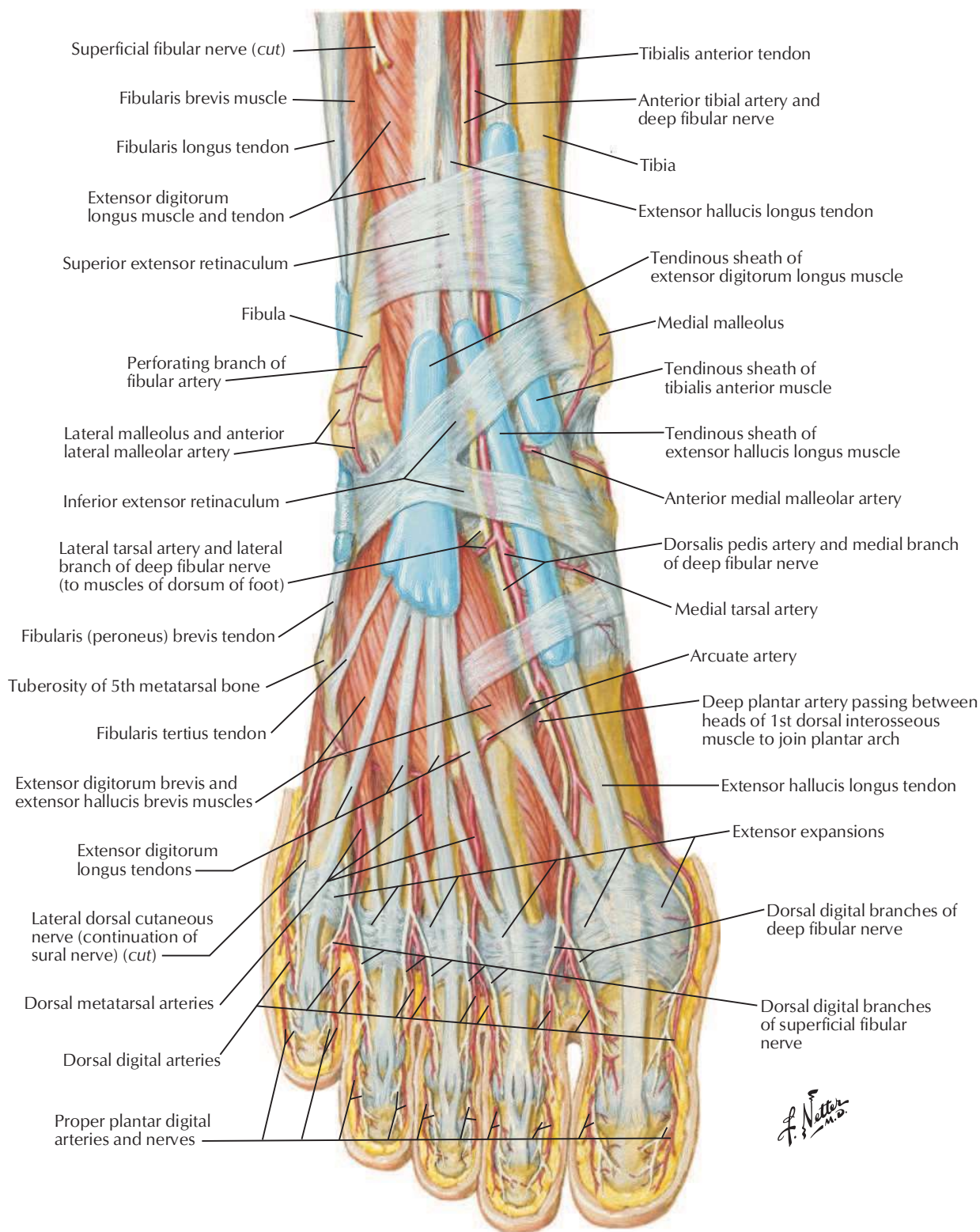


Capsules and ligaments of metatarsophalangeal and interphalangeal joints: lateral view

Tendon Sheaths of Ankle

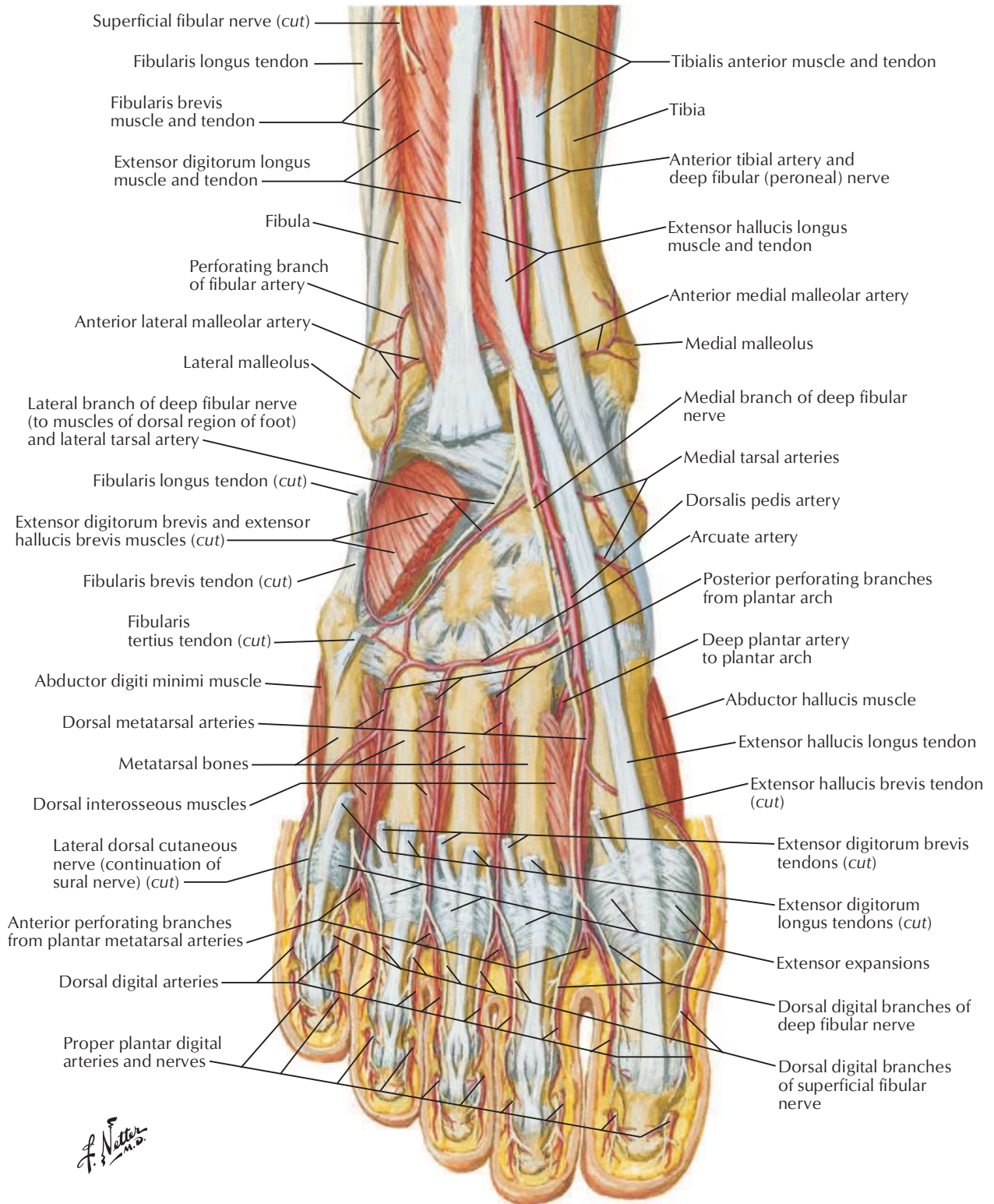
See also [Plate 510](#)

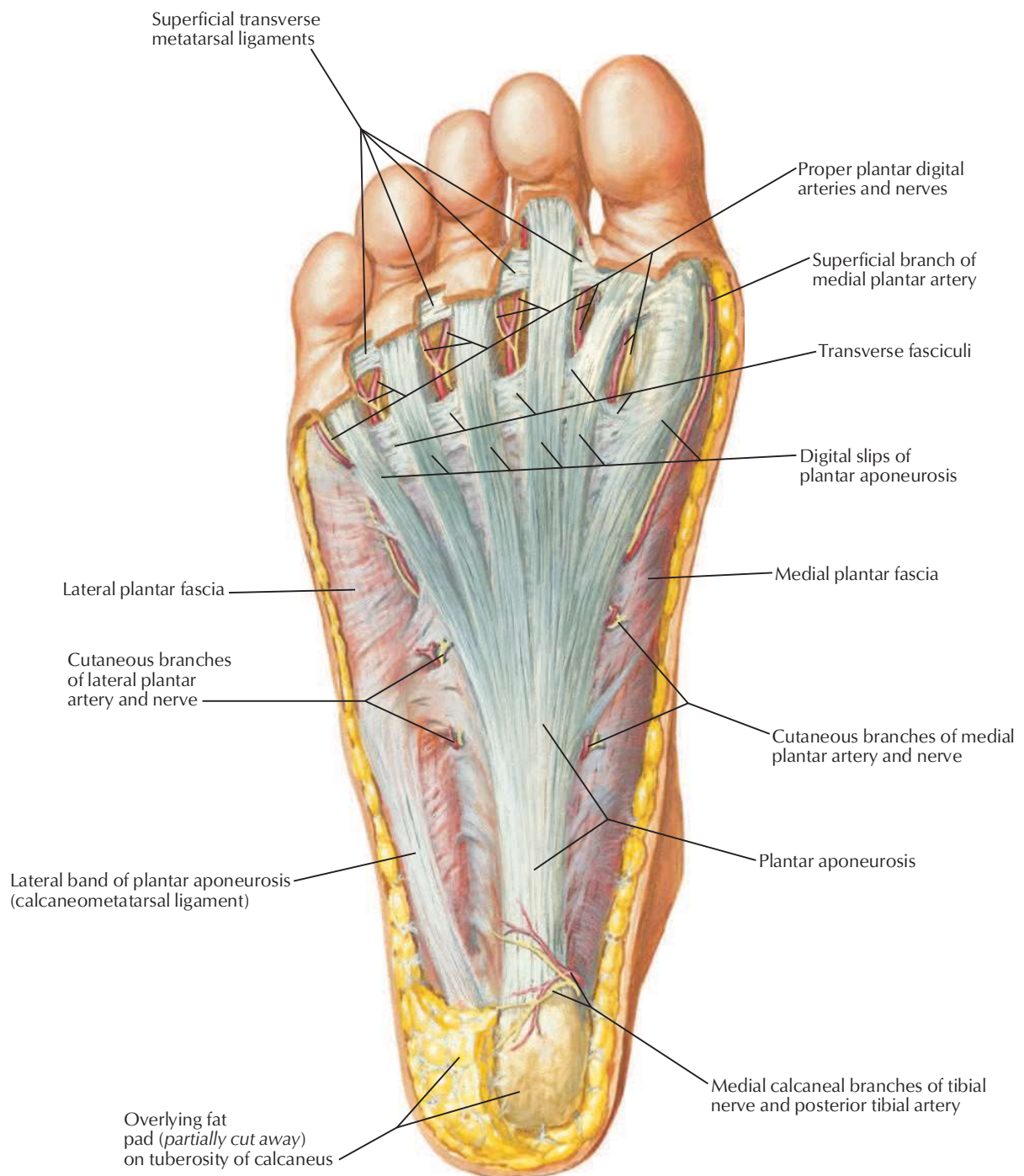




Dorsum of Foot: Deep Dissection

See also [Plate 527](#)



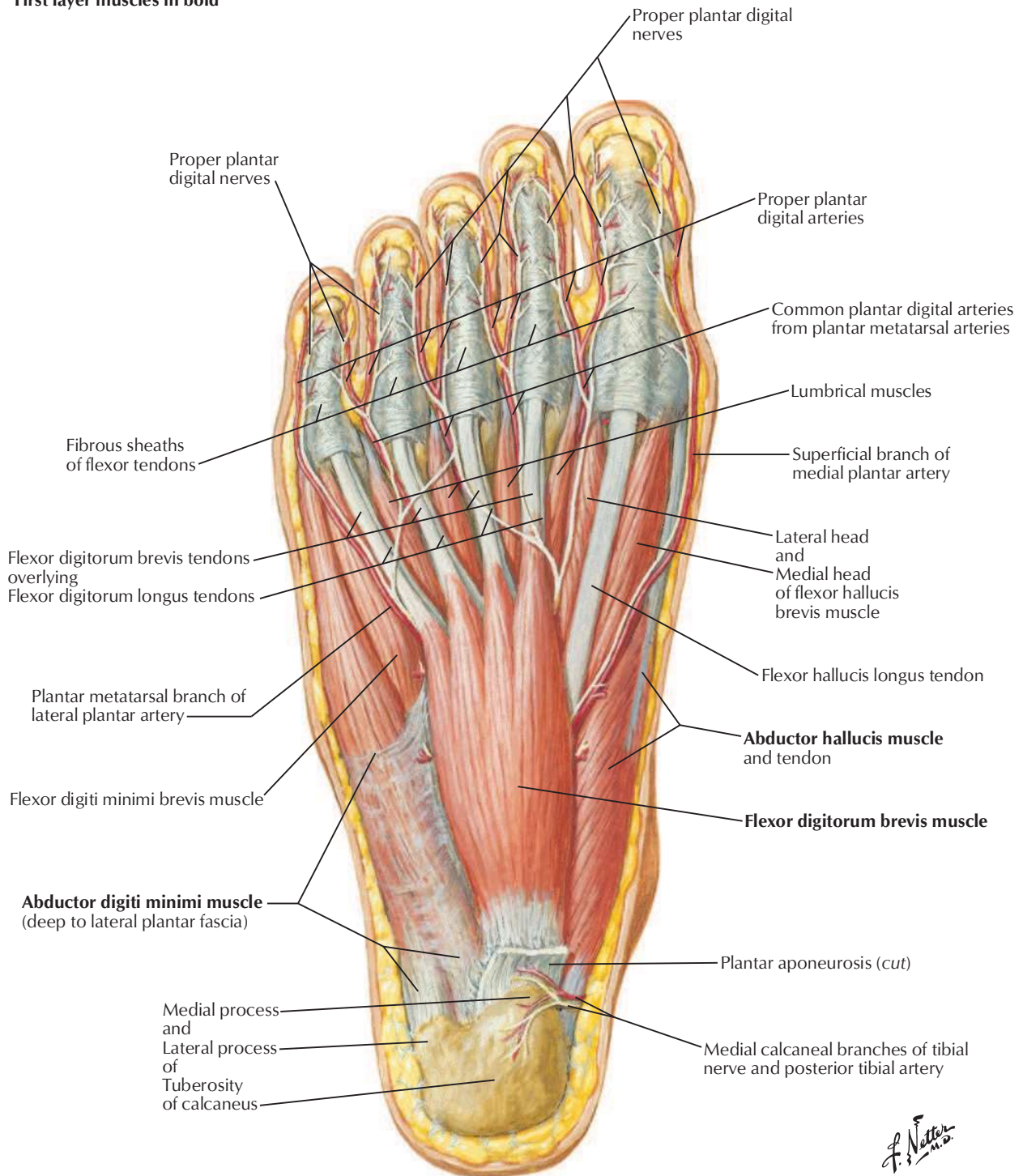


F. Netter M.D.

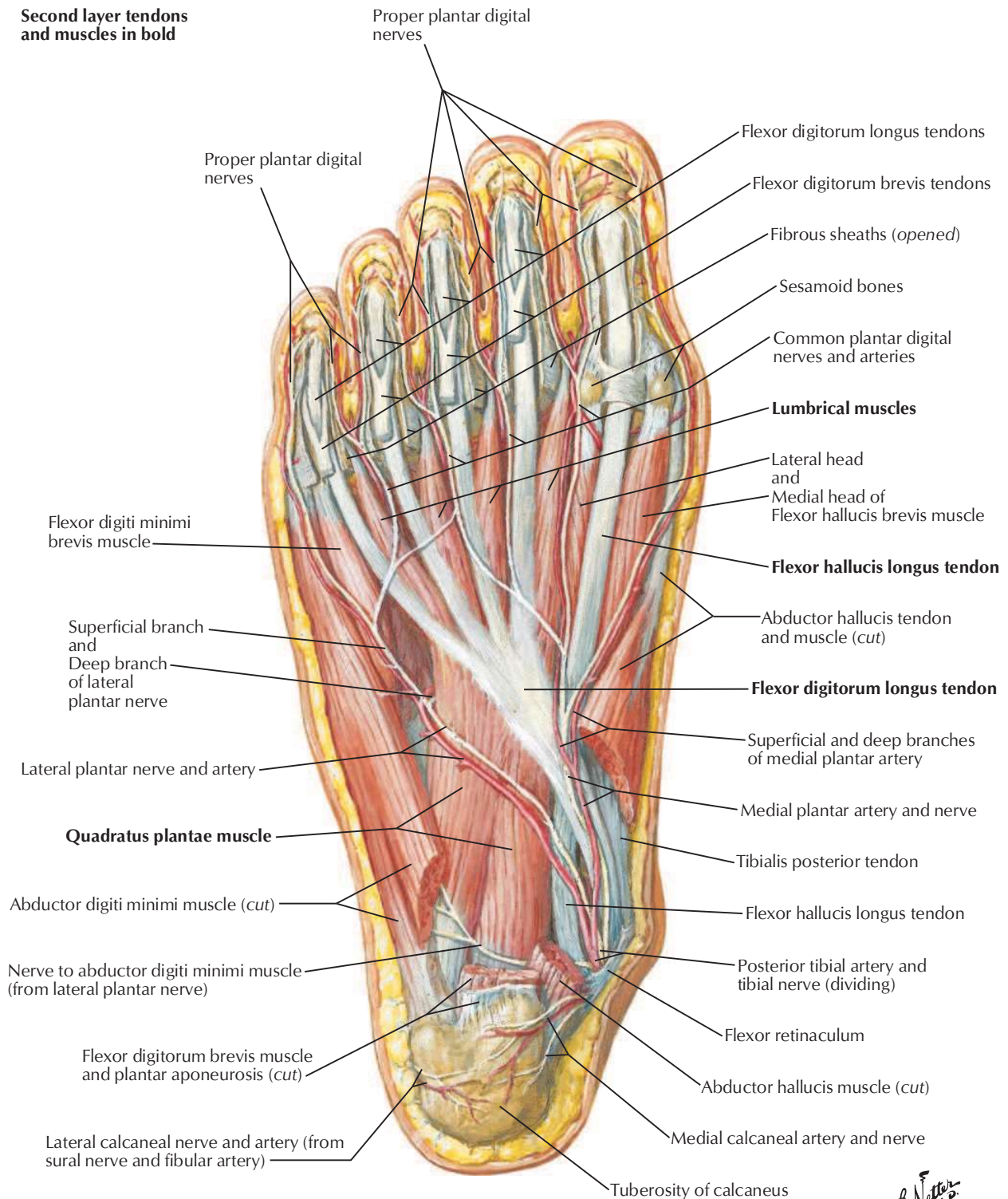
Muscles of Plantar Region of Foot: First Layer

See also [Plate 532](#)

First layer muscles in bold



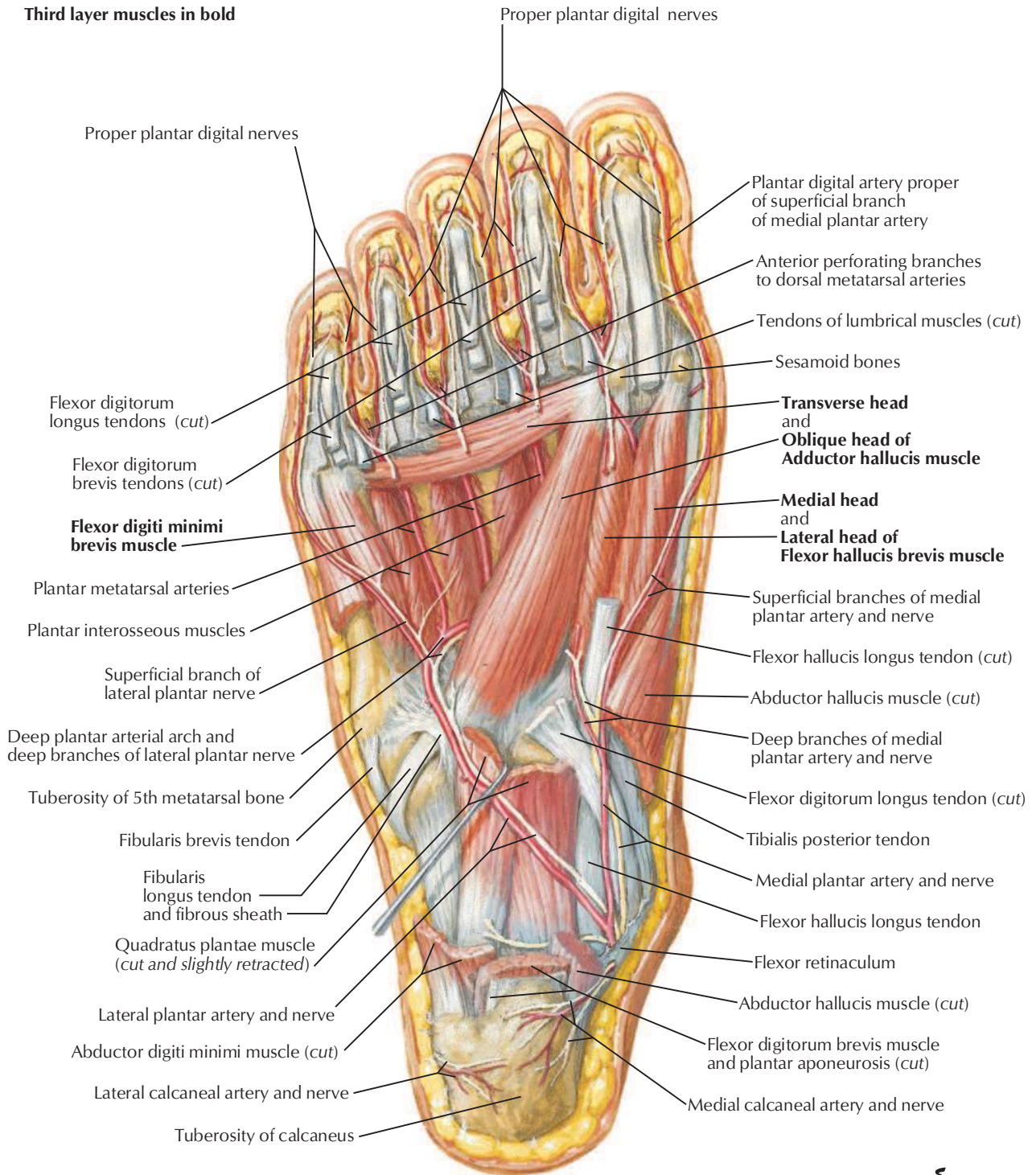
Second layer tendons and muscles in bold

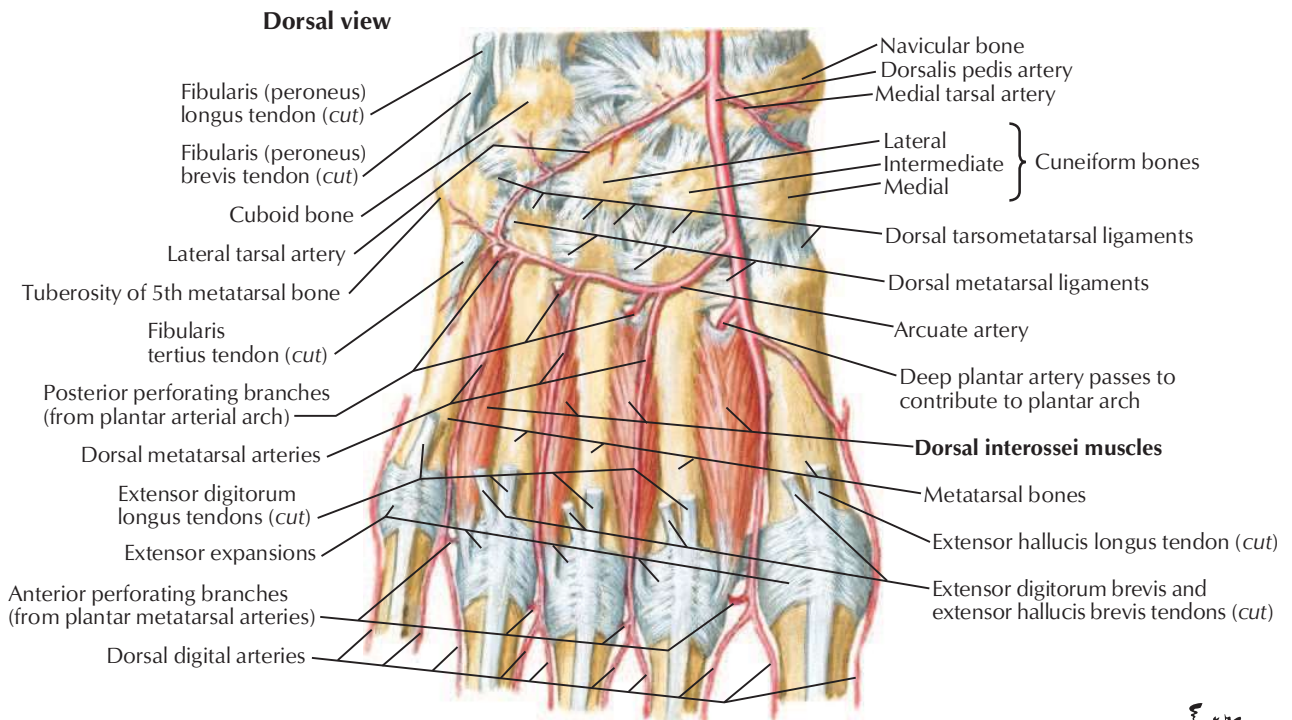


F. Netter M.D.

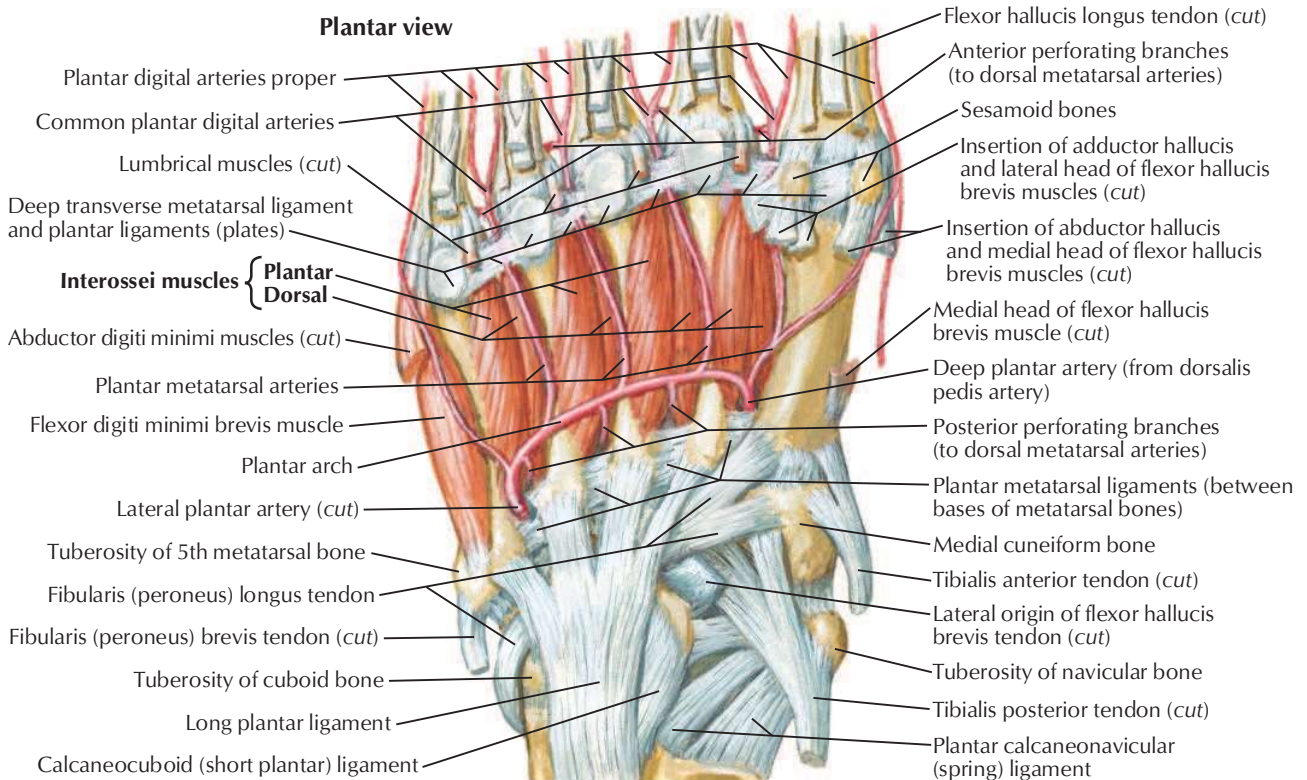
Muscles of Plantar Region of Foot: Third Layer

Third layer muscles in bold

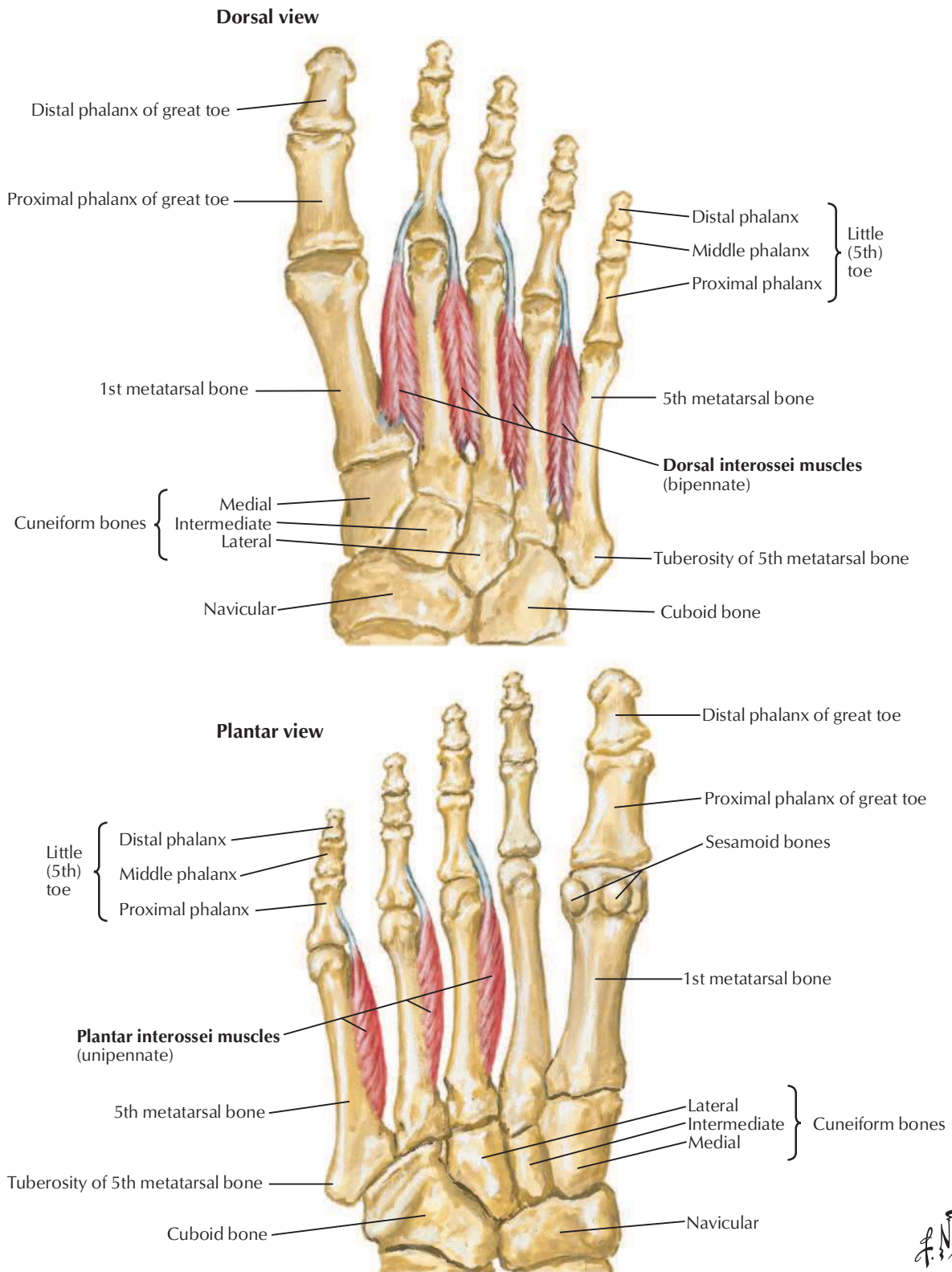


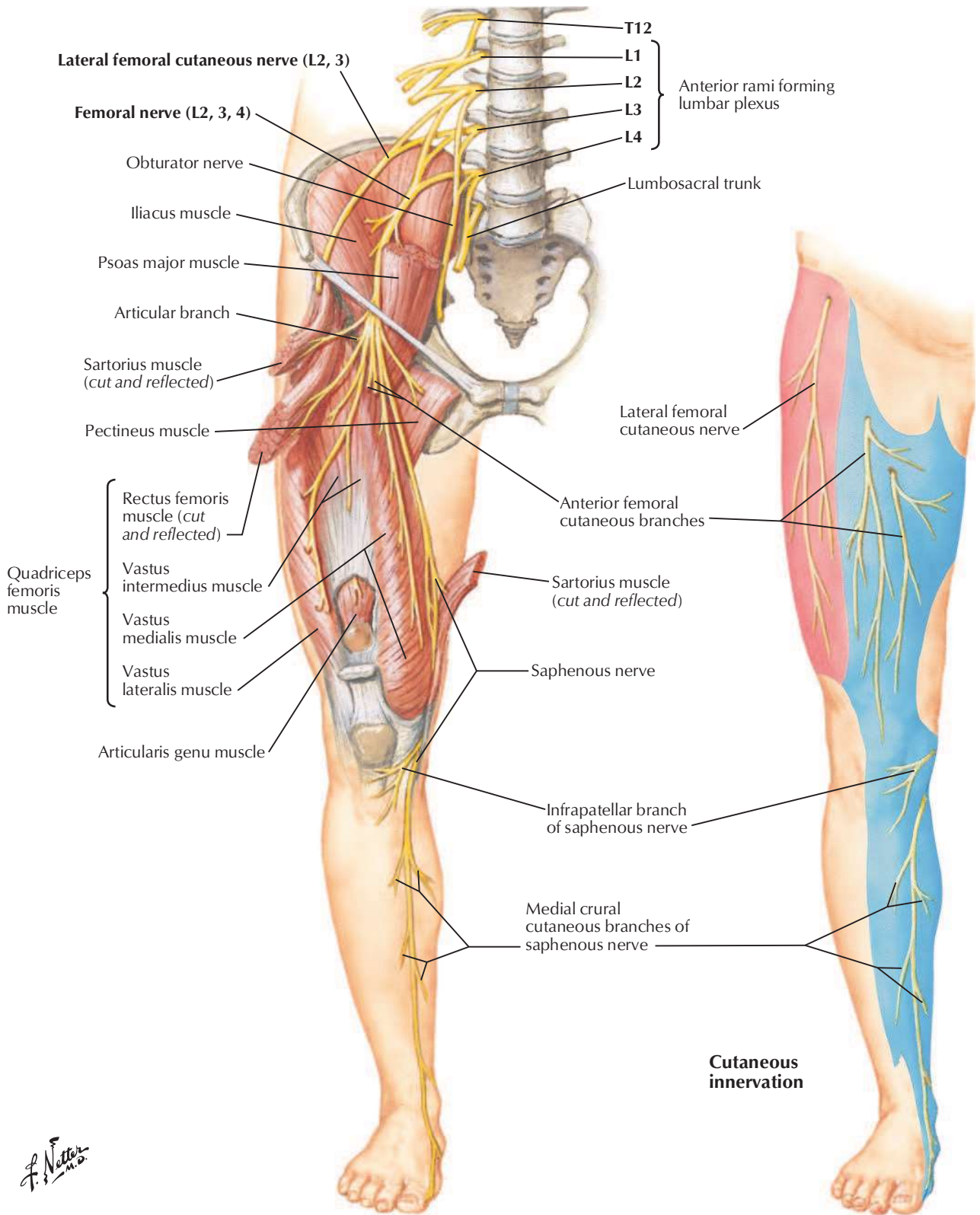


F. Netter M.D.



Fourth layer muscles in bold

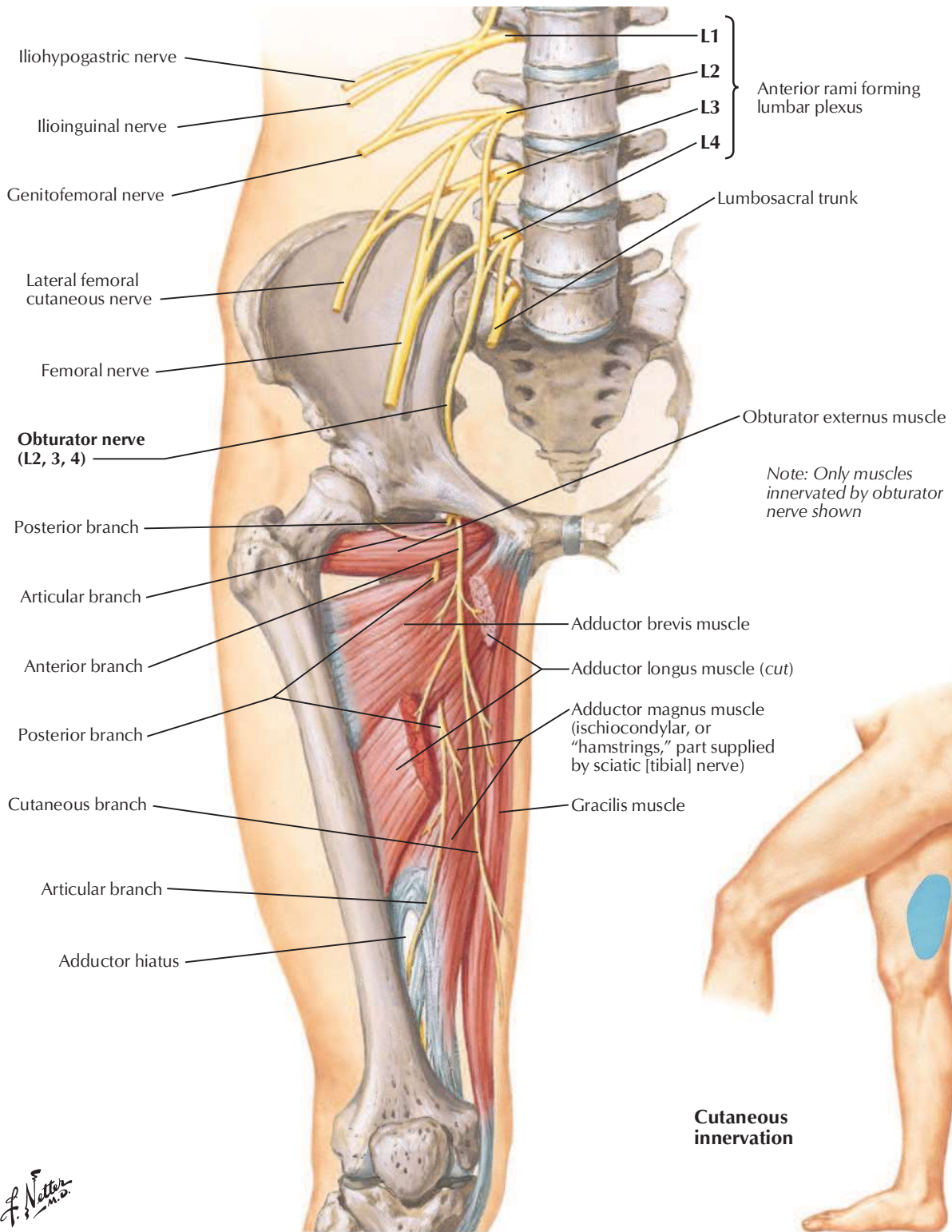


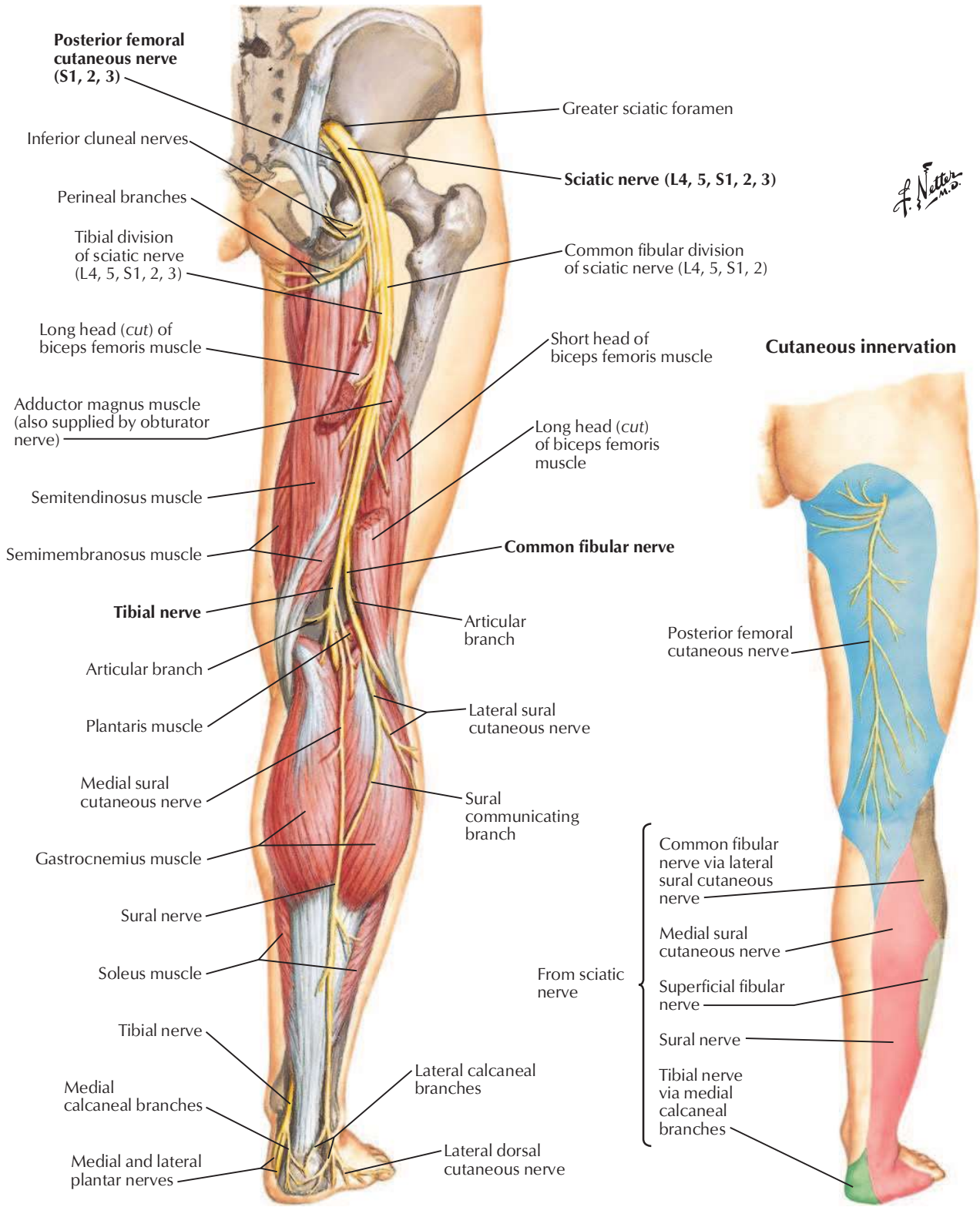


F. Netter M.D.

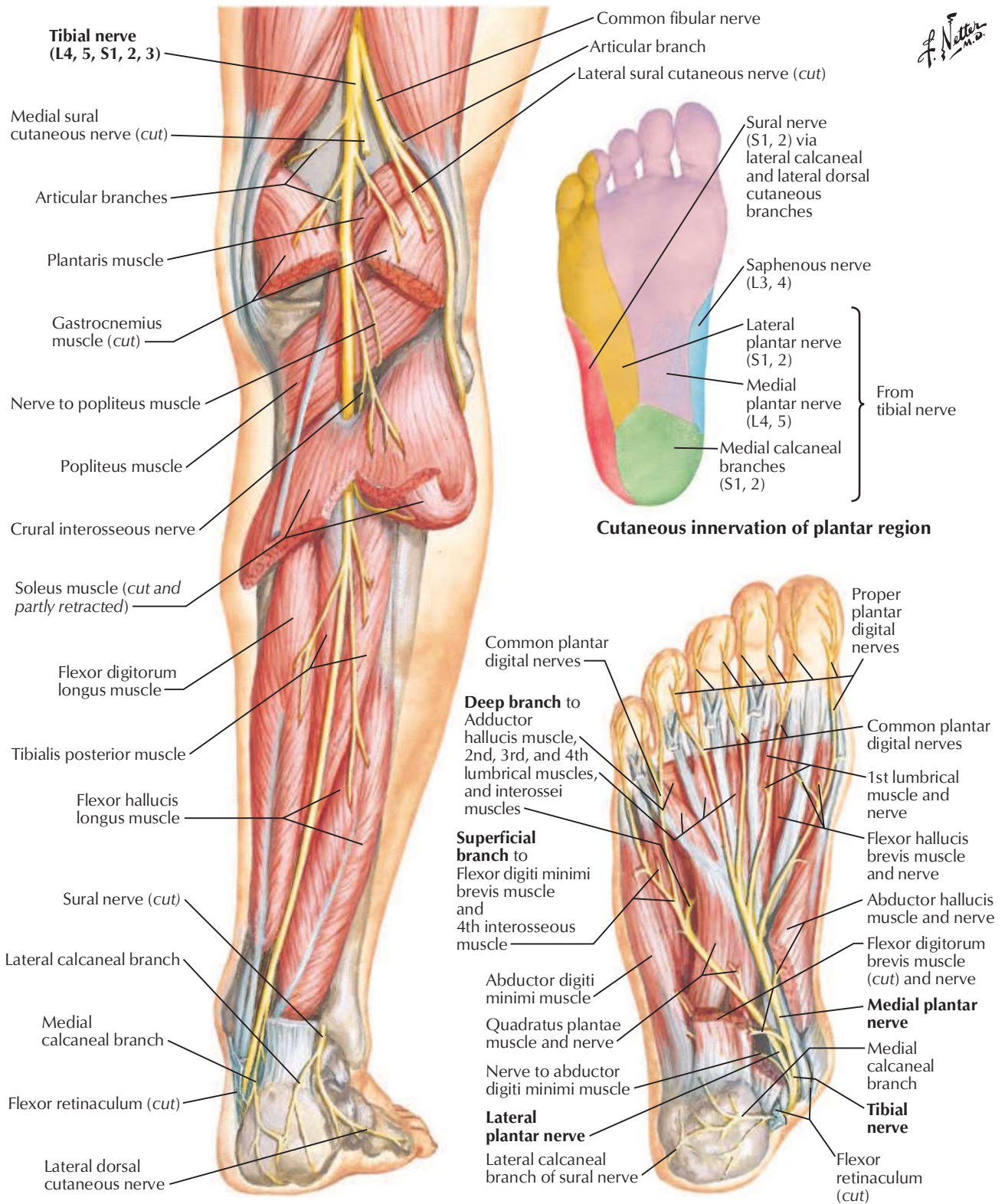
Obturator Nerve

See also [Plate 491](#)

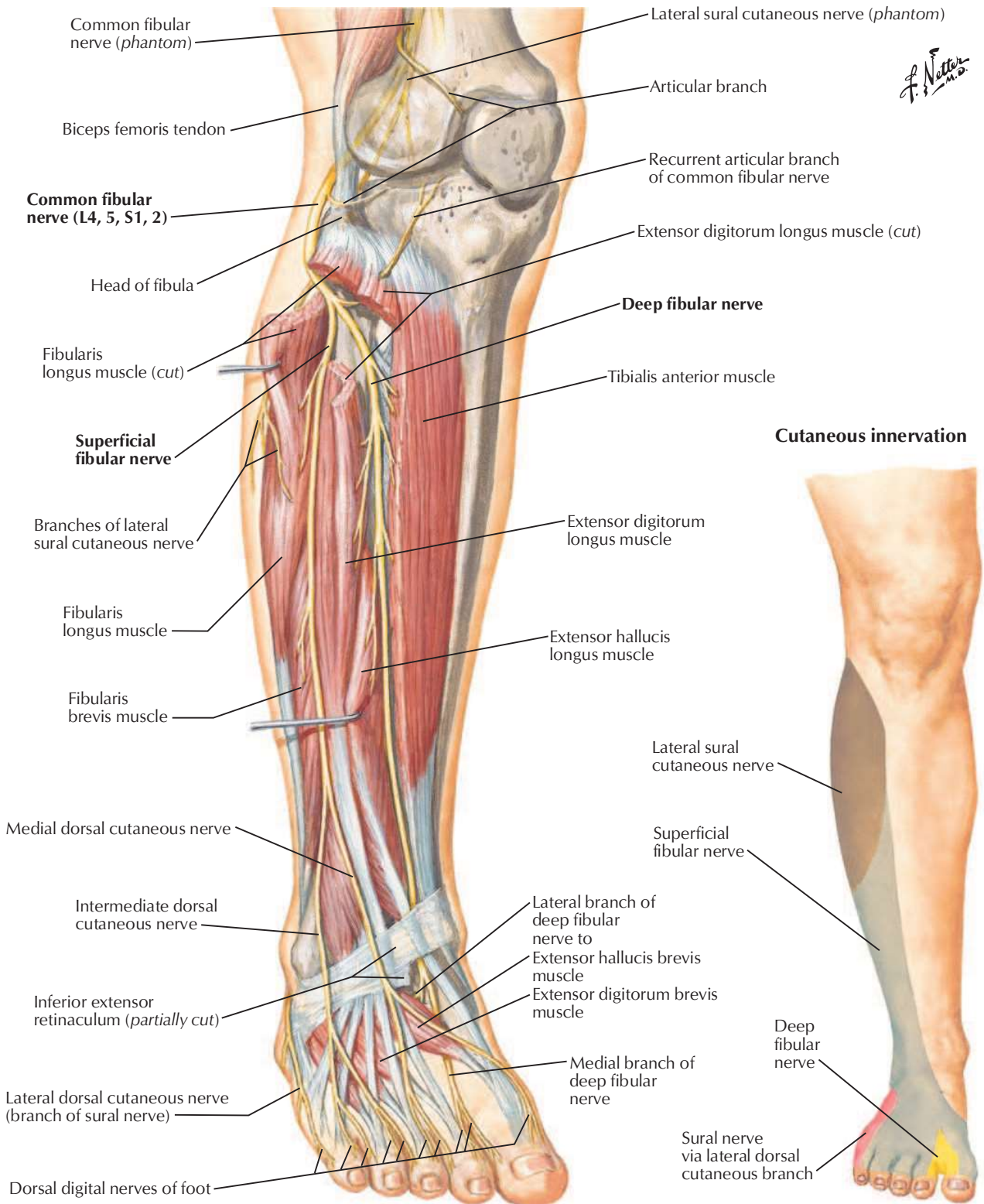




F. Netter M.D.

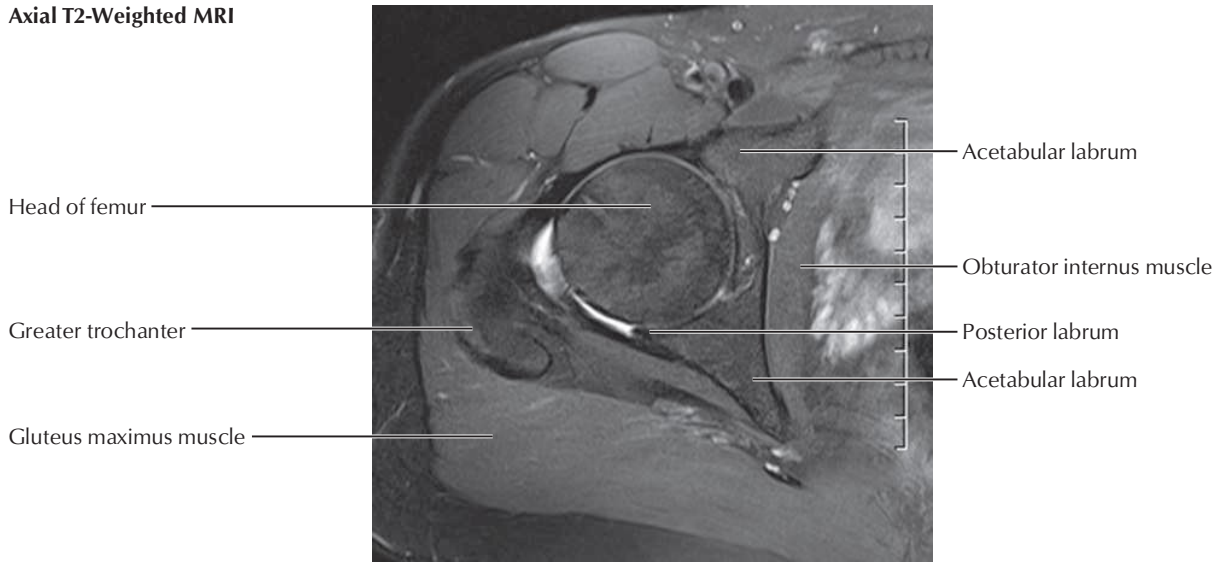


F. Netter M.D.

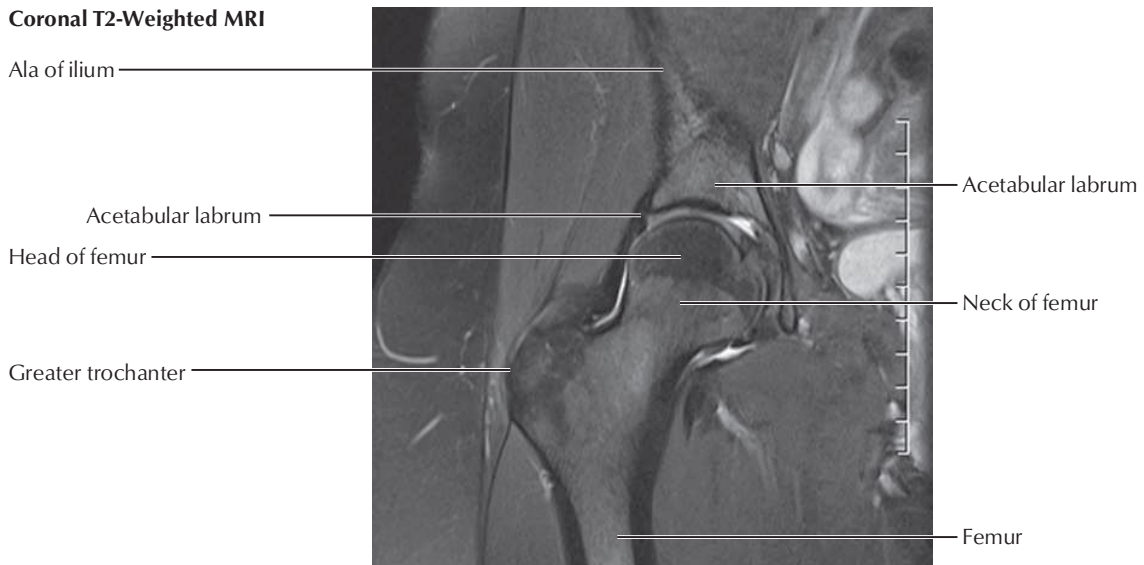


See also [Plates 334, 400, 495](#)

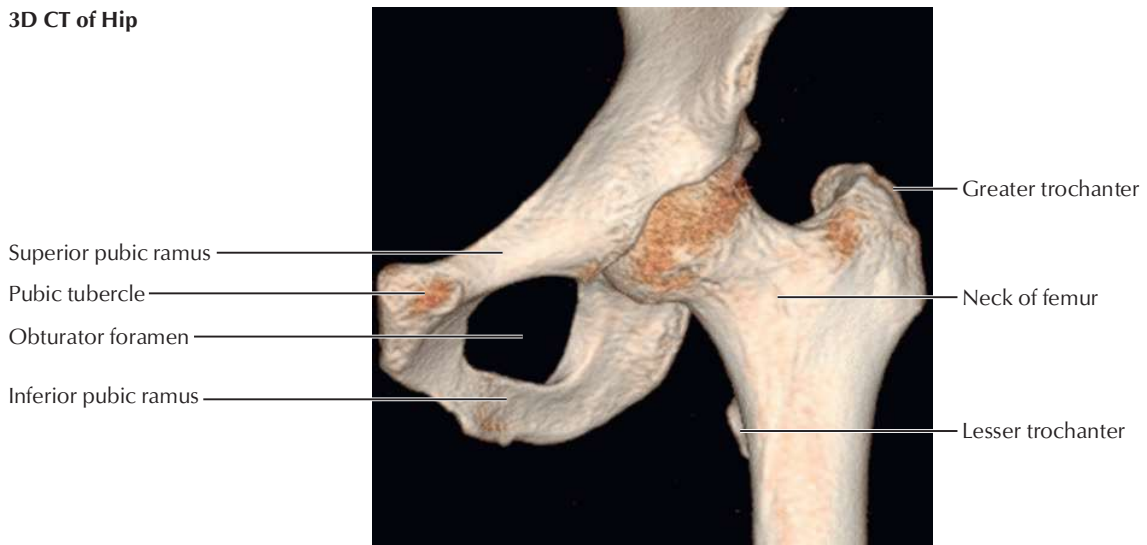
Axial T2-Weighted MRI



Coronal T2-Weighted MRI

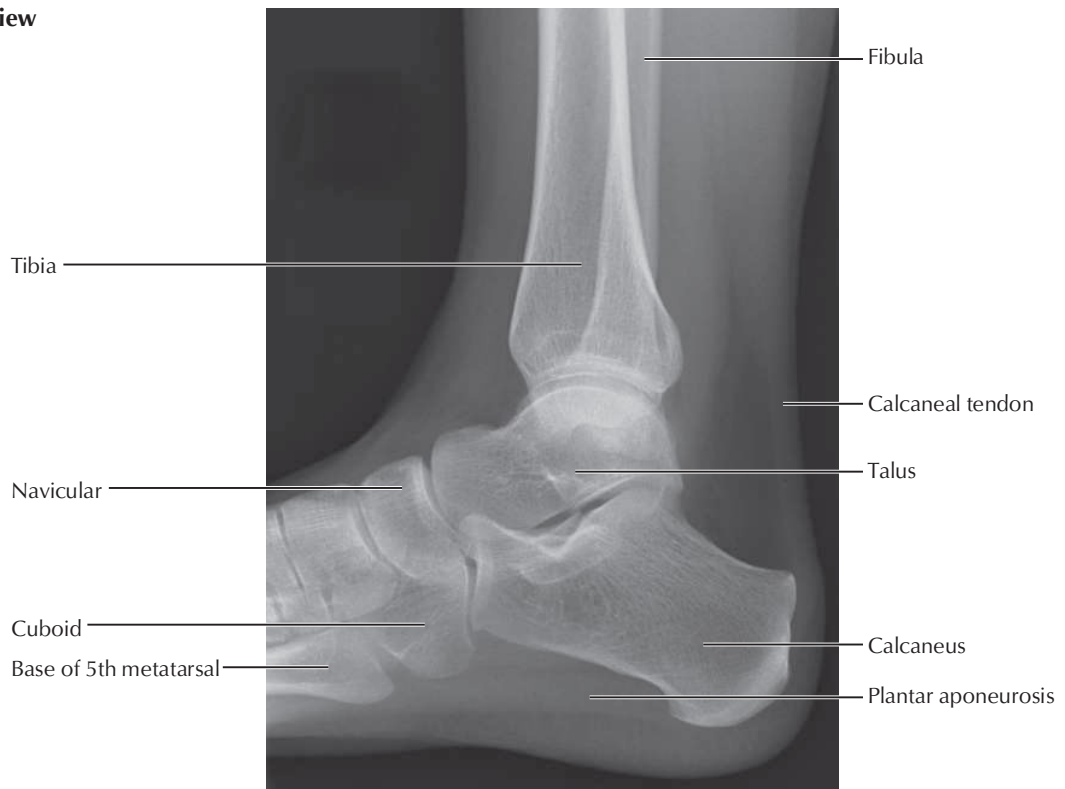


3D CT of Hip

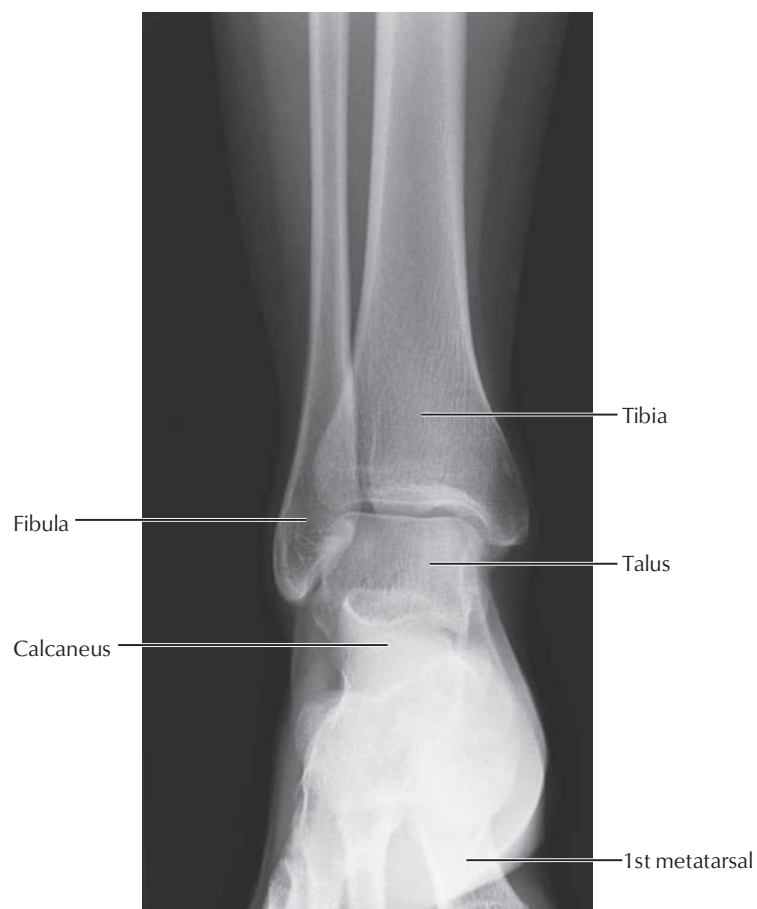

See also [Plates 510, 517, 518](#)

Lateral view






Anterior view



ANATOMICAL STRUCTURES	CLINICAL IMPORTANCE	PLATE NUMBERS
SKELETAL SYSTEM		
Neck of femur	Common fracture in elderly persons; can lead to avascular necrosis of femoral head	478, 479, 495
Shaft of femur	The midshaft is a common fracture site in high-energy trauma (motor vehicle accidents)	479
Hip joint	Potential for vascular necrosis of femoral head in hip dislocations or fractures	477, 495
Medial (tibial) collateral ligament, anterior cruciate ligament, and medial meniscus	"Unhappy triad" from blow to lateral aspect of joint in extension; damage to medial collateral and anterior cruciate ligaments and medial meniscus	498, 499, 500
Tibia and fibula	High-energy fractures of shaft (boot-top skiing fracture) from falling forward at high speed	504
First metatarsophalangeal joint	Joint misalignment leading to hallux valgus (bunion), often result of wearing shoes that are too narrow; also, strong genetic component	515
Calcaneus	Most common tarsal bone fracture, usually caused by landing forcefully on heel after falling from height	517
Ankle joint	Most sprains are inversion injuries that occur when foot is plantarflexed; places stress on lateral ligaments of ankle	518
MUSCULAR SYSTEM		
Gracilis, adductor longus, adductor brevis, adductor magnus	Excessive stretching or tearing of thigh adductor muscles is common in sports that require repeated sprints or quick changes in direction (e.g., soccer, hockey)	482, 483
Patellar ligament	Striking patellar ligament with reflex hammer elicits patellar (knee jerk) reflex to test L3 to L4 spinal cord levels (innervation of quadriceps femoris muscle by femoral nerve)	482, 498
Iliotibial tract (band)	Commonly injured in runners as iliotibial tract rubs across lateral femoral epicondyle	484, 497
Semitendinosus, semimembranosus, biceps femoris (long head)	Excessive stretching or tearing of hamstring muscles occurs most often during high-speed running or activities with high kicks	485
Piriformis muscle	Piriformis muscle strain or structural variations (e.g., split piriformis muscle) may produce compression of sciatic nerve	492
Gluteus medius and minimus muscles (superior gluteal nerve)	Paralysis of these muscles results in contralateral pelvic dip due to weakened hip abduction when standing on affected limb (Trendelenburg sign or gait)	493
Calcaneal (Achilles) tendon	Inflammation results from repetitive stress on tendon, often from running on uneven surfaces; extreme stress may cause tendon to rupture	507, 508, 518
Calcaneal (Achilles) tendon	Striking calcaneal tendon with reflex hammer elicits ankle (ankle jerk) reflex to test S1 to S2 spinal cord levels (innervation of superficial calf muscles by tibial nerve)	507, 508, 531
Anterior compartment of leg	Exertional compartment syndromes (midtibial pain; shin splints) usually result from excessive training (swelling, periostitis, or stress fractures occur because of tight fascial boundaries of muscle compartments)	514
Plantar aponeurosis	Inflammation results from increased tension, weight, or overuse, causing heel and foot pain (plantar fasciitis; heel spur syndrome)	523

Table 8.1

ANATOMICAL STRUCTURES	CLINICAL IMPORTANCE	PLATE NUMBERS
 NERVOUS SYSTEM		
Sural nerve	Nerve is commonly biopsied for peripheral neuropathies and commonly used as donor graft in neurotization procedure	474, 531
Common fibular nerve	Injury to this nerve from blunt trauma or compression by leg cast weakens dorsiflexion and results in foot drop	529, 531, 533
Obturator nerve	Nerve is blocked or transected for adductor muscle spasticity in cerebral palsy; may be injured during pelvic fractures or pelvic surgical procedures such as lymphadenectomy	530
Femoral nerve	Can be compressed from femoral hematoma and can be anesthetized for procedures of the lower limb	488, 490, 529
Saphenous nerve	Can be anesthetized in the adductor canal to provide pain relief after knee replacement	473, 490, 529
 CARDIOVASCULAR SYSTEM		
Deep veins of leg	Deep venous thrombosis of deep leg veins is due to venous stasis, vessel injury, and/or coagulation disorders; can lead to thrombus formation and thromboemboli	513
Great saphenous vein	Often used as coronary artery bypass grafts	473
Superficial veins	Varicose veins (dilated tortuous superficial veins connected by perforating veins to deeper veins with incompetent venous valves)	473, 513
Femoral artery in femoral triangle; popliteal artery in deep popliteal region of knee; dorsalis pedis artery on dorsum of foot; posterior tibial artery in tarsal tunnel posterior to medial malleolus	Lower limb pulse points	490, 503, 508, 513
Major arteries of lower limb (femoral artery, popliteal artery, tibial artery, and fibular artery)	Peripheral arterial disease due to atherosclerosis may occur in major arteries of lower limb, resulting in reduced blood flow; patients experience claudication (cramping pain in thigh or calf), especially upon exertion	503
 LYMPHATIC SYSTEM		
Superficial inguinal nodes	Superficial inguinal nodes drain the lower limb, gluteal region, lower abdominal region, and perineum; are palpable when enlarged	475
Lymph vessels	Lymphedema (stasis of lymph flow in lymph vessels obstructed by inflammation, fibrosis, tumor, or abnormally small diameter)	475

*Selections were based largely on clinical data as well as commonly covered clinical correlations in gross anatomy courses.

MUSCLE	MUSCLE GROUP	PROXIMAL ATTACHMENT (ORIGIN)	DISTAL ATTACHMENT (INSERTION)	INNERVATION	BLOOD SUPPLY	MAIN ACTIONS
Abductor digiti minimi	Foot	Medial and lateral tubercles of tuberosity of calcaneus, plantar aponeurosis, and intermuscular septum	Lateral side of base of proximal phalanx of 5th digit	Lateral plantar nerve	Mediolateral plantar artery, plantar metatarsal and plantar digital arteries to 5th digit	Abducts and flexes 5th digit
Abductor hallucis	Foot	Medial tubercle of tuberosity of calcaneus, flexor retinaculum, and plantar aponeurosis	Medial side of base of proximal phalanx of 1st digit	Medial plantar nerve	Medial plantar and 1st plantar metatarsal arteries	Abducts and flexes 1st digit
Adductor brevis	Medial thigh	Body and inferior pubic ramus	Pectineal line and proximal part of linea aspera of femur	Obturator nerve	Profunda femoris, medial circumflex femoral, and obturator arteries	Adducts thigh at hip, weak hip flexor
Adductor hallucis	Foot	<i>Oblique head:</i> bases of 2nd through 4th metatarsals <i>Transverse head:</i> ligaments of metatarsophalangeal joints of digits 3–5	Tendons of both heads lateral to side of base of proximal phalanx of 1st digit	Deep branch of lateral plantar nerve	Medial and lateral plantar arteries and plantar arch, plantar metatarsal arteries	Adducts 1st digit, maintains transverse arch of foot
Adductor longus	Medial thigh	Body of pubis inferior to pubic crest	Middle third of linea aspera of femur	Obturator nerve (anterior division)	Profunda femoris and medial circumflex femoral arteries	Adducts thigh at hip
Adductor magnus	Medial thigh	Inferior pubic ramus, ramus of ischium <i>Hamstring part:</i> ischial tuberosity	Gluteal tuberosity, linea aspera, medial supracondylar line <i>Hamstring part:</i> adductor tubercle of femur	<i>Adductor part:</i> obturator nerve <i>Hamstring part:</i> sciatic nerve (tibial division)	Femoral, profunda femoris, and obturator arteries	<i>Adductor part:</i> adducts and flexes thigh <i>Hamstring part:</i> extends thigh
Articularis genus	Anterior thigh	Distal femur on anterior surface	Suprapatellar bursa	Femoral nerve	Femoral artery	Pulls suprapatellar bursa superiorly with extension of knee
Biceps femoris	Posterior thigh	<i>Long head:</i> ischial tuberosity <i>Short head:</i> Linea aspera and lateral supracondylar line of femur	Lateral side of head of fibula	<i>Long head:</i> sciatic nerve (tibial division) (L5–S2) <i>Short head:</i> sciatic nerve (common fibular division)	Perforating branches of profunda femoris, inferior gluteal, and medial circumflex femoral arteries	Flexes and laterally rotates leg, extends thigh at hip
Dorsal interossei (four muscles)	Foot	Adjacent sides of 1st through 5th metatarsals	<i>1st:</i> medial side of proximal phalanx of 2nd digit <i>2nd through 4th:</i> lateral sides of digits 2–4	Lateral plantar nerve	Arcuate artery, dorsal and plantar metatarsal arteries	Abduct 2nd through 4th digits of foot, flex metatarsophalangeal joints, and extend phalangeal bones
Extensor digitorum brevis and extensor hallucis brevis	Foot	Superolateral surface of calcaneus, lateral talocalcaneal ligament, deep surface of inferior extensor retinaculum	First tendon into dorsal surface of base of proximal phalanx of great toe; other three tendons into lateral sides of tendons of extensor digitorum longus to digits 2–4	Deep fibular nerve	Dorsalis pedis, lateral tarsal, arcuate, and fibular arteries	Aids extensor digitorum longus in extending of 4 medial digits at metatarsophalangeal and interphalangeal joints
Extensor digitorum longus	Anterior leg	Lateral condyle of tibia, proximal 3/4 of anterior surface of interosseous membrane and fibula	Middle and distal phalangeal bones of lateral four digits	Deep fibular nerve	Anterior tibial artery	Extends lateral four digits and dorsiflexes foot at ankle
Extensor hallucis longus	Anterior leg	Middle part of anterior surface of fibula and interosseous membrane	Dorsal aspect of base of distal phalanx of great toe	Deep fibular nerve	Anterior tibial artery	Extends great toe, dorsiflexes foot at ankle

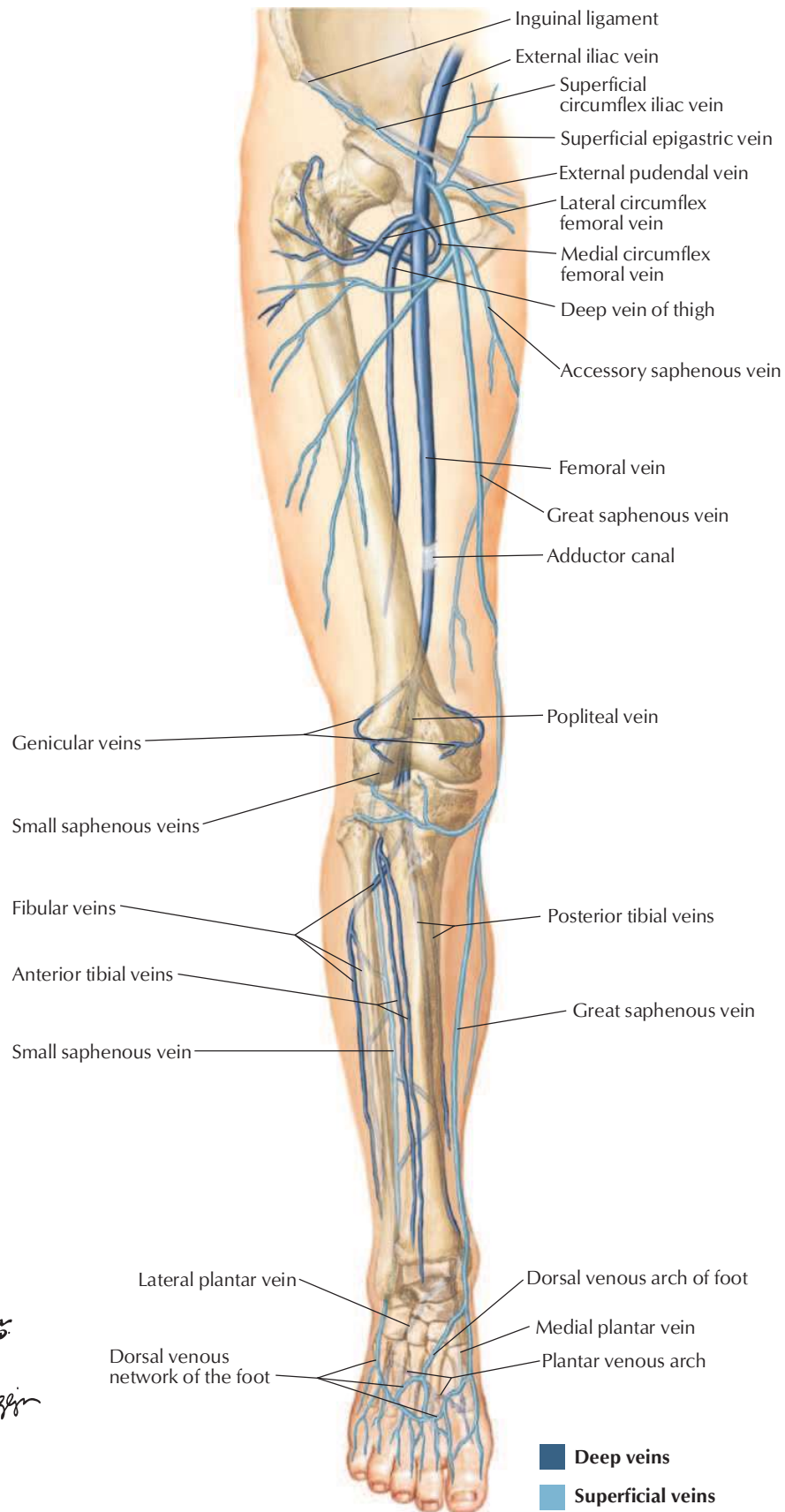
Variations in spinal nerve contributions to the innervation of muscles, their arterial supply, their attachments, and their actions are common themes in human anatomy. Therefore, expect differences between texts and realize that anatomical variation is normal.

MUSCLE	MUSCLE GROUP	PROXIMAL ATTACHMENT (ORIGIN)	DISTAL ATTACHMENT (INSERTION)	INNERVATION	BLOOD SUPPLY	MAIN ACTIONS
Fibularis brevis	Lateral leg	Distal 2/3 of lateral surface of fibula	Dorsal surface of tuberosity on lateral side of 5th metatarsal	Superficial fibular nerve	Anterior tibial and fibular arteries	Everts foot and weakly plantarflexes foot at ankle
Fibularis longus	Lateral leg	Head and proximal 2/3 of lateral fibula	Plantar base of 1st metatarsal and medial cuneiform bone	Superficial fibular nerve	Anterior tibial and fibular arteries	Everts foot and weakly plantarflexes foot at ankle
Fibularis tertius	Anterior leg	Distal third of anterior surface of fibula and interosseous membrane	Dorsum of base of 5th metatarsal	Deep fibular nerve	Anterior tibial artery	Dorsiflexes foot at ankle and aids in eversion of foot
Flexor digiti minimi brevis	Foot	Base of 5th metatarsal	Lateral base of proximal phalanx of 5th digit	Superficial branch of lateral plantar nerve	Lateral plantar artery, plantar digital artery to 5th digit, arcuate artery	Flexes proximal phalanx of 5th digit
Flexor digitorum brevis	Foot	Medial tubercle of tuberosity of calcaneus, plantar aponeurosis, and intermuscular septum	Both sides of middle phalangeal bones of lateral four digits	Medial plantar nerve	Medial and lateral plantar arteries and plantar arch, plantar metatarsal and plantar digital arteries	Flexes 2nd through 5th digits
Flexor digitorum longus	Posterior leg	Medial part of posterior tibia inferior to soleal line	Plantar bases of distal phalangeal bones of lateral four digits	Tibial nerve	Posterior tibial artery	Flexes lateral four digits and plantarflexes foot at ankle; supports longitudinal arches of foot
Flexor hallucis brevis	Foot	Plantar surfaces of cuboid bone and lateral cuneiform bone	Both sides of base of proximal phalanx of 1st digit	Medial plantar nerve	Medial plantar artery, 1st plantar metatarsal artery	Flexes proximal phalanx of 1st digit
Flexor hallucis longus	Posterior leg	Distal 2/3 of posterior fibula and interosseous membrane	Base of distal phalanx of great toe	Tibial nerve	Fibular artery	Flexes all joints of great toe, weakly plantarflexes foot at ankle
Gastrocnemius	Posterior leg	<i>Lateral head:</i> lateral aspect of lateral condyle of femur <i>Medial head:</i> popliteal surface above medial condyle of femur	Posterior aspect of calcaneus via calcaneal tendon	Tibial nerve	Popliteal and posterior tibial arteries	Plantarflexes foot at ankle joint, assists in flexion of knee joint
Gluteus maximus	Gluteal region	Ilium posterior to posterior gluteal line, dorsal surface of sacrum and coccyx, sacrotuberous ligament	Most fibers end in iliotibial tract that inserts into lateral condyle of tibia; some fibers insert into gluteal tuberosity of femur	Inferior gluteal nerve	Inferior gluteal arteries mainly, and superior gluteal arteries occasionally	Extends flexed thigh, assists in lateral rotation, and abducts thigh
Gluteus medius	Gluteal region	Lateral surface of ilium between anterior and posterior gluteal lines	Lateral surface of greater trochanter of femur	Superior gluteal nerve	Superior gluteal artery	Abducts and medially rotates thigh at hips; steadies pelvis on leg when opposite leg is raised
Gluteus minimus	Gluteal region	Lateral surface of ilium between anterior and inferior gluteal lines	Anterior surface of greater trochanter of femur	Superior gluteal nerve	Main trunk and deep branch of superior gluteal artery	Abducts and medially rotates thigh at hips; steadies pelvis on leg when opposite leg is raised
Gracilis	Medial thigh	Body and inferior ramus of pubis	Superior part of medial surface of tibia	Obturator nerve	Profunda femoris artery, medial circumflex femoral artery	Adducts thigh, flexes and medially rotates leg
Iliacus (iliopsoas)	Anterior thigh	Superior 2/3 of iliac fossa, iliac crest, ala of sacrum, anterior sacroiliac ligaments	Lesser trochanter of femur and shaft inferior to it, to psoas major tendon	Femoral nerve	Iliac branches of iliolumbar artery	Flexes thigh at hips and stabilizes hip joint, acts with psoas major
Inferior gemellus	Gluteal region	Ischial tuberosity	Medial surface of greater trochanter of femur	Nerve to quadratus femoris muscle	Medial circumflex femoral artery	Laterally rotates extended thigh and abducts flexed thigh

MUSCLE	MUSCLE GROUP	PROXIMAL ATTACHMENT (ORIGIN)	DISTAL ATTACHMENT (INSERTION)	INNERVATION	BLOOD SUPPLY	MAIN ACTIONS
Lumbricals	Foot	Tendons of flexor digitorum longus	Medial side of dorsal digital expansions of lateral four digits	<i>Medial one:</i> medial plantar nerve <i>Lateral three:</i> lateral plantar nerve	Lateral plantar artery and plantar metatarsal arteries	Flexes proximal phalangeal bones at metatarsophalangeal joint, extends phalangeal bones at proximal interphalangeal and distal interphalangeal joints
Obturator externus	Medial thigh	Margins of obturator foramen, obturator membrane	Trochanteric fossa of femur	Obturator nerve	Medial circumflex femoral artery, obturator artery	Laterally rotates thigh, stabilizes head of femur in acetabulum
Obturator internus	Gluteal region	Pelvic surface of obturator membrane and surrounding bone	Medial surface of greater trochanter of femur	Nerve to obturator internus muscle	Internal pudendal and obturator arteries	Laterally rotates extended thigh, abducts flexed thigh at hip
Pectineus	Medial thigh	Superior ramus of pubis	Pectineal line of femur	Femoral nerve and sometimes obturator nerve	Medial circumflex femoral artery, obturator artery	Adducts and flexes thigh at hip
Piriformis	Gluteal region	Anterior surface of sacral segments 2–4, sacrotuberous ligament (inconstant)	Superior border of greater trochanter of femur	Ventral rami of L5, S1, S2	Superior and inferior gluteal arteries, internal pudendal artery	Laterally rotates extended thigh, abducts flexed thigh at hip
Plantar interossei (three muscles)	Foot	Bases and medial sides of 3rd through 5th metatarsals	Medial sides of bases of proximal phalangeal bones of 3rd through 5th digits	Lateral plantar nerve	Lateral plantar artery and plantar arch, plantar metatarsal and plantar digital arteries	Adduct digits (3-5) and flex metatarsophalangeal joint and extend phalangeal bones
Plantaris	Posterior leg	Inferior end of lateral supracondylar line of femur and oblique popliteal ligament	Posterior aspect of calcaneus via calcaneal tendon	Tibial nerve	Popliteal artery	Weakly assists gastrocnemius
Popliteus	Posterior leg	Lateral aspect of lateral condyle of femur, lateral meniscus	Posterior tibia superior to soleal line	Tibial nerve (L4–S1)	Inferior medial and lateral genicular arteries	Weakly flexes knee and unlocks it by rotating femur on fixed tibia
Psoas major (iliopsoas)	Anterior thigh	Transverse processes of lumbar vertebrae, sides of bodies of T12–L5 vertebrae, intervening intervertebral discs	Lesser trochanter of femur	Anterior rami of first three lumbar nerves	Lumbar branches of iliolumbar artery	Acting superiorly with iliacus, flexes hip; acting inferiorly, flexes vertebral column laterally; used to balance trunk in sitting position; acting inferiorly with iliacus, flexes trunk
Quadratus femoris	Gluteal region	Lateral margin of ischial tuberosity	Quadratus tubercle on intertrochanteric crest of femur	Nerve to quadratus femoris muscle	Medial circumflex femoral artery	Laterally rotates thigh at hip
Quadratus plantae	Foot	Medial and lateral sides of plantar surface of calcaneus	Posterolateral edge of flexor digitorum longus tendon	Lateral plantar nerve	Medial and lateral plantar arteries and deep plantar arterial arch	Corrects for oblique pull of flexor digitorum longus tendon, thus assisting in flexion of digits of foot
Rectus femoris (quadriceps)	Anterior thigh	Anterior inferior iliac spine and ilium superior to acetabulum	Base of patella and to tibial tuberosity via patellar ligament	Femoral nerve	Profunda femoris and lateral circumflex femoral arteries	Extends leg at knee joint and flexes thigh at hip joint
Sartorius	Anterior thigh	Anterior superior iliac spine and superior part of notch below it	Superior part of medial surface of tibia	Femoral nerve	Femoral artery	Abducts, laterally rotates, and flexes thigh; flexes knee joint
Semimembranosus	Posterior thigh	Ischial tuberosity	Posterior part of medial condyle of tibia	Sciatic nerve (tibial division)	Perforating branch of profunda femoris and medial circumflex femoral arteries	Flexes leg, extends thigh

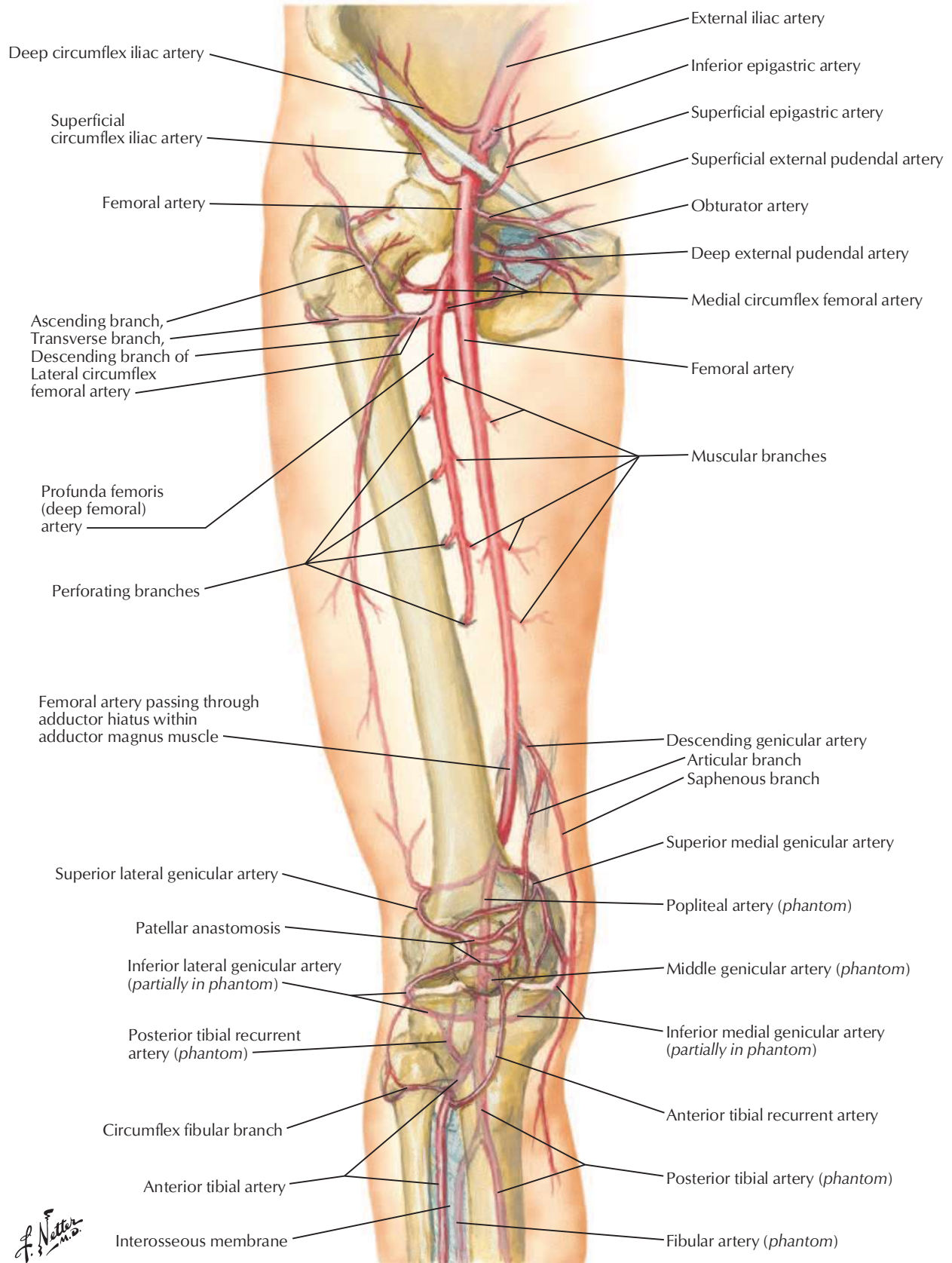
Table 8.5

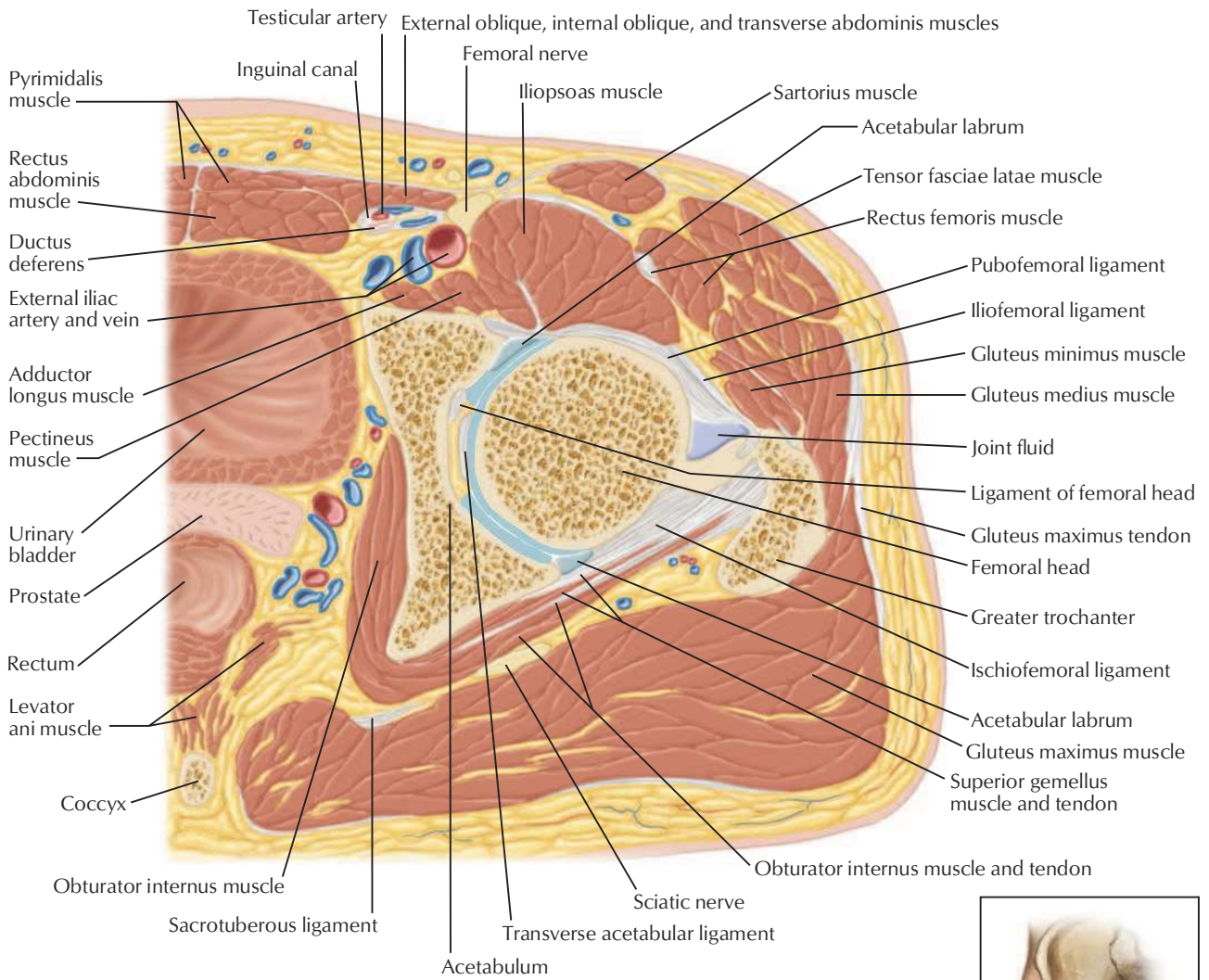
MUSCLE	MUSCLE GROUP	PROXIMAL ATTACHMENT (ORIGIN)	DISTAL ATTACHMENT (INSERTION)	INNERVATION	BLOOD SUPPLY	MAIN ACTIONS
Semitendinosus	Posterior thigh	Ischial tuberosity	Superior part of medial surface of tibia	Sciatic nerve (tibial division)	Perforating branch of profunda femoris and medial circumflex femoral arteries	Flexes leg, extends thigh
Soleus	Posterior leg	Posterior aspect of head of fibula, proximal 1/4 of posterior surface of fibula, soleal line of tibia	Posterior aspect of calcaneus via calcaneal tendon	Tibial nerve	Popliteal, posterior tibial, and fibular arteries	Plantarflexes foot at ankle, stabilizes leg over foot
Superior gemellus	Gluteal region	Outer surface of ischial spine	Medial surface of greater trochanter of femur	Nerve to obturator internus muscle	Inferior gluteal and internal pudendal arteries	Laterally rotates extended thigh and abducts flexed thigh
Tensor fasciae latae	Gluteal region	Anterior superior iliac spine and anterior part of iliac crest	Iliotibial tract that attaches to lateral condyle of tibia	Superior gluteal nerve	Ascending branch of lateral circumflex femoral artery	Abducts, medially rotates, and flexes thigh at hip; helps to keep knee extended
Tibialis anterior	Anterior leg	Lateral condyle, proximal half of lateral tibia, interosseous membrane	Medial plantar surfaces of medial cuneiform bone and base of 1st metatarsal bone	Deep fibular nerve	Anterior tibial artery	Dorsiflexes foot at ankle and inverts foot
Tibialis posterior	Posterior leg	Posterior tibia below soleal line, interosseous membrane, proximal half of posterior fibula	Tuberosity of navicular bone, all cuneiforms, cuboid, and bases of 2nd through 4th metatarsal bones	Tibial nerve	Fibular artery	Plantarflexes foot at ankle and inverts foot
Vastus intermedius (quadriceps)	Anterior thigh	Anterior and lateral surfaces of body of femur	Base of patella and to tibial tuberosity via patellar ligament	Femoral nerve	Lateral circumflex femoral and profunda femoris arteries	Extends leg at knee joint
Vastus lateralis (quadriceps)	Anterior thigh	Greater trochanter, lateral lip of gluteal tuberosity, lateral lip of linea aspera	Base of patella and to tibial tuberosity via patellar ligament	Femoral nerve	Lateral circumflex femoral and profunda femoris arteries	Extends leg at knee joint
Vastus medialis (quadriceps)	Anterior thigh	Intertrochanteric line, greater trochanter, lateral lip of gluteal tuberosity, and lateral lip of linea aspera	Base of patella and to tibial tuberosity via patellar ligament	Femoral nerve	Femoral and profunda femoris arteries	Extends leg at knee joint



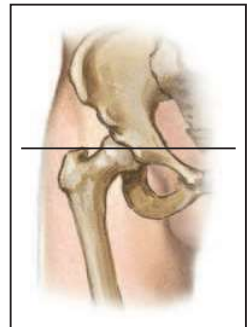F. Netter M.D.
K. Marzari

Arteries of Thigh and Knee

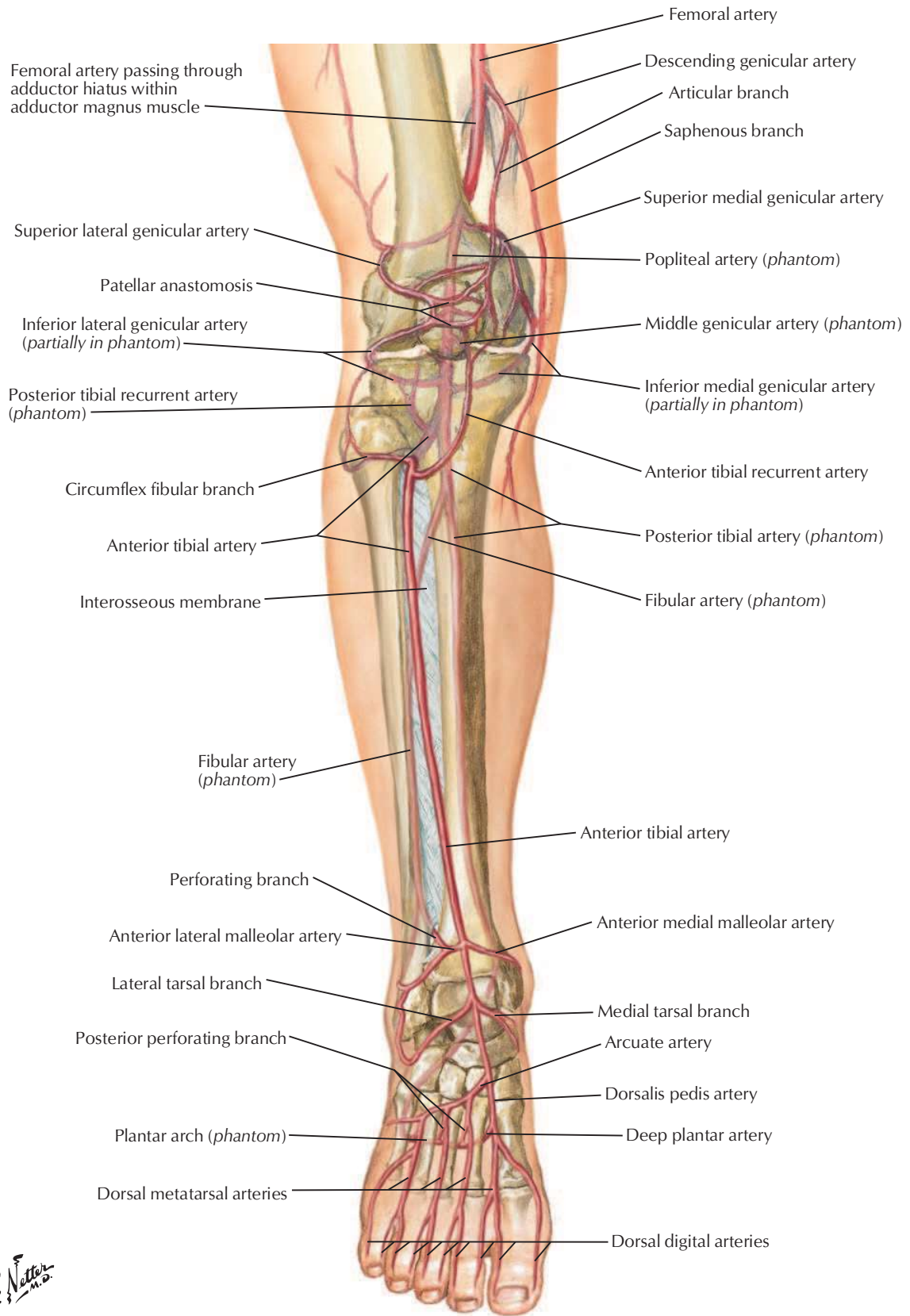


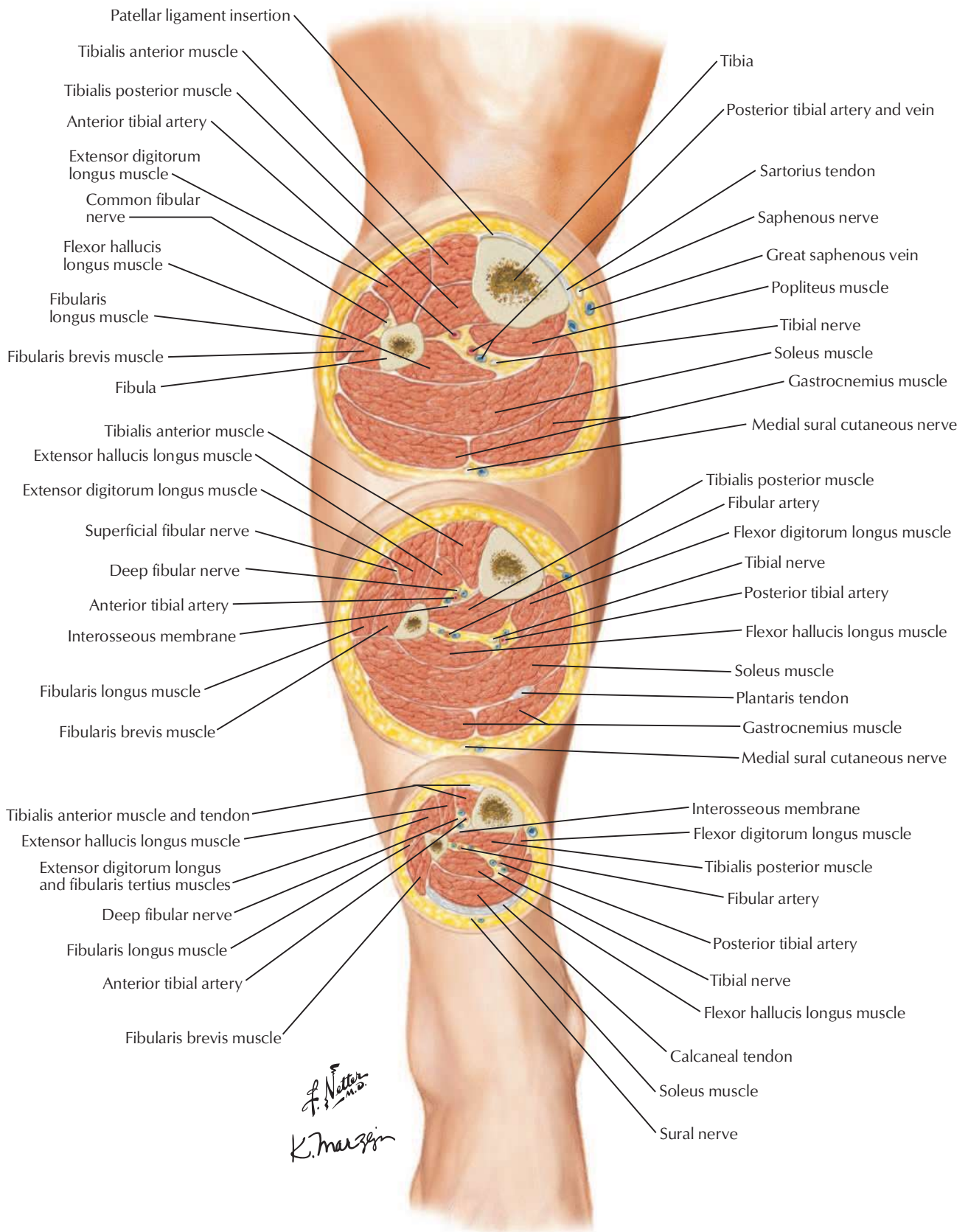


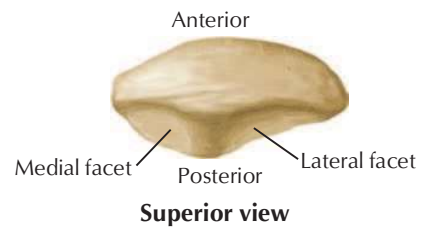
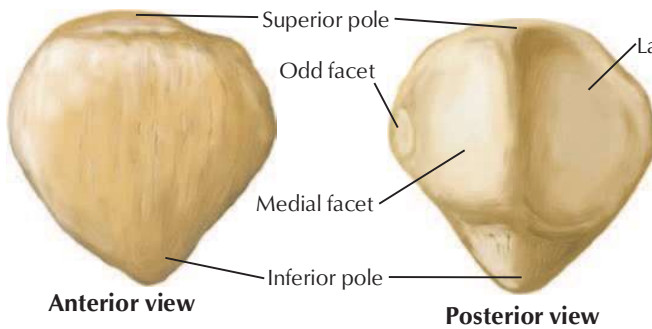
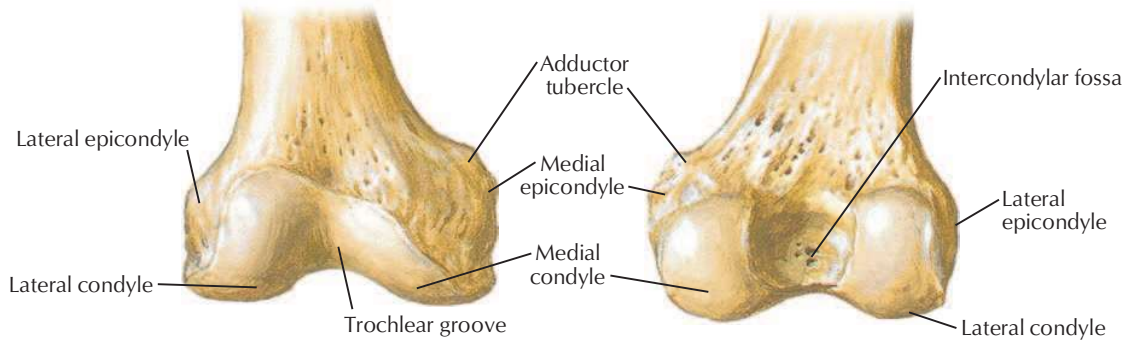
F. Netter M.D.
K. Marszalek



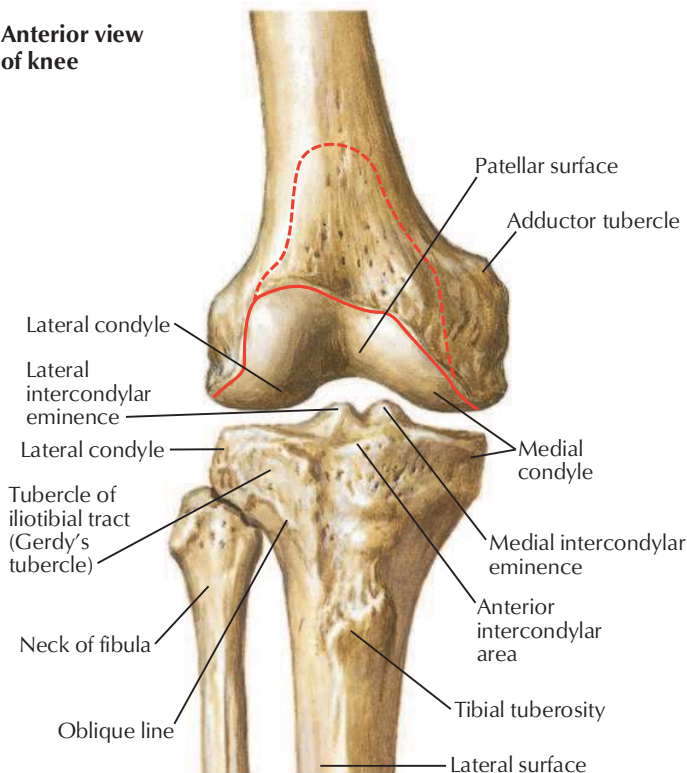
Arteries of Knee and Foot



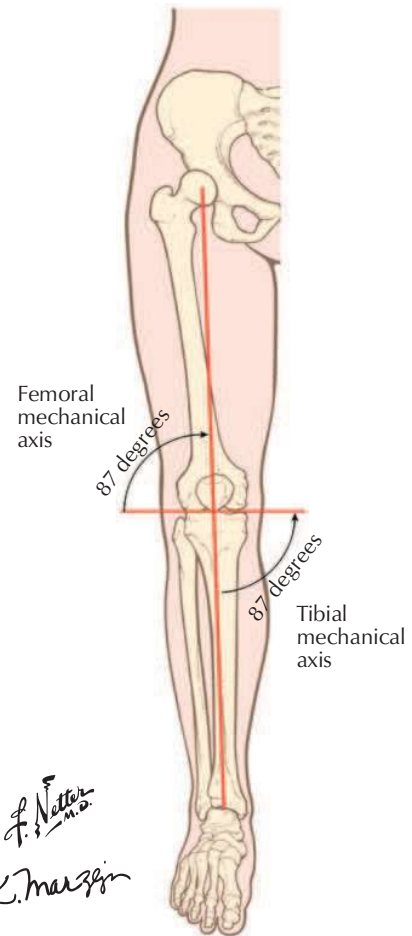




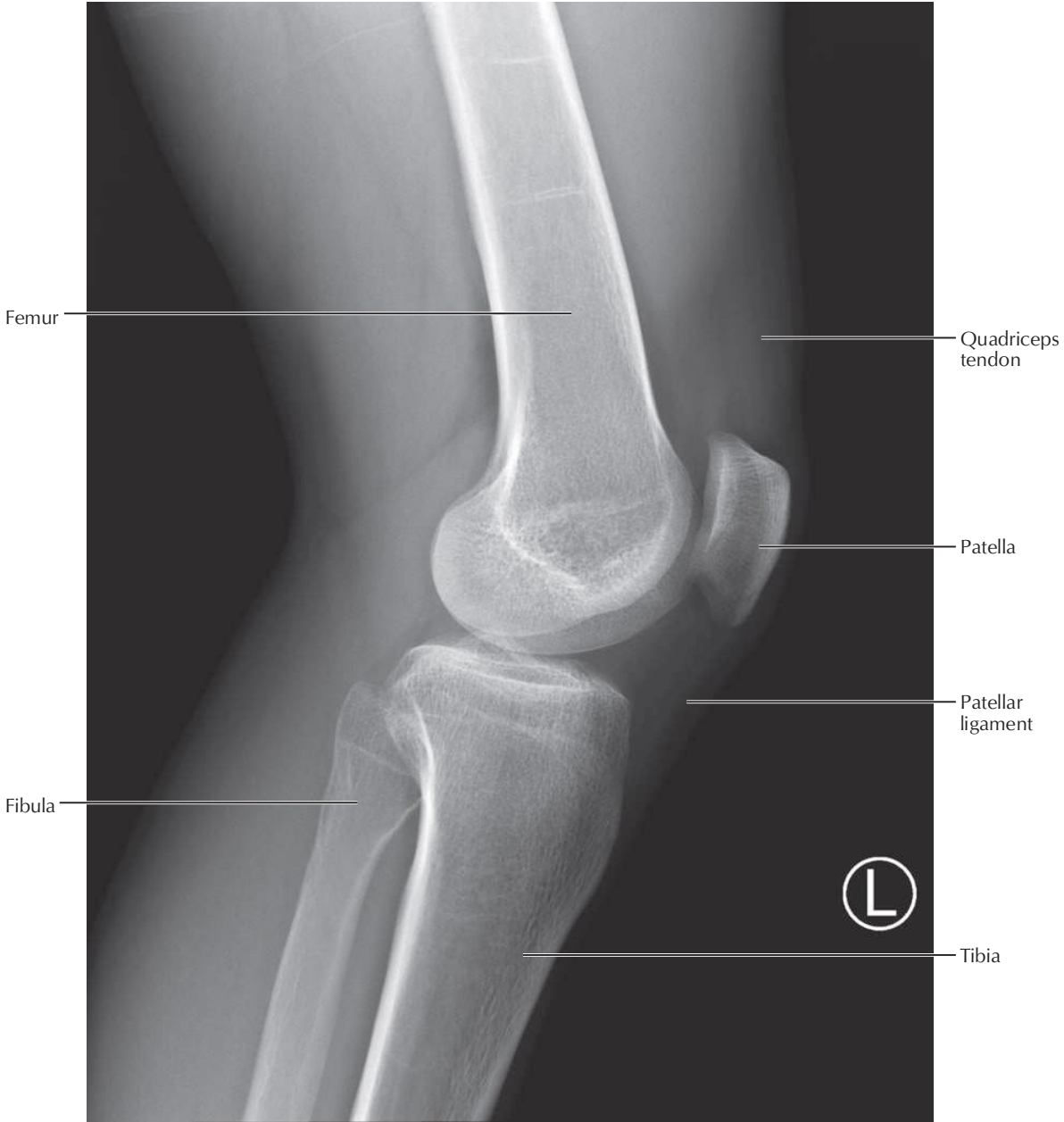Anterior view of knee



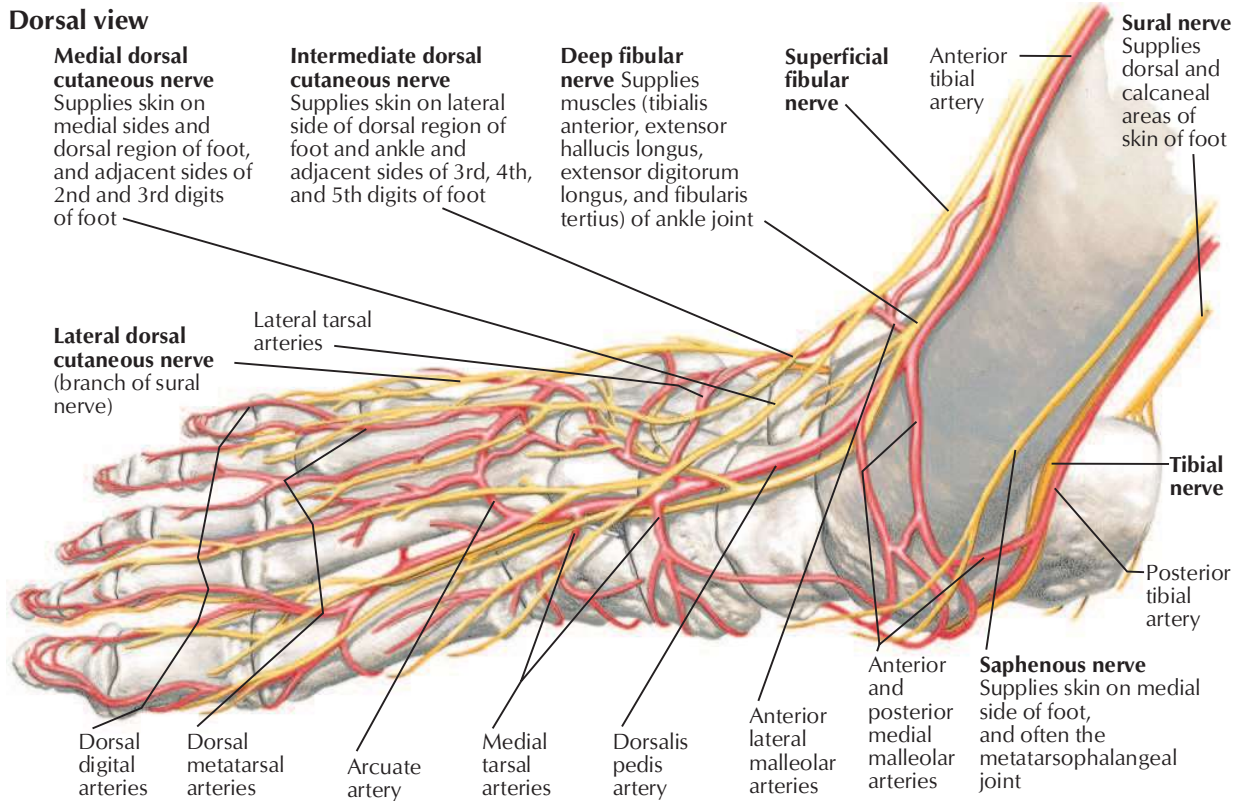
— Line of attachment of synovium (edge of articular cartilage) to distal femur
 - - - Line of reflection of synovial membrane



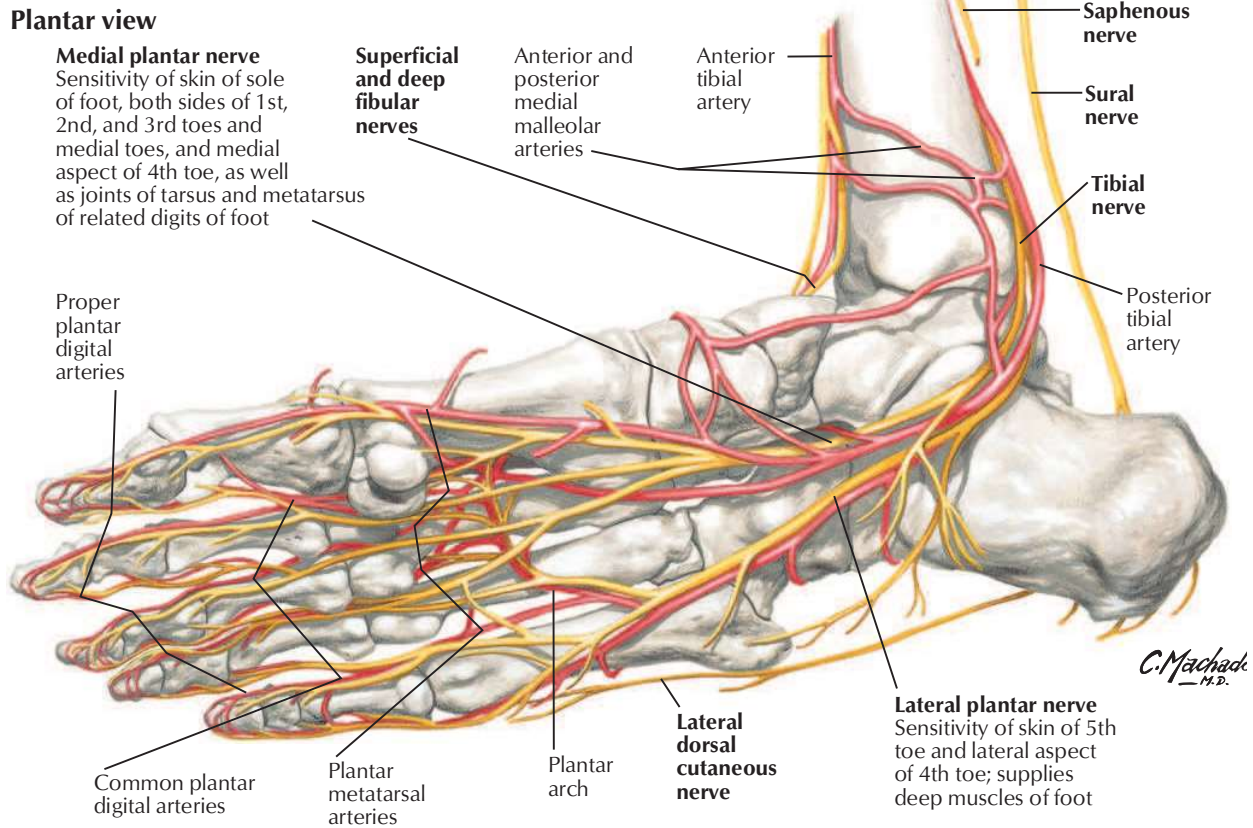
F. Netter M.D.
K. Margolin

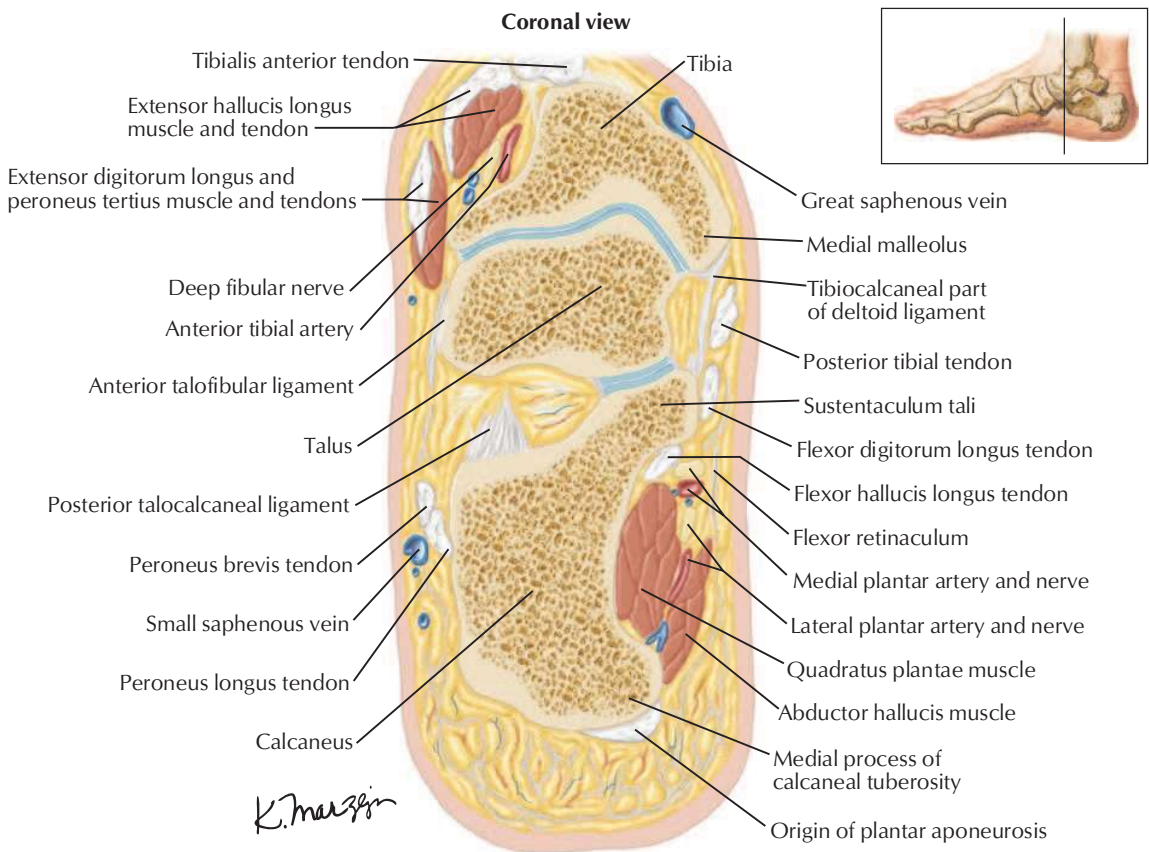
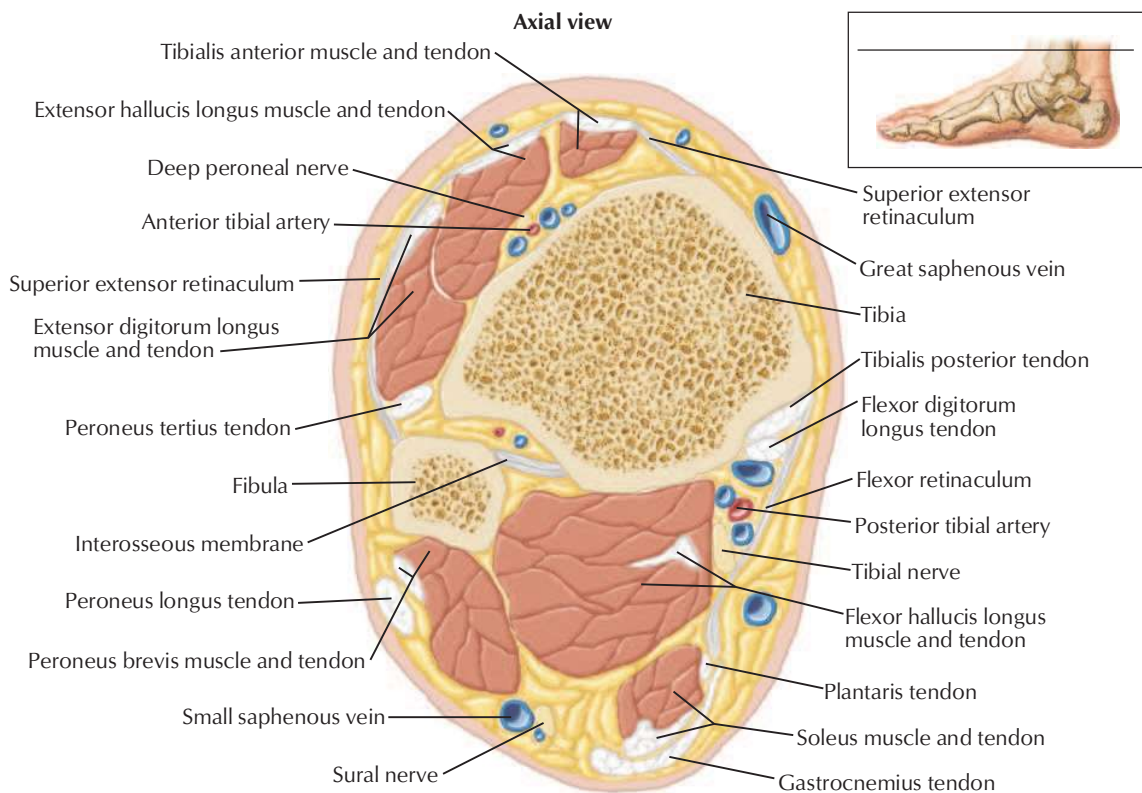


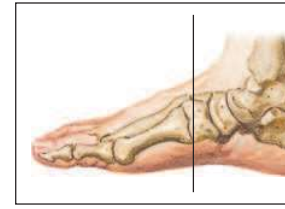Dorsal view



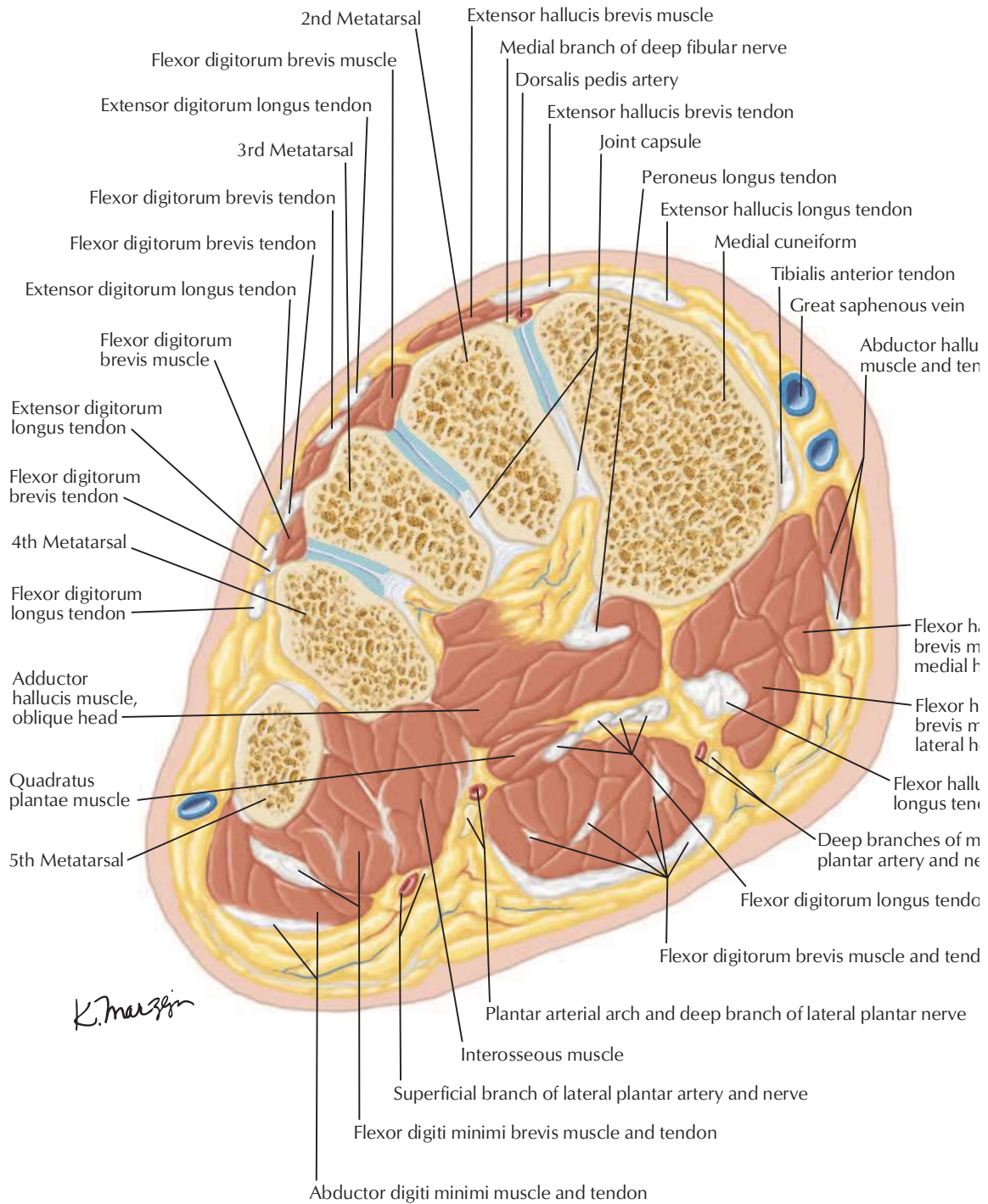
Plantar view

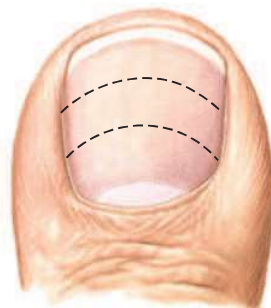
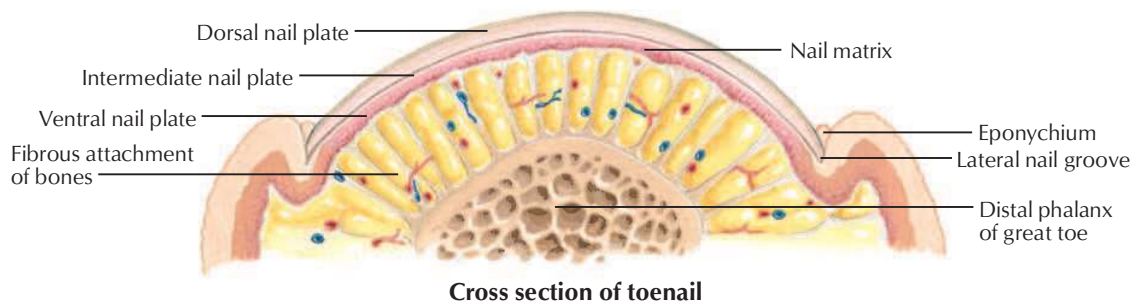
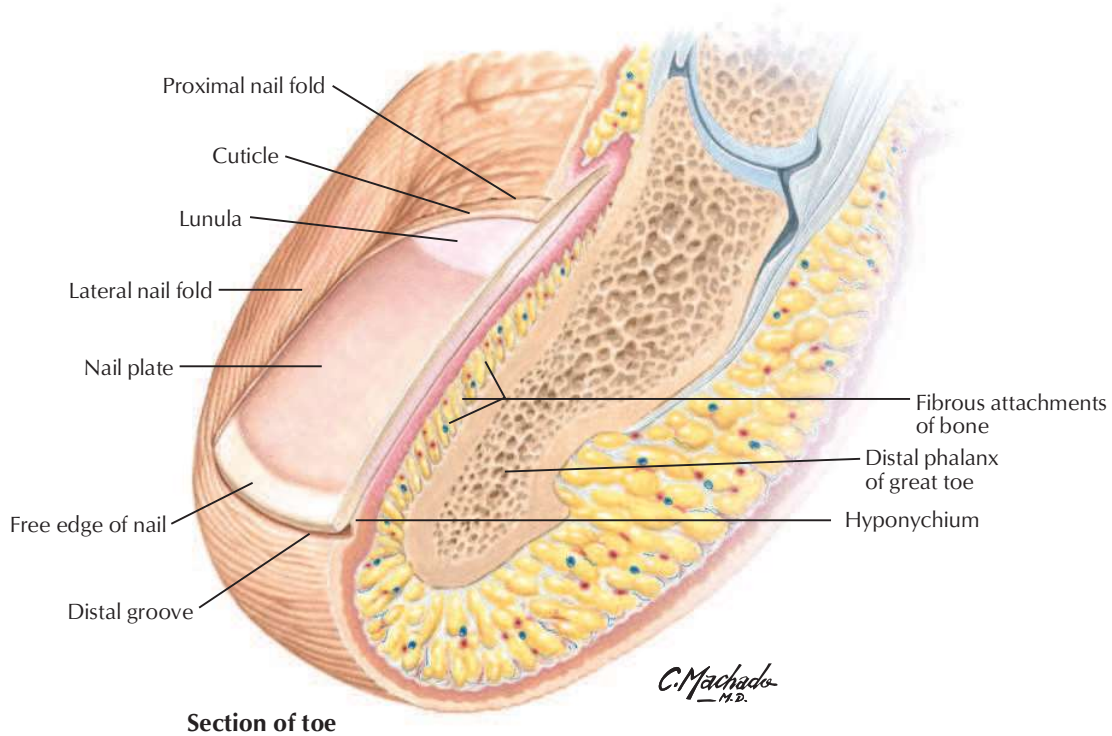






Coronal view





Toenail growth

The average growth rate of toenails is about 1 mm a month.

The rounded shape of the free edge of the nails is dictated by the shape of the lunula. After avulsion of a nail, the free edge of the new one grows parallel to the lunula.

This page intentionally left blank

REFERENCES

Plates 15, 43-45, 50-52

Lang J. *Clinical Anatomy of the Nose, Nasal Cavity, and Paranasal Sinuses*. New York: Thieme; 1989.

Plates 26-28

Baccetti T, Franchi L, McNamara J Jr. The cervical vertebral maturation (CVM) method for the assessment of optimal treatment timing in dentofacial orthopedics. *Semin Orthod*. 2005;11:119–129.

Roman PS. Skeletal maturation determined by cervical vertebrae development. *Eur J Orthod*. 2002;24:303–311.

Plate 30

Tubbs RS, Kelly DR, Humphrey ER, et al. The tectorial membrane: anatomical, biomechanical, and histological analysis. *Clin Anat*. 2007;20:382–386.

Plates 31-36, 55, 56, 69, 75, 81

Noden DM, Francis-West P. The differentiation and morphogenesis of craniofacial muscles. *Dev Dyn*. 2006;235:1194–1218.

Plate 34

Feigl G. Fascia and spaces on the neck: myths and reality. *Medicina Fluminensis*. 2015;51(4):430–439.

Jain M, Dhall U. Morphometry of the thyroid and cricoid cartilages in adults. *J Anat Soc India*. 2008;57(2):119–123.

Plates 39, 41, 136-142

Chang KV, Lin CP, Hung CY, et al. Sonographic nerve tracking in the cervical region: a pictorial essay and video demonstration. *Am J Phys Med Rehabil*. 2016;95:862–870.

Tubbs RS, Salter EG, Oakes WJ. Anatomic landmarks for nerves of the neck: a vade mecum for neurosurgeons. *Neurosurgery*. 2005;56(2 suppl):256–260.

Plate 50

de Miranda CMNR, Maranhão CPM, Arraes FMNR, et al. Anatomical variations of paranasal sinuses at multislice computed tomography: what to look for. *Radiol Bras*. 2011;44(4):256–262.

Souza SA, de Souza MMA, Idagawa M, et al. Computed tomography assessment of the ethmoid roof: a relevant region at risk in endoscopic sinus surgery. *Radiol Bras*. 2008;41(3):143–147.

Plate 55

Benninger B, Lee BI. Clinical importance of morphology and nomenclature of distal attachment of temporalis tendon. *J Oral Maxillofac Surg*. 2012;70:557–561.

Plate 58

Alomar X, Medrano J, Cabratosa J, et al. Anatomy of the temporomandibular joint. *Semin Ultrasound CT MRI*. 2007;28(3):170–183.

Campos PSF, Reis FP, Aragão JA. Morphofunctional features of the temporomandibular joint. *Int J*. 2011;29(4):1394–1397.

Cristo JA, Townsend GC. Discal attachments of the human temporomandibular joint. *Aust Dent J*. 2005;50(3):152–160.

Cuccia AM, Caradonna C, Caradonna D, et al. The arterial blood supply of the temporomandibular joint: an anatomical study and clinical implications. *Imaging Sci Dent*. 2013;43(1):37–44.

Langdon JD, Berkovitz BKV, Moxham BJ. *Surgical Anatomy of the Infratemporal Fossa*. London: Martin Dunitz; 2005.

Schmolke C. The relationship between the temporomandibular joint capsule, articular disc and jaw muscles. *J Anat*. 1994;184:335–345.

Siéssere S, Vitti M, de Sousa LG, et al. Bilaminar zone: anatomical aspects, irrigation, and innervation. *Braz J Morphol Sci*. 2004;21(4):217–220.

Plates 59, 69

Benninger B, Kloenne J, Horn JL. Clinical anatomy of the lingual nerve and identification with ultrasonography. *Br J Oral Maxillofac Surg*. 2013;51:541–544.

Plate 60

Joo W, Yoshioka F, Funaki T, et al. Microsurgical anatomy of the trigeminal nerve. *Clin Anat*. 2004;27:61–88.

Joo W, Yoshioka F, Funaki T, Rhoton AL Jr. Microsurgical anatomy of the infratemporal fossa. *Clin Anat*. 2013;26:455–469.

Plate 66

Fawcett E, Edin MB. The structure of the inferior maxilla, with special reference to the position of the inferior dental canal. *J Anat Physiol*. 1895;29(Pt 3):355–366.

He P, Truong MK, Adeeb N, et al. Clinical anatomy and surgical significance of the lingual foramina and their canals. *Clin Anat*. 2017;30:194–204.

Iwanaga J. The clinical view for dissection of the lingual nerve with application to minimizing iatrogenic injury. *Clin Anat*. 2017;30:467–469.

Otake I, Kageyama I, Mataga I. Clinical anatomy of the maxillary artery. *Okajimas Folia Anat Jpn*. 2011;87(4):155–164.

Siéssere S. Anatomic variation of cranial parasympathetic ganglia. *Braz Oral Res*. 2008;22(2):101–105.

Plates 67, 73

Benninger B, Andrews K, Carter W. Clinical measurements of hard palate and implications for subepithelial connective tissue grafts with suggestions for palatal nomenclature. *J Oral Maxillofac Surg*. 2012;70:149–153.

Plates 78, 106, 107

Kierner AC, Mayer R, v Kirschhofer K. Do the tensor tympani and tensor veli palatini muscles of man form a functional unit? A histochemical investigation of their putative connections. *Hear Res*. 2002;165:48–52.

Plates 85, 86

Benninger B, Barrett R. A head and neck lymph node classification using an anatomical grid system while maintaining clinical relevance. *J Oral Maxillofac Surg*. 2011;69:2670–2673.

Plates 91-93

Ludlow CL. Central nervous system control of the laryngeal muscles in humans. *Respir Physiol Neurobiol*. 2005;147:205–222.

Plate 98

Cornelius CP, Mayer P, Ehrenfeld M, Metzger MC. The orbits—anatomical features in view of innovative surgical methods. *Facial Plast Surg*. 2014;30:487–508.

Sherman DD, Burkat CN, Lemke BN. Orbital anatomy and its clinical applications. In: Tasman W, Jaeger EA, eds. *Duane's Ophthalmology*. Philadelphia: Lippincott Williams & Wilkins; 2006.

Plates 112-125

Rhoton AL Jr. *Cranial Anatomy and Surgical Approaches*. Schaumburg, IL: Congress of Neurological Surgeons; 2003.

Plates 115, 151

Tubbs RS, Hansasuta A, Loukas M, et al. Branches of the petrous and cavernous segments of the internal carotid artery. *Clin Anat*. 2007;20:596–601.

Plates 127-129, 135

Schrott-Fischer A, Kammen-Jolly K, Scholtz AW, et al. Patterns of GABA-like immunoreactivity in efferent fibers of the human cochlea. *Hear Res*. 2002;174:75–85.

Plates 169, 184

Tubbs RS, Loukas M, Slappey JB, et al. Clinical anatomy of the C1 dorsal root, ganglion, and ramus: a review and anatomical study. *Clin Anat*. 2007;20:624–627.

Plate 171

Forester O. The dermatomes in man. *Brain*. 1933;56:1–39.

Plates 171, 403

Keegan JJ, Garrett FD. The segmental distribution of the cutaneous nerves in the limbs of man. *Anat Rec*. 1948;102:409–437.

Plates 171, 403, 472, 517

Lee MW, McPhee RW, Stringer MD. An evidence-based approach to human dermatomes. *Clin Anat*. 2008;21:363–373.

Plate 177

Bosmia AN, Hogan E, Loukas M, et al. Blood supply to the human spinal cord: part I. Anatomy and hemodynamics. *Clin Anat*. 2015;28:52–64.

Plate 178

Stringer MD, Restieaux M, Fisher AL, Crosado B. The vertebral venous plexuses: the internal veins are muscular and external veins have valves. *Clin Anat*. 2012;25:609–618.

Plates 183, 184

Tubbs RS, Mortazavi MM, Loukas M, et al. Anatomical study of the third occipital nerve and its potential role in occipital headache/neck pain following midline dissections of the craniocervical junction. *J Neurosurg Spine*. 2011;15:71–75.

Vanderhoek MD, Hoang HT, Goff B. Ultrasound-guided greater occipital nerve blocks and pulsed radiofrequency ablation for diagnosis and treatment of occipital neuralgia. *Anesth Pain Med*. 2013;3:256–259.

Plates 188-190

Hassiotou F, Geddes D. Anatomy of the human mammary gland: current status of knowledge. *Clin Anat*. 2013;26:29–48.

Plate 206, 207

Hyde DM, Hamid Q, Irvin CG. Anatomy, pathology, and physiology of the tracheobronchial tree: emphasis on the distal airways. *J Allergy Clin Immunol*. 2009;124(6 suppl):S72–S77.

Plate 209

Ikeda S, Ono Y, Miyazawa S, et al. Flexible broncho-fiberscope. *Otolaryngology (Tokyo)*. 1970;42:855.

Plate 222

Angelini P, Velasco JA, Flamm S. Coronary anomalies: incidence, pathophysiology, and clinical relevance. *Circulation*. 2002;105:2449–2454.

Plates 222, 223

Chiu IS, Anderson RH. Can we better understand the known variations in coronary arterial anatomy? *Ann Thorac Surg*. 2012;94:1751–1760.

Plate 229

James TN. The internodal pathways of the human heart. *Prog Cardiovasc Dis*. 2001;43:495–535.

Plates 229-231

Hildreth V, Anderson RH, Henderson DJ. Autonomic innervation of the developing heart: origins and function. *Clin Anat*. 2009;22:36–46.

Plate 243

Yang HJ, Gill YC, Lee WJ, et al. Anatomy of thoracic splanchnic nerves for surgical resection. *Clin Anat*. 2008;21:171–177.

Plate 286

MacSween RNM, Anthony PP, Scheuer PJ, et al, eds. *Pathology of the Liver*. London: Churchill Livingstone; 2002.

Robinson PJA, Ward J. *MRI of the Liver: A Practical Guide*. Boca Raton, FL: CRC Press; 2006.

Plates 290, 291

Odze RD. *Surgical Pathology of the GI Tract, Liver, Biliary Tract, and Pancreas*. Philadelphia: Saunders; 2004.

Plate 308

Thomas MD. *The Ciba Collection of Medical Illustrations*. Vol. 3 part 2: *Digestive System: Lower Digestive Tract*. Summit, NJ: CIBA; 1970:78.

Plates 324, 349, 366, 378, 396

Stormont TJ, Cahill DR, King BF, Myers RP. Fascias of the male external genitalia and perineum. *Clin Anat*. 1994;7:115–124.

Plates 339, 345, 350, 353, 359, 360

Oelrich TM. The striated urogenital sphincter muscle in the female. *Anat Rec*. 1983;205:223–232.

Plochocki JH, Rodriguez-Sosa JR, Adrian B, et al. A functional and clinical reinterpretation of human perineal neuromuscular anatomy: application to sexual function and continence. *Clin Anat*. 2016;29:1053–1058.

Plates 343, 349

Myers RP, Goellner JR, Cahill DR. Prostate shape, external striated urethral sphincter, and radical prostatectomy: the apical dissection. *J Urol*. 1987;138:543–550.

Plates 343, 349, 365, 366

Oelrich TM. The urethral sphincter muscle in the male. *Am J Anat*. 1980;158:229–246.

Plate 356

Feil P, Sora MC. A 3D reconstruction model of the female pelvic floor by using plastinated cross sections. *Austin J Anat*. 2014;1(5):1022.

Shin DS, Jang HG, Hwang SB, et al. Two-dimensional sectioned images and three-dimensional surface models for learning the anatomy of the female pelvis. *Anat Sci Educ*. 2013;6(5):316–323.

Plate 385

Cahill D, Raychaudhuri B. Pelvic fasciae in urology. *Ann R Coll Surg Engl*. 2008;90:633–637.

Lee SE. A comprehensive review of neuroanatomy of the prostate. *Prostate Int*. 2013;1(4):139–145.

Nathoo N, Caris EC, Wiener JA, Mendel E. History of the vertebral venous plexus and the significant contributions of Breschet and Batson. *Neurosurgery*. 2011;69(5):1007–1014.

Pai MM, Krishnamurthy A, Prabhu LV, et al. Variability in the origin of the obturator artery. *Clinics (Sao Paulo)*. 2009;64(9):897–901.

Stoney RA. The anatomy of the visceral pelvic fascia. *J Anat Physiol*. 1904;38(4):438–447.

Walz J. A critical analysis of the current knowledge of surgical anatomy related to optimization of cancer control and preservation of continence and erection in candidates for radical prosta. *Eur Urol*. 2010;57:179–192.

Plate 472

Keegan JJ. Neurological interpretation of dermatome hypalgesia with herniation of the lumbar intervertebral disc. *J Bone Joint Surg Am*. 1944;26:238–248.

Last RJ. Innervation of the limbs. *J Bone Joint Surg Br*. 1949;31:452–464.

Plate 494

Beck M, Sledge JB, Gautier E, et al. The anatomy and function of the gluteus minimus muscle. *J Bone Joint Surg Br*. 2000;82(3):358–363.

Woodley SJ, Mercer SR, Nicholson HD. Morphology of the bursae associated with the greater trochanter of the femur. *J Bone Joint Surg Am*. 2008;90(2):284–294.

Plate 513

Aragão JA, Reis FP, de Figueiredo LFP, et al. The anatomy of the gastrocnemius veins and trunks in adult human cadavers. *J Vasc Br*. 2004;3(4):297–303.

This page intentionally left blank

INDEX

References are to plate numbers. In most cases, structures are listed under singular nouns

A

A1 pulley fibers, BP106

Abdomen, 249–332

- autonomic nerves and ganglia, 300
- axial CT images of, BP87, 326–327
- bony framework of, 250
- cross section of, BP84
- left lower quadrant of, 251
- left upper quadrant of, 251
- regions and planes of, 251
- right lower quadrant of, 251
- right upper quadrant of, 251
- superficial fascia of, 252
- surface anatomy of, 249
- transverse section of, 85–86

Abdominal aorta, BP56, BP84, BP98, T5.2, 185, 201, 217, 236, 266, 271, 274, 276, 278, 291, 295, 306, 311, 313, 317, 324, 330–332, 344, 346, 348, 380, 382–384, 394

Abdominal aortic plexus, 303, 392, 394, 396, 398–399. *See also* Intermesenteric (abdominal aortic) plexus

Abdominal cavity, BP3

Abdominal muscles, 344, 348

Abdominal oblique muscle, external, 413–414

Abdominal ostium, 355

Abdominal viscera, 270

Abdominal wall

- anterior, 266–267, 317
- arterial anastomoses of, T5.2
- arteries of, 258
- deep dissection of, 254
- intermediate dissection of, 253
- internal view of, 256
- nerves of, 260
- superficial dissection of, 252
- veins of, 259
- venous anastomoses of, T5.2
- paramedian (parasagittal) section of, 324
- posterior
 - arteries of, 266
 - internal view of, 265
 - lymph vessels and nodes of, 268
 - nerves of, 269
 - peritoneum of, 275
 - veins of, 267
- posterolateral, 257

Abdominis muscle

- rectus, 344, 347–349, 359, 379
- transverse, BP109
- transversus, 181, 185
- tendon of origin of, 181–182

Abdominopelvic cavity, BP3

Abducens nerve (CN VI), BP26, T2.2, 60, 64, 96–98, 115, 124, 128

- distribution of, 129
- imaging of, BP32
- schema of, 132
- in superior orbital fissure, 20

Abducens nucleus, 127–128, 132

Abduction, of lower limbs movements, 472

Abductor digiti minimi muscle, BP117, T8.3, T7.3, 452, 455, 460, 467, 520, 522, 524–527, 532

- nerve to, 525

Abductor digiti minimi tendon, BP117, 519

Abductor hallucis muscle, BP117, T8.3, BP116, 520, 522, 524–526, 532

- insertion of, 527

Abductor hallucis nerve, 532

Abductor hallucis tendon, BP117, 519, 524–525

Abductor pollicis brevis muscle, T7.3, 452, 455–456, 466

Abductor pollicis longus muscle, T7.3, 431, 434–435, 439–441, 469

Abductor pollicis longus tendon, 434, 438, 441, 457, 459–460

Aberrant ductule, 372

Accessory nerve (CN XI), T2.2, 39–41, 49, 64, 76, 82, 85–86, 115, 124, 127–128, 138, 140, 183, 417

- cranial root of, 138
- distribution of, 129
- in jugular foramen, 20
- in jugular fossa, 19
- schema of, 138
- spinal roots of, 20, 138
 - in foramen magnum, 19

Accessory nucleus, 127–128

Accessory oculomotor nucleus, 127–128, 132, 143

Accessory process, 164

Accessory saphenous vein, BP107

Acetabular branch, 495

Acetabular fossa, 400

fat in, 477

Acetabular labrum, 338, 477, 495

superior, 534

Acetabular ligament, transverse, 338, 477

Acetabular margin, 337–338, 342

Acetabular notch, 338, 476

Acetabulum, BP5, BP109, 338, 476, 478

lunate (articular) surface of, 400, 477

margin of, 476

radiograph of, 335

Acetabulum labrum

anterior, 534

posterior, 534

Achilles tendon, 518. *See also* Calcaneal tendon

Acinus, BP48

Acoustic meatus

external, BP28, BP24, 13, 17, 22, 105–106, 109

internal, BP28, 15, 20, 105, 134–135

Acoustic opening, internal, 110

Acromial anastomosis, 418

Acromial plexus, 418

Acromioclavicular joint, 412, 415

capsule, 412

Acromioclavicular ligament, 412

Acromion, BP5, BP23, 36, 194, 402, 409–413, 415, 417–419, 421, 470

of scapula, 192

Adamkiewicz, artery of, 176

Adduction, of lower limbs movements, 472

Adductor brevis muscle, T8.3, T8.1, 480–481, 483, 491, 496, 530

Adductor canal, BP107, 490

Adductor compartment, BP104

Adductor hallucis muscle, BP117, T8.3, 526

deep branch to, 532

insertion of, 527

oblique head of, 526

transverse head of, 526

Adductor hallucis tendon, 519

Adductor hiatus, 491–492, 503

Adductor longus muscle, T8.3, T8.1, BP109, 400, 480–483, 490–491, 496, 530

Adductor magnus muscle, T8.3, T8.1, 395, 471, 480–481, 483, 485, 490–492, 494, 496, 503, 530–531

adductor hiatus within, femoral artery passing through, BP108

adductor minimus part of, 483, 485, 492, 494

femoral artery, passing through adductor hiatus within, BP110

Adductor magnus tendon, 483, 491, 497, 502, 508

Adductor minimus muscle, 395

Adductor pollicis muscle, T7.3, BP105, 452–453, 455–456, 467

Adductor thigh muscle, T8.1

Adductor tubercle, 479

on medial epicondyle of femur, 491, 500

Aditus; *See* (aditus)

Adnexa, 355

Adrenal glands, BP38, BP57. *See also* Suprarenal glands

Adrenergic synapses, BP42

- schema of, BP41

Adventitia, BP16

Afferent fibers, 309

of autonomic reflex pathways, 307

of kidneys and upper ureters, 321

of lower ureter, 399

of reproductive organs, 397

male, 398

of tracheobronchial tree, 214

of urinary bladder, 399

Agger nasi, 43–44

Aggregate lymphoid nodules, 279. *See also* Peyer's patches (aggregate lymphoid nodules)

Ala, 17, 166

of ilium, 250, 334, 338, 342

of nose, 8

of sacrum, radiograph of, 335

Alar cartilage

major, 42, 44–45, 49

lateral crus of, 42

medial crus of, 42, 45

minor, 42

Alar fascia, 33–34

Alar fibrofatty tissue, 42, 44

Alar folds, 498

Alar ligaments, 30

Alveolar artery

- inferior, 47, 57–58, 69, 84
- lingual branch of, 83
- mental branch of, 57, 83
- mylohyoid branch of, 25, 83
- superior, 57
 - anterior, 57, 63
 - middle, 57, 63
 - posterior, 57, 60, 63, 83

Alveolar capillary, BP50

Alveolar ducts, BP48

opening of, BP48

Alveolar foramina, 13

Alveolar macrophage, BP50

Alveolar nerve

inferior, 25, 56–57, 59–60, 66, 69, 82, 133, 142, 145

superior

dental branches of, 63

gingival branches of, 63

infraorbital, 60

middle, 66

posterior, 60

Alveolar pores (of Kohn), BP48

Alveolar process, of maxillary bone, BP22, 11, 13, 15, 23, 44, 50

Alveolar sac, BP48

Alveolar veins

inferior, 84

posterior superior, 84

Alveolar wall

capillary bed within, BP49

capillary plexuses within, BP49

Alveoli, BP48, BP50

Amacrine cells, 131

Amorphous matrix, BP6

- Ampulla**, 355
of ductus deferens, BP93, 366
of ear, 109
 anterior, 108
 lateral, 108
 posterior, 108
of rectum, 350
of uterine tube, 357
- Amygdaloid body**, 121, 123, 130, 146
- Anal canal**, 375
arteries of, 380
muscularis mucosae of, 375–376
veins of, 381
- Anal cleft**. *See* Intergluteal cleft
- Anal columns, Morgagni's**, 375
- Anal crypt**, 375
- Anal glands**, 375
- Anal nerves, inferior**, 306, 361, 392–393, 395–396, 487, 493
- Anal pit**, 370
- Anal region**, 3
- Anal sinus**, 375
- Anal sphincter muscle**
external, T6.3, 283, 306, 339, 345, 349–350, 359–360, 363–364, 373–374, 376–377, 380, 386
 attachment of, 341
 deep, 324, 349, 373, 376–378
 subcutaneous, 324, 349, 373, 376–378
 superficial, 324, 349, 373, 376–378
 internal, 374, 376
- Anal triangle**, 362
- Anal tubercle**, 370
- Anal valve**, 375
- Anal verge**, 375
- Anastomosis**
 between medial and lateral circumflex femoral arteries, 495
 paravertebral, 177
 patellar, 503
 prevertebral, 177
- Anastomotic loops**
 to anterior spinal artery, 176
 of ileum, 279
 of jejunum, 279
 to posterior spinal artery, 176
- Anastomotic vein**
 inferior (of Labbé), 113, 156
 superior (of Trolard), 113
- Anatomical snuffbox**, 402, 434
- Anconeus muscle**, T7.3, 410, 422, 434–435, 440–441, 468–469
- Angle of mandible**, 8, 12, 22, 24, 76, 79
- Angular artery**, 10, 42, 57, 83, 99, 149
- Angular gyrus**, 116
 artery to, 152–153
- Angular vein**, 10, 84, 99
- Ankle**, T8.1
 cross-sectional anatomy of, 115–116
 ligaments of, 518
 radiographs of, 535
 tendon of, 518
 tendon sheaths of, 520
- Annular hymen**, BP96
- Anococcygeal body**, 341, 359–360, 377–378
- Anococcygeal ligament**, 364, 378
- Anococcygeal nerves**, 393, 395, 487, 489
- Anoderm**, 375
- Anorectal flexure**, 400
- Anorectal hiatus**, 342
- Anorectal junction**, 343
- Anorectal line**, 375
- Anorectal musculature**, 376
- Ansa cervicalis**, 38–41, 139–140
 inferior root of, 39–41, 82, 87, 139–140
 superior root of, 39–41, 82, 87, 139–140
- Ansa of Galen**, 92
- Ansa pectoralis**, 419
- Ansa subclavia**, 141, 213, 230–231, 243
- Anserine bursa**, 498
 deep to semitendinosus, 497
- Antebrachial cutaneous nerve**
 lateral, 404–406, 421, 425, 436, 438, 441, 459, 462–465
 medial, 404–405, 419–420, 423, 425, 441, 459, 462–466
 posterior, 404–406, 422, 425, 441, 458–459, 462, 464, 468–469
- Antebrachial fascia**, 441
- Antebrachial region**
 anterior, 2
 posterior, 2–3
- Antebrachial vein, median**, BP99, 402, 405–406, 441
- Anterior chamber**
 of eye, 94, 100, 102–103
 of eyeball, 101
- Anterior femoral cutaneous vein**, BP107
- Anterior plane**, 1
- Anterior ramus**, 177
- Anterior root**, 177
 rootlets of, 174
- Anterior root ganglion**, 399
- Anterior tibial artery**, BP116, 512–513
- Anterior tibial veins**, BP107
- Anterolateral system (ALS)**, BP43
- Antidromic conduction**, BP41
- Antihelix**, 8, 106
 crura of, 106
- Antitragus**, 8, 106
- Anular ligaments**, 208
- Anulus fibrosus**, 164, 168
- Anus**, 341, 345, 358, 362, 364, 370, 377
- Aorta**, BP44, BP38, BP87, 33, 149, 177, 211, 217, 223–224, 233, 244, 309, 323, 325, 327, 385
 abdominal, BP84, T5.2, 185, 266, 271, 274, 276, 278, 291, 295, 306, 311, 313, 317, 324, 330–332, 344, 346, 348, 380, 382–384, 394
 ascending, BP57, 149, 219, 221, 224, 227–229, 244, 247
 descending, 149
 thoracic, 4, 177
 ureteric branch from, 317
- Aortic arch**, BP23, BP57, 4, 87–88, 149, 217
- Aortic arch lymph node of ligamentum arteriosum**, 212
- Aortic heart valve**, BP57, 41–42, 217, 221, 225–229
 left semilunar cusp of, 225–229
 posterior semilunar cusp of, 225–229
 right semilunar cusp of, 225–229
- Aortic hiatus**, 201
- Aortic nodes, lateral**, 388
- Aortic plexus, abdominal**, 397
- Aortic sinuses (of Valsalva)**, 227
- Aorticorenal ganglion**, BP39, 172, 269, 303–304, 306, 320–322, 391, 396–397, 399
 left, 299, 305, 392, 398
 right, 300, 305
- Apical ligament, of dens**, BP19, 30, 77–78
- Apical trabeculations**, 224
- Aponeurosis, of external abdominal oblique muscle**, 359, 363
- Appendicular artery**, 280, 294–295, 305
- Appendicular vein**, 298–299
- Appendix**, BP62, T5.1, 137, 282
 of epididymis, 369, 371
 of testis, 369, 371
- Arachnoid**, 111, 113
- Arachnoid-dura interface**, 113
- Arachnoid granulations**, 111–113, 120
- Arachnoid mater**, 120, 174, 177
- Arch of aorta**, BP56, BP51, 202, 210, 214–216, 218–219, 225, 229, 235–237, 240, 246
 lung groove for, 205
- Arcuate artery**, BP110, BP115, 314, 503, 512, 521, 527
- Arcuate eminence**, 18, 105
- Arcuate ligament**
 inferior, 343
 lateral, 201, 265
 medial, 201, 265
- Arcuate line**, 250, 254, 256, 258, 262, 334, 338–339, 342, 476
 of ilium, 340
- Arcuate nucleus**, 158
- Arcuate popliteal ligament**, 499
- Arcuate public ligament**, 359, 365
- Arcus tendineus fasciae pelvis**, 354
- Areola**, 188
- Areolar glands (of Montgomery)**, 188
- Areolar tissue**, 185, 349
 loose, 113
- Areolar venous plexus**, 259
- Arm**
 arteries of, BP100, 424
 muscles of
 anterior views of, 421
 posterior views of, 422
 radial nerve in, 468
 serial cross sections of, 425
- Arrector pili muscle**, 1–2
 innervation to, 172
- Arteriae rectae**, 294–295
- Arterial arches, superficial palmar**, 450
- Arterial rete, marginal**, 107
- Arterial wall**, BP16
 avascular zone, BP16
 matrix of, BP16
 vascular zone, BP16
- Arteries**. *See also specific arteries*
 of anal canal, 380
 of brain
 frontal section of, 152
 frontal view of, 152
 inferior view of, 150
 lateral view of, 153
 medial view of, 153
 of deep face, 63
 of ductus deferens, BP98, 380, 383
 of duodenum, 291, 293
 of esophagus, BP55, 240
 of eyelids, 99
 of hypothalamus and hypophysis, BP30
 of large intestine, 295
 of liver, 290–291
 of malleolar stria, 107
 of mammary gland, 189
 of nasal cavity, 47
 of oral and pharyngeal regions, 83
 of orbit, 99
 of pancreas, 291, 293
 of pelvic organs, female, 382
 of pelvis
 female, 383
 male, BP98, 385
 of penis, T6.2
 of perineum, 386
 male, 387
 of posterior cranial fossa, 154
 of rectum, 380
 of round ligament, 382
 of scalp, T2.2
 of small intestine, 294
 of spinal cord
 intrinsic distribution, 177
 schema of, 176
 of spleen, 290–291

Arteries (Continued)

- of stomach, 290
 - of testis, 383
- Arteriole**
- intralobular, 286
 - macular
 - inferior, 103
 - superior, 103
 - nasal retinal
 - inferior, 103
 - superior, 103
 - periportal, 286
 - portal, 286
 - temporal retinal
 - inferior, 103
 - superior, 103
- Artery of Adamkiewicz**
- , 176
- Articular branch**
- , 492, 529
- Articular cartilage**
- , BP5, BP106, BP114, 428, 460–461, 477
- Articular cavity**
- , BP19, 193, 460–461, 502
- of sternoclavicular joint, 408
- Articular disc**
- , BP102, 24–25, 60, 193
- of sternoclavicular joint, 408
- Articular facet**
- cervical, 26
 - inferior, 27
 - superior, 26
 - of dens, posterior, 30
 - inferior, 168
 - for sacrum, 164
 - thoracic, superior, 163
 - vertebral body for, 193
 - inferior, 193
 - superior, 193
 - transverse, 193
- Articular nerve, recurrent**
- , 533
- Articular process**
- cervical
 - inferior, 26–28
 - superior, BP18, 27–28
 - lumbar
 - inferior, 164, 167–168
 - superior, 164, 167–168
 - sacral, superior, 166
 - thoracic
 - inferior, 163
 - superior, 163
- Articular surface, superior**
- , 505
- Articular tubercle**
- , 13, 17, 25, 56
- Articularis genu muscle**
- , T8.3, 480, 498, 502, 529
- Aryepiglottic fold**
- , 75, 79, 91
- Arytenoid cartilage**
- , 90
- muscular process of, 90–91
 - vocal process of, 90–91
- Arytenoid muscle**
- oblique, T2.9, 75, 80, 91–92
 - action of, 93
 - aryepiglottic part of, 91–92
 - transverse, T2.9, 75, 77, 80, 91–92
 - action of, 93
- Ascending cervical artery**
- , 176
- Ascending colon**
- , 344, 348
- as site of referred visceral pain, BP13
- Ascending fibers**
- , 321, 399
- Asterion**
- , 13
- Atlantoaxial articulation**
- , BP35
- Atlantoaxial joint**
- , BP34
- lateral, 29
 - capsule of, 29–30
 - median, 30
- Atlantoaxial ligament**
- , 30
- Atlantoaxial membrane, posterior**
- , BP19
- Atlantooccipital joint, capsule of**
- , 29–30
- Atlantooccipital junction**
- , BP19
- Atlantooccipital ligament, anterior**
- , 30

Atlantooccipital membrane

- anterior, BP19, 29, 77–78
 - posterior, BP19, 29
- Atlas (C1)**
- , BP5, BP18, 22, 28–30, 169
- anterior arch of, BP35, BP42, BP34
 - anterior tubercle of, 28
 - anterior view of, 162
 - arch of
 - anterior, BP19, BP17, 14, 26, 28, 77
 - imaging of, 160
 - posterior, 26
 - dens of, articular facet for, 26
 - groove for vertebral artery of, 26
 - inferior articular surface of, BP35
 - inferior longitudinal band of cruciate ligament of, BP19
 - inferior view of, 26
 - lateral mass of, 12, 26
 - left lateral view of, 162
 - posterior arch of, BP35, BP19, BP17, BP34, 184
 - posterior tubercle of, 182
 - posterior view of, 162
 - superior articular facet for, 26
 - superior longitudinal band of cruciate ligament of, BP19
 - superior view of, 26
 - transverse foramen of, 26
 - transverse ligament of, BP19, 30
 - tubercle for, 26
 - transverse process of, 26, 29, 37, 182
 - tubercle of
 - anterior, 26, 30
 - posterior, 26, 181
 - vertebral foramen of, 26
- Atonic stomach**
- , BP60
- Atrial appendage**
- .
- See*
- Auricle (atrial appendage)
- Atrioventricular (AV) bundle (of His)**
- , 229
- Atrioventricular (AV) node**
- , 229
- Atrioventricular valve**
- left, 220–221, 225–229, 248
 - anterior cusp of, 225–228
 - left fibrous ring of, 226
 - posterior cusp of, 225–228
 - right, 220–221, 224, 226–228
 - anterosuperior leaflet (cusp) of, 224, 226–228
 - inferior leaflet (posterior cusp) of, 224, 226–228
 - orifice of, 248
 - right fibrous ring of, 226, 229
 - septal leaflet (cusp) of, 224, 226–228
- Atrium**
- , 228
- left, BP56, BP51, 217–220, 224–225, 227–228, 244, 248
 - oblique vein of (of Marshall), 218–219, 222, 225
 - right, BP51, 216, 218–221, 227–228, 234, 244, 248
- Auditory canal, internal, imaging of**
- , BP32
- Auditory ossicles**
- , BP4
- Auditory tube**
- , 27–29, 105–107, 109, 137
- cartilaginous part of, BP29, 49, 56, 67, 72, 75, 78
 - lateral lamina of, BP29
 - medial lamina of, BP29
 - groove for, 17
 - opening of, 43
 - pharyngeal opening of, 72, 77, 79
- Auerbach's plexus**
- , BP54.
- See also*
- Myenteric (Auerbach's) plexus
- Auricle (atrial appendage)**
- , BP28, 14, 105, 110
- concha of, 106
 - left, 56–57, 216, 218–219, 222–223, 225, 228–229
 - lobule of, 106
 - right, BP51, 216, 224, 228

Auricular artery

- anterior, 10
 - deep, 57–58, 107
 - posterior, 10, 41, 57, 60, 83, 107, 112, 147, 149, 184
- Auricular cartilage**
- , 49
- Auricular muscle, branches to**
- , 134
- Auricular nerve**
- great, 9, 38–40, 140, 183
 - posterior, BP21, 54, 59, 134
 - occipital branch of, 134
- Auricular surface**
- , 166
- of sacrum, 167, 476
- Auricular tubercle (of Darwin)**
- , 106
- Auricular vein, posterior**
- , 10, 39, 84
- Auricularis muscle**
- anterior, BP20, T2.4, 31
 - posterior, T2.4, 31
 - superior, T2.4, 31
- Auriculotemporal nerve**
- , 9, 25, 53, 56–57, 59–60, 82–83, 133, 136, 145
- roots of, 60
- Auscultation**
- of heart, 217
 - precordial areas of, 217
- Autonomic nerves**
- .
- See also*
- Motor (autonomic) nerve
- in head, 142
 - in neck, 141
 - in thorax, 213
- Autonomic neurons, postganglionic**
- , BP11
- Autonomic reflex pathways**
- , 307
- Axilla**
- anterior view, 419
 - posterior wall of, 414
- Axillary artery**
- , BP23, BP56, BP100, 4, 189, 195, 204, 258, 416, 418–419, 423–424
- acromial branch of, BP100
 - clavicular branch of, BP100
 - left, 199
 - pectoral branch of, BP100
 - right, 199
- Axillary fasciae**
- , 416
- Axillary fold**
- anterior, 187
 - posterior, 187
- Axillary fossa**
- , 245–247
- Axillary lymph nodes**
- , 7, 41–42, 416
- anterior, 190
 - apical, 190–191
 - central, 190–191, 416
 - lateral, 190–191, 407
 - pectoral, 416
 - posterior, 190–191
- Axillary nerve**
- , T7.1, 404, 414, 417, 419–420, 422, 464–466, 468–469
- branches of, 414
 - superior lateral brachial cutaneous nerve from, 183, 404
- Axillary region**
- , 2
- Axillary tail (of Spence)**
- , 189
- Axillary vein**
- , BP56, BP99, 5, 195, 204, 259, 407, 416
- intercostal tributaries, 259
 - right, 217
- Axis (C2)**
- , BP18, 22, 28–30, 169
- anterior view of, 26, 162
 - body of, 26, 29
 - dens of, BP19, 12, 14, 26, 28, 77
 - inferior articular process, 26
 - inferior articular surface of lateral mass for, 26
 - interarticular part of, 26
 - left lateral view of, 162
 - odontoid process of, BP34
 - pedicle of, 26
 - posterior view of, 162
 - posterosuperior view of, 26

Axis (C2) (*Continued*)
spinous process of, BP19, 26, 180, 182
superior articular facet of, BP35
transverse process of, 26
posterior tubercle of, 37
vertebral body of, imaging of, 160

Axolemma, BP11
Axon hillock, BP11
Axon nerve, BP11
Axons, BP11
myelinated, cell membrane of, BP12

Azygos vein, BP84, BP57, 198, 200, 210–211, 213, 220, 234, 241, 247–248, 328
arch of, 236
lung groove for, 205

B

Back, 161–186
lumbar region of, 185
muscles of
deep layers, 182
intermediate layers, 181
superficial layers, 180
nerves of, 183
surface anatomy of, 161

Ball-and-socket joints, BP5
Bartholin's gland, 360–361, 371, 386
opening of, 358
primordium, 371

Basal nuclei, 121
Basal vein (of Rosenthal), 155–157
Basement membrane, BP8, BP93, BP16
Basilar artery, 147, 149–152, 154, 176
imaging of, 31–32, 159–160

Basilar membrane, 109
Basilic hiatus, BP99
Basilic vein, BP99, 5, 402, 405–407, 419, 425, 441, 458
median, BP99

Basivertebral vein, BP42, 178
Batson, internal vertebral venous plexus of, 177–178

Biceps brachii muscle, T7.3, T7.1, 187, 402, 409, 413–414, 416, 419, 421, 423, 425, 439–440, 463, 465
long head of, 245
tendon of, 246–247

Biceps brachii tendon, T7.1, 412, 415, 417, 421, 423, 428, 436–438

Biceps femoris muscle, T8.3, T8.1, 471, 480–481, 484–485, 492–493, 496–497, 501, 506–507, 510
long head of, 395, 471, 510, 531
tendon of, 494
short head of, 395, 471, 510, 531
superior bursa of, 494

Biceps femoris tendon, 497–498, 501–502, 505, 508–512, 533

Bicipital aponeurosis, 406, 421, 423, 436, 463
Bicipital groove, 409
Bifid spinous process, 27
Bifurcate ligament, 518
Bifurcation. See Pulmonary trunk
Bile ducts, 137, 173, 286
common, BP62, BP87, 274, 278–279, 284–285, 287, 290–293, 329
sphincter, 287
innervation to, 172

Biliary disease, areas of referred pain in, 309
Bipolar cells, 131
Bladder, T6.1, BP88, BP109, BP89, 351, 359.
See also Urinary bladder
fundus of, 352
lateral ligament of, 347

Bladder (*Continued*)
neck of, 352
pubocervical fascia, 354
trigone of, 352, 356
uvula of, 352, 366–367

Bladder-prostate gland junction, 400
Blood, composition of, BP15
Blood vessels. See Vessels
Bloodless fold of Treves, 280. See also Ileocecal fold (bloodless fold of Treves)

Body cavities, BP3
dorsal, BP3
ventral, BP3

Body planes, terms and relationship of, 1
Bohler's angle, 517
Bone marrow, 7
Bones
architecture of, BP7
of foot, 515
of nasal cavity, 52
of paranasal sinuses, 52
of thorax, 192

Bony labyrinth, 108–109
Bony spicule, 27
Bouton, BP11
Brachial artery, T7.2, 4, 100–101, 189, 418–419, 421, 424–425, 436–438, 463
branches of, 435
lateral cord of, 423
medial cord of, 423
middle collateral branch of, 435
muscular branch of, 423
pulses at, 4
in situ, 423

Brachial cutaneous nerve
inferior lateral, 405, 422, 468–469
medial, 405, 419–420, 423, 425, 463–466
posterior, 405, 422, 464, 468–469
superior lateral, 183, 405, 414, 417, 422, 468–469

Brachial fascia, 416, 425
Brachial plexus, 8, 36, 38–40, 82, 169, 189, 195, 199, 204, 210, 215, 232, 234–236, 416–417, 419
anterior divisions of, 420
inferior trunks of, 414, 420
lateral cord of, 221, 416, 420, 464–466
medial cord of, 416, 420, 464–466
middle trunks of, 414, 420
posterior cord of, 416, 420, 464–466
posterior divisions of, 420
roots of, 420
schema of, 420
superior trunks of, 414, 420
terminal branches of, 420
trunks of, 37, 414

Brachial region
anterior, 2
posterior, 2–3
Brachial veins, BP99, 5, 419, 425
Brachialis muscle, T7.3, 409–410, 419, 421, 423, 425, 436, 438–439, 463, 465
Brachiocephalic artery, 217
Brachiocephalic trunk, BP23, 40, 87–89, 147, 149, 196, 199, 210, 215–216, 218, 221, 236, 240, 245
Brachiocephalic vein, 5, 87, 196, 212
left, BP51, BP57, 84, 88, 179, 198, 210, 215–216, 221, 234–236, 241, 245
lung groove for, 205
right, BP51, BP57, 88, 179, 198, 210, 215–217, 234, 237, 241, 245
Brachioradialis muscle, T7.3, 402, 409, 421–423, 425, 434–437, 439–441, 463, 468–469
Brachioradialis tendon, 438, 441

Brain, BP22, 6, 50
arteries of, 147
frontal section of, 152
frontal view of, 152
inferior view of, 150
lateral view of, 153
medial view of, 153
schema of, 149
axial and coronal MRIs of, BP32
inferior view of, 118
lateral view of, 116
medial view of, 117
veins of
deep, 156
subependymal, 157
ventricles of, 119
Brainstem, 124
cranial nerve nuclei in, 127–128
Breast, 217
lymphatic drainage of, 191
pathway to/from opposite, 190
suspensory retinacula of, 188
Bregma, 16
Bridging vein, T2.2, 111, 113–114, 120
imaging of, BP31, 159
Broad ligament, 344–346, 353, 371
anterior lamina of, 357
posterior lamina of, 357
Bronchi, BP41, 173, 208–209
extrapulmonary, 208
inferior lobar, 208
anterior basal, 209
anteromedial basal, 209
lateral basal, 209
medial basal, 209
posterior basal, 209
innervation to, 172
intermediate, 205
intrapulmonary, 208
lingular, 208–209
inferior, 209
superior, 209
main
left, BP44, BP57, 205, 208, 210–211, 220, 235–238, 247
right, BP44, BP57, 208, 211, 217, 220, 234, 236, 244, 247
major, 208
middle lobar, 208
lateral, 209
medial, 209
nomenclature of, schema of, 209
superior division, 208
anterior, 209
apicoposterior, 209
superior lobar, 208
anterior, 209
apical, 209
posterior, 209
right, 210
Bronchial artery, BP49, 211, 234–235
esophageal branch of, 211
left, 205
inferior, 211, 240
superior, 211, 240
right, 205, 211, 240
Bronchial veins, 211
left, 211
right, 211
Bronchioles
respiratory, 48–49
terminal, BP48
elastic fibers of, BP48
smooth muscle of, BP48
Bronchomediastinal lymphatic trunk, 212
Bronchopulmonary (hilar) lymph nodes, 193, 234–235

- Bronchopulmonary segments**, 206–207
 anterior, 206–207
 basal, 206–207
 anteromedial basal, 206–207
 apical, 206–207
 apicoposterior, 206–207
 inferior lingular, 206–207
 lateral, 206–207
 basal, 206–207
 medial, 206–207
 basal, 206–207
 posterior, 206–207
 basal, 206–207
 superior, 206–207
 lingular, 206–207
- Bronchus intermedius**, BP57
- Buccal artery**, 57, 83
- Buccal nerve**, 9, 57, 59–60, 66, 82, 133
 long, 68
- Buccinator lymph nodes**, 85
- Buccinator muscle**, T2.4, BP22, 20–21, 31, 34, 50, 53, 55–56, 59, 67–68, 78, 81, 83, 134
- Buccopharyngeal fascia**, 33, 68, 77–78
- Buck's fascia**, 364. *See also* Deep (Buck's) fascia
 intercavernous septum of, 367
 of penis, BP88, BP98, 349, 362–365, 369, 377–378, 387
- Bulbar conjunctiva**, BP26, 94, 100–101
- Bulboreticulospinal tract**, BP43
- Bulbospongiosus muscle**, BP90, T6.3, 324, 349, 352–353, 356, 359–361, 363, 365, 377–378, 386–387, 399
- Bulbourethral (Cowper's) gland**, 256, 324, 349, 352, 365–367, 371
 duct of, 365
 primordium, 371
- Bulbourethral ducts**, 366–367
- Buttock, nerves of**, 493
- C**
- Calcaneal artery**
 lateral, 525–526
 medial, 525–526
- Calcaneal bursa, subcutaneous**, 520
- Calcaneal nerve**
 lateral, 525–526
 medial, 525–526
- Calcaneal sulcus**, 517
- Calcaneal tendon**, BP111, T8.1, 471, 507–510, 518, 520, 535
 soleus muscle into, 508
- Calcaneal tuberosity**, 471, 507–508
 medial process of, BP116
- Calcaneocuboid ligament**, 518, 527
 dorsal, 518
- Calcaneofibular ligament**, 505, 517
- Calcaneonavicular ligament**, 518
- Calcaneus bones**, T8.1, BP116, 515–516, 519, 535
 tuberosity of, 519, 525–526
- Calcar avis**, 122–123
- Calcarine sulcus**, 116–118, 122, 131
- Callosomarginal artery**, 152–153
- Calot's triangle**, 287
- Calvaria**, 113
 inferior view of, 16
 superior view of, 16
- Camper chiasm**, 451
- Camper's fascia**, BP88. *See also* Fatty (Camper's) fascia
- Camper's layer**, 252, 324, 359
 of superficial fascia, 362
- Canal of Schlemm**, 101, 103–104
- Canine teeth**, 73–74
- Capillaries**, BP6
 in Haversian canal, BP7
- Capillary lumen**, BP50
- Capillary plexus**, BP50
- Capitate bone**, BP102, 442–443, 445–447, 452
- Capitohamate ligament**, 444–445
- Capitotriquetral ligament**, BP102
- Capitulum**, 409–410, 426–427
- Capsular branches**, BP98
- Capsular ligaments**, 412
- Cardiac branches**, 172
- Cardiac impression**, 205
- Cardiac notch**, 239, 276
 of left lung, 202, 205
- Cardiac orifice**, 277
- Cardiac plexus**, 39–40, 137, 213, 230–231, 243
- Cardiac veins**, BP52
 anterior, 222
 great, 222
 middle, 218, 222
 small, 222
 variations of, BP53
- Cardiac zone**, 277
- Cardinal (Mackenrodt's) ligament**, 346, 353–354
 with uterine artery, 347
- Cardiophrenic angle**, 217
- Cardiovascular system**, T6.2, T3.1, T5.2, 41–42
 composition of blood and, BP15
 general organization of, BP14
- Carina**, 217
- Carinal lymph nodes, inferior**, 212
- Caroticotympanic artery**, 148
- Caroticotympanic nerve**, 134
- Carotid artery**, 41
 common, T2.2, 10, 33, 38, 40–41, 64, 76, 82–84, 87–89, 136, 139, 141–142, 144–145, 147, 149, 196, 204, 236, 240
 left, BP51, 4, 179, 199, 210, 215–218, 221, 245
 right, BP23, 4, 37, 179, 199, 210, 217
 external, 10, 32, 35, 38, 41, 47, 53, 57, 60, 63–64, 68, 70, 76, 82–84, 87–89, 107, 112, 136, 141–142, 145, 147, 149
 left, 58
 right, BP23, 58
 schema of, 41
 internal, BP27, 10, 41, 49, 56, 60, 62, 64, 76, 82–83, 87–89, 99, 107, 112, 115, 136, 139, 141–145, 147, 149–152
 caroticotympanic branch of, 149
 in carotid canal, 19–20
 cavernous part of, 148
 cavernous segment of, 115
 cerebral part of, 148
 cervical part of, 148
 imaging of, 31–32, 159–160
 left, 153–154
 meningohypophyseal trunk of, 112
 petrous part of, 148
 in petrous part of temporal bone, 148
 right, BP23, 153
 pulses at, 4
- Carotid body**, 41, 136, 141, 147, 214
- Carotid canal**, 17, 19–20
- Carotid-cavernous sinus fistula**, T2.3
- Carotid groove**, 18
- Carotid nerve**
 external, BP39, 172
 internal, 62, 64, 141–142, 144, 172, 232
- Carotid plexus**, 107, 142
 common, 141–142
 external, 141–142, 144
 internal, 20, 97, 134, 142–143, 172
- Carotid sheath**, 32–33
- Carotid sinus**, T2.3, 136, 141, 147, 214
- Carotid sinus nerve (of Hering)**, 136, 141–142
- Carotid tubercle (of Chassaignac)**, 28
- Carpal arch, dorsal**, 459
- Carpal artery, dorsal**, BP101, 424
- Carpal articular surface**, 429
- Carpal bones**, BP4, 442–461
- Carpal ligament**
 palmar, 406, 436–437, 444, 449–450, 452, 456, 467
 transverse, BP104
- Carpal tunnel release**, BP104
- Carpometacarpal joint**, 443, 445
 1st, BP102
- Carpometacarpal ligaments**
 dorsal, BP102
 palmar, BP102, 448
- Cartilage**, BP6
 articular, BP6
 of larynx, 90
 of thyroid, 8
- Cartilage end plate**, 168
- Cast-off cytoplasm**, BP93
- Cauda equina**, T3.1, 169–170, 185
 anterior roots forming, 177
 nerve roots, within thecal sac, BP38
 posterior roots forming, 177
 radiology of, 165
- Caudal, as term of relationship**, 1
- Caudate nucleus**, 121
 anterior vein of, 156–157
 body of, 117, 121
 head of, 121–123, 154, 156
 imaging of, BP32, 160
 posterior terminal vein of, 157
 posterior vein of, 156
 tail of, 119, 121, 123
 transverse veins of, 156–157
- Caval foramen**, 265
 opening of, 201
- Cave of Retzius**, 324
- Cavernous nerves**, BP40, T6.2
 of penis, 392, 398
- Cavernous plexus**, 132
- Cavernous sinus**, 99, 115, 147, 151
- Cavernous tissue**, T6.2
- Cavernous vein**, 385
- Cavernous venous plexus, of urethra**, BP90
- Cavum septum pellucidum**, 111
- Cecal artery**, 305
 anterior, 280, 294–295
 posterior, 280, 294–295
- Cecal folds**, 280, 344, 348
- Cecal vein**
 anterior, 299
 posterior, 298–299
- Cecum**, BP62, BP66, 85–86, 137, 270, 272, 282–283, 344, 348
 peritoneal attachment of, BP66
 as site of referred visceral pain, BP13
 vascular fold of, 280
- Celiac branch**, 392
- Celiac ganglion**, BP39, BP41, BP84, T5.2, 172–173, 300–301, 303–306, 309–310, 320–322, 391–392, 396–399
- Celiac nodes**, 242, 268
- Celiac plexus**, 301, 304–305, 321, 392, 397
 posterior vagal trunk to, 243
- Celiac trunk**, BP57, 4, 201, 233, 236, 240, 266, 271, 288, 292–293, 303, 310, 324, 392
 arteriogram of, 292
 variations in, BP72
- Central arteries**
 anterolateral, 148, 150–152, 154
 anteromedial, 151
 posteromedial, 151
- Central axillary nodes**, 190
- Central canal**, 128
 of spinal cord, 120, 125

- Central nervous system**, 6
- Central sulcus (of Rolando)**, 116–117
- Central tendon, of diaphragm**, 200
- Central vein**, 285–286
- Cephalic vein**, BP99, 187, 194–195, 221, 259, 402, 405–407, 413, 416, 419, 425, 441, 458
- accessory, 405–406
- median, 406
- Cerebellar artery**
- inferior
- anterior, 147, 149–152, 154, 159, 176
- posterior, 147, 149–150, 152, 154, 176
- tonsillar branch of posterior, 154
- superior, 147, 149–152, 154, 176
- imaging of, BP32, 159
- Cerebellar hemispheric veins, inferior**, 155
- Cerebellar notch**
- anterior, 126
- posterior, 126
- Cerebellar nuclei**, 126
- dentate of, 126
- emboliform of, 126
- fastigial, 126
- globose of, 126
- Cerebellar peduncle**, 125
- inferior, 124–126, 135
- middle, 124–126
- imaging of, BP32, 160
- superior, 124–126
- decussation of, 126
- Cerebellar vein**
- precentral, 155
- superior, 155
- Cerebellomedullary cistern, posterior**, 120
- Cerebellum**, BP35, 110, 117, 122, 125–126, 157
- anterior lobe of, 126
- biventer lobule of, 126
- flocculonodular lobe of, 126
- flocculus of, 124, 126
- fourth ventricle of, 126
- horizontal fissure of, 126
- imaging of, BP32, 160
- medullary velum of
- inferior, 126
- superior, 126
- posterior lobe of, 126
- posterolateral fissure of, 126
- postlunate fissure of, 126
- primary fissure of, 126
- quadrangular lobule of, 126
- retrotonsillar fissure of, 126
- secondary fissure of, 126
- semilunar lobule of
- inferior, 126
- superior, 126
- simple lobule of, 126
- tonsil of, 126
- vermis of, 125
- central lobule of, 125
- culmen of, 125
- declive of, 125
- folium of, 125
- lingula of, 125
- nodulus of, 125
- pyramid of, 125
- tuber of, 125
- uvula of, 125
- Cerebral aqueduct**, T2.2, 50, 117–118, 120, 125, 128, 157–158
- imaging of, 160
- Cerebral arterial circle (of Willis)**, T2.3, 150–151
- Cerebral arteries**, 113
- anterior, 147–152, 154, 156
- cingular branches of, 153
- imaging of, 31–32, 159
- Cerebral arteries (Continued)**
- left, 153
- medial frontal branches of, 152–153
- terminal branches of, 153
- middle, 147–152, 154
- branches of, 148
- imaging of, 31–32, 159
- left, 153
- occipitotemporal branches of, 153
- temporal branches of, 152
- posterior, 147–152, 154
- calcarine branch of, 153–154
- imaging of, 31–32, 159
- parietooccipital branch of, 153–154
- right, 153
- temporal branches of, 154
- terminal branches of, 153
- Cerebral crus**, 118, 124, 126, 150
- Cerebral fissure, longitudinal**, 118, 154, 156
- imaging of, 160
- Cerebral hemisphere**, 113
- Cerebral peduncle**, 50, 117, 125
- Cerebral sulcus, lateral**, 152
- Cerebral veins**
- anterior, 155–157
- inferior, 113, 115
- internal, 117, 122, 155–157
- imaging of, BP31, 159
- left, 157
- right, 157
- middle
- deep, 111, 155–157
- superficial, 111, 113, 115, 156
- superficial, 113
- superior, 113
- opening of, 112
- Cerebrospinal fluid**
- circulation of, 120
- radiology of, 165
- within thecal sac, BP35
- Cerebrum**
- frontal lobe of, 116
- frontal pole of, 116, 118
- inferior (inferolateral) margin of, 118
- occipital lobe of, 116
- occipital pole of, 116, 118
- parietal lobe of, 116
- temporal lobe of, 116
- temporal pole of, 116, 118
- Cervical artery**
- ascending, BP23, 40, 82–83, 87–89, 149, 176, 418
- deep, BP23, 149, 176
- superficial, 183
- transverse, BP23, 39–40, 89, 418–419
- deep branch of, BP23
- superficial branch of, BP23, 183
- Cervical cardiac branch**, BP40
- Cervical cardiac nerves**, BP39, 213, 232
- inferior, 141, 231
- middle, 141, 230–231
- superior, 76, 83, 141, 230–231
- Cervical fascia**, 34, 194
- deep
- prevertebral layer of, 33
- superficial layer of, 31–33, 77, 413
- Cervical ganglion**
- middle, 39–40, 76, 139, 141, 230–231, 243
- superior, 62, 64, 76, 136, 139, 141–145, 172, 230–231, 243
- Cervical lordosis**, 162
- Cervical lymph nodes**, 7
- anterior deep, 85
- anterior superficial, 85
- deep lateral, 86
- inferior deep lateral, 85
- Cervical lymph nodes (Continued)**
- posterior lateral superficial, 85
- superior deep lateral, 85
- superior lateral superficial, 85
- Cervical muscles, deep**, 33
- Cervical nerve, transverse**, 9, 39–40, 140
- Cervical pleura**, BP44, T4.1, 87
- Cervical plexus**, T2.2, 169, 183
- branches from, 9
- schema of, 40, 140
- Cervical region**
- anterior, 2
- lateral, 2
- posterior, 3
- Cervical ribs, related anomalies and**, BP45
- Cervical spinal cord**, BP35
- Cervical spinal nerves**, 33
- C1, 82, 138, 169–170
- anterior rootlets of, 82, 124
- posterior rootlets of, 124
- vertebrae relation to, 182
- C2, 82, 138, 170
- anterior ramus of, 39
- dermatome of, 171
- vertebrae relation to, 182
- C3, 138, 170
- anterior ramus of, 39
- dermatome of, 171
- C4, 82, 138, 170
- dermatome of, 171
- vertebrae relation to, 184
- C5, 170
- anterior ramus of, 39
- dermatome of, 171
- vertebrae relation to, 184
- C6, 170
- dermatome of, 171
- vertebrae relation to, 184
- C7, 170
- C8, 169–170
- enlargement of, 170
- groove for, 27–28
- posterior rami of, 9
- Cervical spine, radiographs of**, BP34
- MRI, BP35
- open-mouth, BP35
- Cervical sympathetic ganglion**, BP41
- superior, 68
- Cervical sympathetic trunk**, BP39
- Cervical sympathetic trunk ganglion**, 232
- Cervical vein, deep**
- left, 179
- right, 179
- Cervical vertebrae**, T2.1, 162, 217
- anulus fibrosus of, 28
- arteries, 176
- body of, 27–28
- C3, 22, 26
- bifid spinous process of, 27
- costal lamella of, 27
- inferior articular facet for, 26–27
- inferior articular process of, 27–28
- inferior aspect of, 27
- lamina of, 27
- pedicle of, 27
- superior articular process of, 28
- transverse foramen of, 27
- transverse process of, 27
- tubercles of, 37
- vertebral body of, BP18, 27
- vertebral foramen of, 27
- C4, 26–27
- anterior view of, 27
- articular surface of, 27
- body of, 27

- Cervical vertebrae** (*Continued*)
 groove for spinal nerve, 27
 inferior articular facet of, 27
 inferior articular process of, 27
 lamina of, 27
 left uncinat process of, 27
 spinous process of, 27
 superior articular facet of, 27
 superior articular process of, 27
 superior aspect of, 27
 transverse foramen of, 27
 transverse process of, 27
 uncinat process of, 27
 vertebral body of, 27
- C6**
 anterior tubercle of, 29
 transverse process of, 147
- C7**, BP18, 22, 27, 169
 anterior view of, 27, 162
 articular surface of, 27
 body of, 27
 costal lamella of, 27
 inferior articular process of, 27
 lamina of, 27
 lateral view of, 162
 pedicle of, 27
 posterior view of, 162
 septated transverse foramen of, 27
 spinal nerve of, groove for, 27
 spinous process of, 27, 29, 161, 180, 413
 superior articular process and facet of, 27
 superior view of, 27
 transverse process of, 27
 posterior tubercle of, 37
 uncinat process of, 27
 articular surface of, 27
 vertebral body of, 27
 vertebral foramen of, 27
 degenerative changes in, BP18
 intervertebral disc of, 28
 nucleus pulposus of, 28
 transverse foramen of, 28
 transverse process of, 28
 uncinat processes of, 28
 uncovertebral joints of, 28
 upper, 26
- Cervicofacial division**, 54
- Cervicothoracic (stellate) ganglion**, BP39, 141, 213, 230–231, 243
- Cervix**, T6.1, 354, 397
 of uterus, 345–347, 353, 355–356
- Chest scans, axial CT images**, 244
- Chiasma**, BP91
- Chiasmatic cistern**, 120
- Choanae**, BP29, 17, 23, 43, 45, 56, 67, 75, 79
- Cholinergic synapses**, BP41
 schema of, BP41
- Chorda tympani**, BP27, 59–60, 82, 106–107, 133, 135, 142, 144–145
- Chordae tendineae**, 224–225, 227
- Choroid**, 100, 103
- Choroid plexus**, 122–123, 125
 of third ventricle, 117
- Choroid vein, superior**, 156–157
- Choroidal artery**
 anterior, 148, 150–152, 154
 posterior lateral, 150, 154
 posterior medial, 150
- Ciliary arteries**
 anterior, 103–104
 recurrent branch of, 104
 posterior, 99
 long, 103–104
 short, 103–104
- Ciliary body**, 100–103
 blood vessels of, 103
 orbiculus ciliaris of, 102
- Ciliary ganglion**, BP40, 61, 64, 97–98, 132–133, 142–143, 173
 branch to, 132–133, 143
 oculomotor root of, 143
 parasympathetic root of, 97, 132, 142
 schema of, 143
 sensory root of, 97, 142
 sympathetic root of, 97, 132, 142–143
- Ciliary muscle**, T2.4, 100, 132, 143
 circular fibers of, 101
 meridional fibers of, 101
- Ciliary nerves**
 long, 61, 97–98, 132–133, 142–143
 short, 61, 97–98, 132–133, 142–143
- Ciliary process**, 100–102
- Ciliary vein, anterior**, 101, 103–104
- Cingulate gyrus**, 117
 isthmus of, 117–118
- Cingulate sulcus**, 117
- Circular esophageal muscle**, 239
- Circular folds (valves of Kerckring)**, 279, 287
- Circular intramuscular plexus**, 308
- Circular muscle**, BP54, 375–376
- Circulation, prenatal and postnatal**, 233
- Circumflex fibular branch**, BP108, BP110, 503
- Cisterna chyli**, 7, 268, 300, 325
- Clastrum**, 121
- Clavicle**, BP34, BP57, T7.1, 4–5, 8, 31–32, 34–36, 38, 187–188, 191, 193–196, 202–204, 217, 221, 234–235, 245, 402, 408–416, 418–419, 470
 acromial end of, 408
 acromial facet of, 408
 conoid tubercle, 408
 sternal articular surface of, 408
 sternal end of, 408
- Clavicular head**. *See also* Pectoralis major muscle
 of sternocleidomastoid muscle, 8
- Clavipectoral fasciae**, 194, 416
- Clinoid process**
 anterior, 14–15, 18, 98
 posterior, 18
- Clitoral artery**, 361
 internal, 386
- Clitoris**, 360–361, 377
 body of, 345, 370
 crus of, 345, 352–353, 356, 360–361
 deep artery of, 361, 386
 deep nerve of, 361
 dorsal artery of, 386
 dorsal nerve of, 395–396, 487
 dorsal vein of, deep, 339–341, 345, 347, 350, 361
 frenulum of, 358
 glans of, 358, 370
 prepuce of, 356, 358
 suspensory ligament of, 359–361
- Clivus**, BP35, 18, 30
 imaging of, 160
- Clunial nerves**
 inferior, 183, 393, 395, 474, 492–493, 531
 medial, 474, 492
 middle, 183
 superior, 183, 474, 492
- CN I**. *See* Olfactory nerve (CN I)
- CN II**. *See* Optic nerve (CN II)
- CN III**. *See* Oculomotor nerve
- CN IV**. *See* Trochlear nerve (CN IV)
- CN V**. *See* Trigeminal nerve
- CN VI**. *See* Abducens nerve (CN VI)
- CN VII**. *See* Facial nerve
- CN VIII**. *See* Vestibulocochlear nerve (CN VIII)
- CN IX**. *See* Glossopharyngeal nerve
- CN X**. *See* Vagus nerve
- CN XI**. *See* Accessory nerve (CN XI)
- CN XII**. *See* Hypoglossal nerve (CN XII)
- Coccygeal cornu**, 166
- Coccygeal nerve**, 169–170, 489
- Coccygeal plexuses**, 487, 489
- Coccygeus muscle**, T6.1, T6.3, 265, 339–343, 384–385, 392–394
 nerve to, 487, 489
- Coccyx**, BP4, BP109, 166–167, 169–170, 250, 334, 337–340, 360, 373
 anterior view of, 162
 lateral view of, 162
 measurements of, 336
 posterior view of, 162
 tip of, 341, 343, 362, 364, 377, 400
 transverse process of, 166
- Cochlea**, BP28, 64, 108, 110
 course of sound in, 105
 duct of, BP28
 helicotrema of, BP28, 105, 108–109
 modiolus of, 109
 scala tympani of, BP28, 105
 scala vestibuli of, BP28, 105
 section through turn of, 109
- Cochlear aqueduct**, 109
- Cochlear cupula**, 108
- Cochlear duct**, 108–110
- Cochlear nerve**, BP28, 105, 108–110, 135
- Cochlear nucleus**, 135
 anterior, 127–128, 135
 posterior, 127–128, 135
- Cochlear recess**, 108
- Cochlear (round) window**, BP28, 21, 105, 108
 fossa of, BP27, 106
- Cochlear (spiral) ganglion**, 135
- Cockett's veins**. *See* Perforating veins
- Colic artery**
 ascending branch, 380
 descending branch, 380
 left, 266, 294–295, 300, 305, 316, 380
 middle, 288, 291, 294–295, 304, 324
 right, 294–295, 316
 variations in, 73–74
- Colic flexure**
 left, splenic, 270, 272–273, 276, 278, 283, 323
 right, hepatic, 270, 272–273, 276, 278, 283, 285, 318
- Colic impression**, 284
- Colic nodes, right**, BP82
- Colic vein**, 297
 left, 298–299
 middle, 298–299
 right, 298–299
- Collagen**
 in arterial wall, BP16
 fibers, in connective tissues and cartilage, BP6
 lamellae of anulus fibrosus, 168
- Collar of Helvetius**, 239
- Collateral artery**
 middle, BP100, 422, 424–425
 radial, BP100, 422, 424–425
- Collateral eminence**, 122
- Collateral ligament**, BP106, 448, 454
 accessory, 448
 of ankle, medial, 505
 fibular, 497–502, 505, 508–510, 512
 of foot, 519
 medial, T8.1
 radial, BP102, 428
 tibial, 497–500, 502, 505, 508–509, 511
 ulnar, BP102, 428
- Collateral sulcus**, 117–118
- Collateral trigone**, 122
- Collecting vessels**
 apical, 86
 basal, 86
 central, 86
 marginal, 86

Colles' fascia, BP88, BP90, 352–353, 359–365, 373, 377–378, 386–387, 393
superficial, 349

Colliculus
facial, 125
inferior, 117, 122, 124–125
brachium of, 122
left, 155
superior, T2.2, 117–118, 122, 124–125, 127, 143, 154
brachium of, 122
left, 155

Colon, T5.1
air within, 217
area for, 311
ascending, 137, 270, 272, 278, 311, 330, 344, 348
as site of referred visceral pain, BP13
circular muscle, 281
descending, BP85, 271, 278, 283, 311, 327, 330–331, 344, 348, 392
innervation to, 172
sigmoid, 344, 346, 348, 356, 373–376, 392, 394
innervation to, 172
as site of referred visceral pain, BP13
splenic flexure of, 282
transverse, 270–272, 274, 278, 283, 287–289, 295, 297, 330–331

Column system, posterior, BP43

Commissure, BP43
anterior, 117, 125, 130, 157–158
of lips, 8
posterior, 117, 122, 125, 370
of semilunar valve cusps, 227

Common bony limb, 109

Common iliac arteries, BP38

Common iliac nodes, 268, 319

Common membranous limb, 108–109

Common tendinous ring (of Zinn), BP26, 96–97, 132

Communicating artery
anterior, 147–153
imaging of, 31–32, 159
posterior, 115, 147–154
imaging of, 31–32, 159

Communicating vein, BP42, 38, 179

Compressor urethrae muscle, T6.3, 339, 351, 360–361, 386

Concha, inferior, 23

Condylar canal, 17, 20

Condylar fossa, 17

Condylar process
head of, BP24
of mandible, 24
head of, 13

Condyles
of femur
lateral, 479, 498–501
medial, 479, 499–501
of fibula
lateral, 505
medial, 505
of knee
lateral, BP112
medial, BP112
mandibular, 14
occipital, 15, 17–18, 23, 37
of tibia
lateral, 484, 504, 510
medial, 498

Cone of light, 106

Cones, 131

Confluence of sinuses, 110, 114–115, 155–156
imaging of, 159

Conjoined longitudinal muscle, 343, 376

Conjoint tendon, 262–263

Conjunctiva, 104

Conjunctival fornix
inferior, 94
superior, 94

Connective tissues, BP6
dense, BP6
layer of, in hair follicle, BP1
of skull, 113

Conoid ligament, 408, 412, 415

Conoid tubercle, 408

Conus arteriosus, BP51, 216, 224–226

Conus elasticus, 91–92

Conus medullaris, T3.1, 169–170
radiology of, 165

Cooper's ligament, 188. *See also* Pectineal ligament (Cooper's)

Coracoacromial ligament, 412, 415, 417, 421

Coracobrachialis muscle, T7.3, 246–247, 409, 414, 417, 419, 421, 423, 425, 463, 465

Coracobrachialis tendon, 414, 417

Coracoclavicular ligament, 408, 412, 415

Coracohumeral ligament, 412

Coracoid process, 194–195, 409–412, 414–419, 421, 423, 470
of scapula, 192

Cornea, BP26, 94, 100–101, 103–104

Corneoscleral junction, 94

Corniculate cartilage, 90

Corniculate tubercle, 75, 79, 91

Corona radiata, BP95

Coronal plane, 1

Coronal sulcus, 370

Coronal suture, BP17, 11–16, 21

Coronary arteries, 41–42, 222
imaging of, 223
left, 222–223
anterior interventricular branch of, BP52, 216, 222
anterior interventricular sulcus of, BP51, 216
circumflex branch of, BP52, 222–223, 226
interventricular septal branches of, BP52, 223
left (obtuse) marginal branch of, BP52, 223
opening of, 227
posterior left ventricular branch of, 222
posterolateral branches of, 227
opening of, 228
right, BP51, 216, 218, 222–223, 226
anterior oblique views with arteriograms, BP52
atrial branch of, 222
AV nodal branch of, BP52, 223, 226
interventricular septal branches of, 218, 222–223
opening of, 227
posterior interventricular branch of (posterior descending artery), 223, 226
right (acute) marginal branch of, BP52, 223
SA nodal branch of, BP52, 223
variations of, BP53

Coronary ligament
hepatorenal portion of, 284
of liver, 275, 284, 324

Coronary sinus, BP56, 218–220, 222, 225, 248
opening of, 221, 224, 227
valve (thebesian) of, 224

Coronary sulcus, BP51, 216, 218

Coronoid fossa, 409, 426

Coronoid process, 60, 429, 433
of mandible, 13–14, 24

Corpora cavernosa, of penis, 364

Corpus albicans, BP95, 355

Corpus callosum, 117, 122, 152, 154
body of, imaging of, BP32, 160
dorsal vein of, 155, 157
genu of, 117–118, 121, 123, 157
imaging of, 160

Corpus callosum (Continued)
right dorsal branch to, 154
rostrum of, 117, 152, 156
imaging of, 160
splenium of, 117–118, 121, 123, 125, 154–157
imaging of, 160
sulcus of, 117
trunk of, 117, 152

Corpus cavernosum, 349, 363, 365, 367

Corpus hemorrhagicum, BP95

Corpus luteum, BP95, BP92, 355

Corpus spongiosum, BP93, 349, 352, 363–364, 367

Corpus striatum, 152

Corrugator cutis ani muscle, 375–376

Corrugator supercilii muscle, T2.4, BP20, 31, 42, 134

Cortex, BP95
of kidney, 314

Cortical bone, BP7

Cortical lymph vessels, 319

Corticospinal tract, anterior, BP43

Costal cartilages, 191, 193, 202, 250, 328, 408
fifth, 200
left, 220
second, 247
seventh, BP44, 204
sixth, BP44, 413

Costal facet, 163
inferior, 163, 193
superior, 163, 193
transverse, 163, 193

Costal groove, 193

Costal impressions, 284

Costal pleura, 235–236

Costocervical trunk, BP23, 40, 147, 149, 179

Costochondral joints, 193

Costoclavicular ligament, 193, 408, 416

Costocoracoid ligament, 416

Costocoracoid membrane, 416

Costodiaphragmatic recess, BP56, 204, 221

Costomediastinal space, 204

Costotransverse joint, 245

Costotransverse ligament, BP33, 193
lateral, BP33, 193
superior, 193

Costoxiphoid ligament, 193

Cough receptors, 214

Cowper's gland, BP93, 349, 352, 365–367, 371.
See also Bulbourethral (Cowper's) gland primordium, 371

Coxal bone, BP4, 476

Cranial, as term of relationship, 1

Cranial base
foramina and canals of
inferior view of, 19
superior view of, 20
inferior view of, 17
nerves of, 64
superior view of, 18
vessels of, 64

Cranial cavity, BP3

Cranial fossa
anterior, 18
middle, 18
floor of, BP24
posterior, 18
arteries of, 154
veins of, 155

Cranial imaging, BP31, 159–160

Cranial nerves
motor and sensory distribution of, 129
nuclei of, in brainstem, 127–128

Cranial root, 137

Craniocervical ligaments
external, 29
internal, 30

Cranium, BP4
Creaster fascia, 369, 372
Creaster muscle, BP59, T6.3, 254, 260, 263, 369
 lateral origin, BP58, 253
 medial origin, BP58, 253, 262
Creaster artery, 258, 264
Creaster fascia, BP59, 263
Creaster vessels, 263, 383
Cribriform fascia, within saphenous opening, 475
Cribriform hymen, BP96
Cribriform plate, 15, 18, 46
 foramina of, 20
Cricoaeroid muscle
 lateral, T2.5, 91–92
 action of, 93
 posterior, T2.7, 75, 80, 91–92
 action of, 93
Cricoesophageal tendon, 80
Cricoid cartilage, 21–22, 32, 35, 77–78, 81, 87, 90–92, 202, 208, 210, 237–238
 arch of, 90
 arytenoid articular surface of, 90
 lamina of, 80, 90–91
 posterolateral surface of, 238
 prominence over lamina of, 79
Cricopharyngeal muscle, 34, 75, 78, 81, 88–89, 92
Cricothyroid artery, 83, 87
Cricothyroid joint, 90, 93
Cricothyroid ligament, 87
 lateral, 90
 median, 35, 78, 81, 87, 90, 208
Cricothyroid muscle, T2.4, 35, 81, 87, 91–92, 137
 action of, 93
 oblique part of, 91
 straight part of, 91
Crista galli, 15, 18
 imaging of, 160
Crista terminalis, 224, 229
Crossing over, BP91
Cruciate ligaments, 30, 498, 505
 anterior, T8.1, 499–500
 covered by synovium, BP114
 posterior, 499–500
Crura, of respiratory diaphragm, 185
Crural artery
 anterior, 107
 posterior, 107
Crural fascia, 473, 475, 513–514
Crus of diaphragm, BP38
Crypt, 71
Crypts of Lieberkühn, BP62
Cubital fossa, 402
Cubital region, 2
Cubital vein, median, T7.2, BP99, 405, 407
Cuboid bones, 515–516, 518, 527–528, 535
 articular surface for, 517
 tuberosity of, 519, 527
Cuboidal cells, BP95
Cuboideonavicular ligament
 dorsal, 518
 plantar, 519
Cumulus oöphorus, BP95
Cuneate fasciculus, BP43
Cuneate tubercle, 124–125
Cuneiform bones, 515–516, 527–528
 medial, BP117, 518, 527
Cuneiform tubercle, 75, 79, 91
Cuneocuboid ligament, dorsal, 518
Cuneonavicular ligaments
 dorsal, 518
 plantar, 519
Cuneus, 117
 apex of, 118

Cutaneous nerves, BP1
 brachial
 medial, 259
 superior lateral, 183
 dorsal
 intermediate, BP115, 533
 lateral, BP115, 473–474, 521, 531–533
 medial, BP115, 533
 femoral
 anterior, 529
 lateral, 264, 269, 311, 391, 473–475, 486–488, 490–491, 496, 529–530
 posterior, 169, 183, 395, 474, 487, 489, 492–493, 496, 531
 of head, 9
 of neck, 9, 38
 perforating, 393, 395, 474, 487, 489, 493
 sural
 lateral, 473–474, 492, 507–508, 514, 531–533
 medial, BP111, 474, 492, 507–508, 514, 531–532
Cutaneous vein, femoral, anterior, BP107
Cuticle, BP1
Cystic arteries, T5.2, 287, 290–291
 variations in, BP69
Cystic duct, 284, 287–288, 290–291
 variations in, BP68
Cystohepatic trigone (of Calot), 287, 291
Cystourethrograms, BP89

D

Dartos fascia
 of penis, 349, 362–364, 369
 of scrotum, BP88, 349, 362, 369, 372, 377, 387
Deep artery
 of clitoris, 386
 of penis, 363, 365, 387
Deep (Buck's) fascia
 of penis, 252–254, 324, 349
 of thigh, 362–363
Deep cervical artery, 176
Deep cervical lymph nodes, inferior, 212, 242
Deep cervical lymphatic chain, T2.3
Deep cervical vein, BP42
Deep fascia, of hand, 457
Deep vein of thigh, BP107
Deeper membranous layer, 359
Deltoid ligament. *See also* Collateral ligament
 tibioacalcanal part of, BP116
Deltoid muscle, T7.3, 32, 36, 161, 180, 183, 187, 221, 245–247, 402, 408–410, 413–414, 416–417, 419, 421–423, 425, 463, 468, 470
Deltoid region, 3
 anterior, 2
Deltoid tuberosity, 409–410
Deltopectoral groove, 402
Deltopectoral triangle, 413
Dendrite, BP11
Denonvilliers' fascia, 343, 349, 366, 373, 378.
See also Rectoprostatic (Denonvilliers') fascia
Dens, BP5, BP42, 30
 abnormalities of, BP19
 apical ligament of, BP19, 30, 77–78
 of atlas, 26
 of axis, 12, 14, 26, 28
 posterior articular facet of, 30
Dental plexus, inferior, 133
Dental pulp, 74
Dentate gyrus, 117, 119, 122–123, 130
Dentate line, 375. *See also* Pectinate (dentate) line
Dentate nucleus, 125
Denticulate ligament, 174, 177

Dentine, of teeth, 74
Depressor anguli oris muscle, T2.4, 20–21, 31, 55, 134
Depressor labii inferioris muscle, T2.4, 20–21, 31, 55, 134
Depressor septi nasi muscle, T2.4, BP20, 31, 42, 134
Dermal papilla, 1–2
Dermatomes, 171
 levels of, 171
 schematic demarcation of, 171, 472
 of upper limb, 403
Dermis, BP1
Descemet's membrane, 101
Descending aorta. *See* Thoracic aorta
Descending colon, 173, 344, 348, 392
Descending fibers, 321, 399
Desmosome, BP16
Detrusor muscle, of bladder wall, BP90
Diagonal conjugate, 336
Diaphragm, BP57, 392. *See also* Respiratory diaphragm
 central tendon of, 235
 silhouette, BP36
Diaphragmatic constriction, 237
Diaphragmatic ligament, 368, 371. *See also* Suspensory (diaphragmatic) ligament
Diaphragmatic recess, right, 217
Digastric fossa, 24
Digastric muscle, T2.4, 75
 anterior belly of, BP22, 34–36, 38, 41, 50, 53, 59, 69, 81
 intermediate tendon of, 70
 mastoid notch for, 17
 phantom, 41
 posterior belly of, 32, 35–36, 41, 53, 57, 59, 68–70, 75, 81, 86, 134
Digastric tendon, intermediate, 68
 fibrous loop for, 32, 35, 69–70
Digestive system, T6.1, T5.1
Digestive tract, BP10
Digital arteries
 dorsal, BP110, BP115, 459–461, 503, 512, 521, 527
 palmar, BP101, 424, 449
 common, BP101, 424, 450, 453, 455–456
 proper, BP101, 450, 456, 459–461
 proper, 424
 plantar, branches of, 512
Digital fibrous sheaths, 448
Digital nerve
 dorsal, 406, 458, 460–461, 473, 511
 of foot, 533
 lateral, 473
 palmar, 406, 449–450
 common, 456, 466–467
 proper, 450, 456, 458–460, 466–467
 proper plantar, branches of, 512
Digital vein
 dorsal, 406, 473
 palmar, BP99, 406
 dorsal, 458
Digits
 extensors of, 431
 flexors of, 433
Dilator pupillae muscle, T2.1, T2.4, 101, 132, 143
Diploë, 16
Diploic vein, 111, 113
 anterior temporal, 111
 frontal, 111
 occipital, 111
 posterior temporal, 111
Direct vein, lateral, 156–157
Distal, as term of relationship, 1
Distal interphalangeal (DIP) joint, BP102, 402, 447–448

Dorsal arteries
of clitoris, 386
of penis, 363, 365, 383
deep, BP98

Dorsal interossei muscle, T8.3

Dorsal nerves
of clitoris, 395
of penis, 363, 365, 387, 391–393, 395, 398

Dorsal plane, 1

Dorsal rami, spinal, 174

Dorsal root, BP38

Dorsal veins
deep
of clitoris, 339–341, 345, 347, 350, 361
of penis, BP98, 342–343, 349, 365, 383, 385, 387
superficial, of penis, BP98, 333, 363, 385

Dorsal venous arch, BP107

Dorsal venous network, 406

Dorsalis pedis artery, BP117, 4, 512, 527
foot, proximal, T8.2
pulses at, 4

Dorsiflexion, of lower limbs movements, 472

Dorsolateral fasciculus, BP43

Dorsum, 443
of foot, 3, 522
of hand, 3

Duct of gland, 71

Duct systems, of liver, 285

Ductuli efferentes testis, BP93

Ductus arteriosus, 233

Ductus (vas) deferens, BP93, T6.2, BP98, BP59, BP109, 256, 262, 264, 266, 348–349, 352, 366, 368–369, 371–373, 385, 391–392, 398, 475
ampulla of, BP93, 366
arteries of, BP98, 266, 369, 380, 383, 385
covered by peritoneum, 263

Ductus reuniens, 109

Ductus venosus, 233

Duodenal bulb, 277, 279

Duodenal flexure
inferior, 279
superior, 279

Duodenal fossa
inferior, 271
superior, 271

Duodenal impression, 284

Duodenal papilla
major, 287
minor, 279, 287

Duodenal wall, layers of, BP61

Duodenojejunal flexure, 271, 278–279, 288, 318, 323

Duodenojejunal fold, 271

Duodenojejunal junction, 185

Duodenomesocolic fold, 271, 278

Duodenum, BP62, T5.1, 137, 271, 274–276, 284–285, 311, 316, 318, 323, 326–327
arteries of, 291, 293
ascending part of, 271, 278
autonomic innervation of, 301–303
descending part of, 185, 271, 273, 278–279
inferior part of, 271, 278
longitudinal muscle of, 278, 287
as site of referred visceral pain, BP13
in situ, 278
superior part of, 278, 287, 329
suspensory muscle of, 271
veins of, 296

Dura mater, BP35, BP42, 45, 106, 109, 111–112, 120, 130, 177, 179
endostial layer of, 113
meningeal layer of, 113
radiology of, 165
spinal, 169, 185

Dura-skull interface, 111, 113

Dural sac, termination of, 165

Dural venous sinuses, T2.3
sagittal section of, 114
superior view of, 115

E

Ear
ampulla of, 108–109
bony and membranous labyrinths of, 108–109
course of sound in cochlea and, 105
external, 106
pediatric, anatomy of, BP28
vestibule of, 108–109

Ear ossicles, T2.1

Edinger-Westphal nucleus. *See* Accessory oculomotor nucleus

Efferent ductules, 371–372

Ejaculatory ducts, BP97, 366–367, 371
in prostatic urethra, 400

Elastic fibers, BP1, BP6

Elastic membrane, of arterial wall
external, BP16
internal, BP16

Elbow
anterior region of, 2
bones of, 426–441
ligaments of, 428
posterior region of, 3
radiographs of, 427

Elliptical recess, 108

Emissary vein, 20, 111, 113
condylar, 179
mastoid, 10, 111, 179
in mastoid foramen, 19
occipital, 111
parietal, 10, 111

Enamel, of teeth, 74

Endocrine system, T4.1, T5.1, BP10

Endolymphatic duct, 20, 108

Endolymphatic sac, 109

Endometrium, of uterus, 379

Endomysium, BP8

Endoneurium, BP12

Endopelvic fascia, T6.1, 347
deep perineal pouch with, BP88
paravesical, 352

Endosteal surface, BP7

Endothelial cell, BP6

Endothelium, of arterial wall, BP16

Eosinophils, BP15, BP6

Epicolic nodes, BP82

Epicondyles
of femur
lateral, 479, 483, 498
medial, 479, 492, 497–498
of knee, medial, BP112

Epicranial aponeurosis, BP20, 10, 31, 113, 184

Epicranium muscle
frontal belly (frontalis) of, 20–21
occipital belly (occipitalis) of, T2.6

Epidermis, 1–2

Epididymal duct, 372

Epididymis, BP93, 368–369, 371–372, 398
appendix of, 369, 371
body, 372
head, 372
sinus of, 369
tail, 372

Epidural fat, BP42
radiology of, 165

Epidural space, fat in, 177

Epidural venous plexus. *See* Internal vertebral venous plexus, anterior

Epidural vertebral venous plexus. *See* Internal vertebral venous plexus, anterior

Epigastric artery
inferior, BP59, BP108, 266–268, 317, 347, 380, 382, 503
cremasteric branches of, 256, 266
pubic branches of, 256, 266, 348
superficial, BP108, 254, 258, 266, 503
superior, 194–197, 215, 258–259

Epigastric node, inferior, 268

Epigastric region, 251

Epigastric veins
inferior, 259, 267, 382
superficial, BP107, 259, 267, 333, 473
superior, 196, 198

Epigastric vessels
inferior, BP98, 254, 256, 262, 264, 344, 348, 356, 383, 385
pubic branches of, 262
superficial, BP58, 252, 254
superficial circumflex, 490

Epiglottis, BP44, 22, 71–72, 75, 77, 79–80, 89–92, 146, 237

Epimysium, BP8

Epineurium
inner, BP12
outer, BP12

Epiphyseal plate, 495

Epiphysis, 460–461
nutrient branch to, 460–461

Epiplonic appendices. *See* Omental (epiploic) appendices

Episcleral artery, 103

Episcleral space, BP26, 100

Episcleral vein, 103–104
segment of, 104

Epithelial cord, BP95

Epithelial tag, 370

Epithelium
gingival, 74
superficial, germinal, BP95

Epitympic recess, 27–28, 105–106

Eponychium, 460–461

Epoöphoron, 371

Erector spinae muscle, T3.2, BP85, 161, 180, 182, 186, 197, 245, 261, 312

Esophageal artery, 211

Esophageal hiatus, 201

Esophageal impression, 284

Esophageal mucosa, 80, 239

Esophageal muscle, 77, 208
circular, 75, 78, 80, 239
longitudinal, 75, 78, 80, 88, 239
cricoid attachment of, 75, 78

Esophageal plexus, 39–40, 137, 210, 213, 220, 234–236, 243, 303
sympathetic branch to, 213

Esophageal prominence, 219

Esophageal submucosa, 80

Esophageal veins, T5.2, 241, 299

Esophagogastric junction, 221, 239, 328–332
cross-sectional anatomy, 328–332

Esophagus, BP56, BP44, BP9, 33–34, 76–77, 79, 81, 89, 91, 137, 200, 210–211, 220–221, 234–235, 237, 241, 243–248, 265, 267–268, 271, 305, 311, 324
abdominal part of, 236–237, 240, 276
air within, BP36
arteries of, 240
variations in, BP55
autonomic innervation of, 303
cervical part of, 236, 240
longitudinal muscle of, 277
lung area for
left, 205
right, 205
lung groove for
left, 205
right, 205

Esophagus (*Continued*)

lymph vessels and nodes of, 242
musculature of, 238
nerves of, 243
variations in, intrinsic and, BP54
recurrent branch of, 201, 266
in situ, 236
thoracic part of, 236, 240
topography and constrictions of, 237
veins of, 241
ventral surface of, bare are on, 238

Estrogen, BP92**Ethmoid bone**, 11, 13, 15, 18, 44–45

anterior ethmoidal foramen of, 21
cribriform plate of, 15, 18, 43–45, 130
crista galli of, 15, 18, 45
nasal concha of
highest, 44
middle, 11, 15, 44
superior, 15, 44
of newborn, 21
orbital plate of, 11, 13, 21
perpendicular plate of, 11, 15, 45
uncinate process of, 44, 52

Ethmoid sinus, imaging of, 160**Ethmoidal artery**

anterior, 20, 99
anterior meningeal branch of, 112
posterior, 20, 99, 112
lateral nasal branch of, 47
septal nasal branch of, 47

Ethmoidal bulla, 43–44**Ethmoidal cells**, BP26, BP22, 50–51

anterior, 98
middle, opening of, 43–44
posterior, openings of, 44

Ethmoidal foramen

anterior, 20
posterior, 20

Ethmoidal nerve

anterior, 20, 61, 97–98, 132–133
external nasal branch of, 9, 46, 48, 61
lateral internal nasal branch of, 46
medial internal nasal branch of, 46, 98
posterior, 20, 61, 97–98, 132–133

Ethmoidal sinus, 12**Ethmoidal vein**

anterior, 20
posterior, 20

Eustachian tube. See Auditory tube**Eversion, of lower limbs movements**, 472**Extension, of lower limbs movements**, 472

Extensor carpi radialis brevis muscle, T7.3,
402, 422, 431, 434–435, 439–441,
468–469

Extensor carpi radialis brevis tendon,
434–435, 441, 457, 459–460

Extensor carpi radialis longus muscle, T7.3,
402, 409, 422, 425, 431, 434–435, 439–441,
468–469

Extensor carpi radialis longus tendon,
434–435, 441, 457, 459–460

Extensor carpi ulnaris muscle, T7.3, 402, 422,
431, 434, 439–441, 468–469

Extensor carpi ulnaris tendon, 434–435, 441,
459–460

Extensor digiti minimi muscle, T7.4, 431, 434,
439–441, 469

Extensor digiti minimi tendon, 434–435, 441,
459–460

Extensor digitorum brevis muscle, T8.3, 510,
512, 520, 527, 533

Extensor digitorum brevis tendon, 511–512,
522

Extensor digitorum longus muscle, BP116,
BP111, T8.3, 484, 498, 506, 510–512, 514,
520, 533

Extensor digitorum longus tendon, 116–117,
471, 510–512, 521, 527

tendinous sheath of, 521

Extensor digitorum muscle, T7.4, 422, 431,
434, 439–441, 468–469

Extensor digitorum tendon, 105–106, 402,
434–435, 441, 459–460

Extensor expansion, 105–106, 454, 460

system, 521, 527

Extensor hallucis brevis muscle, BP117, T8.3,
512, 521, 533

Extensor hallucis brevis tendon, BP117,
511–512, 522, 527

Extensor hallucis longus muscle, BP116,
BP111, T8.3, 506, 510–512, 514, 522,
533

Extensor hallucis longus tendon, 116–117,
471, 510–512, 521, 527

tendinous sheath of, 520

Extensor indicis muscle, T7.4, 431, 435,
440–441, 469

Extensor indicis tendon, 105–106, 402, 431,
434, 441, 459–460

Extensor pollicis brevis muscle, T7.4, 431,
434–435, 440, 469

Extensor pollicis brevis tendon, 434, 438, 441,
457, 459–460

Extensor pollicis longus muscle, T7.4, 431,
435, 440–441, 469

Extensor pollicis longus tendon, 402, 434,
441, 453, 457, 459–460

Extensor retinaculum, 406, 434–435,
457–460

inferior, 510–511, 520, 533
superior, BP116, 510–511, 520

Extensor tendon, 453–454

common, 409–410, 431, 434–435, 439
long, 454

External abdominal oblique muscle, 484

External capsule, 121

imaging of, 160

External genitalia, 358, 362–363

homologues of, 370

nerves of
female, 395
male, 391

External iliac vein, BP107

External oblique muscle, 344, 348

External occipital protuberance, 13–15, 17, 23,
161

External os, 355

of uterus, 357

External pudendal vein, BP107

External vertebral venous plexus, anterior,
BP42

Extrahepatic bile ducts, 287

Extraperitoneal fascia, BP59, 254, 263–264,
394

Extraperitoneal space, 374

Extreme capsule, 121

Extrinsic muscle, of eye, 96

innervation of, 96

Eye, 173

anterior chamber of, 94, 100, 102–103

extrinsic muscles of, 96, 103

innervation of, 96

innervation to, 172

intrinsic arteries and veins of, 103

muscles of, T2.1

posterior chamber of, 94, 100, 102–103

vascular supply of, 104

Eyeball, BP22, 50

fasciae of, BP26

imaging of, 160

posterior chamber of, 101

transverse section of, 100

Eyelashes, 94

Eyelids, 94

arteries and veins of, 99
tarsus of, BP26

F**Face**, BP4

arterial supply sources of, 10
deep

arteries of, 63

nerves of, 63

musculature of, BP21

superficial arteries and veins of, 10

Facial artery, 10, 38, 41–42, 49, 53, 57–58, 68,
76, 83–84, 88, 99, 142, 144, 147, 149

pulses at, 4

tonsillar branch of, 72

transverse, 10, 41–42, 53, 58, 83, 99

Facial canal, 135

prominence of, BP27, 106

Facial colliculus, 125

Facial expression, muscles of, T2.1, 31, 68

anterior view of, BP20

Facial muscles, 134

Facial nerve (CN VII), T2.2, BP40, 20, 27–28,

41, 49, 57, 59–60, 62, 64, 66, 68, 76, 82,
105, 107, 110, 115, 124, 128, 133–134, 142,
145–146

branches of, 53–54, 173

buccal, BP21, 54

cervical, BP21, 54

digastric, 54

lateral nasal, 47

marginal mandibular, BP21, 38, 54

stylohyoid, 54

temporal, BP21, 54

zygomatic, BP21, 54

communication to, 136

distribution of, 129

geniculate ganglion of, BP27, 127, 142

imaging of, BP32

internal genu of, 128

motor nucleus of, 134

motor root of, 135

proper, 54

schema of, 134

stylomastoid foramen and, 19

Facial nerve (CN VII) intermediate nerve, 144

chorda tympani of, 19

Facial nodes, 85

Facial nucleus, 127–128

Facial vein, 10, 38–39, 49, 53, 68, 70, 84, 99

common, 10, 39

deep, 10, 84, 99

transverse, 10, 84

Falciform ligament, 255–256, 270, 276, 284,
299, 327

Fallopian tube, 344–346, 353–356, 371,
382, 394, 397. See also Uterine (fallopian)

tube

left, 356

right, 356

False ribs, 192

Falx cerebri, BP22, 45, 50, 113–115, 155

Fascia

of hand, 453

of orbit and eyeball, BP26

Fascia lata, 252–253, 389, 473, 475, 490, 496

Scarpa's layer of, 252

of thigh, 353, 359, 362–363

Fascial sheath, lumbrical, 450

Fascicle, BP12

Fasciculi proprii, BP43

Fasciculus

cuneate, 125

gracile, 125

lateral, 125

Fasciculus (*Continued*)

- longitudinal
 - dorsal, 158
 - medial, BP43, 125–126
- mammillothalamic, 117
- septomarginal, BP43

Fat, BP10**Fat body, suprapatellar**, 502**Fat cells**, BP6**Fat pads**, 235, 428**Fat tissue**, 188, 401**Fatty (Camper's) fascia**, BP88**Fauces**, 72**Female, anterior view of**, 2**Femoral artery**, BP110, BP108, 4, 258, 266,

- 362, 400–401, 475, 483, 490, 495–496, 503
- ascending branch of, BP108
- deep, 4, 401. *See also* Profunda femoris artery in femoral triangle, T8.2
- lateral circumflex, BP108, 490–491, 495, 503
- medial circumflex, BP108, 491–492, 495, 503
- muscular branches of, BP108, 503
- perforating branches, 503
- pulses at, 4
- transverse branch of, BP108

Femoral canal, 475

- lymph nodes (Cloquet's), 264

Femoral cutaneous nerve

- lateral, 260, 391
- posterior, 169
 - perineal branch of, 395
 - posterior, 393

Femoral nerve, BP86, BP109, 169, 256, 262, 264, 269, 389, 391, 400–401, 475, 486–488, 490–491, 529–530

- anterior cutaneous branches of, 473
- anterior femoral cutaneous branches of, 391
- branches of, 496
- terminal branch of. *See* Saphenous nerve

Femoral region, BP58

- anterior, 2
- posterior, 3

Femoral ring, T5.1, 262, 264, 344, 347–348, 475**Femoral sheath**, 254, 256, 264, 490

- femoral vein in, 253, 264

Femoral vein, BP86, BP107, BP58, 259, 263, 267, 362, 400, 473, 475, 483, 490, 496

- circumflex
 - lateral, BP107
 - medial, BP107
- deep, 5
- in femoral sheath, 253, 264
- greater, 401
- opening of, 265

Femoral vessels, 383, 389**Femur**, BP113, BP4, 479, 496, 498, 501–502, 534

- adductor tubercle of, 479
- articular surface of, BP114
- body of, 479
- calcar of, 479
- condyle of
 - lateral, 479, 498–501
 - medial, 479, 499–501
- epicondyles of
 - lateral, 479, 483, 498
 - medial, 479, 492, 497–498
- gluteal tuberosity of, 479
- head of, BP109, 400, 477–479, 534
 - arteries of, 495
 - fovea for ligament of, 479
 - ligament of, BP109, 477
 - radiograph of, 335
- intercondylar fossa of, 479
- intertrochanteric crest of, 479
- intertrochanteric line of, 479

Femur (*Continued*)

- lateral supracondylar line of, 479
- linea aspera of, 479
- medial condyle of, 479
- medial epicondyle of, 479
- medial supracondylar line of, 479
- midshaft of, T8.1
- neck of, T8.1, 400–401, 477–479, 534
 - arteries of, 495
- nutrient artery of, 495
- nutrient foramen of, 479
- pectineal line of, 479
- popliteal surface of, 479
- quadratus tubercle of, 479
- radiograph of, 335
- retinacular foramina of, 479
- trochanter of
 - greater, BP109, 161, 334, 401, 471, 477–479, 483, 485–486, 492–493, 534
 - lesser, 265, 334, 477–479, 534
 - radiograph of, 335
- trochanteric fossa of, 479

Fibrin, BP95**Fibroblast**, BP6

- in arterial wall, BP16
- nuclei, BP6

Fibrocartilaginous labrum. *See* Acetabular labrum**Fibroelastic membranes, of esophagus**, 238**Fibrofatty tissue**, 374**Fibromuscular extension**, BP90**Fibromuscular stroma**, 366**Fibrous appendix, of liver**, 284**Fibrous capsule**, BP114, BP5, 289**Fibrous pericardium**, 204, 219, 235**Fibrous septum**, 376

- transverse, 375
- of ischioanal fossa, 374, 376–377

Fibrous sheaths, 525–526**Fibrous trabecula**, 158**Fibrous trigone**

- left, 226
- right, 226

Fibula, T8.1, BP113, BP116, BP111, BP4, 501, 504–505, 510–511, 514, 517–518, 521–522, 535

- anterior border of, 504–505
- apex of, 504
- calcaneal branches of, 507
- common, 497
- condyle of
 - lateral, 505
 - medial, 505
- fibular notch of, 504
- head of, 482–484, 498, 500, 502, 504–505, 508–512, 533
- ligament of, 505
 - posterior ligament of, 502
- inferior articular of, 504
- interosseous border of, 504–505
- lateral malleolus of, 504, 520–522
- medial crest of, 504
- medial surface of, 504
- neck of, BP112, 504
- nutrient foramen for, 504
- oblique line of, 504
- soleal line of, 504
- surface of, lateral, 504–505

Fibular artery, BP108, 4, 110–111, 503,

- 507–509, 513–514
- calcaneal branches of, 508
- communicating branch of, 509
- lateral calcaneal branch of, 509
- lateral tarsal branch of, BP110
- perforating branch of, BP110, 503, 509, 512, 521–522
 - posterior, BP110
 - posterior lateral malleolar branch of, 509

Fibular collateral ligament, 483–484**Fibular nerve**

- common, BP111, T8.2, 485, 487, 489, 492, 497–498, 501, 507–512, 531–533
 - sural communicating branch of, 474
- deep, BP111, 115–116, 512, 514, 521–522, 533
 - dorsal digital branch of, 511–512, 521–522
 - lateral branch of, 521–522, 533
 - medial branch of, BP117, 511–512, 521–522, 533
 - recurrent branch of, 512
 - superficial, BP115, 473, 510–512, 521–522, 531, 533
 - dorsal digital branches of, 521–522
 - intermediate dorsal cutaneous branch, 473
 - medial dorsal cutaneous branch, 473

Fibular retinaculum, 518

- inferior, 509–510, 518, 520
- fibular tendon in, 517
- superior, 507–510, 518, 520

Fibular vein, BP107, 513–514**Fibularis brevis muscle**, BP111, T8.4, 506,

- 510–512, 514, 520, 522, 533

Fibularis brevis tendon, 507–510, 512, 522,

- 526–527

Fibularis longus muscle, BP111, T8.4, 471,

- 484, 497–498, 506, 508, 510–512, 514, 520, 533

Fibularis longus tendon, 507–510, 512, 522,

- 526–527

Fibularis longus tendon, 507–510, 512, 522,

- common tendinous sheath of, 520

Fibularis longus muscle, BP111, T8.4, 471,

- 484, 497–498, 506, 508, 510–512, 514, 520, 533

Fibularis longus tendon, 507–510, 512, 522,

- common tendinous sheath of, 520

Fibularis longus tendon, 507–510, 512, 522,

- passing to plantar region of foot, 510

Fibularis tertius muscle, BP111, T8.4, 506,

- 514

Fibularis tertius tendon, 510–511, 520, 522,

- 527

Filiform papillae, 71**Filum terminale externum**, 169–170**Filum terminale internum**, 169–170, 177**Fimbriae**, 355

- of uterine tube, 357

Fimbriated fold, 65**Finger**, 461

- extensor tendons in, 454
- fibrous tendon sheath of, 453, 460–461
- flexor tendon of, 454, 460
- flexor tendon sheath of, 450, 461
- index, 447
- little, 447
- middle, 447
- ring, 447
- tendon sheath of, 450–451, 453

Fixed retrocecal appendix, 282**Flexion, of lower limbs movements**, 472**Flexor carpi radialis muscle**, T7.4, 421, 423,

- 432, 436, 438–439, 441, 463, 466

Flexor carpi radialis tendon, 402, 437–438,

- 441, 444, 450, 452–453, 463

Flexor carpi ulnaris muscle, T7.4, 402, 422,

- 432, 434–437, 439–441, 463, 467

Flexor carpi ulnaris tendon, BP102, 402, 438,

- 441, 444, 450, 452, 455

Flexor digiti minimi brevis muscle, T7.4,

- BP117, T8.4, 452, 467, 524–527, 532

Flexor digiti minimi brevis tendon, BP117

- plantar, 519

Flexor digitorum brevis muscle, BP117, T8.4,

- 520, 524–525

Flexor digitorum brevis nerve, 532**Flexor digitorum brevis tendon**, BP117,

- 524–526

- plantar, 519

Flexor digitorum longus muscle, BP111, T8.4,

- 506, 509, 513–514, 532

Flexor digitorum longus tendon, 116–117, 507–509, 524–526
 plantar, 519
 tendinous sheath of, 520

Flexor digitorum profundus muscle, T7.4, 433, 438–441, 463, 466–467

Flexor digitorum profundus tendon, 105–106, 433, 441, 444, 448, 450–454, 460–461

Flexor digitorum superficialis muscle, T7.4, 409, 433, 436–439, 441, 463, 466

Flexor digitorum superficialis tendon, 105–106, 402, 433, 436, 441, 444, 448, 450–454, 460–461, 463

Flexor hallucis brevis muscle, T8.4, 524–525, 532
 lateral head of, BP117, 525–527
 medial head of, BP117, 525–527
 origin of, medial, 527

Flexor hallucis brevis nerve, 532

Flexor hallucis brevis tendon, origin of, lateral, 527

Flexor hallucis longus muscle, BP116, BP111, T8.4, 506, 509, 513–514, 532

Flexor hallucis longus tendon, 116–117, 507–509, 524–527
 groove for, 517
 plantar, 519
 tendinous sheath of, 520

Flexor muscles, superficial, 436, 514

Flexor pollicis brevis muscle, T7.4, 452, 455–456, 466–467

Flexor pollicis longus muscle, T7.4, 409, 433, 437–439, 441, 450, 453, 463, 466

Flexor pollicis longus tendon, 105–106, 438, 444, 452–453

Flexor retinaculum, BP116, 437, 444, 450, 452–453, 455–456, 463, 507–509, 513, 520, 525–526, 532

Flexor sheath, common, 450–453, 456

Flexor tendon, 453, 456
 common, 409–410, 432–433, 436, 439
 fibrous sheaths of, 524
 sheaths, 450
 at wrist, 452

Floating ribs, 192

Fluid-filled follicular cavity, BP95

Foliate papillae, 71, 146

Follicle-stimulating hormone, BP92

Follicles
 developing, BP95, BP92
 stages of, BP95

Follicular cavity, fluid-filled, BP95

Fontanelle
 anterior, BP17, 21
 posterior, 21

Foot
 arteries of, 114–115, 527
 bones of, 515
 cross-sectional anatomy of, 115–116
 digital nerves of, dorsal, 473
 dorsal venous arch of, 513
 dorsal venous network of, BP107
 dorsum of, 3, 522
 muscle of, 521
 interosseous muscle of, 527–528
 ligaments of, 519
 muscle of sole of
 second layer, 525–526
 nerves of, 114–115
 plantar region of, fibularis longus tendon passing to, 510
 plantar surface of, 471
 tendon of, 519

Foramen
 interventricular (of Monro), 119–120, 125, 156–157

Foramen (Continued)
 of Luschka, 119–120
 of Magendie, 117, 120, 125, 128
 transverse section through S2, 166

Foramen cecum, 18, 20, 71, 77

Foramen lacerum, BP29, 17, 19–20
 recurrent artery of, 148

Foramen magnum, BP29, 15, 19–20, 23, 138
 posterior margin of, BP19

Foramen ovale, BP29, 13, 17, 19–20, 23, 56, 59–60, 233
 branch to, 148
 valve of, 225

Foramen rotundum, 12, 20, 61
 branch to, 148

Foramen spinosum, BP29, 17, 19–20, 23, 59
 branch to, 148

Forearm
 arteries of, BP101
 bones of, 429
 cutaneous nerves of, 406
 muscles of
 anterior, T7.1
 attachments of, 439–440
 deep layer, 435, 438
 extensors of wrist and digits, 431
 flexors of digits, 433
 flexors of wrist, 432
 intermediate layer, 437
 posterior, T7.1
 rotators of radius, 430
 superficial layer, 434, 436
 proximal, arteries of, BP100, 424
 radial nerve in, 469
 serial cross sections of, 441
 superficial veins of, 406

Fornix, 117, 123, 158
 anterior, 354
 body of, 117, 123, 125
 columns of, 117, 121–123, 154, 156
 commissure of, 123
 crus of, 117, 121, 123

Fossa ovalis, 221, 224, 233
 limbus of, 224

Fovea
 centralis, 103
 inferior, 125
 superior, 125

Free nerve endings, BP1

Free taenia, 272, 280–281, 283

Frenulum, 281
 artery to, 70
 of clitoris, 358
 of labia minora, 358
 of lower lip, 65
 of penis, 364
 of tongue, 53, 65
 of upper lip, 65

Frontal artery, 10

Frontal bone, BP17, 8, 11, 13–18, 42, 44–45, 94–95
 anterior meningeal vessels of, groove for, 18
 foramen cecum of, 18
 frontal crest of, 18
 glabella of, 11, 13
 nasal spine of, 44–45
 of newborn, 21
 orbital part of, superior surface of, 18
 orbital surface of, 11
 sinus of, 15, 44–45
 squamous part of, 21, 44–45
 superior sagittal sinus of, groove for, 18
 supraorbital notch of, 11, 13, 21

Frontal crest, 16, 18, 45

Frontal gyrus
 inferior
 opercular part of, 116
 orbital part of, 116
 triangular part of, 116
 medial, 117
 middle, 116
 superior, 116

Frontal (metopic) suture, BP17, 21

Frontal nerve, BP26, 61, 97–98, 132–133, 142

Frontal pole, of cerebrum, 116, 118

Frontal region, 2

Frontal sinus, BP22, BP44, 12, 14, 43–45, 50–51, 77
 growth of, 52

Frontal sulcus
 inferior, 116
 superior, 116

Frontal vein, 10

Frontobasal artery
 lateral, 150, 153
 medial, 148, 150, 152–153

Frontonasal canal, opening of, 44

Frontonasal duct, opening of, 51

Frontopolar artery, 152–153

Fundic glands. *See* Gastric (fundic) glands

Fundic zone, 277

Fundiform ligament, 252
 of penis, 262, 349

Fundus
 of stomach, BP57, 237, 239, 276, 328
 of urinary bladder, 349–350, 352
 of uterus, 345, 355, 379

Fungiform papillae, 71, 146

Furrow, 71

G

Gallaudet's fascia, BP90, 349, 352–353, 359–360, 363–365, 373, 377–378

Gallbladder, BP62, BP87, T5.1, BP9, 137, 173, 202, 270, 273, 276, 282, 284, 287–288, 291, 327, 329
 innervation to, 172
 as site of referred visceral pain, BP13

Ganglion, 243
 inferior, 136, 145
 superior, 136
 of trigeminal nerve, 142

Ganglion cells, 131

Gartner's duct, 371. *See also* Mesonephric (Gartner's) duct

Gas exchange, BP50

Gastric artery
 left, 240, 273, 290, 300–301, 303, 392
 esophageal branch of, 240, 290
 right, 279, 287, 290–291, 301–303
 short, 290

Gastric folds (rugae), 239, 277, 328

Gastric (fundic) glands, BP60

Gastric impression, 284, 289

Gastric nodes, left, 242

Gastric plexus, 392

Gastric veins
 left, 241, 296–298
 esophageal tributary of, 241
 right, 241, 296–297, 299
 short, 241, 296, 299

Gastric zone, 277

Gastrocnemius muscle, BP111, T8.4, 471, 481, 484–485, 492, 497–498, 506–514, 531–532
 lateral head of, 471, 501–502
 lateral subtendinous bursa of, 501
 medial head of, 471, 501–502
 medial subtendinous bursa of, 501

Gastrocnemius tendon, BP116

Gastrocolic ligament, 273
 anterior layers of, 273
 posterior layers of, 273

Gastrooduodenal artery, 279, 287, 291–293, 303–304, 309

Gastrooduodenal plexus, 304

Gastroepiploic artery. *See* Gastrointestinal (gastroepiploic) artery

Gastroepiploic vessels. *See* Gastrointestinal (gastroepiploic) vessels

Gastroesophageal junction, T5.1

Gastrointestinal system, BP9

Gastrointestinal tract, BP41

Gastrolial ligament. *See* Gastrosplenic (gastrolial) ligament

Gastrointestinal (gastroepiploic) artery, 273, 290–291
 anastomosis of, 273
 left, 291
 plexus on, 301–302

Gastrointestinal (gastroepiploic) vessels, 273, 289
 left, 296
 right, 296, 298

Gastrointestinal vein
 left, 241
 right, 241

Gastrophrenic ligament, 273

Gastrosplenic (gastrolial) ligament, 273–274

Gelatinous substance, BP43

Gemellus muscle
 inferior, T8.4, 395, 400–401, 480–481, 485, 492–494
 nerve to, 487, 489
 superior, T8.5, BP109, 395, 480, 492–494
 nerve to, 487, 489, 492

Gemellus tendon, superior, BP109

Genicular artery
 descending, BP110, BP108, 491, 503
 articular branch of, BP110, BP108, 490
 saphenous branch of, BP110
 descending, saphenous branch of, BP108, 490
 lateral
 inferior, BP110, BP108, 503, 508–512
 superior, BP110, BP108, 492, 503, 507–509, 511–512
 medial
 inferior, BP110, BP108, 490–491, 503, 508–509, 511–512
 superior, BP110, BP108, 490–492, 503, 507–509, 511–512
 middle, BP110, BP108, 503
 superior lateral, 510

Genicular veins, BP107

Geniculate body
 lateral, 118, 121–122, 124, 127, 131, 143, 150, 154–156
 medial, 118, 121–122, 124, 150, 154–156

Geniculate ganglion, 59–60, 62, 107, 110, 134–136, 146

Genioglossus muscle, T2.1, T2.4, BP22, 45, 50, 68, 70, 77, 139

Geniohyoid fascia, 33

Geniohyoid muscle, BP22, T2.5, 33, 50, 69–70, 77–78, 139–140

Genital cord, 371

Genital tubercle, 370

Genitalia
 external, 173, 358, 362–363
 female, 395
 homologues of, 370
 innervation to, 172
 male, 391
 nerves of, 391
 internal, homologues of, 371

Genitalia (Continued)
 lymph nodes of
 female, 388
 male, 390
 lymph vessels of
 female, 388
 male, 390

Genitofemoral nerve, T5.2, 264, 269, 311, 316, 391, 486–488, 530
 femoral branches of, 260, 264, 269, 391, 473, 487
 genital branch of, 260, 262, 264, 269, 369, 391, 473, 487

Gerdy's tubercle, BP112, 484, 500, 504–505
 iliotibial tract to, 498

Gerota's fascia. *See* Renal (Gerota's) fascia

Gimbernat's ligament. *See* Lacunar ligament (Gimbernat's)

Gingiva, lamina propria of, 74

Gingival epithelium, 74

Gingival groove, 74

Glabella, 8, 11, 13

Gland lobules, 188

Glans, of clitoris, 370

Glans penis, 333, 364, 367, 370
 corona, 364
 neck, 364

Glassy membrane, BP1

Glenohumeral joint, BP57, 470
 capsule of, 422

Glenohumeral ligament
 inferior, 412
 middle, 412
 superior, 412

Glenoid cavity, of scapula, 192, 409, 411–412, 470

Glenoid labrum, 412
 inferior, 470
 superior, 470

Glial process, BP11

Glisson's capsule. *See* Perivascular fibrous (Glisson's) capsule

Glomerulus, 130

Glossoepiglottic fold
 lateral, 71
 median, 71

Glossoepiglottic ligament, median, 91

Glossopharyngeal nerve (CN IX), 40–41, 49, 64, 66, 72, 76, 83, 115, 124, 127–128, 134, 137, 141–142, 144–146, 214
 branch of, 173
 carotid sinus nerve of, 41
 distribution of, 129
 inferior (petrosal) ganglion of, 64, 146
 in jugular foramen, 20
 in jugular fossa, 19
 lingual branch of, 146
 schema of, 136
 tympanic branch of, 19

Gluteal aponeurosis, 492
 over gluteus medius muscle, 257, 312, 484–485

Gluteal artery
 inferior, BP98, 266, 317, 380, 384–385, 492
 superior, BP98, 266, 317, 380, 384–385, 489, 492

Gluteal fold, 161, 471

Gluteal lines, 476
 anterior, 338, 476
 inferior, 338, 476
 posterior, 338, 476

Gluteal nerves
 inferior, 169, 487, 489, 492–493
 superior, 169, 487, 489, 492–493

Gluteal region, 3

Gluteal surface. *See* Ilium, ala of

Gluteal vein
 inferior, 267
 superior, 267, 298

Gluteus maximus muscle, BP86, T8.4, BP109, 161, 180, 183, 257, 312, 343, 360, 363–364, 377, 392–393, 395, 400–401, 471, 481, 484–485, 492–494, 496, 534
 sciatic bursa of, 494
 trochanteric bursa of, 494
 inferior extension of, 494

Gluteus maximus tendon, BP109

Gluteus medius muscle, T8.1, T8.4, BP109, 161, 395, 400–401, 471, 481–482, 486, 490–494
 gluteal aponeurosis over, 484–485
 trochanteric bursae of, 494

Gluteus minimus muscle, BP86, T8.4, BP109, 480–481, 485, 490–494

Gluteus minimus tendon, 400

Gonadotropic hormone, BP92

Gonads, 371
 retroperitoneal, 368

Graafian follicle, BP95

Gracile fasciculus, BP43, 124

Gracile tubercle, 124–125

Gracilis muscle, T8.1, T8.4, 395, 480, 482–483, 485, 490–492, 496–498, 501, 507, 530

Gracilis tendon, 471, 482–483

Granular foveolae, 16, 111, 113

Granulosa, BP95

Gray matter, BP43
 imaging of, BP32, 160
 lateral horn of, 174, 322
 of spinal cord, 174
 of spinal nerves, 174

Gray rami communicantes, BP41, BP39, 141, 143–145, 172, 174, 177, 197, 213, 231–232, 234–235, 243, 269, 300, 303, 320–321, 392, 394, 397–399, 488–489

Great auricular nerve, 184

Great cardiac vein, 222

Great cerebral vein (of Galen), 114–115, 117, 125, 155–157
 imaging of, BP31, 159

Great saphenous vein, BP107, 5

Great vessels, of superior mediastinum, 210

Greater occipital nerve, 184

Greater omentum, 270, 272, 283, 285

Greater thoracic splanchnic nerve, BP39, 201, 213, 234–235
 left, 200, 220, 243
 right, 200, 243

Gubernaculum, 368, 371

H

Habenula, 121

Habenular commissure, 117, 122, 125

Habenular trigone, 122

Hair
 bulb of, BP2
 cortex of, BP2
 cuticle of, 1–2
 matrix of, BP1
 medulla of, BP2
 root sheath of
 external, BP2
 internal, BP2
 shaft of, BP2

Hair cells
 inner, 109
 outer, 109

Hair follicle, BP41, BP1
 external sheath of, BP1
 internal sheath of, BP1
 papilla of, BP1

Hamate bone, BP102, 442–443, 445–446, 452

Hamstring muscle, T8.1

Hand

arteries of, 456, 459
bones of, 446
bursae of, 453
cross section of, 105–106
cutaneous innervation of, 462
cutaneous nerves of, 406
dorsal fascia of, 453
dorsum of, 3
extensor zones of, BP103
flexor zones of, BP103
intrinsic muscles of, 455
nerves of, 456, 459
radial nerve in, 469
radiographs of, 447
spaces of, 453
superficial palmar dissections of, 449
superficial radial dissection of, 457
superficial veins of, 406
tendon sheaths of, 453

Hard palate, BP22, 72, 77

imaging of, 160
posterior nasal spine of, BP19

Haustra, 280, 283

Haversian canals, capillaries in, BP7

Head, 8–160

autonomic nerves in, 142
bony framework of, 22
cutaneous nerves of, 9
lymph vessels and nodes of, 85
nerves of, 82
radiate ligament of, BP33
superior articular facet on, BP33
surface anatomy of, 8

Heart, BP41, BP10, 137, 173

anterior aspect of, BP51
anterior exposure of, 216
apex of, BP51, 216, 218, 248
auscultation of, 217
base and diaphragmatic surface of, 218
conducting system of, 229
CT angiograms, 217
inferior border of, 216
innervation of, 172, 231
left border of, 202, 216
radiographs of, 217
right border of, 202
in situ, 215–233
valves and fibrous skeleton of, 226–227

Heart valves

aortic, T4.2, BP57, T4.1, 217, 221, 225–229
mitral, 217, 220–221, 225–229, 248

pulmonic, 217

tricuspid, 217, 220–221, 224, 226–228

Heel, 2

Helicotrema, of cochlea, BP28, 105, 108–109

Helix, 8, 106

crux of, 106

Hematopoietic cells, BP7

Hemiazygos vein, 198, 200, 220

accessory, 198, 211, 235, 241, 247

Hemidiaphragm, right, 217

Henle layer, BP2

Hepatic arteries, 287

branch of, 286
common, 273, 275, 279, 287, 290–291, 293–294, 300, 303, 309
intermediate, 291
left, 290–291
nerve branches of, BP63
proper, 274, 278–279, 284–285, 288, 290–293, 303, 324, 329
right, 290
variations in, BP70

Hepatic duct, 287

common, BP62, 284, 287, 291

left, 288

right, 288

variations in, BP68

Hepatic plexus, 137, 301–302, 304

Hepatic portal vein, T5.2, 221, 233, 241, 274, 276, 278–279, 284, 287–288, 296–299, 324, 326

tributaries of, 299

variations and anomalies of, BP71

Hepatic veins, 236, 241, 267, 284–285, 296

Hepatoduodenal ligament, 273, 276, 279, 329

Hepatogastric ligament, 276, 285

Hepatopancreatic ampulla, sphincter of, 309

Hepatorenal recess (Morison's pouch), BP84

Hepatorenal space (of Morrison), 278

Hering-Breuer reflex, 214. *See also* Stretch receptors (Hering-Breuer reflex)

Hernial sac, BP59

neck of, BP59

Hesselbach's triangle. *See* Inguinal (Hesselbach's) triangle

Hilar lymph nodes, 205. *See also*

Bronchopulmonary (hilar) lymph nodes

Hilum, 205, 289

Hinge joints, BP5

Hip

arthrogram of, 534
cross-sectional anatomy of, BP109
MRI of, 534
muscle of, 484–485
bony attachments of, 480–481
nerves of, 493
radiograph of, 534

Hip bursa, 494

Hip joint, T8.1, 477

anteroposterior radiograph of, 478

iliofemoral ligament of, 486

ligaments of, 483

Hippocampal sulcus, 123

Hippocampus, 119, 122–123

alveus of, 123

fimbria of, 117, 119, 121–123, 130

pes of, 122–123

Homologous chromosomes, BP91

Hook of hamate, BP102, 432, 438, 442, 444, 446–448

Horizontal cells, 131

Horizontal fissure, of lungs, right, 205

Horizontal plate, of palatine bone, BP29, 11, 17, 23, 43–45, 67, 73

Horn

anterior, BP43

posterior, BP43, 174

Humeral artery

anterior circumflex, BP100, 417–419, 421, 423–424

posterior circumflex, BP100, 417–419, 422–424

Humeral ligament, transverse, 412

Humeral lymph nodes, 190–191

Humeral vein, posterior circumflex, 405

Humerus, T7.1, 4–5, 217, 409, 411, 423, 425–428

anatomical neck of, 409–410

anterior view of, 409

body of, 247

capitulum of, 409

coronoid fossa of, 409

epicondyles of

lateral, 409–410, 421–422, 426–428, 430–433, 435, 438, 469

medial, 409–410, 421–423, 426–428, 430–438, 467–468

greater tubercle of, 409–412, 417, 421

crest of, 409

Humerus (Continued)

head of, 409–411, 470

intertubercular sulcus, 409

lateral supracondylar ridge, 409–410

left

head of, 217

shaft of, 245

medial supracondylar ridge, 409–410

posterior view of, 410

radial fossa of, 409

right, surgical neck of, 245

shaft of, 246

surgical neck of, 409–410, 470

trochlea of, 409

Huxley layer, BP2

Hyaloid canal, 100

Hydatid of Morgagni, 355

Hydrocele, 369

Hymen, variations of, BP96

Hymenal caruncle, 353, 358

Hyoepiglottic ligament, 77, 90

Hyoglossus muscle, T2.5, 34–36, 41, 68–70, 72, 78, 81, 139

Hyoid bone, BP34, BP4, 22, 32, 35–36, 38, 41, 53, 68, 70, 75, 77–78, 81, 87, 89–90, 92

body of, 22, 69

greater horn of, 22, 69, 81

tip of, 88

lesser horn of, 22, 69

Hyperplastic lateral lobe, BP98

Hyperplastic middle lobe, BP98

Hypertonic stomach, BP60

Hypochondriac region

anterior, 2

left, 251

posterior, 3

right, 251

Hypogastric nerve, BP39, 305, 320–321, 391–392, 396–399

left, 394

right, 394

Hypogastric (neurovascular) sheath, 347

Hypogastric plexus, 392

inferior, 306, 320–321, 391–392, 394, 396–399

superior, 172, 299, 305–306, 320, 344, 348, 392, 394, 396–399

uterovaginal, 397

Hypogastric region, 2, 251

Hypoglossal canal, BP19, 15, 17, 19–20

Hypoglossal nerve (CN XII), 39–41, 49, 59, 64, 68, 76, 82–84, 86, 115, 124, 128, 139–140

distribution of, 129

in hypoglossal canal, 19–20

meningeal branch of, 139

nucleus of, 127–128, 139

schema of, 139

vena comitans of, 70, 84

Hypoglossal trigone, 125

Hypophyseal artery

inferior, 148, 151

superior, 148, 151

Hypophyseal fossa, of newborn, 52

Hypophyseal portal system, primary plexus of, BP30

Hypophyseal portal veins

long, BP30

short, BP30

Hypophyseal veins, efferent, 151

Hypophysis, 115, 117–118, 158

arteries and veins of, BP30

in sella turcica, 43

Hypothalamic area, lateral, 146

Hypothalamic artery, 151

Hypothalamic nucleus

paraventricular, 158

supraoptic, 158

Hypothalamic sulcus, 117, 125, 158

Hypothalamic vessels, BP30
Hypothalamohypophyseal tract, 158
Hypothalamus, BP10, 119, 158
 arteries and veins of, BP30
 principal nuclei of, 158
 arcuate (infundibular), 158
 dorsomedial, 158
 mammillary body, 158
 paraventricular, 158
 posterior, 158
 supraoptic, 158
 ventromedial, 158
Hypothenar compartment, BP104
Hypothenar eminence, 402
Hypothenar muscles, BP105, 447, 449–450, 453, 467
Hypotonic stomach, BP60

I

Ileal arteries, 294–295
Ileal orifice, 283
Ileal papilla, 281
Ileal veins, 297
 internal, 298
Ileocecal fold (bloodless fold of Treves), 280
Ileocecal junction, BP85
Ileocecal lips, 281
Ileocecal recess
 inferior, 280
 superior, 280
Ileocecal region, 279–281, 304
Ileocolic artery, 280, 294, 305, 316
Ileocolic nodes, BP82
Ileocolic plexus, 305
Ileocolic vein, 297–299
Ileum, 85–86, 270, 279, 283, 297, 331
 circular muscle layer of, 279
 terminal part of, 272, 280–281, 344, 348
Iliac artery
 common, BP85, 4, 300, 311, 316–317, 380, 382, 384–385, 394
 left, 384
 right, 384
 deep circumflex, BP108, 491, 503
 ascending branch of, 258, 266
 external, 4, 108–109, 266, 300, 311, 316, 353, 380, 382, 384, 394, 491, 503
 internal, BP86, 4, 266, 293, 295, 300, 311, 316–317, 356, 380, 382, 384, 394
 superficial circumflex, BP108, 254, 266, 503
Iliac crest, BP85, 161, 167, 180–183, 249–250, 257, 311–312, 333–334, 337–338, 471, 474, 476, 484–486, 492–493
 iliac tubercle of, 338
 inner lip of, 250, 334, 338, 476
 intermediate zone of, 250, 334, 338, 476
 outer lip of, 250, 334, 338, 476
 tuberculum of, 250, 334, 476
Iliac fascia, 264, 347
Iliac fossa, 337–338, 344. *See also* Ilium, ala of
Iliac lymph nodes, 7
 common, 268, 388, 390
 external, 268, 319, 390, 475
 inferior, 388
 superior, 388
 internal, 268, 319, 388, 390
Iliac plexus
 common, 394
 external, 394
 internal, 394
Iliac spine
 anterior
 inferior, 250, 265, 334, 337–338, 342, 476–477
Iliac spine (*Continued*)
 superior, BP58, T5.1, 249–250, 252–253, 262–263, 265, 333–334, 337–338, 359, 362, 471, 476–477, 482, 484, 486, 490
 posterior
 inferior, 167, 476
 superior, 161, 167, 337–338, 476
Iliac tubercle, 337
Iliac tuberosity, 250, 334, 476
Iliac vein
 common, BP86, 5, 267, 381
 deep circumflex, 267
 tributaries to, 259
 external, BP107, BP109, 5, 267, 353, 381, 491
 internal, T6.2, 5, 267, 381
 superficial circumflex, BP107, 259, 267, 333, 473
Iliac vessels
 common, BP98, 272, 383, 394
 deep circumflex, BP98, 256, 264, 347
 external, BP98, 256, 262, 264, 280, 344–349, 356–357, 374, 383, 385
 covered by peritoneum, 263
 left, 385
 internal, BP98, 347, 383
 right, 385
 superficial circumflex, BP58, 252, 490
Iliacus fascia, 374
Iliacus muscle, T8.4, T5.3, T6.3, 262, 265, 311, 347, 374, 400, 480, 482, 486, 488–489, 495, 529
 muscular branches to, 488
 nerve to, 487
Iliococcygeus muscle, T6.3, 339–343, 353, 377
Iliocostalis cervicis muscle, 181
Iliocostalis lumborum muscle, 181
Iliocostalis muscle, 181
Iliocostalis thoracis muscle, 181
Iliofemoral joint capsule, 495
Iliofemoral ligament, BP109, 477, 495
 of hip joint, 486
Iliohypogastric nerve, T5.2, 169, 183, 269, 311–312, 391, 396, 486–488, 530
 anterior branch of, 487
 anterior cutaneous branch of, 260, 269, 391
 lateral cutaneous branch of, 257, 260, 474, 487
Ilioinguinal nerve, T5.2, 169, 263, 269, 311, 391, 396, 486–488, 530
 anterior scrotal branches of, 269, 391, 473
 labial branch of, anterior, 395
Iliolumbar artery, BP98, 266, 317, 384–385
Iliolumbar ligament, 167, 312, 337
Iliolumbar vein, 267
Iliopectineal bursa, 477, 486
Iliopectineal line, 374
Iliopsoas muscle, BP109, 256, 400–401, 480–481, 483, 490–491, 496. *See also* Iliacus muscle
Iliopsoas tendon, 495
Iliopubic eminence, 250, 334, 337–338, 342, 476–477
Iliopubic tract, 262, 344, 347–348
Iliotibial tract, T8.1, 395, 471, 480, 482, 484–485, 496–499, 501, 505–507, 510–512
 bursa deep to, 497–498
 to Gerdy's tubercle, 498
 vastus lateralis muscle deep to, 492
Ilium, 476, 478
 ala of, 250, 334, 338, 342, 476, 534
 arcuate line of, 340
 body of, 338, 476
 radiology of, 165, 335
Incisive canal, 15, 43, 45–46, 48, 77
 anastomosis in, 57
Incisive fossa, 17, 19, 23, 67, 73
Incisive papilla, 67
Incisor teeth, 73–74
Incus, BP28, 60, 105–106, 109, 135
 lenticular process of, BP27, 106
 long limb of, BP27, 106
 posterior ligament of, BP27
 short limb of, BP27, 106
 superior ligament of, BP27
Indirect inguinal hernia, BP59
Inferior, as term of relationship, 1
Inferior articular facet, of L4, BP36
Inferior articular process, 163–164
 of L1, BP37
 of L2, 165
 of L3, BP37
Inferior fascia, 349
 of pelvic diaphragm, 359
Inferior hypogastric plexus, 39–40, 172
Inferior mesenteric ganglion, BP41, BP39
Inferior mesenteric plexus, BP39
Inferior nodes, 389
Inferior phrenic nodes, 268
Inferior pubic ligament, 250
Inferior pubic ramus, 250
Inferior vena cava, BP38, BP87, BP98, BP84, 5, 267, 273–276, 278, 284, 288, 293, 296, 311–313, 323, 326–332, 344, 347–348, 381–384, 394
Inferior vertebral notch, of L2 vertebra, BP37
Inferolateral lobe, BP97
Inferoposterior lobe, BP97
Infraclavicular fossa, 2
Infradiaphragmatic fascia, 239
Infraglenoid tubercle, 409–410
Infraglottic cavity, 92
Infrayoid artery, 87
Infrayoid fascia, 33
Infrayoid muscle, fascia of, 32–33
Inframammary lymph nodes, 191
Inframammary region, 2
Infraorbital artery, 10, 42, 57, 63, 83, 94, 99
Infraorbital foramen, BP17, 11–13, 42
 of newborn, 21
Infraorbital groove, 11
Infraorbital margin, 8
Infraorbital nerve, BP26, 9, 42, 61–64, 66, 82, 94, 98, 132–133
 internal nasal branches of, 48
 superior alveolar branches of, 133
Infraorbital vein, 10, 84
Infrapatellar bursa
 deep, 502
 subcutaneous, 502
Infrapatellar fat pads, 498–499, 502
Infrapatellar synovial fold, 498–499
Infrascapular region, 3
Infraspinatus fascia, 180, 183, 257, 413
Infraspinatus muscle, T7.4, 161, 186, 197, 245–247, 410, 413, 415–418, 422, 468
Infraspinatus tendon, 412, 415, 417, 422
Infraspinatus fossa, 410
 of scapula, 192
Infratemporal crest, 13
Infratemporal fossa, 13, 23
 superior view of, 60
Infratrochlear nerve, 9, 42, 61, 97, 133
 left, 98
 right, 98
Infundibular process, 158
 capillary plexus of, BP30
Infundibular recess, 117
Infundibular stem, 158
Infundibulum, 124, 158, 355
 of uterine tube, 357
Inguinal canal, BP109, 263–264
Inguinal falx, BP58, 253–254, 256, 262–263
Inguinal fold, 371

- Inguinal (Hesselbach's) triangle**, T5.1, 256, 262
- Inguinal ligament (Poupart's)**, BP107, BP58, T5.1, 249, 252–254, 262–265, 333, 340, 356, 359, 362–363, 389, 471, 473, 475, 482, 488, 491
reflected, 253–254, 262
- Inguinal lymph nodes**, 7
deep, 475
- Inguinal nerve**, 260
anterior scrotal branch of, 260
- Inguinal nodes**
of Cloquet, proximal deep, 388–390
deep, 268, 388–390
superficial, 268, 388–390, 475
inferior, 475
superolateral, 475
superomedial, 475
- Inguinal region**, BP58, 2
dissections of, 262
left, 251
right, 251
- Inguinal ring**
deep, BP59, T5.1, 254, 256, 262, 344, 346–348, 368
lateral crus, 262
medial crus, 262
superficial, BP58, 252, 262–263, 359, 363, 368–369
- Inhibin**, BP92
- Inion**, 13–15, 17, 23
- Initial segment**, BP11
- Insula (island of Reil)**, 116, 121, 152
central sulcus of, 116
circular sulcus of, 116
limen of, 116
long gyrus of, 116
short gyrus of, 116
- Integumentary system**, T5.1
- Interalveolar septa**, 24
- Interarytenoid notch**, 79
- Interatrial septum**, 224, 248
- Intercalated node**, 85–86
- Intercapital veins**, BP99, 406, 458
- Intercarpal ligament, dorsal**, 445
- Intercartilaginous ligaments**, 208. *See also* Anular ligaments
- Intercavernous septum, of deep fascia**, 363–364, 367
- Intercavernous sinus**
anterior, 114–115
posterior, 114–115
- Interchondral joints**, 193
- Interclavicular ligament**, 193
- Intercondylar area**
anterior, 504–505
posterior, 505
- Intercondylar eminence**, 499, 501, 504–505
- Intercondylar fossa**, 479
- Intercondylar tubercles**, 505
- Intercostal artery**, 197, 258
anterior, 196–197
collateral branches of, 196
cutaneous branches
anterior, 260
lateral, 260
lower, anastomoses, 258
posterior, 176, 194–195, 197, 234–235, 417
dorsal branch of, 177, 197
lateral mammary branches of, lateral cutaneous branches of, 189, 197
right, 197, 211, 240
spinal branch of, 147
supreme, BP23, 147, 149
- Intercostal membrane**
external, 186, 197, 417
innermost, 186
internal, 186, 197
- Intercostal muscles**, BP56, 188, 204, 221, 245–247, 258
external, T4.3, 182, 186, 194–195, 197, 253, 258, 261, 417
internal intercostal membrane deep to, 197, 234–235
innermost, T4.3, 196–197, 234–235, 258, 261
internal, T4.3, BP47, 186, 194–197, 258, 261, 417
- Intercostal nerves**, T5.2, T4.1, 169, 188, 195–197, 232, 234–235, 487
anterior cutaneous branches of, 194, 196–197, 417
anterior ramus of, 177, 186
collateral branches of, 196
cutaneous branches of
lateral, 183
posterior, 183
eight, 213
first, 231
lateral cutaneous branches of, 194–195, 197, 417
anterior branch of, 197
lower, 199
sixth, 213
third, 243
- Intercostal nodes**, 242
- Intercostal veins**, 5
anterior, 196, 198
collateral branches of, 196
posterior, 198, 234–235
right, 241
superior
left, 235, 241
right, 198, 234, 241
- Intercostobrachial nerve**, 195, 260, 404–405, 417, 419, 463
- Intercrural fibers**, BP58, 252, 262–263
- Intercuneiform ligaments, dorsal**, 518
- Interdigitating fibers, of perineum**, 341
- Interfascicular fasciculus**, BP43
- Interfoveolar ligament**, 256
- Intergluteal cleft**, 161
- Interlobar lymph vessels**, 212
- Interlobular arteries**, 314
- Intermaxillary suture**, 17, 42
- Intermediate bronchus, right**, BP56
- Intermediate nerve (of Wrisberg)**, 107, 134, 142, 146
motor root of, 135
- Intermediate sulcus, posterior**, BP43
- Intermediolateral cell column**, 322
- Intermediolateral nucleus**, BP43
- Intermesenteric (abdominal aortic) plexus**, 269, 300, 304–305, 321, 392, 394, 396–399
- Intermetacarpal joints**, 445
- Intermuscular septum**
anterior, 514
lateral, 421–422, 425, 435, 438, 468
medial, 421–422, 425, 435, 437–438
posterior, 514
transverse, 514
- Intermuscular stroma**, 308
- Internal abdominal oblique muscles**, 185
- Internal capsule**, 119, 121, 152
anterior limb of, 121
imaging of, 160
cleft for, 121
genu of, 121
imaging of, 160
posterior limb of, 121
imaging of, 160
retrolenticular part of, 121
- Internal carotid nerve**, BP41, BP39
- Internal carotid plexus**, BP39, 19
- Internal genitalia, homologues of**, 371
- Internal jugular vein, left**, 179
- Intervertebral (neural) foramen**, BP34
exiting L4 nerve root, BP38
- Internal oblique muscle**, 344, 348
- Internal occipital protuberance**, 18
- Internal os**, 355
- Internal vertebral venous plexus, anterior**, BP42
- Interosseous artery**
anterior, 100–101, 424, 435, 437–438, 441
common, 100–101, 424, 437–438, 441
posterior, 100–101, 424, 435, 438, 441
recurrent, 100–101, 424, 435
- Interosseous compartments**
dorsal, BP104
palmar, BP104
- Interosseous fascia**
dorsal, 453
palmar, 453
- Interosseous intercarpal ligaments**, 445
- Interosseous membrane**, BP102, BP110, BP116, BP111, BP108, 429, 431, 433, 441, 444, 501–503, 509, 512, 514, 517
- Interosseous muscle**, BP105, BP117, 454, 519, 527
dorsal, T7.4, BP106, 453, 455, 460, 522, 527–528
first, BP105, 435, 450, 455, 457, 467
palmar, T7.4, 453, 455, 467
- Interosseous nerve**
anterior, 438, 441, 466
crural, 532
posterior, 435, 441, 469
- Interosseous veins, anterior**, BP99
- Interpectoral (Rotter's) lymph nodes**, 190–191
- Interpeduncular cistern**, 120
imaging of, BP32
- Interpeduncular fossa**, 50
- Interphalangeal (IP) joint**, 519
- Interphalangeal ligaments**, 448
- Interscapular region**, 3
- Intersigmoid recess**, 272, 316
- Intersphincteric groove**, 374–376
- Interspinales muscle**, T3.2
- Interspinalis cervicis muscle**, 182
- Interspinalis lumborum muscle**, 182
- Interspinous ligament**, 167–168
- Interspinous plane**, 251
- Intertendinous connections**, 460
- Interthalamic adhesion**, 117, 121–122, 125, 157–158
- Intertragic notch**, 106
- Intertransversarii muscle**, T3.2
- Intertransversarius laterales lumborum muscle**, 182
- Intertransverse ligament**, 193
- Intertrochanteric crest**, 477, 493
- Intertrochanteric line**, 477
- Intertubercular plane**, 251
- Intertubercular sulcus**, 409
- Intertubercular tendon sheath**, 412, 417, 421
- Interureteric crest**, 352
- Interventricular artery, anterior, diagonal branch of**, 222
- Interventricular branch**
anterior, 223
diagonal branches of, 223
inferior, 223
- Interventricular foramen (of Monro)**, 117, 120, 125, 156–157
imaging of, 160
left, 117
- Interventricular septal branches**, 222
- Interventricular septum**, 228, 248
membranous part of, 224
muscular part of, 224–225, 227–229

Interventricular sulcus
 anterior, BP51, 248
 inferior, 218–219

Intervertebral disc space, BP37
 C6–C7, BP34
 L4–L5, BP36

Intervertebral discs, T3.1, BP33, 164, 168
 C6–C7, BP35
 cervical, 28–29
 L1–2, cross section at, 331
 lumbar, 167
 L2–L3, 165
 lumbosacral, 338
 T12–L1, cross section at, 330

Intervertebral foramen, BP37, T3.1, BP36,
 BP34, T3.2, 28, 164, 166–168, 186
 narrowing of, BP18

Intervertebral vein, BP42, 178

Intestinal arteries, T5.2

Intestinal trunk, 268

Intestines, 173, 233. *See also* Large intestine;
 Small intestine
 autonomic innervation of, 306
 enteric plexus of, 308
 lymphoid nodules of, 7
 mesenteric relations of, 271
 superior, 172

Intima, of arterial wall, BP16

Intraarticular ligament, BP33
 of head of rib, 193

Intraarticular sternocostal ligament, 193

Intraclavicular node, 407

Intraculminate vein, 155

Intralaminar nuclei, 122

Intralobular arteriole, 286

Intralobular bile ductules, 286

Intraparietal sulcus, 116

Intrapulmonary airways, 209
 schema of, BP48

Intrapulmonary blood circulation, schema of,
 BP49

Intrapulmonary lymph nodes. *See* Pulmonary
 (intrapulmonary) lymph nodes

Intrarenal arteries, 315

Intrinsic back muscles, T3.1

Intrinsic muscle
 of larynx, 91
 action of, 93
 of tongue, 71

Inversion, of lower limbs movements, 472

Investing fascia, BP90, 353, 359–360, 363–365,
 373, 377
 deep, 349, 352

Iridocorneal angle, 100–101, 103

Iris, 94, 100, 102–103
 arteries and veins of, 104
 folds of, 101
 major arterial circle of, 101, 103–104
 minor arterial circle of, 101, 103–104

Irritant receptors, 214

Ischial ramus, 478

Ischial spine, T6.1, 167, 250, 265, 334,
 337–342, 380, 393, 395, 476–477, 493
 measurements of, 336
 radiograph of, 335

Ischial tuberosity, T6.1, 167, 250, 334,
 337–338, 341, 343, 359–360, 362–365, 374,
 377, 401, 476–478, 485, 492–493
 radiograph of, 335
 ramus of, 476
 measurements of, 336

Ischioanal fossa, 360, 374
 anterior recess of, 256, 352–353
 fat body of, 359, 362, 374, 400
 fibrous septum of, transverse, 376–377
 levator ani muscle roofing, 363
 transverse fibrous septum of, 374

Ischiocavernosus muscle, T6.3, 345, 352–353,
 359–361, 363–365, 373, 377, 386–387

Ischiofemoral joint capsule, 495

Ischiofemoral ligament, BP109, 477, 495

Ischiopubic ramus, 337–338, 343, 349, 353,
 359–360, 362, 364–366, 377

Ischium; *See* Ischial tuberosity

Island of Reil. *See* Insula (island of Reil)

Isthmus, 355
 of uterus, 355

J

Jejunal arteries, 294–295
 anastomotic loop (arcade) of, 279, 294

Jejunal veins, 297

Jejunum, 270–271, 278–279, 297, 327, 330–331
 circular muscle layer of, 279
 longitudinal muscle layer of, 279
 submucosa of, 279

Joint capsule, BP6, BP117, 428, 448, 497, 499,
 511
 attachment of, 502
 of foot, 519
 synovium lining, BP114

Joint fluid, BP109

Joints
 ball-and-socket, BP5
 connective tissues and cartilage of, BP6
 hinge, BP5
 pivot, BP5
 plane, BP5
 saddle, BP5
 synovial, BP5
 types of, BP5

Jugular foramen, 15, 20, 115, 136–138

Jugular fossa, BP27, 17, 19

Jugular nerve, 141

Jugular notch, 8, 32, 187, 202
 of sternum, 192

Jugular trunk, 85

Jugular vein
 anterior, 38, 87
 termination of, 84
 external, T2.2, 5, 8, 10, 38–39, 53, 84, 87,
 204, 210, 215, 241
 internal, 5, 10, 32–33, 35, 37–38, 40–41, 49,
 53, 64, 70, 76, 84, 86–89, 105, 107, 110,
 139, 191, 195–196, 204, 212, 215, 236,
 241
 imaging of, BP31, 159
 inferior bulb of, 88, 179
 in jugular fossa, 19
 left, 216, 221
 right, T2.2, 210, 217
 superior bulb of, 179

Jugulodigastric node, 85–86

Juguloomohyoid node, 85–86

K

Kidneys, BP38, BP57, T5.1, BP10, 173, 185,
 233, 273, 278, 285, 368, 382
 autonomic nerves of, 320
 gross structure of, 314
 inferior pole of, 314
 innervation of, 172
 autonomic, 321
 lateral border of, 314
 left, BP87, BP84, 203, 274, 289, 316, 323
 lymph vessels and nodes of, 319
 major calyces of, 314
 medial border of, 314
 medulla (pyramids) of, 314, 330
 minor calyces of, 314
 parenchyma of, blood vessels in, BP78
 pole of, 278

Kidneys (*Continued*)
 renal capsule of, 314
 renal column (of Bertin) of, 314
 renal sinus of, 314
 right, 203, 274–276, 284, 310–311, 316, 318,
 323, 326–327
 sagittal view of, 278
 as site of referred visceral pain, BP13
 in situ
 anterior view of, 311
 posterior view of, 312
 superior pole of, 314
 superior pole of, 314

Knee, 497–503
 anterior region of, 2
 arteries of, BP108
 bursa of, 499
 condyle of
 lateral, BP112
 medial, BP112
 epicondyle of, medial, BP112
 joint capsule of, 497
 osteology of, BP112
 posterior region of, 3
 radiograph of, BP113, 501
 transverse ligament of, 500

L

L5/S1 vertebrae, T3.1

Labia majora
 commissure of, anterior, 358
 posterior commissure of, 358

Labia minora, 356
 frenulum of, 358

Labia minus, 345

Labial artery
 inferior, 42, 83
 posterior, 361, 386
 superior, 42, 83

Labial nerves
 posterior, 395–396

Labial vein
 inferior, 84
 superior, 84

Labioscrotal swelling, 370

Labium majus, BP90, 345, 350, 353, 358,
 370

Labium minus, BP90, 345, 350, 353, 358, 361,
 370

Labrum
 anterior, BP109, 534
 posterior, BP109, 534

Labyrinthine artery, 20, 107, 150–152, 154
 left, 147

Lacrimal apparatus, 95

Lacrimal artery, 99, 149
 recurrent meningeal branch of, 112

Lacrimal bone, 11, 13, 44, 50
 of newborn, 21, 52

Lacrimal canaliculi, 95

Lacrimal caruncle, 95

Lacrimal gland, BP26, BP40, 50, 97–99, 144,
 173
 excretory ducts of, 95
 innervation to, 172
 orbital part of, 95
 palpebral part of, 95

Lacrimal nerve, BP26, 61, 63, 97–98, 132–133,
 142
 palpebral branch of, 9, 61

Lacrimal papilla
 inferior, 94–95
 superior, 94–95

Lacrimal punctum
 inferior, 94–95
 superior, 94–95

- Lacrimal sac**, 94–95
fossa for, 11, 13
- Lactiferous ducts**, 188
- Lactiferous sinus**, 188
- Lacuna magna**, 367
- Lacuna (of Trolard), lateral (venous)**, 111–112
- Lacunar ligament (Gimbernat's)**, 253–254, 256, 262, 264–265
- Lambda**, 16
- Lambdoid suture**, BP17, 12, 14–16, 21
- Lamina**, BP38, T3.1, 164, 167–168
anterior, of broad ligament, 357
of C6, BP34
of L1, 165
of L4 vertebra, BP37
lumbar, 167
of mesosalpinx, 357
of mesovarium, 357
posterior, of broad ligament, 357
thoracic, 163
- Lamina affixa**, 122
- Lamina propria, of arterial wall**, BP16
- Lamina terminalis**, 117–118, 125, 158
- Large intestine**, BP9, 283
arteries of, 295
autonomic innervation of, 305
lymph vessels and nodes of, BP82
veins of, 298
- Laryngeal artery**
inferior, 92
superior, 41, 80, 83, 87–89, 92, 147
- Laryngeal inlet (aditus)**, 77, 79–80
- Laryngeal nerve**
recurrent, T2.2, 33, 40, 76, 82, 92, 141, 236, 243
left, 87–89, 137, 199, 210, 213–214, 216, 230, 235–236, 243, 245–246
right, 34, 80, 87–89, 92, 137, 230, 243
superior, 76, 137, 141–142, 146, 214, 243
external branch of, 82, 87–89, 92, 137
internal branch of, 75, 78, 80, 82, 87–89, 92, 137, 146
- Laryngeal prominence**, 90
- Laryngeal vein, superior**, 84
- Laryngopharynx**, BP44, 77, 79
- Larynx**, BP41, BP44, 146, 173, 214
cartilages of, 90
coronal section of, 92
innervation to, 172
intrinsic muscles of, 91
action of, 93
nerves of, 92
- Lateral, as term of relationship**, 1
- Lateral aortic nodes**, 268
- Lateral aperture**, 120
left, 117
- Lateral circumflex femoral vein**, BP107
- Lateral corticospinal tract**, BP43
- Lateral direct vein**, 157
- Lateral ligament, of ankle**, 518
- Lateral node**, 390
- Lateral plantar vein**, BP107
- Lateral recess**, 125
left, 117
- Lateral rectus (semilunar) plane**, BP62
- Lateral semilunar plane**. *See* Lateral rectus (semilunar) plane
- Lateral sulcus**
anterior, BP43
posterior, BP43
- Latissimus dorsi fascia**, 416
- Latissimus dorsi muscle**, T7.4, T3.2, 161, 180, 183, 185–187, 194, 248, 252–253, 257, 260–261, 312, 328, 409–410, 413–414, 416–417, 419, 421, 423
digitations of costal origin of, 257
left, 246
- Latissimus dorsi tendon**, 246–247, 423, 425
- Least thoracic splanchnic nerve**, 213
- Left bundle**
Purkinje fibers of, 229
subendocardial branches of, 229
- Left lateral region**, 251
- Leg**
anterior compartment of, T8.1
anterior region of, 2
arteries of, BP110
deep veins of, T8.2
muscle of, 507–512
attachments of, 506
posterior region of, 2–3
serial cross sections of, BP111
venous drainage of, 513
- Lens**, BP26, 94, 100–103
axis of, 102
capsule of, 100–102
cortex of, 102
equator of, 102
nucleus of, 101–102
supporting structures of, 102
- Lentiform nucleus**, 121
globus pallidus of, 119, 121
putamen of, 119, 121
imaging of, 160
- Lesser occipital nerve**, 9
- Lesser thoracic splanchnic nerve**, BP39, 201, 213
- Lesser tubercle**, 409, 411–412, 421
crest of, 409
- Levator anguli oris muscle**, BP20, T2.5, 55, 134
- Levator ani fascia, superior**, 347
- Levator ani muscle**, BP90, T6.1, BP109, T6.3, 256, 265, 283, 299, 306, 324, 340–341, 345, 351–353, 359–360, 365, 375–376, 380, 384–386, 392–393, 489
fibromuscular extensions of, 343
iliococcygeus, 341–343, 377
left, 339
levator plate of, 340
medial border of, 343
median raphe of, 341
muscle fibers from, 342–343
muscular trochlea of, 265
nerve to, 487, 489
of pelvic diaphragm, 345, 349, 364, 373–374, 378
prerectal muscle fibers from, 343
puboanal (puborectalis), 341, 377, 400–401
pubococcygeus, 341–343, 377
roofing ischioanal fossa, 363
tendinous arch of, 339–343, 347, 350, 352–353, 360, 374
- Levator costarum muscle**, T4.3, 182
- Levator labii superioris alaeque nasi muscle**, BP21, T2.5, 31, 55, 134
- Levator labii superioris muscle**, T2.5, 20–21, 31, 55, 134
- Levator palpebrae superioris muscle**, BP26, T2.1, T2.5, 94, 96–98, 132
insertion of, 94
- Levator scapulae muscle**, T7.4, 32–33, 36, 39, 180, 183, 410, 413, 417–418, 468
- Levator veli palatini muscle**, T2.1, T2.5, BP27, 49, 56, 67, 72, 75, 78, 81, 137
interdigitating fibers of, 67
- Levatores costarum muscles**, 182
brevis, 182
longus, 182
- Level of Carina**, BP36
- Ligament of Treitz**, 271
- Ligamenta flava**, 29
- Ligaments**
of ankle, 518
of elbow, 428
of foot, 519
of pelvis, 357
of uterus
fascial, 354
round, BP90, 344–346, 352–354, 356, 359, 371, 382
of wrist, BP102, 444–445
- Ligamentum arteriosum**, 41–42, 210, 216, 225, 233, 235
aortic arch lymph node of, 212
- Ligamentum flavum**, BP19, 167–168
radiology of, 165
- Ligamentum teres, of liver**, 233, 285
fissure for, 284
- Ligamentum venosum**, 233
fissure for, 284
- Limb, lower**, 471–535
- Limen nasi**, 43
- Linea alba**, BP86, BP84, BP58, T5.1, 187, 194, 249, 252–255, 261–262, 333, 344, 348
- Linea semilunaris**, 249, 333
- Linea terminalis**, 166, 353
of pelvis, 347–348
- Linea translucens**, 101
- Lingual artery**, 10, 41, 57–58, 68, 70, 83, 88, 144, 147, 149
deep, 65
dorsal, 70
tonsillar branch of, 72
- Lingual glands**, 71
- Lingual gyrus**, 117
- Lingual muscle, longitudinal**
inferior, T2.5, 70
superior, T2.8
- Lingual nerve**, 25, 53, 56–57, 59, 65–66, 68–70, 82, 133–134, 142, 144–146
- Lingual tonsil**, 71–72, 77
- Lingual vein**, 10, 70, 84
deep, 65
dorsal, 70
- Lingula**, 24, 69, 126, 205
- Lip**
commissure of, 8
lower, frenulum of, 65
philtrum, 8
superior, tubercle of, 8
upper
frenulum of, 65
tubercle of, 65
vermillion border of, 8
- Lister's tubercle**, 429
- Liver**, BP62, BP38, T5.1, BP9, 56–57, 137, 173, 202–203, 217, 221, 233, 241, 273, 278, 287, 318, 324, 326, 328–329
area for, 311
arteries of, 290–291
autonomic innervation of, 309
bed of, 284
caudate lobe of, 273, 276, 284–285
coronary ligament of, 275
falciform ligament of, 258
fibrous appendix of, 284
inferior border of, 276
innervation to, 172
left lobe of, 270, 276, 285
lymph vessels and nodes of, BP83
pathway to, 190
quadrate lobe of, 276, 284
right lobe of, BP87, 270, 276, 285
round ligament of, 256, 284, 299
as site of referred visceral pain, BP13
structure of, 286
surfaces and bed of, 284
topography of, BP63

Liver (*Continued*)

- variations in form of, BP62, BP64
- vascular systems of, 285
- Lobules**, 8, 372
- Locus coeruleus**, 125
- Longissimus capitis muscle**, 181, 184
- Longissimus cervicis muscle**, 181
- Longissimus muscle**, 181
- Longissimus thoracis muscle**, 181
- Longitudinal esophageal muscle**, 239
- Longitudinal fasciculi**
 - dorsal, 158
 - medial, BP43, 125–126
- Longitudinal fold**, 287
- Longitudinal ligament**
 - anterior, BP35, BP19, 29, 77–78, 167–168, 185, 193, 337, 344, 348
 - posterior, BP35, BP19, BP33, 30, 167–168
- Longitudinal muscle**, BP54, 375
 - conjoined, 374–376
 - lateral mass of, 238
- Longitudinal pharyngeal muscle**, 75, 78, 80
- Longitudinal vessels**, BP12
- Longus capitis muscle**, T2.6, 36–37, 49, 68
- Longus colli muscle**, T2.6, 33, 37, 236
 - innervation of, 420
- Loop of Heiss**, 351
- Lower limb**, 471–535
 - arteries of, T8.2
 - cutaneous anatomy of, 473–475
 - lymphatics of, 7
 - surface anatomy of, 471
 - veins of, BP107
- Lumbar arteries**, 266
- Lumbar artery**, 176
- Lumbar ganglion, 1st**, 172
- Lumbar lordosis**, 162
- Lumbar lymph nodes**, 7, 268
 - lateral, 388
- Lumbar lymph trunks**, 319
- Lumbar plexus**, 169, 486, 488, 529–530
 - anterior rami of, 488
- Lumbar region**
 - anterior, 2
 - posterior, 3
- Lumbar spinal nerves**, 185
 - enlargement, 170
 - L1, 164–165, 169
 - anterior ramus of, 392
 - anterior view of, 162
 - dermatome of, 171
 - left lateral view of, 162
 - posterior view of, 162
 - vertebrae relation to, 170
 - L2, 164
 - anterior ramus of, 167, 399
 - dermatome of, 171
 - ganglion, 394
 - superior view of, 164
 - vertebrae relation to, 170
 - L3, 164
 - anterior ramus of, 397
 - dermatome of, 171
 - posterior view of, 164
 - superior view of, 164
 - vertebrae relation to, 170
 - L4, 164, 167
 - dermatome of, 171
 - posterior view of, 164
 - vertebrae relation to, 170
 - L5, 164, 169, 394
 - anterior ramus of, 392
 - anterior view of, 162
 - dermatome of, 171
 - left lateral view of, 162
 - posterior view of, 162
 - vertebra, body of, 167
 - vertebrae relation to, 170

Lumbar spine

- MRIs, BP38
- radiographs of, MRI, BP38
 - T2-weighted sagittal MRI of, 165
- Lumbar splanchnic nerves**, BP39
- Lumbar triangle (of Petit)**, 161, 180, 257
- Lumbar trunk**
 - left, 268
 - right, 268
- Lumbar trunk ganglion**
 - lower, 232
 - upper, 232
- Lumbar veins**
 - ascending, 267
 - right, 267
- Lumbar vertebrae**, BP37, 162, 164, 176
 - articulated, lateral view of, 164
 - body of, 164
 - L1
 - body of, 167
 - spinal nerve relation to, 170
 - transverse process of, 201
 - L2, spinal nerve relation to, 170
 - L3
 - body of, 344, 348
 - spinal nerve relation to, 170
 - L4, 379
 - body of, 338
 - intervertebral disc, 379
 - radiograph of, 335
 - spinal nerve relation to, 170
 - L5, BP37, T3.1
 - body of, 338, 379
 - intervertebral disc, 379
 - radiograph of, 335
 - spinal nerve relation to, 170
 - radiographs of, BP37
 - section through, 177
 - transverse process of, 250, 334
- Lumbar vertebral body**, 168
- Lumbocostal ligament**, 312
- Lumbocostal triangle**, 201
- Lumbosacral plexus**, 269, 487
- Lumbosacral region, vertebral ligaments**, 167
- Lumbosacral trunk**, 269, 320, 392, 486–489, 529–530
- Lumbral muscles**, T8.5, T7.4, 105–106, 450–455, 466–467, 524–525, 527
 - tendon of, 526
- Lumbral tendons**, 451, 519
 - distal, 451
- Lumen**, 308
- Lunate (articular) surface**, 338
- Lunate bone**, BP102, 442–443, 445–447
 - articulation with, 429
- Lunate sulcus**, 116
- Lunate surface**, 476
- Lungs**, BP41, 173, 177, 188
 - apex of, T4.1, 202, 217
 - innervation to, 172
 - left, 205, 215, 219–221, 244–247
 - anterior border of, 205
 - apex of, 203, 205
 - bronchopulmonary segments of, 206–207
 - cardiac impression of, 205
 - cardiac notch of, 202, 204
 - diaphragmatic surface of, 205
 - esophagus area of, 205
 - hilum of, 216
 - inferior border of, 202–203
 - inferior lobe of, 204–205
 - lower lobe of, BP57
 - lymph vessels and nodes of, 212
 - oblique fissure of, 202–203, 205, 246
 - root of, 199
 - superior lobe of, BP56, 204–205
 - trachea area of, 205
 - upper lobe of, BP57

Lungs (*Continued*)

- lymph nodes of, 212
- lymph vessels of, 212
- lymphatic drainage routes of, 212
- medial views of, 205
 - right, 205, 215, 220–221, 245–247
 - anterior border of, 205
 - apex of, 205
 - bronchopulmonary segments of, 206–207
 - cardiac impression of, 205
 - diaphragmatic surface of, 205
 - esophagus area of, 205
 - hilum of, BP44, 216
 - horizontal fissure of, BP56, 202–205
 - inferior border of, 202
 - inferior lobe of, 204–205
 - lymph vessels and nodes of, 212
 - middle lobe of, BP56, 204–205
 - oblique fissure of, BP56, 202, 205
 - root of, 199
 - superior lobe of, 204–205
 - trachea area of, 205
- in situ, anterior view of, 204
- topography of
 - anterior view of, 202
 - posterior view of, 203
- Lunotriquetral ligament**, 444
- Lunula**, 227
- Lunule**, 460–461
- Luteal cells**, BP95
- Luteinizing hormone**, BP92
- Lymph follicles**, 71
- Lymph nodes**, 401
 - axillary, 7
 - cervical, 7
 - of esophagus, 242
 - in femoral canal, 264
 - of genitalia
 - female, 388
 - male, 390
 - of head, 85
 - iliac, 7
 - inguinal, 7
 - lumbar, 7
 - of lungs, 212
 - of mammary gland, 7, 190
 - mediastinal, 7
 - of neck, 85
 - paraortic, T6.2
 - of pelvis, T6.2
 - female, 388–389
 - male, 390
 - of pharynx, 86
 - popliteal, 475
 - preaortic, T6.2, 388
 - submandibular, 68
 - tongue, 86
 - tracheobronchial, T6.2
- Lymph vessels**, T8.2, 286
 - along arcuate arteries, 319
 - along arteries, 319
 - along interlobar arteries, 319
 - of esophagus, 242
 - of genitalia
 - female, 388
 - male, 390
 - of head, 85
 - of lungs, 212
 - of mammary gland, 190
 - medullary, 319
 - of neck, 85
 - of pelvis
 - female, 388–389
 - male, 390
 - of pharynx, 86
 - superficial, 475
 - tongue, 86

Lymphatic drainage
of breast, 191
of lungs, 212
of pharynx, 86
of prostate gland, 390
of tongue, 86

Lymphatic duct, right, 7, 191, 212

Lymphatic system, T6.2, T4.2, T5.2, T4.1, 7

Lymphatic trunk
bronchomediastinal, 212
jugular, 212

Lymphatics, abdominal and pelvic, 325

Lymphocytes, BP15

Lymphoid nodule, solitary, 279

M

Mackenrodt's ligament, 346, 353–354. *See also* Cardinal (Mackenrodt's) ligament with uterine artery, 347

Macrophage, BP6

Macula, 103

Macular arteriole
inferior, 103
superior, 103

Macular venule
inferior, 103
superior, 103

Malleolar fold
anterior, BP27, 106
posterior, BP27, 106

Malleolar arteries, anterior
lateral, BP110, BP115, 503, 512, 521–522
medial, BP110, 503, 512, 521–522

Malleolar region, medial, 00001#

Malleolar stria, arteries of, 107

Malleolus
lateral, 471, 505, 507–512, 521–522
medial, BP116, 471, 505, 507, 509, 511–513, 520–522

Malleus, 60, 106, 109
anterior ligament of, 106
anterior process of, BP27
handle of, BP27, 106–107
head of, 27–28, 105–106, 135
lateral process of, 106
superior ligament of, BP27, 106

Mammary gland, T4.1
anterolateral dissection of, 188
arteries of, 189
lymph nodes of, 7, 190
lymph vessels of, 190
sagittal section of, 188

Mammary region, 2

Mamillary bodies, BP30, 50, 117–119, 123–124, 158
imaging of, BP32, 160

Mamillary process, 164

Mammillothalamic fasciculus, 117

Mammillothalamic tract (of Vicq d'Azyr), 158

Mandible, 11–13, 22, 24, 33, 77
of aged person, 24
alveolar part of, 24
angle of, 8, 12, 22, 24, 76, 79
base of, 24
body of, BP22, 11–13, 22, 24, 36, 50
buccinator crest of, 81
condylar process of, 22, 24
head of, 13
condyle of, BP17, 12, 14
coronoid process of, BP17, 13–14, 22, 24, 49
head of, 24
mandibular foramen of, 24
mandibular notch of, 13
mental foramen of, 11, 13, 24
mental protuberance of, 8, 11, 24
mental spines of, 24
mental tubercle of, 11, 24

Mandible (Continued)
mylohyoid groove of, 24
mylohyoid line of, 24
neck of, 24, 49
oblique line of, 13, 24, 81
opening of, BP24
pterygoid fovea of, 24
ramus of, BP24, 11–13, 22, 24, 36, 68
retromolar fossa of, 24
sublingual fossa of, 24
submandibular fossa of, 24

Mandibular foramen, 24, 69

Mandibular fossa, BP29, 13, 17, 21, 25

Mandibular nerve, 9, 19–20, 25, 59–60, 66, 82, 97–98, 115, 132–133, 136, 142, 144–146
anterior division of, 59
auricular branches of, 133
meningeal branch of, 19–20, 59, 97, 133
motor root of, 59
parotid branches of, 133
posterior division of, 59
sensory root of, 59
superficial temporal branches of, 133

Mandibular nodes, 85

Mandibular notch, BP24, 13, 22, 24

Manubriosternal joint, 193

Manubriosternal junction, 247

Manubriosternal synchondrosis, 408

Manubrium, 245–246, 408
of sternum, 32–34, 36, 77, 192, 196, 204

Marginal artery, T5.2, 294–295, 380
left, 222
right, 222–223

Marginal sulcus, 117

Masseter muscle, T2.6, 32, 36, 49, 53, 55, 60, 68
deep part of, 55
insertion of, 55
superficial part of, 55

Masseteric artery, 55–58, 60, 83

Masseteric fascia, 31

Masseteric nerve, 55–57, 59–60, 82
nerve to, 133

Mast cell, BP6

Mastication, muscles involved in, T2.1, 55–56

Mastoid cells, BP34, 12, 14, 49

Mastoid angle, 18

Mastoid antrum, BP27, 107

Mastoid canaliculus, 17, 19

Mastoid cells, BP27, 64, 107

Mastoid emissary vein, 10, 111
in mastoid foramen, 19

Mastoid fontanelle, 21

Mastoid foramen, 17, 19–20, 23

Mastoid nodes, 85

Mastoid process, BP29, BP24, 12–13, 17, 22–23, 32, 36–37, 69–70, 182

Maturation, BP91

Mature follicle, BP95, BP92

Maxilla, BP17

Maxillary artery, 25, 41, 47, 55–60, 63, 82–83, 107, 112, 142, 144–145, 147, 149
posterior lateral nasal branch of, 57
proximal, 58

Maxillary bone, 11, 13, 15, 17, 44–45, 49
alveolar process of, BP22, 11, 13, 15, 23, 44, 50
anterior nasal spine of, 11, 13, 15, 42, 44–45
frontal process of, 11, 13, 42, 44, 94
incisive canal of, 15, 44–45
incisive fossa of, 17
infraorbital foramen of, 11, 13
infratemporal surface of, 13
intermaxillary suture of, 17
nasal crest of, 45
nasal surface of, 15
of newborn, 21, 52
orbital surface of, 11

Maxillary bone (Continued)
palatine process of, BP29, 15, 17, 23, 43–45, 50, 67, 73
tuberosity of, 13, 23
zygomatic process of, 11, 17

Maxillary nerve, 9, 20, 46, 59–61, 63–64, 66, 82, 97–98, 115, 132–133, 142, 144–146
meningeal branch of, 97, 133
nasal branch of anterior superior alveolar branch of, 48
posterior superior lateral nasal branch of, 48
zygomaticofacial branch of, 133
zygomaticotemporal branch of, 133

Maxillary ostium, 64

Maxillary sinus, BP22, 12, 14, 49–51, 62, 64, 96
alveolar recess of, BP22
growth of, 52
imaging of, BP32
infraorbital recess of, BP22
opening of, BP22, 43–44, 50–51
postsynaptic fibers to, 62
recesses of, 50
transverse section of, 49
wall of, 63
zygomatic recess of, BP22

Maxillary vein, 84, 99

McBurney's point, 281

McGregor's line, BP19

Media, of arterial wall, BP16

Medial, as term of relationship, 1

Medial circumflex femoral vein, BP107

Medial eminence, 125

Medial ligament, of ankle, 518

Medial plantar vein, BP107

Median aperture, 117, 120, 125, 128

Median fissure, anterior, BP43

Median lobe, BP97

Median nerve, T7.1, 404, 419–421, 423, 425, 436–438, 441, 444, 450, 452, 455, 462–466
articular branch of, 466
branches of, 455–456
common palmar digital branch of, 463
communicating branch of, 456
palmar branch of, 404, 406, 436–437, 449, 456, 462, 466
palmar digital branches of, 404
proper, 462–463
recurrent branch of, T7.1, 456, 463

Median nuclei, 122

Median raphe, of levator ani muscle, 341

Median sulcus, posterior, BP43, 125

Mediastinal lymph nodes, 7, 245

Mediastinal nodes
anterior, pathway to, 190
posterior, 242

Mediastinal pleura, 200, 216

Mediastinum
anterior, lung area for, 205
cross section of, 220
anterior, 200
lateral view
left, 235
right, 234
of testis, 369, 372

Medulla oblongata, BP35, BP41, 20, 49, 62, 117, 125, 135, 145–146, 173, 306, 321
in foramen magnum, 19
imaging of, 160

Medullary artery, segmental, 176

Medullary lamina
external, 122
internal, 122

Medullary vein, anteromedian, 155

Medullary velum
inferior, 117, 125
superior, 117, 124–125

Meiosis, BP91

- Meissner's corpuscle**, BP1
- Meissner's plexus**, BP54. *See also* Submucosal (Meissner's) plexus
- Melanocyte**, BP1
- Membranous labyrinth**, 108–109
- Membranous (Scarpa's) fascia**, BP88
- Membranous septum**, 225–229
atrioventricular part of, 220, 224–229
interventricular part of, 220, 225–229
- Membranous urethra**, BP93, BP89, 367
- Mendelian inheritance**, BP91
- Meningeal artery**, 112
accessory, 19–20, 57, 60, 112
anterior, 99
dorsal, 148
middle, T2.3, 20, 25, 56–60, 82–83, 107, 111–113, 115, 142, 147–149
accessory branch of, 107
branches of, 113
frontal (anterior) and parietal (posterior) branches of, 112
left, 147
posterior, 20
in mastoid foramen, 19
- Meningeal vein, middle**, 20, 111, 113
- Meningeal vessels**
anterior, groove for, 18
middle, 19
groove for, 18
grooves for branches of, 15–16
posterior, groove for, 18
- Meninges**, 20, 111, 113
arteries to, 147
- Meningohypophyseal trunk**, 148
tentorial branch of, 148
- Meniscomfemoral ligament, posterior**, 499–500
- Meniscus**, BP114, BP5, 445
articulating surfaces of, BP114
lateral, 498–500, 502
medial, T8.1, 498–499
- Menstrual cycle**, BP92
- Mental foramen**, 11, 13, 24
- Mental nerve**, 9, 59, 66, 82, 133
- Mental protuberance**, 8, 11, 24
- Mental region**, 2
- Mental spine, superior**, 69
- Mental tubercle**, 24
- Mental vein**, 84
- Mentalis muscle**, BP20, T2.6, 31, 55, 134
- Meridional fibers**, 101
- Mesencephalic nucleus, of trigeminal nerve**, 133, 146
- Mesencephalic vein**
lateral, 155
posterior, 155, 157
- Mesenteric artery**
inferior, 4, 271, 295, 311, 313, 316–317, 380, 382–383, 392
superior, T5.2, BP57, 4, 185, 233, 271, 279–280, 291–295, 297, 303–304, 311, 313, 316–317, 324, 327, 331, 392
- Mesenteric ganglion**
celiac, 269
inferior, 172, 300, 305, 320, 391–392, 396–399
superior, 172, 269, 300, 303, 305, 320–321, 391–392, 396, 398–399
- Mesenteric nodes**
inferior, 266, 268
superior, BP82, 268
- Mesenteric plexus, inferior**, 392
- Mesenteric vein**
inferior, 241, 271, 288, 298–299, 381
superior, 241, 278–279, 294, 296–299, 318, 330
- Mesentericoparietal recess**, 271
- Mesentery**, 185, 271, 279, 308
root of, 288, 316, 344, 348
- Mesoappendix**, BP62, 280, 304
- Mesocolic taenia**, 280, 283
- Mesocolon**
sigmoid, 373
transverse, 270–271, 273–274, 278, 283, 297
attachment of, 275
- Mesometrium**, 355
- Mesonephric (Gartner's) duct**
caudal, residua of, 371
cranial, 371
- Mesonephric tubules**, 371
caudal, 371
cranial, 371
vestigial, 372
- Mesonephric (wolffian) duct**, 368, 371
- Mesosalpinx**, 346, 355
laminae of, 357
- Mesovarium**, 353, 355
laminae of, 357
- Metacarpal arteries**
dorsal, 459
palmar, BP101, 424, 455
- Metacarpal bones**, BP102, BP104, BP4, 442–446, 448, 454
fifth, BP105, 434–435, 438, 447
first, 435, 438, 447, 452, 457
fourth, 105–106
second, 105–106, 435
third, 105–106, 443, 447
- Metacarpal ligaments**
deep transverse, BP106, 448, 455
dorsal, BP102
palmar, BP102, 448
superficial transverse, 406, 449
- Metacarpal veins**
dorsal, 406, 458
palmar, BP99
- Metacarpophalangeal ligaments**, 448
- Metacarpophalangeal (MP) joint**, BP102, 448
- Metaphyseal bone**, BP114, BP5
- Metaphysis, nutrient branches to**, 460–461
- Metatarsal arteries, dorsal**, BP110, BP115, 512, 521–522, 527
anterior perforating branches to, 526
- Metatarsal bones**, BP117, BP4, 515–516, 519, 527
fifth, 509–510, 528
tuberosity of, 526–528
first, 509, 518, 528
tuberosity of, 520
- Metatarsal ligaments**
deep transverse, 519, 527
dorsal, 518, 527
plantar, 527
transverse, superficial, 523
- Metatarsal veins, dorsal**, 473
- Metatarsophalangeal (MTP) joint**, 519
first, T8.1
- Metopic suture**. *See* Frontal (metopic) suture
- Midbrain, imaging of**, 160
- Midcarpal joint**, 443, 445
- Middle colic nodes**, BP82
- Middle sacral node**. *See* Promontorial nodes
- Midline groove**, 71
- Midpalmar space**, 450–451, 453
- Minimus muscle**, T8.1, 486
- Minute fasciculi**, 449
- Mitochondria**, 11–12
- Mitral cell**, 130
- Mitral heart valve**. *See* Atrioventricular valve, left
- Modiolus**, 31
- Molar teeth**, 73–74
growth of, 52
- Monocytes**, BP15, BP6
- Mons pubis**, 358
- Morison's pouch**. *See* Hepatorenal recess (Morison's pouch)
- Motor (autonomic) nerve**, BP1
- Motor nucleus**, 133
of trigeminal nerve, 146
- Mucosa**
of ileum, 279
of intestine, 308
of jejunum, 279
- Mucous glands**, 71
innervation of, 173
- Müllerian duct**, 371. *See also* Paramesonephric (Müllerian) duct
- Müller's muscle**. *See* Tarsal (Müller's) muscle, superior
- Multifidus lumborum muscle**, 182
- Multifidus muscle**, T3.2, 185
- Multifidus thoracis muscle**, 182
- Muscles**, BP8. *See also specific muscles*
of arm
anterior views of, 421
posterior views of, 422
of back
deep layer, 182
intermediate layers, 181
superficial layers, 180
contracted, BP8
of dorsum of foot, 521
of eye, T2.1
of face, facial expression, T2.1, 31, 68
anterior view of, BP20
of facial expression, T2.1, 31, 68
fascicles of, BP8
fiber of, BP8
of forearm
anterior, T7.1
attachments of, 439–440
deep layer, 435, 438
extensors of wrist and digits, 431
flexors of digits, 433
flexors of wrist, 432
intermediate layer, 437
posterior, T7.1
rotators of radius, 430
superficial layer, 434, 436
of hip, 484–485
hypothenar, BP105, 447, 449–450, 453, 467
intercostal, BP56, 188, 204, 221, 245–247, 258
lumbical, T8.5, T7.4, 105–106, 450–455, 466–467, 524–525, 527
of mastication, T2.1, 55–56
of neck
anterior view of, 32
infrahyoid and suprahyoid, 35
lateral view of, 36
scalenus and prevertebral, 37
of pharynx
lateral view of, 81
medial view of, 78
partially opened posterior view of, 75
relaxed, BP8
of sole of foot
second layer, 525–526
table, 32–33
- Muscular artery**, 103–104
- Muscular branches**. *See* Sural branches
- Muscular system**, T3.1, T6.1, T4.1, BP8, T5.1
- Muscular vein**, 103
- Muscularis mucosae**, 308, 375
of anal canal, 375–376
of rectum, 376
- Musculocutaneous nerve**, 419–421, 423, 425, 438, 462–466
anterior branch of, 465
articular branch of, 465
posterior branch of, 465
terminal part of, 404

Musculophrenic arteries, 195–196, 204, 215, 258
Musculophrenic vein, 195–196, 259
Musculus uvulae, T2.1, T2.9, 67
Myelin sheath, BP11
Myenteric (Auerbach's) plexus, 308
Mylohyoid artery, 57
 nerve to, 69
Mylohyoid groove, 24
Mylohyoid line, 24
Mylohyoid muscle, BP22, T2.6, 32, 34–36, 38, 41, 50, 53, 59, 68–70, 77–78, 81
 nerve to, 56, 59, 68–69, 82, 133
Mylohyoid nerve, 25, 57
Myofibril, BP8
Myofilaments, BP8
Myometrium, of uterus, 379

N

Nail bed, 460–461
Nail body, 461
Nail fold
Nail matrix, 460–461
Nail root, 460–461
Nares, 8
 anterior, 8
Nasal artery
 external, 10, 42, 57, 83, 99, 149
 lateral, 42
Nasal bone, BP17, 8, 11–13, 15, 42, 44–45, 50
 of newborn, 21, 52
Nasal cartilage, accessory, 42
Nasal cavity, BP26, BP22, BP44, 52, 95
 arteries of, 47
 autonomic innervation of, 62
 bones of, 52
 floor of, 43
 lateral wall of, 43–44, 46
 medial wall of, 45
 nerves of, 46, 48
 postsynaptic fibers to, 62
Nasal concha
 inferior, BP22, 11–12, 15, 43–44, 49, 51, 79, 95
 ethmoidal process of, 44
 growth of, 52
 middle, BP22, 11, 15, 43–44, 51, 95
 growth of, 52
 superior, 43–44
Nasal concha turbinate
 inferior, 50
 middle, 50
Nasal meatus
 highest, lower border of, 52
 inferior, BP22, 43, 50, 95
 middle, BP22, 50
 atrium of, 43
 opening into, 51
 superior, 43, 52
 lower branch of, 52
Nasal nerve
 external, 42
 posterior, 144
Nasal region, 2
Nasal retinal arteriole
 inferior, 103
 superior, 103
Nasal retinal venule
 inferior, 103
 superior, 103
Nasal septal cartilage, 42, 45, 49
 lateral process of, 42, 44–45
Nasal septum, BP22, 12, 23, 46–48, 50, 77, 79
 growth of, 52
 schematic hinge of, 47–48
Nasal slit, 20

Nasal spine
 anterior, BP17, 11, 13, 15, 42, 45
 posterior, 17
Nasal turbinates, BP44
Nasal vein, external, 10, 84
Nasal vestibule, 43–45, 49
Nasalis muscle, BP21, T2.6, 31, 134
 alar part of, BP20, 31, 42
 transverse part of, BP20, 31, 42
Nasion, BP17, 11
Nasociliary nerve, BP26, 61, 97–98, 132–133, 142–143
Nasofrontal vein, 10, 84, 99
Nasolabial lymph nodes, 85
Nasolacrimal canal, opening of, 44
Nasolacrimal duct, 95
 opening of, 43, 95
Nasolacrimal foramen, of newborn, 52
Nasopalatine nerve, 46, 48, 62–63, 66
 groove for, 45
 in incisive fossa, 19
Nasopalatine vessels, groove for, 45
Nasopharyngeal adenoids, 34–35
 imaging of, 160
Nasopharynx, BP44, BP28, 77, 79, 105, 115
 airway to, 43
Navicular bones, 515–516, 518, 527, 535
 tuberosity of, 519, 522, 527
Navicular fossa, 349, 367
Neck, 8–160
 autonomic nerves in, 141
 bony framework of, 22
 cutaneous nerves of, 9, 38
 fascial layers of, 33
 lymph vessels and nodes of, 85
 muscles of
 anterior view of, 32
 infrahyoid and suprahyoid, 35
 lateral view of, 36
 nerves of, 39–40, 82
 posterior triangle of, 194
 of scapula, 192
 superficial veins of, 38
 surface anatomy of, 8
 triangle of, 184
 posterior, 180
 vessels of, 39–40
Nephron, BP77
Nerve fiber bundles, BP12
Nerve fibers, 109
Nerves. *See also specific nerves*
 of abdominal wall
 anterior, 260
 posterior, 269
 of back, 183
 of buttocks, 493
 of cranial base, 64
 of deep face, 63
 of esophagus, 243
 of external genitalia
 female, 395
 male, 391
 of head, 82
 regions, 82
 of hip, 493
 of larynx, 92
 of nasal cavity, 46, 48
 of neck, 39–40
 regions, 39–40, 82
 of orbit, 97
 of perineum
 female, 395
 male, 393
Nervous system, T6.2, T3.1, T5.2, T4.1
 general organization of, 6
Nervus spinosus, 60

Neural foramen. *See* Intervertebral foramen
Neuroendocrine G cell, BP60
Neurofilaments, BP11
Neuroforamina; *See* Intervertebral (neural) foramen
Neurons, BP11
Neurotubules, BP11
Neurovascular compartment, 425
Neurovascular sheath, 347. *See also* Hypogastric (neurovascular) sheath
Neutrophils, BP15
Newborn, skull of, 21
Nipple, 187–188, 333
Node of Cloquet/Rosenmüller, 268
Node of Ranvier, BP12
Nose, 42
 ala of, 8
 innervation of, 173
 transverse section of, 49
Nostril, 8
Nuchal ligament, BP19, 29, 161
Nuchal line
 inferior, 17, 23
 superior, 17, 23, 180
Nucleus ambiguus, 127–128, 136–138
Nucleus pulposus, 28, 164, 168
Nutrient artery, of femur, 495
Nutrient foramen, of femur, 479

O

Obex, 125
Oblique cord, 429
Oblique fibers, 497
Oblique fissure, of lungs, 204
 left, 205
 right, 205
Oblique line, 24, 90
Oblique muscle
 external, BP58, BP109, T5.3, 85–86, 249, 252–258, 260–263, 265, 312, 330
 abdominal, BP47, 180–181, 183, 185, 187–188, 194, 197, 333, 359, 362–363
 aponeurosis of, BP58, 253–255, 260, 262, 264, 312
 aponeurotic part, 252
 muscular part of, 252
 inferior, T2.5, 96, 98, 132
 tendon of, 98
 internal, BP86, BP109, T5.3, 253–258, 260, 262–263, 265
 aponeurosis of, 254–255, 260
 internal abdominal, BP47, 180–181, 185, 194
 in lumbar triangle (of Petit), 180
 tendon of origin of, 185
 superior, BP26, T2.8, 96–98
Oblique popliteal ligament, 499, 501
Obliquus capitis inferior muscle, T3.2, 181–182, 184
Obliquus capitis superior muscle, T3.2, 181–182, 184
Obturator anastomotic, 267
Obturator artery, BP98, BP108, 266, 317, 346–347, 380, 382, 384–385, 392, 400, 477, 495, 503
 accessory, 380, 384
 acetabular branch of, 477, 495
 anterior branch, 477
 posterior branch, 477
Obturator canal, 338–340, 342, 346–347, 350, 384, 491
Obturator crest, 338, 476
Obturator externus muscle, T8.5, 401, 480–481, 483, 491, 530
Obturator fascia, 339–340, 342, 346, 353, 360, 384, 393
 over obturator internus muscle, 350

- Obturator foramen**, 250, 334, 476, 478, 534
radiograph of, 335
- Obturator groove**, 476
- Obturator internus fascia**, 347, 374
- Obturator internus muscle**, T8.5, BP109, T6.3, 256, 265, 339–343, 350, 352–353, 365, 374, 380, 384, 393, 395, 400–401, 480–481, 485, 489, 492–494, 534
nerve to, 487, 489, 492–493
sciatic bursa of, 494
- Obturator internus tendon**, BP109, 341, 343
- Obturator membrane**, 338, 353, 477
- Obturator nerve**, T8.2, 256, 264, 269, 382, 392, 400, 486–488, 496, 529–530
accessory, 269, 487–488
adductor hiatus, 530
anterior branch of, 491, 530
articular branch of, 530
cutaneous branch of, 473–474, 491, 530
posterior branch of, 491, 530
- Obturator node**, 388
- Obturator vein**, 267, 298, 381, 400
- Obturator vessels**, 256
accessory, 262, 264
right, BP98
- Occipital artery**, 10, 41, 76, 83–84, 112, 147, 149, 184
descending branch of, 41, 184
groove for, 17
mastoid branch of, 112, 147
medial, 153
meningeal branch of, 10
sternocleidomastoid branch of, 41
- Occipital bone**, BP17, 13–18, 29, 169–170
basilar part of, 15, 17–18, 29, 37, 43–45, 67, 72, 75, 78–79
clivus of, 18
condylar canal and fossa of, 17
condyle of, 18
foramen magnum of, 15, 17
groove
for inferior petrosal sinus, 15, 18
for occipital sinus, 18
hypoglossal canal of, 15, 17
jugular foramen of, 15
jugular process of, 37
of newborn, 21
nuchal line of
inferior, 17
superior, 17
occipital crest of
external, 17
internal, 18
occipital protuberance of
external, 15, 17
internal, 18
pharyngeal tubercle of, 17, 77
posterior meningeal vessels of, groove for, 18
superior sagittal sinus of, groove for, 18
transverse sinus of, groove for, 15, 18
- Occipital condyle**, BP29, 15, 17, 23, 37, 139
lateral mass for, superior articular surface of, 26
superior articular surface for, 26
- Occipital crest**
external, 17, 23
internal, 18
- Occipital nerve**
greater, 9, 140, 183–184
lesser, 9, 39–40, 140, 183–184
third, 9, 183–184
- Occipital nodes**, 85
- Occipital pole, of cerebrum**, 116, 118
- Occipital (posterior) horn**, 120
- Occipital protuberance**
external, 13–15, 17, 23, 161
internal, 18
- Occipital region**, 3
- Occipital sinus**, 114
groove for, 18
- Occipital sulcus, transverse**, 116
- Occipital vein**, 10, 84
internal, 157
- Occipitofrontalis muscle**
frontal belly of, T2.4, 31, 42, 98, 134
occipital belly of, 31, 134, 184
- Occipitomastoid suture**, 23
- Occipitotemporal gyrus**
lateral, 117–118
medial, 117–118
- Occipitotemporal sulcus**, 117–118
- Oculomotor nerve (CN III)**, T2.2, BP40, 60, 96–98, 115, 124, 127–128, 142, 155
distribution of, 129
inferior branch of, BP26, 97, 132
innervation of, 173
schema of, 132
superior branch of, BP26, 97, 132
in superior orbital fissure, 20
- Oculomotor nucleus**, 127–128, 132
- Odontoid process, of C2**, BP35
- Olecranon fossa**, 410, 426–427
- Olfactory bulb**, BP22, 46, 50, 118, 130
contralateral, 130
- Olfactory bulb cells**, 130
- Olfactory cells**, 130
- Olfactory mucosa**, 130
distribution of, 46
- Olfactory nerve (CN I)**, T2.2, 20, 46, 48
distribution of, 129
schema of, 130
- Olfactory nerve fibers**, 130
- Olfactory nucleus, anterior**, 130
- Olfactory stria**
lateral, 130
medial, 130
- Olfactory sulcus**, 118
- Olfactory tract**, 46, 117–118, 124, 130
- Olfactory tract nucleus, lateral**, 130
- Olfactory trigone**, 130
- Olfactory tubercle**, 130
- Oligodendrocyte, cell body of**, BP12
- Olivary complex, inferior**, 128
- Olive**, 124
- Omental bursa**, 274, 324
cross section of, 274
stomach reflected, 273
superior recess of, 284, 324
- Omental (epiploic) appendices**, 272, 283
- Omental foramen**, 273–274, 276, 285, 324
- Omental taenia**, 280, 283
- Omental veins**, 241
- Omentum**
greater, 270, 272, 283, 285, 331
lesser, 285, 324
anterior layer of, 287–288, 301
posterior layer of, 301
right free margin of, 278
window cut in, 285
- Omothyoid muscle**, T2.7, 33, 35, 38, 69, 194, 204, 409, 413, 416, 419
inferior belly of, 8, 35–36, 39, 139–140
phantom, 41
superior belly of, 32, 35–36, 38, 139–140
- Oogenesis**, BP91
- Oogonium**, BP91
- Operculum**
frontal, 116
parietal, 116
temporal, 116
- Ophthalmic artery**, T2.2, 20, 57, 64, 99, 143, 147–149, 151, 154
continuation of, 99
in optic canal, BP26
- Ophthalmic nerve**, 9, 59–61, 64, 66, 97–98, 115, 132, 142–146
frontal branch of, 20
lacrimal branch of, 20
nasociliary branch of, 20
tentorial (recurrent meningeal) branch of, 97, 133
- Ophthalmic vein**
inferior, 99, 104
superior, BP26, 20, 84, 99, 104, 115
- Opponens digiti minimi muscle**, T7.5, 452, 455, 467
- Opponens pollicis muscle**, T7.5, 452, 455–456, 466
- Optic canal**, 11, 15, 20
- Optic chiasm**, BP22, BP30, 50, 115, 117–118, 124, 131, 148, 151–152, 156–158
imaging of, 160
- Optic disc**, BP26, 103
- Optic nerve (CN II)**, BP22, 20, 50, 64, 96–98, 100, 103, 115, 117–118, 143, 154–155
distribution of, 129
internal sheath of, vessels of, 104
left, 148
meningeal sheath of, 97, 100, 104
in optic canal, BP26
right, 148
schema of, 131
- Optic nerve tract, imaging of**, BP32
- Optic radiation**, 131
- Optic tract**, 50, 118–119, 123–124, 131, 150, 155
- Ora serrata**, 100, 102–103
- Oral cavity**, BP22, BP44, BP9, 45, 50, 77
afferent innervation of, BP25, 66
floor of, 69
inspection of, 65
roof of, 67
- Oral region**, 2
arteries of, 83
veins of, 84
- Orbicularis oculi muscle**, T2.7, BP21, 31, 134
orbital part of, 20–21, 31
palpebral part of, 20–21, 31, 94
- Orbicularis oris muscle**, 20–21, 31, 42, 55, 68, 134
- Orbit**, T2.1, 51
anterior view of, 98
arteries of, 99
fasciae of, BP26
growth of, 52
medial wall of, BP22, 50
nerves of, 97
right, frontal and slightly lateral view of, 11
superior view of, 98
surface of, 11
veins of, 99
- Orbital fat**, BP22
- Orbital fat body**, BP26
- Orbital fissure**
inferior, BP26, BP17, 11, 13, 23
superior, BP26, BP17, 11–12, 20
- Orbital gyri**, 118
- Orbital muscles**, BP22
- Orbital plate, of newborn**, 21
- Orbital process, of palatine bone**, 11
- Orbital region**, 2
- Orbital septum**, 94
- Orbital sulcus**, 118
- Oropharynx**, BP44, 33, 72, 77, 79, 237
- Orthotonic stomach**, BP60
- Osseous cochlea**, 109
- Osseous spiral lamina**, 108–109
- Osteoblasts, active**, BP7
- Osteocytes**, BP7
- Osteoid**, BP7
- Ostium, of auditory tube**, BP44

Otic capsule, 109
Otic ganglion, 25, 56, 59–60, 107, 133–134, 136, 142, 144–146, 173
 schema of, 145
Ova, BP95
Ovarian artery, 382, 394, 397. *See also* Testicular artery
 uterine, 386
Ovarian cycle, BP92
Ovarian hormone, BP92
Ovarian plexus, 394, 397
Ovarian vein, 267, 382. *See also* Testicular vein
Ovarian vessels, 316, 344, 347, 386
 tubal branches of, 386
Ovaries, BP95, T6.2, BP10, 316, 344–346, 353, 355, 371, 382, 394, 397
 blood vessels, BP95
 corpus albicans of, 355
 corpus luteum of, 355
 follicle (graafian), 355
 infant, BP95
 left, 356
 ligaments of, 344, 356, 371
 proper, 345–346, 353–355
 suspensory, 344–347, 355–357, 371, 382
 right, 356–357
Ovum, BP95, 91–92
 stages of, BP95

P

Pacinian corpuscle, BP1
Pain, referred visceral, sites of, BP13
Palate
 growth of, 52
 innervation of, 173
 postsynaptic fibers to, 62
 uvula of, 65, 72, 75, 79
Palatine aponeurosis, 67, 78
Palatine artery
 ascending, 57, 72, 83
 tonsillar branch of, 72
 descending, 63–64, 83
 greater, 47, 57, 63–64, 67
 lesser, 47, 57, 63–64, 67, 72
 tonsillar branch of, 72
Palatine bone, 15, 17, 44
 horizontal plate of, BP29, 11, 17, 23, 43–45, 67, 73
 nasal crest of, 45
 nasal spine of, posterior, 17, 44–45
 of newborn, 21, 52
 orbital process of, 11, 44
 palatine foramen
 greater, 17, 45
 lesser, 17, 45
 perpendicular plate of, 11, 44–45
 pyramidal process of, 17, 21, 23
 sphenoidal process of, 44
Palatine fold, transverse, 67
Palatine foramen
 greater, 19, 44, 47, 67, 73
 lesser, 19, 44, 47, 67, 73
Palatine gland, 67, 72, 77
Palatine nerve, 46, 144
 descending, 144
 greater, 46, 48, 62–64, 67, 82, 133, 142, 144
 in greater palatine foramen, 19
 posterior inferior lateral nasal branch of, 46, 48, 142
 lesser, 46, 48, 62–64, 67, 82, 133, 142, 144
 in lesser palatine foramen, 19
Palatine process, 15, 23
Palatine raphe, 67
Palatine tonsil, 65, 67–68, 71–72, 77, 79
Palatine vein, 84
 external, 84

Palatine vessels
 greater, 19
 lesser, 19
Palatoglossal arch, 65, 71–72
Palatoglossus muscle, T2.7, 67, 70–72, 137
Palatomaxillary suture, 17
Palatopharyngeal arch, 65, 71–72, 79
Palatopharyngeal ridge, 78
Palatopharyngeus muscle, T2.7, 67, 70–72, 75, 78, 80, 137
Palm, 443
Palmar aponeurosis, 406, 432, 436, 444, 449–450, 453
Palmar arch, 4
 carpal, 455
 deep, BP101, BP99, 424, 455
 superficial, BP101, BP99, 424, 452, 456, 463
Palmar digital veins, 5
Palmar ligament, 448, 451, 454, 460–461
Palmar longus muscle, 438
Palmar plate, BP106
Palmar region, 2
Palmar venous arches, 5
Palmaris brevis muscle, T7.5, 449, 467
Palmaris longus muscle, T7.5, 432, 436, 439, 441, 466
Palmaris longus tendon, 402, 436–437, 441, 444, 449–450, 452
Palpebral arterial arches
 inferior, 99
 superior, 99
Palpebral artery
 lateral, 99
 inferior, 99
 superior, 99
 medial, 99
 inferior, 99
 superior, 99
Palpebral conjunctiva, BP26, 94
 inferior, 94
 superior, 94
Palpebral ligament
 lateral, BP26
 medial, BP26, 94
Pampiniform (venous) plexus, T6.2, BP98, 259, 369
Pancreas, BP38, BP56, T5.1, BP9, 137, 173, 185, 274, 276, 323–324, 329
 autonomic innervation of, 310
 body of, 273, 276, 288
 head of, 273, 276, 278–279, 287, 327
 arteries of, 293
 as site of referred visceral pain, BP13
 innervation to, 172
 lymph vessels and nodes of, BP80
 in situ, 288
Pancreatic arteries, 291
 dorsal, 290–291, 294
 great, 291
 inferior, 291, 293–294
Pancreatic duct, BP62, BP87, BP67, 287–288
 accessory (of Santorini), 279, 288
 sphincter of, 287
 variations in, 67–68
 of Wirsung, 279
Pancreatic islets, BP10
Pancreatic pain, areas of referred pain in, 310
Pancreatic tail, BP87, 273, 289, 291
Pancreatic veins, 296, 298
 great, 296
Pancreaticoduodenal arteries
 anterior
 inferior, 291, 293, 303
 superior, 273, 290–291, 293–294, 303
 inferior, 291, 293–295, 304
 posterior

Pancreaticoduodenal arteries (*Continued*)
 inferior, 291, 293, 303
 superior, 290–291, 293, 303
Pancreaticoduodenal vein
 anterior
 inferior, 296, 298
 superior, 296, 299
 posterior
 inferior, 296, 298
 superior, 296, 299
Papilla, 74
 keratinized tip of, 71
Papillary muscle, 220, 248
 inferior, 224–225, 227
 anterior, 229
 left, 228
 right, 228
 septal, 227–228
 superoposterior, 224–225, 227
 anterior, 229
 left, 228
 right, 228
Parabrachial nucleus, 146
Paracentral artery, 152–153
Paracentral lobule, 117
Paracentral sulcus, 117
Paracolic gutter
 left, 272, 344, 348
 right, 272, 280, 344, 348
Paracolic nodes, BP82
Paradidymis, 371
Paraduodenal fossa, 271
Parahippocampal gyrus, 117–119, 130
Parallel fibers, 497
Paramesonephric (Müllerian) duct, 371
Paranasal sinuses, 21–22
 bones of, 52
 changes with age, 52
 coronal section of, 50
 innervation of, 173
 sagittal view of, 51
 transverse section of, 50
Pararectal fossa, 344, 346, 348, 374
Pararenal fat, 185
Paraspinal muscle, BP38
Pasternal lymph nodes, 190–191
Parasympathetic fibers, 309
 of autonomic reflex pathways, 307
 of kidneys and upper ureters, 321
 of lower ureter, 399
 postsynaptic, BP41
 presynaptic, BP41
 in reproductive organs, 397
 male, 398
 of tracheobronchial tree, 214
 of urinary bladder, 399
Parasympathetic nervous system, BP40
 general topography, BP40
 schema of, 173
Parathyroid gland, BP10, 76, 89
 inferior, 88–89
 superior, 88–89
Paratracheal lymph nodes
 left, 212
 right, 212
Paratracheal nodes, 242
Paraumbilical veins, T5.2, 299
 in round ligament of liver, 259
 tributaries of, 259
Paraurethral glands, primordium of, 371
Paraurethral (Skene's) ducts, BP90
 openings of, 358
Paraurethral (Skene's) gland, 371
Paravertebral anastomoses, 177
Paravesical endopelvic fascia, 352
Paravesical fossa, 346
Parental generation, BP91

- Parietal artery**, 10
anterior, 152–153
posterior, 152–153
- Parietal bone**, BP17, 11, 13–18
mastoid angle of, 18
middle meningeal vessels of, groove for, 18
of newborn, 21
tuber (eminence) of, 21
- Parietal emissary vein**, 10, 111
- Parietal foramen**, 16
- Parietal lobule, superior**, 116
- Parietal nodes, posterior**, 242
- Parietal peritoneum**, BP84, 264, 272, 274–275, 309, 324, 332, 344, 348
- Parietal pleura**
cervical, 202–203, 234
costal part of, 199–200, 204, 210, 215, 235
left border, 203
right border, 203
costal pleura, 234
diaphragmatic part of, BP44, 199–200, 204, 210, 215, 236
mediastinal part of, BP44, 199–200, 204, 210, 215–216, 219–220, 235–236
- Parietal region**, 3
- Parietal vein**, 10
- Parietooccipital sulcus**, 116–117
- Paroöphoron**, 371
- Parotid duct (of Stensen)**, 53–56, 83
- Parotid fascia**, 31
- Parotid gland**, BP41, T2.1, BP40, 32, 36, 38, 49, 53–54, 60, 68, 79, 105, 136, 145, 173
accessory, 53
innervation to, 172
- Parotid lymph node, superficial**, 85
- Parotid space**, 41
- Parous introitus**, BP96
- Pars distalis**, 158
- Pars flaccida**, 106
- Pars interarticularis**, 164
- Pars intermedia**, 158
- Pars tensa**, BP27, 106
- Pars tuberalis**, 158
- Parturition, neuropathways in**, 396
- Passavant's ridge**, 78
- Patella**, BP4, 113–114, 471, 482–484, 491, 497–498, 502, 510–511
articular surface of, BP114
- Patellar anastomosis**, BP110, BP108, 490–491
- Patellar ligament**, T8.1, 471, 482–484, 491, 497–499, 502, 505, 510–512
insertion of, BP111
- Patellar nerve plexus**, 473
- Patellar retinaculum**
lateral, 482, 484, 497–498, 510–512
medial, 482–483, 491, 497–499, 511–512
- Patellar tendon**, BP113
- Pecten**, 375
- Pecten pubis**, 250, 334, 338, 476
- Pectinate (dentate) line**, 375
- Pectinate ligament**, 101
- Pectinate muscles**, 224
- Pectineal fascia**, 254
- Pectineal ligament (Cooper's)**, 253–254, 256, 262, 264–265
- Pectineus muscle**, T8.5, BP109, 400–401, 480–483, 490–491, 495–496, 529
- Pectoral fasciae**, 188, 416
- Pectoral girdle**, BP4
- Pectoral lymph nodes**, 190–191
- Pectoral nerve**
lateral, 194, 416, 419–420
medial, 194, 419–420
- Pectoral region**
anterior, 2
lateral, 3
- Pectoralis major muscle**, T4.3, T7.5, 32, 36, 38, 187–188, 191, 194–195, 197, 204, 220–221, 244–249, 252–254, 402, 408–409, 414, 416, 419, 421, 423, 425
abdominal part of, 413
clavicular head of, 187, 413
pectoral fasciae and, 188
sternal head, 187
sternocostal head of, 413
- Pectoralis major tendon**, 423, 425
- Pectoralis minor muscle**, T4.3, T7.5, 194–195, 204, 221, 245–247, 409, 414, 416, 419, 423
- Pectoralis minor tendon**, 414, 417, 419, 421
- Pedicle**, BP33, 163, 167–168
of C5, BP34
cervical, 27
of L1, BP36
of L3, BP37
of L4, 165
lumbar, 164
thoracic, 163
- Pedis artery**
dorsal, BP110, 503, 521–522
medial tarsal branch of, BP110
dorsalis, BP115
- Pelvic brim**, 353
sacral part of, 166
- Pelvic cavity**, BP3
contrast medium in, 357
- Pelvic diaphragm**, 349
fascia of, 378
female, 339–341
inferior fascia of, 359–360, 364, 374, 376, 387
levator ani muscle of, 345, 364, 373–374, 378
male, 342–343
superior fascia of, 347, 350, 359, 374, 376
- Pelvic fascia, tendinous arch of**, 347, 352
- Pelvic floor**, T6.1
- Pelvic foramina, anterior**, 342
- Pelvic girdle**, BP4
- Pelvic outlet, measurements of**, 336
- Pelvic plexus**
inferior, 391–392, 394, 396–399
superior, 391
uterovaginal, 397
- Pelvic sacral foramina**. *See* Sacral foramina, anterior
- Pelvic splanchnic nerves**, BP41, 487
S2–4, BP40
- Pelvic surface**, 166
- Pelvic viscera**
female, 345–346
nerves of, 394
male, 349
nerves of, 392
- Pelvis**, 333–401
arcus tendineus fasciae, 354
bones and ligaments of, 337–338
bony framework of, 334
electronic bonus plates in, BP97, BP92, BP93, BP96, 88–89
female
arteries of, 382–383
contents, 344
diaphragm, 339–341
fasciae of, BP88
lymph nodes of, 388
lymph vessels of, 388
measurements of, 336
radiograph of, 335
relationships, 356
urethra, 401
vagina, 401
veins of, 382
viscera, 345
greater, 338
lesser, 338
- Pelvis (Continued)**
ligaments of, 357
linea terminalis of, 347–348
male
arteries of, BP98, 385
bladder-prostate gland junction, 400
contents, 348
diaphragm, 342–343
fasciae of, BP88
lymph nodes of, 390
lymph vessels of, 390
measurements of, 336
radiograph of, 335
veins of, BP98, 385
viscera of, 349
sagittal T2-weighted MRIs in, 379
surface anatomy of, 333
- Penile fascia, superficial**, BP88
- Penile urethra**, BP93
- Penis**, 364, 379
arteries of, T6.2
body (shaft) of, 333, 370
bulb of, 364–365, 367
artery of, 365, 387
cavernous nerves of, 392, 398
corpora cavernosa of, 364–365
crus of, 352, 363–364, 367
Dartos fascia of, 349, 362–364, 369
deep arteries of, 363, 365, 367, 387
deep (Buck's) fascia of, BP88, BP98, 252–254, 324, 349, 362–365, 369, 377–378, 387
dorsal arteries of, 363, 365, 383, 387
deep, BP98, 387
left, 385
dorsal nerves of, 363, 365, 387, 391–393, 395, 398, 487, 493
dorsal veins of
deep, BP98, 342–343, 349, 363, 365, 383, 385
superficial, BP98, 252, 259, 333, 363, 385
fundiform ligament of, 262
glans, 333, 349, 364, 370
corona, 364
neck, 364
ligament of
fundiform, 349
suspensory, 349
raphe of, 370
skin of, 362–364, 369
superficial fascia of, 253–254
suspensory ligament of, BP58, 253
- Perforated substance**
anterior, 118, 124, 130
posterior, 118
- Perforating artery**
first, 492
fourth, 492
second, 492
third, 492
- Perforating branches**, 491
anterior, 527
posterior, 527
- Perforating cutaneous nerves**, 393, 395
- Perforating radiate artery**, 314
- Perforating veins**, BP99, 405–406, 513
anterior, 198
- Perianal skin**, 376
sweat glands in, 375
- Perianal space**, 374–375, 378
- Perianal tissues**, 370
- Pericallosal artery**, 152–153
- Pericardiophrenic artery**, 196, 210, 215–216, 220, 234–235, 258
left, 199–200
right, 199

Pericardiophrenic vein, 196, 210, 215–216, 220, 234–235
left, 200
right, 200

Pericardiophrenic vessels, 219

Pericardial cavity, BP3, 220

Pericardial reflection, 218, 224–225

Pericardial sac, 219
oblique, 219

Pericardial sinus
oblique, 219–220, 248
transverse, BP51, 216, 219, 224–225

Pericardium, T4.2, BP44, T4.1, 33, 200, 210, 215–216, 219, 236
bare area of, 202
central tendon covered by, 200
diaphragmatic part of, 219
sternocostal part of, 219

Perichoroidal space, 100–101

Pericranium, 113

Pericyte, BP6

Periglandular plexus, 308

Periglomerular cell, 130

Perimysium, BP8

Perineal artery, BP98, 353, 361, 385–387
transverse, 387

Perineal body, BP88, T6.1, 343, 349–351, 359–360, 364–366, 373, 377, 387

Perineal compartment, superficial, 378

Perineal fascia, BP88
deep, BP90, 349, 352–353, 359–360, 363–365, 373, 377–378
transverse, 366
superficial, BP90, 349, 352–353, 359–365, 373, 377–378, 386–387, 393

Perineal ligament, transverse, 340, 342, 347, 349–350, 359, 365, 387

Perineal membrane, BP88, BP98, BP90, 256, 265, 324, 339, 343, 345, 349–350, 352–353, 359–361, 363–366, 373, 377, 386–387, 393, 395, 399
anterior thickening of, 350, 365

Perineal muscles
deep, 373
fascia of, 340
transverse
deep, 339, 345, 349, 360–361, 365–366, 378, 385–386
superficial, T6.4, 339, 359–361, 363–365, 373, 377–378, 386–387
superior, 387

Perineal nerves, 361, 374, 392–393, 395, 487, 493
deep, 393
branches of, 361, 393, 395
superficial, 393
branches of, 361, 393, 395

Perineal pouch
deep, with endopelvic fascia, BP88
superficial, BP88

Perineal raphe, 358, 370

Perineal region, 2

Perineal spaces
deep, 361
male, 365
perineal, 386
superficial, 349, 353, 359–361, 363–364, 386–387

Perineal vein, 387

Perineopelvic spaces, 378

Perineum, 333–401
arteries of, 386
deep, 360
electronic bonus plates in, BP88, BP95, BP98, BP94, 90–91
female, 345, 358, 360
fasciae of, BP88

Perineum (Continued)
lymph nodes of, 389
lymph vessels of, 389
nerves of, 395
superficial dissection, 359
interdigitating fibers of, 341
male, 348, 362–363
arteries of, 387
fasciae of, BP88
nerves of, 393
veins of, 387
surface anatomy of, 333
veins of, 386

Perineurium, BP12

Periodontium, 74

Periorbita, BP26

Periosteal vessels, BP7

Periosteum, BP7

Peripheral arteries, BP41

Peripheral nerve, features of, BP12

Peripheral nervous system, 6

Periportal arteriole, 286

Periportal bile ductule, 286

Periportal space, 286

Perirenal fat, 185

Perisinusoidal spaces, 286

Peritoneal cavity, 271–272

Peritoneal reflection, 373, 375

Peritoneal vessels, testicular vessels in, 348

Peritoneum, BP88, BP59, T6.1, 185, 239, 255–256, 263, 283, 304, 311, 323, 345, 359, 374, 382, 394
inferior extent of, 397–398
paravesical pouch, 353
parietal, BP84, 264, 272, 274–275, 309, 324, 332, 348–350, 352
uterus through overlying, 356
visceral, 274

Perivascular fibrous (Glisson's) capsule, 285

Permanent teeth, 73–74

Peroneal nerve, deep, BP116

Peroneal retinaculum. *See* Fibular retinaculum, superior

Peroneus brevis muscle, BP116. *See also* Fibularis brevis muscle

Peroneus brevis tendon, BP116

Peroneus longus muscle. *See* Fibularis longus muscle

Peroneus longus tendon, 116–117

Peroneus tertius tendon, BP116

Perpendicular plate, 11, 15

Pes anserinus, 480, 482–483, 497–498

Petit, lumbar triangle of, 161, 180
internal oblique muscle in, 180

Petropharyngeus muscle, 75

Petrosal artery, superficial, descending branch of, 107

Petrosal nerve
deep, 46, 62, 134, 136, 142, 144
greater, BP27, 19–20, 60, 62, 64, 97, 136, 142, 144
in foramen lacerum, 19
groove for, 18, 110
hiatus for, 20
from intermediate nerve, 134
lesser, 19–20, 59–60, 97, 106, 133–134, 136, 145
groove for, 18
hiatus for, 20

Petrosal sinus
inferior, 20, 114–115
groove for, 15, 18
superior, 110, 114–115
groove for, 15, 18

Petrosal vein, 115, 155

Petrosquamous fissure, 21

Petrotympanic fissure, 17, 19

Peyer's patches (aggregate lymphoid nodules), 279

Phalangeal bones, 448
foot, BP4, 516
distal, 515, 519
middle, 515, 519
proximal, 515, 519
hand
distal, BP4, 446–448, 460–461, 466
middle, BP102, BP4, 446–448, 460–461
proximal, BP102, BP105, BP4, BP106, 446–448

Pharyngeal aponeurosis, 75, 78, 80

Pharyngeal artery, 57, 63
ascending, 41, 57, 64, 76, 83, 107, 147, 149
meningeal branch of, 20, 112, 147
pharyngeal branch of, 72
tonsillar branch of, 72

Pharyngeal constrictor muscle, 77, 92
inferior, T2.5, 36, 75, 78, 80–81, 88–89, 92, 137, 237–238
cricopharyngeal part of, 80, 237–238
middle, T2.6, 36, 70, 72, 75, 78, 80–81, 88, 137
superior, T2.8, 56–57, 67–68, 70, 72, 75, 78, 80–81, 83, 88, 137
glossopharyngeal part of, 70, 78

Pharyngeal nerve, 144

Pharyngeal nervous plexus, 76

Pharyngeal plexus, 136–137, 141–142

Pharyngeal raphe, 43, 72, 75, 77–78, 88, 238

Pharyngeal recess, 43, 49, 72, 79

Pharyngeal region
arteries of, 83
veins of, 84

Pharyngeal tonsil, 43, 45, 72, 75, 77, 79

Pharyngeal tubercle, 17, 29, 45, 72, 75, 78

Pharyngobasilar fascia, 67, 70, 75, 78, 81, 86

Pharyngoepiglottic fold, 75, 80
fibers to, 78

Pharyngoesophageal constriction, 237

Pharyngoesophageal junction, 80

Pharynx, BP44, BP9
afferent innervation of, BP25, 66
lymph vessels and nodes of, 86
lymphatic drainage of, 86
medial view of, 77
muscles of
lateral view of, 81
medial view of, 78
partially opened posterior view of, 75
opened posterior view of, 79
posterior view of, 76, 88
posterior wall of, 65
zone of sparse muscle fibers, 80–81, 88

Philtrum, 8, 65

Phrenic arteries, inferior, 236, 240, 266, 273, 290, 300–301, 322–323, 392
left, 243

Phrenic ganglion, 201

Phrenic lymph nodes, inferior, pathway to, 190

Phrenic nerve, T4.1, 33, 37–40, 82–83, 87, 141, 195–196, 199, 204, 210, 215–216, 220, 230, 234–236, 299, 417, 419–420
anterior branch of, 201
left, 199–201, 219, 235
inferior, 201
pericardial branch of, 199
phrenicoabdominal branches of, 199
right, 199–200, 219, 246, 322
inferior, 201

Phrenic nodes, superior, 242

Phrenic plexus, 300–301, 322

Phrenic veins, inferior, 267, 311
left, 241

Phrenocolic ligament, 273

- Phrenicoesophageal ligament**, 239
- Pia mater**, 111, 113, 177
overlying spinal cord, 174
- Pial plexus**, 176
arterial, 177
peripheral branches from, 177
venous, 178
- PICA**. See Posterior inferior cerebellar artery
- Pigment cells**, 131
- Pillar (rod) cells**, 109
- Pilosebaceous unit**, BP2
- Pineal body**, 121
- Pineal gland**, BP10, 117, 122, 124–125
- Pineal recess**, 117
- Piriform cortex**, 130
- Piriform recess**, 79, 91
- Piriformis muscle**, T8.1, T8.5, T6.3, 265, 339–342, 384, 392–395, 480, 485, 489, 492–494
bursa of, 494
left, 385
nerve to, 487, 489
tendon of, 494
- Pisiform bone**, BP102, 432, 436–438, 442–450, 452, 455
- Pisohamate ligament**, BP102, 444
- Pisometacarpal ligament**, BP102, 444
- Pituitary gland**, BP10, 115, 117–118, 158
anterior lobe (adenohypophysis) of, BP30, 151, 158
cleft of, 158
imaging of, 160
posterior lobe (neurohypophysis) of, BP30, 151, 158
- Pituitary stalk, imaging of**, 160
- Pivot joint**, BP5
- Plane joint**, BP5
- Plantar aponeurosis**, T8.1, 520, 523, 525, 535
digital slips of, 523
lateral band of, 523
origin of, BP116
- Plantar arch**, BP110, BP115, 503, 527
deep, 522
perforating branches from, posterior, 512
- Plantar arterial arch, deep**, 526
- Plantar artery**
deep, BP110, 503, 512, 521, 527
lateral, BP116, 509, 513, 520, 525–527
deep branch of, BP117
plantar metatarsal branch of, 524
superficial branch of, BP117
medial, BP116, 509, 513, 520, 523, 525–526
deep branch of, BP117, 525–526
superficial branch of, 523–526
- Plantar calcaneocuboid ligament**, 519
- Plantar calcaneonavicular ligament**, 518, 527
- Plantar digital arteries**, 521–523, 527
common, BP115, 525, 527
- Plantar digital nerves**
common, 525, 532
proper, 532
- Plantar fascia**
lateral, 523
medial, 523
- Plantar interosseous muscle**, T8.5, 526
- Plantar ligaments**, 519, 527
of foot, 519
long, 518, 527
short, 518
- Plantar metatarsal arteries**, BP115, 524, 526–527
perforating branches from, 522
- Plantar metatarsal ligaments**, 519
- Plantar nerve**
lateral, 115–117, 513, 520, 525–526, 531–532
deep branch of, 525–526
plantar cutaneous branches of, 474
- Plantar nerve (Continued)**
plantar digital branches of, 524
proper plantar digital branches of, 525–526
superficial branch of, 525–526
medial, BP116, 509, 513, 520, 523, 525–526, 531–532
deep branches of, BP117, 526
plantar cutaneous branches of, 474
plantar digital branches of, 524
proper plantar digital branches of, 525–526
superficial branches of, 526
- Plantar vein**
lateral, BP107
medial, BP107
- Plantar venous arch**, BP107
- Plantarflexion, of lower limbs movements**, 472
- Plantaris muscle**, T8.5, 481, 484–485, 492, 497, 501–502, 506–509, 513, 531–532
- Plantaris tendon**, BP116, BP111, 485, 507–508, 513–514
- Plasma, composition of**, BP15
- Plasma cell**, BP6
- Plasma proteins**, BP15
- Platelets**, BP15
- Platysma muscle**, T2.7, 20–21, 31–33, 38, 134
- Pleura**, 177, 205
visceral, BP49
- Pleural cavity**, BP3, 220
costodiaphragmatic recess of, 202–203, 234–235
costomediastinal recess of
left, 200
right, 200
- Pleural reflection**, T4.1, 202–204
- Plica semilunaris**, 94–95
- Polar body**, BP91
- Pons**, BP35, 117, 124–125, 145–146
imaging of, BP32, 160
- Pontine arteries**, 150–151, 154
basilar and, 152
- Pontine vein**
lateral, 155
transverse, 155
- Pontomesencephalic vein, anterior**, 155
- Pontoreticulospinal tract**, BP43
- Popliteal artery**, BP110, BP108, 4, 492, 503, 507–509, 513
of knee, in deep popliteal region, T8.2
pulses at, 4
- Popliteal fossa**, 3, 471
- Popliteal ligament**
arcuate, 499, 501–502
oblique, 502
- Popliteal vein**, BP107, 5, 475, 492, 507–508, 513
- Popliteal vessels**, 485
- Popliteus muscle**, T8.5, BP111, 481, 485, 501–502, 506, 508–509, 513–514, 532
nerve to, 532
- Popliteus tendon**, 499–500
origin of, 498
- Porta hepatis**, 284
- Portacaval anastomoses**, 299
- Portal arteriole**, 286
- Portal space, limiting plate of**, 286
- Portal triad**, 285, 288, 329
- Portal vein**, BP57, 329
branch of, 286
- Postanal space**
deep, 378
superficial, 378
- Postcentral gyrus**, 116
- Postcentral sulcus**, 116
- Posterior chamber**
of eye, 94, 100, 102–103
of eyeball, 101
- Posterior cord**, 414
- Posterior cutaneous branches**, 183
- Posterior horn**. See Occipital (posterior) horn
- Posterior inferior cerebellar artery (PICA)**, 176
- Posterior plane**, 1
- Posterior ramus**, 177
- Posterior root**, 144
rootlets of, 174
- Posterior root ganglion**, 197, 399. See also Spinal sensory (posterior root) ganglion
- Posterior sacral foramen**, BP86
- Posterior tibial artery, pulses at**, 4
- Posterior tibial veins**, BP107
- Postganglionic fibers**
of lower ureter, 399
in reproductive organs, 397
male, 398
of urinary bladder, 399
- Postnatal circulation**, 233
- Postsynaptic cell**, BP11
- Postsynaptic membrane**, BP11
- Poupart's ligament**, 249, 252–254, 262–265, 333, 340. See also Inguinal ligament (Poupart's)
- Praoortic nodes**, 390
- Precentral gyrus**, 116
- Precentral sulcus**, 116
- Prechiasmatic groove**, 18
- Preculminate vein**, 155
- Precuneal artery**, 153
- Precuneus**, 117
- Prefrontal artery**, 150, 152
- Preganglionic fibers**
of lower ureter, 399
in reproductive organs, 397
male, 398
of urinary bladder, 399
- Premolar teeth**, 73–74
- Prenatal circulation**, 233
- Preoccipital notch**, 116
- Prepatellar bursa, subcutaneous**, 502
- Prepontine cistern**, 120
- Prepuce**, 349, 370
- Preputial gland**, 364
- Prepyloric vein**, 296, 298
- Presacral fascia**, 347, 378
- Presacral space**, 347, 378
- Presternal region**, 2
- Presymphyseal node**, 390
- Presynaptic membrane**, BP11
- Pretracheal fascia**, 77
visceral layer of, 208
- Pretracheal lymph nodes**, 87
- Pretracheal space**, 34
- Pretracheal (visceral) fascia**, 33
- Prevertebral anastomoses**, 177
- Prevertebral fascia**, 68, 77
- Prevertebral soft tissue**, BP34
- Prevesical fascia, umbilical**, 350
- Prevesical plexus**, 390
- Prevesical space**, 349–350. See also Retropubic (prevesical) space
fat in, 343
of Retzius, 378
- Primary oocyte**, BP91
- Primary ova**, BP95
- Primary spermatocytes**, BP93, BP91
- Primordial follicles**, BP95
- Princeps pollicis artery**, BP101, 424
- Procerus muscle**, T2.7, 20–21, 31, 42, 134
- Processus vaginalis**, 368
- Profunda brachii artery**, BP100, 417, 419, 422–425
- Profunda femoris artery**, BP108, 483, 490–491, 495–496, 503
perforating branches of, BP108

- Profunda femoris vein**, 496
- Profundus flexor tendons**, 453
- Progesterone**, BP92
- Promontorial nodes**, 319, 388, 390
- Promontory**, BP28, 105
sacral, 166, 334
measurements of, 336
- Pronator quadratus muscle**, T7.5, 430, 438–439, 441, 453, 455, 466
- Pronator teres muscle**, T7.5, 409, 421, 423, 430, 435–441, 463, 466
- Prostate**, BP97, T6.1, BP109, 379
- Prostate gland**, BP41, 173, 256, 349, 352, 365–367, 371, 373, 385, 400
apex of, 366
base of, 366
branch to, BP98
capsule of, BP97, 352
central zone of, 366
innervation to, 172
lymphatic drainage from, 390
peripheral zone of, 366
primordium of, 371
transitional zone of, 366
- Prostatic ducts**, 366–367
- Prostatic lobules**, BP93
- Prostatic plexus**, T6.2, 320, 392, 398–399
- Prostatic sinuses**, BP97, 366–367
- Prostatic urethra**, BP97, BP93, BP89, 352, 367, 400
- Prostatic utricle**, BP97, 366–367, 371
- Prostatic venous plexus**, 385
- Proximal, as term of relationship**, 1
- Proximal interphalangeal (PIP) joint**, BP102, 402, 447–448
- Proximal palmar crease**, 402
- Psoas minor tendon**, 265
- Psoas muscle**, BP38, 400, 486, 495
major, T5.3, 85–86, 185, 201, 262, 265–267, 269, 278, 311–312, 344, 347–348, 382, 482, 486, 488–489, 529
nerves to, 487
minor, T5.3, 265, 344, 348, 486
nerves to, 487
muscular branches to, 488
- Psoas tendon**, 400
- Pterion**, T2.1, 13
- Pterygoid artery**, 57
lateral, 57
medial, 57
- Pterygoid canal**
artery of, 57, 63–64, 107, 148
nerve (vidian) of, 46, 48, 61–62, 64, 107, 133–134, 136, 142, 144, 146
- Pterygoid fossa**, 23
- Pterygoid fovea**, 24
- Pterygoid hamulus**, BP29, 13, 15, 23, 56, 59, 67, 72, 78
of newborn, 52
- Pterygoid muscle**
lateral, 24–25, 49, 55–59
inferior head of, BP24, 34, 60
nerve to, 82, 133
superior head of, BP24, 60
medial, T2.6, 49, 56–57, 59–60, 67–68, 75, 82
nerves to, 133
- Pterygoid nerve, medial**, 56
- Pterygoid plate**
lateral, BP29, 22–23, 49, 56, 81
medial, BP29, 23, 56, 67, 72, 78
hamulus of, 22
right, 64
- Pterygoid plexus**, 60, 84, 99
deep facial vein from, 10
- Pterygoid process**, 17, 23
hamulus of, 13, 17, 23
lateral plate of, 13, 15, 17, 23
- Pterygoid process** (*Continued*)
medial plate of, 15, 17, 23
of newborn, 52
pterygoid fossa of, 17
scaphoid fossa of, 17
- Pterygoid venous plexus**, T2.2
- Pterygomandibular raphe**, 22, 56–57, 67–68, 72, 78, 81
- Pterygomaxillary fissure**, 13
- Pterygopalatine fossa**, 13, 23, 51
- Pterygopalatine ganglion**, BP40, 46, 48, 61–64, 82, 132–134, 136, 142, 144, 146, 173
branches to, 61
pharyngeal branch of, 46
posterior and superior lateral nasal branches of, 142
posterior superior lateral nasal branches from, 46
schema of, 144
- Pubic arch**, 250, 334
measurements of, 336
- Pubic bone**, 324, 339–340, 351, 365, 379, 401
- Pubic branch**, 347
- Pubic crest**, 262
- Pubic ligament, inferior (arcuate)**, 334, 340–343, 347, 349–350, 359, 365
- Pubic ramus**, T6.1
inferior, 250, 334, 341, 345, 352, 476–478, 486, 534
superior, 250, 334, 337–338, 345, 349, 364, 476–478, 486, 489, 534
radiograph of, 335
- Pubic symphysis**, T6.1, 249–250, 262, 265, 333–334, 337, 340–341, 343, 345, 347, 349–350, 356, 359, 361–362, 365, 384, 401
measurements of, 336
radiograph of, 335
superior portion of, 400
- Pubic tubercle**, BP58, 249–250, 253–254, 262, 265, 333–334, 337–338, 343, 359, 364, 476, 482–483, 534
- Pubic vein**, 267
- Pubis**, 476
body of, 400
radiograph of, 335
superior ramus of, 342, 483
symphyseal surface of, 394
- Puboanalis (puborectalis) muscle**, T6.3, 324, 341–343, 373, 377
left, 339
- Pubocervical fascia**
distal portion of, 354
horizontal portion of, 354
- Pubococcygeus muscle**, T6.3, 339–341, 343, 353, 377
- Pubofemoral ligament**, BP109, 477
- Puboprostatic ligament, medial**, 347, 350
- Puborectalis muscle**, 341–343, 373. *See also* Puboanalis (puborectalis) muscle
left, 339
- Pubovesical ligament**
lateral, 347
median, 350
- Pudendal artery**
deep external, 258, 266
external
deep, BP108, 503
superficial, BP108, 258, 266, 503
internal, BP98, 266, 317, 361, 365, 380, 384–387, 400, 489
in pudendal canal (Alcock's), 386
- Pudendal canal (Alcock's)**, 374, 380–381, 387, 393
pudendal artery, internal, 384, 386
pudendal nerve of, 395
internal, 387
pudendal vessels, internal, 387
- Pudendal cleft**, 358
- Pudendal nerve**, T6.2, 169, 269, 306, 361, 374, 392–400, 487, 489, 492–493
internal, 401
nerve to, 489
in pudendal canal, 395
- Pudendal vein**
external, BP107, 259
superficial, 473
internal, 298, 381, 385, 400
- Pudendal vessels**
external, 385
deep, 383, 490
superficial, 252, 254, 267, 383
internal, 374, 401
superficial, 490
- Pudendum**, 358
- Pulmonary arteries**, BP50, T4.2, BP49, T4.1
left, 56–57, 205, 210, 216–217, 225, 233, 235, 244, 247
right, 56–57, 205, 210, 216, 218, 224–225, 233–234, 244, 247–248
- Pulmonary heart valve**, 224, 229
anterior semilunar cusp of, 224, 226
left semilunar cusp of, 224, 226
right semilunar cusp of, 224, 226
- Pulmonary (intrapulmonary) lymph nodes**, 212
- Pulmonary ligament**, 205, 212, 234–235
- Pulmonary plexus**, 39–40, 137, 214, 243
anterior, 213
posterior, 213
- Pulmonary trunk**, BP57, 210, 216–217, 219, 221, 224, 228–229, 233, 244, 247
outflow to, 228
- Pulmonary veins**, 217
inferior
left, 205, 218, 220
right, 205, 218, 220, 224
left, 210, 218–219, 225, 228, 233, 235
right, BP50, BP57, 210, 219, 225, 229, 233–234, 244
septum of, BP49
superior
left, 205, 216, 218, 225
right, 205, 216, 218, 224, 228
- Pulses**, 4
brachial artery, 4
carotid artery, 4
dorsalis pedis artery, 4
facial artery, 4
femoral artery, 4
popliteal artery, 4
posterior tibial artery, 4
radial artery, 4
ulnar artery, 4
- Pulvinar**, 118, 121–122, 124–125
left, 155
right, 155
of thalamus, 150, 154, 156
- Pupil**, 94
- Purkinje fibers**
of left bundle, 229
of right bundle, 229
- Pyloric canal**, 329
- Pyloric glands**, BP60
- Pyloric orifice**, 279
- Pyloric zone**, 277
- Pylorus**, 276, 278, 329
- Pyramidal eminence**, BP27, 106–107
- Pyramidal process**, 17, 21, 23
- Pyramidal tract**. *See* Lateral corticospinal tract
- Pyramidalis muscle**, T5.3, 254, 262
- Pyramids**, 124
decussation of, 124–125

Q

- Quadrangular space**, 417
- Quadrate ligament**, 428
- Quadrate tubercle**, 479
- Quadratus femoris muscle**, T8.5, 395, 480–481, 483, 485, 491–494
 - nerve to, 487, 489, 493
- Quadratus lumborum fascia**, 185
- Quadratus lumborum muscle**, T5.3, 182, 185, 201, 265–267, 269, 311–312, 344, 348, 486, 488
- Quadratus plantae muscle**, T8.5, 116–117, 525–526, 532
- Quadratus plantae nerve**, 532
- Quadriceps femoris muscle**, 480, 529
- Quadriceps femoris tendon**, 471, 482, 491, 497–498, 502, 510, 512
- Quadriceps muscle**. *See* Rectus femoris muscle
- Quadriceps tendon**, BP113
- Quadrigeminal cistern**, 120
 - imaging of, BP32

R

- Radial artery**, BP100, T7.2, BP101, 4, 423–424, 435–438, 441, 444, 450, 452, 455–457, 459–460
 - dorsal carpal branch of, 457
 - palmar carpal branch of, 438, 455
 - pulses at, 4
 - superficial palmar branch of, BP101, 424, 437–438, 444, 450, 455–456
- Radial collateral ligament**, BP102, 428
- Radial fossa**, 409, 426
- Radial groove**, 410
- Radial longitudinal crease**, 402
- Radial metaphyseal arcuate ligament, dorsal**, 445
- Radial nerve**, T7.1, 404, 414, 417, 419–420, 422, 425, 437–438, 462–466, 468–469
 - communicating branches of, 458
 - deep branch of, 437, 441, 463, 469
 - dorsal digital branches of, 457, 462, 469
 - dorsal digital nerves from, 404
 - inferior lateral brachial cutaneous nerve from, 404
 - lateral branch of, 457
 - medial branch of, 457
 - posterior brachial cutaneous nerve from, 404
 - superficial branch of, 404, 406, 434, 437, 441, 458–459, 462–464, 469
- Radial recurrent artery**, 100–101, 423, 437–438
- Radial styloid process**, 442
- Radial tubercle, dorsal**, 442
- Radial tuberosity**, 421, 427
- Radial vein**, BP99, 5
- Radialis indicis artery**, BP101, 424
- Radiate ligament, of head of rib**, 193
- Radiate sternocostal ligament**, 193, 408
- Radicular artery**
 - anterior, 176–177
 - posterior, 177
- Radicular vein**, 178
 - segmental
 - anterior, 178
 - posterior, 178
- Radiocarpal joint**, 443, 445
 - articular disc of, 443, 445
- Radiocarpal ligament**
 - dorsal, BP102, 445
 - palmar, BP102
- Radiolunate ligament**
 - long, 444
 - palmar, 444
 - short, 444
- Radioscaphocapitate ligament**, 444
- Radioulnar joint, distal**, 445
- Radioulnar ligament**
 - dorsal, BP102, 445
 - palmar, BP102
- Radius**, BP102, BP4, T7.1, 426–433, 435, 438–445, 447, 455, 460
 - anterior border of, 429
 - anterior surface of, 429
 - anular ligament of, 428
 - articular surface of, 447
 - head of, 421, 426–427, 429
 - interosseous border of, 429
 - lateral surface of, 429
 - neck of, 426–427, 429
 - posterior border of, 429
 - posterior surface of, 429
 - rotators of, 430
 - styloid process of, 429, 447
 - tuberosity of, 426
- Rami communicantes**, 396, 487
- Rathke's pouch, vestigial remnant of**, 52
- Recombinant chromatids**, BP91
- Rectal artery**
 - inferior, BP98, 295, 380, 384–387
 - middle, BP98, 266, 295, 316, 347, 380, 382, 384–385
 - superior, 266, 295, 300, 305–306, 316, 347, 380, 382, 392
- Rectal canal**, 375
- Rectal fascia**, BP88, 346–347, 359, 366, 373–376, 378
- Rectal nerves, inferior**, T6.2, 361, 392–393, 395–396
- Rectal plexus**, 305, 320, 322, 392, 394
 - external, 381
 - internal, 381
 - perimuscular, 381
 - superior, 392
- Rectal veins**, T6.2
 - inferior, 298–299, 381
 - middle, 267, 298–299, 381
 - superior, T5.2, 298–299, 381
- Rectal venous plexus**, 267
 - external, 298, 376
 - in perianal space, 375
 - internal, 375–376
 - perimuscular, 298, 381
- Rectalis muscle**, 377
- Rectocervical spaces**, 346
- Rectococcygeus muscle**, 265
- Rectoprostatic (Denonvilliers') fascia**, 324, 343, 349, 366, 373
- Rectosigmoid arteries**, 380
- Rectosigmoid junction**, 283, 373, 375–376
- Rectourethral superior muscle**, 343
- Rectouterine fold**, 346
- Rectouterine pouch, of Douglas**, T6.1, 345–346, 355–356, 373
- Rectouterine (sacrouterine) ligament**, 346
- Rectovaginal spaces**, 346–347
- Rectovesical fascia**, 366, 378
- Rectovesical pouch**, 324, 348–349, 373
- Rectovesical space**, 378
- Rectum**, BP88, T6.1, BP109, 173, 265, 272, 283, 311, 324, 339–341, 344–345, 347–350, 356, 359, 366, 373, 379, 382, 394, 401
 - ampulla of, 350
 - arteries of, 380
 - circular muscle of, 376
 - innervation to, 172
 - longitudinal muscle of, 376
 - muscularis mucosae of, 376
 - radiology of, 165
 - in situ
 - female, 373
 - male, 373

- Rectum (Continued)**
 - transverse folds of, 375
 - veins of, 381
- Rectus abdominis muscle**, BP47, BP109, T5.3, 187, 194–195, 197, 249, 253–256, 258, 261–262, 324, 333, 344, 347–349, 359, 379
- Rectus capitis muscle**
 - anterior, T2.7, 37, 49, 86
 - lateral, T2.7, 37
 - posterior
 - major, T3.2, 181–182, 184
 - minor, T3.3, 181–182, 184
- Rectus femoris muscle**, T8.5, BP109, 400–401, 471, 480–482, 484, 490–491, 496, 529.
See also Quadriceps femoris muscle
- Rectus femoris tendon**, 471, 482–483, 498, 511
- Rectus muscle**
 - inferior, 25–26, 96, 98, 132
 - branches to, 97
 - lateral, 25–26, 50, 96–98
 - check ligament of, BP26
 - tendon of, 100
 - medial, BP26, 50, 96–98, 132
 - branches to, 97
 - check ligament of, BP26
 - tendon of, 100
 - superior, BP26, T2.8, 96–98
 - tendon of, 104
- Rectus sheath**, 252–253, 359
 - anterior layer of, BP58, 194, 253–255, 260, 262, 349
 - cross section of, 255
 - posterior layer of, 254–255, 258, 260, 262
- Recurrent artery**
 - of Heubner, 150–153
 - tibial
 - anterior, BP110, BP108, 503, 512
 - posterior, BP110, 503, 509
- Recurrent process**, 130
- Red blood cells**, BP15, BP6
- Red nucleus**, 118, 127–128
- Referred pain, visceral, sites of**, BP13
- Reinforcing fibers**, 287
- Reissner's membrane**. *See* Vestibular (Reissner's) membrane
- Renal artery**, 4, 317, 321, 382, 399
 - left, 266, 292, 305, 323, 392
 - right, 266, 292, 300, 303, 310, 313
 - in situ, 313
 - variations in, BP75
- Renal column (of Bertin)**, 314
- Renal corpuscle, histology of**, BP76
- Renal cortex**, 278, 330
- Renal (Gerota's) fascia**, 185, 318, 323, 331
 - anterior layer of, 318
 - posterior layer of, 318
 - transverse section of, 318
- Renal ganglion**, 320–322, 398–399
- Renal impression**, 284, 289
- Renal plexus**, 320–322, 399
 - left, 392
- Renal segments**, 315
- Renal vein**, 5, 317, 324, 382
 - left, 241, 267, 323, 327
 - right, 241, 267, 310, 313
 - in situ, 313
 - variations in, BP75
- Renal vessels**, 383
- Reproduction, genetics of**, BP91
- Reproductive organs, innervation of**
 - female, 397
 - male, 398
- Reproductive system**, T6.1
 - male, BP93

Respiration

- muscle attachment of, BP46
- muscles of, BP47

Respiratory bronchioles, 48–49

Respiratory diaphragm, BP62, BP56, T4.3, BP47, BP44, T4.1, BP3, T5.3, 196, 204, 210, 213, 215, 217, 221, 234, 236–237, 239–241, 255, 258, 265, 267, 273–274, 276, 284, 289, 311–312, 325, 328, 488

- abdominal surface of, 201
- central tendon of, 201, 265
- costal origin of, slips of, 196
- costal part of, 201
- crura of, 185

- left, 201, 236, 265, 271
- right, 201, 236, 271

dome of

- left, 202–203
- right, 202–203

- esophageal hiatus of, T5.1
- lumbar part of, 201
- sternal part of, 196, 201
- thoracic surface of, 200

Respiratory system, BP44, T4.1

Rete testis, BP93

Reticular fibers, BP6

- in arterial wall, BP16

Reticular nuclei, 122

Retina

- ciliary part of, 100–101
- optic (visual) part of, 100, 102
- structure of, 131

Retinacula cutis, BP1

Retinacular arteries, 495

Retinal artery, 103

- central, 99–100, 103–104

Retinal vein, 103

- central, 100, 103–104

Retrobulbar fat, BP26, 50

Retrocecal recess, 272, 280

Retrodiscal tissue (bilaminar zone), BP24

- inferior layer of, BP24
- upper layer of, BP24

Retromandibular vein, 10, 38–39, 49, 53, 68, 70, 84, 99

- anterior branch, 39
- posterior branch, 39

Retromolar fossa, 24

Retroperitoneal space, 356

Retropharyngeal nodes, 86

Retropharyngeal space, 33–34, 77–78

Retroprostatic fascia, 378

Retropubic (prevesical) space, 324, 347, 349–350

- fat in, 254, 343
- of Retzius, 378

Retropubic venous plexus. *See* Vesical (retropubic) venous plexus

Retrotonsillar vein, superior, 155

Retzius, retropubic space of, 254

Rhinal sulcus, 117–118

Rhomboid major muscle, T3.3, T7.5, 180, 183, 186, 197, 245, 247, 257, 410, 413, 468

Rhomboid minor muscle, T3.3, T7.5, 180, 183, 410, 413, 468

Rhomboid muscle, 246

Ribs, BP4, T4.1, 246–247, 274

- angle of, 192–193
- associated joints and, 193
- body, 192
- costal groove of, 193
- eight, 192, 220
- eleventh, 192
- false, 192
- fifth, 192, 217

Ribs (Continued)

- first, BP34, BP57, 22, 28, 37, 87, 169, 192, 198, 202–203, 215, 234–236, 408, 419–420

- costal cartilage of, 245
- lung groove for, 205

floating, 192

fourth, 192

head of, 192–193

- intraarticular ligament of, 193
- radiate ligament of, 193

left, T4.1

- muscle attachment of, BP46

neck of, 192–193

ninth, 192

posterior of, BP36

radiate ligament of, BP33

second, 34, 188, 192, 408

seventh, 163, 192, 248

sixth, 188, 192

posterior view of, 193

superior articular facet on, BP33

tenth, 192

third, 192, 217

true, 192

tubercle of, 192–193

twelfth, 169, 180, 192, 201, 486

radiology of, 165

Right bundle

- Purkinje fibers of, 229
- subendocardial branches of, 229

Right lateral region, 251

Risorius muscle, T2.7, 20–21, 31

Rod cells. *See* Pillar (rod) cells

Rods, 131

Root ganglion, posterior, 139, 143

Rotation, of lower limbs movements, 472

Rotator cuff muscles, T7.1, 415

Rotatores cervicis muscle, 182

brevis, 182

longus, 182

Rotatores muscle, T3.3

Rotatores thoracis muscle, 182

brevis, 182

longus, 182

Rotter's lymph nodes, 190–191. *See also*

- Interpectoral (Rotter's) lymph nodes

Round ligament, 357

of artery, 382

of liver, 256, 276, 284, 299

of uterine artery, 386

of uterus, BP90, 344–346, 352–354, 356, 359, 371, 382

Round window. *See* Cochlear (round) window

Rubrospinal tract, BP43

Rugae, 277. *See also* Gastric folds (rugae)

Ruptured follicle, BP95, BP92

S

Saccule, 108–109, 135

Sacral arteries

- lateral, BP98, 176, 266, 317, 384–385
- spinal branches of, 176
- median, 266, 293, 295, 317, 347, 380, 384–385

Sacral canal, 166, 342

Sacral cornu, 166

Sacral crest

- intermediate, 166
- lateral, 166
- median, 166, 339

Sacral foramina, BP37

- anterior, 166, 337, 342
- radiograph of, 335
- posterior, 166, 337

Sacral ganglion, 1st, 172

Sacral hiatus, T3.1, 166

Sacral kyphosis, 162

Sacral nerve, perineal branch of, 487, 489

Sacral nodes

- lateral, 268, 388, 390
- middle, 268, 388, 390

Sacral plexus, 169, 321, 392, 397–399, 489

Sacral promontory, BP86, 250, 334, 337–338, 340, 345–346, 348, 394

- measurements of, 336

Sacral region, 3

Sacral spinal nerves

S1, 169

- anterior ramus, 392, 396
- dermatome of, 171
- vertebral body of, 379

S2, dermatome of, 171

S3, dermatome of, 171

S4, dermatome of, 171

S5, 169

dermatome of, 171

Sacral splanchnic nerves, BP39, 172

Sacral sympathetic trunk, 305

Sacral tuberosity, 166

Sacral veins

- lateral, 267
- median, 298, 381, 385

Sacral vessels, median, BP98, 346, 382

Sacrocccygeal ligaments

anterior, 337, 340, 342, 347

lateral, 167, 337–338

posterior, 167, 337–338

Sacrogenital fold, 348, 374. *See also*

- Vesicosacral (sacrogenital) fold

Sacroiliac joint, BP86, 342, 478

measurements of, 336

radiograph of, 335

radiology of, 165

Sacroiliac ligaments

anterior, 337

posterior, 167, 337–338

Sacrospinous ligament, 167, 337–339, 341, 343, 392, 395, 485, 493

Sacrospinous ligament, BP109, 167, 337–339, 341, 343, 360, 377, 384, 392–393, 395, 400, 485, 492–493

Sacrospinous ligament, 346. *See also*

- Rectouterine (sacrospinous) ligament

Sacrum, BP4, 161–162, 166–167, 169–170, 250, 334, 341–342, 379

ala of, radiograph of, 335

apex of, 166

arteries of, 176

articular facet for, 164

auricular surface for, 167, 476

base of, 166

radiology of, 165

Saddle joints, BP5

Sagittal plane, 1

Sagittal sinus

- inferior, 111, 114–115, 155–157
- superior, 111–115, 117, 120, 155–156
- emissary vein to, 20
- groove for, 16, 18
- imaging of, 31–32, 159

Sagittal suture, BP17, 12, 16, 21

Salivary gland, BP9, 53, 68

lingual minor, 65

molar minor, 67

sublingual, 68

submandibular

deep lobe, 68

superficial lobe, 68

Salivatory nucleus

- inferior, 127–128, 136, 145
- superior, 62, 127–128, 134, 144

Salpingopharyngeal fold, 72, 79

- Salpingopharyngeus muscle**, T2.7, 72, 75, 78, 137
- Saphenous nerve**, BP115, BP111, 473, 490–491, 512, 529, 532
branches of, 474
great, 496, 514
infrapatellar branch of, 473, 490–491, 511–512, 529
medial crural cutaneous of, 529
small, 492
- Saphenous opening**, BP58, 253, 259, 359, 362, 473
cribriform fascia and, BP58, 259, 475
falciform margin of, 264
- Saphenous veins**, T8.2
accessory, BP107, 473–474
great, BP107, BP116, BP111, BP58, 252–253, 259, 267, 362, 471, 473–475, 513–514
greater, 116–117, 401
lesser, BP116
small, BP107, 471, 473–475, 507, 513–514
- Sarcolemma**, BP8
- Sarcomere**, BP8
- Sarcoplasm**, BP8
- Sartorius muscle**, T8.5, BP109, 400–401, 471, 480–482, 484–485, 490–491, 496–497, 501, 507, 529
insertion of, 511
- Sartorius tendon**, 482–483, 497–498
insertion of, BP111, 512
- Satellite cell**, BP8
- Scala tympani**, 108–109
- Scala vestibuli**, 109
- Scalene lymph nodes, inferior**, 212
- Scalenus muscle**, 32, 35–37, 417
anterior, BP56, T2.7, 33, 36–40, 46–47, 82–84, 87, 195–196, 199, 204, 210, 215, 221, 234–236, 417–419
innervation of, 420
medius, T2.7, 33, 36–37, 39, 46–47, 82–84, 195, 417
posterior, BP56, T2.7, 33, 36–37, 46–47, 195, 236, 417
- Scalp**, 10, 31
arteries of, T2.2
skin of, 31
superficial arteries and veins of, 10
superficial fascia of, 31
- Scaphocephalic ligament**, 444
- Scaphoid bone**, BP102, T7.1, 442–443, 445–447, 457
articulation with, 429
- Scaphoid fossa**, BP29, 106
- Scapholunate ligament**, 445
- Scaphotrapeziotrapezoid ligament**, 444
- Scapula**, BP4, 186, 197, 217, 245–247, 409, 416–417
acromial angle of, 409–410
acromion of, 192
anastomoses around, 418
anterior view of, 409
body of, 416
coracoid process of, 192, 217, 409–411
glenoid cavity of, 192, 409, 411–412
inferior angle of, 161, 248, 409–410
infraglenoid tubercle, 409–410
infraspinous fossa of, 192
lateral border of, 409–411
medial border of, 161, 409–410
neck of, 192, 409–410
posterior view of, 410
spine of, 161, 180, 183, 192, 203, 217, 410, 413, 415–418, 470
subscapular fossa of, 192
superior angle of, 409–410
superior border of, 409–410, 415
- Scapula (Continued)**
suprascapular notch of, 192
supraspinous fossa of, 192
- Scapular artery**
circumflex, BP23, BP100, T7.2, 417–419, 421, 424
dorsal, BP23, T7.2, 39–40, 179, 418–419
- Scapular ligament, transverse**, 412
inferior, BP23
superior, BP23, 414–415, 417–418
- Scapular nerve**, 419
dorsal, 420, 468
lower, 419
- Scapular notch, superior**, 409–410, 417
- Scapular region**, 3
- Scapulohumeral dissection**, 417
- Scapulothoracic dissection**, 417
- Scarpa's fascia**, BP88, 324, 362. *See also* Membranous (Scarpa's) fascia
- Scarpa's layer**, 359
of superficial fascia, 362–363
- Schwalbe's line**, 101
- Sciatic bursa**
of gluteus maximus muscle, 494
of obturator internus muscle, 494
- Sciatic foramen**
greater, 167, 337–339, 531
lesser, 167, 337–338
- Sciatic nerve**, BP109, 169, 395, 401, 485, 487, 489, 492–494, 496, 531
left, 400
muscular branches of, 492
right, 400
tibial division of, 531
- Sciatic notch**
greater, 250, 334, 476
lesser, 250, 334, 476
- Sclera**, BP26, 94, 100–103
lamina cribrosa of, 100
- Scleral spur**, 100–101
- Scleral venous sinus**, 100–101, 103–104
- Scrotal arteries, posterior**, BP98, 385, 387
- Scrotal branches, posterior**, 395
- Scrotal ligament**, 371
- Scrotal nerves, posterior**, 392–393, 493
- Scrotal veins, anterior**, 259
- Scrotal vessels, anterior**, 385
- Scrotum**, 333, 368–370
Dartos fascia of, BP88, 349, 362, 369, 372, 377, 387
septum of, 349, 369, 372, 377, 387
skin of, 369, 372
superficial fascia of, 253–254
- Sebaceous glands**, 1–2, 94
- Secondary oocyte**, BP91
- Secondary spermatocytes**, BP93, BP91
- Segmental medullary arteries**, T3.1, 176–178
- Sella turcica**, BP34, 14–15, 18, 45, 77
dorsum sellae of, 18
hypophyseal fossa of, 18
hypophysis in, 43
posterior clinoid process of, 18
tuberculum sellae of, 18
- Semicircular canal**
anterior, 64, 108–109
plane of, 110
lateral, 108–110
prominence of, BP27, 105
posterior, 108–109
plane of, 110
- Semicircular duct**
anterior, 108–110
lateral, 108–110
ampulla of, 135
posterior, 108–110
ampulla of, 135
superior, ampulla of, 135
- Semilunar folds**, 72, 283
- Semilunar hiatus**, 51
of newborn, 52
- Semimembranosus bursa**, 497, 502
- Semimembranosus muscle**, T8.1, T8.5, 395, 481, 484–485, 492, 496–497, 501, 506–507, 531
bursa of, 501
- Semimembranosus tendon**, 497, 499, 501–502, 508–509
groove for, 504
- Seminal colliculus**, BP97, 352, 366
- Seminal vesicles**, BP93, 256, 348–349, 366, 371, 373, 385
- Seminiferous epithelium**, BP93
- Seminiferous tubules, convoluted**, BP93, 372
- Semispinalis capitis muscle**, 180–182, 184
- Semispinalis cervicis muscle**, 182, 184
- Semispinalis muscle**, T3.3
- Semispinalis thoracis muscle**, 182
- Semitendinosus muscle**, T8.1, 85–86, 395, 471, 480–481, 485, 492–494, 496–498, 501, 507, 531
tendon of, 497
- Semitendinosus tendon**, 482–483
- Sensory cortex**, 146
- Sensory nerves**, BP1
- Septal papillary muscle**, 224
- Septate hymen**, BP96
- Septomarginal fasciculus**, BP43
- Septomarginal trabecula**, 224, 228–229
- Septum**, 372
bulging, 43
nasal, 12, 23, 45
of scrotum, 387
- Septum pellucidum**, 117, 121–122, 152, 154, 156, 158
posterior veins of, 157
vein of, 156–157
- Serosa (visceral peritoneum)**, BP62, 279, 289
- Serosus glands of von Ebner**, 71
- Serratus anterior fascia**, 416
- Serratus muscle**
anterior, T4.3, T7.5, BP46, 180, 186–188, 197, 221, 245–249, 252–253, 257, 260–261, 333, 402, 409, 413–414, 417, 419
digitations of, 194–195
posterior, T4.3
inferior, T3.3, T4.3, 180–181, 185, 257, 312
superior, T3.3, T4.3, 180–181
- Sertoli cell**, BP93
- Sesamoid bones**, BP4, 443, 446, 515–516, 525–528
foot, 519
- Shoulder**
anteroposterior radiograph of, 411
arthrogram of, 470
computed tomography of, 470
glenohumeral joint of, 412
joint capsule of, 417
magnetic resonance imaging of, 470
muscles of, 413
nerves of, 468
- Sibson's fascia**. *See* Suprapleural membrane (Sibson's fascia)
- Sigmoid arteries**, 266, 293, 295, 305, 316, 380
- Sigmoid colon**, BP65, 173, 270, 272, 283, 344, 346, 348, 356, 373–376, 392, 394
innervation to, 172
as site of referred visceral pain, BP13
- Sigmoid mesocolon**, 272, 283, 294–295, 310, 316, 373
- Sigmoid sinus**, 64, 76, 110, 114–115
groove for, 15, 18
imaging of, BP31, 159
in jugular foramen, 20

- Sigmoid veins**, 298–299, 381
- Sinuatrial (SA) nodal artery**, 229
- Sinuatrial (SA) node**, 41–42, 229
- Sinuses**. *See also specific sinuses*
confluence of, 110, 114–115, 155–156
prostatic, BP97
- Sinusoids**, 285–286
- Skeletal system**, T3.1, T6.1, T4.1, T5.1
axial and appendicular, BP4
- Skene's ducts**, BP90. *See also* Paraurethral (Skene's) ducts
openings of, 358
- Skene's glands**, 371. *See also* Paraurethral (Skene's) gland
primordium of, 371
- Skin**, 33, 113
cross section of, BP1
radiology of, 165
of scalp, 10, 31
- Skin ligaments**, BP1
- Skull**, BP4
anterior view of, 11
base of, 79
lateral view of, 13
midsagittal view of, 15
of newborn, 21
nuchal line of, superior, 181
orientation of labyrinths in, 110
radiographs of
lateral view of, 14
posterior view of, 12
Waters' view of, 12
reconstruction of, BP17
superior nuchal line of, 182
- Small intestine**, BP9, 137, 270, 282, 324
area for, 311
arteries, 294
autonomic innervation of, 304
lymph vessels and nodes of, BP81
mucosa and musculature of, 279
as site of referred visceral pain, BP13
veins of, 297
- Small saphenous veins**, BP107
- Smooth muscle cell**, BP16
- Soft palate**, 43, 45, 65, 72, 77, 79
imaging of, 160
muscles of, 78
- Sole, muscle of**
second layer, 525–526
- Soleus muscle**, BP116, BP111, 85–86, 497, 506–514, 520, 522, 531–532
arch of, 485
into calcaneal tendon, 508
nerve to, 507–508
tendinous arch of, 508–509
- Soleus tendon**, BP116
- Solitary lymphoid nodule**, 279
- Solitary tract, nuclei of**, 127–128, 134, 136–137, 146, 231, 321
- Somatic fibers**, BP41
- Space of Poirier**, BP102
- Space of Retzius**, 350
- Spermatic cord**, 256, 263, 363–364, 400
exiting, external spermatic fascia on, 262
external spermatic fascia over, 387
testicular vessels in, 383
- Spermatic fascia**
external, BP59, 253–254, 260, 262, 349, 362–364, 369, 372
spermatic cord and, 264, 387
testis and, 387
internal, BP59, 254, 369, 372
origin of, 263
- Spermatids**, BP93, BP91
- Spermatogenesis**, BP93, BP91
- Spermatogonium**, BP93, BP91
- Spermatozoa**, BP93, BP91
- Sphenothmoidal recess**, 43–44
- Sphenoid bone**, 11, 13, 15, 17–18, 22, 44–45, 49
anterior clinoid process of, 15, 18
body of, 15, 18, 45
jugum of, 18
prechiasmatic groove of, 18
sella turcica of, 18
carotid groove of, 18
clivus of, 18
crest of, 45
foramen ovale of, 17
foramen spinosum of, 17
greater wing of, BP17, 11, 13–15, 17–18, 21
groove for middle meningeal vessels, 18
infratemporal crest of, 13
lesser wing of, 11–12, 15, 18
of newborn, 21, 52
optic canal of, 15
orbital surface of, 11
pterygoid process of, 17, 23, 44
hamulus of, 13, 15, 17, 23, 44
lateral plate of, 13, 15, 17, 21, 23, 44–45
medial plate of, 15, 17, 21, 23, 44–45
pterygoid fossa of, 17
scaphoid fossa of, 17
sella turcica of, 15, 18
dorsum sellae of, 18
hypophyseal fossa of, 18
posterior clinoid process of, 18
tuberculum sellae of, 18
sphenoidal sinus of, 15, 44–45
spine of, 17, 23
- Sphenoidal emissary foramen (of Vesalius)**, 20
- Sphenoidal fontanelle, of newborn**, 21
- Sphenoidal sinus**, BP26, BP22, BP34, BP44, 14–15, 43, 45, 50–51, 64, 72, 77, 98, 115, 148
imaging of, 160
opening of, 43–44, 51
- Sphenomandibular ligament**, 25, 56–58, 60
- Sphenooccipital synchondrosis**, 77
- Sphenopalatine artery**, 47, 57, 63, 83
posterior lateral nasal branches of, 47, 63
posterior septal branches of, 47, 57
- Sphenopalatine foramen**, 13, 15, 23, 44, 47–48, 57
- Sphenopalatine vessels, in incisive fossa**, 19
- Sphenoparietal sinus**, 114–115
- Spherical recess**, 108
- Sphincter muscle**
external
deep part of, 375
subcutaneous part of, 375
superficial part of, 375
internal, 375
- Sphincter pupillae muscle**, T2.1, T2.8, 101, 132, 143
- Sphincter urethrae**, BP97, 345, 350, 359, 378
muscle, BP90, T6.4, 339, 343, 351–352, 360
- Sphincter urethrovaginalis muscles**, T6.4, 350, 353, 359–361
- Sphincters, female**, 351
- Spinal artery**
anterior, 149–150, 152, 154, 176–177
anastomotic loops to, 176
posterior, 150, 152, 176–177
anastomotic loops of, 176
left, 154, 177
right, 177
segmental medullary branches of, 149
- Spinal branch**, 177
- Spinal canal**, 326
- Spinal cord**, BP38, 6, 62, 169, 245–246
anterior rami and, 169
arteries of
intrinsic distribution of, 177
schema of, 176
central canal of, 120, 125
cross sections, BP43
fiber tracts, BP43
descending tracts in, 214
gray matter of, 174
imaging of, 160
lateral horn of, 174
lumbar part of, 399
upper, BP41
pia mater overlying, 174
principal fiber tracts of, BP43
sacral part of, BP41, 399
sections through, BP43
segments, 321
sulcal (central) branches to, 177
termination of, 170
thoracic part of, BP41, 143–145, 214
thoracolumbar, 306
veins of, 178
white matter of, 174
- Spinal dura mater**, 169, 185
termination of, 170
- Spinal ganglion**, 399
posterior root of, 174, 177, 186
- Spinal meninges**, T3.1
nerve roots and, 174
- Spinal nerve**, 174, 177, 186, 232
anterior ramus of, 174, 261
anterior root of, 174, 303
C8, 169
dorsal ramus of, 177
lateral branch of, 177
medial branch of, 177
L5, posterior ramus of, 167
meningeal branch of, 177
origin of, 175
cross section of, 175
posterior ramus of, 174
T1, 169
- Spinal nerve roots**
anterior root of, 174
posterior root of, 174
S1, 170
S2, 170
S3, 170
S4, 170
S5, 170
vertebrae relation to, 170
- Spinal nerve trunk**, 261, 276
- Spinal nucleus**, 133
- Spinal sensory (posterior root) ganglion**, 303, 306, 309–310, 321
- Spinal tract**, 133, 137
- Spinal vein**
anterior, 155, 178
posterior, 155, 178
- Spinalis cervicis muscle**, 181
- Spinalis muscle**, 181
- Spinalis thoracis muscle**, 181
- Spinocerebellar tract**
anterior, BP43
posterior, BP43
- Spinohypothalamic fibers**, BP43
- Spinomesencephalic fibers**, BP43
- Spinoolivary tract**, BP43
- Spinoreticular fibers**, BP43
- Spinothalamic fibers**, BP43
- Spinous process**, BP38, BP18, 163–164, 167–168
of C2, BP34
of C7, BP35, T3.1, BP34, 181–182
cervical, 27, 29

- Spinous process** (*Continued*)
of L1, 165, 185
of L2, radiology of, 165
of L3, BP37, 164
of L4, BP37
lumbar, 163
of T12, 161, 180–181, 183
thoracic, 163
- Spinous processes**, T3.1
- Spiral ganglion**. *See* Cochlear (spiral) ganglion
- Spiral ganglion of Corti**, 109
- Spiral lamina**
hamulus of, 108
osseous, 108–109
- Spiral ligament**, 109
- Splanchnic nerves**, 305, 396
greater, 172, 391, 396
thoracic, 300–301, 303–304, 309–310, 320, 322
least, 172, 391, 396
lesser, 172, 391, 396
thoracic, 300–301, 303–304, 320–322
lumbar, 172, 306, 320, 322, 391–392, 394, 396–397, 399
fifth, 392
first, 321–322
upper, 398
pelvic, 173, 305–306, 321, 392, 394, 396–399, 489
sacral, 172, 306, 320, 392, 394, 399, 489
sympathetic, T5.2
thoracic, 392
greater, 397–398
least, 398
lesser, 397–398
- Spleen**, BP38, BP87, BP56, T5.2, BP84, BP57, 202–203, 217, 273–274, 285, 289, 323, 326–327, 330
anterior extremity of, 289
area for, 311
inferior border of, 289
posterior extremity of, 289
as site of referred visceral pain, BP13
in situ, 289
superior borders of, 289
- Splenic artery**, 217, 289–291, 293–294, 300–301, 303, 309–310, 329
splenic branches of, 290
- Splenic flexure of colon**, 282
- Splenic notch**, 290
- Splenic plexus**, 301
- Splenic red pulp**, 289
- Splenic trabeculae**, 289
- Splenic vein**, 217, 241, 274, 294, 296–299, 323–324, 326
- Splenic white pulp**, 289
- Splenius capitis muscle**, T3.3, 36, 180, 184
- Splenius cervicis muscle**, T3.3, 180–181, 184
- Splenorenal ligament**, 273, 289
- Spongy urethra**, BP89
bulbous portion of, 352, 367
pendulous portion of, 367
- Squamous suture**, BP17, 21
- Stapedius muscle**, T2.8, 107
nerve to, 134
tendon of, BP27
and tendon of, 106
- Stapes**, 106–107
footplate of, 106
limbs of, 27–28, 105
- Stellate ganglion**, 213, 230–231, 243. *See also* Cervicothoracic (stellate) ganglion
- Sternal angle (of Louis)**, T4.1
- Sternal head, of sternocleidomastoid muscle**, 8
- Sternalis muscle**, 194
- Sternoclavicular joint**, 202, 245, 408
- Sternoclavicular ligament, anterior**, 408
- Sternocleidomastoid muscle**, T2.1, BP47, T2.8, 32–33, 36, 38–39, 41, 53, 68, 86, 138, 140, 180, 184, 187, 194, 204, 408, 413–414, 419
clavicular head of, 8, 32, 36, 187
medial margin of, 87
sternal head of, 8, 32, 36, 187
- Sternocleidomastoid nodes**, 85
- Sternocleidomastoid region**, 3
anterior, 2
- Sternocostal articulations**
anterior view of, 193
left anterolateral view of, 193
right posterolateral view of, 193
- Sternocostal head**. *See* Pectoralis major muscle
- Sternocostal joint**, 408
- Sternocostal triangle**, 196
- Sternohyoid muscle**, T2.8, 32–33, 35–36, 38, 69, 139, 194, 196, 204, 408
- Sternothyroid muscle**, T2.8, 32–33, 35–36, 38, 92, 139–140, 194, 196, 204
- Sternum**, BP44, BP4, 186, 197, 200, 217, 220, 244, 413
angle, 192
body of, 187, 192, 194, 196, 198, 248–250
jugular notch of, 192
manubrium of, 31–34, 34–35, 36, 77, 196, 204
xiphoid process of, 187, 192, 194
- Stomach**, BP87, BP56, T5.1, BP9, 173, 202, 221, 236, 240, 270, 274, 282, 284, 287, 289, 324, 326
air within, 217
arteries of, 290
autonomic innervation of, 301–303
body of, 276
cardiac part of, 237, 239, 276
fundus of, BP57, 237, 239, 276, 328
greater curvature of, 276
innervation to, 172
longitudinal muscle layer of, 278
lymph vessels and nodes of, BP79
mucosa of, 277
oblique muscle layer of, innermost, 239
outer longitudinal muscle layer of, 239
posterior surface of, 273
pyloric part of, 276
as site of referred visceral pain, BP13
in situ, 276–283
variations in position and contour of, BP60
veins of, 296
- Straight arteries**, 279, 294–295
- Straight gyrus**, 118
- Straight sinus**, 110, 114–115, 117, 120, 155–157
imaging of, BP31, 159
- Straight veins**, 297
- Stratum basale**, BP1
- Stratum corneum**, BP1
- Stratum granulosum**, BP1
- Stratum lucidum**, BP1
- Stratum spinosum**, BP1
- Stretch receptors (Hering-Breuer reflex)**, 214
- Stria medullaris**, 125
of thalamus, 117
- Stria terminalis**, 117, 122–123
- Striate artery, long medial**, 148, 150–153
- Striated muscle**, BP41
- Stroma**, BP97
- Styloglossus muscle**, T2.8, 49, 57, 68, 70, 78, 81, 139
- Stylohyoid ligament**, 22, 70, 72, 78, 81
- Stylohyoid muscle**, T2.8, 32, 35–36, 41, 49, 53, 57, 59, 68–70, 75, 81, 134
- Styloid process**, BP24, 13, 17, 21–23, 25, 36–37, 41, 49, 69–70, 75, 79, 81, 107
- Stylomandibular ligament**, 22, 25, 60
- Stylomastoid artery**, 76, 107
posterior tympanic branch of, 107
stapedial branch of, 107
- Stylomastoid foramen**, BP29, 17, 19, 134, 136
- Stylopharyngeus muscle**, T2.8, 68, 70, 72, 75–76, 78, 80–81, 136–137
- Subacromial bursa**, 412, 421
- Subaponeurotic space, dorsal**, 453
- Subarachnoid space**, 100, 111, 113, 120, 177
- Subcallosal area**, 117, 130
- Subcallosal gyrus**, 117
- Subcapsular lymphatic plexus**, 319
- Subchondral bone**, BP114, BP5
- Subclavian artery**, BP23, 4, 37, 39–40, 76, 82–84, 87, 89, 141, 147, 149, 176, 189, 195–196, 204, 215–216, 236, 240, 258, 266, 417–419
grooves for, BP46
left, 88, 179, 210, 217–218, 235, 245
lung groove for, 205
right, BP23, 88, 137, 179, 210, 234
- Subclavian lymph nodes**, 190–191
- Subclavian lymphatic trunk**, 212
- Subclavian node**, 85
- Subclavian region**, 2
- Subclavian trunk**, 85
right, 268
- Subclavian vein**, T2.2, 5, 37, 39–40, 84, 87, 195–196, 204, 212, 215–216, 236, 241, 259, 417, 419
grooves for, BP46
left, 88, 179, 210, 235
right, 88, 179, 210, 234
- Subclavius fascia**, 416
- Subclavius muscle**, T7.5, T2.8, BP46, 188, 195, 221, 234–235, 408, 414, 416, 419
fascia investing, 416
groove for, 408
- Subcostal muscles**, T4.3, 261
- Subcostal nerve**, T5.2, 169, 269, 311–312, 391, 396, 486–488
anterior branch of, 487
cutaneous branch of
anterior, 260
lateral, 257, 269, 473
lateral branch of, 487
- Subcostal plane**, 251
- Subcostal vein**, 267
- Subcutaneous artery**, BP1
- Subcutaneous bursa**, 520
lateral malleolus of, 520
- Subcutaneous fat, radiology of**, 165
- Subcutaneous olecranon bursa**, 428
- Subcutaneous space, dorsal**, 453
- Subcutaneous vein**, BP1
- Subdeltoid bursa**, 412
- Subdiaphragmatic lymph nodes, pathway to**, 190
- Subhiatal fat ring**, 239
- Sublime tubercle**, 426
- Sublingual artery**, 53, 70
- Sublingual fossa**, 24
- Sublingual gland**, BP22, BP40, 50, 53, 59, 65, 69, 134, 144, 172
innervation to, 173
- Sublingual nerve**, 59
- Sublingual vein**, 53, 70
- Sublobular veins**, 285–286
- Submandibular duct (of Wharton)**, 53, 65, 68–70
- Submandibular fossa**, 24
- Submandibular ganglion**, BP40, 53, 59, 70, 82, 133–134, 142, 144, 173
schema of, 144
- Submandibular glands**, BP40, 8, 32, 34, 36, 38, 53, 59, 69, 79, 83–84, 134, 144, 172
innervation to, 173

- Submandibular node**, 85–86
- Submental artery**, 57, 83
- Submental node**, 85–86
- Submental vein**, 38, 84
- Submucosa**
- esophageal, 239
 - of ileum, 279
 - of intestine, 308
 - of jejunum, 279
- Submucosal glands**, 308
- Submucosal (Meissner's) plexus**, 308
- Submucous space**, 374–375, 378
- Suboccipital nerve**, 29, 184
- Suboccipital triangle**, 184
- Subparotid node**, 85
- Subperiosteal circumferential lamellae**, BP7
- Subpleural capillaries**, BP49
- Subpleural lymphatic plexus**, 212
- Subpopliteal recess**, 498–499
- Subpubic angle, radiograph of**, 335
- Subscapular artery**, BP23, BP100, 417–419, 424
- Subscapular fossa**, 409
- of scapula, 192
- Subscapular lymph nodes**, 190–191
- Subscapular nerve**
- lower, 414, 417, 420, 468
 - upper, 414, 419–420
- Subscapularis muscle**, BP56, T7.6, 186, 197, 245–247, 409, 412, 414–417, 421, 423
- Subscapularis tendon**, 412, 415, 417
- Subserous fascia**, 394
- Subserous neural plexus**, 308
- Substantia nigra**, 118, 128
- Subsynovial arteries**. *See* Retinacular arteries
- Subtendinous bursa**, 502, 520
- of subscapularis muscle, 412
- Subungual space**, 460–461
- Sulcal artery**
- central, 153
 - precentral, 153
 - prefrontal, 153
- Sulcal central vein**
- anterior, 178
 - posterior, 178
- Sulcus**
- calcarine, 116–118, 122, 131
 - central
 - of insula, 116
 - of Rolando, 116–117
 - cingulate, 117
 - collateral, 117–118
 - of corpus callosum, 117
 - frontal
 - inferior, 116
 - superior, 116
 - hippocampal, 123
 - hypothalamic, 117, 125, 158
 - intertubercular, 409
 - lateral (of Sylvius), 116, 118
 - anterior ramus of, 116
 - ascending ramus of, 116
 - posterior ramus of, 116
 - lunate, 116
 - marginal, 117
 - median, 71, 125
 - nasolabial, 8
 - occipital, transverse, 116
 - occipitotemporal, 117–118
 - olfactory, 118
 - orbital, 118
 - paracentral, 117
 - parietooccipital, 116–117
 - postcentral, 116
 - rhinal, 117–118
- Sulcus** (*Continued*)
- temporal
 - inferior, 116, 118
 - superior, 116
 - terminal, 71
- Sulcus limitans**, 125
- Sulcus terminalis**, 218
- Superciliary arch**, 8
- Superficial capsular tissue**, BP102
- Superficial circumflex iliac vein**, BP107, 249
- Superficial epigastric veins**, BP107, 249
- Superficial fascia**, BP88, BP1, 33, 255, 349, 359
- deep membranous layer of, 363
 - deeper membranous layer of, 362
 - fatty layer of, 324
 - membranous layer of, 324
 - penile, BP88
 - of penis, 252–253
 - of scalp, 10
 - superficial fatty (Camper's) layer of, 359, 362
- Superficial fibers**. *See* Tibial collateral ligament
- Superficial fibular nerve**, BP111, 514
- Superficial inguinal nodes**, T8.2
- Superficial temporal artery**, 49, 57
- Superficial vein**, T8.2
- of forearm, 406
 - lateral, of penis, 363
 - of neck, 38
- Superficialis flexor tendons**, 453
- Superior, as term of relationship**, 1
- Superior articular facet, of L5**, BP36
- Superior articular process**, 164, 167
- facets of, 166
 - of L1, BP37
 - of L2, 165
 - of L4, BP37
- Superior bulb, in jugular fossa**, 19
- Superior cervical ganglion**, BP39
- Superior cervical sympathetic cardiac nerve**, 142
- Superior cluneal nerves**, 257
- Superior costal facet**, 163
- Superior costotransverse ligament**, BP33
- Superior fascia, of pelvic diaphragm**, 350, 359
- Superior gemellus muscle**, T8.6, 481, 485
- Superior hypogastric plexus**, BP39
- Superior laryngeal vein**, 80
- Superior mediastinum**, BP3
- Superior mesenteric artery**, 276
- Superior mesenteric ganglion**, BP41, BP39, 173
- Superior mesenteric plexus**, 39–40
- Superior oblique muscle**, 132
- Superior petrosal sinus**, 64
- Superior pubic ramus**, 250
- Superior rectus muscle**, 132
- Superior suprarenal artery, left**, 201
- Superior vena cava vein**, 5
- Superior vertebral notch**, 163
- of L3 vertebra, BP37
- Superolateral nodes**, 389
- Superomedial nodes**, 389
- Supinator muscle**, T7.6, 409, 430, 435, 437–441, 463, 469
- Supraclavicular nerves**, 9, 38–40, 140, 404–405
- intermediate, 404–405
 - lateral, 404–405
 - medial, 404–405
- Supraclavicular nodes**, 85
- Supracondylar ridge**
- lateral, 409–410, 426
 - medial, 409–410, 426
- Supradiaphragmatic fascia**, 239
- Supraduodenal artery**, 290–291, 293–294
- Supraglenoid tubercle**, 409
- Suprahyoid artery**, 70, 83
- Suprahyoid node**, 85
- Suprlevator space**, 374
- Supramarginal gyrus**, 116
- Supramastoid crest**, 13
- Supraoptic recess**, 117
- Supraopticohypophyseal tract**, 158
- Supraorbital artery**, 10, 42, 57, 94, 99, 149
- Supraorbital margin**, BP17, 12
- Supraorbital nerve**, 9, 42, 61, 94, 133
- lateral branch of, 97–98
 - left, 98
 - medial branch of, 97–98
- Supraorbital notch**, 8, 11, 13
- of newborn, 21
- Supraorbital vein**, 10, 84, 99
- Suprapatellar bursa**, 498, 502
- Suprapatellar synovial bursa**, 499
- Suprapineal recess**, 117
- Suprupleural membrane (Sibson's fascia)**, 234
- Suprarenal arteries**
- inferior, 266, 323
 - middle, 266, 313, 323
 - superior, 266, 313, 323
- Suprarenal glands**, BP41, BP10, 278, 284, 288, 311–324, 368
- arteries of, 323
 - autonomic nerves of, 322
 - cross section, 323
 - innervation to, 172
 - left, 203, 273, 311, 330
 - right, BP56, 203, 275, 311, 322
 - veins of, 323
- Suprarenal impression**, 284
- Suprarenal plexus**
- left, 305
 - right, 300
- Suprarenal vein**, 323
- left, 241
 - inferior, 267, 313
 - right inferior, 267
- Suprascapular artery**, BP23, T7.2, 39–40, 87–89, 149, 417–419
- infraspinous branch of, 418
- Suprascapular foramen**, 412, 415, 417–418
- Suprascapular nerve**, 417, 419–420, 468
- Suprascapular notch, of scapula**, 192
- Suprascapular region**, 3
- Supraspinatus muscle**, BP56, T7.6, 180, 183, 409–410, 412–418, 422, 468, 470
- Supraspinatus tendon**, T7.1, 412, 415, 417, 422, 470
- Supraspinous fossa**, 410
- of scapula, 192
- Supraspinous ligament**, 29, 167–168, 185, 337–338
- radiology of, 165
- Suprasternal space (of Burns)**, 32–34, 77
- Supratonsillar fossa**, 72
- Supratrochlear artery**, 10, 42, 57, 94, 99, 149
- Supratrochlear nerve**, 9, 42, 61, 94, 97–98, 133
- Supratrochlear node**, 407
- Supratrochlear vein**, 10, 84
- Supraventricular crest**, 224, 228
- Supravesical fossa**, 256
- Sural branches**, 509
- Sural nerve**, BP111, T8.2, 115–116, 474, 531–533
- calcaneal branches of, lateral, 474
 - lateral calcaneal branch of, 509
- Surface anatomy**
- of female, 2
 - of male, 3
- Suspensory (diaphragmatic) ligament**, 368
- of axilla, 416
 - of clitoris, 359, 361
 - of ovary, 345–346, 355–357, 371, 382
 - of penis, 253, 349
- Suspensory retinacula, of breast**, 188

Sustentaculum tali, BP116, 516–517
Sutural (wormian) bone, 13, 16
Sweat glands, BP41, BP1
 innervation to, 172
 in perianal skin, 375
 pore of, BP1
Sympathetic fibers, 309
 of autonomic reflex pathways, 307
 of kidneys and upper ureters, 321
 of lower ureter, 399
 postganglionic, 232
 postsynaptic, BP41
 presynaptic, BP41
 of renal artery, T5.2
 in reproductive organs, 397
 male, 398
 of tracheobronchial tree, 214
 of urinary bladder, 399
Sympathetic ganglion, 177, 186, 197, 391–392, 396–398
 sacral
 left, 394
 right, 394
 thoracic, fourth, 231
Sympathetic nerves, BP16, 214
Sympathetic nervous system, BP39
 general topography, BP39
 schema of, 172
Sympathetic plexus, 64
Sympathetic trunks, 33, 49, 62, 76, 83, 136, 142, 144–145, 197, 201, 213–214, 234–235, 243, 261, 265, 269, 299–300, 309, 320, 322, 344, 348, 391–392, 394, 396–399, 488–489
 cervical, 243
 ganglia of, 320
 left, 200, 220, 310, 322
 right, 200, 310, 322, 394
 sacral, 399
 left, 394
 right, 394
Symphyseal surface, 338, 476
Synapses, BP11
Synaptic cleft, BP11
Synaptic endings, schematic of, BP11
Synaptic vesicles, BP11
Synchondrosis, of 1st rib, 408
Synovial bursa. *See* Suprapatellar bursa
Synovial cavities, BP33, 30
Synovial joints, BP114, BP5
Synovial membrane, BP6, 412, 428, 460–461, 498–499, 502
 attachment of, 499
 protrusion of, 477
Synovium, BP114, BP5
 covering femur, BP114
 cut edge of, BP114

T

Taenia

fibers of, 376
 free, 373, 376

Talar articular surface, 517

Talocalcaneal ligament, 517

lateral, 518
 medial, 518

posterior, BP116, 517–518

Talofibular ligament

anterior, BP116, 505, 518
 posterior, 505, 517–518

Talonavicular ligament, dorsal, 518

Talus bone, BP116, 515–517, 535

posterior process of, 518

Tarsal artery

lateral, 503, 512, 521, 527
 medial, BP115, 503, 512, 521–522, 527

Tarsal bones, BP4

Tarsal glands, 94

openings of, 94

Tarsal (Müller's) muscle, superior, T2.1, 94

Tarsometatarsal joint, 515

Tarsometatarsal ligaments

dorsal, 518, 527
 plantar, 519

Tarsus

inferior, 94
 superior, 94, 96

Taste buds, 71

Taste pathways, schema of, 146

Tectal plate, 117, 125

Tectorial membrane, BP19, 30, 109

deeper (accessory) part of, 30

Tectospinal tract, BP43, 143

Tectum, imaging of, 160

Teeth, BP9, 73–74

apical foramina of, 74
 bone around, 74
 canine, 73–74
 cement of, 74
 crown of, 74
 dental pulp of, 74
 dentinal tubules of, 74
 dentine of, 74
 enamel of, 74
 incisor, 73–74
 interglobular spaces of, 74
 interproximal spaces of, 74
 molar, 73–74
 neck of, 74
 odontoblast layer of, 74
 permanent, 73–74
 premolar, 73–74
 root of, 51, 74

Tegmen tympani, BP28, 105–106

Temporal artery

anterior, 153
 deep, 58, 83, 111
 anterior, 57, 60
 posterior, 13, 57, 60
 middle, 10, 111, 153
 polar, 153
 posterior, 153
 superficial, 41–42, 53, 57–58, 60, 63, 76, 82–84, 107, 111–112, 145, 147, 149
 frontal and parietal branches of, 111
 frontal branch of, 10, 99
 parietal branch of, 10

Temporal bone, BP17, 11, 13, 15, 17–18, 22

acoustic meatus of
 external, BP17, 13, 17
 internal, 15
 articular tubercle of, 13, 17
 asterion of, 13
 carotid canal of, 17
 cochlear window of, 21
 external occipital protuberance of, 13
 inferior tympanic canaliculus of, 17
 jugular fossa of, 17
 lambdoid suture of, 13
 mandibular fossa of, 13, 17, 21
 mastoid canaliculus of, 17
 mastoid foramen of, 17
 mastoid notch of, 17
 mastoid process of, 13, 17
 of newborn, 21
 occipital artery of, groove for, 17
 oval window of, 21
 petrosquamous fissure of, 21
 petrotympanic fissure of, 17
 petrous part of, BP29, 12, 15, 17–18, 21, 110
 arcuate eminence of, 18
 greater petrosal nerve of, groove for, 18
 internal carotid artery in, 148

Temporal bone (Continued)

lesser petrosal nerve of, groove for, 18
 sigmoid sinus of, groove for, 18
 superior petrosal sinus of, groove for, 18
 trigeminal impression of, 18
 posterior deep temporal artery of, groove for, 13
 sigmoid sinus of, groove for, 15
 squamous part of, 13, 15, 18, 21
 styloid process of, 13, 17, 21
 styломastoid foramen of, 17
 superior petrosal sinus of, groove for, 15
 supramastoid crest of, 13
 tympanic part of, 21
 vestibular aqueduct of, opening of, 15
 zygomatic process of, 13, 17, 21, 58

Temporal fascia, 31, 34, 55, 59

deep layer of, 55

superficial layer of, 55

Temporal fossa, 13, 22

Temporal gyrus

inferior, 116, 118
 middle, 116
 superior, 116

Temporal line

inferior, 13
 superior, 13

Temporal lobe, 50, 124, 152

imaging of, 160

medial, BP32

Temporal nerve, deep, 82, 133

anterior, 57, 59–60

posterior, 57, 59–60

Temporal pole, of cerebrum, 116, 118

Temporal region, 3

anterior, 2

Temporal retinal arteriole

inferior, 103
 superior, 103

Temporal retinal venule

inferior, 103
 superior, 103

Temporal sulcus

inferior, 116, 118
 superior, 116

Temporal vein

deep, 111
 middle, 10, 111
 superficial, 53, 60, 84, 111
 frontal and parietal tributaries of, 111
 frontal branch of, 10
 parietal branch of, 10
 tributary of, 113

Temporalis muscle, T2.9, 34, 50, 55, 59–60, 111, 113

Temporalis tendon, 53

Temporofacial division, 54

Temporomandibular joint, T2.1, 25, 56

articular disc of, 55–56

capsule of, 58, 60

joint capsule of, 24–25

Temporomandibular ligament, lateral, 25

Tendinous arch, 81

of levator ani muscle, 339, 342–343, 347, 350, 352–353, 360, 374

of pelvic fascia, 347, 352

Tendinous intersection, 187, 249, 253–254, 333

Tendocalcaneus bursa, 510

Tendon sheath, 452

of ankle, 520
 of finger, 450–451, 453

of hand, 453

Tendons, BP8

of ankle, 518

of foot, 519

Tenon's capsule, BP26, 100

Tensor fasciae latae muscle, BP109, 85–86, 400–401, 471, 481–482, 484, 490–493, 496

Tensor tympani muscle, T2.9, BP27, 59, 106–107
nerve to, 133

Tensor tympani tendon, 107

Tensor veli palatini muscle, T2.9, 56, 59, 67, 72, 78, 81, 106
nerves to, 60, 133
tendon of, 67, 78

Tensor veli palatini tendon, 67, 72

Tentorial artery, 115

Tentorium cerebelli, 97, 114–115, 155–156

Teres major muscle, T7.6, BP100, 161, 180, 183, 186, 246–247, 409–410, 413–414, 416–419, 421–423, 425, 468

Teres major tendon, 422

Teres minor muscle, T7.6, 180, 183, 197, 245–246, 410, 413–418, 422, 468

Teres minor tendon, 412, 415, 422

Terminal bronchiole, BP49

Testicle, 369

Testicular artery, BP98, BP109, 266, 300, 311, 313, 369, 385, 391, 398

Testicular plexus, 391, 398

Testicular vein, 256, 262, 264, 298, 311, 313, 316
covered by peritoneum, 263

Testicular vessels, 348, 383, 390
in spermatic cord, 383

Testis, BP93, BP10, 324, 349, 368–369, 371–372, 390, 398
appendix of, 371
arteries of, 383
descent of, 368
external spermatic fascia over, 387
lobules of, 372
mediastinum of, 369, 372
rete, 372
tunica albuginea of, 369
tunica vaginalis, 369
parietal layer of, 372
visceral layer of, 372
veins of, 383

Thalamic veins, superior, 157

Thalamogeniculate arteries, 154

Thalamoperforating arteries, 151, 154

Thalamostriate vein
inferior, 155, 157
superior, 117, 122, 156–157

Thalamotuberal artery, 151

Thalamus, 119, 121–125, 156, 158, 303
geniculate bodies of, 154
imaging of, 160
left, 155
pulvinar of, 150, 154, 156
stria medullaris of, 117, 122
ventral posteromedial nucleus of, 146

Theca externa, BP95

Theca interna, BP95

Thenar eminence, 402

Thenar muscles, 447, 449–450, 466

Thenar space, 450–451, 453

Thigh
arteries of, BP108, 490, 492
deep vein of, BP107
fascia lata of, 353, 359, 362–363
medial, 2
muscle of, 482, 484–485
bony attachments of, 480–481
nerves of, 490, 492
serial cross sections, 496

Thoracic aorta, 41–42, 177, 197, 200, 220, 235–236, 240
descending, BP57, 244, 247–248
lung groove for, 205

Thoracic aortic plexus, 213

Thoracic artery
inferior, esophageal branch of, 240
internal, BP23, 41–42, 88, 149, 189, 196–197, 204, 210, 215–216, 220, 236, 246–248, 258, 418
anterior intercostal branches of, 195
left, 199–200, 235
medial mammary branches of, 189
perforating branches of, 189, 194, 196, 417
right, 199–200, 234
lateral, BP100, 189, 194–195, 258, 417–419, 424
superior, BP100, 195, 418–419, 424

Thoracic cage, BP4

Thoracic cardiac branches, 213, 231, 243

Thoracic cardiac nerves, 199

Thoracic cavity, BP3

Thoracic constriction, 237

Thoracic duct, BP56, BP84, T2.3, 7, 85, 195, 200, 204, 210, 212–213, 215, 220, 235–236, 241–242, 245–248, 268, 300, 324, 328

Thoracic ganglion
first, 172
fourth, 230
second, 231
section through, 177
sixth, 213
third, 230, 243

Thoracic intervertebral discs, T8-9, 200

Thoracic kyphosis, 162

Thoracic nerve, 417
internal, 258
lateral, 419
long, T7.1, T4.1, 189, 194–195, 260, 417
posterior ramus of, 197
superior, 417

Thoracic region, lateral, 2

Thoracic spinal cord, 214

Thoracic spinal nerves
T1, 143–145, 169
dermatome of, 171
vertebrae relation to, 170
T2, 144–145
dermatome of, 171
vertebrae relation to, 170
T3
dermatome of, 171
vertebrae relation to, 170
T4
dermatome of, 171
vertebrae relation to, 170
T5
dermatome of, 171
vertebrae relation to, 170
T6
dermatome of, 171
vertebrae relation to, 170
T7
anterior ramus, 396
dermatome of, 171
dorsal rootlets of, 169
vertebrae relation to, 170
T8
dermatome of, 171
dorsal rootlets of, 169
vertebrae relation to, 170
T9
dermatome of, 171
vertebrae relation to, 170
T10
anterior ramus, 392
dermatome of, 171
vertebrae relation to, 170
T11
anterior ramus, 396
dermatome of, 171

Thoracic spinal nerves (Continued)
T12, 169
dermatome of, 171
dorsal rootlets of, 169
vertebrae relation to, 170
typical, 186

Thoracic splanchnic nerves, 232
greater, 261, 269
left greater, 305
lesser, 261, 269

Thoracic sympathetic trunk ganglion, first, 143

Thoracic trunk ganglion
lower, 232
upper, 232

Thoracic vein
internal, 88, 195–196, 198, 204, 216, 220, 246–248, 259
left, 200
perforating branches of, 196
perforating tributaries to, 259
right, 200
lateral, 259
perforating branch of, 197

Thoracic vertebrae, 162–163
L1, body of, 167
T1, 22, 29
anterior view of, 162
inferior articular facet for, 22
lateral view of, 162
posterior view of, 162
spinal nerve relation to, 170
spinous process of, 203
T2, spinal nerve relation to, 170
T3, spinal nerve relation to, 170
T4, spinal nerve relation to, 170
T5, spinal nerve relation to, 170
T6
lateral view of, 163
spinal nerve relation to, 170
superior view of, 163
T7
posterior view of, 163
spinal nerve relation to, 170
T8, 220
posterior view of, 163
spinal nerve relation to, 170
T9, 165
posterior view of, 163
spinal nerve relation to, 170
T10, spinal nerve relation to, 170
T11, spinal nerve relation to, 170
T12, 217
lateral view of, 162–163
posterior view of, 162
spinal nerve relation to, 170
spinous process of, 413
vertebra, BP36

Thoracic visceral nerves, BP39

Thoracic wall
anterior, 194–195
internal view of, 196
internal, veins of, 198

Thoracoabdominal nerves, 261
anterior root of, 261
collateral branch, 261
communicating branch, 261
cutaneous branch of, 194
anterior, 261
lateral, 261
lateral branch of, 261
medial branch of, 261
meningeal branch of, 261
posterior ramus of, 261
posterior root of, 261

Thoracoacromial artery, BP100, 194–195, 416, 418–419, 424
 acromial branch of, 418–419, 424
 clavicular branch of, 418–419, 424
 deltoid branch of, 413, 418–419, 424
 pectoral branch of, 418–419, 424

Thoracoacromial vein, acromial branch of, 405

Thoracodorsal artery, BP23, BP100, 417–419, 424

Thoracodorsal nerve, 414, 417, 419–420

Thoracodorsal vein, BP99

Thoracoepigastric vein, 252, 259

Thoracolumbar fascia, 180, 182–183, 185, 257, 312
 anterior layer, 182, 185
 middle layer, 185
 posterior layer, 181, 185

Thoracolumbar spinal cord, 306

Thoracolumbar spine
 anteroposterior radiograph of, 165
 L3
 inferior end plate of, BP36
 superior end plate of, BP36
 lateral radiograph of, BP36
 radiographs of, BP36

Thorax, 187–248
 autonomic nerves in, 213
 bony framework of, 192
 coronal CTs in, BP57
 coronal section of heart and ascending aorta, BP56, 221
 cross section of
 at T3–4 disc level, 246
 at T3 level, 245–248
 at T4–5 disc level, 247
 at T7 level, 248
 nerves of, 230
 surface anatomy of, 187

Thumb, 447

Thymus, BP10, 7, 215, 234–235, 244, 246
 lung area for, 205

Thyroarytenoid muscle, T2.9, 91–92
 action of, 93
 thyroepiglottic part of, 91–92

Thyrocerical trunk, BP23, 39–41, 76, 82–83, 87–89, 147, 149, 236, 240, 418
 left, 179
 right, 179

Thyroepiglottic ligament, 90

Thyrohyoid membrane, 35, 75, 77–78, 80–81, 87, 89–90, 92

Thyrohyoid muscle, T2.9, 32, 35–36, 38, 69, 92, 139–140
 branch to, 41
 nerve to, 82, 140

Thyroid artery
 inferior, 22–23, 40–41, 76, 87–89, 147, 149, 230, 418
 superior, 38, 41, 76, 83, 87–89, 147, 149
 laryngeal branch of, 41

Thyroid articular surface, 91–92

Thyroid cartilage, T2.1, 8, 22, 32, 35, 38, 77–78, 80–81, 87, 92, 202, 208, 210, 237–238
 inferior horn of, 90
 lamina of, 90–91
 posterior border of, 75
 oblique line of, 35
 superior horn of, 75, 80–81, 90

Thyroid gland, T2.2, BP10, 33, 35, 38, 40, 76–77, 84, 89, 92, 202, 204, 210, 221
 anterior view of, 87
 fibrous capsule of, 89
 isthmus of, 87
 left lobe of, 87, 89
 posterior view of, 88

Thyroid gland (Continued)
 pyramidal lobe of, 87
 right lobe of, 87–89

Thyroid ligament, posterior, 89

Thyroid nodes, superior, 85

Thyroid notch, superior, 90

Thyroid vein
 inferior, 38, 84, 87–89, 204, 215
 internal, 241
 middle, 38, 84, 87, 89
 superior, 38, 84, 87, 89, 92

Thyropharyngeus muscle, 80

Tibia, T8.1, BP113, BP116, BP111, BP4, 501–502, 504–505, 511–512, 514, 517–518, 520, 522, 535
 anterior border of, 471
 articulating surface of, BP114
 condyle of
 lateral, 484, 510
 medial, 498
 medial malleolus of, 520, 522
 superior articular surface of, 499
 synovium covering, BP114

Tibial artery, 514
 anterior, BP110, BP111, BP108, 4, 115–116, 503, 509, 512, 514, 521–522
 posterior, BP110, BP111, BP108, 4, 115–116, 503, 507–509, 513–514, 520, 524–525
 medial calcaneal branches of, 523
 medial malleolar branches of, 513
 posterior medial malleolar branch of, 509
 in tarsal tunnel posterior to medial malleolus, T8.2

Tibial collateral ligament, 483, 501, 512

Tibial nerve, BP111, 115–116, 485, 487, 489, 492, 507–509, 513–514, 531–532
 articular branch of, 531–532
 lateral calcaneal branch of, 532
 medial calcaneal branch of, 474, 523, 531–532
 posterior, 520, 525

Tibial plateau, 501

Tibial recurrent artery, posterior, BP108

Tibial tendon, posterior, BP116

Tibial tuberosity, 482–483, 497–500, 502, 505, 510–511

Tibial vein, 507, 514
 anterior, BP107, 5, 514
 posterior, BP111, 5, 507, 509, 513–514
 medial malleolar branches of, 513

Tibialis anterior muscle, BP116, BP111, 85–86, 471, 484, 497–498, 506, 510–512, 514, 522, 533

Tibialis anterior tendon, BP116, BP111, BP117, 511–512, 522, 527
 tendinous sheath of, 521

Tibialis posterior muscle, BP111, 85–86, 506, 509, 513–514, 532

Tibialis posterior tendon, BP116, 507–509, 513, 518, 525–527

Tibiofibular ligament
 anterior, 505, 518
 posterior, 517–518

Toe
 digital nerves of, dorsal, 473
 fifth, vein of, 473
 great, phalanx of, 519, 528

Toenail, anatomy of, BP117

Tongue, BP35, BP9, 45, 53, 68, 70–72
 apex of, 71
 body of, BP22, 50, 71, 77
 dorsum of, 71
 frenulum of, 53, 65
 imaging of, 160

Tongue (Continued)
 intrinsic muscles of, 71, 139
 inferior longitudinal, 139
 superior longitudinal, 139
 transverse and vertical, 139
 longitudinal lingual muscle of
 inferior, 68
 superior, 68
 lymph vessels and nodes of, 86
 lymphatic drainage of, 86
 root of, 71, 75, 77, 79–80, 91
 transverse muscle of, T2.9
 transversus linguae muscle of, 68
 vertical muscle of, T2.9
 verticalis linguae muscle of, 68

Tonsillar artery, 57, 83

Tonsillar branches, 57

Tonsils, 7, 125

Torus tubarius, 43, 45, 72, 79

Trabeculae, BP7, BP30
 artery of, BP30

Trabecular bone, BP7

Trabecular meshwork and spaces of iridocorneal angle (of Fontana), 101

Trachea, BP41, BP56, BP34, BP44, BP57, 22, 33, 35, 77–79, 81, 87–91, 137, 173, 202, 204, 208, 210–211, 215, 217, 221, 234, 236–238, 240, 245–246
 air within, BP36
 connective tissue sheath of, 208
 cross section through, 208
 elastic fibers of, 208
 epithelium of, 208
 gland of, 208
 innervation to, 172
 lung area for
 left, 205
 right, 205
 lymph vessels of, 208
 nerve of, 208
 small artery of, 208

Trachea air column, BP34

Tracheal bifurcation, 41–42

Tracheal cartilages, 208

Tracheal wall
 anterior, 208
 posterior, 208
 mucosa of, 208

Trachealis muscle, 208

Tracheobronchial lymph nodes, 268
 inferior, 212, 242, 247
 superior, 242, 246
 left, 212
 right, 212

Tracheobronchial tree, innervation of, schema of, 214

Tracheoesophageal groove, 81

Tract of Lissauer. *See* Dorsolateral fasciculus

Tragus, 8, 106

Transpyloric plane, 251

Transversalis fascia, BP59, 185, 254–256, 262–264, 266, 324, 344, 347–348, 350, 359

Transverse acetabular ligament, BP109

Transverse cervical nerves, 38

Transverse colon, 270, 274, 278, 283, 287–289, 295, 297, 330–331

Transverse costal facet, 163

Transverse fasciculi, 449, 523

Transverse fibers, BP6

Transverse foramen, 26
 bony spicule dividing, 27
 septated, 27

Transverse ligament, of atlas, 30

Transverse mesocolon, 270, 273–274, 278, 283, 297
 attachment of, 275

- Transverse plane, 1**
- Transverse process, 163–164, 167–168, 185, 193**
of C6, BP34
cervical, 26, 29
of coccyx, 166
lumbar, 163, 167, 334
L1, 165
L3, BP37
thoracic, 163
- Transverse ridges, 166**
- Transverse sinus, 110, 114–115, 156**
groove for, 15, 18
imaging of, BP31, 159
left, 155
- Transverse vesical fold, 256**
- Transversospinal muscle, 245**
- Transversus abdominis muscle, BP47, BP85, T5.3, 181, 195–196, 254, 256, 258–259, 261–262, 265, 269, 283, 311–312, 344, 348, 486, 488**
aponeurosis of, 255, 258
tendon of origin, 181, 185
- Transversus abdominis tendon, 181**
- Transversus thoracis muscle, T4.3, 186, 195–197, 220**
- Trapeziocapitate ligament, 444–445**
- Trapeziotrapezoid ligament, 444–445**
- Trapezium bone, BP102, BP5, 442–448, 452, 457**
- Trapezius muscle, T3.3, T2.1, BP56, T3.1, T7.6, 8, 32–36, 38, 138, 194–195, 197, 245–248, 257, 402, 408–410, 413–414, 416, 419**
spine of, T3.2, 161, 180, 183–184, 186
- Trapezoid bone, BP102, 442–443, 445–447, 452**
- Trapezoid ligament, 408, 412, 415**
- Triangle**
anal, 362
of auscultation, 161, 257, 413
cystohepatic (Calot's), 287
deltopectoral, 413
inguinal, T5.1, 256, 262
transversalis fascia within, 262
lumbar (of Petit), 161, 180, 257
lumbocostal, 201
sternocostal, 196
suboccipital, 184
urogenital, 362
- Triangular aponeurosis, 454**
- Triangular fold, 72**
- Triangular fossa, 106**
- Triangular ligament**
left, 284
right, 275, 283–284
- Triangular space, 417**
- Triceps brachii muscle, T7.6, 161, 187, 402, 409–410, 413–414, 418–419, 422–423, 425, 427, 440, 468**
lateral head of, 161, 246–247, 402, 413
long head of, 161, 245–247, 402, 410, 413
tendon of, 161, 402
- Triceps brachii tendon, 425, 428, 434–435, 468**
- Tricuspid valve. See Atrioventricular valve, right**
- Trigeminal cave, imaging of, 160**
- Trigeminal ganglion, 59, 61, 66, 97–98, 115, 128, 143–146**
- Trigeminal impression, 18**
- Trigeminal nerve (CN V), T2.2, 60–61, 64, 66, 110, 124, 128, 142, 144–146, 155, 171**
distribution of, 129
ganglion of, 133, 142
imaging of, 160
mandibular division of, 9
maxillary division of, 9
mesencephalic nucleus of, 127–128, 146
motor nucleus of, 127–128, 146
- Trigeminal nerve (CN V) (Continued)**
motor root of, 142
ophthalmic division of, 9
principal sensory nucleus of, 127–128, 133
schema of, 133
sensory root of, 142
spinal nucleus of, 137
- Trigeminal tubercle, 125**
- Trigonal ring, 351**
- Triquetrocipitate ligament, 444**
- Triquetrohamate ligament, 444–445**
- Triquetrum bone, BP102, 442–443, 445–447**
- Triticeal cartilage, 90**
- Trochanter of femur**
greater, BP109, 161, 250, 334, 400–401, 477–478, 483, 485–486, 492–493, 534
radiograph of, 335
lesser, 250, 334, 477–478, 534
radiograph of, 335
- Trochanteric bursae**
of gluteus maximus muscle, 494
inferior extension of, 494
of gluteus medius muscle, 494
- Trochanteric fossa, 479**
- Trochanteric region, 2**
- Trochlea, 96, 409, 426**
- Trochlear nerve (CN IV), BP26, T2.2, 60, 64, 96–98, 115, 124–125, 127–128, 155**
distribution of, 129
schema of, 132
in superior orbital fissure, 20
- Trochlear notch, 426–427, 429**
- Trochlear nucleus, 127–128, 132**
- True ribs, 192**
- Tubal artery, 107**
- Tubal branches**
of ovarian vessels, 386
of uterine artery, 386
- Tuber cinereum, 117–118, 124**
median eminence of, 158
- Tubercle**
anal, 370
anterior, 122
lateral part of, 370
- Tuberophyseal tract, 158**
- Tuberosity, 517**
tibial, 504
- Tufted cell, 130**
- Tunica albuginea, BP95, 363, 367, 372**
of testis, 369
- Tunica vaginalis**
cavity of, 368
testis, 324, 369, 372
parietal layer of, 369
visceral layer of, 369
- Tympanic artery**
anterior, 57–58, 60, 107, 149
inferior, 64, 107
superior, 60
- Tympanic canaliculus, inferior, 17, 19**
- Tympanic cavity, 27–28, 62, 105–107, 109, 135–136**
labyrinthine wall of, BP27
lateral wall of, BP27
- Tympanic cells, BP27**
- Tympanic membrane, 27–28, 59, 105–107, 109**
- Tympanic nerve, 64, 106, 134, 136, 145**
inferior, 107
- Tympanic plexus, 107, 134, 136, 143, 145**
tubal branch of, 136
- Tyson's gland, 364**
- U**
- Ulna, BP102, T7.1, 4–5, 426–433, 435, 439–445, 447, 455, 460**
anterior border of, 429
- Ulna (Continued)**
anterior surface of, 429
coronoid process of, 426
interosseous border of, 429
olecranon of, 402, 422, 426–427, 429, 431, 434–435, 468
radial notch of, 426, 429
styloid process of, 429, 447
tuberosity of, 426
- Ulnar artery, 4, 100–101, 423, 436–438, 441, 444, 449–450, 452, 456, 463**
deep branch of, 444
deep palmar branch of, BP101, 424, 437, 444, 449–450, 455–456, 463
dorsal carpal branch of, 459
palmar carpal branch of, 438, 455
pulses at, 4
- Ulnar collateral artery**
inferior, 100–101, 423, 435
superior, 100–101, 423, 425, 434–435
- Ulnar collateral ligament, BP102, 428**
- Ulnar nerve, T7.1, 404, 419–420, 422–423, 425, 434–438, 441, 444, 450, 452, 455–456, 459, 462–467**
articular branch of, 467
common palmar digital branch of, 463
communicating branches of, 458
deep branch of, 437–438, 449–450, 455–456, 463, 467
dorsal branch of, 404, 406, 434, 437–438, 441, 458–459, 463, 467
groove for, 410, 426
palmar branch of, 404, 406, 437, 449, 462, 467
digital, 404, 462–463
superficial branch of, 437, 449–450, 456, 463, 467
- Ulnar recurrent artery**
anterior, 100–101, 424, 437–438
posterior, 100–101, 424, 434–435, 438
- Ulnar styloid process, 442**
- Ulnar tuberosity, 421, 429**
- Ulnar vein, BP99, 5**
- Ulnocapitate ligament, 444**
- Ulnocarpal ligament**
dorsal, BP102
palmar, BP102, 444
- Ulnolunate ligament, 444**
- Ulnotriquetral ligament, 444–445**
- Umbilical artery, BP98, 233, 256, 317, 380, 382, 384–385**
fibrous part of, 344, 347–348, 384
obliterated, 357
left, 256
occluded distal part of, 384
patent part, 266
right, BP98
- Umbilical fold**
lateral, 344, 348
right, 256
medial, 344, 348, 356, 382
right, 256
median, 344, 348
- Umbilical ligament**
medial, BP98, 233, 254–256, 262–264, 266, 316–317, 344, 347–348, 356, 382, 384
median, BP98, 255–256, 264, 324, 344, 347–348, 350, 356, 382
- Umbilical prevesical fascia, 256, 262, 347, 349**
- Umbilical region, 2, 251**
- Umbilical vein, T5.2, 233**
- Umbilicus, T5.1, 249, 256, 299, 333, 379**
- Umbo, 106, 109**
- Uncal vein, 156**

Uncinate process, 43–44, 51
 cervical, 27
 left, area for articulation of, 27
 right, articular surface of, 27

Uncovertebral articulation, BP34

Uncovertebral joints, 28

Uncus, 28, 117–118, 130

Upper limb, BP4, 402–470
 arteries of, 463
 cutaneous innervation of, 404
 dermatomes, 403
 lymph vessels and nodes of, 407
 lymphatics of, 7
 nerves of, 463–464
 cutaneous, 405
 superficial veins of, 405
 surface anatomy of, 402
 veins of, BP99

Urachus, 344, 349, 359, 382
 median, BP98, 350
 remnant of, 356

Ureter, BP98, T6.1, BP85, 256, 264, 267, 272, 299, 311, 314, 316, 344–350, 353, 355, 366, 373–374, 382–386, 392, 394, 399
 in abdomen and pelvis, 316
 arteries of, 317
 left, 356
 autonomic nerves of, 320
 lower, innervation of, 399
 retroperitoneal space, 356
 right, 316, 357
 as site of referred visceral pain, BP13

Ureteric branch, middle, 320

Ureteric fold, 344, 346, 348

Ureteric orifice, BP90, 356, 366
 left, 352
 right, 352

Ureteric plexus, 392

Ureteropelvic junction, 331

Ureterovesical junction, pubocervical fascia, 354

Urethra, BP41, 89–90, 265, 339–341, 343, 345, 350–352, 354, 356, 360, 363, 365–367, 371, 401
 beginning of, 400
 cavernous venous plexus of, BP90
 female, BP90
 pelvis, 401
 floor of, 367
 hiatus of, 342
 membranous, BP93, BP89, 367
 musculofascial extensions to, 341
 penile, BP93
 prostatic, BP97, BP93, BP89, 367, 400
 pubocervical fascia, 354
 roof of, 367
 spongy, BP89
 bulbous portion of, 352, 367
 pendulous portion of, 367

Urethrae muscle
 compressor, T6.3, 353, 360–361, 386
 sphincter, T6.4, 360

Urethral artery, 365, 387

Urethral branches, BP98

Urethral crest, 366–367

Urethral glands, BP90
 of Littre, 367

Urethral lacunae, of Morgagni, 367

Urethral meatus, external, 349

Urethral orifice, external, BP90, 333, 345, 358, 361, 364, 367, 370, 377

Urethral raphe, 370

Urethral sphincter muscle
 external, BP88, BP98, 256, 349, 351, 365–367, 399
 internal, 351–352, 367
 loop of Heiss, 351

Urethral sphincter muscle (*Continued*)
 posterior loop, 351
 trigonal ring, 351

Urethrovaginalis sphincter muscle, T6.4, 339, 351, 353

Urinary bladder, BP41, 165, 173, 256, 263, 270, 282, 305, 311, 324, 344–350, 356, 365–366, 368, 373, 379, 382, 385, 394, 399
 apex of, 349–350
 autonomic nerves of, 320
 body of, 349–350
 female, 352
 fundus of, 349–350
 innervation of, 172, 399
 interior of, 400
 male, 352
 neck of, BP90, 349–350
 orientation and supports of, 350
 pulled up and back, 350
 trigone of, BP90, 349–350, 366–367
 ureteric orifice of, 350

Urinary fascia, 349

Urinary system, T6.1, T5.1

Urogenital diaphragm, 385

Urogenital fold, 370

Urogenital groove, 370

Urogenital hiatus, 351

Urogenital sinus, 371

Urogenital triangle, 362

Uterine artery, T6.2, 316–317, 356–357, 382, 384
 branches of, 386
 cardinal (Mackenrodt's) ligament with, 347
 vaginal branches of, 386

Uterine cavity, contrast within in, 357

Uterine cycle, BP92

Uterine development, BP94

Uterine fascia, 347

Uterine ostium, 355

Uterine veins, 267
 superior, 381

Uterine vessels, 346, 353, 386
 ovarian branches of, 357

Uterine (fallopian) tube, 344–346, 353–356, 371, 382, 394, 397
 ampulla, 357
 contrast within, 357
 fimbriae of, 357
 folds of, 355
 infundibulum of, 357
 left, 356
 right, 356

Uterosacral fold, 316, 344
 right, 356

Uterosacral ligament, 345, 347, 354–355

Uterovaginal fascia, BP88, 346, 353, 359

Uterovaginal plexus, 394, 396

Uterovaginal venous plexus, 267

Uterovesical pouch, 357. *See also* Vesicouterine (uterovesical) pouch

Uterus, BP88, T6.1, 353, 355, 359, 371, 373, 394, 397
 arteries of, 386
 body of, 345–346, 355
 cervix of, 345–347, 353, 355–356
 endometrium of, 379
 external os of, 357
 fundus of, 344–346, 350, 355, 379
 isthmus of, 355
 ligaments of
 fascial, 354
 round, BP90, 344–346, 352–354, 356, 359, 371, 382
 myometrium of, 379
 round ligament of, 267

Uterus (*Continued*)
 supporting structures, 353
 through overlying peritoneum, 356
 veins of, 386

Utricle, 108–109, 135

Uvula
 of bladder, 366–367
 of palate, 65, 72, 75, 79
 of vermis, 125

V

Vagal fibers, 137

Vagal trigone, 125

Vagal trunk, 265
 anterior, BP40, 137, 213, 236, 243, 300–301, 304–305, 309–310, 320, 322, 392
 gastric branches of, 137
 hepatic branch of, 137
 posterior, BP40, 243, 300–301, 304–305, 309–310, 320, 392

Vagina, BP90, T6.1, 339–341, 345, 350–353, 356, 359–360, 371, 373, 377, 379, 382, 397, 401
 horizontal portion of, 354
 musculofascial extensions to, 341
 pubocervical fascia, 354
 supporting structures, 353
 vertical portion of, 354
 vestibule of, 353, 358, 371

Vaginal arteries, 353, 357, 382, 384, 386
 inferior, 350
 internal, 347
 left, 356

Vaginal fascia, 373

Vaginal fornix, 345
 anterior, 345, 356
 posterior, 356

Vaginal orifice, BP90, 345, 358, 361, 370

Vaginal vein, 381

Vaginal wall, 353–354

Vaginorectal fascial fibers, 347

Vagus nerve (CN X), 33, 39–41, 40–41, 49, 64, 66, 76, 83, 87–89, 115, 124, 127–128, 136, 138, 141–142, 146, 173, 210, 213–215, 231, 236, 243, 306, 321
 auricular branch of, 9, 19, 137
 communication to, 136
 cervical cardiac branch of
 inferior, 137, 230
 superior, 137, 141–142, 230
 distribution of, 129
 dorsal nucleus of, 127, 137
 ganglion of
 inferior, 64, 76, 137–139, 146, 243
 superior, 76, 137–138
 in jugular foramen, 20
 in jugular fossa, 19
 laryngopharyngeal branch of, 141
 left, BP51, 88, 199, 210, 216, 230, 235, 245–246
 meningeal branch of, 137
 pharyngeal branch of, 76, 136–137, 141–142, 243
 posterior nucleus of, 128, 231, 306, 321
 recurrent laryngeal branch of, T4.1
 right, 88, 199, 210, 216, 230, 234, 243, 245
 schema of, 137
 superior ganglion of, 243
 thoracic cardiac branch of, 137, 230–231

Vallate papilla, 71, 146

Vallecula, 71–72

Valves of Houston, 375

Valves of Kerckring, 279, 287. *See also* Circular folds (valves of Kerckring)

- Vas deferens**, 348–349, 352, 366, 368, 371, 373, 385, 391–392, 398. *See also* Ductus (vas) deferens
ampulla of, 366
arteries to, 380, 383, 385
- Vasa vasorum**, BP16
- Vascular smooth muscle, innervation to**, 172
- Vastoadductor intermuscular septum**, 482, 491
cover femoral vessels to popliteal fossa, 490
- Vastus intermedius muscle**, 85–86, 480–483, 498, 529. *See also* Quadriceps femoris muscle
- Vastus intermedius tendon**, 491
- Vastus lateralis muscle**, 85–86, 401, 471, 480–484, 490–491, 496–498, 510–511, 529. *See also* Quadriceps femoris muscle
deep to iliotibial tract, 492
- Vastus medialis muscle**, 85–86, 471, 480–483, 490–491, 496–498, 511, 529. *See also* Quadriceps femoris muscle
nerve to, 490
- Veins**. *See also* specific veins
of abdominal wall
anterior, 259
posterior, 267
of anal canal, 381
of duodenum, 296
of esophagus, 241
of eyelids, 99
of face, 10
of forearm, 406
of hypothalamus and hypophysis, BP30
of iris, 104
of large intestine, 298
of leg, T8.2
of lower limb, BP107
of oral and pharyngeal regions, 84
of pancreas, 296
of pelvis
female, 382
male, BP98, 385
of perineum, male, 387
of posterior cranial fossa, 155
of rectum, 381
of scalp, 10
of small intestine, 297
of spinal cord, 178
of spleen, 296
of stomach, 296
of testis, 383
of thoracic wall, 198
of uterus, 386
of vertebral column, 178
- Vena cava**
groove for, 284
inferior, BP87, BP84, 185, 200, 210, 213, 217–219, 221, 225, 229, 233–234, 236, 241, 267, 273–276, 278, 284, 288, 293, 296, 311–313, 323, 326–332
lung groove for, 205
opening of, 227
valve of, 224
superior, BP51, 87–88, 210, 215–221, 224, 228–229, 233–234, 241, 244, 246–248, 325
lung groove for, 205
superior, 198–199
- Venae comitantes**, 450
- Venae rectae**, 297
- Venous arch**
dorsal, 5, 473
posterior, superficial, 513
superficial palmar, 450
- Venous communications, body of C3**, BP42
- Venous plexus**, BP98, 64, 350, 357, 369. *See also* Pampiniform (venous) plexus
around vertebral artery, 179
basilar, 114–115
cavernous, of urethra, BP90
external, 374, 381
in foramen magnum, 19
internal, 374
pampiniform, T6.2, 383
pharyngeal, 76
prostatic, BP98, 349, 385
rectal
external, 375–376
internal, 375–376
perimuscular, 381
vaginal, 401
vertebral artery with, BP42
vertebral (of Batson), 114
internal, 177
vesical (retropubic), BP98, 349, 352, 385
- Ventral plane**, 1
- Ventral root**, BP38
- Ventricles (cardiac)**, 228
left, BP51, BP57, 216, 218–221, 223–225, 228, 244, 248
branches to back to, 223
posterior vein of, 222
right, BP51, 216–221, 228, 244, 248
- Ventricles (of brain)**, 119, 125
fourth, 117, 125, 157
choroid plexus of, 120, 125
choroidal branch to, 154
imaging of, 160
lateral and median apertures of, 157
outline of, 154
rhomboid fossa of, 124
taenia of, 125
vein of lateral recess of, 155
lateral, 117, 121, 123, 150, 157
central part of, 117
choroid plexus of, 117, 120–121, 150, 154, 156
frontal (anterior) horn of, 117, 160
imaging of, BP32
lateral vein of, 157
medial vein of, 157
occipital (posterior) horn of, 117, 121–123, 154, 157, 160
temporal (inferior) horn of, 117, 119, 122, 157
third, 117, 121–122, 125, 157
choroid plexus of, 117, 119–120
imaging of, BP32, 160
infundibular recess of, 50
tela choroidea of, 119, 122, 156
- Ventricular folds**, 91
- Ventricular veins**
hippocampal, 157
inferior, 157
- Vermian artery, inferior**, 154
- Vermian vein**
inferior, 155
superior, 155, 157
- Vermiform appendix**, BP86, 272, 280–281, 283
orifice of, 281
- Vermillion border**, 8
- Vermis**, 50, 126
imaging of, BP32
inferior
nodule of, 126
pyramid of, 126
tuber of, 126
uvula of, 126
superior
central lobule of, 126
culmen of, 126
- Vermis (Continued)**
declive of, 126
folium of, 126
- Vertebrae**, BP4
lamina of, 244
pedicle of, 244
radiology of, 165
- Vertebral artery**, BP23, 19–20, 29, 39–40, 76, 82, 88–89, 141, 149–152, 176, 179, 184, 230, 240, 418
anterior and posterior meningeal branches of, 112
cervical part of, 147
in foramen magnum, 19
imaging of, 31–32
left, 147, 154, 179
meningeal branches of, 20
anterior, 147, 154
posterior, 147, 154
right, BP42, 147, 179
venous plexus and, BP42, 179
- Vertebral body**, BP38, 177
articular facet for, 193
inferior, 193
superior, 193
transverse, 193
branch to, 177
of C2, 34–35
cervical, BP18, 27–28
of L2, 185
of L3, BP37
lumbar, 164
posterior intercostal artery branch to, 177
posterior surface of, BP33
of S1, 165
of T12, 165
thoracic, 176
fourth, 234
- Vertebral canal**, 163–164
- Vertebral cavity**, BP3
- Vertebral column**, BP4, 162
veins of, 178–179
- Vertebral foramen**, T3.1
cervical, 26–27
lumbar, 164
thoracic, 163
- Vertebral ganglion**, 141, 230–231, 243
- Vertebral ligaments**, BP33
lumbar region, 168
lumbosacral region, 167
- Vertebral notch**
inferior, BP36, 163–164
superior, 164
- Vertebral plexus**, 20, 141
- Vertebral region**, 3
- Vertebral veins**, BP42, 241
accessory, 179
anterior, 179
left, 179
right, 179
- Vertebral venous plexus**, T3.1
anterior, BP42
external, 178
anterior, 179
internal, 178
anterior, 179
- Vesical arteries**
inferior, BP98, 266, 316, 350, 380, 382–385
posterior branches of, 385
internal, 347
superior, BP98, 256, 317, 347, 380, 382, 384–385
- Vesical fascia**, BP88, 346–347, 349, 352, 359, 373, 378
- Vesical fold, transverse**, 344, 348, 356–357

Vesical nodes
 lateral, 319
 prevesical, 319

Vesical plexus, 305, 320, 392, 394, 396, 398–399

Vesical (retropubic) venous plexus, BP98, 267, 385

Vesical veins
 inferior, 381
 posterior branches of, 385
 superior, 267, 381

Vesical vessels, inferior, 390

Vesicocervical fascial fibers, 347

Vesicocervical space, 347

Vesicosacral (sacrogenital) fold, 348

Vesicouterine (utero-vesical) pouch, 345–346, 350, 356–357, 373

Vesicovaginal space, 347

Vesicular appendix, 355, 371

Vessels
 blood, innervation of, 214, 232
 fibers direct to, 232
 of neck, 39–40

Vestibular aqueduct
 internal opening of, 108
 opening of, 15, 20, 110

Vestibular area, 125

Vestibular fold, 92

Vestibular fossa, 358

Vestibular ganglion (of Scarpa), 108, 135

Vestibular gland, greater, 360–361, 371, 386
 opening of, 358
 primordium, 371

Vestibular nerve, BP28, 105, 108, 110, 135
 inferior part of, 108, 110, 135
 superior part of, 108, 110, 135

Vestibular nucleus, 127–128
 inferior, 135
 lateral, 135
 medial, 135
 superior, 135

Vestibular (oval) window, 21, 108

Vestibular (Reissner's) membrane, 109

Vestibule, BP28, 92, 105
 bulb of, BP90, 352, 359–361, 386
 artery of, 353, 361, 386
 of ear, 108–109
 of vagina, 353, 358, 371

Vestibulocochlear nerve (CN VIII), BP28, 20, 60, 76, 105, 108, 110, 124, 127–128, 142
 distribution of, 129
 imaging of, BP32
 schema of, 135

Vestibulospinal tract, BP43

Vincula longa, 454

Vinculum breve, 454

Visceral arteries, BP41

Visceral fascia. *See* Pretracheal (visceral) fascia

Visceral lymph nodes, 268

Visceral peritoneum, 279, 378. *See also* Serosa (visceral peritoneum)

Visceral pleura, BP49

Vitreous body, 100

Vitreous chamber, 103

Vocal fold, BP44, 77, 91–92

Vocal ligament, 90–91

Vocalis muscle, T2.9, 91–92
 action of, 93

Vomer, 11, 15, 17, 45, 49

Vomeronasal organ, 43

Vorticoso vein, 99, 103–104
 anterior tributaries of, 104
 bulb of, 104
 posterior tributaries of, 104

Vulva, 358

W

White blood cells, BP15

White commissure, anterior, BP43

White matter, BP43
 imaging of, BP32, 160
 of spinal nerves, 174

White rami communicantes, BP41, BP39, 141, 143–145, 172, 174, 186, 197, 213, 231–232, 234–235, 243, 269, 300, 303, 306, 321, 392, 394, 397–399, 488

Wirsung, pancreatic duct of, 279

Wolffian duct, 368, 371. *See also* Mesonephric (wolffian) duct

Wormian bone, 13, 16. *See also* Sutural (wormian) bone

Wrisberg, intermediate nerve of, 107, 134, 142, 146

Wrist
 arteries of, 452, 459
 bones of, 446
 cutaneous innervation of, 462
 deeper palmar dissections of, 450
 extensor tendons at, 460
 extensors of, 431
 flexor tendons at, 452
 flexors of, 432
 ligaments of, BP102, 444–445
 movements of, 443
 nerves of, 452, 459
 radiographs of, 447
 superficial dorsal dissection of, 458

Wrist (Continued)
 superficial palmar dissections of, 449
 superficial radial dissection of, 457

X

Xiphoid process, 193, 196, 202, 204, 249–250, 252, 328
 pubic, T5.1
 of sternum, 187, 194

Y

Y ligament of Bigelow. *See* Iliofemoral ligament

Yoke, 18

Z

Zigzag line, 239, 277

Zona orbicularis, 477

Zona pellucida, BP95

Zone of sparse muscle fibers, 238

Zonular fibers, 100–103
 equatorial, 102
 postequatorial, 102
 preequatorial, 102

Zygapophysial joint, BP34, 29, 248
 capsule of, 29–30, 168

Zygomatic arch, BP17, 12–13, 22–23, 55

Zygomatic bone, BP17, 8, 11–13, 17, 50, 94
 frontal process, 11
 of newborn, 21
 orbital surface of, 11
 temporal process of, 11, 13
 zygomaticofacial foramen of, 11, 13, 21

Zygomatic nerve, 61, 63, 98, 132–133
 zygomaticofacial branch of, 82
 zygomaticotemporal branch of, 82

Zygomatic process, 21
 of maxillary bone, 11, 17
 of temporal bone, 13, 17

Zygomaticofacial artery, 10, 99

Zygomaticofacial foramen, 11, 13, 21

Zygomaticofacial nerve, 9, 61, 63, 98

Zygomaticofacial vein, 10

Zygomaticofrontal suture, BP17, 12

Zygomaticoorbital artery, 10, 99

Zygomaticotemporal artery, 10

Zygomaticotemporal nerve, 9, 61, 63, 98

Zygomaticotemporal vein, 10

Zygomaticus major muscle, T2.9, 20–21, 31, 55, 134

Zygomaticus minor muscle, T2.9, 20–21, 31, 55, 134